Journal of Diagnostic Medical Sonography
2023, Vol. 39(1) 62–65
© The Author(s) 2022
Article reuse guidelines:
sagepub.com/journals-permissions
DOI: 10.1177/87564793221112354
journals.sagepub.com/home/jdm
SAGE

Recognition of the Type of Cesarean Scar Pregnancy in First Trimester Sonography

Carlos M. Fernandez, MD[1], Elliot M. Levine, MD[1,2], Abraham Shashoua, MD[1], Irma Sodini, MD[1], Jude Duval, MD[1], and Jacqueline Juna, MD[1]

Abstract

This case series is presented to illustrate the clinical value of identifying, sonographically, the type of cesarean scar ectopic pregnancy that may present, as this has become more frequently encountered. The choice of surgical treatment appears to be dependent on the sonographic typing, of this specific type of ectopic pregnancy. This case study illustrates the importance of this topic, given the rising incidence of cesarean deliveries coupled with the increase in first trimester sonograms being more commonly performed. The value of proper diagnostic detection is important, given the contemporary management of this new type of ectopic pregnancy.

Keywords

pelvic ultrasound, cesarean scar pregnancy, surgical treatment, management ectopic pregnancy, first trimester pregnancy

The standard of providing first trimester sonography in pregnancy and the rising incidence of cesarean delivery has led to the more commonly recognized cesarean scar pregnancy (CSP). It can occur as the result of implantation of a gestational sac (GS) within a cesarean scar defect or adjacent to it. This represents a new type of ectopic pregnancy (EP), representing 4.2% of all EPs. An ectopic pregnancy occurs in approximately 1% of all pregnancies,[1] and it is known to be associated with significant maternal morbidity (e.g. tubal rupture, hemorrhage, and subsequent infertility).[2] The sonographic recognition of the type of such a cesarean scar defect implantation and its consequential surgical treatment has now led to the accumulation of data regarding the optimal treatment of CSP, according to the classification as to its type.[3] Rather than from case-control studies, much of the current information has resulted from the publication of case series. A type I (CSP-I) is caused by implantation of the GS on a previous cesarean scar with progression toward either the cervicoisthmic space or the uterine cavity. A type II (CSP-II) is caused by deep implantation of the GS into a previous cesarean scar defect with infiltrating growth, into the uterine myometrium, and bulging from the uterine serosal surface. Uterine rupture and severe intrauterine and vaginal bleeding can therefore possibly occur during the first trimester of this pregnancy. When recognized, its treatment can potentially prevent this from occurring. A variety of surgical treatments for this have been described and updated to avoid the predicted risks which can occur.[4,5] Surgical treatments may sometimes be necessary, in addition to methotrexate (MTX) administration, which is commonly prescribed for medical management of EP.[6,7]

Recent clinical experience with cases of CSP has caused the authors to describe the sonographic identification and surgical treatment of this relatively new phenomenon and to share it with other interested specialists.

Case Series

Case Report 1

The patient was a 33-year-old G_5P_{2032} female, with 2 previous cesarean sections done because of a history of an open myomectomy. A hemicolectomy had been previously

[1]Advocate Illinois Masonic Medical Center, Chicago, IL, USA
[2]University of Illinois at Chicago, Chicago, IL, USA

Received January 3, 2022, and accepted for publication June 13, 2022.

Corresponding Author:
Elliot M. Levine, MD, Advocate Illinois Masonic Medical Center, 3000 N. Halsted, Suite 500, Chicago, IL 60657, USA.
Email: Elliot.levine@aah.org

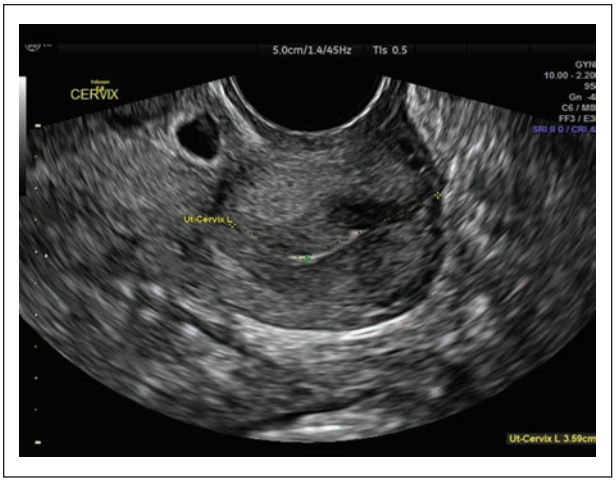

Figure 1. Transvaginal sonography completed in case report 1 that demonstrated a cesarean scar pregnancy with an empty endocervical canal.

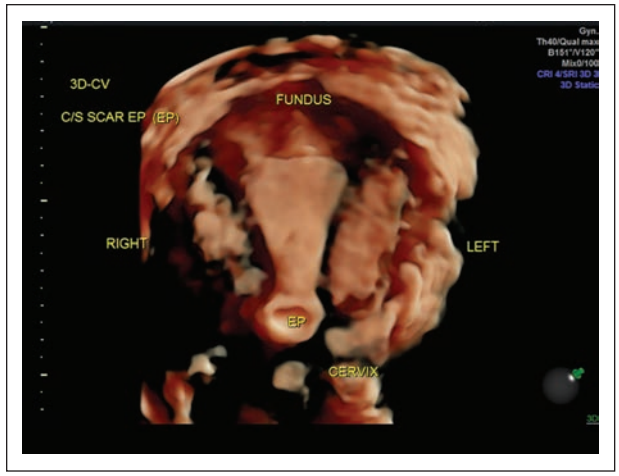

Figure 2. Three-dimensional high-definition live rendering of case report 1 that demonstrated a cesarean scar pregnancy with an empty endometrial cavity and an empty endocervical canal.

performed secondary to appendiceal carcinoid. Patient denied any vaginal bleeding or pelvic pain. Quantitative human chorionic gonadotropin (hCG) was 10 818 mIU. A live CSP-Type II (cardiac motion detected) was confirmed via sonography. A robotic resection of the CSP with lysis of adhesions was performed. The patient also received MTX and her postoperative course was uneventful (see Figures 1 and 2).

Case Report 2

The patient was a 33-year-old G_5P_{3013} female, with a past vaginal delivery and 2 previous cesarean section deliveries, having complaints of vaginal bleeding. A live CSP-Type II (cardiac motion detected) was confirmed via sonography. Laparoscopy with resection of CSP and repair of isthmocele was performed. The patient's postoperative course was uneventful (see Figures 3–5).

Case Report 3

The patient was a 35-year-old G_7P_{3033} female, with a history of 3 previous cesarean section deliveries. At 9 weeks and 5 days of gestation by last mensural period (LMP), she had complaints of vaginal bleeding but no abdominal pain. She vocalized having a strong desire for fertility preservation. The quantitative hCG was 44 283. A live CSP-Type II (cardiac motion detected) was confirmed sonographically. The patient underwent a laparoscopy with resection of CSP and repair of isthmocele. The patient was not given MTX. Her postoperative course was uneventful (see Figures 6–8).

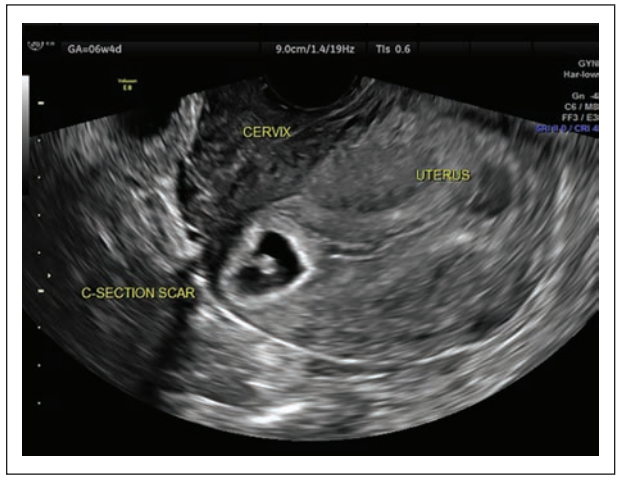

Figure 3. Transvaginal sonography in case report 2 that demonstrated a cesarean scar pregnancy with an empty endometrial cavity and endocervical canal.

Discussion

The epidemic of cesarean deliveries in this country is well-known to practicing obstetrician/gynecologists. This includes its consequence of placenta accreta spectrum (PAS), and now CSP. The sonographic features of the first trimester CSP is less well-known and documented, however, and the treatment dependence of the type of CSP that is identified may be essential for its management. No proper consensus exists as to the ideal management of CSP, though it is well-recognized that transvaginal sonography (TVS) is the best first-line

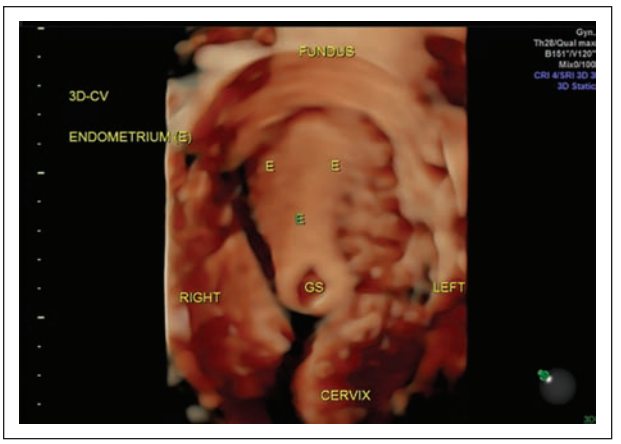

Figure 4. Three-dimensional rendering image in case report 2 that demonstrated a cesarean scar pregnancy with an empty endometrial cavity and endocervical canal.

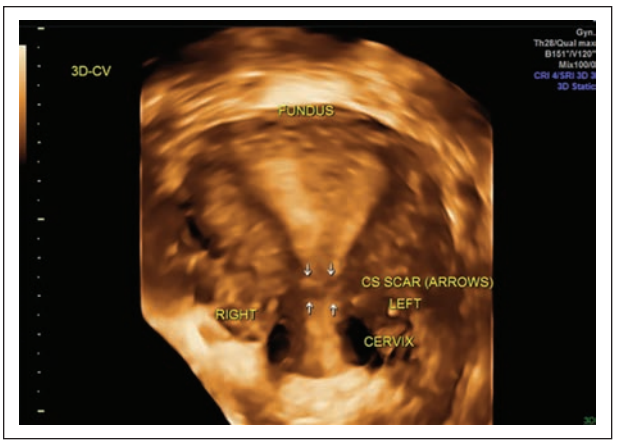

Figure 5. Three-dimensional image of the uterus in case report 2 that demonstrated a well-healed lower uterine segment with no evidence of isthmocele, 4 months after the removal of cesarean scar pregnancy.



Figure 6. Sagittal view of the uterus in case report 3, which demonstrated a cesarean scar pregnancy with collection of blood, within the endometrial cavity.



Figure 7. Sagittal view of the cervix in case report 3, which demonstrated a cesarean scar pregnancy, with an empty endocervical canal.

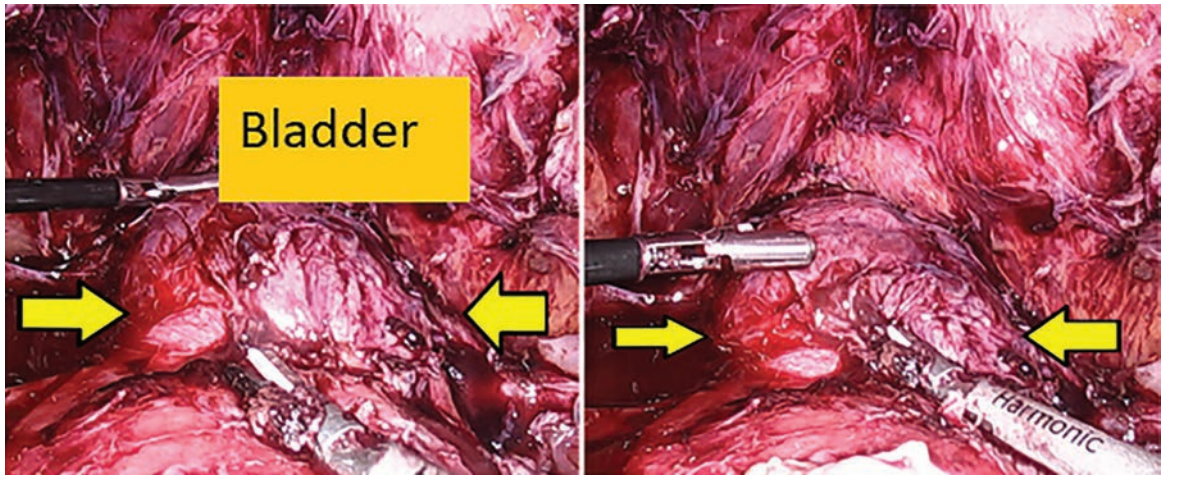

Figure 8. Laparoscopy findings demonstrating a 4 × 4 cm bulging of the cesarean scar pregnancy (seen between the arrows).

diagnostic tool for CSP.[8,9] Its first trimester use for its diagnosis has been encouraged to avoid early hemorrhage associated with the diagnosis.[10] Magnetic resonance imaging (MRI) can be reserved for cases for which there may be a diagnostic uncertainty. The use of color Doppler may enhance its diagnostic acuity.[11] The identification of the type of CSP with first trimester sonography may also be pertinent to patient counseling, as the sort of subsequent surgical treatment may be dependent on the findings.[12] Determining the type of CSP by virtue of recognizing the site of ectopic trophoblast implantation and its relative position with the surrounding tissue is particularly useful in this context. This is especially true when identifying the GS and comparing its position relative to the endometrial cavity and the uterine serosa, if they can be identified. A variety of case series descriptions have been reported in the medical literature, detailing the associated management of CSP.[13–15] It appears that the literature continues to evolve on this subject and future reports will likely be forthcoming. The case series presented here represents another practical manner for the identification of the type of CSP (I or II).

Conclusion

When sonography confirms the type of a CSP that is present, its laparoscopic removal may be indicated, which can allow subsequent wound repair to effectively occur when it is encountered. Laparoscopy can become an effective treatment alternative for CSP-II, as is demonstrated by the sonographic and operative expertise of the case series authors.

Informed Consent

Informed consent was not sought for the present study because all case data were de-identified and/or aggregated and followed ethics committee or IRB guidelines (also referred to as the Honest Broker System).

Declaration of Conflicting Interests

The authors declared no potential conflicts of interest with respect to the research, authorship, and/or publication of this article.

Funding

The authors received no financial support for the research, authorship, and/or publication of this article.

ORCID iD

Elliot M. Levine https://orcid.org/0000-0002-0097-6252

References

1. Birch Petersen K, Hoffmann E, Rifbjerg Larsen C, Svarre Nielsen H: Cesarean scar pregnancy: a systematic review of treatment studies. *Fertil Steril*. 2016;105(4):958–967.
2. Al Naimi A, Moore P, Bruggmann D, Krysa L, Louwen F, Bahlmann F: Ectopic pregnancy: a single-center experience over 10 years. *Reprod Biol Endocrinol*. 2021;19(1):79.
3. Gonzalez N, Tulandi T: Cesarean scar pregnancy: a systematic review. *J Minim Invasive Gynecol*. 2017;24(5):731–737.
4. He Y, Zhong J, Zhou W, et al: Four surgical strategies for the treatment of cesarean scar defect: a systematic review and network meta-analysis. *J Minim Invasive Gynecol*. 2020;27(3):593–602.
5. Zhou X, Li H, Fu X: Identifying possible risk factors for cesarean scar pregnancy based on a retrospective study of 291 cases. *J Obstet Gynaecol Res*. 2020;46(2):272–278.
6. Miller R, Timor-Tritsch IE, Bannerman CG; Society for Maternal-Fetal Medicine (SMFM): Society for Maternal-Fetal Medicine (SMFM) Consult series #49: cesarean scar pregnancy. *Am J Obstet Gynecol*. 2020;222:B2–B14.
7. Liu L, Ross WT, Chu AL, Deimling TA: An updated guide to the diagnosis and management of cesarean scar pregnancies. *Curr Opin Obstet Gynecol*. 2020;32(4):255–262.
8. Cali G, Forlani F, Timor-Tritsch IE, Palacios-Jaraquemada J, Minneci G, D'Antonio F: Natural history of cesarean scar pregnancy on prenatal ultrasound: the crossover sign. *Ultrasound Obstet Gynecol*. 2017;50(1):100–104.
9. Timor-Tritsch I, Buca D, Di Mascio D, et al: Outcome of cesarean scar pregnancy according to gestational age at diagnosis: a systematic review and meta-analysis. *Eur J Obstet Gynecol Reprod Biol*. 2021;258:53–59.
10. De Braud LV, Knez J, Mavrelos D, Thanatsis N, Jauniaux E, Jurkovic D: Risk prediction of haemorrhage with surgical treatment of live cesarean scar pregnancies. *Eur J Obstet Gynecol Reprod Biol*. 2021;264:224–231.
11. Shi L, Huang L, Liu L, et al: Diagnostic value of three-dimensional transvaginal ultrasound combined with color Doppler ultrasound for early cesarean scar pregnancy. *Ann Palliat Med*. 2021;10(10):10486–10494.
12. Timor-Tritsch IE, Monteagudo A, Cali G, D'Antonio F, Agten AK: Cesarean scar pregnancy: patient counseling and management. *Obstet Gynecol Clin North Am*. 2019;46(4):813–828.
13. Hoffman T, Lin J: Cesarean scar ectopic pregnancy: diagnosis with ultrasound. *Clin Pract Cases Emerg Med*. 2020;4(1):65–68.
14. Heidar Z, Modarres SZ, Abediasi Z, Khaghani A, Salehi E, Esfidani T: Cesarean scar pregnancy treatment: a case series. *J Med Case Reports*. 2021;15:506.
15. Mohapatra I, Samantray SR: Scar ectopic pregnancy: an emerging challenge. *Cureus*. 2021;13(7):e16673.

JDMS Article – SDMS CME Credit

SDMS members can earn SDMS CME credit by successfully completing the complimentary online CME test in the SDMS Learning Center at learn.sdms.org. Non-members may access the online CME test for a fee. **Note: questions may appear in random order online.**

Article: Recognition of the Type of Cesarean Scar Pregnancy in First Trimester Sonography
Authors: Carlos M. Fernandez, MD, Elliot M. Levine, MD, Abraham Shashoua, MD, Irma Sodini, MD, Jude Duval, MD, and Jacqueline Juna, MD
Category: OB/GYN [OB]
Credit: 0.5 SDMS CME Credit

Objectives: After studying the article you will be able to:

- Recognize the value of sonography in identifying cesarean scar pregnancies (CSP)
- Describe the sonographic features of CSP
- Discuss the management and treatment of CSP

---

1. CSP, a new type of ectopic pregnancy, represents what percentage of all ectopic pregnancies (EP)?
   A. 1.7%
   B. 2.3%
   C. 3.5%
   D. 4.2%

2. Which type of CSP is caused by deep implantation of the gestational sac on a previous cesarean scar with progression toward either the cervicoisthmic space or the uterine cavity?
   A. Type I
   B. Type II
   C. Type III
   D. Type IV

3. What was the quantitative human chorionic gonadotropin level of the patient in the first case report?
   A. 5672 mIU
   B. 8900 mIU
   C. 10818 mIU
   D. 23670 mIU

4. How was the CSP managed in the second case report?
   A. Robotic resection
   B. Methotrexate
   C. Laproscopic resection
   D. Dilation and curettage

5. What is the best first line diagnostic tool for CSP?
   A. Transvaginal sonography
   B. Computed Tomography
   C. Magnetic resonance imaging
   D. Hysteroscopy