Optimizing Adnexal Ultrasound

Expert Tips for Fertility Imaging

Presented by: Ana Baez-Castillo, BS, RDMS (OB)

1

SPEAKER PRESENTATION DISCLAIMER

The content and views presented are made available for educational purposes only. The information presented are the opinions of the presenter and do not necessarily represent the views of the Society of Diagnostic Medical Sonography (SDMS) or its affiliated organizations, officers, Boards of Directors, or staff members.

The presenter is responsible for ensuring balance, independence, objectivity, scientific rigor, and avoiding commercial bias in their presentation. Before making the presentation, the presenter is required to disclose to the audience any relevant financial interests or relationships with manufacturers or providers of medical products, services, technologies, and programs.

The SDMS and its affiliated organizations, officers, Board of Directors, and staff members disclaim any and all liability for all claims that may arise out of the use of this educational activity.

2

© Copyright. Society of Diagnostic Medical Sonography. All Rights Reserved.

GENERATIVE AI DISCLAIMER

The presenter utilized the use of large language models (LLMs) and generative artificial intelligence (AI) as a productivity tool to assist in drafting and refining content in this presentation.

While these tools can aid in structuring ideas, summarizing, paraphrasing, and language polishing, they have inherent limitations and cannot replace human creativity, critical thinking, or expert judgment. AI-generated content may contain errors, biases, or gaps in knowledge.

This presentation is intended for informational purposes only and should not be construed as definitive or authoritative guidance. Participants are encouraged to critically evaluate the information presented and consult relevant experts as needed. The SDMS and its affiliated organizations, officers, Board of Directors, and staff members disclaim any and all liability for claims that may arise from the use or interpretation of this educational material.

3

Learning Objectives

1. **Identify Normal & Abnormal Structures**
Recognize ovarian and fallopian tube anatomy; distinguish pathological findings from normal variants

2. **Systematic Evaluation Approaches**
Refine protocols for ovarian morphology assessment and adnexal pathology evaluation

3. **Practical Techniques for Accuracy**
Apply ultrasound techniques that enhance diagnostic precision and image quality

4

© Copyright. Society of Diagnostic Medical Sonography. All Rights Reserved.

Introduction

- Adnexal ultrasound is essential in fertility evaluation
- Accurate ovarian assessment impacts diagnosis and treatment planning
- A structured approach improves consistency and reduces error

5

Normal Adnexal Anatomy

Establishing the baseline: What normal looks like before identifying pathology

6

© Copyright. Society of Diagnostic Medical Sonography. All Rights Reserved.

Adnexal Anatomy Review

- Ovaries
- Fallopian tubes
- Adjacent pelvic structures
- Clear anatomy identification is foundational

7

The Normal Ovary: Size & Volume

- Premenopausal Dimensions
  - Length: 2.5–5 cm
  - Width: 1.5–3 cm
  - Depth : 0.6-2.2 cm
  - Volume: 3– 10 mL (up to **20 mL** may be normal in reproductive-age women during stimulation)
- Postmenopausal
  - Volume <4 mL is expected
  - Atrophic appearance (follicles absent)

8

© Copyright. Society of Diagnostic Medical Sonography. All Rights Reserved.

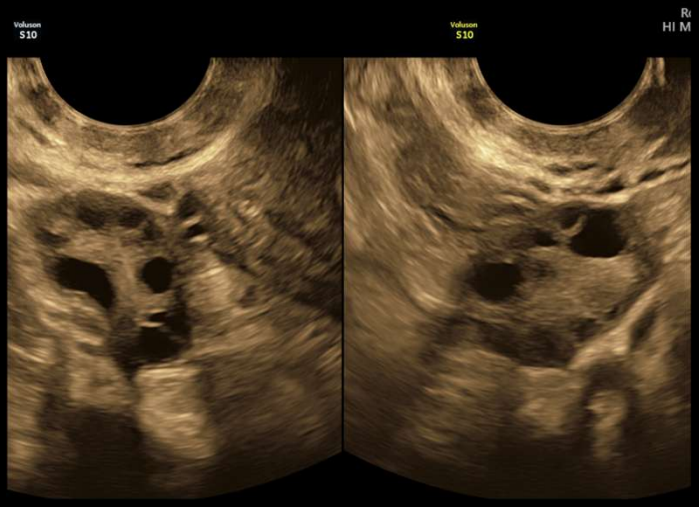

From personal files of Baez-Castillo, A.

Normal Ovarian Appearance

- **Shape:** Ovoid or almond-shaped.
- **Echotexture:** Homogeneous ovarian stroma with multiple small, anechoic follicles.
- **Vascularity:** Normal stromal blood flow on color Doppler.

9

Antral Follicles: Your Window Into Ovarian Reserve

- What Are They?
  - Small fluid filled cyst (2-10 mm) located in the ovarian cortex
  - Best visualized transvaginal ultrasound
- Clinical Significance:
  - Antral follicle count (AFC) is a validated predictor of ovarian reserve and response to stimulation.
- Normal Range:
  - 5-15 follicles per ovary
  - < 5 suggests diminished reserve (DOR)
  - 25 raises concern for PCOM

10

© Copyright. Society of Diagnostic Medical Sonography. All Rights Reserved.

Factors affecting ovarian appearance

1. **Age:** Ovaries become smaller after menopause with few or no visible follicles.
2. **Menstrual cycle:** Follicle size and ovarian volume vary throughout the cycle.
3. **Pregnancy and fertility treatment:** Ovaries may be enlarged with multiple follicles.

11

The Fallopian Tube

- Sonographic Appearance
  - Thin-walled, fluid-filled structure when patent
  - Ampulla (widest segment) most commonly identified
  - Wall thickness **<3 mm** in normal tube
  - Typically **isoechoic** to surrounding tissue when not distended
  - **NOT routinely visualized**

12

© Copyright. Society of Diagnostic Medical Sonography. All Rights Reserved.

Common Adnexal Ultrasound Findings

Benign and functional findings encountered in routine fertility imaging

13

Simple Cysts: Follicular & Functional

- Anechoic
- Smooth thin walls (< 3 mm)
- Posterior acoustic enhancement
- No internal vascularity
- <1 cm - follicle
- 1-2 cm – dominant follicle
- >3 cm - typically functional
- >5 cm warrants follow up imaging , concern for torsion

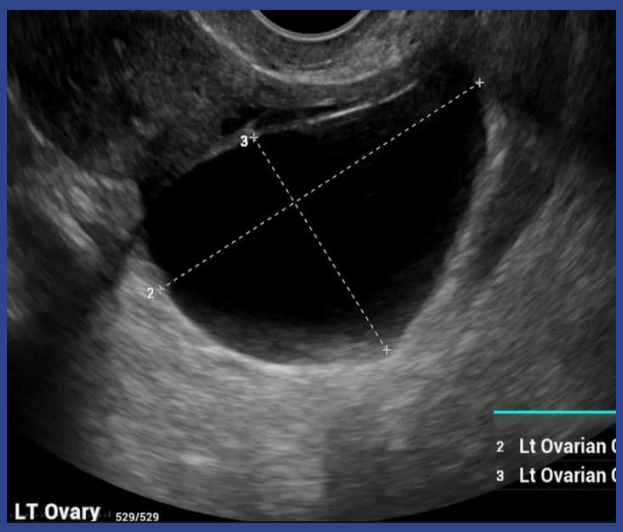

https://iame.com/courses/54601/simple-ovarian-cysts

14

© Copyright. Society of Diagnostic Medical Sonography. All Rights Reserved.

Corpus Luteum Cyst

- Sonographic Appearance
  - Collapsed thick walled cyst that may contain internal echoes or clot.
  - characteristic "ring of fire" due to high peripheral vascularity.
  - Size range – 1-3 cm
- Develops immediately after ovulation
- Regresses within 14 days – no implantation
- Persists in early pregnancy

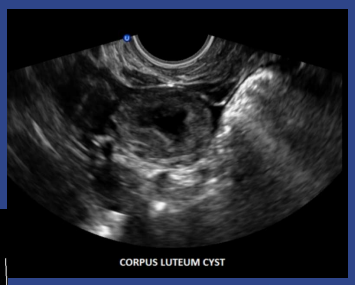

img_2511.png (652×489)

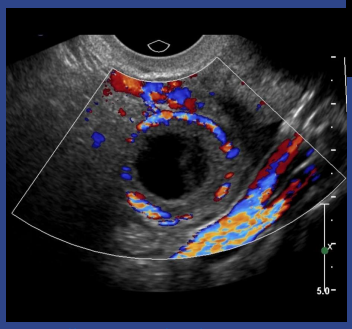

https://radiopaedia.org/cases/corpus-luteum?lang=us

15

Hemorrhagic Cysts

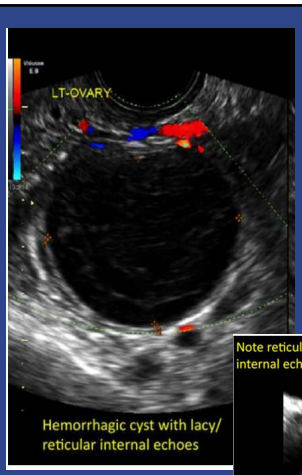

https://www.mdedge.com/obgyn/article/82385/menopause/hemorrhagic-ovarian-cysts-one-entity-many-appearances

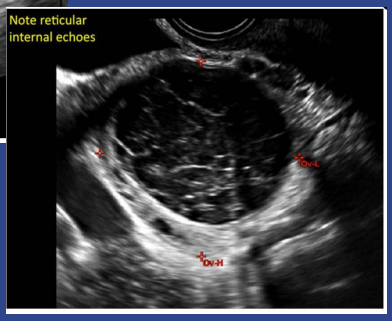

- Reticular "string/lace like " internal echoes
- Thin walled
- No internal color flow
- Posterior acoustic enhancement
- **≤ 5 cm:**
  - Almost certainly benign (O-RADS 2). **No follow-up** required
- **> 5 cm to < 10 cm:**
  - Follow-up ultrasound in 6 to 12 weeks is recommended, preferably during the follicular phase (days 3–10).
- **≥ 10 cm:** Classified as low risk (O-RADS 3)
  - Gynecologic consultation is typically required

16

© Copyright. Society of Diagnostic Medical Sonography. All Rights Reserved.

Mature Cystic Teratoma (Dermoid) Cyst

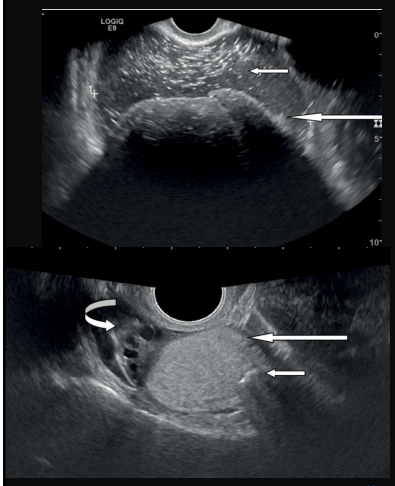

- Echogenic mass with posterior shadowing
- **Tip-of-the-iceberg sign**
- Hyperechoic **Rokitansky nodule**
- Calcification/tooth with shadowing
- Fluid-fluid levels
- **Dot-dash/dermoid mesh** from hair
- **No internal vascularity**



Radiopaedia. *Ovarian dermoid cyst.* Accessed September 22, 2026.

https://obgynkey.com/chapter-8-sonographic-assessment-of-ovarian-cysts-and-masses/

17

Endometrioma

- Homogeneous low level (ground glass) internal echoes
- No internal vascularity
- Posterior acoustic enhancement
- Usually unilocular
- Associated with reduced ovarian reserve and diminished IVF outcomes

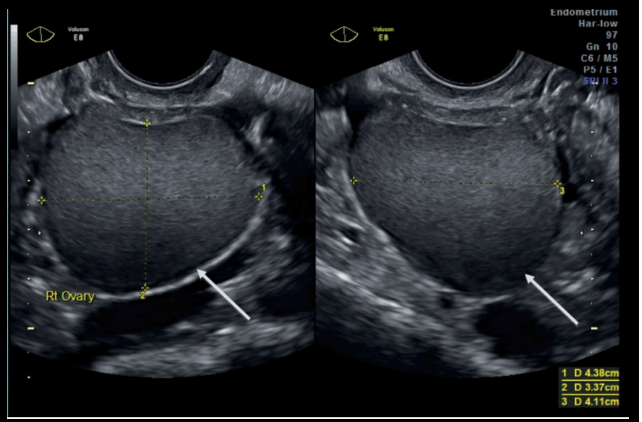

https://obgynkey.com/chapter-8-sonographic-assessment-of-ovarian-cysts-and-masses/

18

© Copyright. Society of Diagnostic Medical Sonography. All Rights Reserved.

Para ovarian cysts

- Anechoic
- thin walled
- ipsilateral ovary identified separately and distinctly
- Arise from the broad ligament or mesosalpinx
- Usually benign rarely undergo torsion

19

Abnormal Adnexal Pathology

Common abnormal adnexal findings in the fertility setting

20

© Copyright. Society of Diagnostic Medical Sonography. All Rights Reserved.

Polycystic Ovarian Morphology (PCOM)

Rotterdam criteria:

- ≥12 antral follicles (2-9 mm) per ovary on standard imaging
- ≥20–25 follicles with higher-resolution transducers (>or 8 MHz)
- Increased ovarian volume (>10 mL)
- Either ovary
- Additional Features
  - Stromal hypertrophy with increased echogenicity
  - Elevated stromal vascularity on color Doppler

21



Polycystic ovary syndrome (PCOS). Reproduced from *My Biology Dictionary*. Accessed September 23, 2026. https://mybiologydictionary.com/pcos-polycystic-ovary-syndrome/

22

© Copyright. Society of Diagnostic Medical Sonography. All Rights Reserved.

Tubal Pathology: Hydrosaplinx

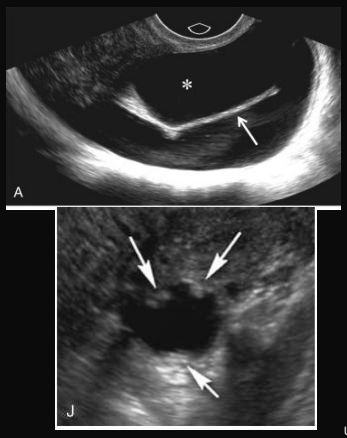

- thin- or thick-walled (in chronic cases)
- elongated or folded, tubular, C-shaped, or S-shaped fluid-filled structure
- distinct from the uterus and ovary
- Waist sign
- "Beads on a string"
- Incomplete septations

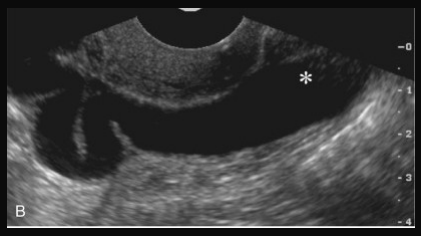

Ultrasound appearance of the fallopian tube. Reproduced from Norton ME.^1

23

Ectopic pregnancy

- No IUP when β-hCG >1,500–2,000 mIU/mL (discriminatory zone)
- Adnexal mass
  - Tubal ring sign
  - Blob sign
- Ring of Fire
- Echogenic fluid in pouch of Douglas
- Pseudo gestational sac
  - Lacks double decidual sac sign

24

© Copyright. Society of Diagnostic Medical Sonography. All Rights Reserved.



The "bagel sign" on grayscale pelvic ultrasound. Reproduced from Lima D, Revels JW, Mattinson T, Wang SS.^1

- Tubal/ Bagel sign
  - Thick walled
  - Hyperechoic ring
  - Gestational sac
    - Yolk sac
    - Embryo
  - Peripheral vascularity
    - "ring of fire"

25

Blob sign

- Inhomogeneous
  - Blood clot and trophoblastic tissue

Peripheral vascularity may be noted



The "blob sign" on grayscale pelvic ultrasound. Reproduced from Lima D, Revels JW, Mattinson T, Wang SS.^1

26

© Copyright. Society of Diagnostic Medical Sonography. All Rights Reserved.

Pseudo gestational sac

- Within uterine cavity
- Fluid collection
  - Thin walled
  - Without yolk sac
  - No decidua sign

27

Follicular Assessment and Monitoring

Consistent imaging through stimulation cycles

28

© Copyright. Society of Diagnostic Medical Sonography. All Rights Reserved.

Follicular Assessment in Fertility

- Ovarian Reserve (AMH- anti mullerian hormone)
- Antral Follicle Count (AFC)
- Assess follicular distribution
- Ovarian accessibility
- Correlate patient history and menstrual phase

29

What is follicular monitoring?

- Series of transvaginal ultrasounds
- Tracks growth and development of follicles
  - Natural cycles
  - Response to fertility medications
- Helps determine whether an egg is maturing
- Identifies the optimal time for time intercourse, Intrauterine insemination, and egg retrieval.

30

© Copyright. Society of Diagnostic Medical Sonography. All Rights Reserved.

Baseline Scan: Day 1-3 Assessment

- Performed in the early follicular phase to establish a baseline before any stimulation begins via medication (gonadotropins)
- What is assessed?
  - AFC
  - Bilateral ovarian volume
  - Endometrial thickness and pattern
  - Identify residual cysts or pathology that may preclude stimulation

31

Ovarian stimulation monitoring

- Scanning Schedule
  - Serial scans every 2–3 days during gonadotropin stimulation
  - Track follicle cohort growth in both ovaries systematically
- Trigger Criteria
  - ≥3 follicles measuring ≥17–18 mm (protocol-dependent)
  - Correlate follicle size with serum estradiol levels for safe stimulation

32

© Copyright. Society of Diagnostic Medical Sonography. All Rights Reserved.

Ovulation Induction: Mid-cycle scans for TI &IUI

- Monitoring begins on day 9-12
  - 1-3 dominant follicles
- Trigger Criteria:
- Leading follicle > 18- 20 mm w/ trilaminar endometrium of > 7 mm.

Ovulation confirmation is not required.

33

What does a typical follicular monitoring look like?

- **Day 1–3 (Baseline)**
  - Assess any cysts
- **Day 5 of stimulation**
- **Day 7 of stimulation**
  - Monitor follicular growth (≈1–2 mm/day)
- **Ongoing monitoring:**
  - usually daily until a cohort of follicles reaches **18–22 mm**
  - Evaluate for signs of impending ovulation

34

© Copyright. Society of Diagnostic Medical Sonography. All Rights Reserved.

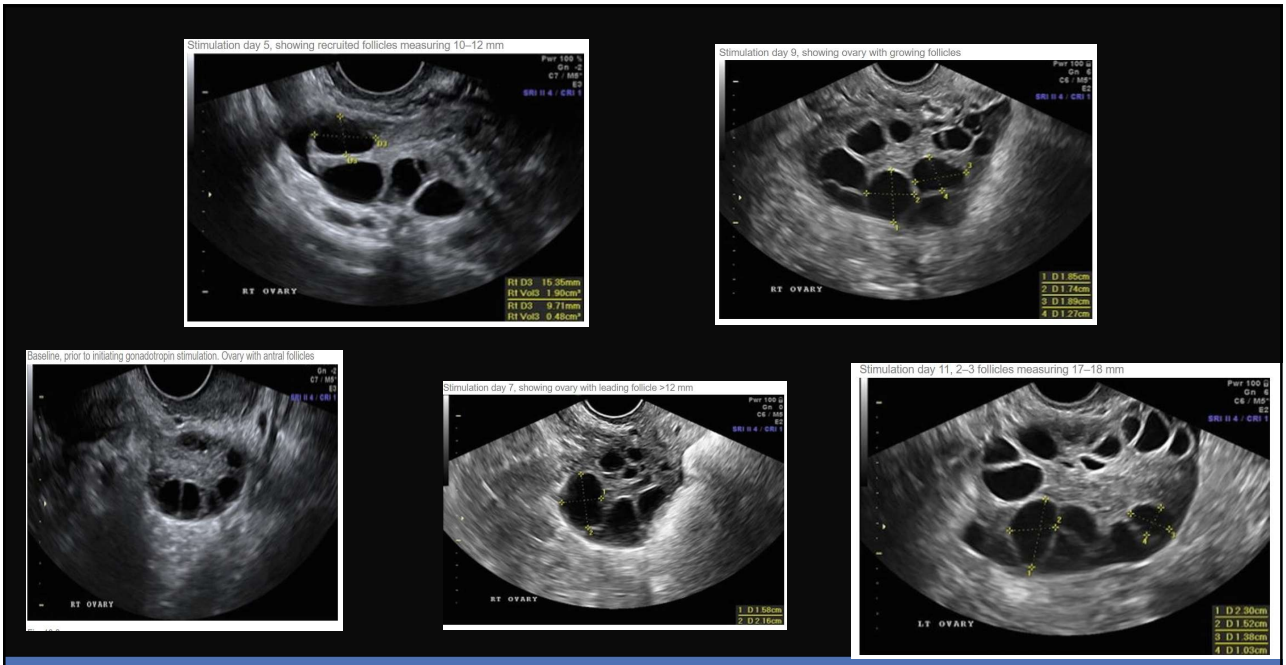

https://radiologykey.com/2d-ultrasound-in-follicle-monitoring-for-art/

35

Common complications in fertility scanning

- OHSS
- Ectopic pregnancies
- Ovarian Torsion

36

© Copyright. Society of Diagnostic Medical Sonography. All Rights Reserved.

OHSS

- What is OHSS?
  - Ovarian Hyper Stimulation Syndrome
  - Complication of ovaries over stimulating due to response of fertility medication
  - Can be mild, moderate or serve based on clinical indications
- How is it detected?
  - Transvaginal ultrasound
  - Clinical indications
    - Pain or abdominal bloating

37

Ultrasound findings with OHSS

- Enlarged ovaries with **multiple enlarged follicles or cysts**
  - Ovarian size may exceed **8–10 cm** in diameter in moderate or severe cases
  - **Free fluid**
    - pelvis or abdomen (ascites)

38

© Copyright. Society of Diagnostic Medical Sonography. All Rights Reserved.

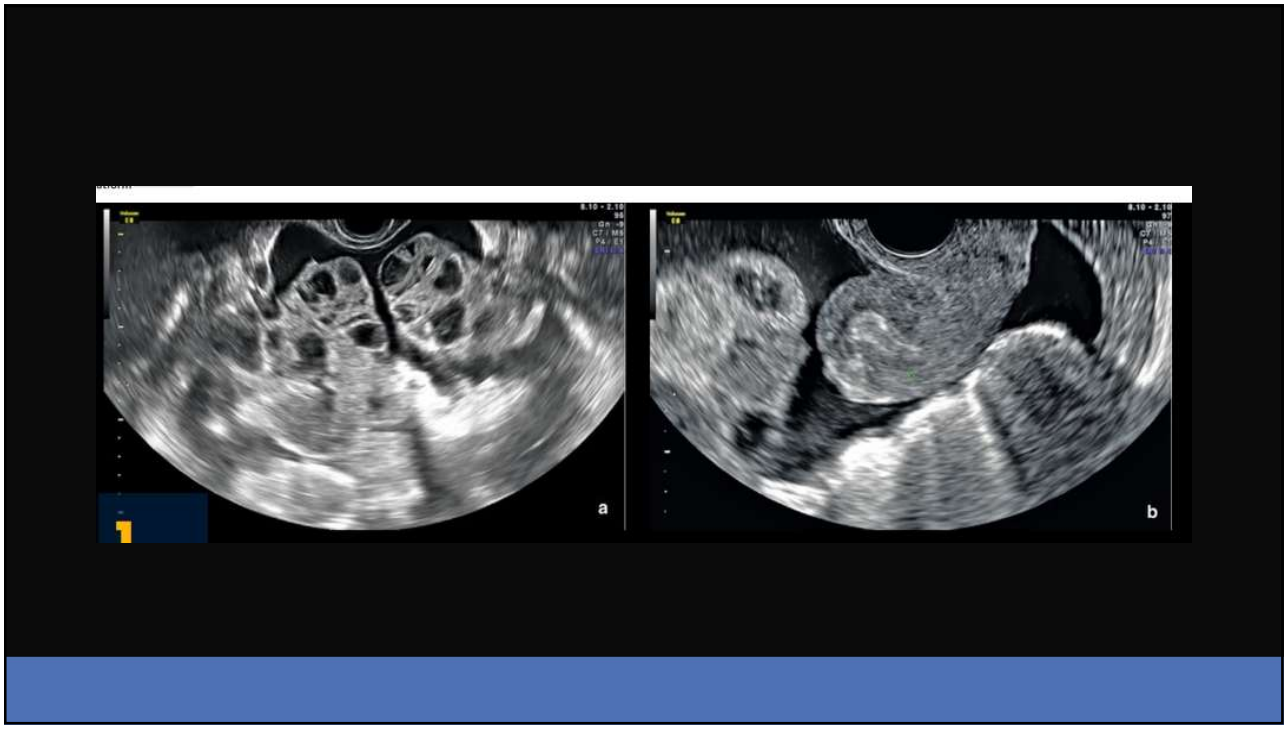

39

Ovarian Torsion

- Enlarged edematous globular ovary is the key finding
- ovary >5 cm in maximum diameter or >20 cc in volume
- Multiple peripherally arranged follicles (**"string of pearls" sign**)
- Reduced or absent venous/arterial Doppler flow
- **Whirlpool sign** of the twisted vascular pedicle
- Free pelvic fluid may be present
- The ovary may be displaced from its normal position

40

© Copyright. Society of Diagnostic Medical Sonography. All Rights Reserved.

Systematic Evaluation Protocols

Standardized, Reproducible approaches for complete adnexal assesment

41

Systematic Ovarian Assessment Protocol

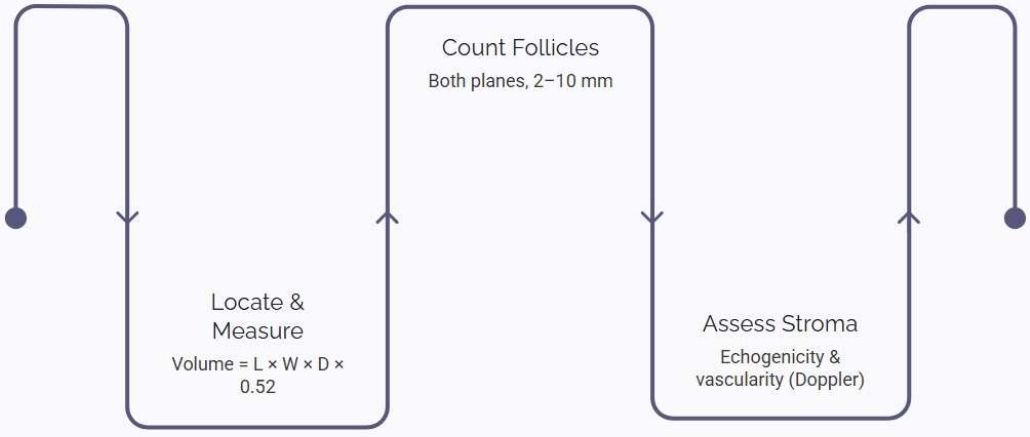

42

© Copyright. Society of Diagnostic Medical Sonography. All Rights Reserved.

Systematic Scanning Technique

- Start Midline
- Sweep slowly and completely lateral
- Use multiple planes
- Take a cine clip of your adnexal sweep for reference
- Probe manipulation and graded compression
- Add doppler
- Transabdominal approach

43

Follicle Counting: Standardized Method

What to Count?

- Count all follicles measuring 2–10 mm in maximum diameter
- Scan entire ovary systematically in multiple planes to avoid double counting

- Documentation
  - Document count per ovary separately (right vs. left)
  - Record total AFC = sum of both ovaries

44

© Copyright. Society of Diagnostic Medical Sonography. All Rights Reserved.

Doppler Evaluation

- Evaluate vascular flow when indicated
- Helps characterize indeterminate adnexal masses
- Benign Lesions often show low or no internal flow
- Doppler should be interpreted with grey scale findings

45

Compression & Mobility Assessment

- **Gentle compression**: Apply gradual probe pressure to differentiate compressible cysts from solid masses
- **Organ mobility**: Gently displace the ovary or uterus
  - fixed, immobile organs suggest adhesions from endometriosis or pelvic adhesions

46

© Copyright. Society of Diagnostic Medical Sonography. All Rights Reserved.

Gain & Dynamic Range Settings

- Gain Optimization
  - Set gain to visualize **subtle internal echoes** within cysts
  - Avoid over-gaining
  - Use **time-gain compensation** (TGC) sliders to equalize near and far-field brightness
- Dynamic Range & Harmonics
  - Narrow dynamic range increases image contrast
  - **Tissue harmonic imaging (THI)** reduces acoustic clutter

47

Common Pitfalls

- Bowel loops can mimic adnexal masses
- Overcalling physiologic cysts as pathology
- Missing small or isoechoic lesions
- Incomplete scanning of the adnexa's
- Limited visualization
- Unable to find an ovary

48

© Copyright. Society of Diagnostic Medical Sonography. All Rights Reserved.

Optimization Tips

- Optimize pelvic presets and depth settings
- Use cine loops
- Tint map
- Maintain a consistent scanning protocol
- Familiarize yourself with your equipment

49

What are the two reliable markers of ovarian reserve?

50

© Copyright. Society of Diagnostic Medical Sonography. All Rights Reserved.

Physiologic or not?

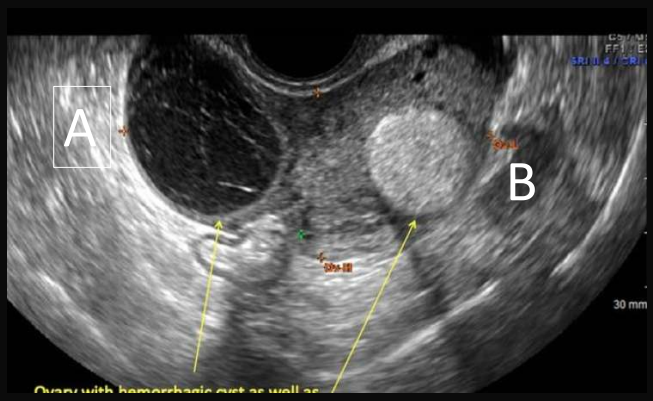

51

What structure confirms a definite ectopic pregnancy?

- A: a blob sign
- B: A ”ring of fire”
- C: a tubal sac with a yolk sac
- D: a pseudogestational sac

52

© Copyright. Society of Diagnostic Medical Sonography. All Rights Reserved.

Summary

- Recognizing normal ovarian variation is essential
- Apply Systematic approach to evaluate ovarian morphology, follicular development and abnormal pathology
- Correlate patient history and menstrual phase

53

References

- Ultrasound Feminsider. Ultrasound image of corpus luteal cyst [Internet]. In: *Ovaries, hormonal cycles and common cysts*. 2018. Accessed September 22, 2026. https://ultrasoundfeminsider.com/all-you-need-to-know-about-ovaries-normal-hormonal-cycles-and-common-cysts/
- Radiopaedia. Corpus luteum. *Radiopaedia.org*. Updated [date if available]. Accessed September 22, 2026. https://radiopaedia.org/cases/corpus-luteum?lang=us
- Institute for Advanced Medical Education. Simple ovarian cysts. IAME. Published April 3, 2023. Updated December 9, 2024. Accessed September 22, 2026. https://iame.com/courses/54601/simple-ovarian-cysts
- Stalnaker ML, Kaunitz AM. Hemorrhagic ovarian cysts: one entity with many appearances. *ObGyn*. May 23, 2014. Accessed September 22, 2026. https://www.mdedge.com/obgyn/article/82385/menopause/hemorrhagic-ovarian-cysts-one-entity-many-appearances
- Radiopaedia. Ovarian dermoid cyst [image]. Radiopaedia.org. Accessed September 22, 2026. https://prod-images-static.radiopaedia.org/images/61509166/8e416875363f20bc8112338f0646f5e600a09f12ce9f2abca08d79517068219a_gallery.jpeg
- O'Neill MJ, et al. Chapter 8: Sonographic assessment of ovarian cysts and masses. OBGYN Key. Accessed September 22, 2026. https://obgynkey.com/chapter-8-sonographic-assessment-of-ovarian-cysts-and-masses/
- Norton ME. Ultrasound evaluation of the fallopian tube. Radiology Key. Published February 16, 2019. Accessed September 22, 2026. https://radiologykey.com/ultrasound-evaluation-of-the-fallopian-tube/
- Baseline ultrasound showing an ovary with antral follicles. Reproduced from *2D Ultrasound in Follicle Monitoring for ART*. Radiology Key. Accessed September 23, 2026. https://radiologykey.com/2d-ultrasound-in-follicle-monitoring-for-art/
- **Polycystic ovary syndrome (PCOS).** *My Biology Dictionary*. Accessed September 23, 2026. https://mybiologydictionary.com/pcos-polycystic-ovary-syndrome/

54

© Copyright. Society of Diagnostic Medical Sonography. All Rights Reserved.