Nutcracker and Beyond: Sonographic Evaluation of Vascular Compression Syndromes

Angelena Zehm, MEd, RDMS, RDCS, RVT
DMS Program Director
Keiser University
New Port Richey, Florida

1

DISCLAIMER

The content and views presented are made available for educational purposes only. The information presented are the opinions of the presenter and do not necessarily represent the views of the Society of Diagnostic Medical Sonography (SDMS) or its affiliated organizations, officers, Boards of Directors, or staff members.

The presenter is responsible for ensuring balance, independence, objectivity, scientific rigor, and to avoid commercial bias in their presentation. Before making the presentation, the presenter is required to disclose to the audience any relevant financial interests or relationships with manufacturers or providers of medical products, services, technologies, and programs.

The SDMS and its affiliated organizations, officers, Board of Directors, and staff members disclaim any and all liability for all claims that may arise out of the use of this educational activity.

2

© Copyright. Society of Diagnostic Medical Sonography. All Rights Reserved.

GENERATIVE AI DISCLAIMER

The presenter utilized the use of large language models (LLMs) and generative artificial intelligence (AI) as a productivity tool to assist in drafting and refining content in this presentation.

While these tools can aid in structuring ideas, summarizing, paraphrasing, and language polishing, they have inherent limitations and cannot replace human creativity, critical thinking, or expert judgment. AI-generated content may contain errors, biases, or gaps in knowledge.

This presentation is intended for informational purposes only and should not be construed as definitive or authoritative guidance. Participants are encouraged to critically evaluate the information presented and consult relevant experts as needed. The SDMS and its affiliated organizations, officers, Board of Directors, and staff members disclaim any and all liability for claims that may arise from the use or interpretation of this educational material.

3

Objectives

1. Describe pathophysiology and clinical significance of Nutcracker syndrome and other vascular compression syndromes
2. Identify key sonographic techniques and Doppler criteria used to evaluate vascular compression syndromes.
3. Differentiate true compression syndromes from normal anatomic, respiratory, positional, or incidental variations.
4. Integrate ultrasound findings with symptoms and CT/MRI correlation for confident reporting.

4

© Copyright. Society of Diagnostic Medical Sonography. All Rights Reserved.

Why these syndromes are missed

- Symptoms may be vague: flank pain, pelvic pain, hematuria, leg swelling, post-prandial pain, nausea, weight loss.
- Compression can be dynamic: respiration, posture, hydration, abdominal pressure, and scanning position change the appearance.
- Deep vessels are technically challenging: bowel gas, body habitus, and Doppler angle limitations reduce confidence.
- Incidental anatomic compression is more common than clinically meaningful syndrome.

5

The Compression Syndrome Equation

- **Predisposing anatomy**: vessel course, skeletal relationship, ligament, fat pad, or arterial crossing
- **Mechanical narrowing**: focal caliber change or altered vessel angle
- **Hemodynamic effect**: focal velocity acceleration, turbulence, loss of phasicity, reversal, collateralization, or upstream dilation
- **Clinical consequence**: symptoms, lab findings, thrombosis, obstruction, or organ-specific effects

6

© Copyright. Society of Diagnostic Medical Sonography. All Rights Reserved.

Duplex Foundations

Before naming a syndrome, prove the physiology

7

Sonographic Technique

B-mode/Color Priorities

- Identify vessel course in two planes
- Document focal narrowing and pre/post–stenotic caliber
- Use low color scale for venous collateral flow
- Avoid transducer pressure that creates compression
- Record patient position and respiratory phase

Spectral Doppler Priorities

- Keep Doppler angle ≤60◦ when possible
- Sample before, at, and after narrowing
- Compare velocity ratios rather than isolated values
- Assess phasicity, turbulence, direction, augmentation
- Repeat equivocal findings dynamically

8

© Copyright. Society of Diagnostic Medical Sonography. All Rights Reserved.

Protocol Checklist for Vascular Compression Workups

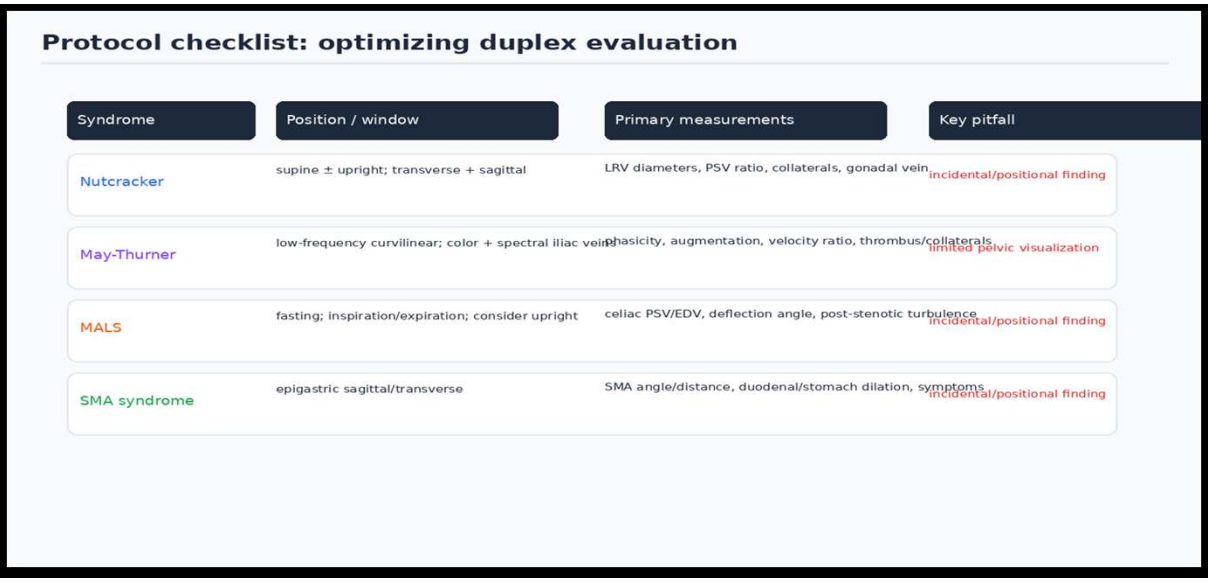

9

General Doppler Criteria: What counts as evidence?

- Focal velocity acceleration at the narrowing compared with proximal or upstream segment.
- Spectral broadening, aliasing, post-stenotic turbulence, or damped distal venous phasicity.
- Upstream dilation, organ congestion, collateral pathways, or varices.
- Reproducibility across planes and consistency with symptoms.
- Correlation with CT/MRI when anatomy is deep, complex, or intervention is considered.

10

© Copyright. Society of Diagnostic Medical Sonography. All Rights Reserved.

Nutcracker Syndrome

Left renal vein entrapment: evaluate anatomy, Doppler, and the clinical fit

11

Nutcracker Anatomy:

Classically, the LRV is compressed between the aorta and SMV

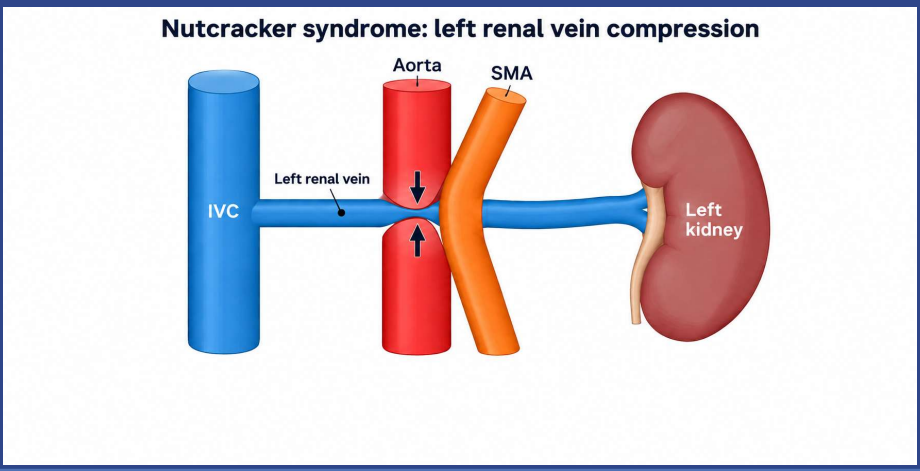

12

© Copyright. Society of Diagnostic Medical Sonography. All Rights Reserved.

Nutcracker Clinical Presentation

- Microscopic or gross hematuria from renal venous hypertension and thin-walled venous communications.
- Left flank or abdominal pain; may be positional or worsened by standing/exertion.
- Pelvic congestion symptoms, vulvar or lower extremity varices, or left-sided varicocele.
- Proteinuria, especially orthostatic proteinuria in some young patients.
- Symptoms and severity vary; asymptomatic compression is common.

13

Nutcracker Scan Protocol

- Begin with transverse epigastric view: identify SMA, aorta, and LRV crossing.
- Measure LRV diameter at renal hilum and at aortomesenteric segment; document grayscale narrowing.
- Acquire Doppler velocities at same sites with careful angle correction and low wall filter.
- Look for collateral pathways: gonadal vein dilation/reflux, lumbar collaterals, pelvic varices, and possible varicocele (although we would not automatically scan the scrotum without an order).
- Consider supine and upright or decubitus comparison when findings are equivocal.

14

© Copyright. Society of Diagnostic Medical Sonography. All Rights Reserved.

Nutcracker Phenomenon or Syndrome

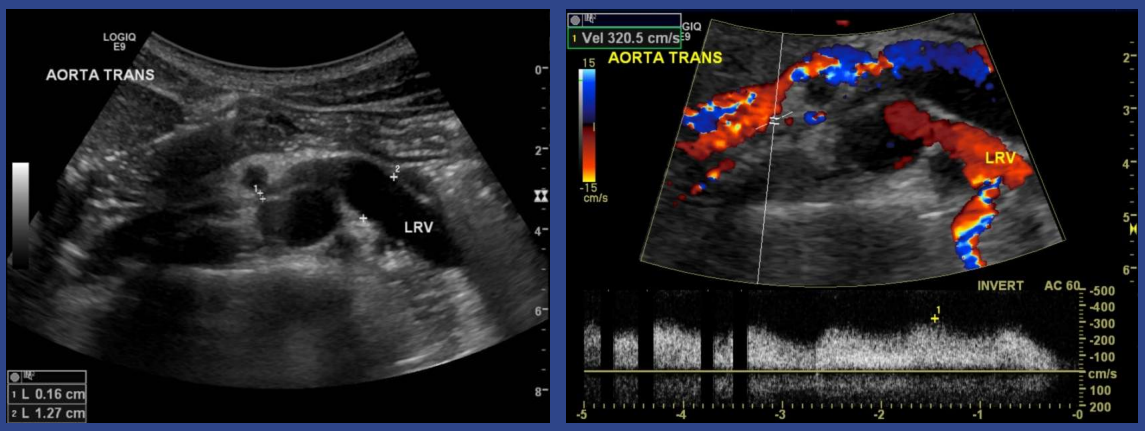

https://radiopaedia.org/cases/nutcracker-phenomenon

15

Nutcracker Doppler: velocity and waveform comparison

Measure at the renal hilum and the compressed aortomesenteric segment

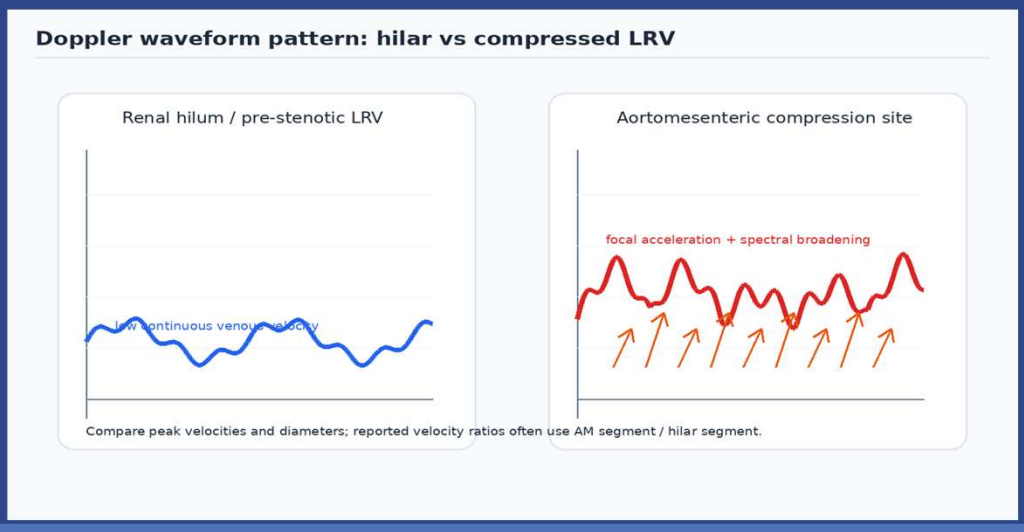

16

© Copyright. Society of Diagnostic Medical Sonography. All Rights Reserved.

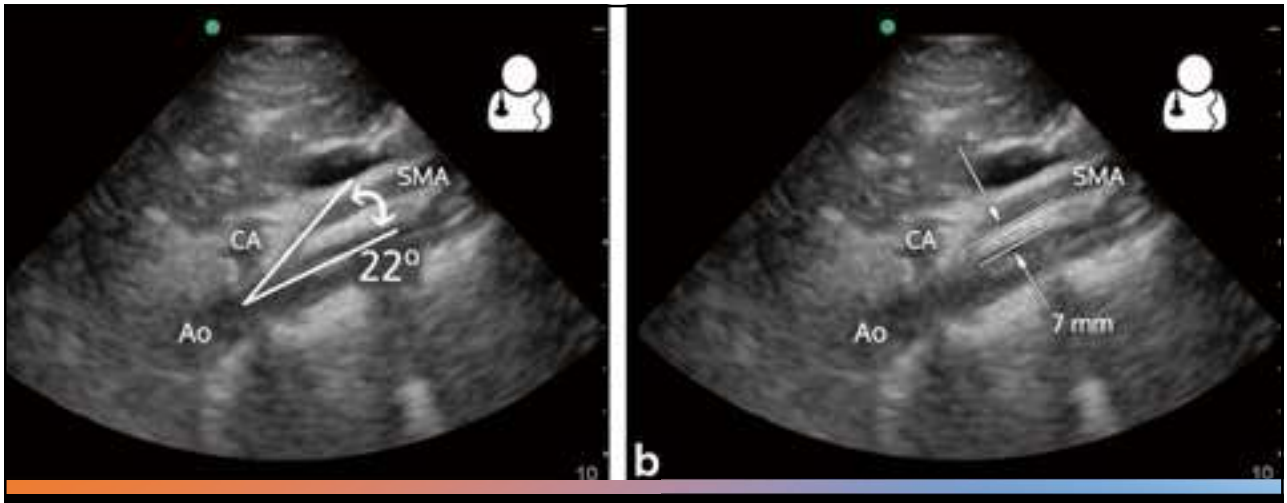

Nutcracker

Normal: 25/28°- 60/65° and 10-28 mm

17

Nutcracker: Alternative Imaging



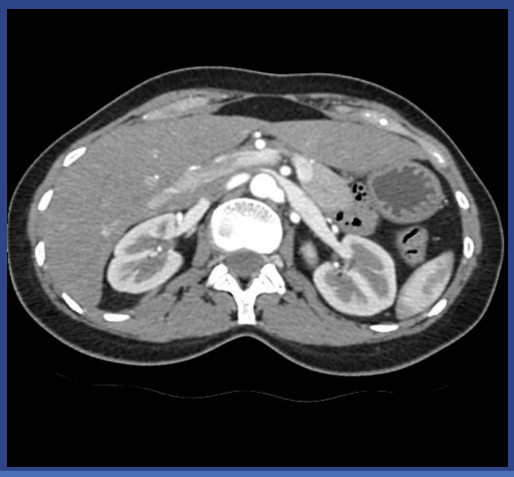

https://pmc.ncbi.nlm.nih.gov/articles/PMC5965416/

https://radiopaedia.org/articles/nutcracker-syndrome

18

© Copyright. Society of Diagnostic Medical Sonography. All Rights Reserved.

Nutcracker: Differentiating syndrome from phenomenon

Supports syndrome: symptoms + marked focal narrowing + velocity/diameter ratio + upstream dilation/collaterals.

Suggests phenomenon/incidental compression: narrowing only, minimal velocity change, no collaterals, unrelated symptoms.

Common pitfall: diagnosing from CT angle alone without Doppler or clinical correlation.

Report uncertainty: "findings may be seen with…" rather than definitive syndrome when incomplete.

19

Treatment for Nutcracker Syndrome

Treatments are essentially to relieve the signs and symptoms associated with NCS

1. Left renal vein transposition
   - Approximately 30-50% failure rate
2. Autotransplantation of the left kidney into the pelvis
3. Therapeutic nephrectomy with possible donation of the left kidney

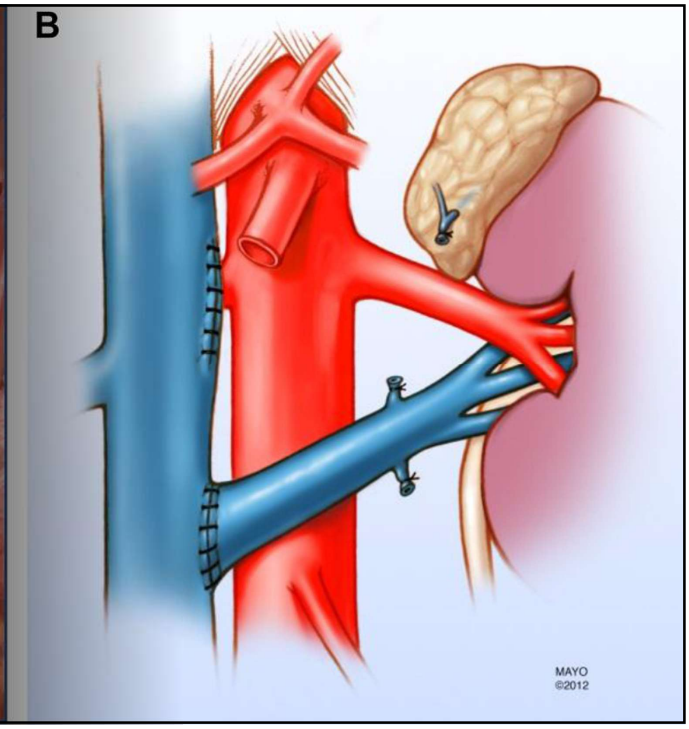

20

© Copyright. Society of Diagnostic Medical Sonography. All Rights Reserved.

SMA Syndrome and related entities

- When the aortomesenteric space narrows beyond the renal vein.
- Also known as Wilkie's Syndrome
  - Dr. Wilkie defined and published research findings about SMA syndrome in 1927

21

SMA Syndrome Anatomy:

Third portion of the duodenum compressed between the aorta and SMA

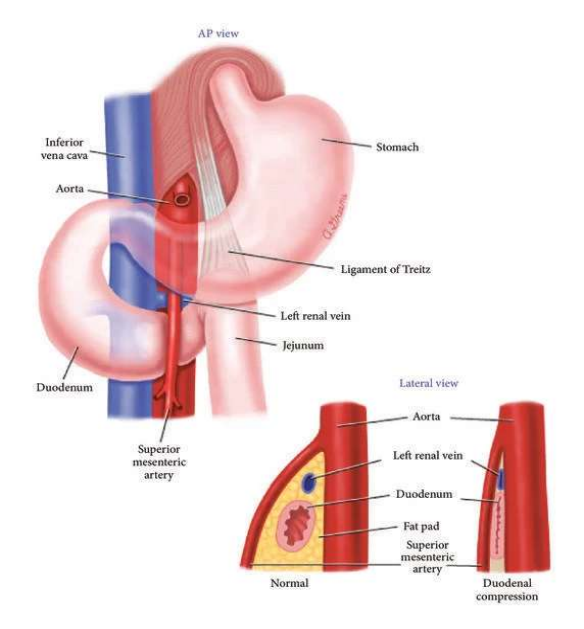

https://www.researchgate.net/figure/Superior-mesenteric-artery-SMA-syndrome-The-superior-mesenteric-artery-arises-from-the_fig5_311862660

22

© Copyright. Society of Diagnostic Medical Sonography. All Rights Reserved.

SMA Syndrome Sonographic Assessment

- Measure aortomesenteric angle on longitudinal/sagittal view and distance on transverse view.
- Evaluate for duodenal or gastric dilation when visible; correlate with nausea, vomiting, early satiety, weight loss.
- Consider overlap with Nutcracker anatomy: both involve the aortomesenteric interval.
- Avoid overdiagnosis from a narrow angle alone, especially in thin patients without obstructive symptoms.
- CT/MRI can confirm anatomy and exclude alternative causes of obstruction.

23

SMA and Nutcracker Syndromes

- Look at the angle between the aorta and SMA
- Normal aortomesenteric angle: 28°-65°
- Normal distance: 10-34 mm

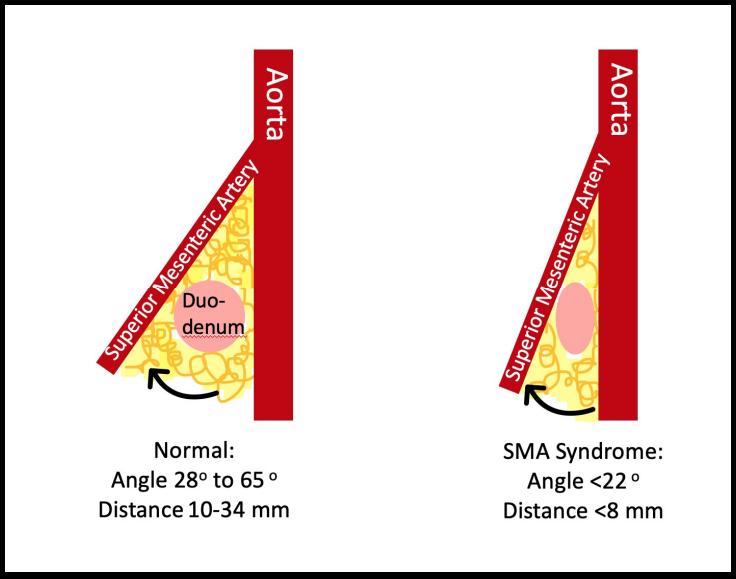

https://pedemmorsels.com/superior-mesenteric-artery-syndrome-sma-syndrome-in-children/

24

© Copyright. Society of Diagnostic Medical Sonography. All Rights Reserved.

SMA Syndrome

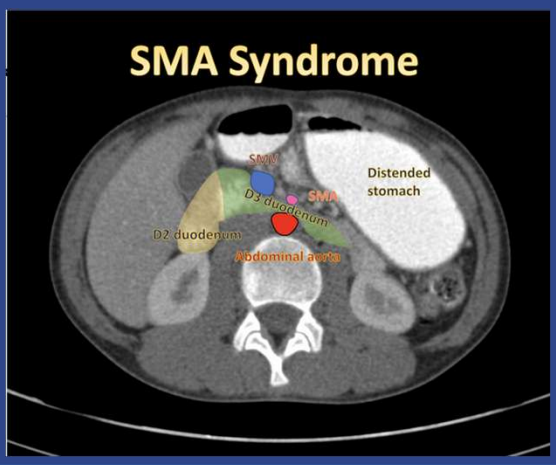

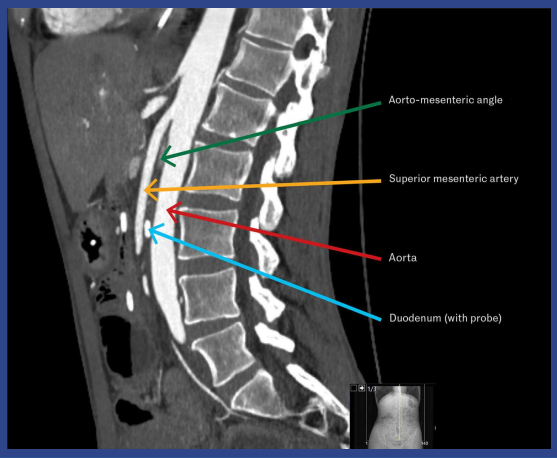

https://radiopaedia.org/cases/superior-mesenteric-artery-syndrome-31

https://tidsskriftet.no/en/2024/02/images-medicine/narrow-angle-between-superior-mesenteric-artery-and-aorta

25

Celiac artery compression / MALS

Respiration can turn a stenosis on and off.



26

© Copyright. Society of Diagnostic Medical Sonography. All Rights Reserved.

MALS: Median Arcuate Ligament Syndrome

- Fibrous band of the diaphragm that may compress the celiac artery
- Signs and symptoms frequently overlap other GI disorders
- Vascular compression is typically worse during expiration
- May be a combination of these mechanisms

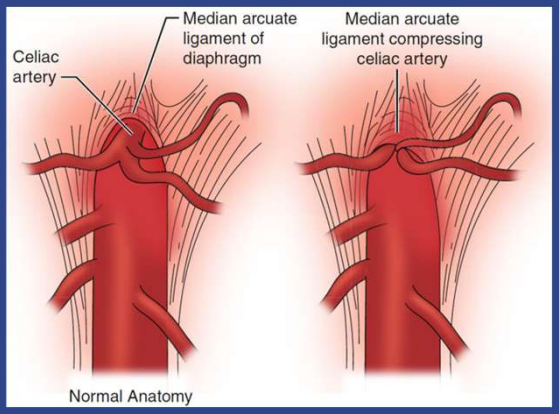

https://northwesternsurgicalassociates.com/median-arcuate-ligament-syndrome/

27

MALS

- Postprandial epigastric pain
- Unintentional weight loss
- Early satiety
- Nausea
- Exercise-induced abdominal discomfort

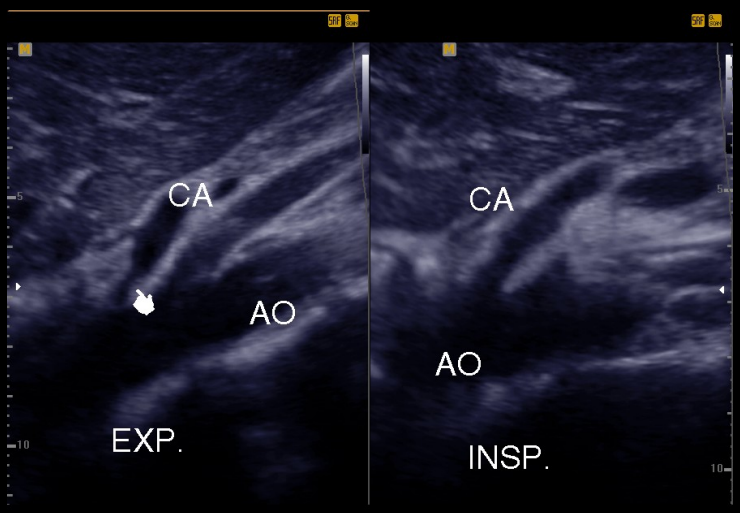

28

© Copyright. Society of Diagnostic Medical Sonography. All Rights Reserved.

MALS – Spectral Doppler Evaluation

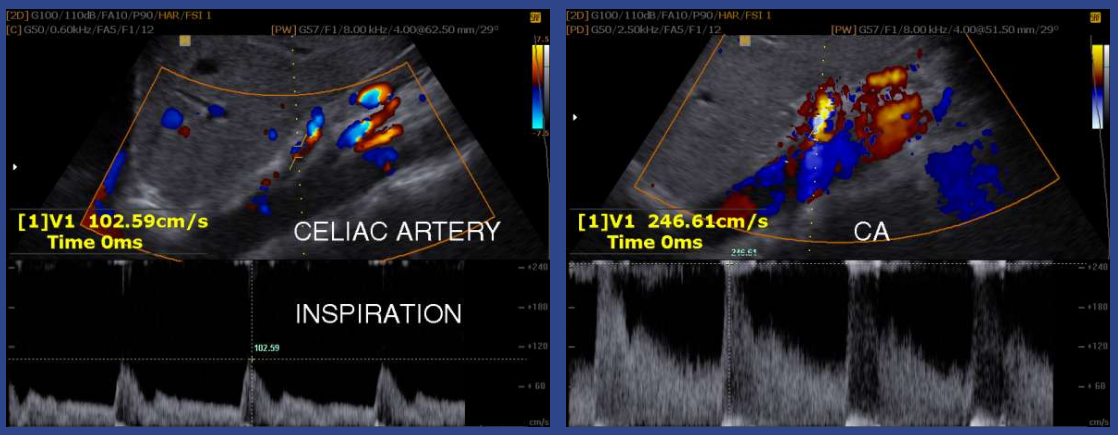

29

MALS Doppler Protocol and Criteria

- Patient fasting when possible; scan sagittal upper abdomen with celiac origin in view.
- Measure celiac PSV and EDV during inspiration and expiration.
- Look for focal proximal velocity elevation, post-stenotic turbulence, and hooked/deflected proximal course.
- Repeat upright or with positional change when supine expiratory velocities are high, but symptoms are uncertain.
- Interpret with symptoms; respiratory velocity normalization argues against fixed atherosclerotic stenosis.

30

© Copyright. Society of Diagnostic Medical Sonography. All Rights Reserved.

MALS

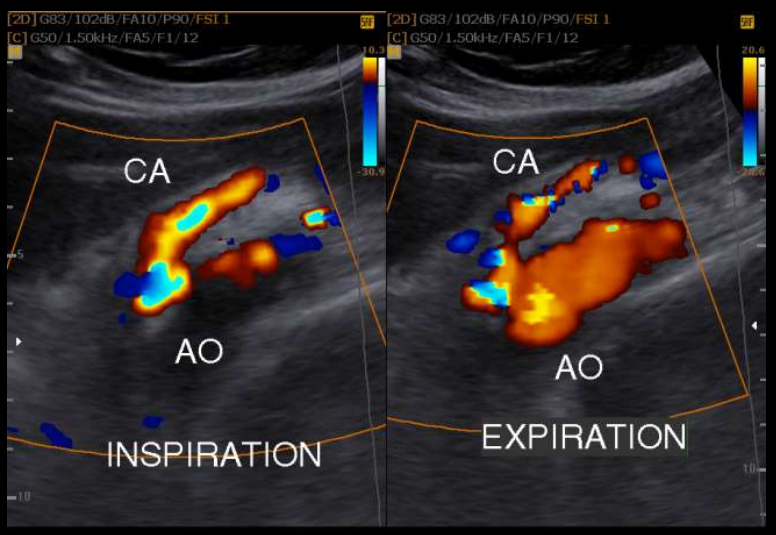

31

MALS Pitfalls

- **False positives**: respiratory motion, excessive Doppler angle, tortuosity, thin body habitus, asymptomatic high velocities.
- **False negatives**: nonfasting bowel gas, limited acoustic window, failure to test expiration, not sampling the origin.
- **Report dynamic findings**: inspiration/expiration PSV, turbulence, vessel morphology, and limitations.
- **Management decisions require clinical assessment**; surgery is not based on velocity alone.

32

© Copyright. Society of Diagnostic Medical Sonography. All Rights Reserved.

May-Thurner Syndrome

Iliac venous compression

33

May-Thurner anatomy:

Left common iliac vein compressed by the right common iliac artery

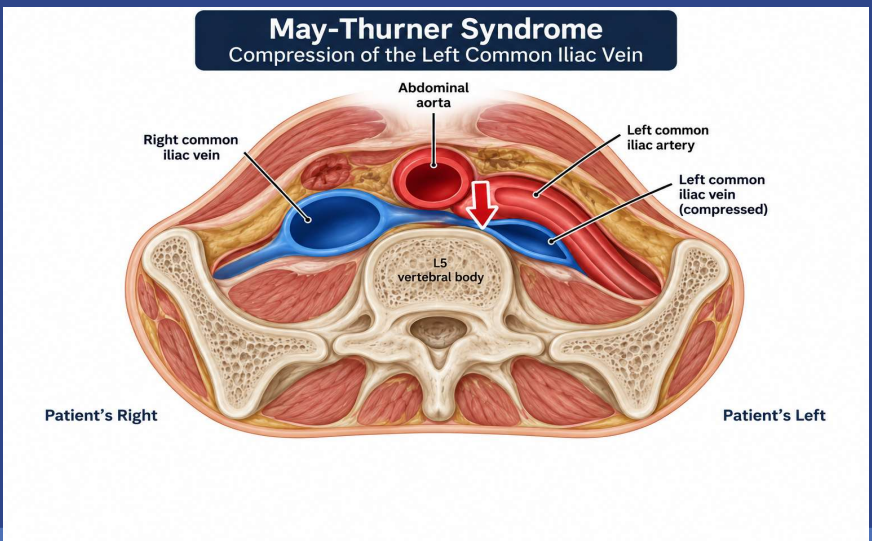

34

© Copyright. Society of Diagnostic Medical Sonography. All Rights Reserved.

May Thurner Syndrome (MTS)

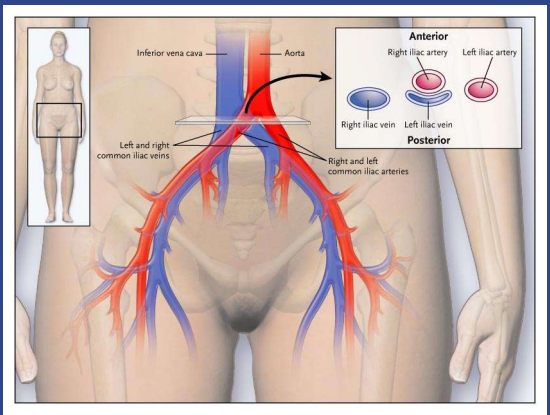

https://www.cardioshoals.com/2016/11/26/can-die-may-thurner-syndrome/



https://www.cvmus.com/vascular-conditions/may-thurner-syndrome

35

May-Thurner Ultrasound Approach

- Evaluate from common femoral vein through iliac veins as far as technically possible.
- Compare right and left common femoral waveforms for respiratory phasicity and symmetry.
- Assess augmentation response and continuous or damped venous flow suggesting proximal obstruction.
- Look for acute/chronic thrombus, venous distention, and pelvic or abdominal wall collaterals.
- Use CT venography, MR venography, or intravascular ultrasound when intervention is contemplated.

36

© Copyright. Society of Diagnostic Medical Sonography. All Rights Reserved.

May-Thurner Syndrome

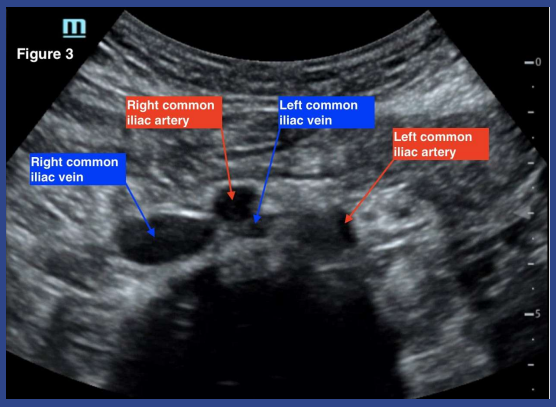

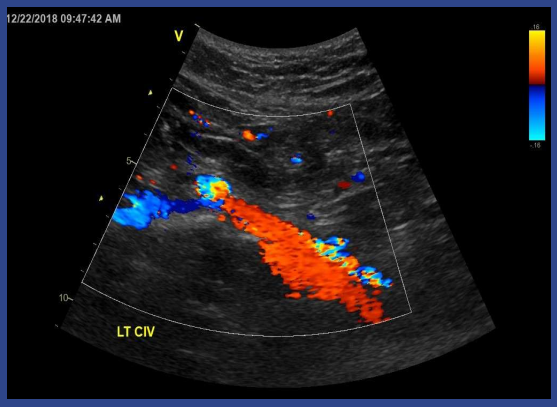

https://jetem.org/may-thurner/

https://www.heartveinnyc.com/case-studies/approach-to-may-turner-syndrome-mts-diagnosis-mts-or-iliac-vein-compression-syndrome-ivcs-on-different-imaging-modalities/

37

May Thurner Syndrome

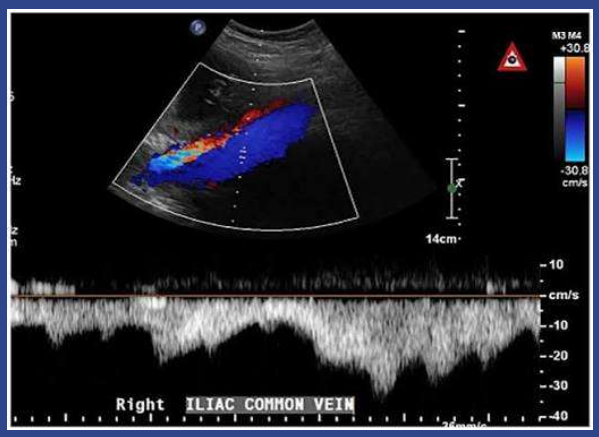

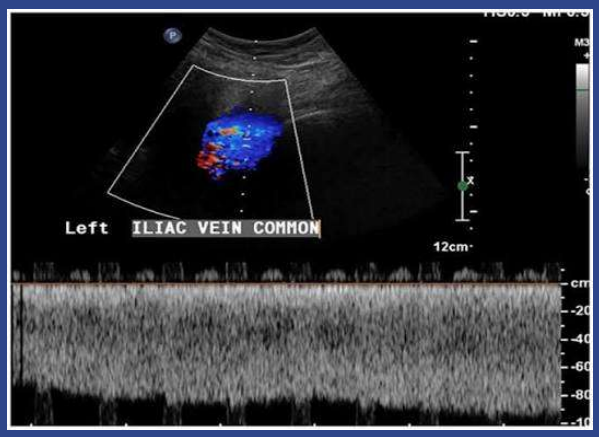

https://journals.sagepub.com/doi/10.1177/1544316720966202

https://journals.sagepub.com/doi/10.1177/1544316720966202

38

© Copyright. Society of Diagnostic Medical Sonography. All Rights Reserved.

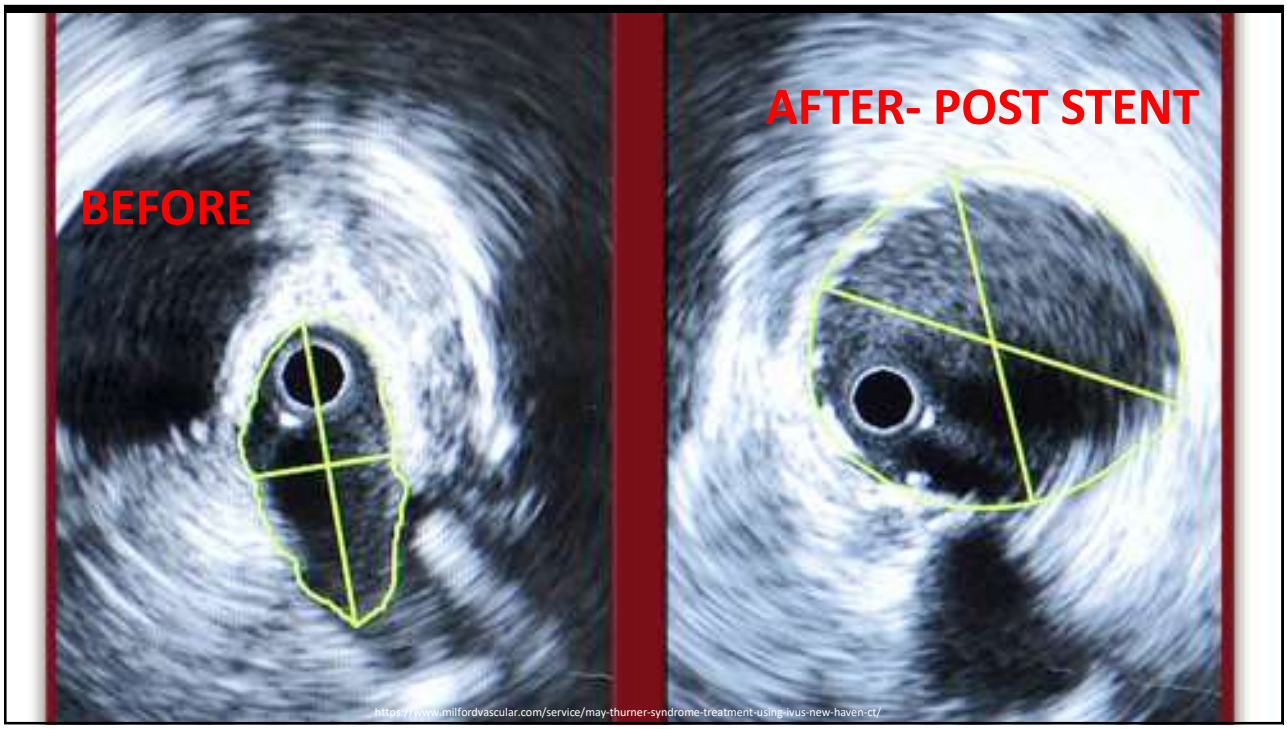

39

May-Thurner Interpretation Pearls

- Compression of the left common iliac vein can be present in asymptomatic individuals.
- Clinically meaningful disease is suggested by swelling, venous claudication, DVT, collaterals, or marked waveform asymmetry.
- A normal femoral waveform with good phasicity lowers suspicion for high-grade iliac obstruction.
- Be precise in reports: suspected proximal obstruction vs directly visualized iliac compression.

40

© Copyright. Society of Diagnostic Medical Sonography. All Rights Reserved.

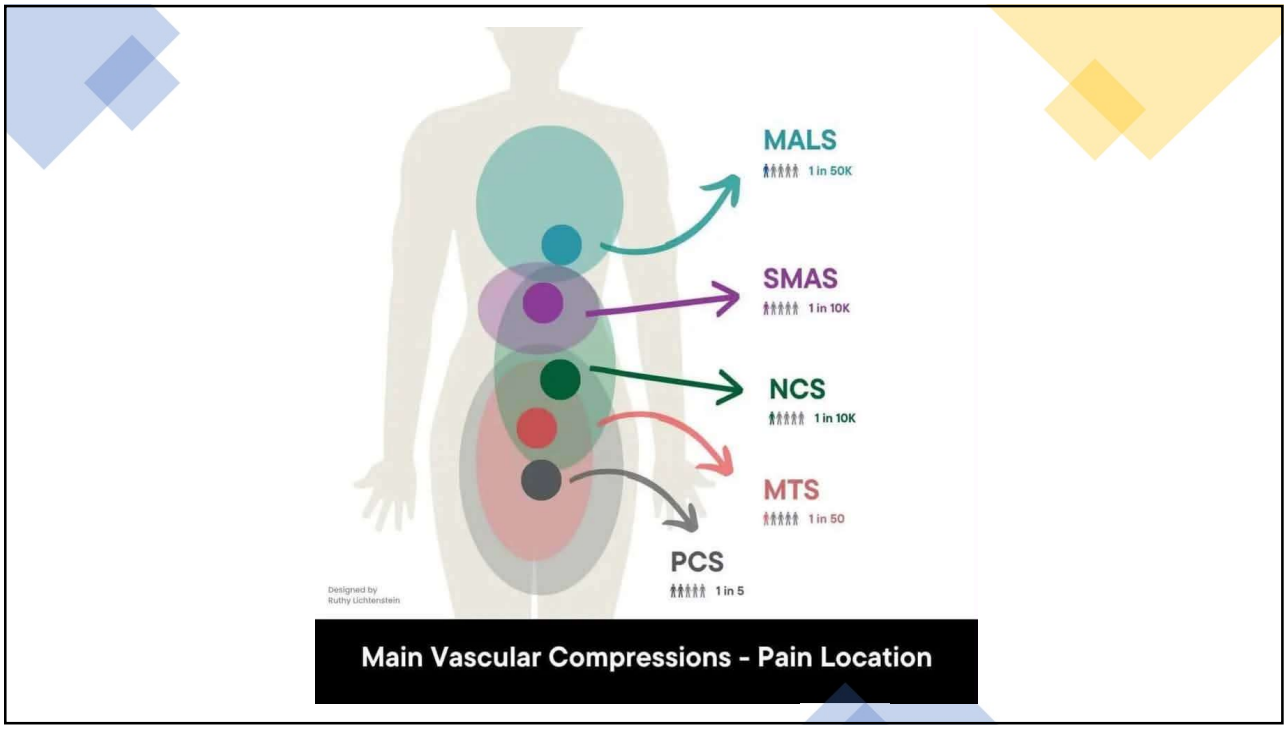

41

Case Study

- 19-year-old male presents with an enlarged left scrotum, intermittent achiness in December 2023, no hematuria
  - Patient is 6'2" and approximately 155 pounds
- Initial scrotal ultrasound reveals a large left-sided varicocele
  - Preliminary view of left renal vein indicates enlargement and possible Nutcracker appearance
  - Full renal vein evaluation was then ordered and performed separately
- Left open inguinal varicolectomy was performed by the urologist in March 2024

42

© Copyright. Society of Diagnostic Medical Sonography. All Rights Reserved.

Left scrotal varicocele



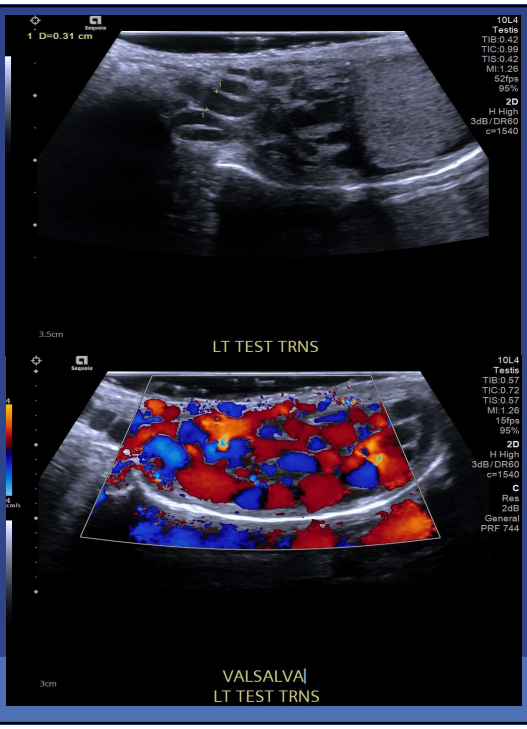

Personal files of A. Zehm

43

Left renal vein evaluation





44

© Copyright. Society of Diagnostic Medical Sonography. All Rights Reserved.

Left renal vein evaluation

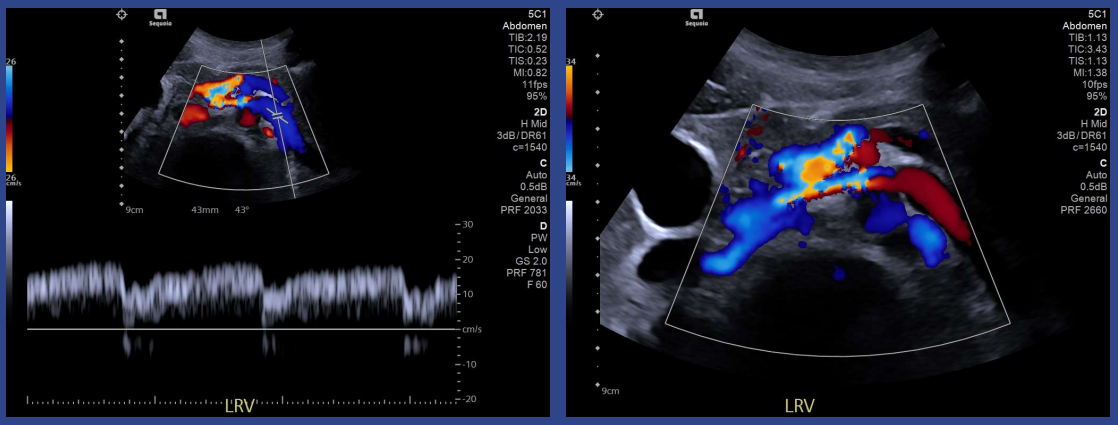

45

Left renal vein evaluatio

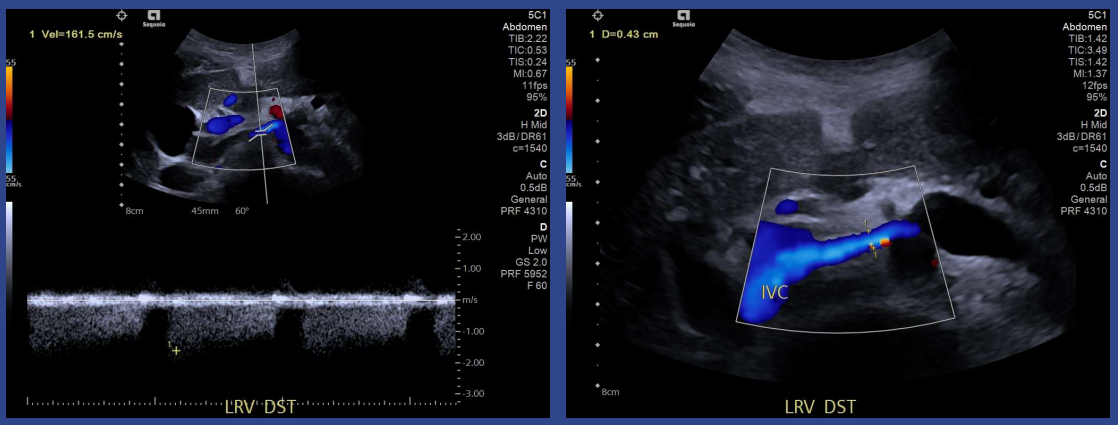

46

© Copyright. Society of Diagnostic Medical Sonography. All Rights Reserved.

Evaluation for Nutcracker Syndrome





47

Evaluation for Nutcracker Syndrome





48

© Copyright. Society of Diagnostic Medical Sonography. All Rights Reserved.

Evaluation of kidneys

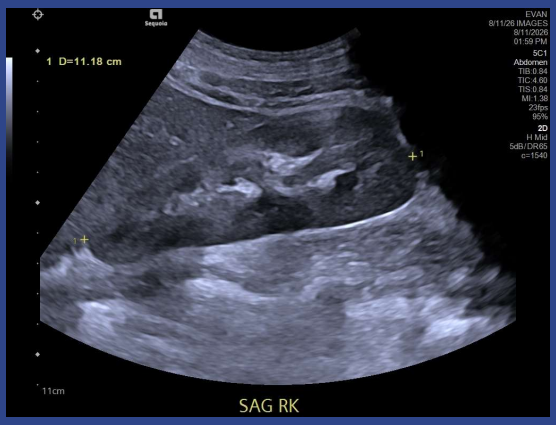



49

Case Study continued

- Several months following the varicolectomy, the patient still had no relief of symptoms and left-sided varicocele remained the same size
- Decision was made to seek a consult with a vascular surgeon which took place in October 2024
- Recommendation by vascular was watchful waiting with an attempt to gain weight and see if symptoms resolve. A a 6-month follow-up ultrasound was scheduled after this.
- At the 6-month follow-up, the vascular doctor also ordered IVC and iliac vein ultrasound due to continued left pelvic pressure and achiness, now radiating down the left leg at times causing the patient to experience significant pain when standing

50

© Copyright. Society of Diagnostic Medical Sonography. All Rights Reserved.

Case Study continued

- Ultrasound in April 2025 revealed a probable reduction in diameter of the left common iliac vein suggestive of May Thurner syndrome
- Decision was made to perform an IVUS and left renal vein balloon angioplasty in July 2025 to see if overall symptoms would resolve
- Follow-up 1 month later revealed mild improvement in symptoms
- In early November 2025, the patient returned to vascular with increased groin pain, left greater than right. Additionally, the patient reported significant bilateral leg pain prohibiting standing for long periods of time
- Next decision was to confirm with IVUS and treat May Thurner by stenting the left common iliac vein later November 2025

51

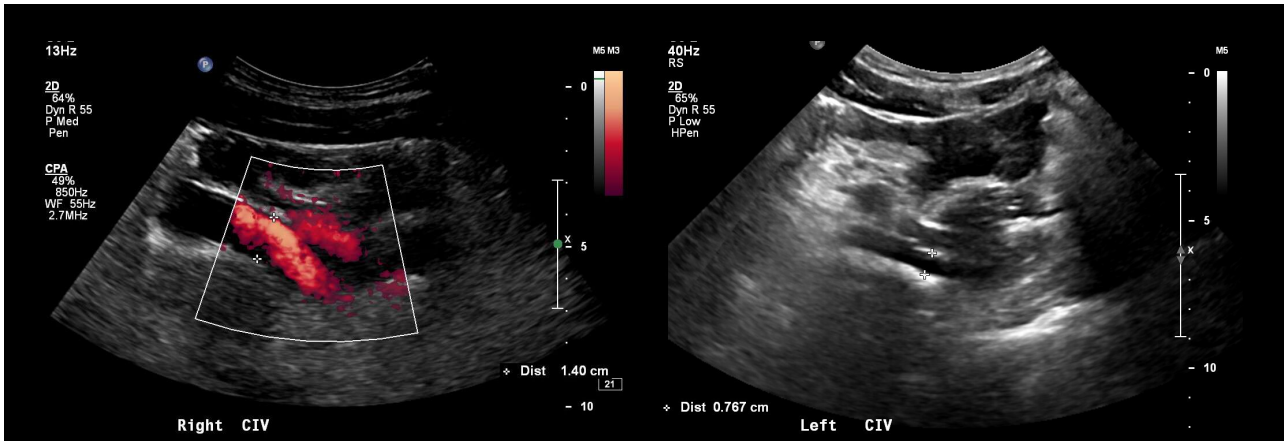

Case Study- Common Iliac Veins

Personal files of A. Zehm

52

© Copyright. Society of Diagnostic Medical Sonography. All Rights Reserved.

Case Study continued-

- Patient had venogram with intravascular ultrasound in November 2025 with subsequent placement of a left common iliac stent
- The diagnosis of May Thurner syndrome was confirmed with an 85% diameter reduction in the left CIV



Personal files of A. Zehm

53

Case Study continued

- Patient returned to vascular spring 2026 with left flank and continued left pelvic pain
- Because of limited NCS treatment options and young age of the patient, the decision was made to coil the left testicular vein to try to help relieve pelvic pressure and inability to stand for long periods
- The coil procedure was scheduled for May 2026, but did not occur due to insurance issues
- Patient subsequently went to a cardiovascular physician for a second opinion.
- CT was performed which confirmed the left CIV stent had migrated slightly (no images available) and the left renal vein was still significantly dilated. Ultrasound performed again to confirm NCS

54

© Copyright. Society of Diagnostic Medical Sonography. All Rights Reserved.

Nutcracker Syndrome



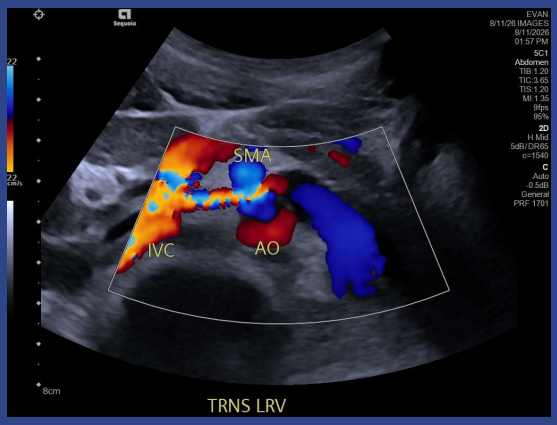

Personal files of A. Zehm

55

Case Study continued

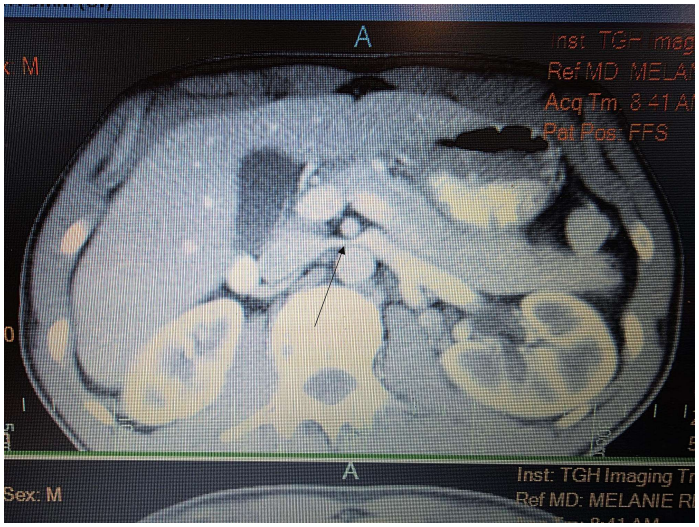

56

© Copyright. Society of Diagnostic Medical Sonography. All Rights Reserved.

Case Study continued

- Currently the patient and his mother (ME!) are exploring options for consultations regarding surgical options of left renal vein transplantation or a therapeutic nephrectomy (and subsequent donation of the LK) to treat the Nutcracker syndrome, which is thought to be the underlying cause of most, if not all, of the patient's signs and symptoms



57

Beyond the "big four": other compression patterns

- Popliteal artery entrapment: dynamic arterial compression with plantarflexion/dorsiflexion maneuvers.
- Thoracic outlet vascular compression: positional subclavian/axillary arterial or venous changes.
- Iliocaval or renal vein variants: retroaortic/circumaortic LRV, duplicated IVC, pelvic collateral pathways.
- Endofibrosis or functional stenosis in athletes can mimic dynamic compression physiology.
- Principle remains the same: reproduce symptoms, provoke compression safely, and document waveform change.

58

© Copyright. Society of Diagnostic Medical Sonography. All Rights Reserved.

CT/MRI correlation slides: what cross-sectional imaging contributes

Ultrasound proves physiology; CT/MRI clarifies anatomy and alternatives.

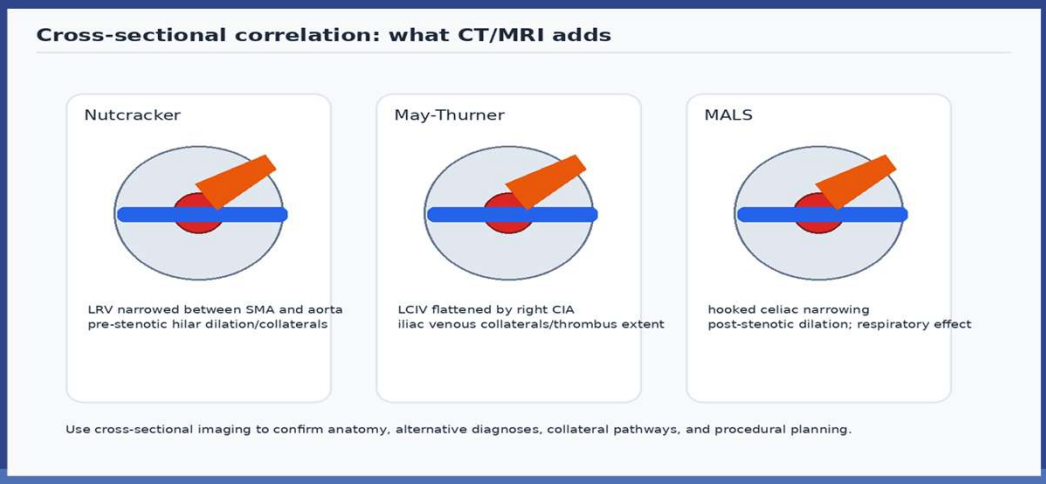

59

How to Write Useful Ultrasound Impressions

- State whether the compressed segment was directly visualized or inferred from indirect findings.
- Include key measurements: velocities, ratios, diameters, respiratory phase, and patient position when relevant.
- Describe secondary signs: upstream dilation, collateral veins, reflux, thrombus, turbulence, damped phasicity.
- Use cautious language when symptoms or secondary signs are absent.
- Recommend correlation or adjunct imaging when ultrasound is limited or intervention is considered.

60

© Copyright. Society of Diagnostic Medical Sonography. All Rights Reserved.

Interpretation framework: Avoid diagnosing a syndrome from anatomy alone

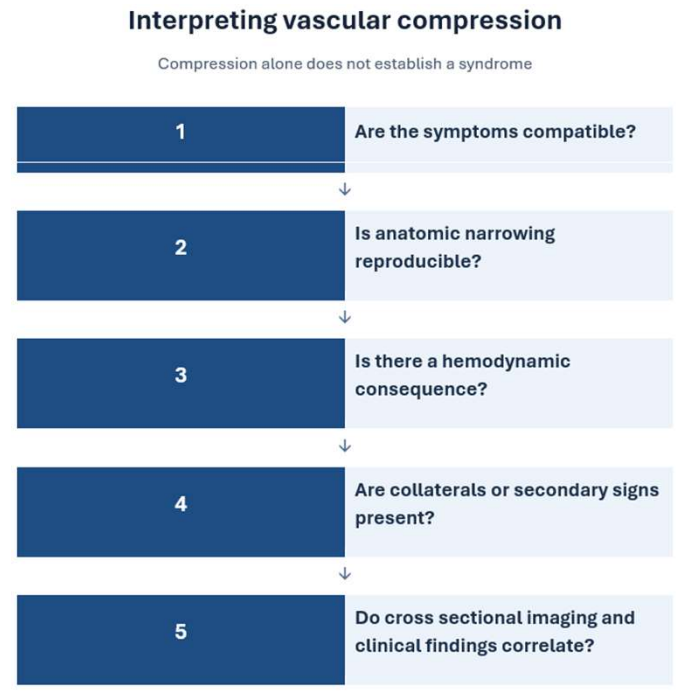

61

Quality and Safety

- Do not press hard over veins when evaluating compression physiology
- Record respiration, body position, fasting state, and provocative manuevers
- Save representative greyscale, color, and spectral Doppler images from each relative segment
- Angle-correct carefully and avoid measuring velocities in sharply curved segments when possible
- Document limitations honestly: bowel gas, body habitus, pain, inability to stand, nonfasting state

62

© Copyright. Society of Diagnostic Medical Sonography. All Rights Reserved.

Take Home Messages

- Compression is anatomy; syndrome is anatomy plus symptoms plus hemodynamic consequence.
- Duplex Doppler is powerful because it is dynamic: respiration, posture, and provocation matter.
- Ratios and waveforms are usually more useful than isolated velocities.
- Secondary signs—collaterals, dilation, reflux, thrombus, damped phasicity—raise diagnostic confidence.
- CT/MRI correlation clarifies anatomy, excludes mimics, and supports procedural planning.

63

References

- Ananthan K, Onida S, Davies AH. Nutcracker syndrome: an update on current diagnostic criteria and management guidelines. Eur J Vasc Endovasc Surg. 2017.
- Erben Y, Gloviczki P, Kalra M …Treatment of nutcracker syndrome with open and endovascular interventions. Journal of Vascular Surgery: Venous and Lymphatic Disorders, 2015; 3, 389-396
- Greenspan, Jacob, et al. "A novel approach for the treatment of Nutcracker syndrome: A case report." *Annals of Vascular Surgery*, vol. 79, Feb. 2022, https://doi.org/10.1016/j.avsg.2021.07.046.
- Horton KM, Talamini MA, Fishman EK. Median arcuate ligament syndrome: evaluation with CT angiography. Radiographics. 2005.
- Kane KE, Koons AL. The Aortomesenteric Angle as an Aid in Diagnosing Superior Mesenteric Artery Syndrome. *Clin Pract Cases Emerg Med*. 2017;1(2):140-141. Published 2017 Mar 16. doi:10.5811/cpcem.2016.12.30676
- Kim SH. Doppler US and CT diagnosis of Nutcracker syndrome. Korean J Radiol. 2019 review literature.

64

© Copyright. Society of Diagnostic Medical Sonography. All Rights Reserved.

References

- Kurklinsky AK, Rooke TW. Nutcracker phenomenon and Nutcracker syndrome. Mayo Clin Proc. 2010.
- Oğuzkurt L, et al. Compression of the left common iliac vein in asymptomatic subjects and patients with left iliofemoral DVT. J Vasc Interv Radiol. 2008.
- Moneta GL, et al. Duplex ultrasound criteria for celiac artery compression syndrome. J Vasc Surg. 1991.
- Merrett ND, et al. Superior mesenteric artery syndrome: diagnosis and treatment strategies. J Gastrointest Surg. 2009.
- Pellerito JS, Polak JF, eds. Introduction to Vascular Ultrasonography. 6th ed. Saunders; 2012.
- Youssef, Ashraf Talaat. "Evaluation of Asymptomatic Patients with Median Arcuate Ligament Syndrome (Mals) Using Color Duplex Ultrasound and Computed Tomographic (Ct) Angiography." *American Journal of Cardiovascular Disease Research* 1.1 (2013): 7-11.

© Copyright. Society of Diagnostic Medical Sonography. All Rights Reserved.