2026 SDMS Annual Conference

Diffuse the Role of Ultrasound in Dense Breast Patient Screening

Beth A. Berry
B.S., RDMS, RDCS

1

SPEAKER PRESENTATION DISCLAIMER

The content and views presented are made available for educational purposes only. The information presented are the opinions of the presenter and do not necessarily represent the views of the Society of Diagnostic Medical Sonography (SDMS) or its affiliated organizations, officers, Boards of Directors, or staff members.

The presenter is responsible for ensuring balance, independence, objectivity, scientific rigor, and avoiding commercial bias in their presentation. Before making the presentation, the presenter is required to disclose to the audience any relevant financial interests or relationships with manufacturers or providers of medical products, services, technologies, and programs.

The SDMS and its affiliated organizations, officers, Board of Directors, and staff members disclaim any and all liability for all claims that may arise out of the use of this educational activity.

2

© Copyright. Society of Diagnostic Medical Sonography. All Rights Reserved.

RESEARCH DISCLAIMER

The information presented in this presentation is based on research conducted to the best of the presenters' abilities and knowledge. Research involves uncertainty and is subject to limitations. The findings and conclusions presented herein may be influenced by various factors including but not limited to data quality, methodology, assumptions, and interpretation.

Research outcomes may not always accurately predict real-world scenarios or future events. While the presenter may make efforts to ensure the accuracy and reliability of the information presented, completeness or absolute correctness is not guaranteed. This presentation is intended for informational purposes only and should not be construed as professional advice. Participants are encouraged to independently verify any information provided and consult relevant experts or professionals where appropriate.

The SDMS and its affiliated organizations, officers, Board of Directors, and staff members disclaim any and all liability for all claims that may arise out of the use of this educational activity.

3

GENERATIVE AI DISCLAIMER

The presenter utilized the use of large language models (LLMs) and generative artificial intelligence (AI) as a productivity tool to assist in drafting and refining content in this presentation.

While these tools can aid in structuring ideas, summarizing, paraphrasing, and language polishing, they have inherent limitations and cannot replace human creativity, critical thinking, or expert judgment. AI-generated content may contain errors, biases, or gaps in knowledge.

This presentation is intended for informational purposes only and should not be construed as definitive or authoritative guidance. Participants are encouraged to critically evaluate the information presented and consult relevant experts as needed. The SDMS and its affiliated organizations, officers, Board of Directors, and staff members disclaim any and all liability for claims that may arise from the use or interpretation of this educational material.

4

© Copyright. Society of Diagnostic Medical Sonography. All Rights Reserved.

Objectives

- Analyze the composition and challenges of dense breast tissue
- Differentiate dense breast imaging and diagnosis across various modalities
- Identify the benefit of ultrasound in imaging dense breast tissue

5

- Ducts
- Glands / Glandular tissue
- Fibrous (connective) tissue
- Fatty tissue

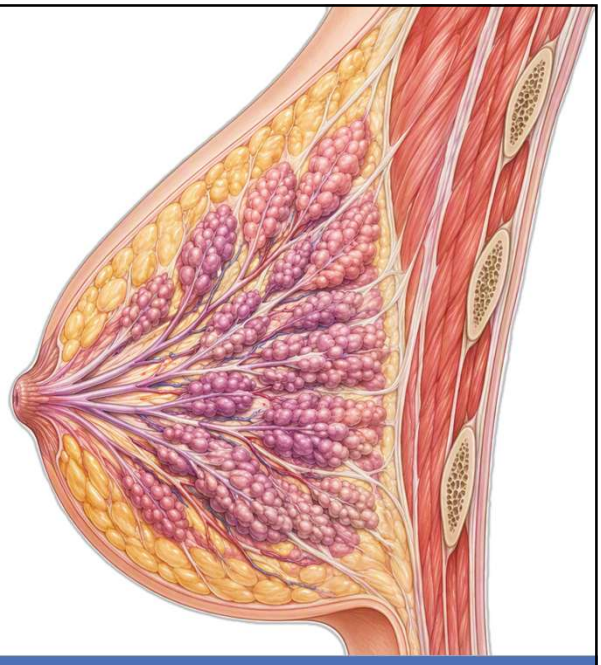

6

© Copyright. Society of Diagnostic Medical Sonography. All Rights Reserved.

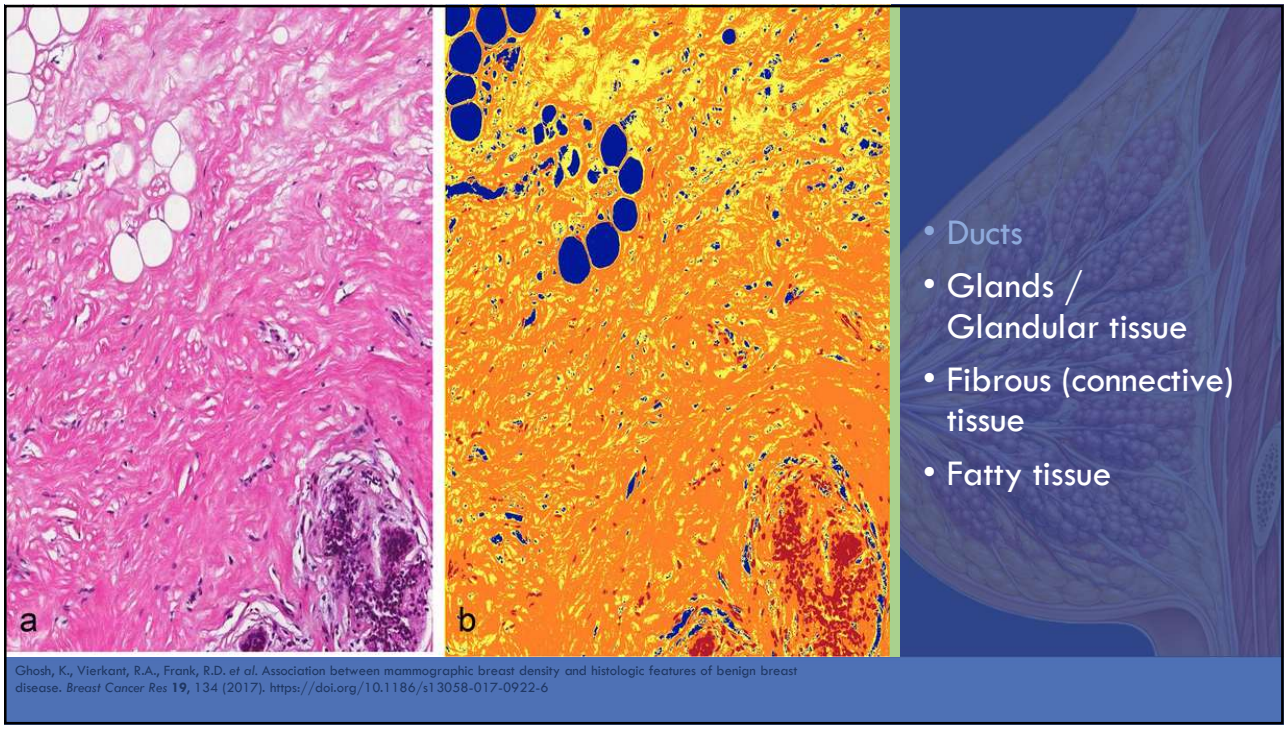

7

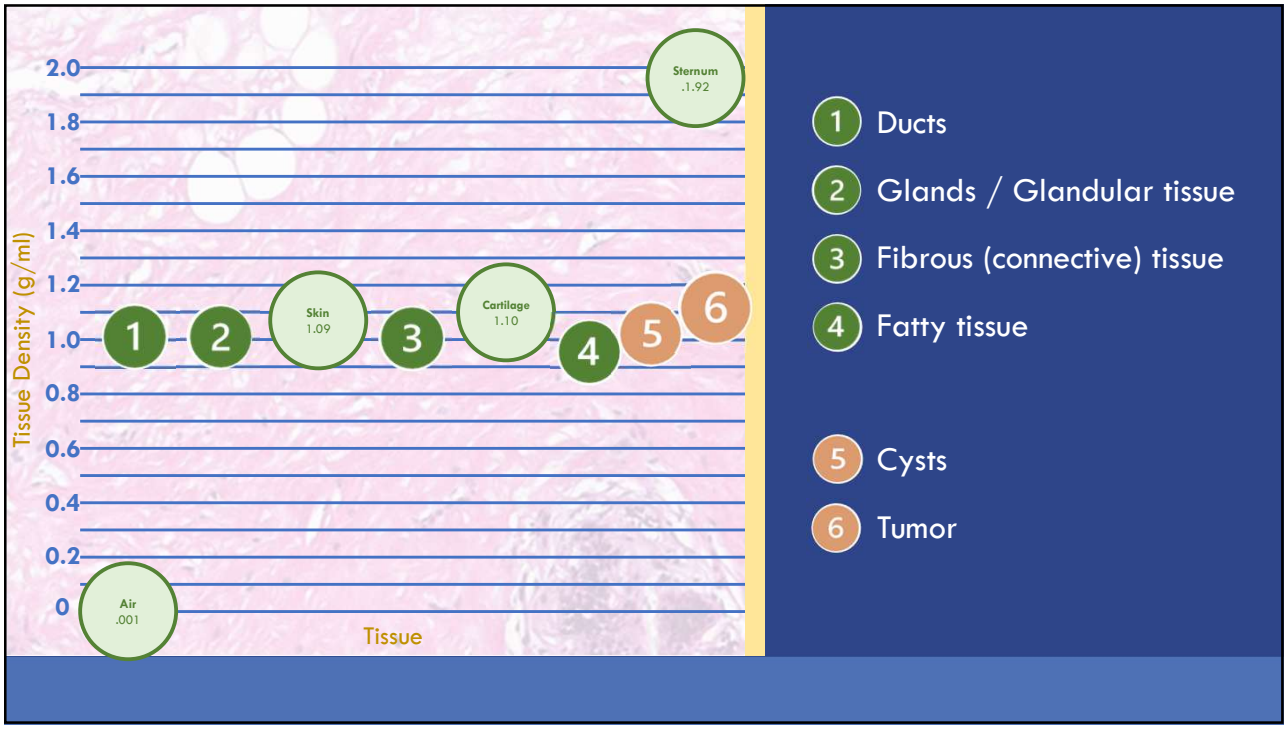

8

© Copyright. Society of Diagnostic Medical Sonography. All Rights Reserved.

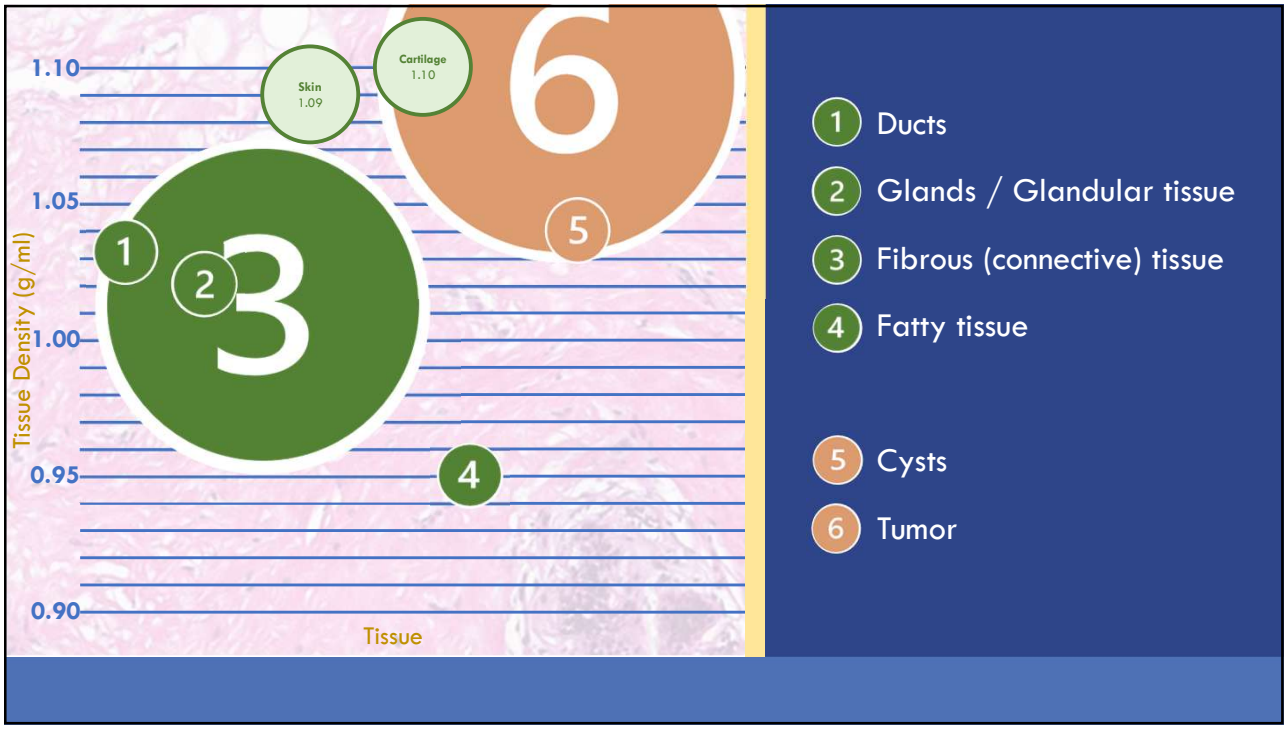

9

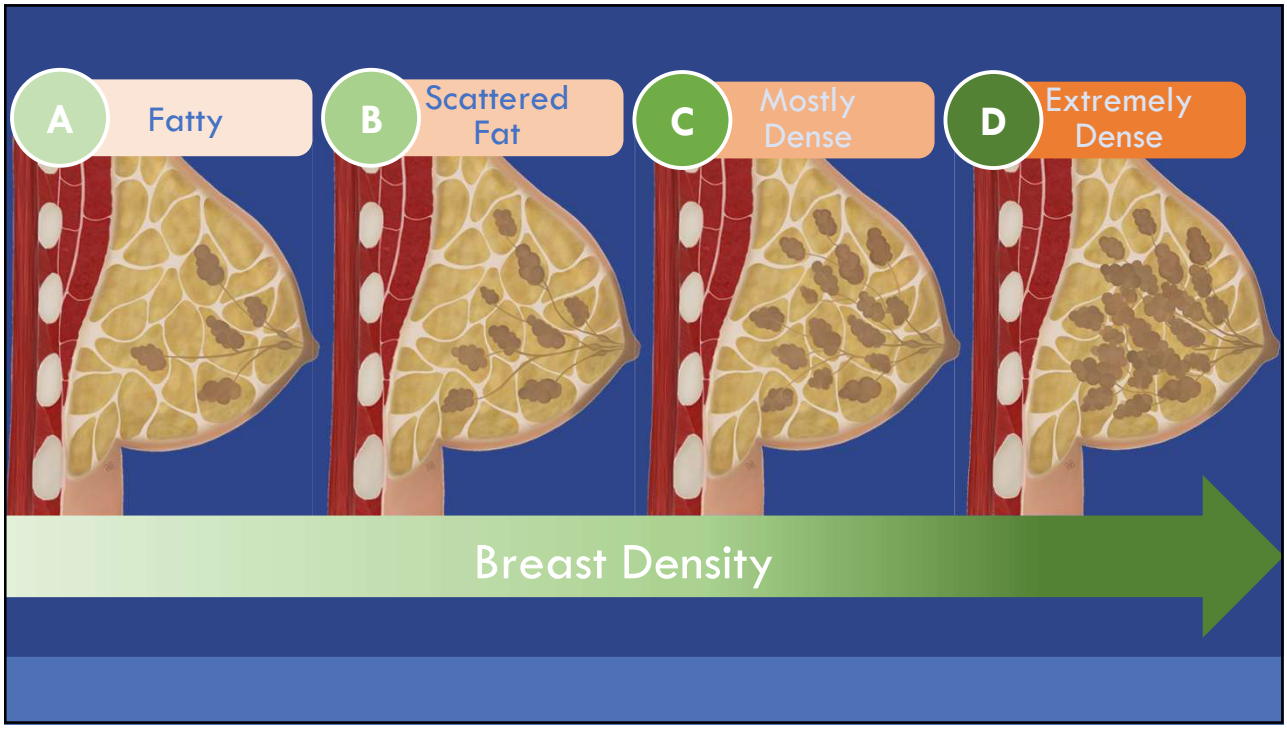

10

© Copyright. Society of Diagnostic Medical Sonography. All Rights Reserved.

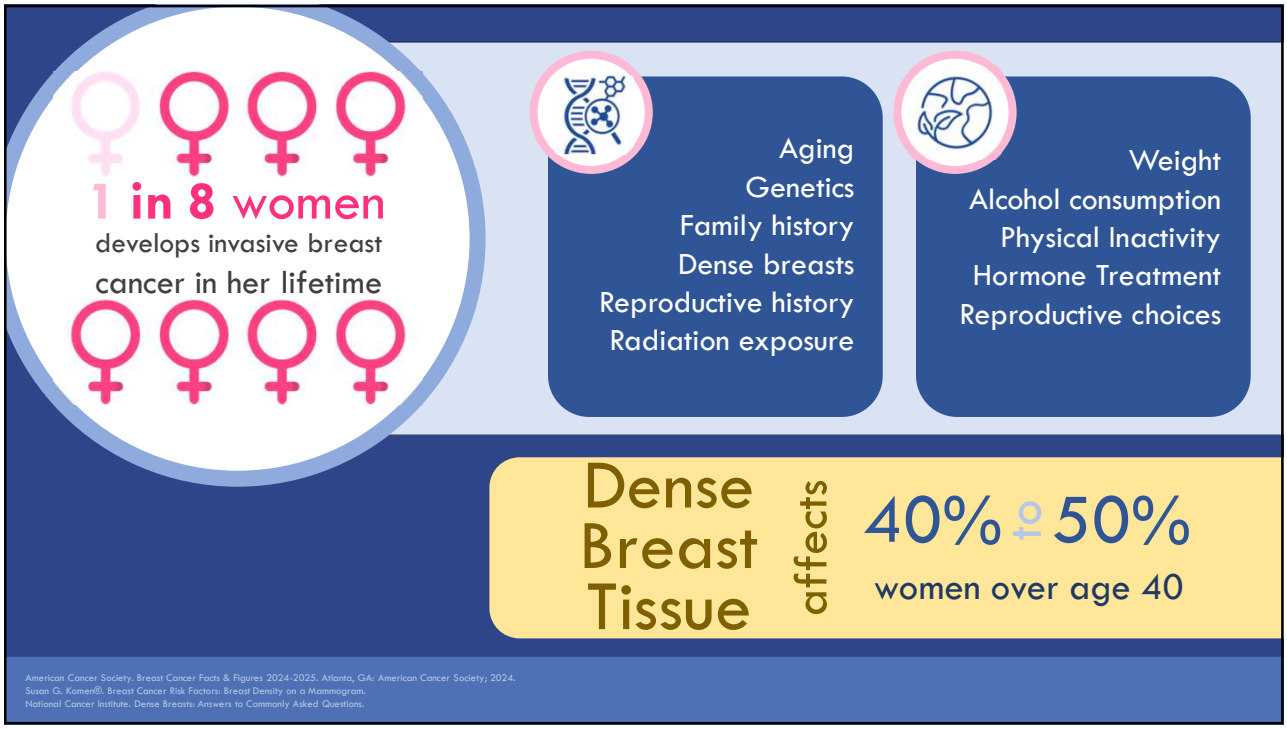

11

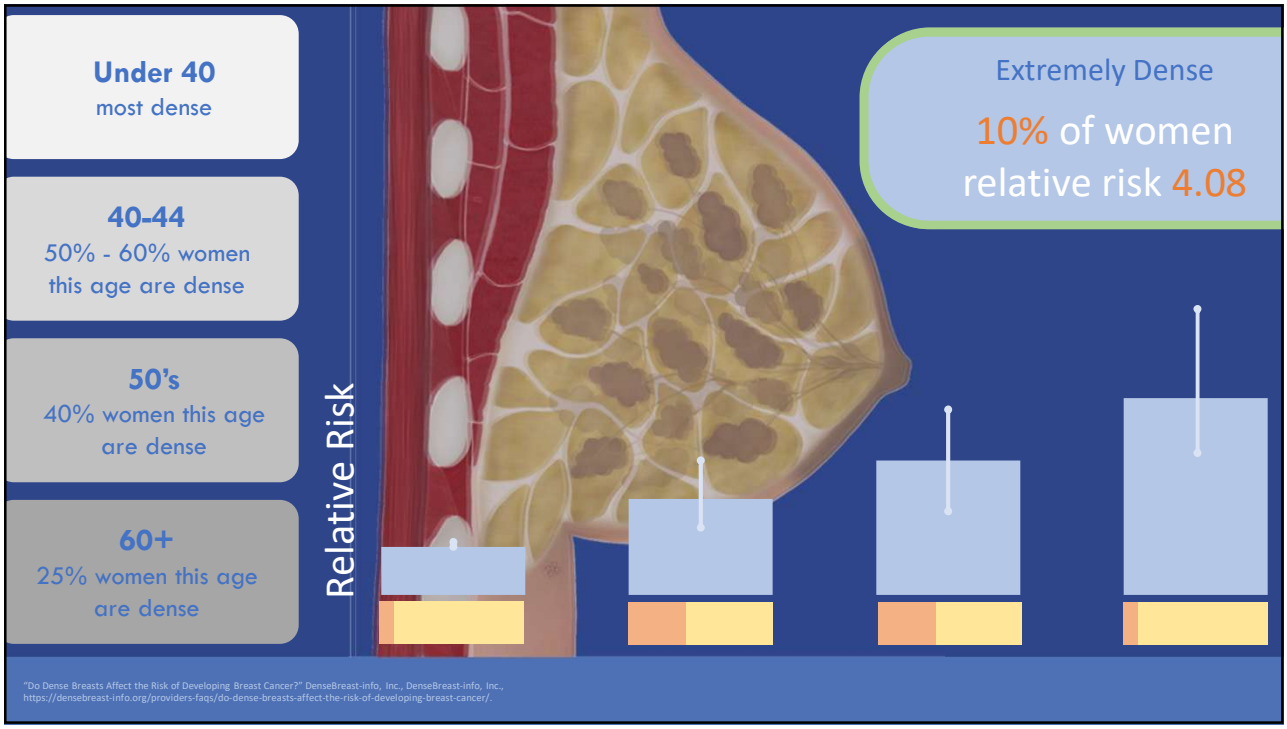

12

© Copyright. Society of Diagnostic Medical Sonography. All Rights Reserved.

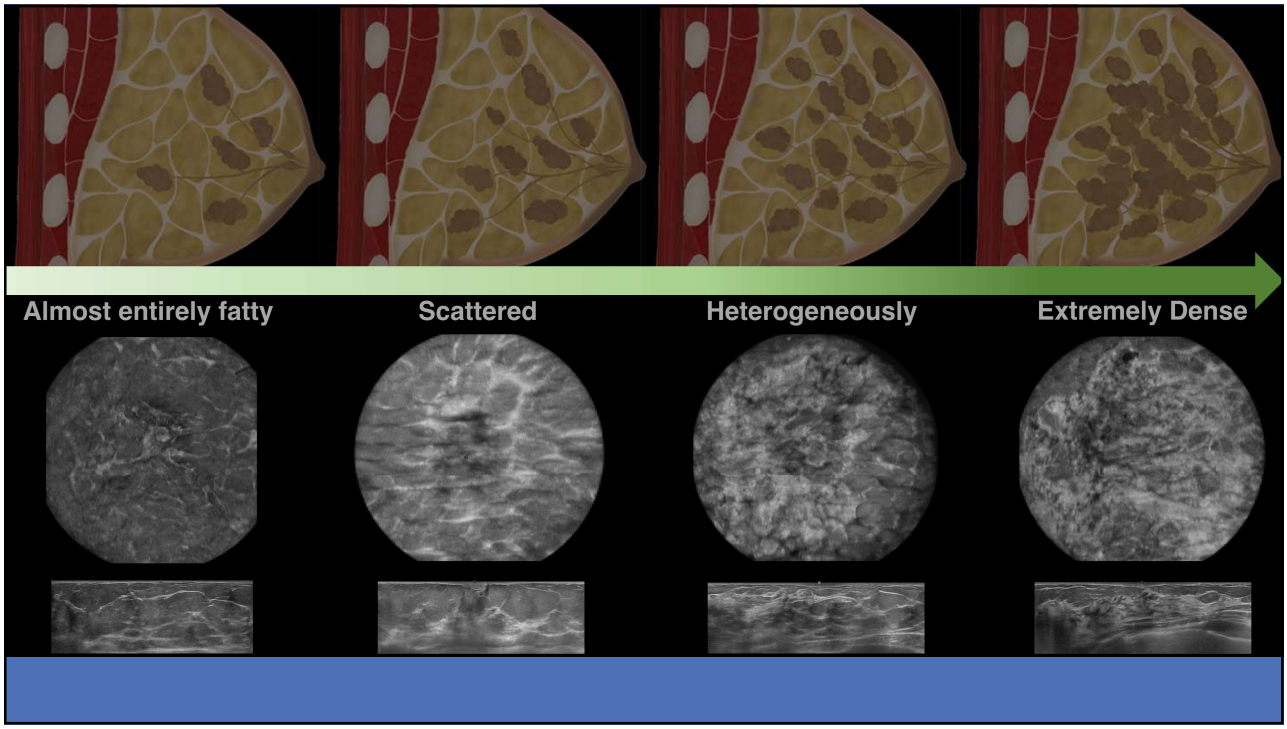

13

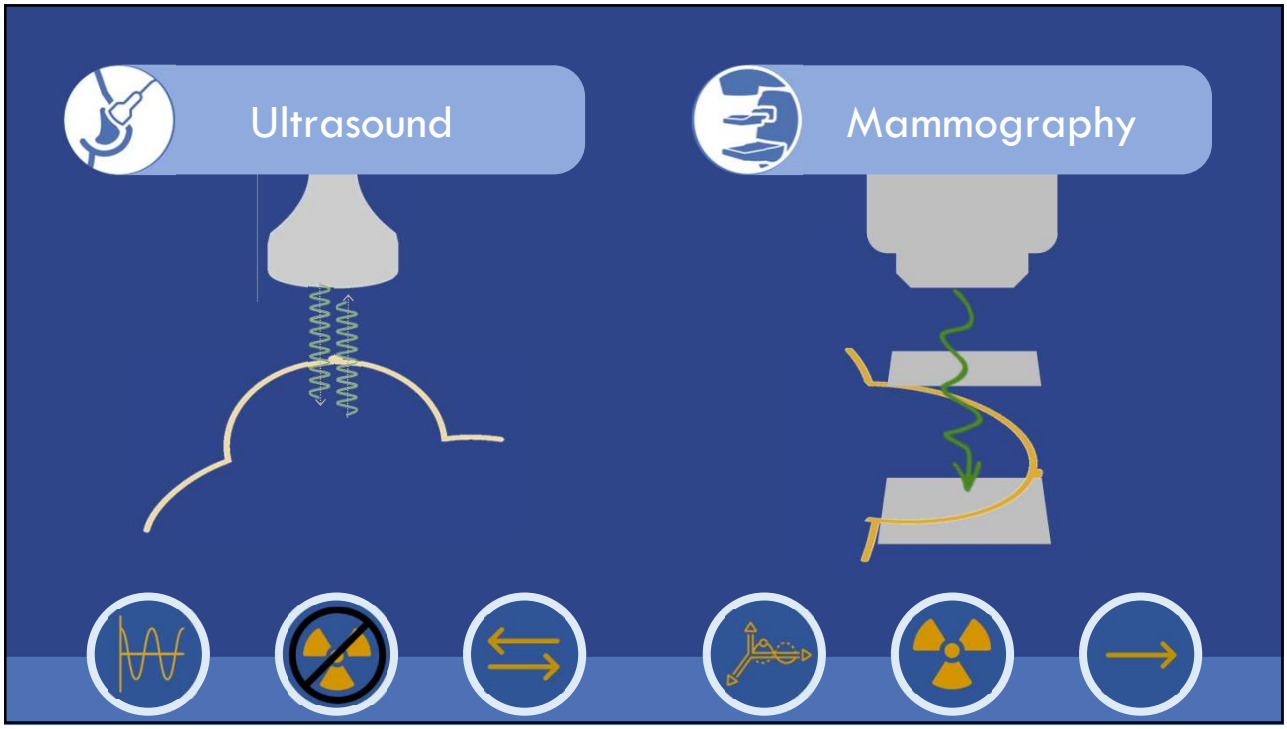

14

© Copyright. Society of Diagnostic Medical Sonography. All Rights Reserved.

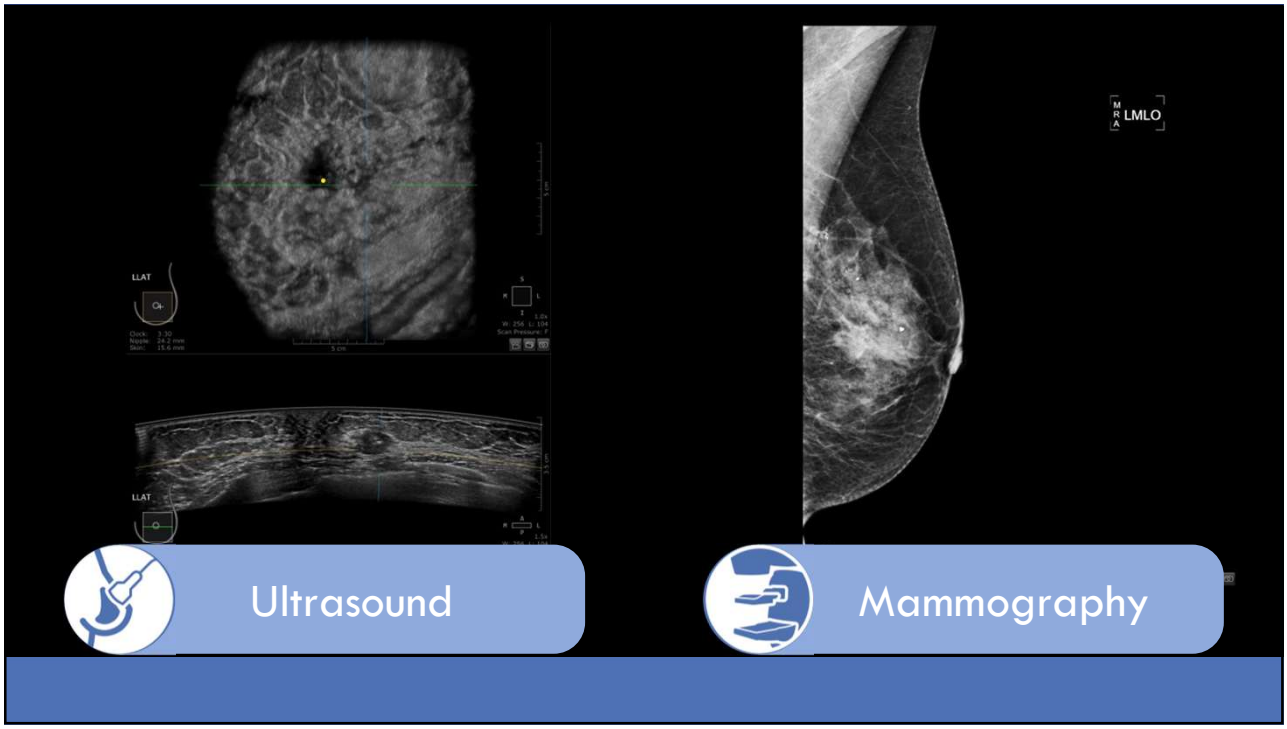

15

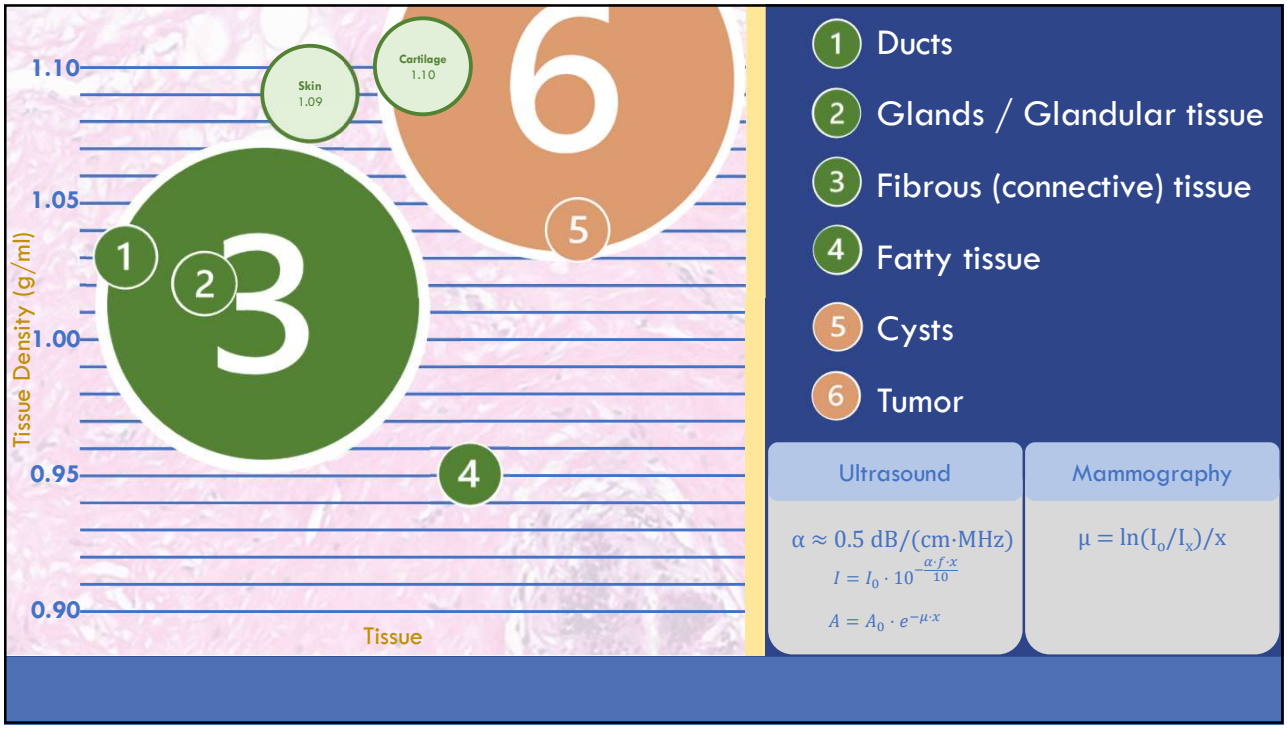

16

© Copyright. Society of Diagnostic Medical Sonography. All Rights Reserved.

	Ultrasound $\alpha \approx 0.5$ dB/(cm·MHz)	Mammography $\mu = \ln(I_o/I_x)/x$
Adipose	.7 dB	0.794 cm^{-1}
Glandular	1.0 dB	1.659 cm^{-1}
Cysts	0.2 dB	0.5 cm^{-1}
Tumor	2.0 dB	1.608 cm^{-1}

17

A. Fatty

B. Scattered fibroglandular

C. Heterogeneously dense

D. Extremely dense

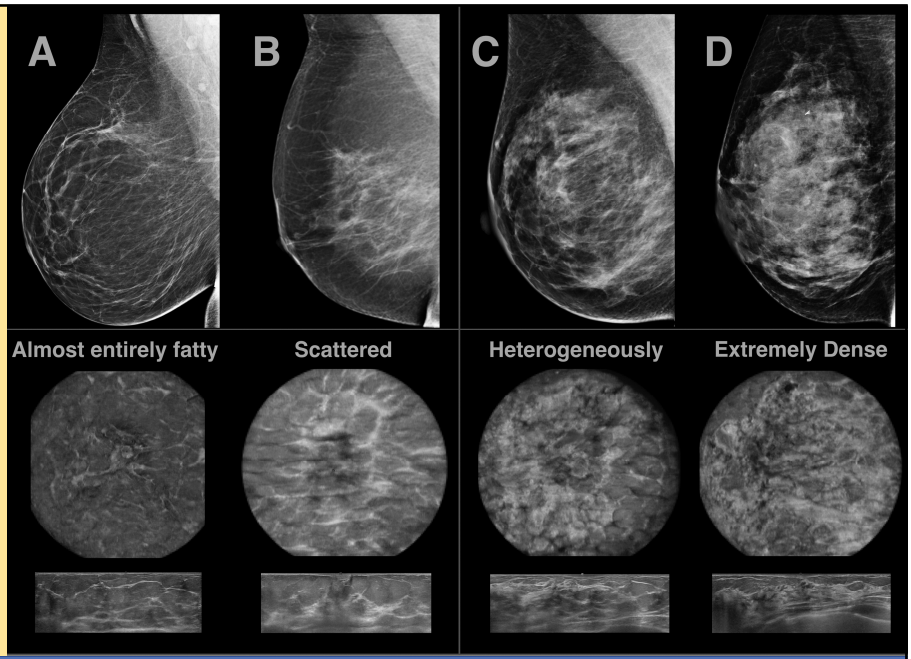

Karst, I., Henley, C., Gottschalk, N., Floyd, S., & Mendelson, E. B. (2019). Three-dimensional automated breast US: Facts and artifacts. RadioGraphics, 39(4), 913–931. https://doi.org/10.1148/rg.2019180104 [pubs.rsna.org]

18

© Copyright. Society of Diagnostic Medical Sonography. All Rights Reserved.

1 Case Study



- 48 y/o female
- Presents for routine annual screening
- Additional screening for breast density

19

1 Case Study

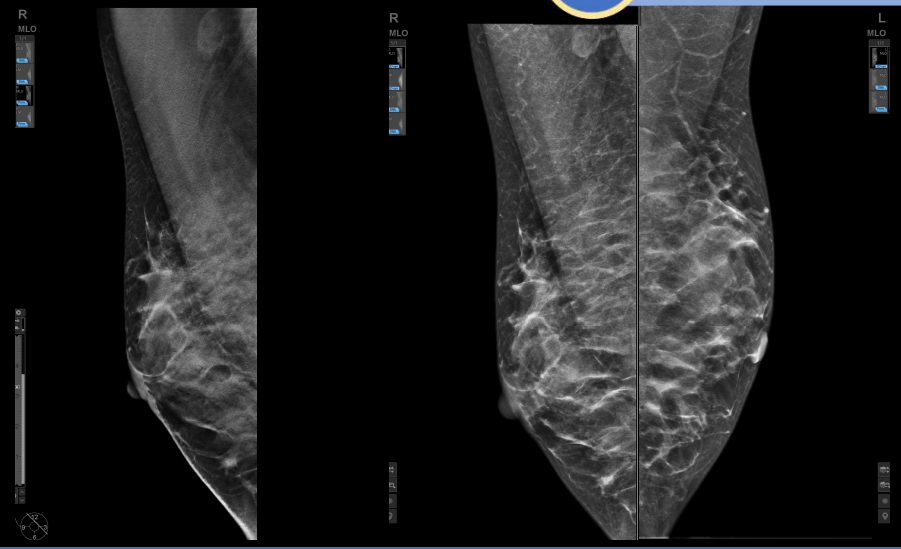

20

© Copyright. Society of Diagnostic Medical Sonography. All Rights Reserved.

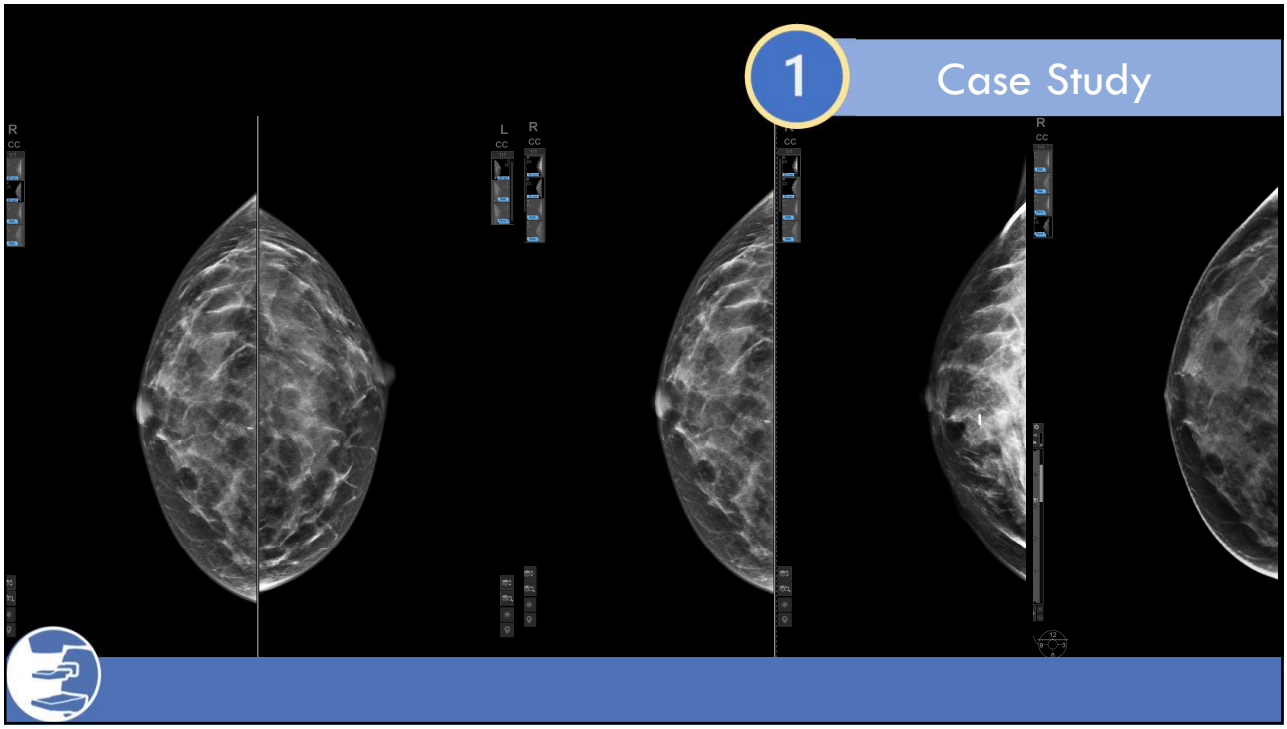

21

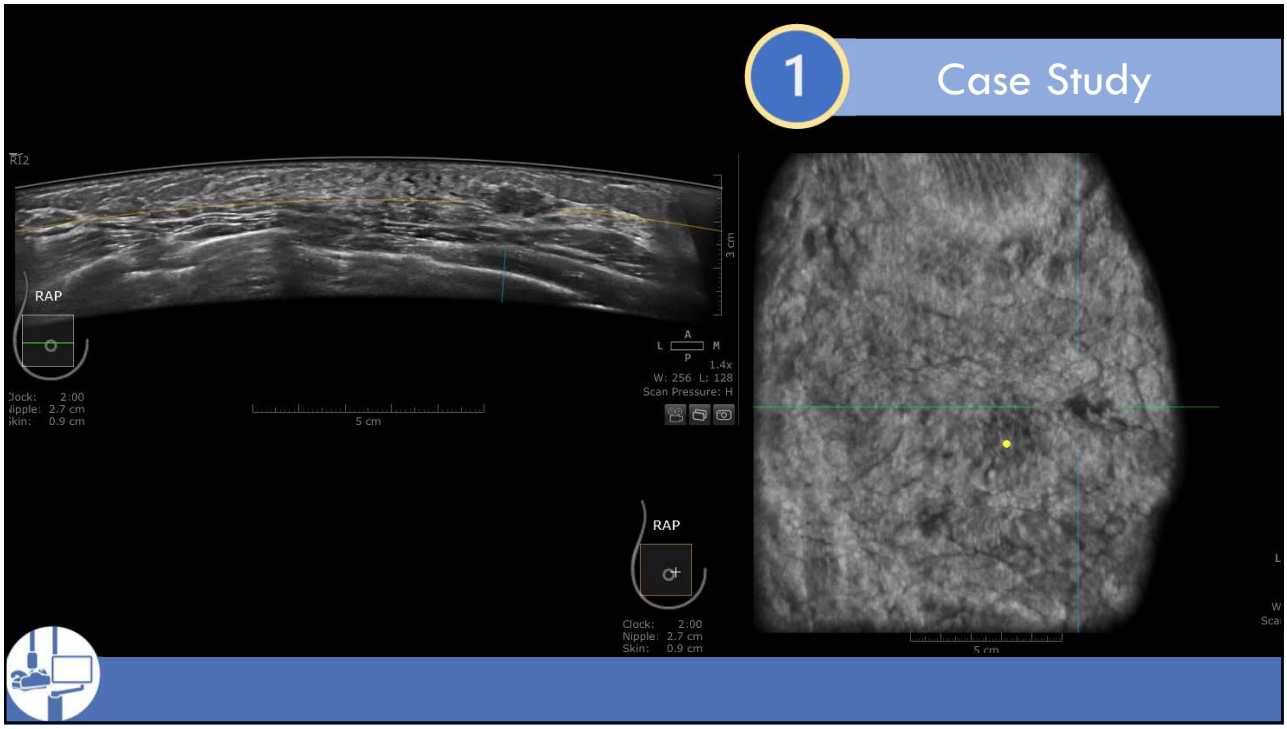

22

© Copyright. Society of Diagnostic Medical Sonography. All Rights Reserved.

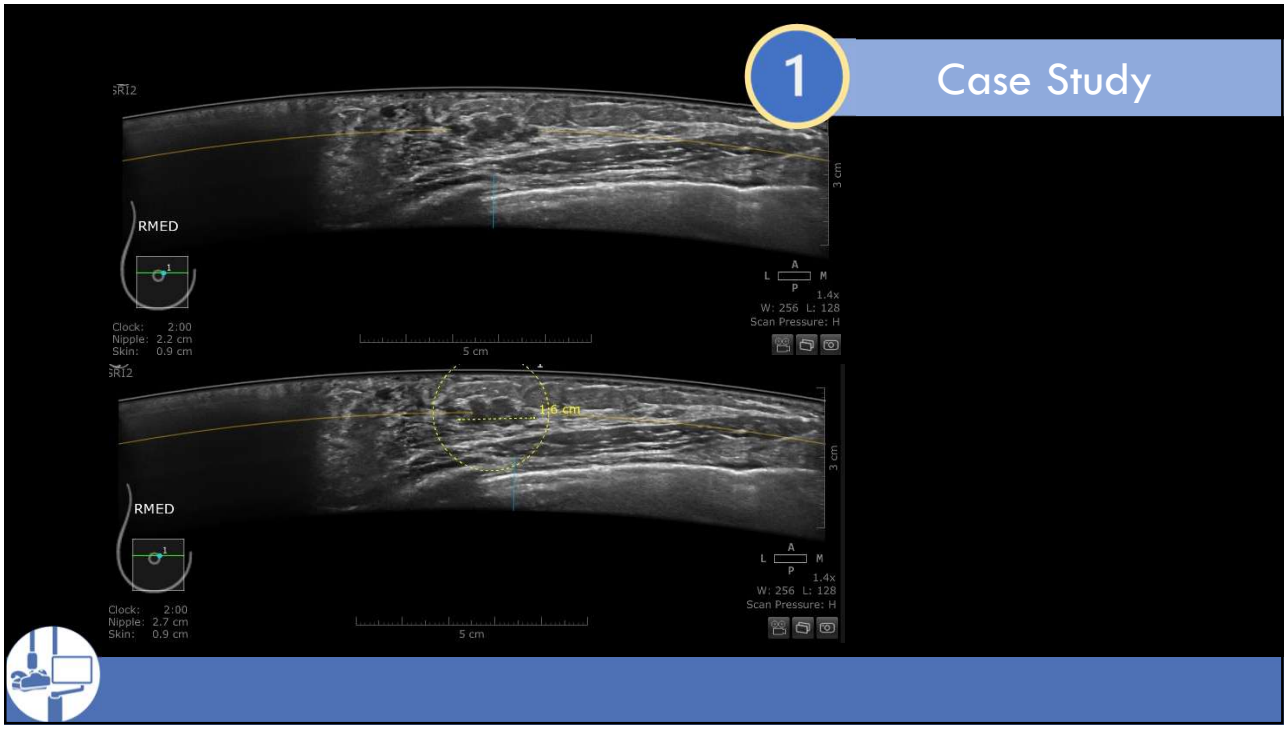

23

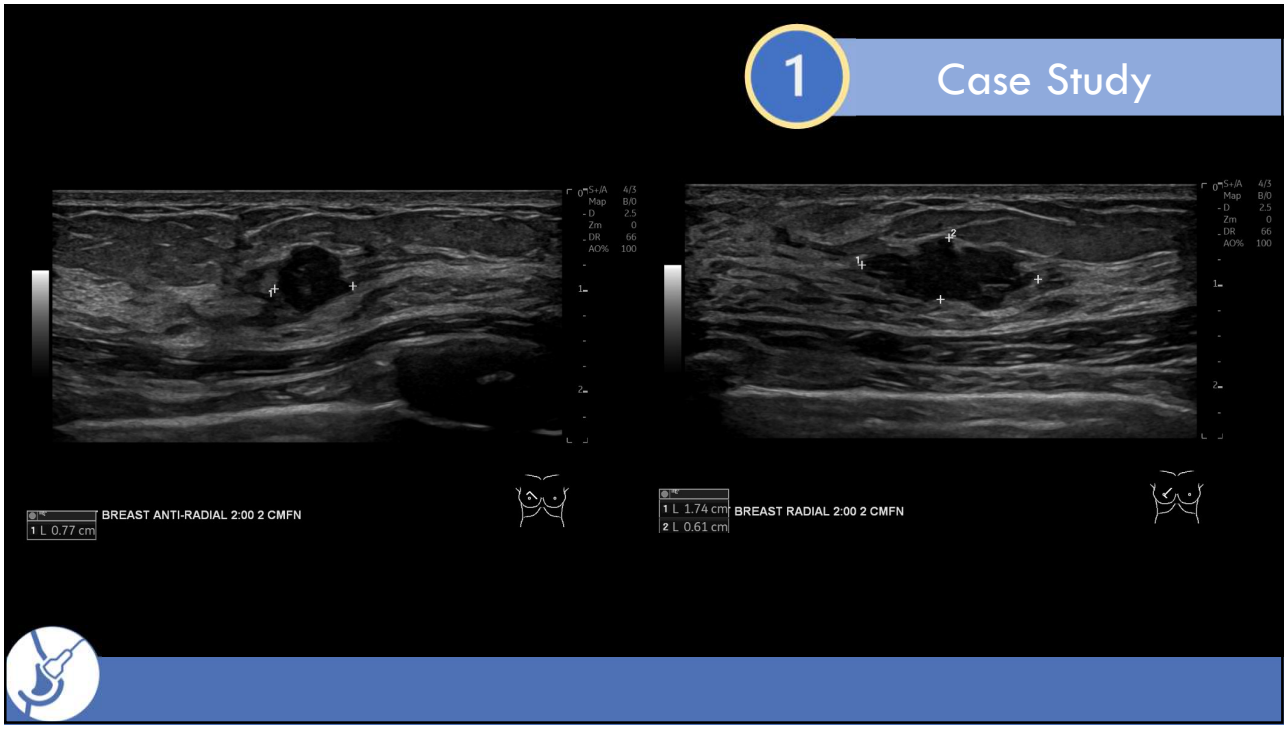

24

© Copyright. Society of Diagnostic Medical Sonography. All Rights Reserved.

1 Case Study



- 1.7cm grade 3 IDC

25

2 Case Study



- 56 y/o female
- Presents for routine annual screening
- Additional screening for breast density

26

© Copyright. Society of Diagnostic Medical Sonography. All Rights Reserved.

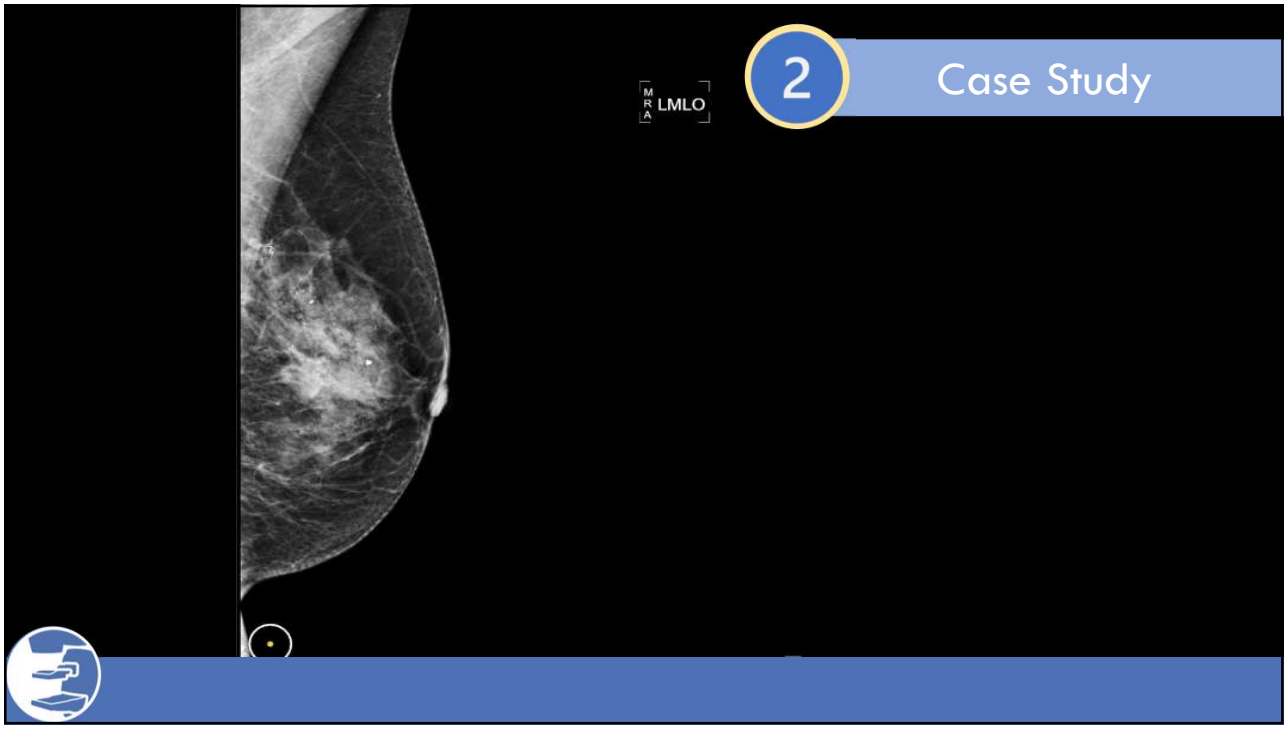

27

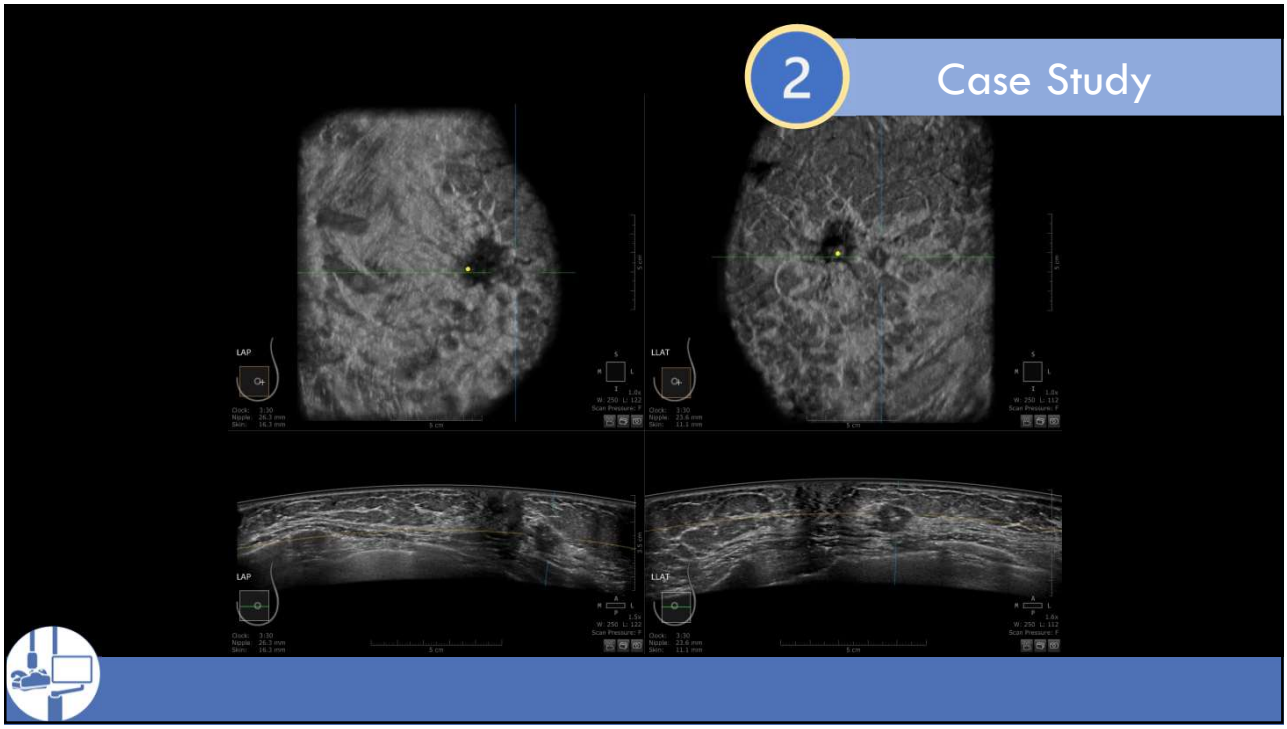

28

© Copyright. Society of Diagnostic Medical Sonography. All Rights Reserved.

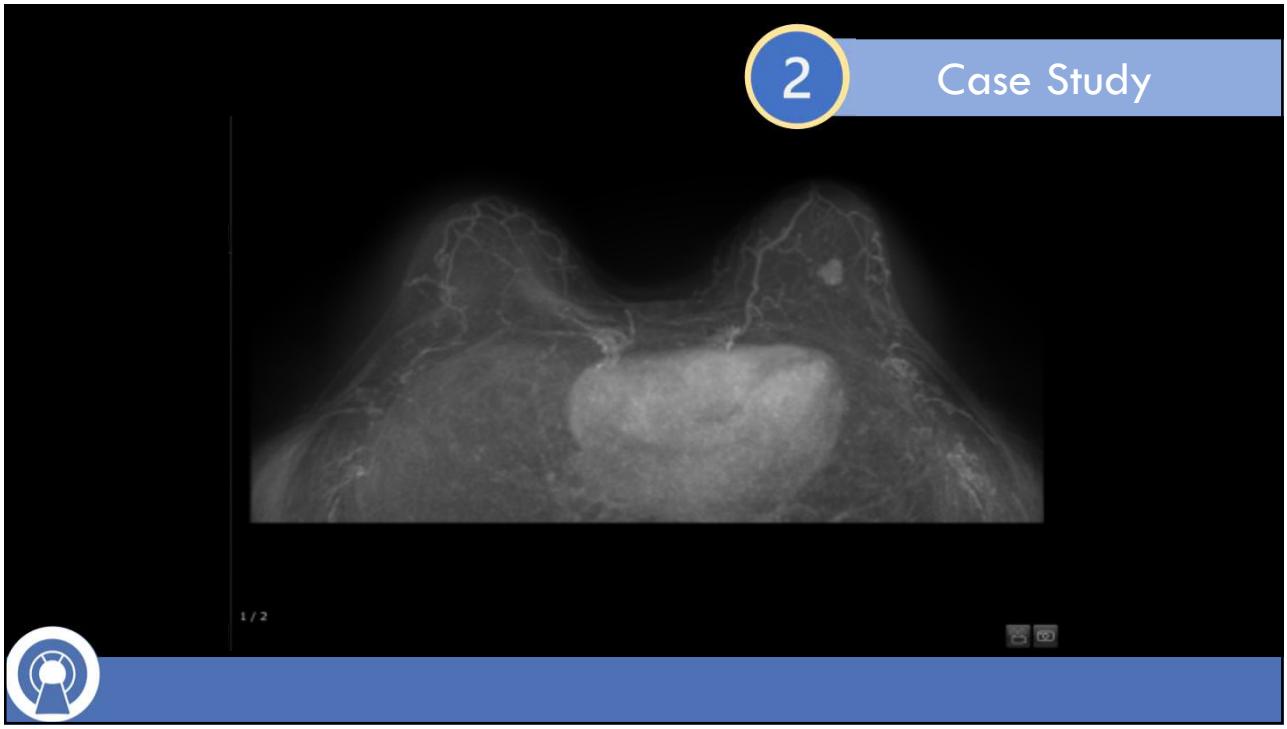

29

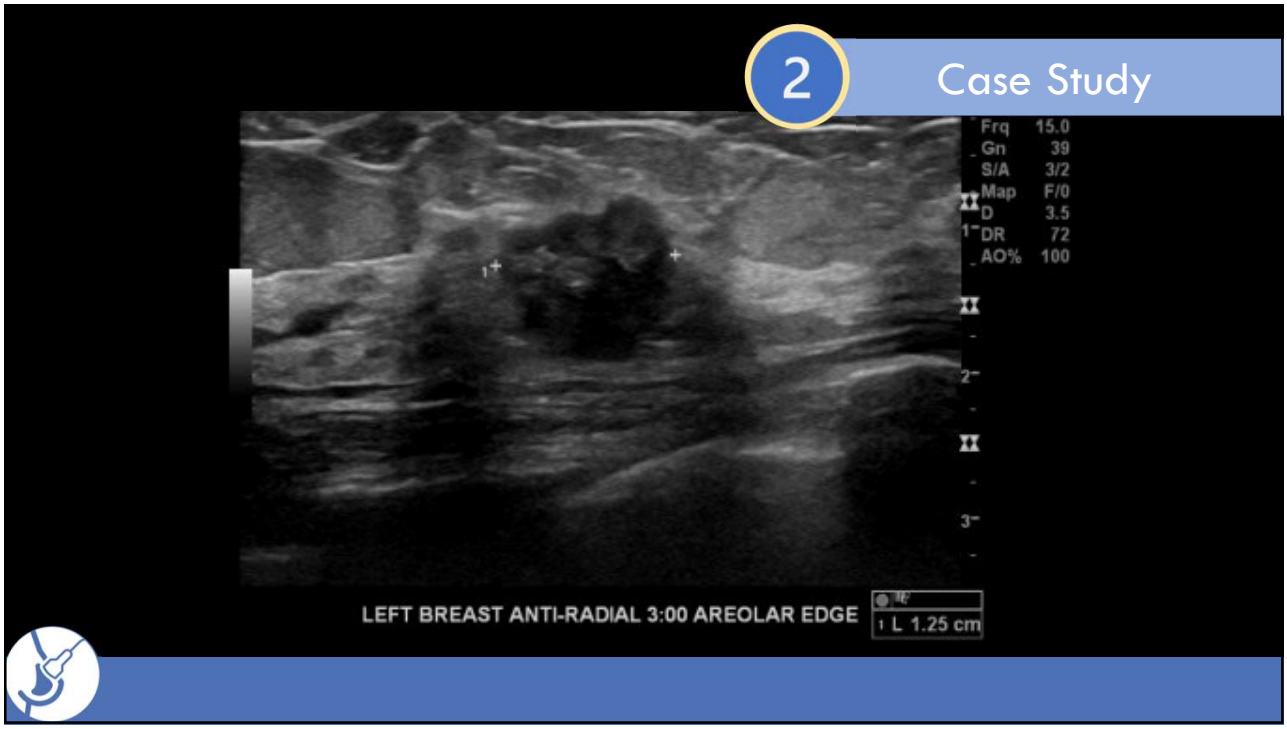

30

© Copyright. Society of Diagnostic Medical Sonography. All Rights Reserved.

2 Case Study



- Biopsy-proven IDC

31

- Visualization of tissue differentiation in dense tissue
- Detection of small invasive cancers obscured on mammography by dense tissue
- Improved patient care and outcomes with earlier detection

32

© Copyright. Society of Diagnostic Medical Sonography. All Rights Reserved.

Summary

- ✓ Analyzed the composition and challenges of dense breast tissue
- ✓ Differentiated dense breast imaging and diagnosis across various modalities
- ✓ Identified the benefit of ultrasound in imaging dense breast tissue

33



34

© Copyright. Society of Diagnostic Medical Sonography. All Rights Reserved.