The Floor Plan:

A Sonographer's Guide to Pelvic Floor Imaging

Cara L. Hill, BS, RDMS, RVT, RT (R)

1

1

SPEAKER PRESENTATION DISCLAIMER

The content and views presented are made available for educational purposes only. The information presented are the opinions of the presenter and do not necessarily represent the views of the Society of Diagnostic Medical Sonography (SDMS) or its affiliated organizations, officers, Boards of Directors, or staff members.

The presenter is responsible for ensuring balance, independence, objectivity, scientific rigor, and avoiding commercial bias in their presentation. Before making the presentation, the presenter is required to disclose to the audience any relevant financial interests or relationships with manufacturers or providers of medical products, services, technologies, and programs.

The SDMS and its affiliated organizations, officers, Board of Directors, and staff members disclaim any and all liability for all claims that may arise out of the use of this educational activity.

2

2

© Copyright. Society of Diagnostic Medical Sonography. All Rights Reserved.

GENERATIVE AI DISCLAIMER

The presenter utilized the use of large language models (LLMs) and generative artificial intelligence (AI) as a productivity tool to assist in drafting and refining content in this presentation.

While these tools can aid in structuring ideas, summarizing, paraphrasing, and language polishing, they have inherent limitations and cannot replace human creativity, critical thinking, or expert judgment. AI-generated content may contain errors, biases, or gaps in knowledge.

This presentation is intended for informational purposes only and should not be construed as definitive or authoritative guidance. Participants are encouraged to critically evaluate the information presented and consult relevant experts as needed. The SDMS and its affiliated organizations, officers, Board of Directors, and staff members disclaim any and all liability for claims that may arise from the use or interpretation of this educational material.

3

3

Objectives

- Demonstrate key scanning techniques for acquiring high-quality pelvic floor ultrasound images
- Deepen anatomical understanding by correlating pelvic floor structures with their sonographic appearance
- Identify common pelvic floor disorders and their characteristic ultrasound findings
- Support professional growth by empowering sonographers to apply advanced imaging techniques that elevate patient outcomes

4

4

© Copyright. Society of Diagnostic Medical Sonography. All Rights Reserved.

Room Check

Join at Menti.com | use code 4297 6580

5

5

Loading...

6

© Copyright. Society of Diagnostic Medical Sonography. All Rights Reserved.



7



8

© Copyright. Society of Diagnostic Medical Sonography. All Rights Reserved.

Why Is Pelvic Floor Ultrasound Important?

A Game Changer for Women's Health!

9

9

Why Is Pelvic Floor Ultrasound Important?

Dynamic Assessment
Enables real-time functional evaluation during strain, pelvic contraction, and Valsalva maneuvers to assess pelvic tissue mobility.

Multicompartmental View
Provides a comprehensive simultaneous examination of anterior, middle, and posterior pelvic compartments in a single modality.

3D/4D Evaluation of Muscle Tears
Delivers high-resolution volumetric imaging to accurately map levator ani muscle avulsions, trauma, and structural defects.

Surgical & Implant Evaluation
Offers non-invasive monitoring of synthetic mesh, slings, and surgical implants to detect erosion, folding, or displacement.

10

10

© Copyright. Society of Diagnostic Medical Sonography. All Rights Reserved.

Quantifiable Clinical Benefits

3D/4D
Volumetric Accuracy for Muscle Avulsion Detection

100%
Radiation-Free Real-Time Dynamic Imaging

< 15 min
Rapid Office-Based Point-of-Care Assessment

11

11



Image adapted from: Dietz HP. *Int Urogynecol J*. 2025. doi:10.1007/s00192-025-06334-4

12

12

© Copyright. Society of Diagnostic Medical Sonography. All Rights Reserved.

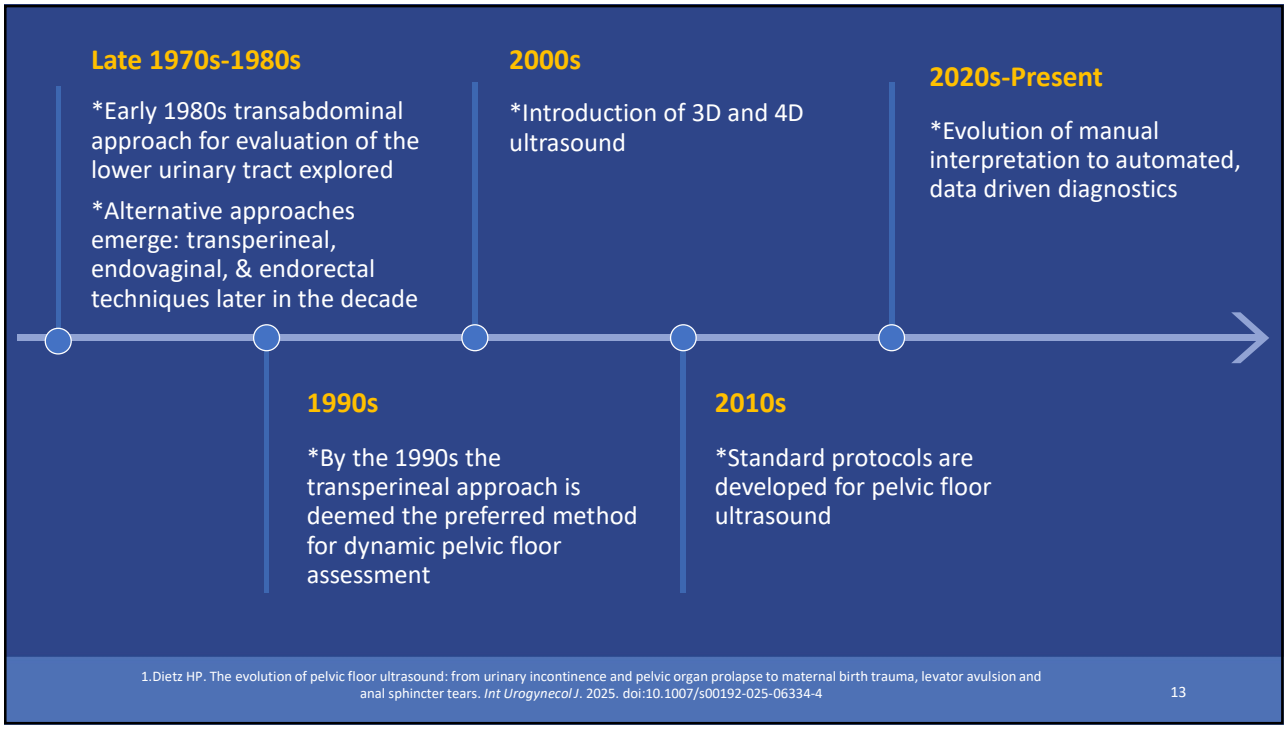

13

Primary Functions of the Female Pelvic Floor

14

14

© Copyright. Society of Diagnostic Medical Sonography. All Rights Reserved.

Primary Functions

- **Continence**
  - Squeezes around the urethra and anus to prevent involuntary leakage of urine, gas, or stool
- **Organ Support**
  - Counteracts abdominal pressure to keep the uterus, bladder, and bowel from sagging down
- **Sexual Function**
  - Provides muscle tone of the vaginal canal

15

15

Anatomy of the Female Pelvic Floor

16

16

© Copyright. Society of Diagnostic Medical Sonography. All Rights Reserved.

Anatomy of the Female Pelvic Floor

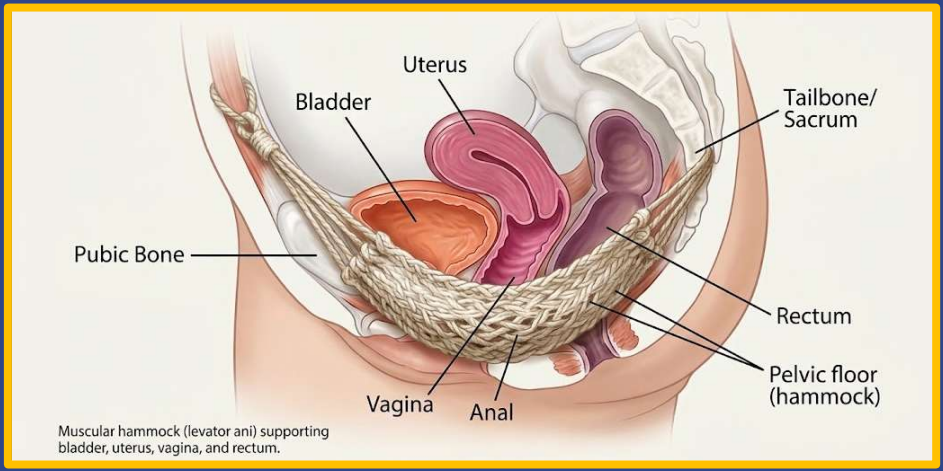

Image. Female Pelvic Floor Anatomy. Image generated using Gemini (Google AI), June 10, 2026, using the prompt: "Female Pelvic Floor Anatomy".

17

17

Anatomy of the Female Pelvic Floor

Anterior Compartment	• Urethra • Lower portion of the bladder
Pubocervical Fascia	
Middle Compartment	• Vagina • Uterus
Rectovaginal Fascia	
Posterior Compartment	• Rectum • Anal canal

18

18

© Copyright. Society of Diagnostic Medical Sonography. All Rights Reserved.

Anatomy of the Female Pelvic Floor

Superficial Layer	• Urogenital Triangle • Maintains continence & sexual function
Deep Layer	• Levator Ani • Keeps organs elevated
Posterior Layer	• Anal Triangle • Controls bowel movements

19

19

Why Ultrasound?

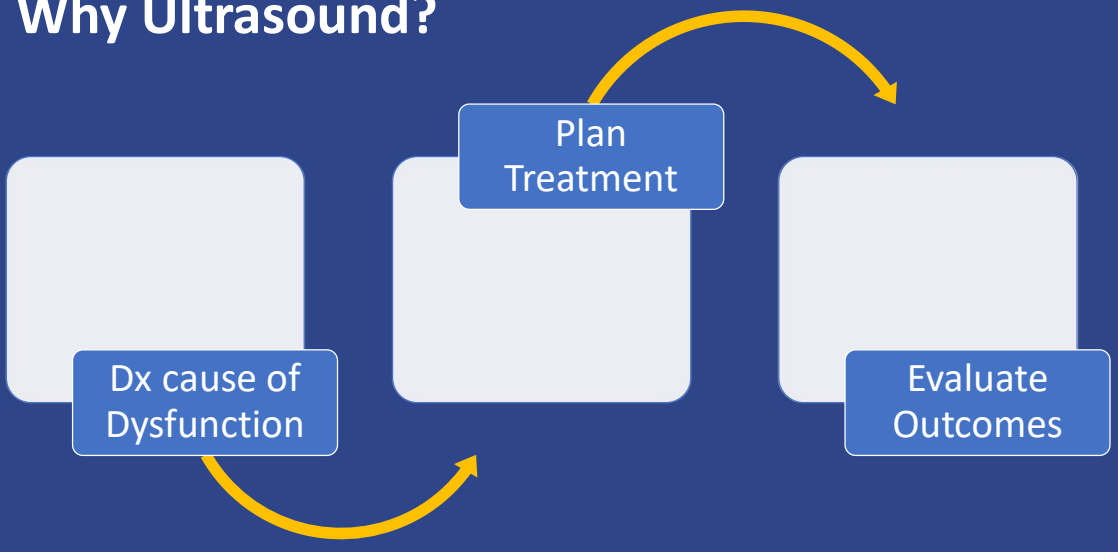

20

20

© Copyright. Society of Diagnostic Medical Sonography. All Rights Reserved.

Instrumentation & Technique

21

21

Patient Position

- Dorsal lithotomy ★
- Left lateral
- Prone

22

22

© Copyright. Society of Diagnostic Medical Sonography. All Rights Reserved.

3 Approaches



Transperineal

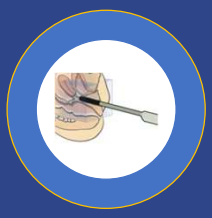

Endovaginal



Endoanal

Images adapted from: Shek KL, Dietz HP. In: Shobeiri SA, ed. *Practical Pelvic Floor Ultrasonography*. Springer; 2013:81-122. doi:10.1007/978-1-4614-8426-4

23

23

2D/3D Convex Probe

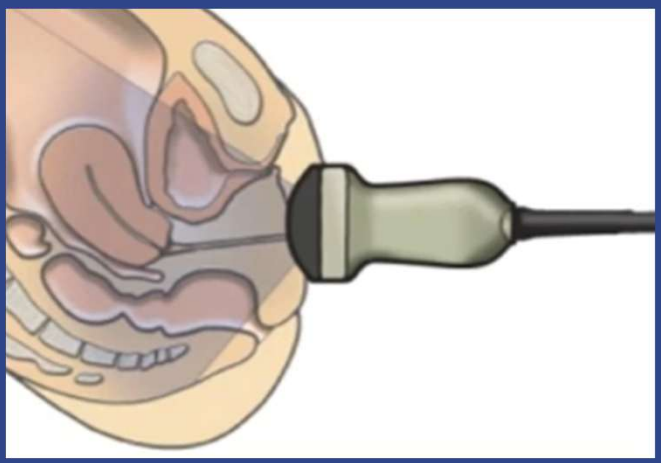

- **Transperineal:** probe placed on the perineum

Image adapted from: Shek KL, Dietz HP. In: Shobeiri SA, ed. *Practical Pelvic Floor Ultrasonography*. Springer; 2013:81-122. doi:10.1007/978-1-4614-8426-4

24

24

© Copyright. Society of Diagnostic Medical Sonography. All Rights Reserved.

2D/3D Endocavitary Probe

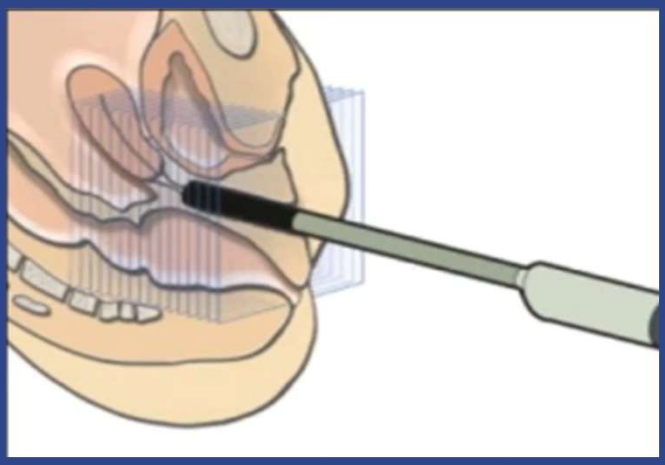

- **Endovaginal:** probe inserted into the vaginal canal

Image adapted from: Shek KL, Dietz HP. In: Shobeiri SA, ed. *Practical Pelvic Floor Ultrasonography*. Springer; 2013:81-122. doi:10.1007/978-1-4614-8426-4

25

25

2D/3D Endocavitary Probe

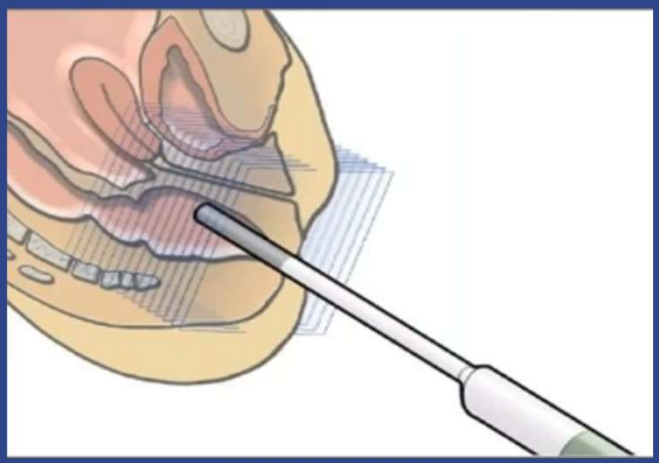

- **Endoanal:** probe placed in the anal canal

Image adapted from: Shek KL, Dietz HP. In: Shobeiri SA, ed. *Practical Pelvic Floor Ultrasonography*. Springer; 2013:81-122. doi:10.1007/978-1-4614-8426-4

26

26

© Copyright. Society of Diagnostic Medical Sonography. All Rights Reserved.

3 Steps for Performing Multicompartmental Pelvic Floor Ultrasound



Transperineal: 2D dynamic & static imaging



Endovaginal: functional anterior & posterior imaging followed by static 360 degrees 3D imaging



Endoanal: 360 degrees 3D imaging

Images adapted from: Shek KL, Dietz HP. In: Shobeiri SA, ed. *Practical Pelvic Floor Ultrasonography*. Springer; 2013:81-122. doi:10.1007/978-1-4614-8426-4

27

27

2D Transperineal Functional Imaging

- **Indications:**
  - Pelvic organ prolapse
  - Levator ani muscle function
  - Stress urinary incontinence
  - Mesh and sling placement and functionality
  - Post partum pelvic floor screening

28

28

© Copyright. Society of Diagnostic Medical Sonography. All Rights Reserved.

2D Transperineal Functional Imaging

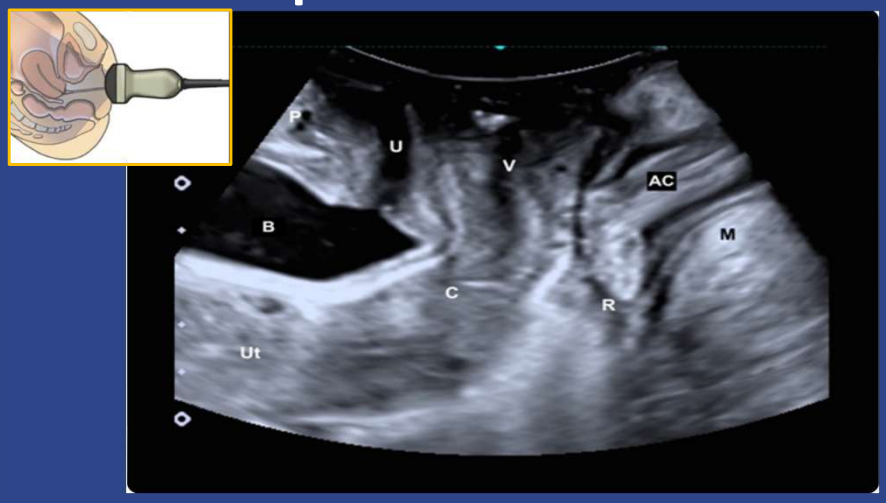

Midsagittal Plane:

- P: Pubis
- U: Urethra
- B: Bladder
- V: Vagina
- C: Cervix
- Ut: Uterus
- AC: Anal Canal
- R: Rectum
- M: Levator Ani Muscle

Image adapted from: Mejido R, Bueno B. *Visions Mag*. Canon Medical Systems; 2023. https://eu.medical.canon/visions-magazine/visions-blog/v41-uleu230089-whc-pelvic-floor/

Image adapted from: Shek KL, Dietz HP. In: Shobeiri SA, ed. *Practical Pelvic Floor Ultrasonography*. Springer; 2013:81-122. doi:10.1007/978-1-4614-8426-4

29

29

2D Endovaginal Functional Imaging

- **Indications:**
  - Pelvic organ prolapse
  - Levator ani muscle function
  - Stress urinary incontinence
  - Mesh and sling placement and functionality

30

30

© Copyright. Society of Diagnostic Medical Sonography. All Rights Reserved.

2D Endovaginal Functional Imaging

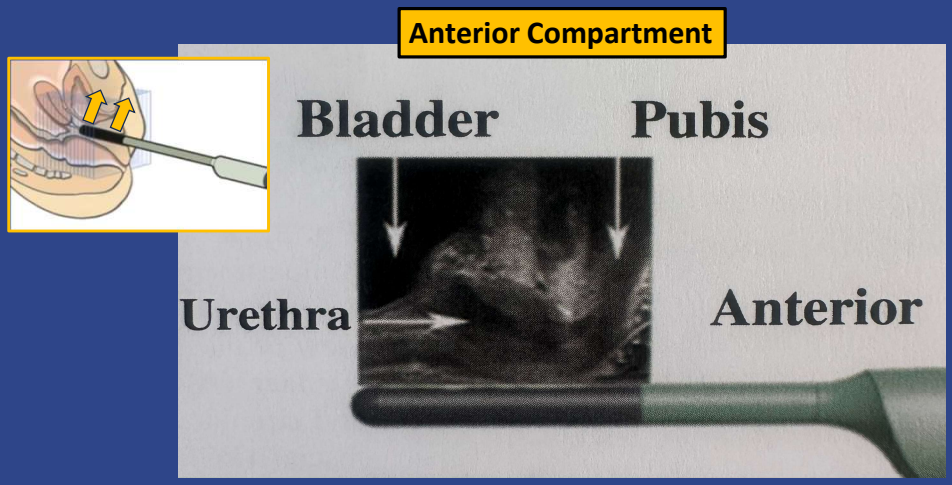

Image adapted from: Shek KL, Dietz HP. In: Shobeiri SA, ed. *Practical Pelvic Floor Ultrasonography*. Springer; 2013:81-122. doi:10.1007/978-1-4614-8426-4

31

31

2D Endovaginal Functional Imaging



Image adapted from: Shek KL, Dietz HP. In: Shobeiri SA, ed. *Practical Pelvic Floor Ultrasonography*. Springer; 2013:81-122. doi:10.1007/978-1-4614-8426-4

32

32

© Copyright. Society of Diagnostic Medical Sonography. All Rights Reserved.

3D 360 Degrees Endovaginal Imaging

- **Indications:**
  - Pelvic organ prolapse
  - Levator ani muscle avulsions and trauma
  - Mesh and sling location

33

33

3D 360 Degrees Endovaginal Imaging

- Anterior and posterior compartment assessment

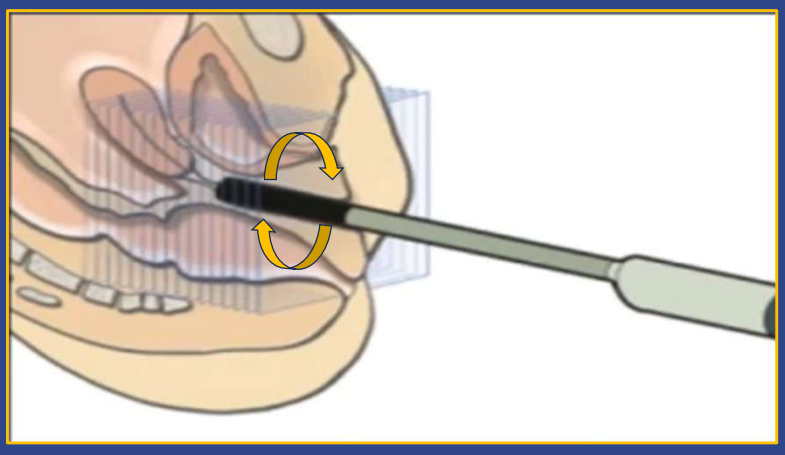

Image adapted from: Shek KL, Dietz HP. In: Shobeiri SA, ed. *Practical Pelvic Floor Ultrasonography*. Springer; 2013:81-122. doi:10.1007/978-1-4614-8426-4

34

34

© Copyright. Society of Diagnostic Medical Sonography. All Rights Reserved.

3D 360 Degrees Endoanal Imaging

- **Indications:**
  - Childbirth Injury Assessment
  - Fecal Incontinence
  - Complex posterior prolapse & rectoceles
  - Perianal fistulas & abscesses
  - Pre surgical plannin

35

35

3D 360 Degrees Endoanal Imaging

- Anterior and posterior compartment assessment

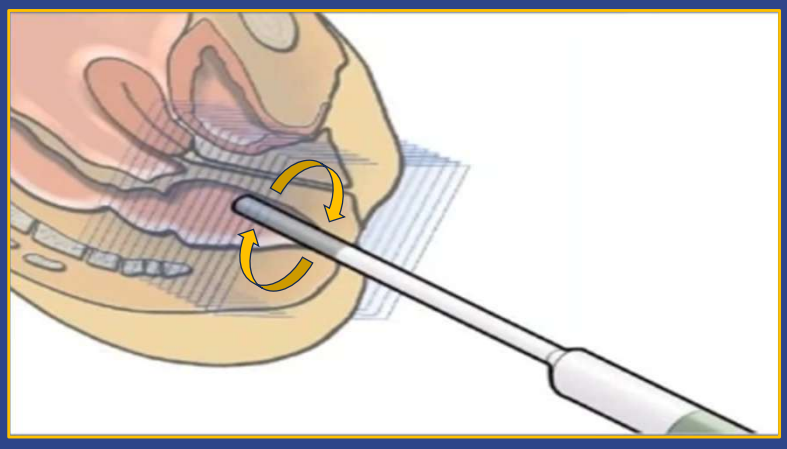

Image adapted from: Shek KL, Dietz HP. In: Shobeiri SA, ed. *Practical Pelvic Floor Ultrasonography*. Springer; 2013:81-122. doi:10.1007/978-1-4614-8426-4

36

36

© Copyright. Society of Diagnostic Medical Sonography. All Rights Reserved.

3D 360 Degrees Endoanal Imaging

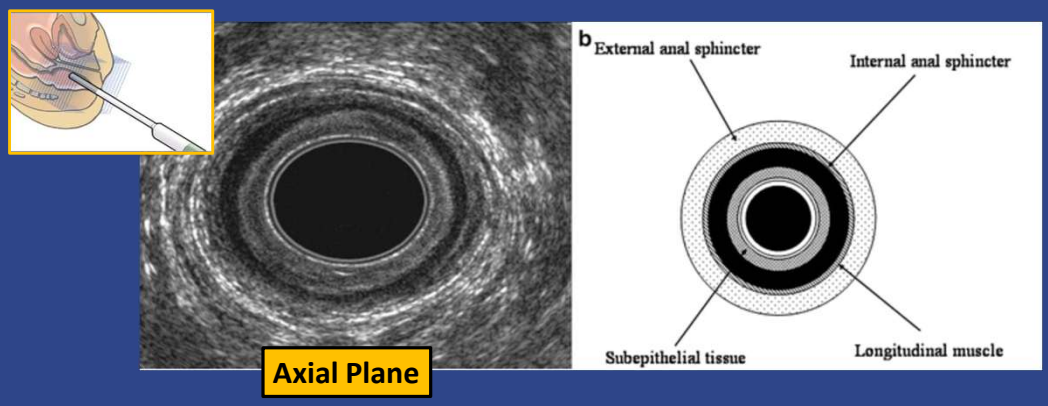

Normal Anal Canal: on ultrasound **five** hypoechoic and hyperechoic layers can be seen in the normal anal canal

Image adapted from: Santoro GA et al. In: Shobeiri SA, ed. *Practical Pelvic Floor Ultrasonography*. Springer; 2013:223-242. doi:10.1007/978-1-4614-8426-4_14

Image adapted from: Shek KL, Dietz HP. In: Shobeiri SA, ed. *Practical Pelvic Floor Ultrasonography*. Springer; 2013:81-122. doi:10.1007/978-1-4614-8426-4

37

37

3D 360 Degrees Endoanal Imaging

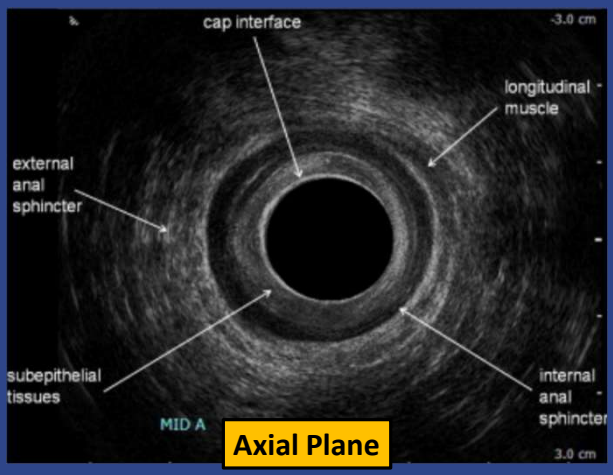

5 Layers of the Anal Canal:

1. Interface of the transducer with the anal mucosal surface
2. Subepithelial tissues
3. Internal anal sphincter (IAS)
4. Longitudinal muscle
5. External anal sphincter (EAS)

Image adapted from: Thorsen AJ, Lakin GE. *Seminars in Colon and Rectal Surgery*. 2010;21(4):186-190. doi:10.1053/j.scrs.2010.09.001

38

38

© Copyright. Society of Diagnostic Medical Sonography. All Rights Reserved.

3D 360 Degrees Endoanal Imaging

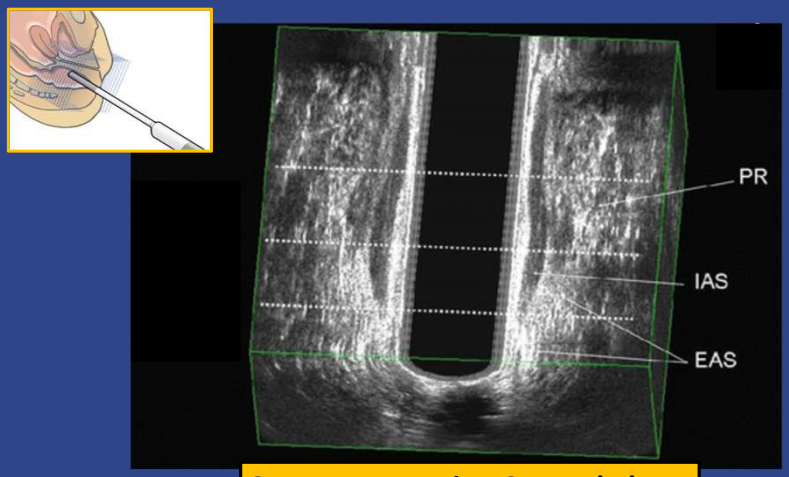

3D Reconstruction Coronal Plane

Image adapted from: Santoro GA et al. In: Shobeiri SA, ed. *Practical Pelvic Floor Ultrasonography*. Springer; 2013:223-242. doi:10.1007/978-1-4614-8426-4_14

Image adapted from: Shek KL, Dietz HP. In: Shobeiri SA, ed. *Practical Pelvic Floor Ultrasonography*. Springer; 2013:81-122. doi:10.1007/978-1-4614-8426-4

39

39

Why 3D US Over 2D US?

Volumetric Reconstruction

Allows multiplanar viewing without losing resolution

Sphincter Volume Calculation

Enables exact measurement of sphincter thickness, gap angle, and tissue volume loss

Off-line Post Processing

Allows clinicians to slice through the dataset repeatedly post-procedure

40

40

© Copyright. Society of Diagnostic Medical Sonography. All Rights Reserved.

Pelvic Floor Disorders

Storage Problems	• Anal Incontinence • Urinary Incontinence
Emptying Problems	• Obstructed Defecation • Voiding Dysfunction
Pelvic Organ Prolapse	• Vagina / Uterus • Urinary Bladder

41

41

Pelvic Floor Disorders: Anal Incontinence

- Commonly caused by vaginal trauma during child delivery
- Damage to the anal sphincters or the muscles of the pelvic floor
- OASIS: obstetric anal sphincter injuries (grade 1-4)
  - 1: vaginal epithelium
  - 2: perineal muscles
  - 3: anal sphincter (3a and 3b = most common)
  - 4: 3+ anal epithelium/mucosa torn

42

42

© Copyright. Society of Diagnostic Medical Sonography. All Rights Reserved.

Detecting OASIS With Ultrasound

- Endoanal approach is the "gold standard" for detecting anal sphincter disruption or atrophy, but transperineal has been shown to be effective as well
- 3D reconstruction helps evaluate OASIS and the thickness of the external anal sphincter (EAS) in a coronal plane

Stickelmann AL, Kennes LN, Hölscher M, et al. Obstetric anal sphincter injuries (OASIS): using transperineal ultrasound (TPUS) for detecting, visualizing and monitoring the healing process. *BMC Womens Health*. 2022;22(1):339. doi:10.1186/s12905-022-01915-7

43

43

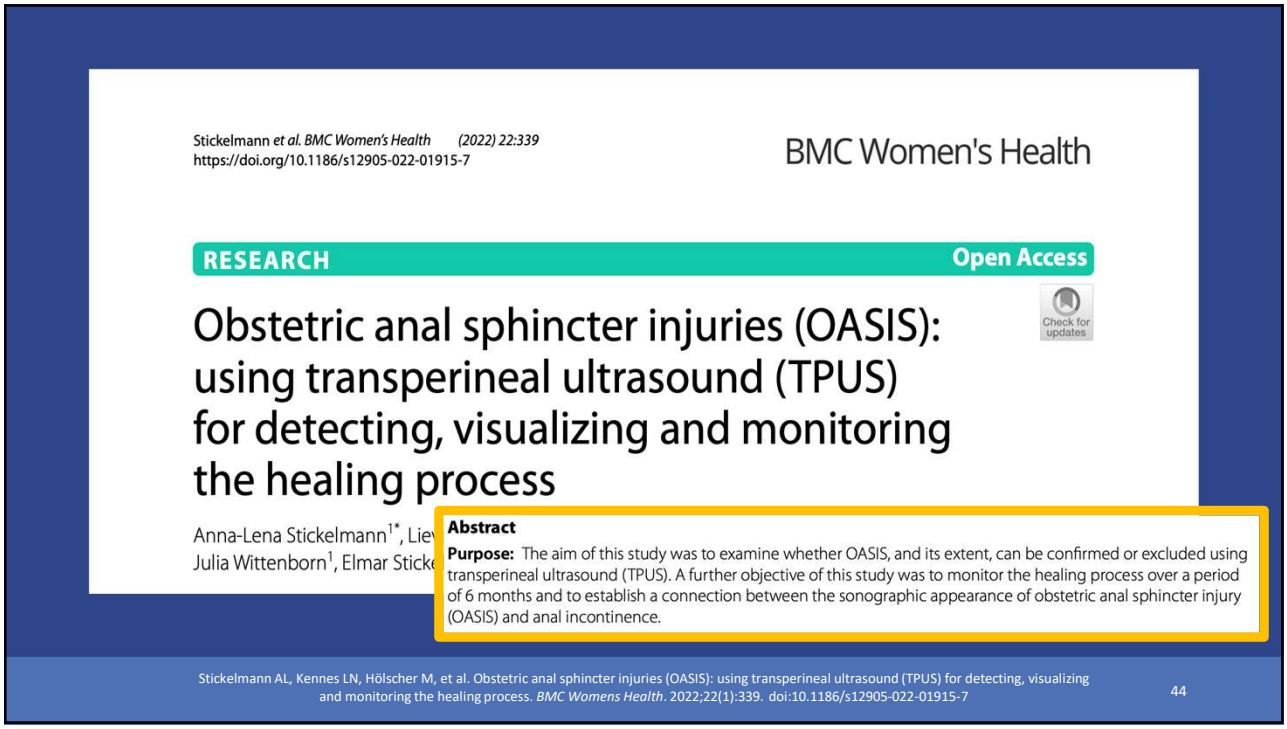

Stickelmann *et al. BMC Women's Health* (2022) 22:339
https://doi.org/10.1186/s12905-022-01915-7

BMC Women's Health

RESEARCH Open Access

Check for updates

Obstetric anal sphincter injuries (OASIS): using transperineal ultrasound (TPUS) for detecting, visualizing and monitoring the healing process

Anna-Lena Stickelmann[1*], Liev
Julia Wittenborn[1], Elmar Sticke

Abstract

Purpose: The aim of this study was to examine whether OASIS, and its extent, can be confirmed or excluded using transperineal ultrasound (TPUS). A further objective of this study was to monitor the healing process over a period of 6 months and to establish a connection between the sonographic appearance of obstetric anal sphincter injury (OASIS) and anal incontinence.

Stickelmann AL, Kennes LN, Hölscher M, et al. Obstetric anal sphincter injuries (OASIS): using transperineal ultrasound (TPUS) for detecting, visualizing and monitoring the healing process. *BMC Womens Health*. 2022;22(1):339. doi:10.1186/s12905-022-01915-7

44

44

© Copyright. Society of Diagnostic Medical Sonography. All Rights Reserved.

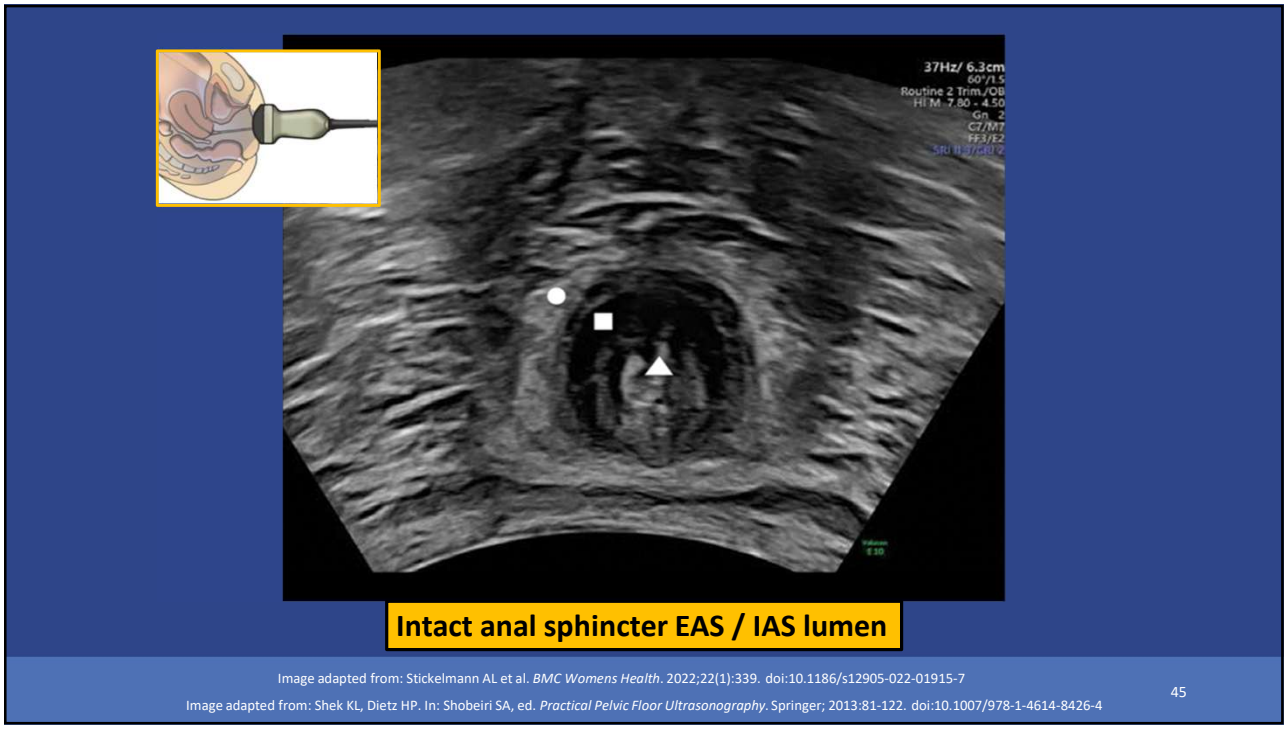

Image adapted from: Stickelmann AL et al. *BMC Womens Health*. 2022;22(1):339. doi:10.1186/s12905-022-01915-7

Image adapted from: Shek KL, Dietz HP. In: Shobeiri SA, ed. *Practical Pelvic Floor Ultrasonography*. Springer; 2013:81-122. doi:10.1007/978-1-4614-8426-4

45

45

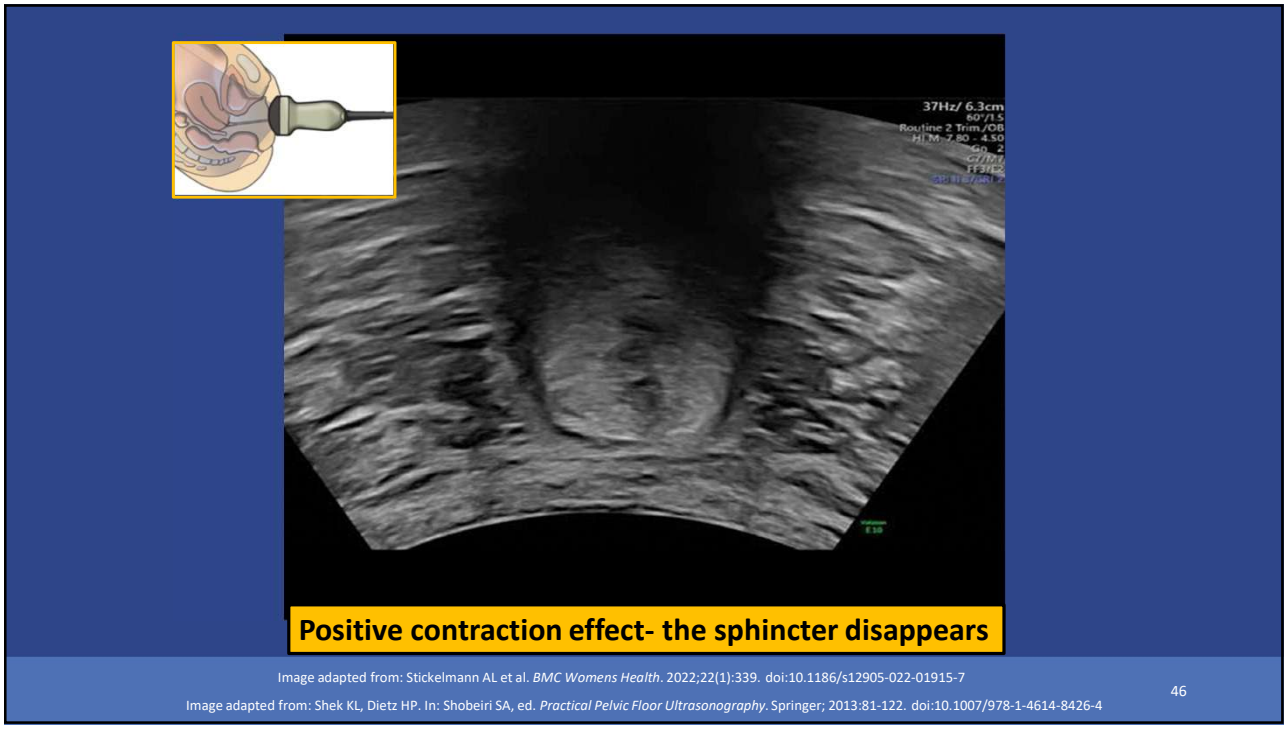

Image adapted from: Stickelmann AL et al. *BMC Womens Health*. 2022;22(1):339. doi:10.1186/s12905-022-01915-7

Image adapted from: Shek KL, Dietz HP. In: Shobeiri SA, ed. *Practical Pelvic Floor Ultrasonography*. Springer; 2013:81-122. doi:10.1007/978-1-4614-8426-4

46

46

© Copyright. Society of Diagnostic Medical Sonography. All Rights Reserved.

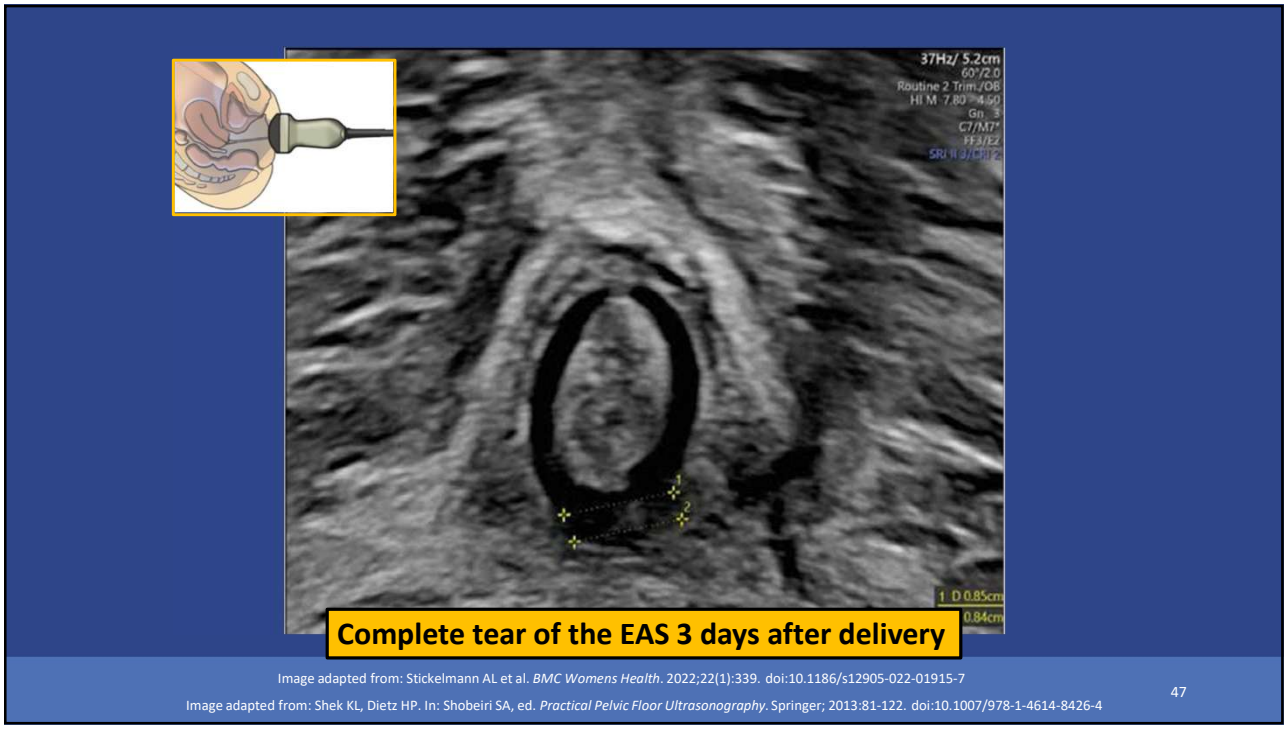

Image adapted from: Stickelmann AL et al. *BMC Womens Health*. 2022;22(1):339. doi:10.1186/s12905-022-01915-7

Image adapted from: Shek KL, Dietz HP. In: Shobeiri SA, ed. *Practical Pelvic Floor Ultrasonography*. Springer; 2013:81-122. doi:10.1007/978-1-4614-8426-4

47

47

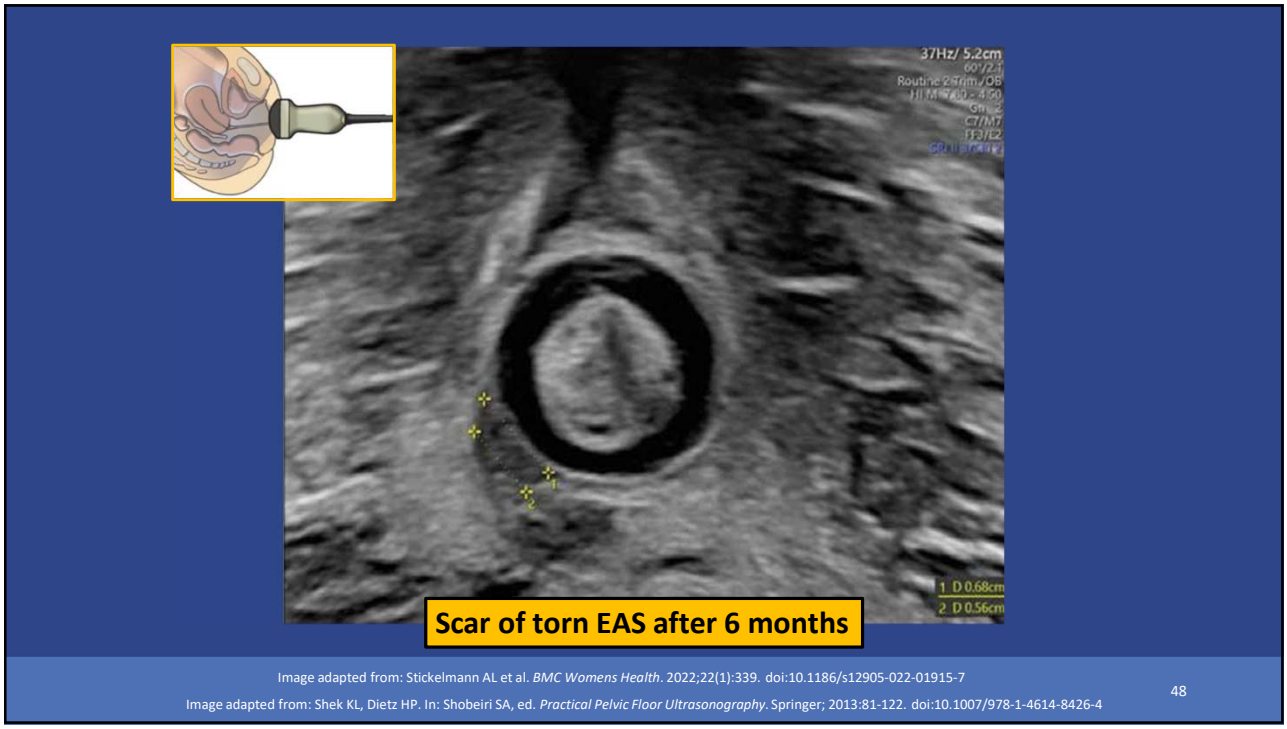

Image adapted from: Stickelmann AL et al. *BMC Womens Health*. 2022;22(1):339. doi:10.1186/s12905-022-01915-7

Image adapted from: Shek KL, Dietz HP. In: Shobeiri SA, ed. *Practical Pelvic Floor Ultrasonography*. Springer; 2013:81-122. doi:10.1007/978-1-4614-8426-4

48

48

© Copyright. Society of Diagnostic Medical Sonography. All Rights Reserved.

Results: Thirty-one of the 55 recruited patients were included in the statistical evaluation. Three patients were excluded from the statistical evaluation because OASIS was excluded on TPUS 3 days after delivery. One patient underwent revision surgery for anal incontinence and an inadequately repaired anal sphincter injury, as shown sonographic assessment, 9 days after delivery. Twenty patients were excluded for other reasons. The results suggest that a tear that appears smaller (in mm) after 3 days implies better healing after 6 months. This effect was statistically significant, with a significance level of alpha = 5% ($p = 0.0328$). Regarding anal incontinence, women who received an episiotomy had fewer anal incontinence symptoms after 6 months. The effect of episiotomy was statistically significant, with a significance level of alpha = 5% ($p = 0.0367$).

Women's Health

Open Access

Obstetric anal sphincter injuries (OASIS): using transperineal ultrasound (TPUS) for detecting, visualizing and monitoring the healing process

Anna-Lena Stickelmann[1*], Liev
Julia Wittenborn[1], Elmar Sticke

Conclusion: TPUS is an accessible, non-invasive method for detecting, quantifying, following-up and monitoring OASIS in patients with third-degree perineal tears. The width, as obtained by sonography, is important with regard to the healing of OASIS. A mediolateral episiotomy seems to prevent anal incontinence after 6 months.

Stickelmann AL, Kennes LN, Hölscher M, et al. Obstetric anal sphincter injuries (OASIS): using transperineal ultrasound (TPUS) for detecting, visualizing and monitoring the healing process. *BMC Womens Health*. 2022;22(1):339. doi:10.1186/s12905-022-01915-7 49

49

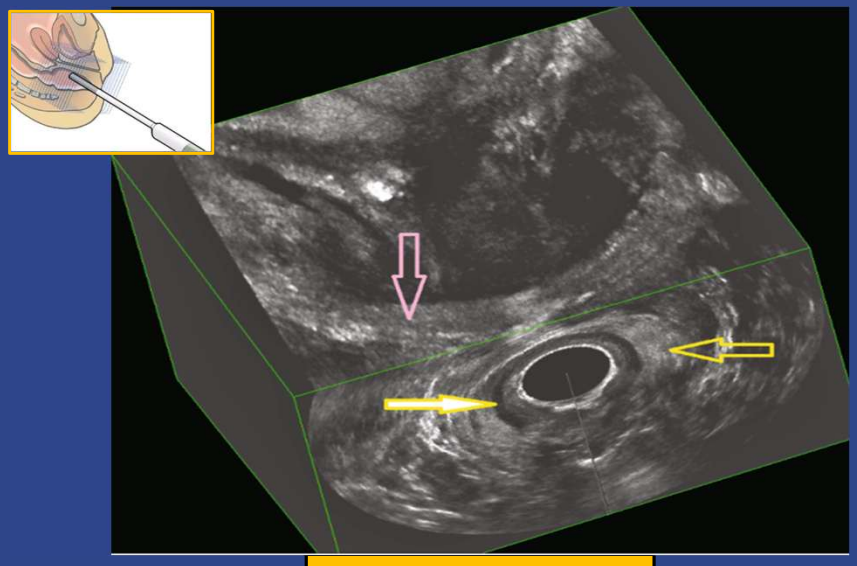

- **Yellow arrow:** EAS
- **Filled yellow arrow:** IAS
- **Pink arrow:** Puborectalis muscle

Intact sphincter complex

Image adapted from: Huber M et al. *Acta Obstet Gynecol Scand*. 2023;102(4):389-395. doi:10.1111/aogs.14514
Image adapted from: Shek KL, Dietz HP. In: Shobeiri SA, ed. *Practical Pelvic Floor Ultrasonography*. Springer; 2013:81-122. doi:10.1007/978-1-4614-8426-4 50

50

© Copyright. Society of Diagnostic Medical Sonography. All Rights Reserved.

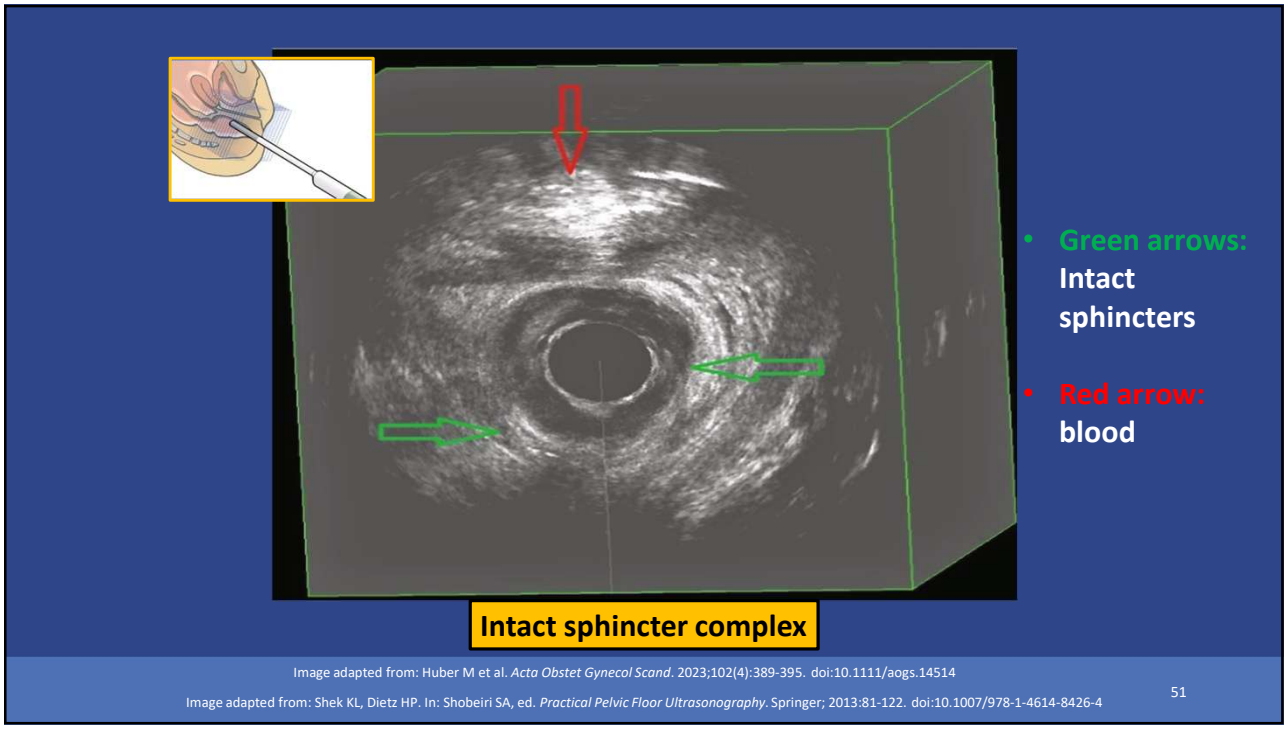

51

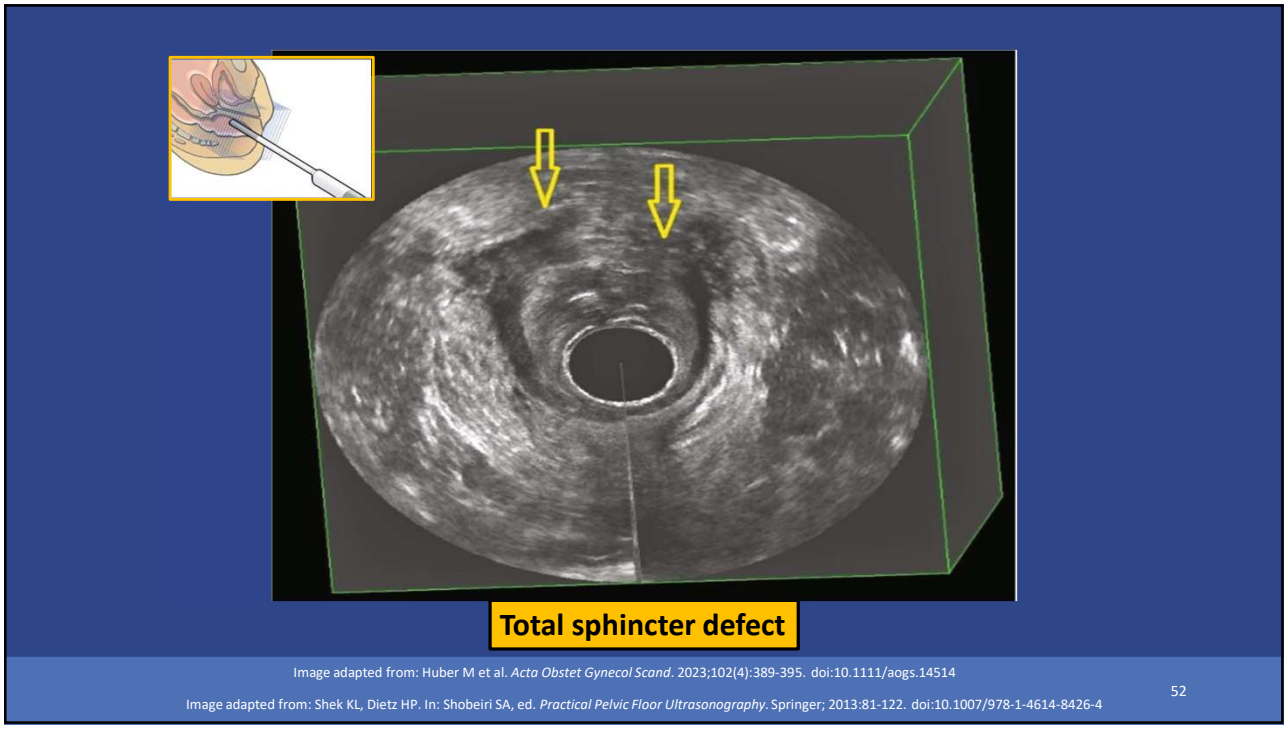

52

© Copyright. Society of Diagnostic Medical Sonography. All Rights Reserved.

Pelvic Floor Disorders: Urinary Incontinence

- Up to 77% of women suffer from urinary incontinence (UI)
- Causes:
  - Pregnancy & vaginal childbirth
  - Menopause & aging
  - Involuntary bladder spasms

Wijarnpreecha K, Scribani M, Raymond P, Harnois DM, Keaveny AP, Ahmed A, Kim D. PNPLA3 gene polymorphism and liver- and extrahepatic cancer–related mortality in the United States. *Clin Gastroenterol Hepatol*. 2021;19(5):1064-1066. doi:10.1016/j.cgh.2020.04.058

53

53

Use of Ultrasound for Urinary Incontinence

- Transperineal and endovaginal approaches can be used
- Visualization and evaluation of the mobility of the bladder neck
- Demonstration of urine leakage during provocative maneuvers
- Evaluate urethral mobility
- Visualization of meshes and slings

54

54

© Copyright. Society of Diagnostic Medical Sonography. All Rights Reserved.

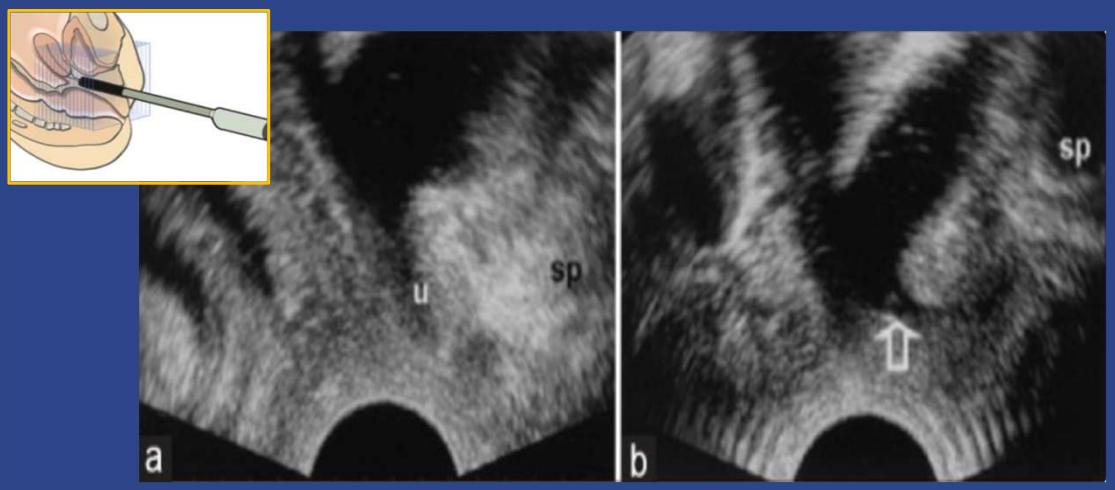

Bladder neck funneling from resting (a) to straining/Valsalva (b)

Image adapted from: Wijarnpreecha K et al. *Clin Gastroenterol Hepatol*. 2021;19(5):1064-1066. doi:10.1016/j.cgh.2020.04.058

Image adapted from: Shek KL, Dietz HP. In: Shobeiri SA, ed. *Practical Pelvic Floor Ultrasonography*. Springer; 2013:81-122. doi:10.1007/978-1-4614-8426-4

55

55

Dynamic Imaging: Sling Evaluation

- Assessment of urethral-sling mobility concordance
- Sling location at maximal Valsalva
- Deformability of the sling
  - **Successful**
    - At rest: flat or slightly curved
    - Valsalva: deforms to c-shaped
  - **Failed**
    - At rest: curved
    - Valsalva: curved
  - **Failed**
    - At rest: flat
    - Valsalva: flat

Hegde A. Part 1: Transperineal and endovaginal ultrasound imaging of slings: sling location and dynamic assessment of sling function. *IUGA Spotlight*. Published June 2020. Accessed June 15, 2026. https://www.iuga.org/spotlight-v16-2/part-1-transperineal-and-endovaginal-ultrasound-imaging-of-slings-sling-location-and-dynamic-assessment-of-sling-function

56

56

© Copyright. Society of Diagnostic Medical Sonography. All Rights Reserved.

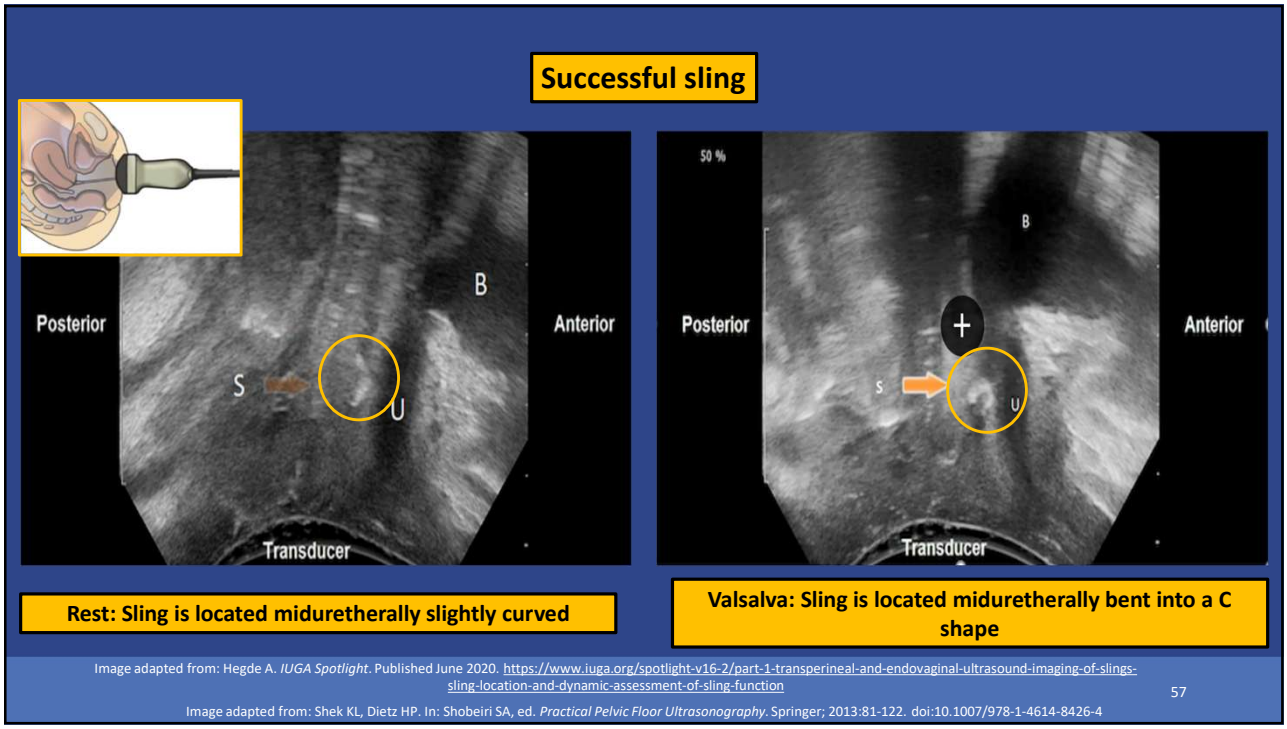

Image adapted from: Hegde A. *IUGA Spotlight*. Published June 2020. https://www.iuga.org/spotlight-v16-2/part-1-transperineal-and-endovaginal-ultrasound-imaging-of-slings-sling-location-and-dynamic-assessment-of-sling-function

Image adapted from: Shek KL, Dietz HP. In: Shobeiri SA, ed. *Practical Pelvic Floor Ultrasonography*. Springer; 2013:81-122. doi:10.1007/978-1-4614-8426-4

57

57

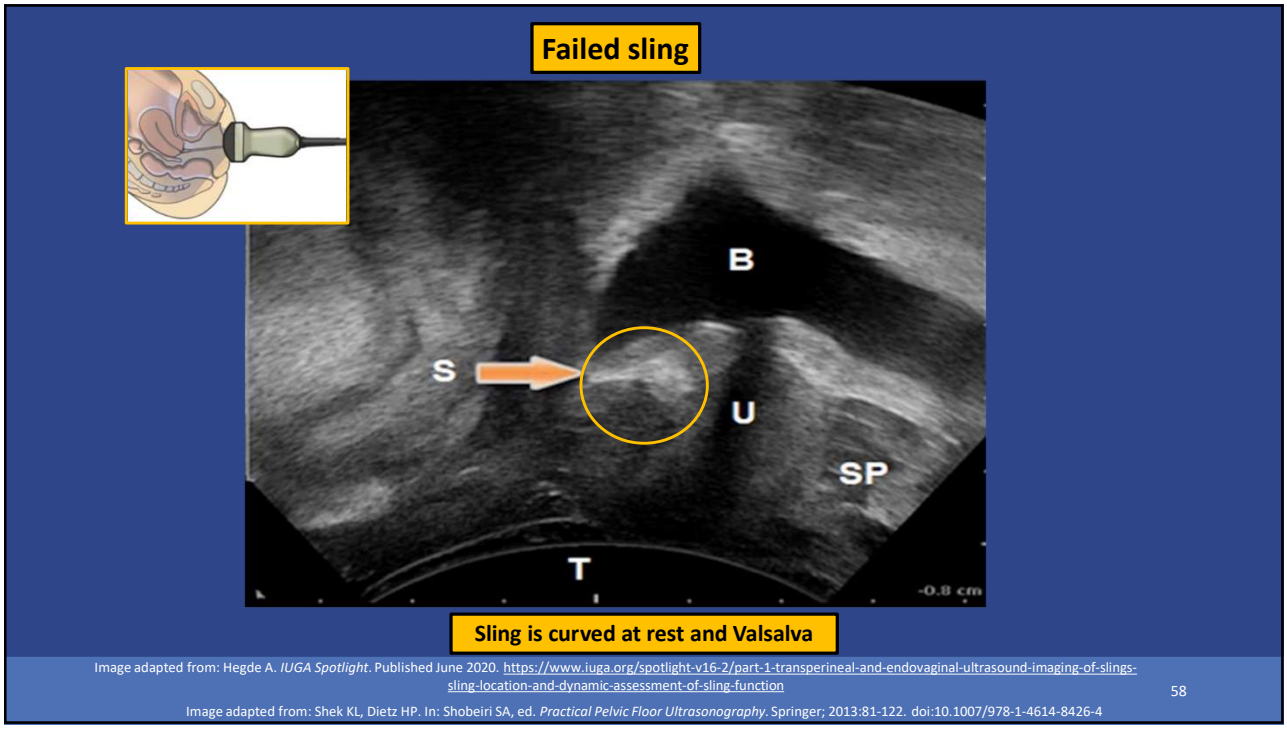

Image adapted from: Hegde A. *IUGA Spotlight*. Published June 2020. https://www.iuga.org/spotlight-v16-2/part-1-transperineal-and-endovaginal-ultrasound-imaging-of-slings-sling-location-and-dynamic-assessment-of-sling-function

Image adapted from: Shek KL, Dietz HP. In: Shobeiri SA, ed. *Practical Pelvic Floor Ultrasonography*. Springer; 2013:81-122. doi:10.1007/978-1-4614-8426-4

58

58

© Copyright. Society of Diagnostic Medical Sonography. All Rights Reserved.

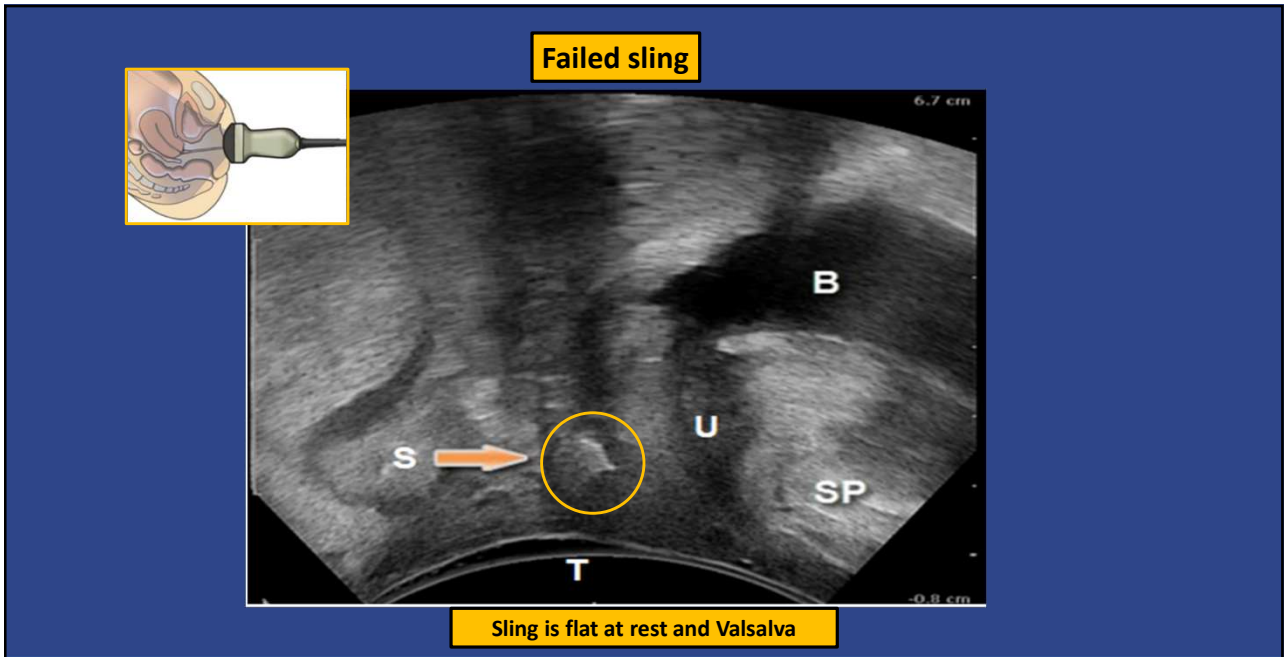

Image adapted from: Hegde A. *IUGA Spotlight*. Published June 2020. https://www.iuga.org/spotlight-v16-2/part-1-transperineal-and-endovaginal-ultrasound-imaging-of-slings-sling-location-and-dynamic-assessment-of-sling-function

Image adapted from: Shek KL, Dietz HP. In: Shobeiri SA, ed. *Practical Pelvic Floor Ultrasonography*. Springer; 2013:81-122. doi:10.1007/978-1-4614-8426-4

59

59

Pelvic Floor Disorders: Pelvic Organ Prolapse

- Occurs when the pelvic muscles weaken and are no longer able to support the uterus, bladder, and rectum causing them to protrude from the vagina
- Pelvic organ prolapse affects about 3% of American women
- Causes:
  - Vaginal childbirth
  - Menopause & aging
  - Frequent straining during bowel movements
- Typically presents later in life

60

60

© Copyright. Society of Diagnostic Medical Sonography. All Rights Reserved.

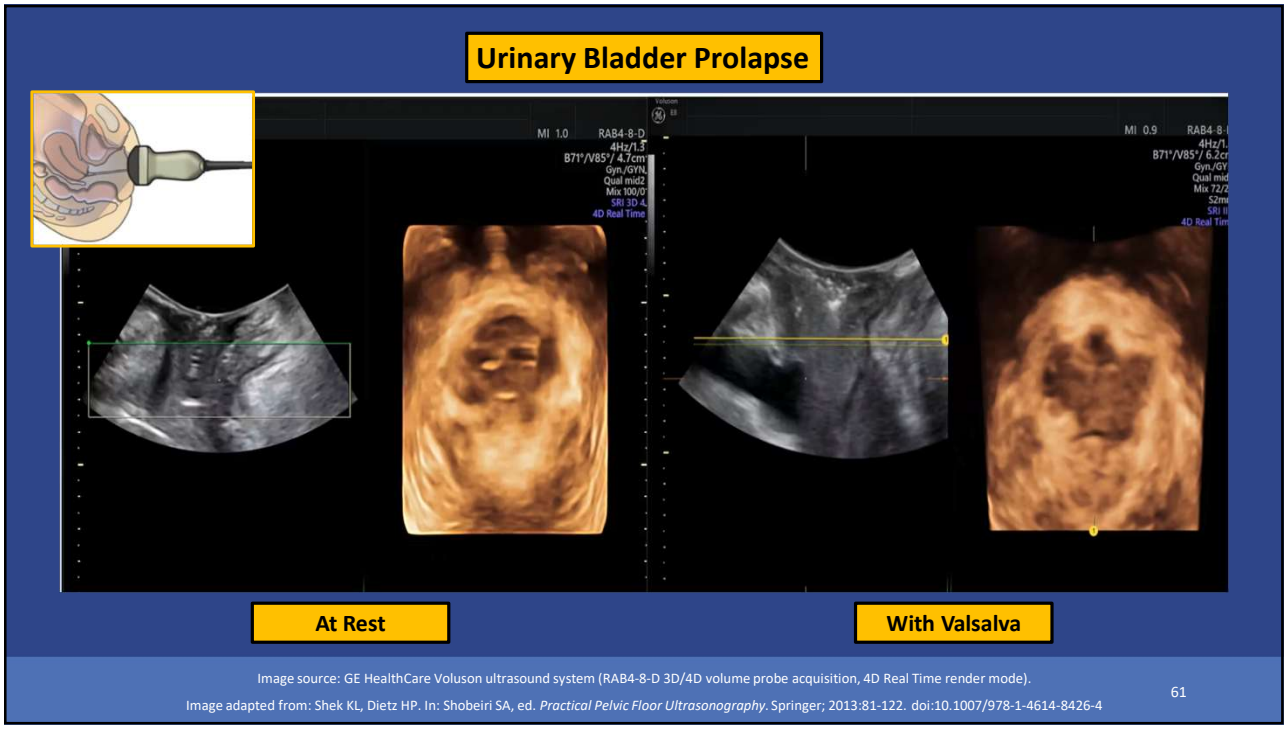

Image source: GE HealthCare Voluson ultrasound system (RAB4-8-D 3D/4D volume probe acquisition, 4D Real Time render mode).

Image adapted from: Shek KL, Dietz HP. In: Shobeiri SA, ed. *Practical Pelvic Floor Ultrasonography*. Springer; 2013:81-122. doi:10.1007/978-1-4614-8426-4

61

61

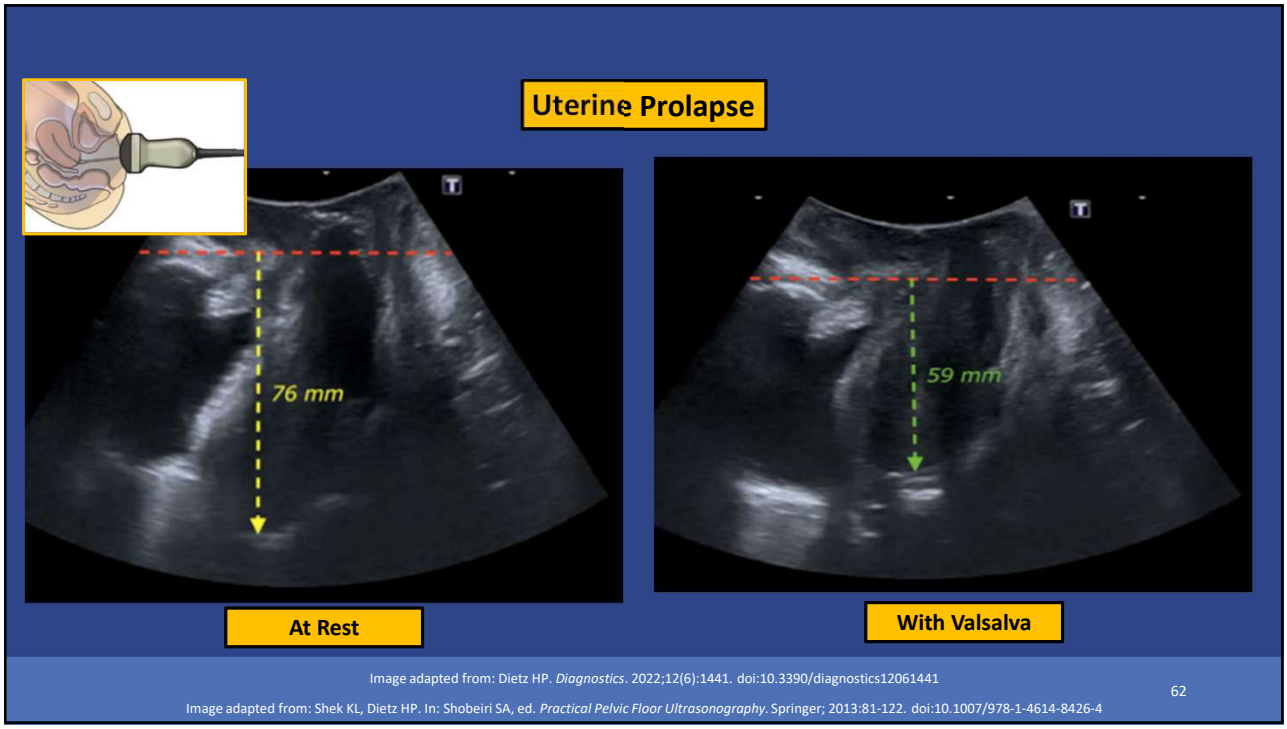

Image adapted from: Dietz HP. *Diagnostics*. 2022;12(6):1441. doi:10.3390/diagnostics12061441

Image adapted from: Shek KL, Dietz HP. In: Shobeiri SA, ed. *Practical Pelvic Floor Ultrasonography*. Springer; 2013:81-122. doi:10.1007/978-1-4614-8426-4

62

62

© Copyright. Society of Diagnostic Medical Sonography. All Rights Reserved.

Rehabilitative Ultrasound Imaging (RUSI)

- Used by Physical Therapists
- Offers real-time visual guidance to make pelvic floor retraining more intuitive and effective
- Treatment for stress urinary incontinence, pelvic girdle pain, and chronic pelvic pain
- RUSI exercises improves muscle control, reduces symptoms, and increases patient confidence
- Limitations include equipment costs, need for specialized clinician training, and lack of standardized protocols

Daniel DS, Goldenberg M, Kalichman L. Rehabilitative ultrasound imaging as visual biofeedback in pelvic floor dysfunction: a narrative review. *Tomography*. 2026;12(1):10. doi:10.3390/tomography12010010

63

63

Conclusion

- Leverage Advanced Technology: 2D/3D ultrasound capabilities make comprehensive, high-resolution pelvic floor assessments fully accessible in daily practice
- Transform Women's Health: Accurate diagnostic imaging directly enhances patient care and quality of life
- Never Stop Learning: Embrace curiosity to master emerging sonography applications and techniques

64

64

© Copyright. Society of Diagnostic Medical Sonography. All Rights Reserved.

Room Check

Join at Menti.com | use code 4297 6580

65

65

Loading...

66

© Copyright. Society of Diagnostic Medical Sonography. All Rights Reserved.

67

Thank You!

68

68

© Copyright. Society of Diagnostic Medical Sonography. All Rights Reserved.

References

1. Women, money, power: times are changing for the better. Money Coaches Canada. Published March 8, 2023. Accessed June 9, 2026. https://moneycoachescanada.ca/blog/women-money-power-times-changing-better/
2. Dietz HP. The evolution of pelvic floor ultrasound: from urinary incontinence and pelvic organ prolapse to maternal birth trauma, levator avulsion and anal sphincter tears. *Int Urogynecol J*. 2025. doi:10.1007/s00192-025-06334-4
3. Google. *Gemini* (Advanced version) [Generative AI tool]. Image generated June 10, 2026. Accessed June 10, 2026. https://gemini.google.com
4. Shobeiri SA. *Practical Pelvic Floor Ultrasonography: A Multicompartmental Approach to 2D/3D/4D Ultrasonography of Pelvic Floor*. Springer; 2013. doi:10.1007/978-1-4614-8426-4
5. Daniel DS, Goldenberg M, Kalichman L. Rehabilitative ultrasound imaging as visual biofeedback in pelvic floor dysfunction: a narrative review. *Tomography*. 2026;12(1):10. doi:10.3390/tomography12010010
6. Mejido R, Bueno B. Assessment of pelvic floor by ultrasound: a useful tool. *Visions Magazine*. Published September 25, 2023. Accessed June 9, 2026. https://eu.medical.canon/visions-magazine/visions-blog/v41-uleu230089-whc-pelvic-floor/
7. Santoro GA, Wieczorek AP, Bartram CI. Three-dimensional endoanal ultrasonography of the anorectal region. In: Shobeiri SA, ed. *Practical Pelvic Floor Ultrasonography: A Multicompartmental Approach to 2D/3D/4D Ultrasonography of Pelvic Floor*. Springer; 2013:223-242. doi:10.1007/978-1-4614-8426-4_14
8. Thorsen AJ, Lakin GE. Basic physics of ultrasonography. *Seminars in Colon and Rectal Surgery*. 2010;21(4):186-190. doi:10.1053/j.scrs.2010.09.001
9. Stickelmann AL, Kennes LN, Hölscher M, et al. Obstetric anal sphincter injuries (OASIS): using transperineal ultrasound (TPUS) for detecting, visualizing and monitoring the healing process. *BMC Womens Health*. 2022;22(1):339. doi:10.1186/s12905-022-01915-7
10. Wijarnpreecha K, Scribani M, Raymond P, Harnois DM, Keaveny AP, Ahmed A, Kim D. PNPLA3 gene polymorphism and liver- and extrahepatic cancer–related mortality in the United States. *Clin Gastroenterol Hepatol*. 2021;19(5):1064-1066. doi:10.1016/j.cgh.2020.04.058

References

12. Hegde A. Part 1: Transperineal and endovaginal ultrasound imaging of slings: sling location and dynamic assessment of sling function. *IUGA Spotlight*. Published June 2020. Accessed June 15, 2026. https://www.iuga.org/spotlight-v16-2/part-1-transperineal-and-endovaginal-ultrasound-imaging-of-slings-sling-location-and-dynamic-assessment-of-sling-function
13. GE HealthCare. *Voluson Series: 3D/4D Transperineal Pelvic Floor Ultrasonography Acquisition via RAB4-8-D Volume Probe*. GE HealthCare; 2026. https://www.gehealthcare.com
14. Dietz HP. Pelvic floor ultrasound in the diagnosis of pelvic organ prolapse. *Diagnostics*. 2022;12(6):1441. doi:10.3390/diagnostics12061441

© Copyright. Society of Diagnostic Medical Sonography. All Rights Reserved.