From Diagnosis to Delivery

The Sonographer's Role in Multidisciplinary Fetal Cardiac Care

Christina Werth, MHA, RDMS, RDCS
Echosonographer | Fetal Heart Program, CHOP

2026 SDMS ANNUAL CONFERENCE
SEPTEMBER 24–26
ATLANTA, GA

1

Learning Objectives

01 Identify sonographic findings associated with critical congenital heart disease to support early diagnosis and interventions.

02 Explain structural and functional cardiac abnormalities to understand their impact on delivery planning and neonatal management.

03 Describe the roles of multidisciplinary team members involved in fetal cardiac care to support coordinated clinical decision-making.

2

© Copyright. Society of Diagnostic Medical Sonography. All Rights Reserved.

I can't fathom a world without prenatal diagnosis.



—Dr. Jonathan Chen, Chief of the Division of Cardiothoracic Surgery
Children's Hospital of Philadelphia

3

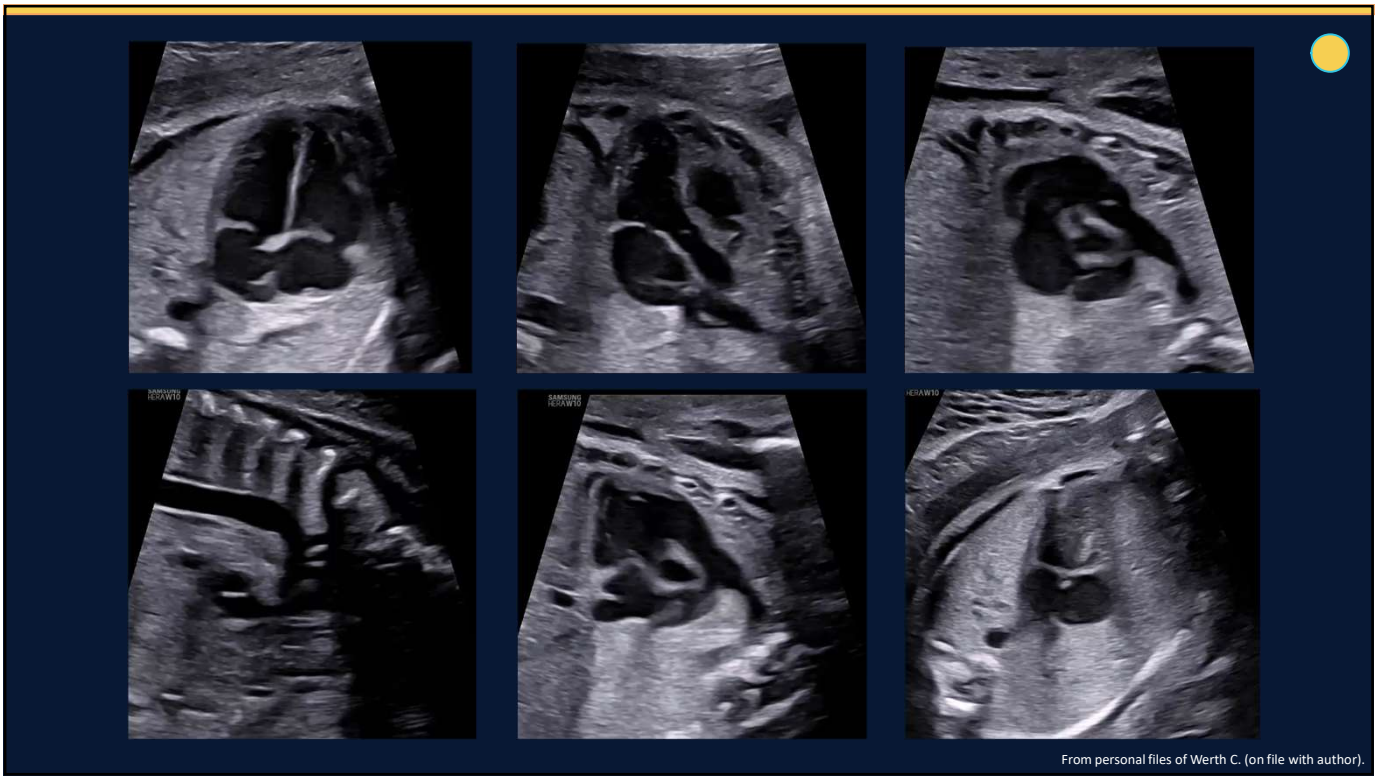

From personal files of Werth C. (on file with author).

4

© Copyright. Society of Diagnostic Medical Sonography. All Rights Reserved.



5

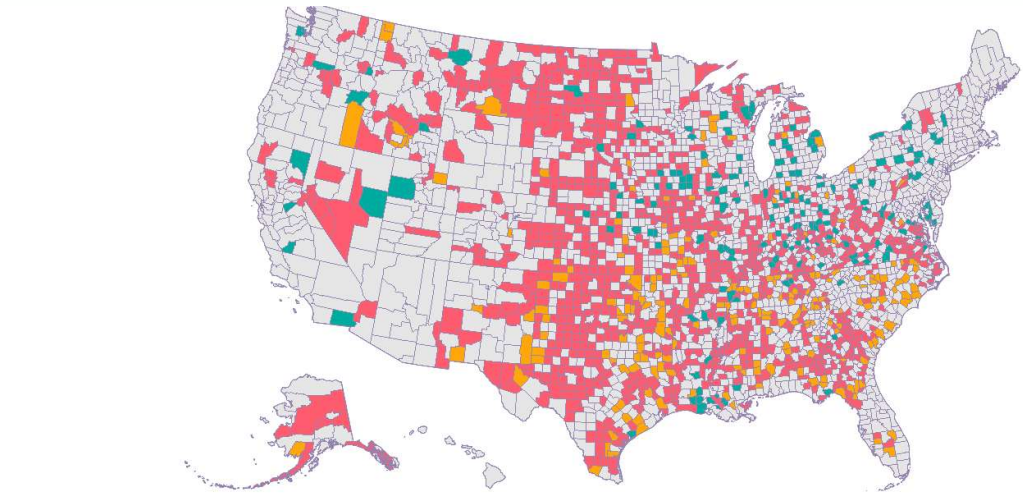

Sources: U.S. Health Resources and Services Administration (HRSA), Area Health Resources Files, 2024-2025 file; American Board of Family Medicine, 2021-2024; American Association of Birth Centers, 2024; Centers for Medicare and Medicaid Services (CMS), National Plan and Provider Enumeration System (NPPES), November 2024 file; National Center for Health Statistics, 2024 final natality data; U.S. Census Bureau, 2024 American Community Survey 5-Year Estimates; American Hospital Association, 2024; CMS Provider of Services File, 2024.

[1] March of Dimes, 2026

6

© Copyright. Society of Diagnostic Medical Sonography. All Rights Reserved.

Barriers to Care

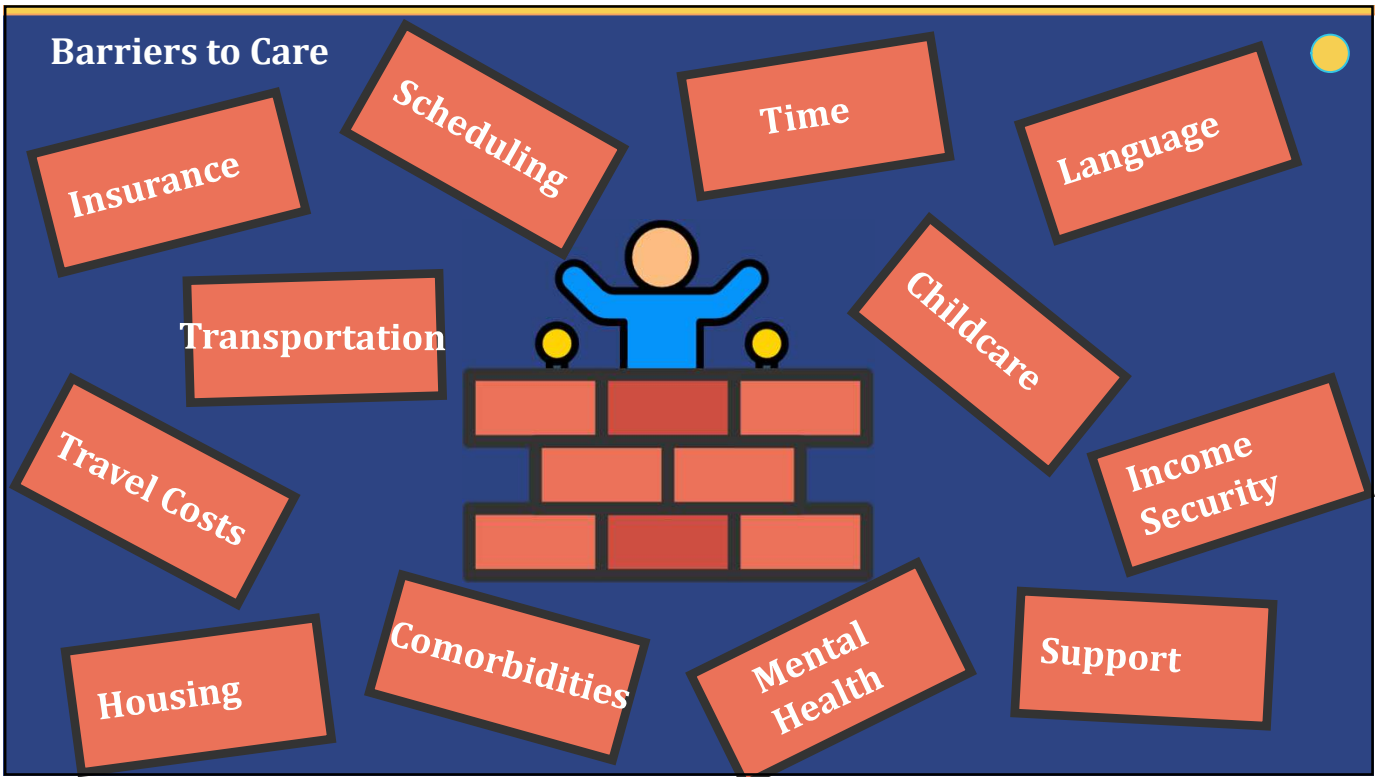

7

Crucial Conversations

Do:

- Meet patients where they are
- Display empathy, validation, & acknowledgement of their feelings
- Set expectations
- Use plain language
- Be supportive



Do Not:

- Make assumptions
- Rush explanations
- Over promise or over reassure
- Use medical jargon OR medical-professional-to-medical-professional conversational language

8

© Copyright. Society of Diagnostic Medical Sonography. All Rights Reserved.

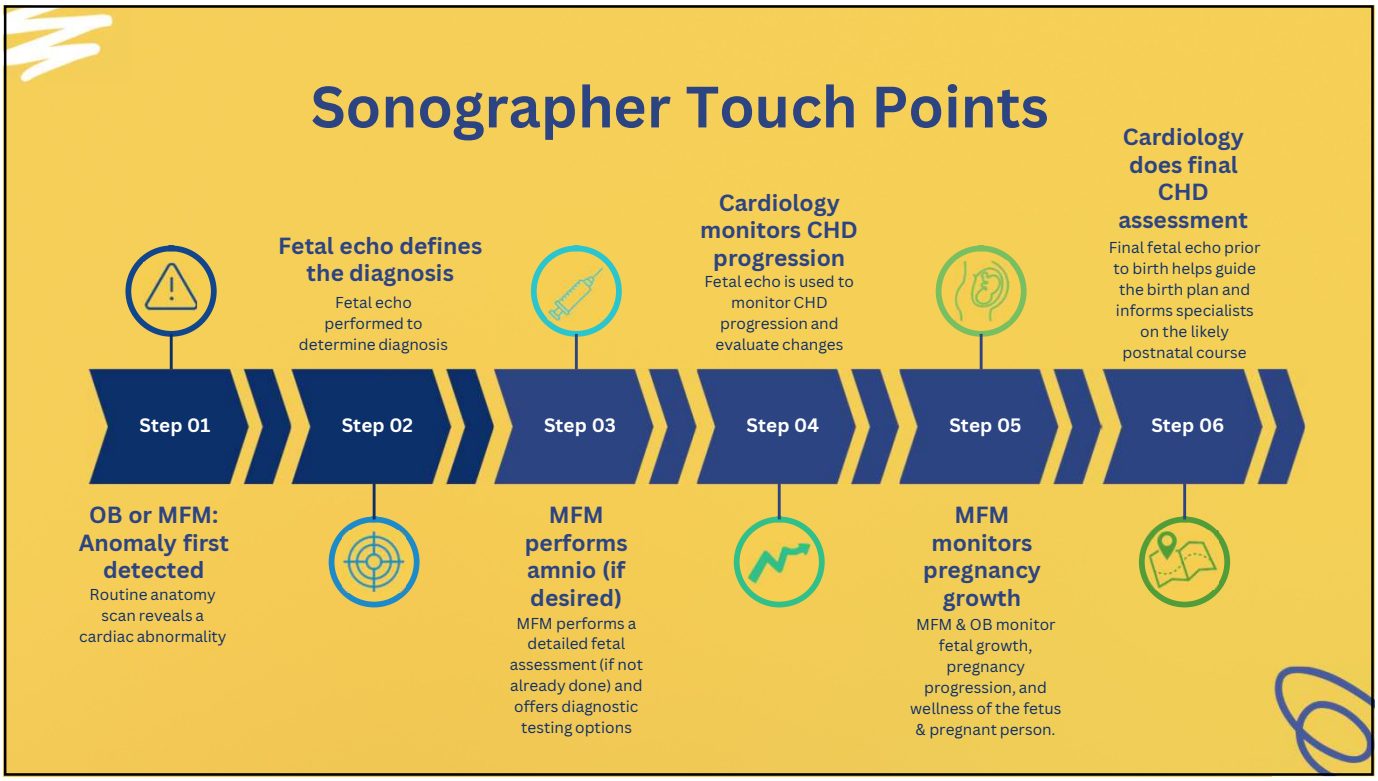

9

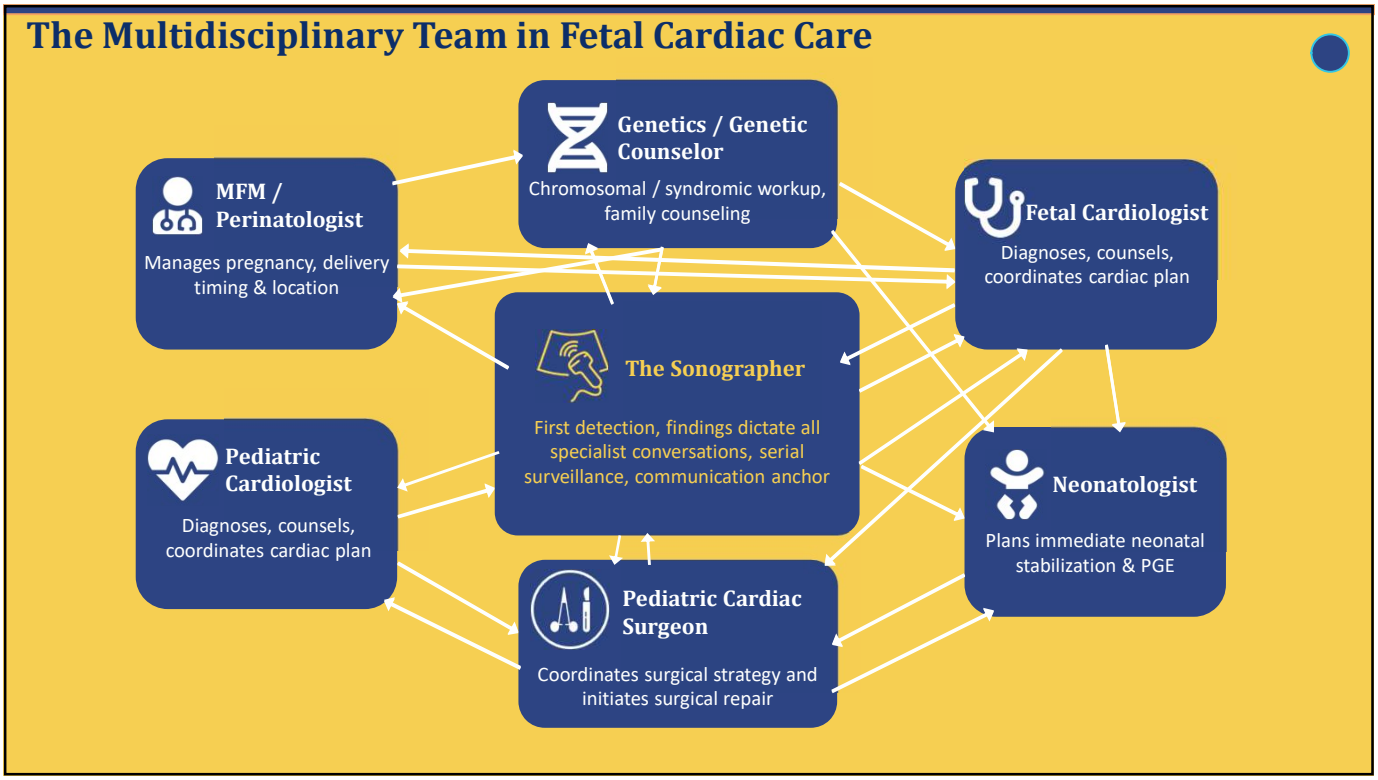

10

© Copyright. Society of Diagnostic Medical Sonography. All Rights Reserved.

Critical Cardiac Care

The Hearts and Lives Shaped by Imaging

11

CHOP Fetal Heart Program & Center for Fetal Diagnosis & Treatment

Fetal Heart Program
Fetal cardiology specialists skilled in treating the rarest and most complex CHD

you are here

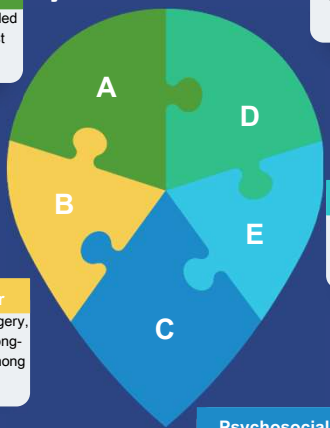

Center for Fetal Diagnosis & Treatment
Advanced pregnancy care specializing in pregnancies with fetal complications

Special Delivery Unit
World's first delivery unit for families expecting children with birth differences

CHOP Cardiac Center
World leader in ped heart surgery, interventional cardiology & long-term follow-up. Outcomes among the best in the world

Psychosocial Support
Social work, psychiatry services, child life enrichment experts, spiritual caregivers, and counselors



The Fetal Heart Program at Children's Hospital of Philadelphia (CHOP) is one of the largest and most experienced fetal heart programs in the world.

The FHP is both a standalone and specialty program within the CHOP Fetal Center for Fetal Diagnosis & Treatment & CHOP Cardiac Center

12

© Copyright. Society of Diagnostic Medical Sonography. All Rights Reserved.

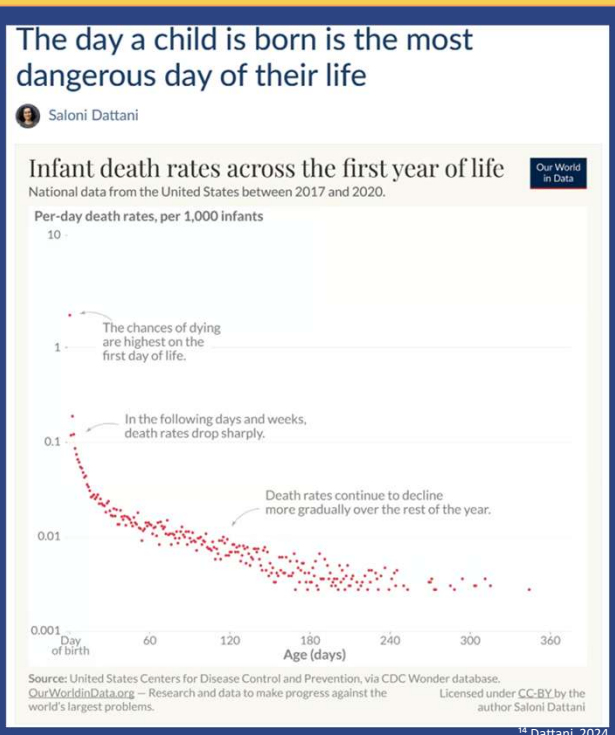

[14] Dattani, 2024

The most dangerous day of a human's life is the day that they are born

Developmental irregularities coupled with physiologic changes when leaving the womb can be cause for distress in a neonate

Some developmental differences can cause significant distress even in the perinatal period if the physiology is unable to accommodate fetal growth which can put the fetus at risk for demise

13

Delivery Classification System

CHOP Fetal Heart Program – SDU Delivery Classification System

CLASS	DEFINITION	PGE	ACCESS	MANAGES	EXAMPLES
I A	**Simple cardiovascular condition**, but **no hemodynamic instability anticipated at delivery**. Do **not** wish to have ductus arteriosus open; **no need for indwelling catheter monitoring.**	NO	P IV	Neonatology	• LV/RV size discrepancy with suspicion of possible CoA • AV Canal, balanced • TOF with mild PS ("Pink TOF") • Benign arrhythmia (non-sustained SVT, no hydrops, no ventricular dysfunction)
I B	**Simple cardiovascular condition**, but **no hemodynamic instability anticipated at delivery**. Do **not** wish to have ductus arteriosus open initially but ***do*** **wish to have indwelling catheter monitoring.**	NO	UA/UV	Neonatology	• Truncus Arteriosus (no truncal stenosis or insufficiency) • LV-RV disproportion, with intent to test ductal closure for possible CoA
II	**Cardiovascular condition of significant severity, with anticipated need for ductal patency.** Hemodynamic **stability is anticipated at delivery.**	YES	UA/UV	Neonatology	• HLHS, standard risk* • Critical aortic stenosis or CoA (ductal dependent) • TOF with significant PS/PA (ductal dependent) • Pulmonary atresia with intact ventricular septum
III A	**Cardiovascular condition of significant severity** with the **possibility or likelihood** of **hemodynamic instability at delivery**. **Ductal patency *is not* desired.**	NO	UA/UV	Neonatology + Cardiology	• TOF with Absent Pulmonary Valve Leaflet Syndrome • Sustained tachyarrhythmia (eg. SVT) • Cardiomyopathy with significant dysfunction • Truncus arteriosus with truncal stenosis/insufficiency • Ebstein's anomaly/ tricuspid valve dysplasia
III B	**Cardiovascular condition of important severity** with the **possibility or likelihood** of **hemodynamic instability at delivery**. **Ductal patency *is* desired.**	YES	UA/UV	Neonatology + Cardiology	• Transposition of the great arteries • HLHS with moderate atrial level restriction, or significant tricuspid regurgitation
IV (IMPACT)	**Cardiovascular condition where hemodynamic instability is anticipated at placental separation** (≥50% confidence). **IMmediate Post-partum Access to Cardiac Therapy (IMPACT)** with C-section delivery adjacent to cardiac procedural venue for urgent life-saving intervention.	+/-	UA/UV	Cardiac Anesthesia + Fetal Heart Program	• HLHS with highly restrictive, or intact atrial septum • Fetus with complete heart block requiring pacing • Transposition of the great arteries, intact ventricular septum and severe restriction of foramen ovale • Total anomalous pulmonary venous connection with concern for critical obstruction

Version: 4.7.2025

*Standard risk = open inter-atrial communication, no significant TR, good right ventricular function
AV, atrioventricular; CoA, coarctation of aorta; HLHS, hypoplastic left heart syndrome; LV, left ventricle; SVT, supraventricular tachycardia; TOF, tetralogy of Fallot; UA, umbilical artery; UV, umbilical vein

From personal files of Werth C. (on file with author).

14

© Copyright. Society of Diagnostic Medical Sonography. All Rights Reserved.

CASE 1

Hypoplastic Left Heart Syndrome

15

Case 1: Clinical Background

- 29yo
- G11P5055
- Declined all genetic screening/testing
- Negative medical history
- Current meds: PNV & baby asprin

- Referred for abnormal cardiac findings & suspicion of HLHS



16

© Copyright. Society of Diagnostic Medical Sonography. All Rights Reserved.

HLHS: Hallmark Features

- A **spectrum** of cardiac disease characterized by under-development of left-sided heart structures and **inadequacy of the left ventricle**
- Incidence: .1-.25 per 1000 live births, accounts for 2-4.5% of CHD[3],[4]
- 5-15% risk of chromosomal anomalies[5]
  - MYH6 gene variants
  - Turner's Syndrome
  - Noonan's syndrome
  - Trisomy
- 10-25% will have extracardiac anomalies[5]

- **Critical Defect** that will be a **ductal dependent** lesion (need PGE)[4]
- True hallmark of HLHS is reversal of PFO (left to right)

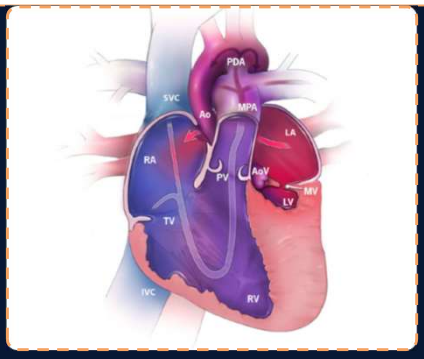

[2] CDC, 2026



Typical HLHS Appearance

From personal files of Werth C. (on file with author).

17

HLHS: Findings





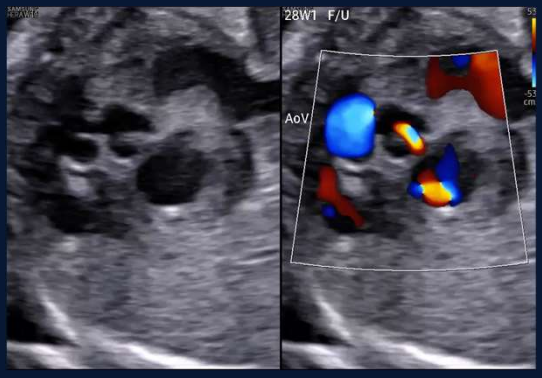

18

© Copyright. Society of Diagnostic Medical Sonography. All Rights Reserved.

HLHS: Thinking Like a Fetal Cardiac Sonographer

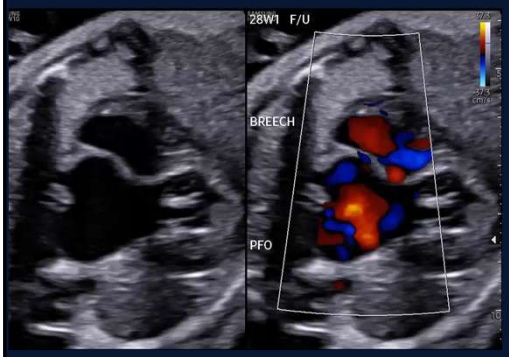

L to R PFO
~1.2m/s

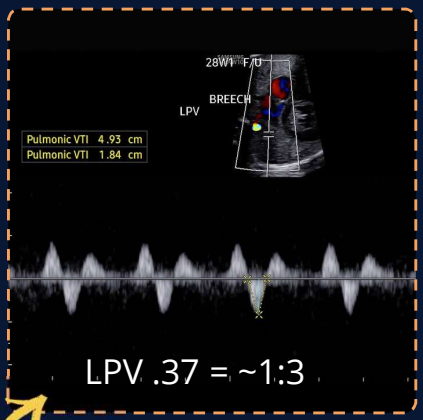

LPV .37 = ~1:3

Our Pulmonary Vein Dopplers



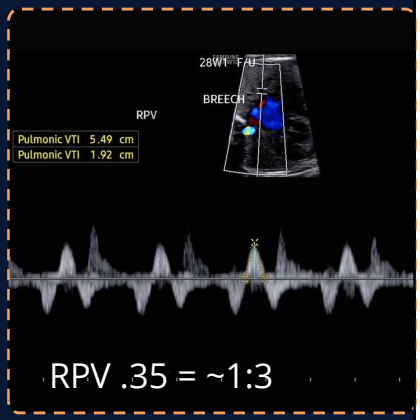

RPV .35 = ~1:3

Normal Pulmonary Vein Doppler

From personal files of Werth C. (on file with author).

19

HLHS: Palliation, Not a Cure

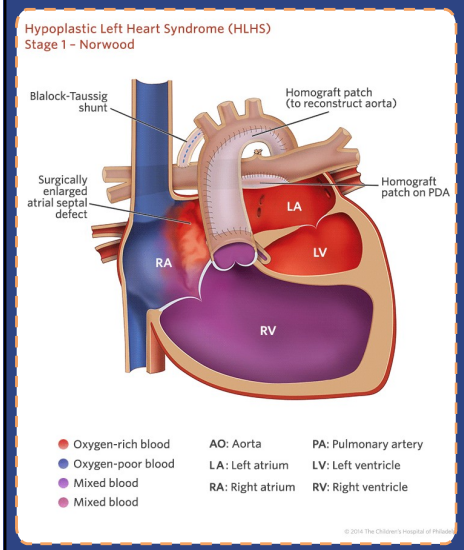

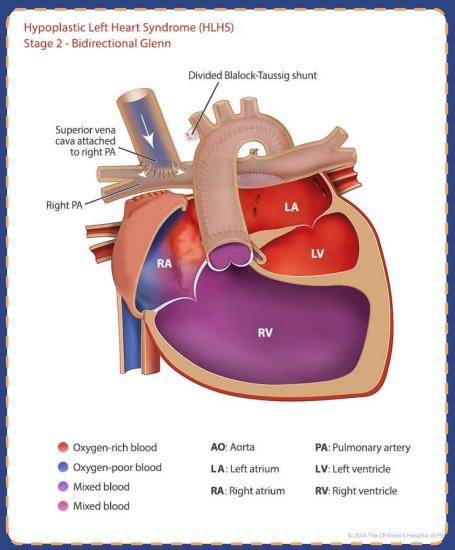

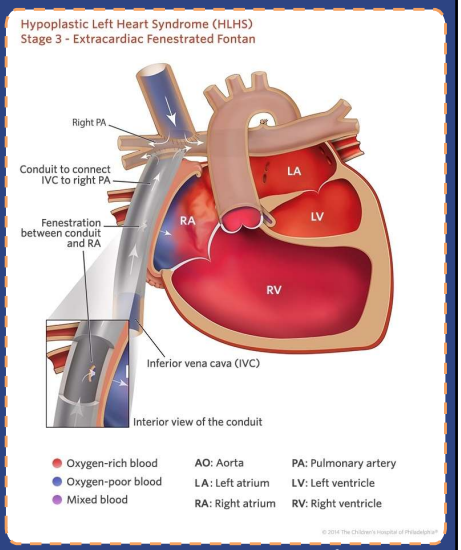

[3] Datta et al, 2023

20

© Copyright. Society of Diagnostic Medical Sonography. All Rights Reserved.

HLHS: Monitoring



From personal files of Werth C. (on file with author).

21

HLHS: Findings

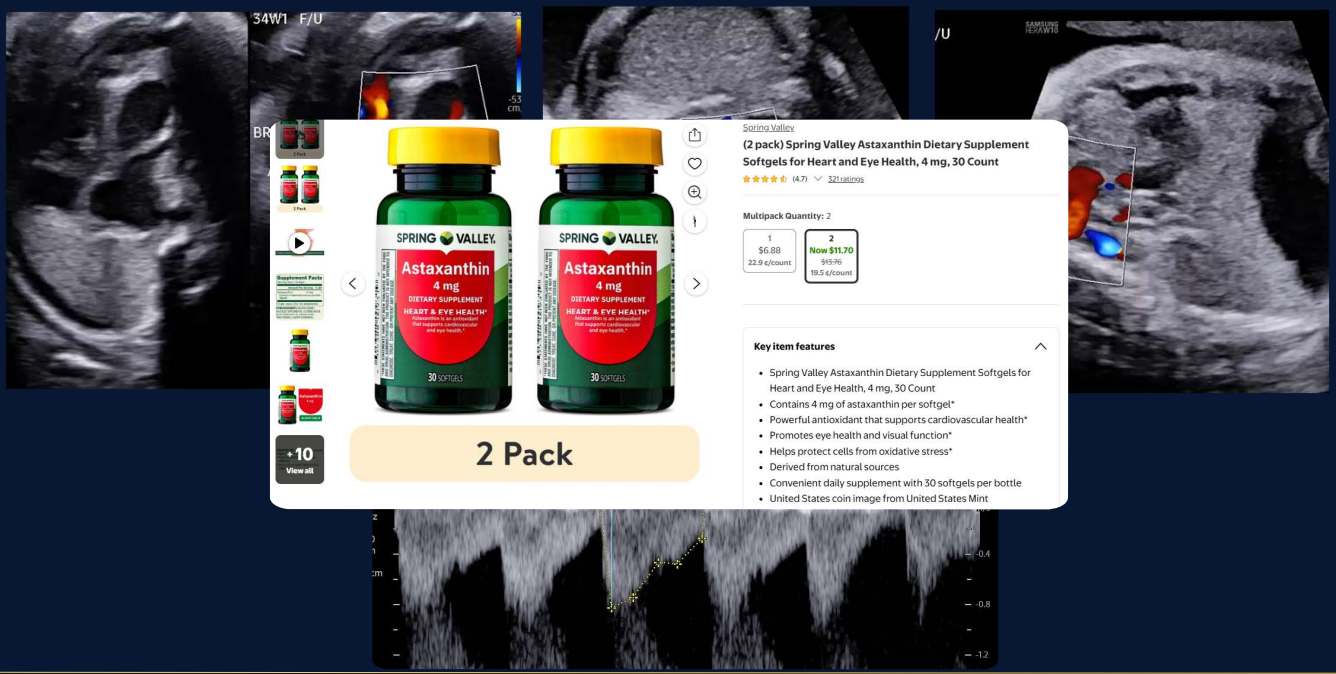

From personal files of Werth C. (on file with author).

22

© Copyright. Society of Diagnostic Medical Sonography. All Rights Reserved.

HLHS: Findings 1 week later



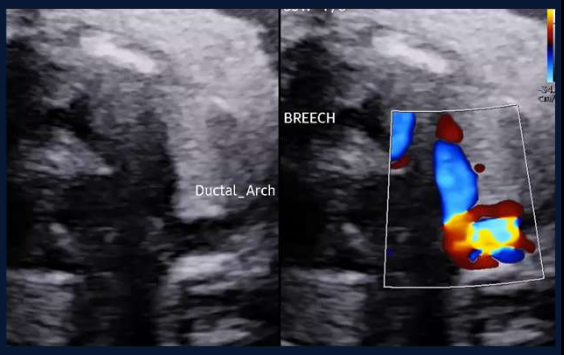

From personal files of Werth C. (on file with author).

23

Case 1 — What Makes The Imaging in this Case Critical?

Detection, Diagnosis, and Monitoring

MFM:
- Evaluates for additional structural differences, growth, pregnancy complications, co-manages pregnancy

Genetics:
- Offers diagnostic testing (amniocentesis), and paints a picture of life with a genetic difference, findings may determine candidacy for cardiac surgery

Fetal Cardiologist:
- provides cardiac dx and prognosis, monitors for changes, makes plan for **IMPACT delivery**
  - Decided due to in-tact atrial septum

Cath Lab:
- Readies for immediate intervention

Cardiac Surgery:
- Establishes early relationship with family, plans palliation

Social Work, Spiritual Care, Psych:
- Navigates the psychosocial impacts and supports family

Guiding Delivery Plan to Optimize Outcomes

- Delivery: 36-37 weeks, planned SDU IMPACT delivery
- Delivery room team: neonatology + cardiology at bedside; cardiac cath lab set up adjacent for BAS
  - Balloon atrial septostomy
    - Immediate postnatal intervention to open the atrial septum
    - Decompresses PVs, allows for better mixing of oxygenated and deoxygenated blood in single ventricle anatomy
- Neonatalogist:
  - PGE_1 started at birth
    - Prostaglandin keeps duct open → systemic perfusion maintained
- Surgery:
  - Norwood Stage I palliation: day 3–5 of life
  - Subsequent: Glenn (4–6 months), Fontan (~3 years)
- Outcome: single-ventricle palliation, life-long follow-up and monitoring of complications

24

© Copyright. Society of Diagnostic Medical Sonography. All Rights Reserved.

CASE 2

Complete AV Canal Defect

25

Case 2: Clinical Background

- 27yo
- G1P0
- 14w4d
- Negative medical/family history
- Abnormal cfDNA result - high risk for T21

- Referred for Early Fetal Cardiac Imaging (EFCI)



26

© Copyright. Society of Diagnostic Medical Sonography. All Rights Reserved.

AV Canal: EFCI



From personal files of Werth C. (on file with author).

27

AV Canal Defect: Hallmark Features

- Defect resulting from the failure of the AV valve tissue to separate into two distinct valves, the mitral and tricuspid
  - Results in one single AV valve and a defect in the atrial septum (atrial primum ASD) and ventricular septum (inlet VSD)
- Central cardiac defect involving atrial septum, ventricular septum, AV valves, abnormal course of conducting system

Incidence:

- accounts for 15-20% of fetal CHD and 4-5% of postnatal CHD[7]

Associations:

- Chromosomal anomaly in 50% of isolated AV Canal Defects[7]
  - **T21 common** - Recommend amniocentesis
- Common in heterotaxy[7] cases (often in conjunction with additional cardiac defects)

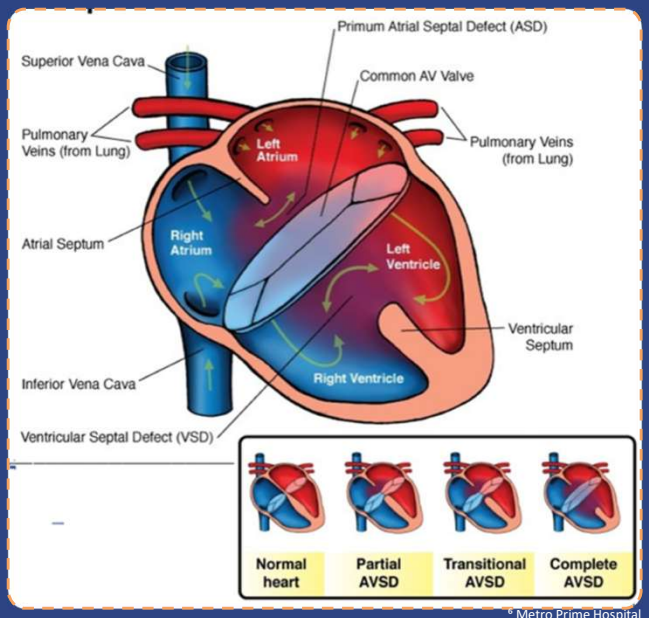

[6] Metro Prime Hospital

28

© Copyright. Society of Diagnostic Medical Sonography. All Rights Reserved.

AV Canal: Hallmark Views



From personal files of Werth C. (on file with author).

29

Thinking Like a Fetal Cardiac Sonographer

Optimizing EFCI:

- Highest frequency probe possible (3-10 Mhz)
  - Consider transvaginal ⟶ less useful with newer wide bandwidth probes on market
- Narrow sector
- Increase frame rate
- Zoom
- Lower persistence (image smoothing)

Monitoring AV Canal Defects:

- Key question: is the defect balanced or unbalanced?
- Key question: What is the degree of AV valve regurg?



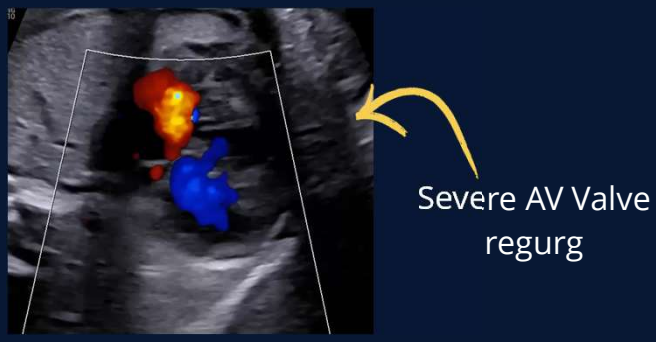

From personal files of Werth C. (on file with author).

30

© Copyright. Society of Diagnostic Medical Sonography. All Rights Reserved.

Case 2 — What Makes The Imaging in this Case Critical?

Genetics, Counseling, & Providing Options

MFM:
- Evaluates for additional structural differences, growth, pregnancy complications

Genetics:
- Offers diagnostic testing (amniocentesis), and paints a picture of life with a genetic difference

Fetal Cardiologist:
- provids cardiac dx and prognosis, monitors for changes

TIME:
- EFCI gives families **TIME** to consider their options and provides more options

Monitoring, Planning, & Building a Care Team

Fetal Monitoring:
- Serial fetal echo to watch for AV valve regurg
- MFM to monitor pregnancy growth & health

Delivery planning:
- Delivery at hospital with cardiology consult service (not necessarily cardiac surgery center)
- Close monitoring for pulmonary overcirculation as PVR drops in first weeks

Neonatal management:
- Postnatal echo; cardiac surgery team consultation begins
- Pulmonary hypertension of newborn monitored
- Surgical repair planned at 2–6 months

Care team assembled:
- Multidisciplinary specialists involved (cardiology, pulmonology, developmental ped)

31

CASE 3

Complete Heart Block

32

© Copyright. Society of Diagnostic Medical Sonography. All Rights Reserved.

Case 3: Clinical Background

- 36yo
- G6P3023
- low risk noninvasive genetic screening
- Medical history significant for vague autoimmune symptoms and incomplete followup after initial diagnosis in college (age 19)
  - positive SSA and SSB antibodies at that time
  - Diagnosed with Sjogren's syndrome
  - Asymptomatic since
- 3 prior children had relatively uncomplicated pregnancies, though youngest daughter developed a facial rash shortly after birth concerning for neonatal lupus
- Current meds: PNV & baby asprin

- Patient presents for 2nd opinion for bradycardia and complete heart block



33

CHB: Hallmark Features

Complete heart block: a life-threatening arrhythmia associated with significant fetal and neonatal mortality[8]

- complete heart block indicates a complete dissociation between atrial and ventricular beats
- Can cause low cardiac output and hydrops

Prognosis: CHB is associated with **IUFD in 5-20%** of cases. Postnatally can be treated with a pacemaker and individuals can live a normal life.[9]

Associations[9]:

- Structural CHD (heterotaxy, cc-TGA)
- Maternal autoimmune disorder
  - Lupus
  - Sjogren's

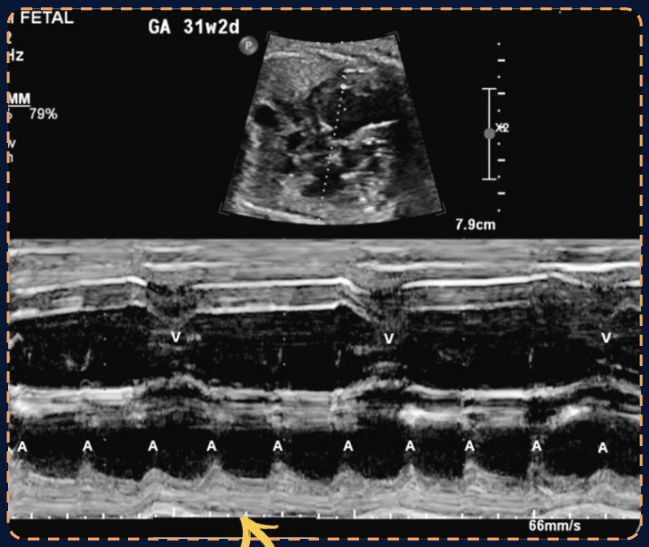

[8] Abdul Ghayum et al, 2025

M-Mode is our best tool!

34

© Copyright. Society of Diagnostic Medical Sonography. All Rights Reserved.

Case 3 — CHB



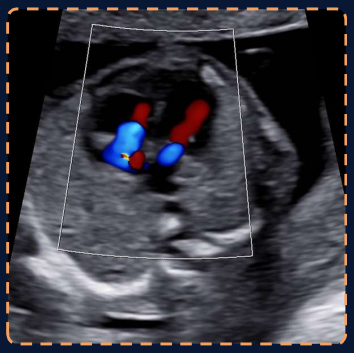

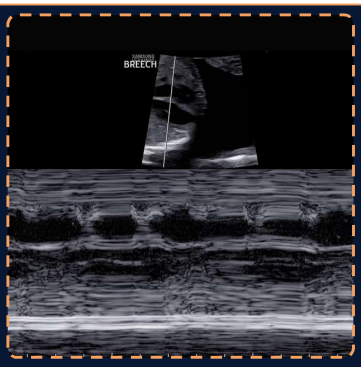

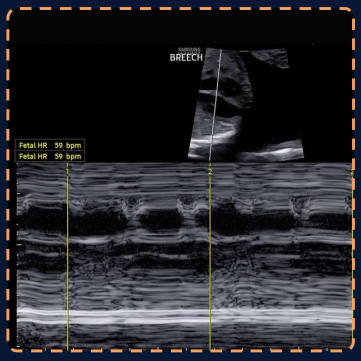

From personal files of Werth C. (on file with author).

35







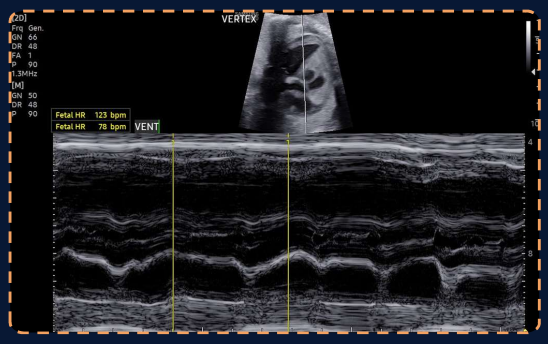

MCOT Monitor



From personal files of Werth C. (on file with author).

[10] First-Call Medical

36

© Copyright. Society of Diagnostic Medical Sonography. All Rights Reserved.

Case 3— What Makes The Imaging in this Case Critical?

Optimization in Utero

MFM:
- Evaluates for growth, maternal complications, hydrops watch
- Oversees administration of theraputic agents and care coordination
- May recommend delivery dependent on declining fetal or maternal wellness

Fetal Cardiologist:
- Provids cardiac dx and prognosis, monitors for evolution and worsening or improving rates
- Recommends theraputic agents and dosing based on serial FEs
  - Commonly dexamethasone, IV immunoglobulin (IG), terbutaline[9]
- May recommend delivery dependent on cardiac function and/or worsening hydrops

Rheumatologist:
- Manages & optimizes underlying autoimmune condition (if present)
- Manages med regimen such as Plaquenil

Mobilization After Birth

Delivery planning:
- IMPACT delivery needed if pacemaker expected to be required at birth
- EP and cath lab or OR mobilized to recieve neonate

CICU Team:
- Ready to recieve infant after pacing or for close monitoring if immediate pacing is not indicated

Peds Cardiology & Electrophysiology:
- Before pacing: continues to monitor heart condition, wellness of child, and for timing of pacing
- After pacing: monitors health of the child, heart condition, and effectiveness of pacemaker, coordinates when replacements are needed

37

CASE 4

Pulmonary Atresia with Intact Ventricular Septum



38

© Copyright. Society of Diagnostic Medical Sonography. All Rights Reserved.

Case 1: Clinical Background

- 38yo
- G9P2062
- Hx of RPL
  - Two with confirmed genetic differences- Triple X, abnormality of chromosome 16
- IVF pregnancy with pre-implantation genetic testing
- Current meds: PNV & baby asprin

- Referred for abnormal cardiac views



39

Case 4 — PA IVS





From personal files of Werth C. (on file with author).

40

© Copyright. Society of Diagnostic Medical Sonography. All Rights Reserved.

Case 4 — PA IVS: Hallmark Views

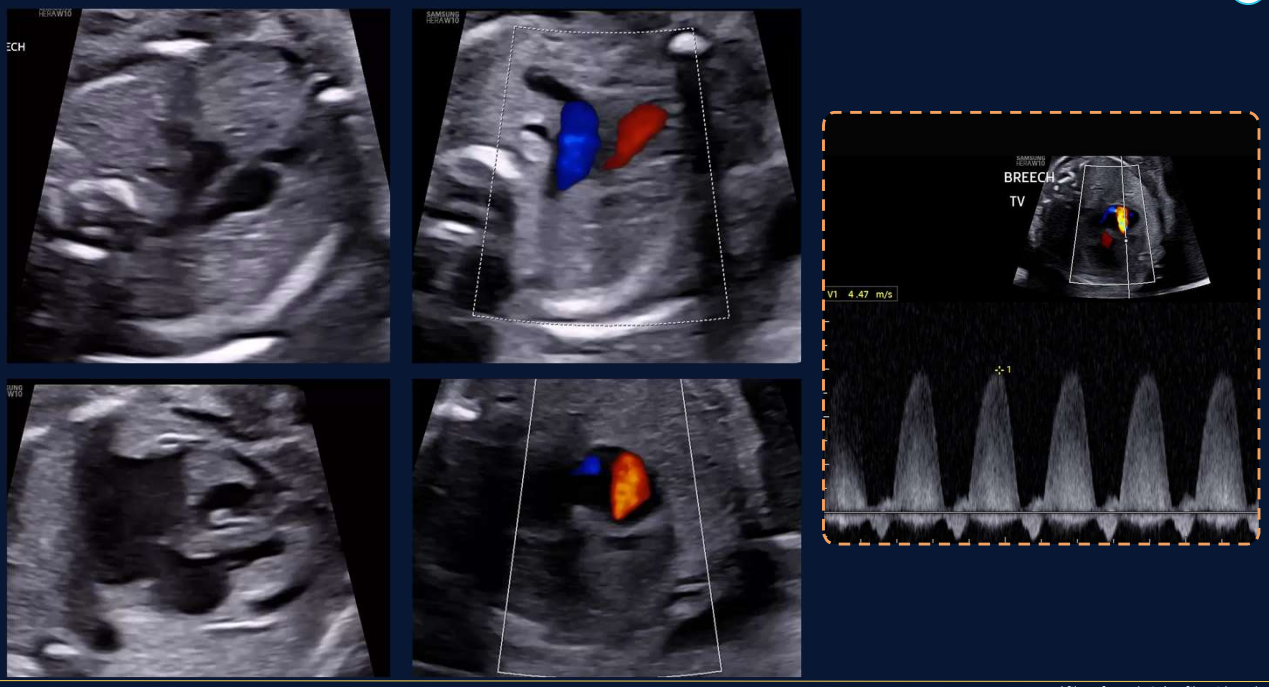

From personal files of Werth C. (on file with author).

41

Pulmonary Atresia with Intact Ventricular Septum

PA-IVS: CHD characterized by a lack of ventricular outflow from the right ventricle[12]

- Usually due to fusion of the pulmonic valve leaflets
- Tricuspid valve and right ventricle can also be underdeveloped

Prognosis: Varies dependent on function and size of the tricuspid valve (biventricular vs single ventricle repair)[12]

Associations[12]:

- Additional structural anomalies in >10% of cases
- Rarely associated with genetic abnormality

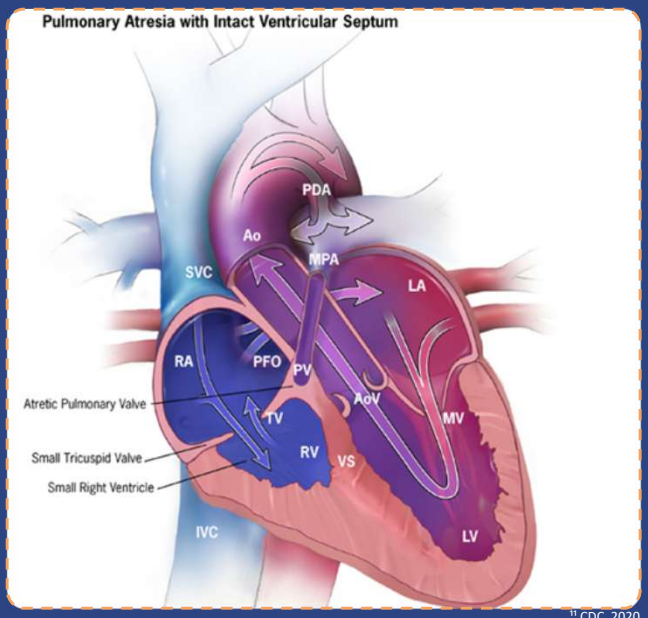

[11] CDC, 2020

42

© Copyright. Society of Diagnostic Medical Sonography. All Rights Reserved.

Case 4 — What Makes The Imaging in this Case Critical?

Detection, Diagnosis, and Monitoring

Fetal cardiologist:
- Defines anatomy, leads counseling
- Monitors for tricuspid valve growth and function which can predict single or biventricular repair status
- Alerts team to need for PGE_1 infusion at birth

MFM:
- co-manages pregnancy; coordinates delivery timing

Optimizing the Neonatal Course

Neonatalogist
- Starts PGE_1 at birth
  - Prostaglandin keeps duct open → maintains pulmonic perfusion

CICU
- Receives, monitors, and treats infant pre and post surgical repair

Pediatric Cardiac Surgeon
- Plans, counsels, and iniates proper surgical palliation

43

CASE 5

Pericardial Teratoma



44

© Copyright. Society of Diagnostic Medical Sonography. All Rights Reserved.

Case 5: Clinical Background

- Presents for evaluation and consideration for fetal surgery in setting of pericardial teratoma at 25w3d



45





From personal files of Werth C. (on file with author).

46

© Copyright. Society of Diagnostic Medical Sonography. All Rights Reserved.

Case 5— What Makes This Case Critical? Arley's Story

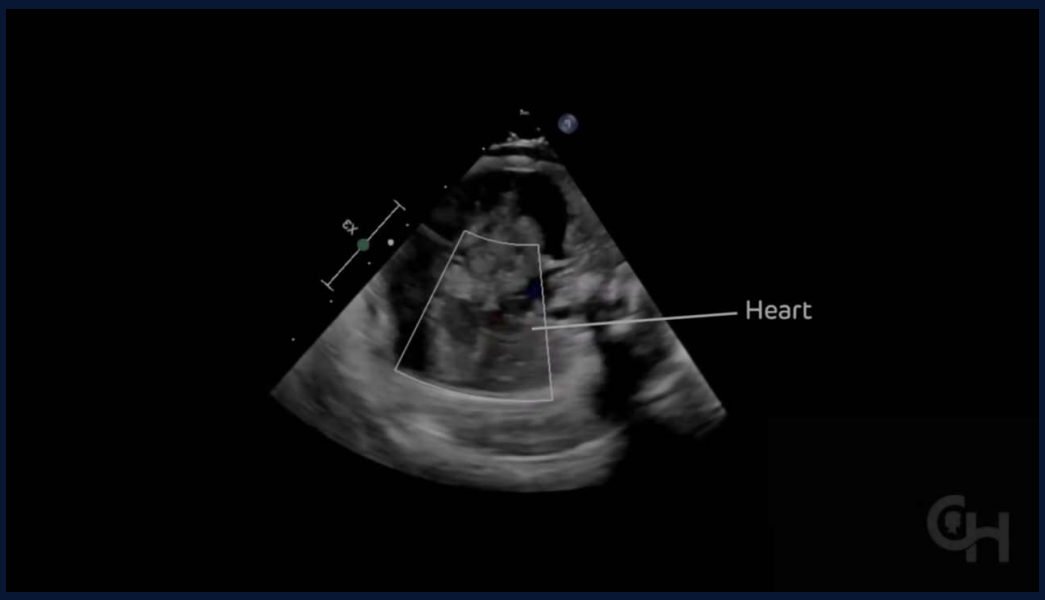

[13] CHOP, 2024

47

"

Over the past decades, the life expectancy of individuals with congenital heart disease (CHD) has increased significantly due to medical advances.

48

© Copyright. Society of Diagnostic Medical Sonography. All Rights Reserved.



49

Refenced Works

1. March of Dimes. Nowhere to go: maternity care deserts across the U.S. March of Dimes website. Published 2026. Accessed September 5, 2026. https://www.marchofdimes.org/maternity-care-deserts-report

2. Centers for Disease Control and Prevention. Hypoplastic left heart syndrome (HLHS). CDC website. Published May 15, 2024. Updated January 9, 2026. Accessed September 5, 2026. https://www.cdc.gov/heart-defects/about/hypoplastic-left-heart-syndrome.html

3. Datta S, Cao W, Skillman M, Wu M. Hypoplastic left heart syndrome: signaling & molecular perspectives, and the road ahead. Int J Mol Sci. 2023;24(20):15249. Published October 17, 2023. doi:10.3390/ijms242015249

4. Gaynor J, Mahle M, Ittenbach R, et al. Long-term survival and patient-reported outcomes after staged reconstructive surgery for hypoplastic left heart syndrome. J Am Coll Cardiol. 2025;85(24):2386-2398. doi:10.1016/j.jacc.2025.04.028

5. Moradi B, Tahmasebpour AR, Fattahi Masrour F, Jeanty P. Hypoplastic left heart syndrome. Visual Encyclopedia of Ultrasound in Obstetrics and Gynecology. VISUOG website. Published February 2022. Accessed September 5, 2026. https://www.isuog.org/education/visuog/obstetrics/heart/abnormal-4-chamber-view/hypoplastic-ventricles/hypoplastic-left-heart-syndrome.html

6. Metro Hospital Jabalpur. Services in cardiology. Heart Center website. Accessed September 5, 2026. http://metroprimehospital.com/heartcenter/cardiology_service.php

7. García Delgado R, Hernández Pérez D, García Rodríguez R, Ortega Cárdenes I, León Arencibia L, Amaro Acosta A. Atrioventricular septal defects. Visual Encyclopedia of Ultrasound in Obstetrics and Gynecology. VISUOG website. Published August 2022. Accessed September 5, 2026. https://www.isuog.org/education/visuog/obstetrics/heart/abnormal-4-chamber-view/septal-defects/atrioventricular-septal-defect.html

8. Abdul Ghayum MA, Schermerhorn J, Hancock H, et al. Fetal congenital complete heart block: 2 success stories through multidisciplinary care. JACC Case Rep. 2025;30(29):105158. doi:10.1016/j.jaccas.2025.105158

9. International Society of Ultrasound in Obstetrics and Gynecology. Congenital heart block. Patient Information Series. ISUOG website. Updated June 2023. Accessed September 5, 2026. https://www.isuog.org/clinical-resources/patient-information-series/patient-information-pregnancy-conditions/heart/congenital-heart-block.html

10. The physician-trusted MCOT monitor. First-Call Medical website. Accessed September 5, 2026. https://site.myfirstcallmedical.com/mcot-monitor

11. Centers for Disease Control and Prevention. 4.5e Pulmonary valve atresia (Q22.0). Birth Defects Surveillance Manual. CDC website. Published December 8, 2020. Accessed September 5, 2026. https://archive.cdc.gov/www_cdc_gov/ncbddd/birthdefects/surveillancemanual/chapters/chapter-4/chapter4-5e.html

12. García Delgado R, García Rodríguez R, Ortega Cárdenes I, Hernández Pérez D, Amaro Acosta A, Benitez Delgado T. Pulmonary atresia with intact ventricular septum. Visual Encyclopedia of Ultrasound in Obstetrics and Gynecology. VISUOG website. Published October 2022. Accessed September 5, 2026. https://www.isuog.org/education/visuog/obstetrics/heart/abnormal-4-chamber-view/hypoplastic-ventricles/pulmonary-atresia-with-intact-ventricular-septum.html

13. Children's Hospital of Philadelphia. Arley's story: fetal surgery for pericardial teratoma. CHOP website. Published 2024. Accessed September 5, 2026. https://www.chop.edu/arleys-story-fetal-surgery-pericardial-teratoma

14. Dattani S. The day a child is born is the most dangerous day of their life. Our World in Data website. Published August 12, 2024. Accessed September 5, 2026. https://ourworldindata.org/data-insights/the-day-a-child-is-born-is-the-most-dangerous-day-of-their-life

50

© Copyright. Society of Diagnostic Medical Sonography. All Rights Reserved.