When the Arch is the Issue

Imaging the Fetal Aortic and Ductal Arch

Christina Werth, MHA, RDMS, RDCS
Echosonographer | Fetal Heart Program
Children's Hospital of Philadelphia

2026 SDMS ANNUAL CONFERENCE
SEPTEMBER 24–26
ATLANTA, GA

1

SPEAKER PRESENTATION DISCLAIMER

The content and views presented are made available for educational purposes only. The information presented are the opinions of the presenter and do not necessarily represent the views of the Society of Diagnostic Medical Sonography (SDMS) or its affiliated organizations, officers, Boards of Directors, or staff members.

The presenter is responsible for ensuring balance, independence, objectivity, scientific rigor, and avoiding commercial bias in their presentation. Before making the presentation, the presenter is required to disclose to the audience any relevant financial interests or relationships with manufacturers or providers of medical products, services, technologies, and programs.

The SDMS and its affiliated organizations, officers, Board of Directors, and staff members disclaim any and all liability for all claims that may arise out of the use of this educational activity.

2

© Copyright. Society of Diagnostic Medical Sonography. All Rights Reserved.

Learning Objectives

01 Identify normal and abnormal anatomy of the fetal aortic arch and ductus arteriosus to support accurate diagnosis.

02 Describe sonographic techniques used to optimize visualization of the great vessels to improve image quality.

03 Apply principles of hemodynamic changes associated with abnormalities to predict need for empirical PGE in clinical practice.

3

Anatomy Review

Embryology · Anatomy of the Arches · Why it Matters

01

4

© Copyright. Society of Diagnostic Medical Sonography. All Rights Reserved.

Just a *Tiny* Bit of Embryology

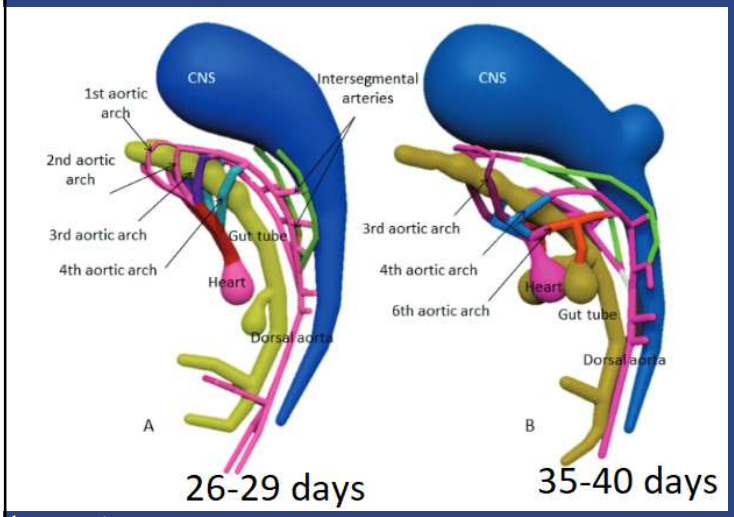

[1] Bravo et al, 2016

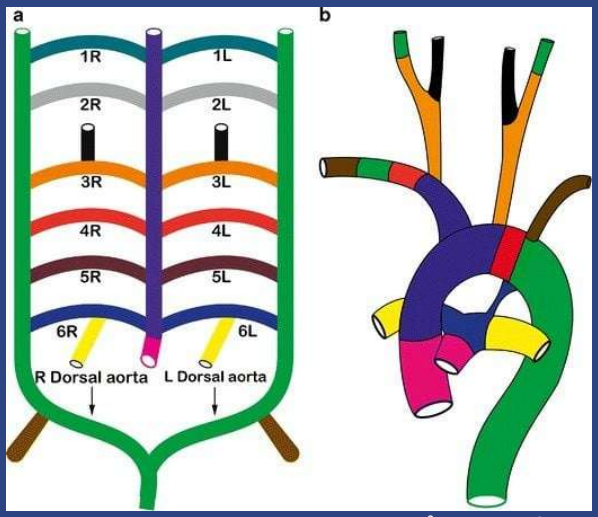

[2] Etesami et al, 2014

5

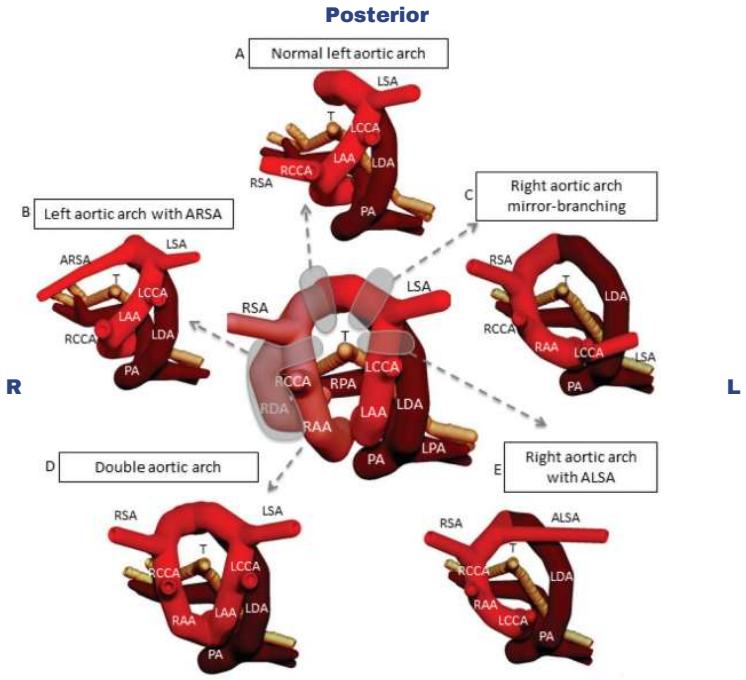

[1] Bravo et al, 2016

6

© Copyright. Society of Diagnostic Medical Sonography. All Rights Reserved.

Normal Anatomy & Branching: Postnatal Arch

Right

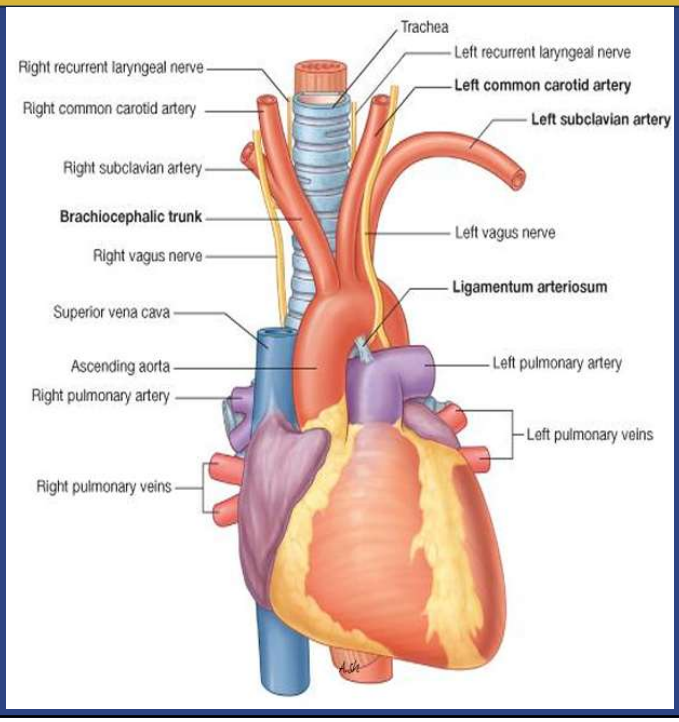

Left

[3] Drake et al, 2019

7

Normal Anatomy: Prenatal Circulation

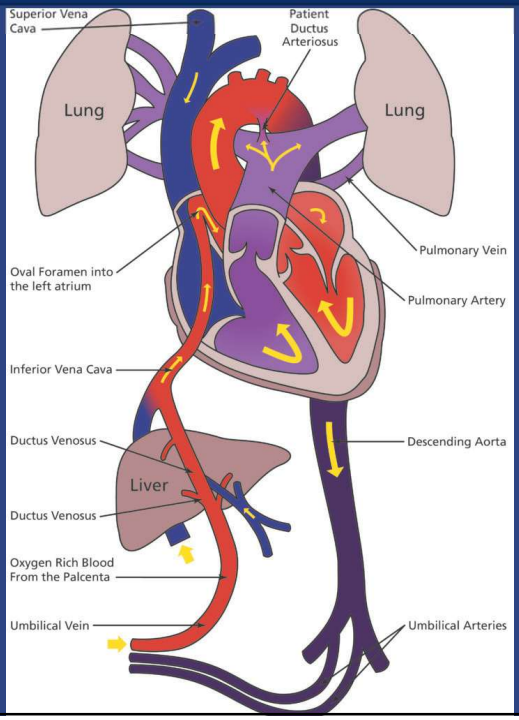

[4] Leeds Teaching Hospitals NHS Trust, 2026

8

© Copyright. Society of Diagnostic Medical Sonography. All Rights Reserved.

Technique & Optimization

02

Pearls for imaging the great vessels

9

Transducer Selection & Patient Setup

Use the **HIGHEST FREQUENCY** ultrasound probe possible while still providing adequate penetration

Know your **KNOBOLOGY**

Optimize fetal position through **PATIENT POSITIONING**

Optimize sonographer **ERGONOMICS** consitently

Maintain patient and sonographer **COMFORT** throughout the study



10

© Copyright. Society of Diagnostic Medical Sonography. All Rights Reserved.

Imaging Strategy

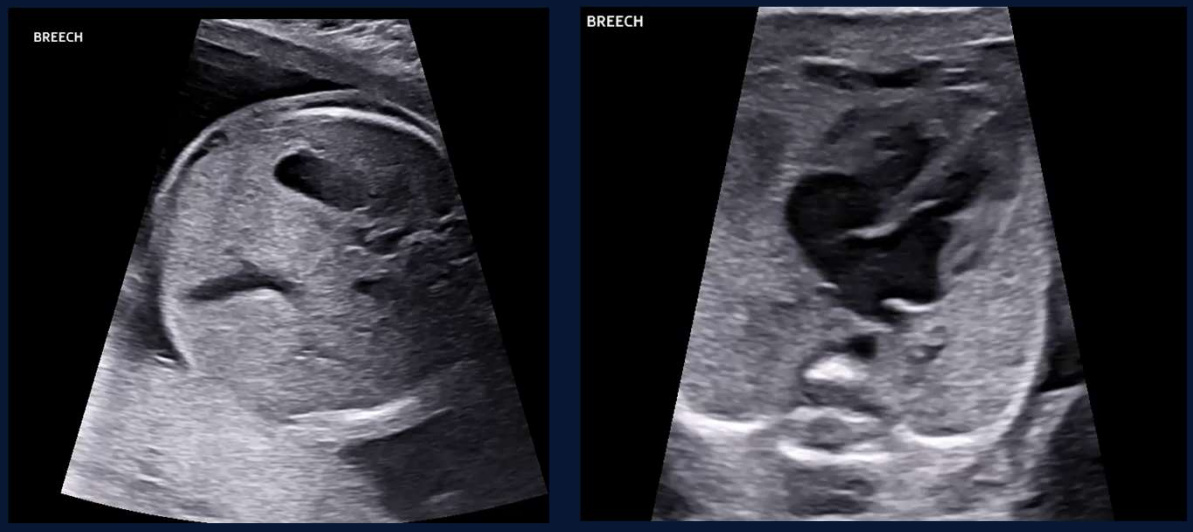

From personal files of Werth C. (on file with author).

11

Normal Aortic Arch: Anatomy & Imaging Characteristics



From personal files of Werth C. (on file with author).

12

© Copyright. Society of Diagnostic Medical Sonography. All Rights Reserved.

Normal Aortic Arch: Anatomy & Imaging Characteristics



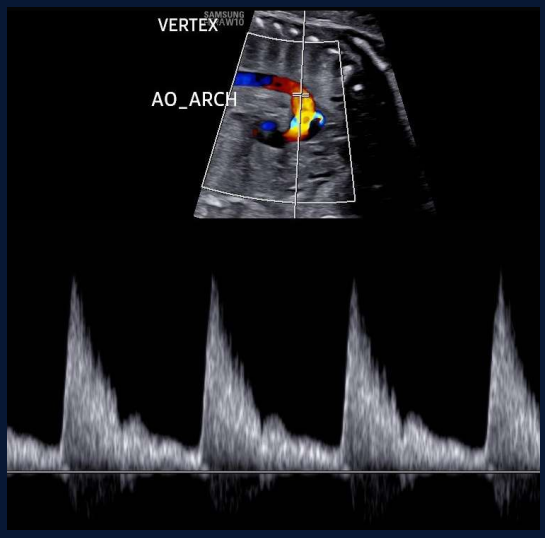

From personal files of Werth C. (on file with author).

13

Normal Ductal Arch: Anatomy & Imaging Characteristics





From personal files of Werth C. (on file with author).

14

© Copyright. Society of Diagnostic Medical Sonography. All Rights Reserved.

Normal Ductal Arch: Anatomy & Imaging Characteristics



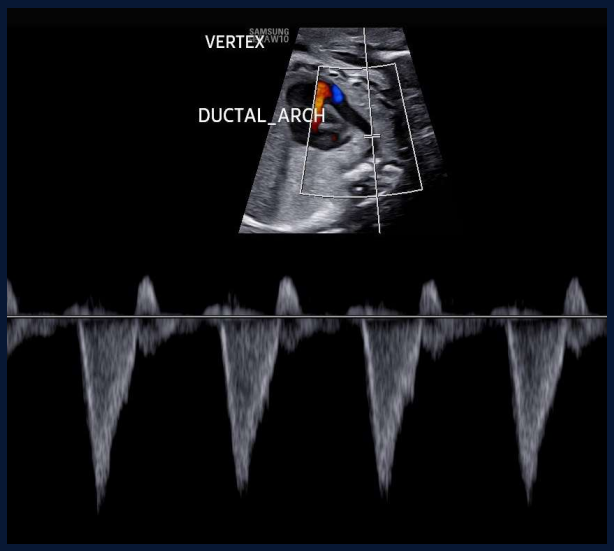

From personal files of Werth C. (on file with author).

15

Three Vessel View: Anatomy & Branching



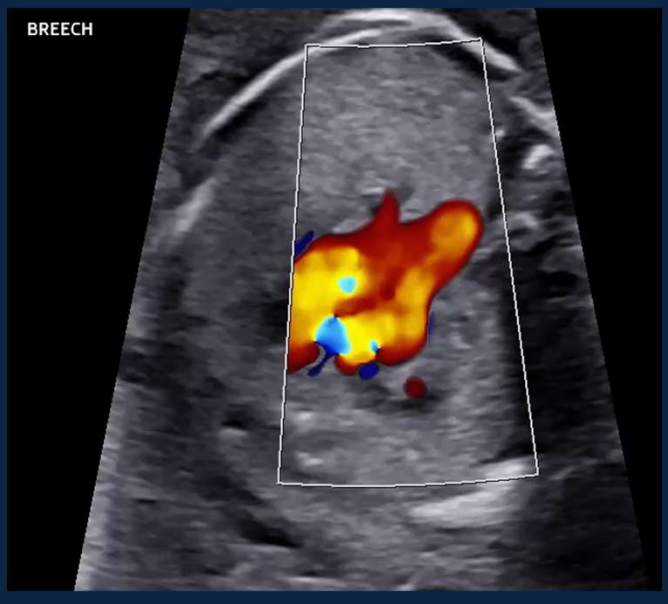

From personal files of Werth C. (on file with author).

16

© Copyright. Society of Diagnostic Medical Sonography. All Rights Reserved.

Doppler Optimization

- PRF / velocity scale:
  - Start at 60-70 cm/s for outflow tracts
    - Drop lower if duct is small or not well seen (~20 cm/s in some CHD)
  - Lower scale to 20-30 cm/s for head vessels/branch pattern
- Wall filter: High to reduce noise, but decrease if needed
- Color gain: increase until noise just appears, then decrease
  - Aliasing can be a helpful tool: look for turbulence, velocity elevations, and be sure to ensure the scale is appropriate to distinguish retrograde flow
- Spectral Doppler: Helpful in "proving" your findings! Familiarize yourself with the normal waveforms and what variations mean

??? Power Doppler: some use when signal is weak (posterior fetal spine, elevated BMI, etc.)
  - direction-independent but sensitive ⟶ PITFALLS

17

Normal, Transient or Disease?

Recognizing when variants are clinically significant

03

18

© Copyright. Society of Diagnostic Medical Sonography. All Rights Reserved.

The Power of the "Abnormal Three Vessel View"

Application of the 3-Vessel View in Routine Prenatal Sonographic Screening for Congenital Heart Disease

Qingqing Wu, MD, Man Li, PhD, Lirong Ju, BS, Weiyuan Zhang, MD, Xinghua Yang, PhD, Yuxiang Yan, PhD, Wei Wang, MD, PhD

Table 3. Sensitivity, Specificity, PPV, and NPV of Different Sonographic Planes

Parameter	4CV	4CV + LVOT	4CV + RVOT	4CV + VVOT	4CV + 3VV
Sensitivity, %	65.6	78.1	81.3	81.3	81.3
Specificity, %	99.9	99.9	99.9	99.9	99.9
PPV, %	84	86.2	86.7	86.7	86.7
NPV, %	99.9	99.9	99.9	99.9	99.9

Abbreviations are as in Table 1.

[5] Wu et al, 2009

- In 2018, the AIUM added the THREE VESSEL VIEW to their anatomy protocol
- Great screening tool because it's as sensitive for major CHD as 4ch+outflow tract

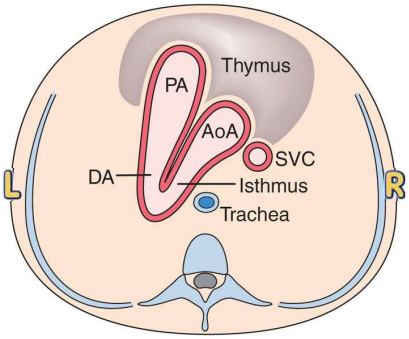

[5] Wu et al, 2009

19

The Lesser Known Normal Anatomy of the "Three Vessel View"

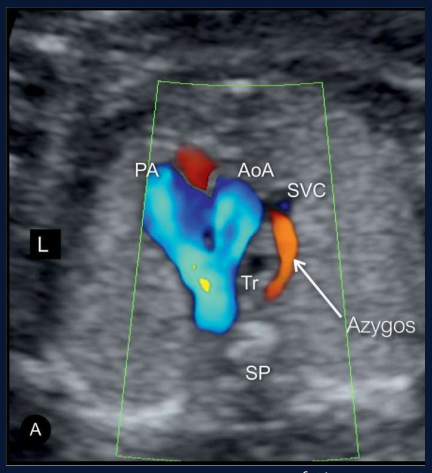

[6] ObgynKey, 2016

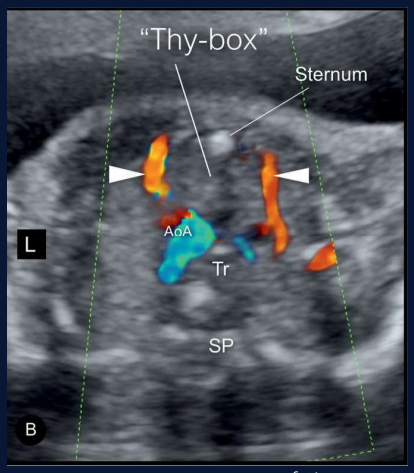

[6] ObgynKey, 2016



[7] Iacovache, 2015

20

© Copyright. Society of Diagnostic Medical Sonography. All Rights Reserved.

Ductal Arch Variants: Constriction, Torturousity, Aneurysm

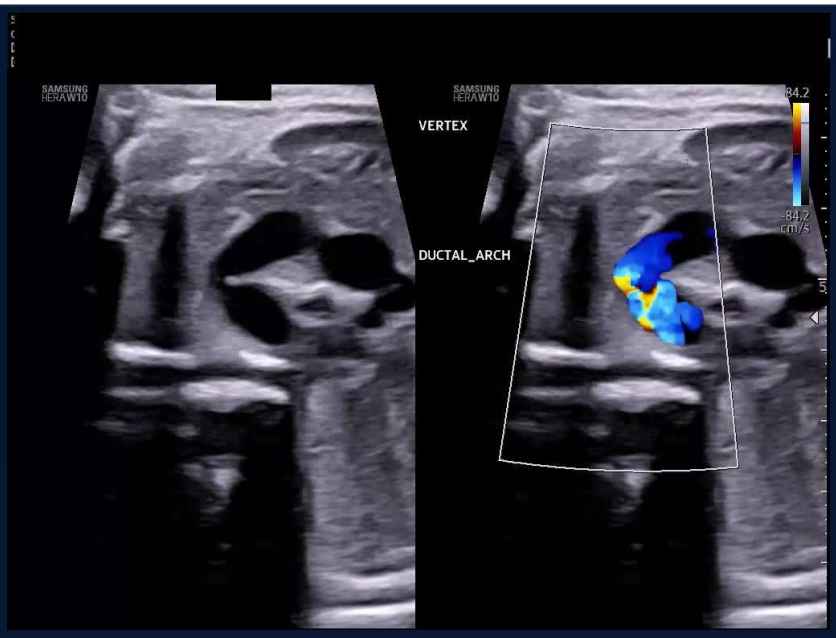

From personal files of Werth C. (on file with author).

21

Ductal Arch Variants: Constriction, Torturousity, Aneurysm

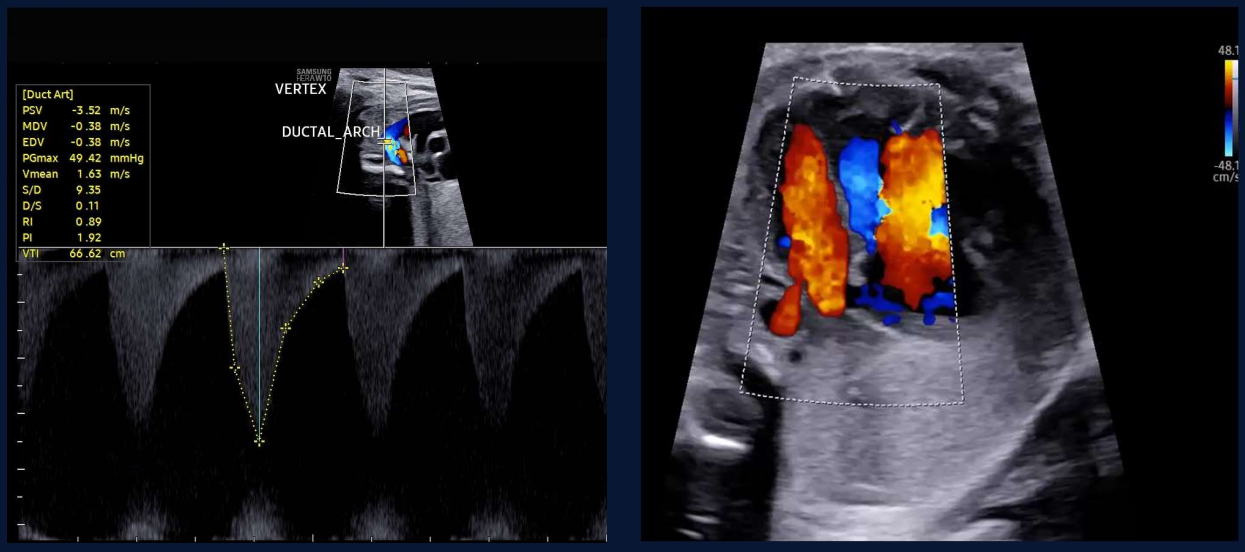

From personal files of Werth C. (on file with author).

22

© Copyright. Society of Diagnostic Medical Sonography. All Rights Reserved.

Ductal Variants: Constriction, Torturousity, Aneurysm

Caused by premature narrowing of the ductal tissue
- will result in **right heart dysfunction** and **hydrops** if left untreated

Provoking Agents [8]:
- non-steroidal anti-inflammatory drugs (NSAIDS)
- some selective serotonin reuptake inhibitors (SSRI)
- adrenergic alpha agonist (oxymetazoline, naphazoline)
- polyphenol-rich substances (herbal tea, caffeine)
- exposure to chemical solvents

Association with Gestational Diabetes

Treatments: discontinue exposure to any provoking agents, monitor, delivery

Postnatally [8]: can contribute to pulmonary issues, transient respiratory problems, and mild neonatal hyperbilirubinemia

[8] Biały et al, 2025

23

Ductal Arch Variants: Constriction, Torturousity, Aneurysm

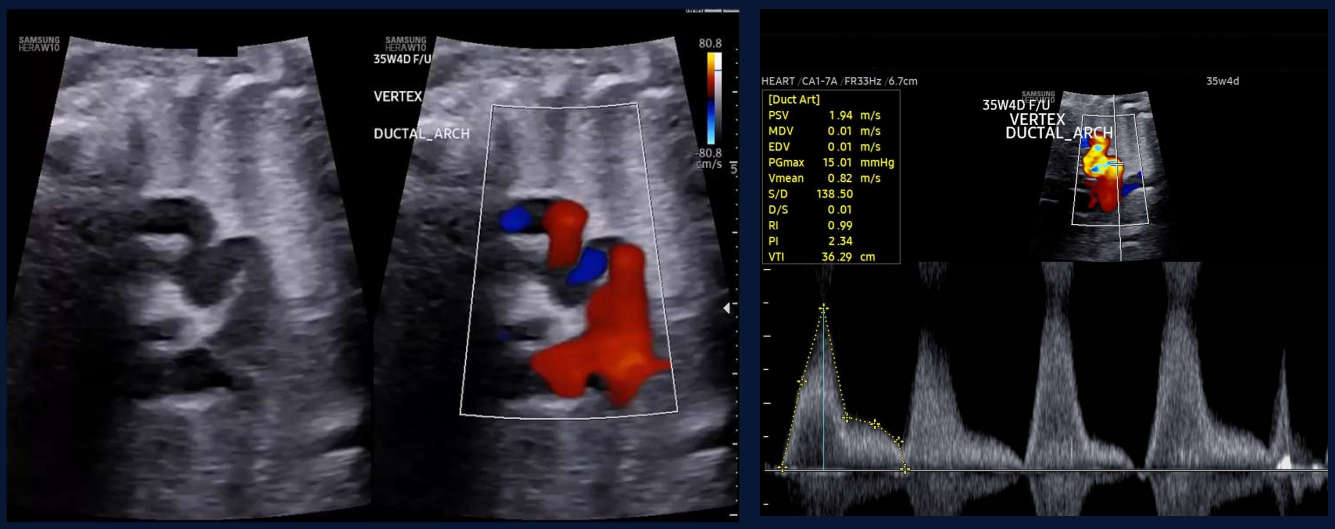

From personal files of Werth C. (on file with author).

24

© Copyright. Society of Diagnostic Medical Sonography. All Rights Reserved.

Ductal Arch Variants: Constriction, Torturousity, Aneurysm

Ductal Torturousity is a term used to describe a serpiginous (curvy) ductus arteriosus

May note elevated velocities at the turn points

Take care to follow the ductal course to ensure there isn't retrograde flow or constriction

Clinically insignificant in isolation[9]

- *May require stenting in ductal dependent CHD*



[9] Nguyen et al, 2026

From personal files of Werth C. (on file with author).

25

Ductal Arch Variants: Constriction, Torturousity, Aneurysm

Ductal Aneurysm is a **generally benign** bulging or enlargement of the ductal tissue

May have delayed spontaneous closure but no increased risk for persistent PDA compared to general population[11]

Associations[10]
Rarely, can be associated with:

- connective-tissue disorders
- thrombo-embolism
- compression of surrounding thoracic structures
- and life-threatening spontaneous rupture requiring surgical correction



[10] Ganesan et al, 2015
[11] Bannan et al, 2021

From personal files of Werth C. (on file with author).

26

© Copyright. Society of Diagnostic Medical Sonography. All Rights Reserved.

Ductal Variants: Constriction, Torturousity, Aneurysm





From personal files of Werth C. (on file with author).

27

Aortic Arch Variants: Physiologic Retrograde Flow

Associations:
Late GA
Low cerebral vascular resistance
Fetal Anemia
Underfilling of the LV, aneyursmic PFO

Carefully assess the arch size and contour
R/o intracranial abnomalities (AVM, Vein of Galen, mass)

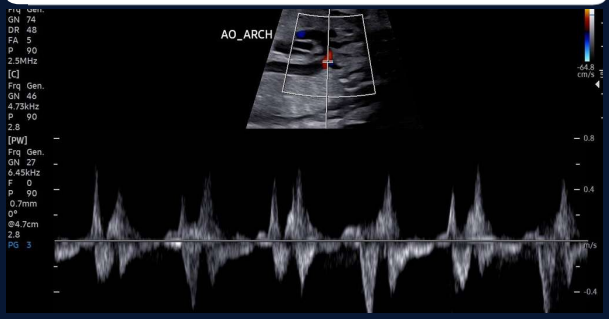



From personal files of Werth C. (on file with author).

28

© Copyright. Society of Diagnostic Medical Sonography. All Rights Reserved.

Rings & Things

Understanding Potentially Problematic Branch Patterns

04

29

Arch Branch Pattern Differences

Non-vascular ring type anomaly

Not likely to require surgical intervention when in isolation.[12]

May have **other implications however:** common for fetuses to have additional anomalies (cardiac, extracardiac, or genetic).

Vascular ring

Vessels must be anterior and posterior to the trachea.

Surgical intervention may be required in 50% of cases.[12]

Surgical intervention is **guided by whether or not a vascular ring is symptomatic** (symptoms are caused by airway or esophageal compression).

[12] Fulton & Prosnitz, 2022

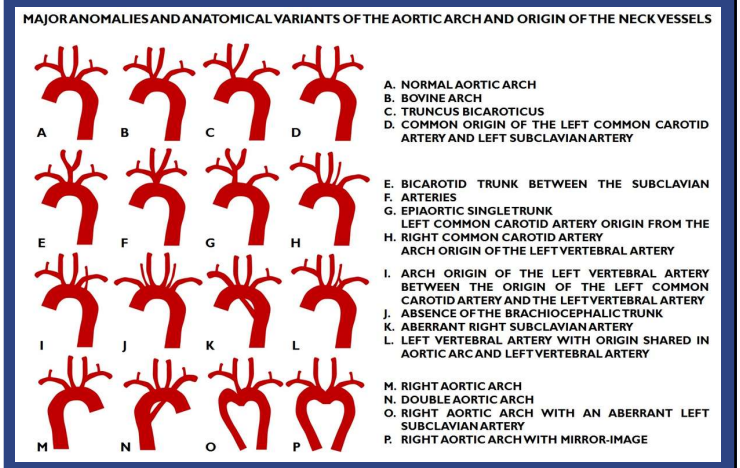

[13] Raimundo et al, 2019

30

© Copyright. Society of Diagnostic Medical Sonography. All Rights Reserved.

Aortic Arch Variants: ARSA

Aberrant right subclavian artery (ARSA) arises directly from the distal portion of the aortic arch, or from the upper portion of the descending aorta, as the lowest fourth branch.

Vascular ring? No.

Incidence: 1-2% of general population[14]

Associations[14]
- T21
- T18
- ~20% will have other anomalies (usually genetic or cardiac)
- 22q11.2 deletion when seen with additional cardiac anomalies

Normal variant in true isolation



[14] Rembouskos & Volpe, 2014

From personal files of Werth C. (on file with author).

31

Right Aortic Arch (RAA) with Left Duct (LDA)

Right Aortic Arch is a sidedness abnormality where the aorta is right of the trachea instead of left.

Pearl: Always assess the ductal sidedness and aortic branch pattern, these determine if it's a vascular ring.

Vascular ring? YES.

Incidence: 1:1000 in general population[15]

Associations[15]
- 22q11.2 deletion
- T21
- Other cardiac anomalies
- Extracardiac anomalies

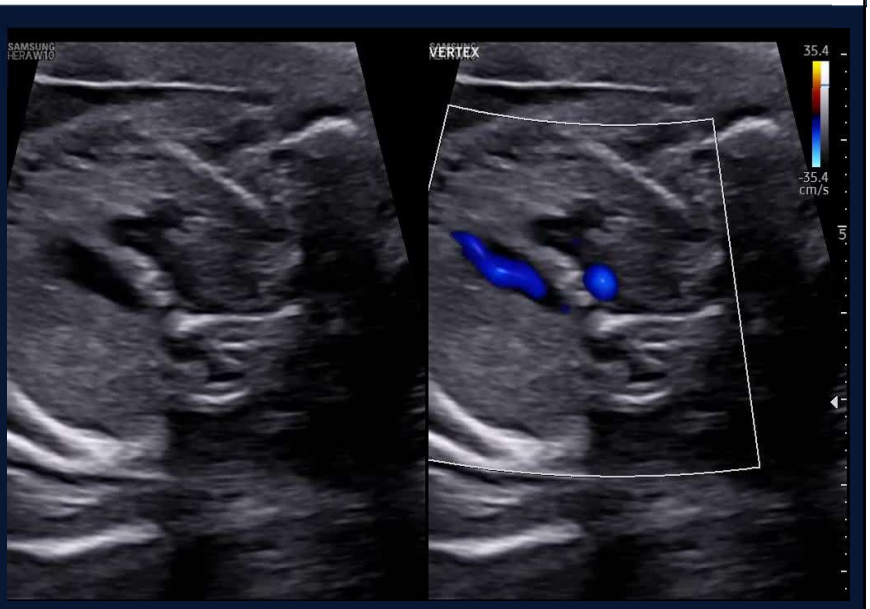

[15] Volpe et al, 2018

From personal files of Werth C. (on file with author).

32

© Copyright. Society of Diagnostic Medical Sonography. All Rights Reserved.

Right Aortic Arch (RAA) with Left Duct (LDA)

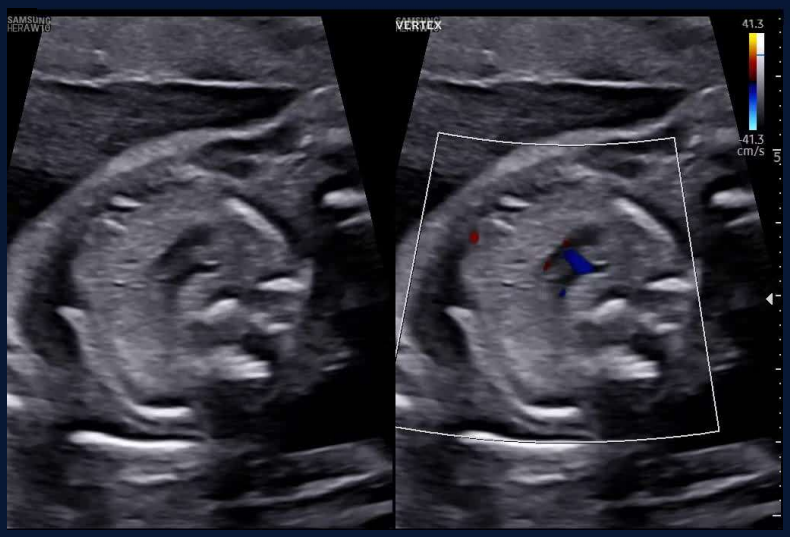

From personal files of Werth C. (on file with author).

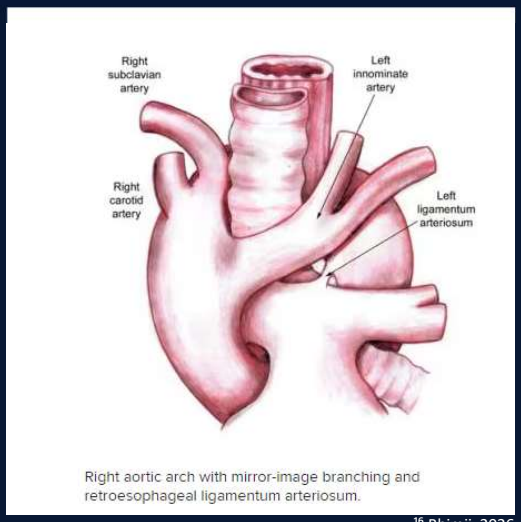

Right aortic arch with mirror-image branching and retroesophageal ligamentum arteriosum.

[16] Bhimji, 2026

33

Right Aortic Arch (RAA), Left Duct, ALSA: Higher Risk Vascular Ring





From personal files of Werth C. (on file with author).

34

© Copyright. Society of Diagnostic Medical Sonography. All Rights Reserved.

Right Aortic Arch (RAA), Right Duct (LDA)

Mirror Image Right Aortic Arch with Right Duct is a sidedness abnormality where the aorta AND the duct is right of the trachea instead of left.

Vascular ring? No.

Incidence: About 10% of RAA will also have a RDA[17]

Associations

- standard associations for a right aortic arch



[18] Li et al, 2022

35

Right Aortic Arch (RAA): Without Vascular Ring (RAA, RDA)

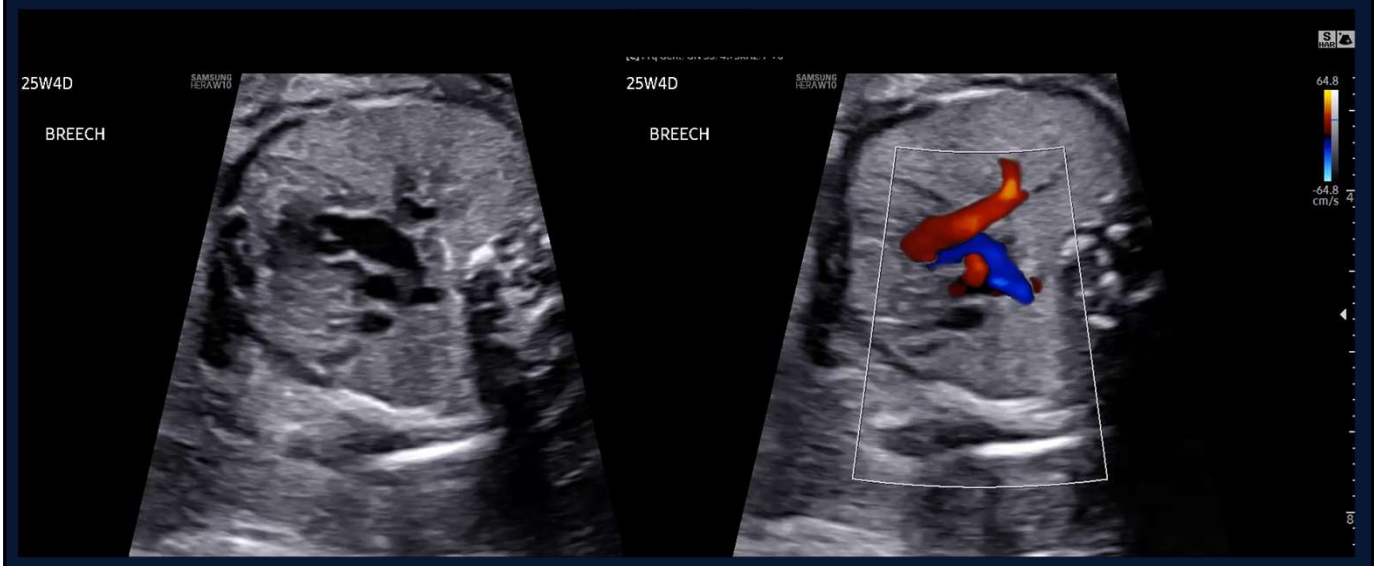

From personal files of Werth C. (on file with author).

36

© Copyright. Society of Diagnostic Medical Sonography. All Rights Reserved.

Double Aortic Arch: The Complete Vascular Ring

Double Aortic Arch is a form of vascular ring where the trachea and esophagus are surrounded in the form of a circle by the right and left aortic arches.

Vascular ring? YES.

Associations

- strong association with 22q11.2 deletion even in the absence of intra-cardiac anomalies[19]

Prognosis: >70% will be symptomatic by age 2.[20]

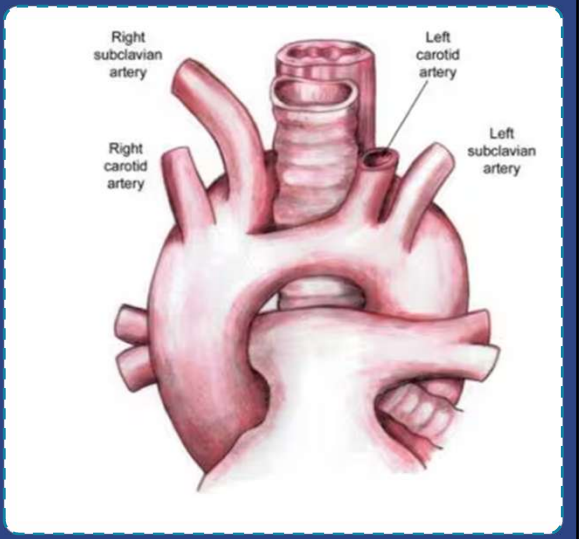

[16] Bhimji, 2026

37

Double Aortic Arch: The Complete Vascular Ring

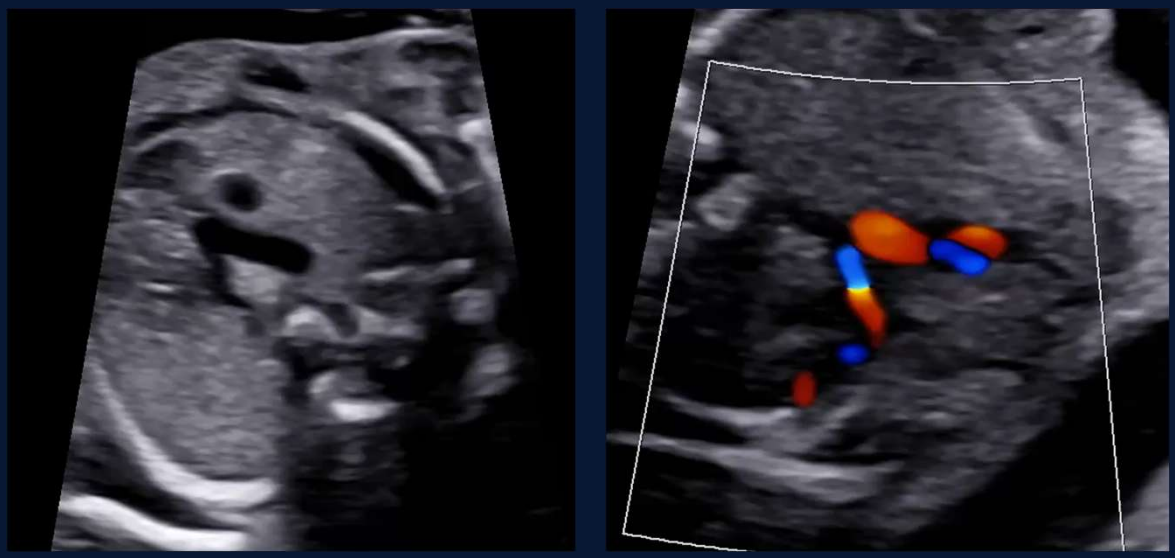

From personal files of Werth C. (on file with author).

38

© Copyright. Society of Diagnostic Medical Sonography. All Rights Reserved.

Ductal Dependent Arch Anomalies

05

The Most Critical of Arch Anomalies

39

The Ductus: A Lifeline in Ductal-Dependent Circulation

Left-Sided Ductal Dependence

- Obstruction to SYSTEMIC flow
  - Examples: CoA, IAA, critical aortic stenosis, HLHS
- Without PGE: lower body ischemia, metabolic acidosis, shock

Right-Sided Ductal Dependence

- Obstruction to PULMONARY flow
  - Examples: PA/IVS, critical PS, tricuspid atresia with PS
- Without PGE: severe hypoxemia, cyanosis



Ductal dependence requires PGE_1 at birth to keep the ductus open until surgical palliation

40

© Copyright. Society of Diagnostic Medical Sonography. All Rights Reserved.

Coarctation of the Aorta (CoA): Prenatal Recognition

Key Findings:

- Ventricular disproportion: RV > LV (often the first clue)
- Aortic arch hypoplasia or isthmus narrowing
- Small or hypoplastic aortic valve
- Discordant vessels in 3VT: PA much bigger than Ao
- **Associated findings**: PLSVC, VSD, AS

Z-score of the aortic arch isthmus: values < −2 raise concern

- **Pearl:** the isthmus should measure at least at GA (32w = 3.2mm)
- **Pearl:** arch >3mm is ok to test, usually will be sufficient for a term neonate

Serial surveillance: many cases identified late or postnatally*



From personal files of Werth C. (on file with author).

41

Coarctation of the Aorta (CoA): Prenatal Recognition

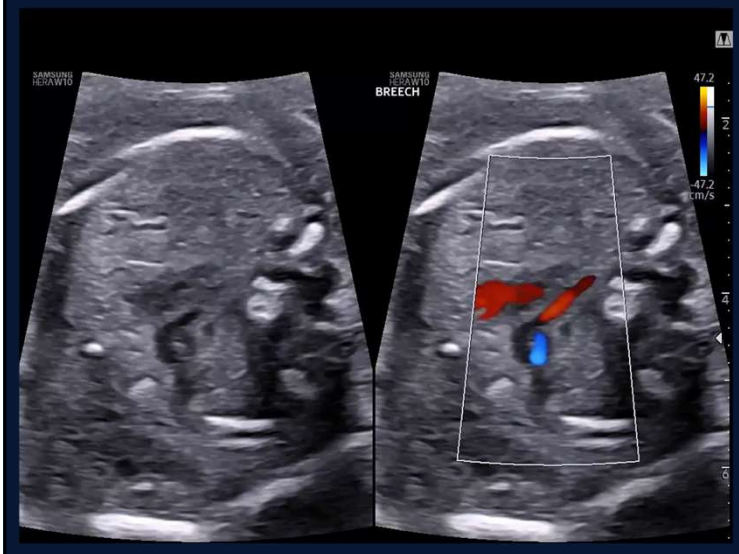

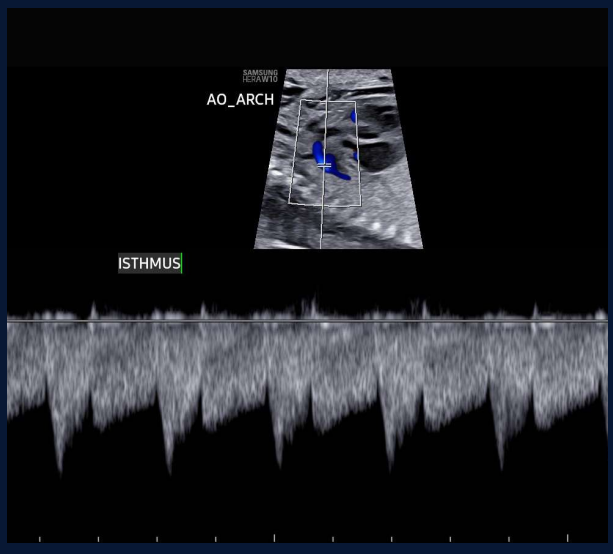

From personal files of Werth C. (on file with author).

42

© Copyright. Society of Diagnostic Medical Sonography. All Rights Reserved.

Coarctation of the Aorta (CoA): Postnatal Imaging

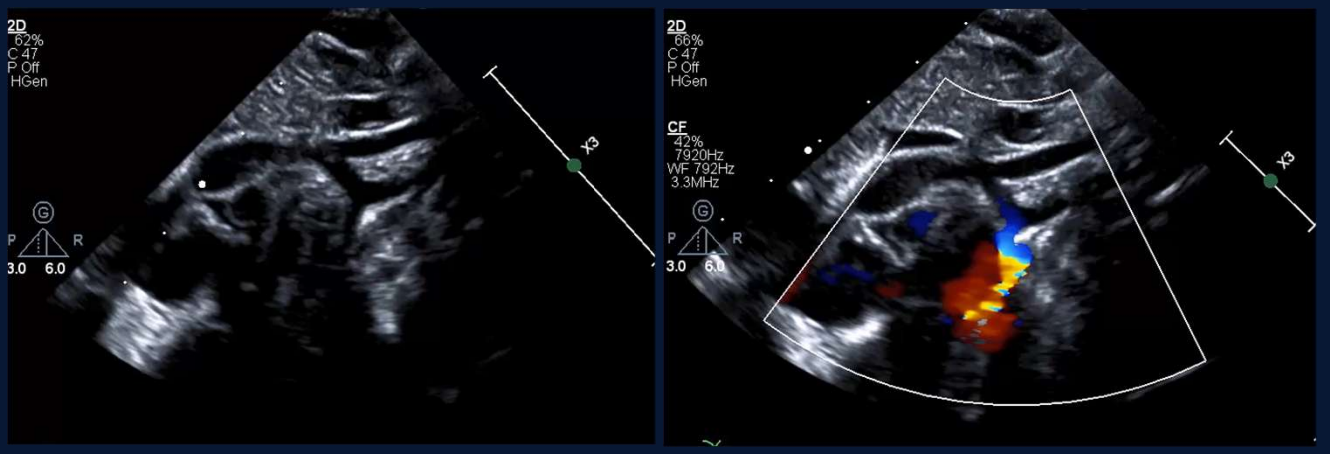

From personal files of Werth C. (on file with author).

43

Coarctation of the Aorta (CoA): PITFALL



From personal files of Werth C. (on file with author).

44

© Copyright. Society of Diagnostic Medical Sonography. All Rights Reserved.

Arch Hypoplasia

Underdevelopment of a larger section of arch, rather than focal area

- Similar physiology and associations to coarctations
  - Both will be **ductal dependent** (require PGE1) and need surgical repair
  - **More severe** in clinical ramifications with shock and instability presenting earlier than in coarctations[21]

Key Findings:

- Ventricular disproportion
- Aortic arch measuring less than GA
- Discordant vessels in 3VT: PA much bigger than Ao



From personal files of Werth C. (on file with author).

45

Arch Hypoplasia





From personal files of Werth C. (on file with author).

46

© Copyright. Society of Diagnostic Medical Sonography. All Rights Reserved.

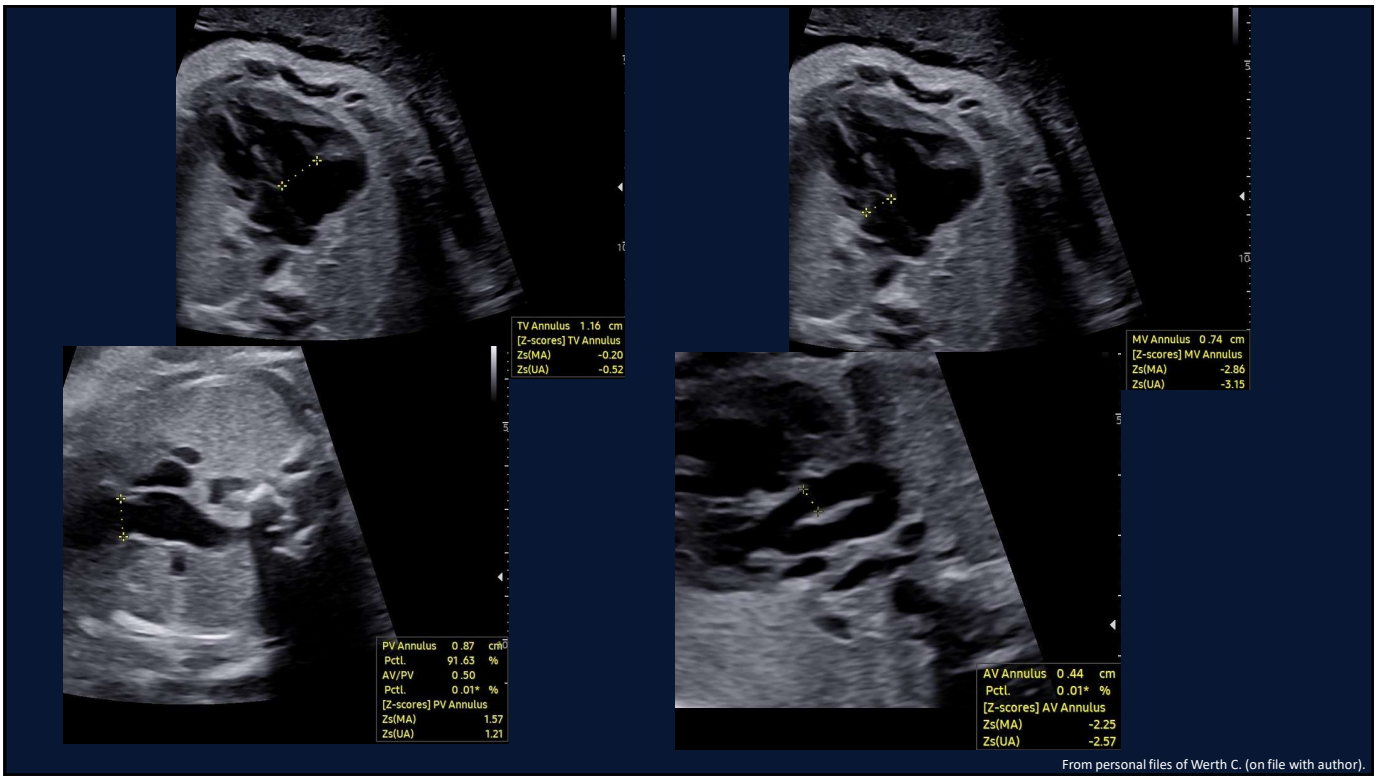

From personal files of Werth C. (on file with author).

47

Arch Hypoplasia

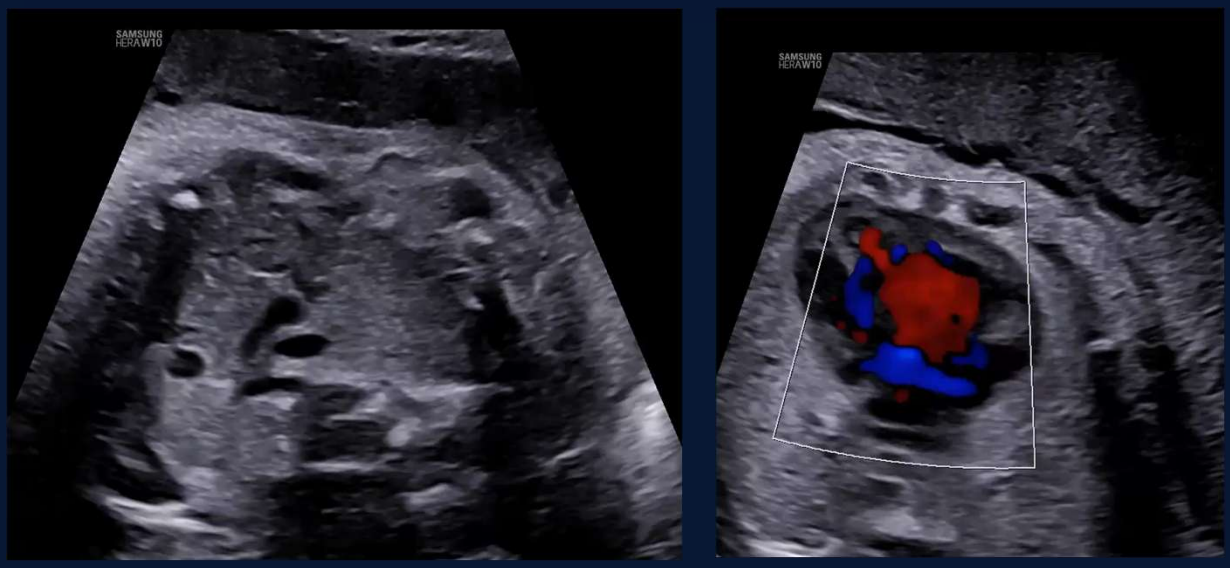

From personal files of Werth C. (on file with author).

48

© Copyright. Society of Diagnostic Medical Sonography. All Rights Reserved.

Arch Hypoplasia: Postnatal Imaging

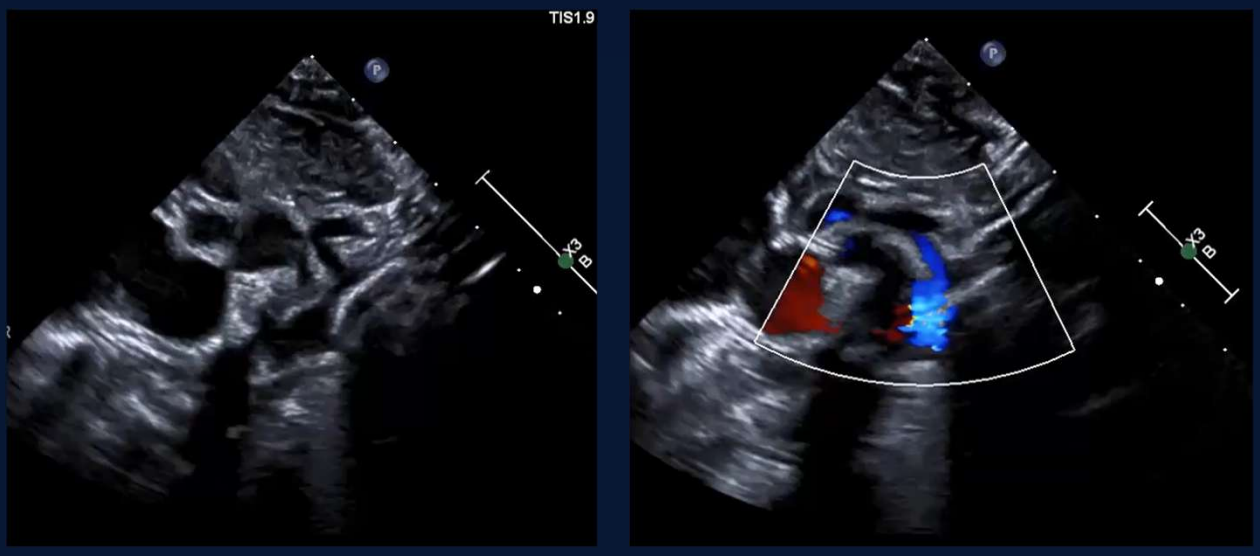

From personal files of Werth C. (on file with author).

49

Arch Hypoplasia: Postnatal Imaging

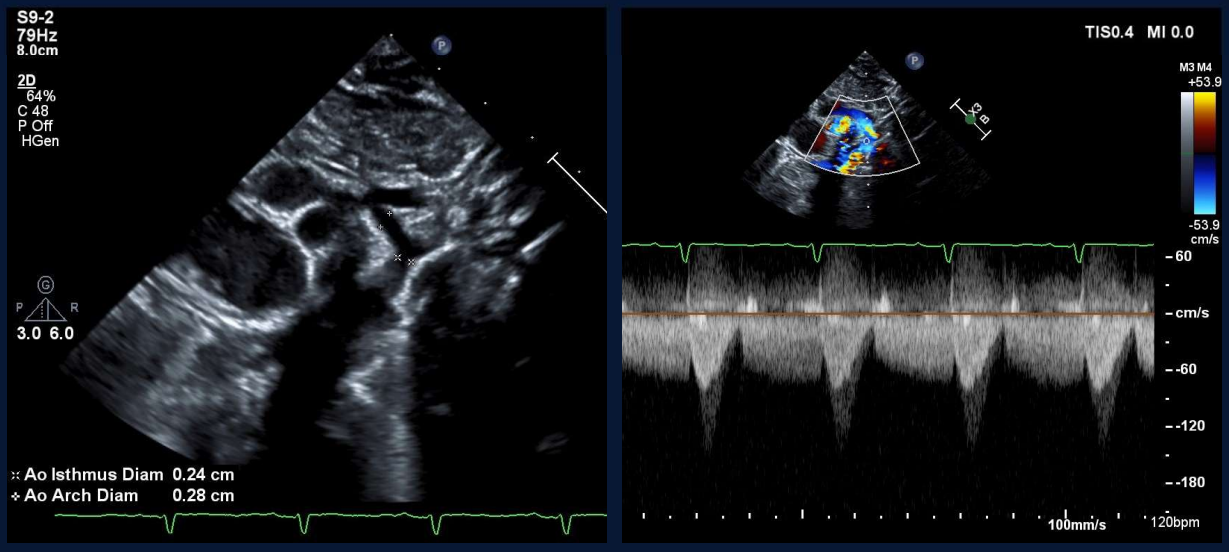

From personal files of Werth C. (on file with author).

50

© Copyright. Society of Diagnostic Medical Sonography. All Rights Reserved.

Interrupted Aortic Arch (IAA): Types & Imaging

- **Complete discontinuity of the aorta to the descending section**
- Types of IAA:
  - Type A (30%): distal to left subclavian artery (all 3 vessels on ascending aorta)
  - Type B (70%): between left carotid and left subclavian (interruption after 2nd head vessel)
  - Type C (rare): between innominate and left carotid (after 1st head vessel)
- Associations:
  - VSD present in nearly all, truncus arteriosus (type IV), AS, DORV, TGA
  - 22q11.2 deletion (more that 50% in type B)[22]
  - Extracardiac anomalies

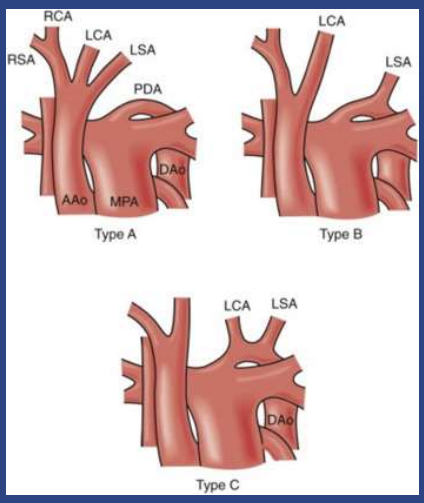

[23] Prendergast & Nicholson

⚑ **IAA: If suspected prenatally, delivery at a center with access to PGE_1 is critical.**

51

Interrupted Aortic Arch





From personal files of Werth C. (on file with author).

52

© Copyright. Society of Diagnostic Medical Sonography. All Rights Reserved.

Case Review

06

How can we better predict postnatal course in borderline cases?

53

Case Review

Presents for late evaluation at 36w4d due to LV/RV size disproportion on recent US

- **Concern for small LV and possible coarctation of the aorta**

History:

- **G4P1021**
- **Maternal hx of Asherman Syndrome**
- **Negative family hx for CHD**
- **Unremarkable pregnancy up to this point**

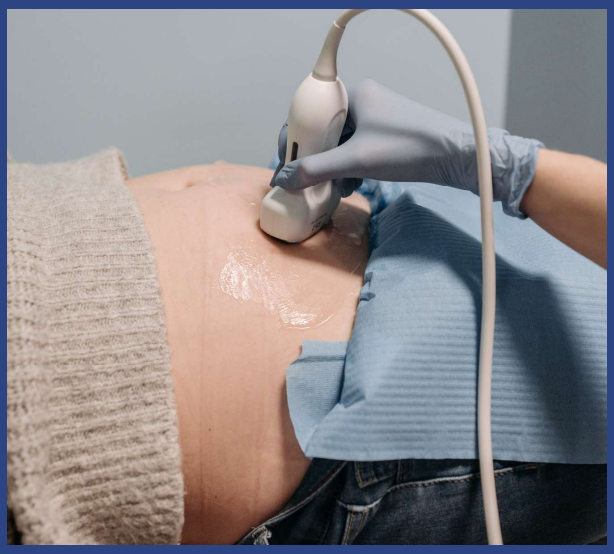

54

© Copyright. Society of Diagnostic Medical Sonography. All Rights Reserved.

Case Review



From personal files of Werth C. (on file with author).

55

Case Review



From personal files of Werth C. (on file with author).

56

© Copyright. Society of Diagnostic Medical Sonography. All Rights Reserved.

Case Review

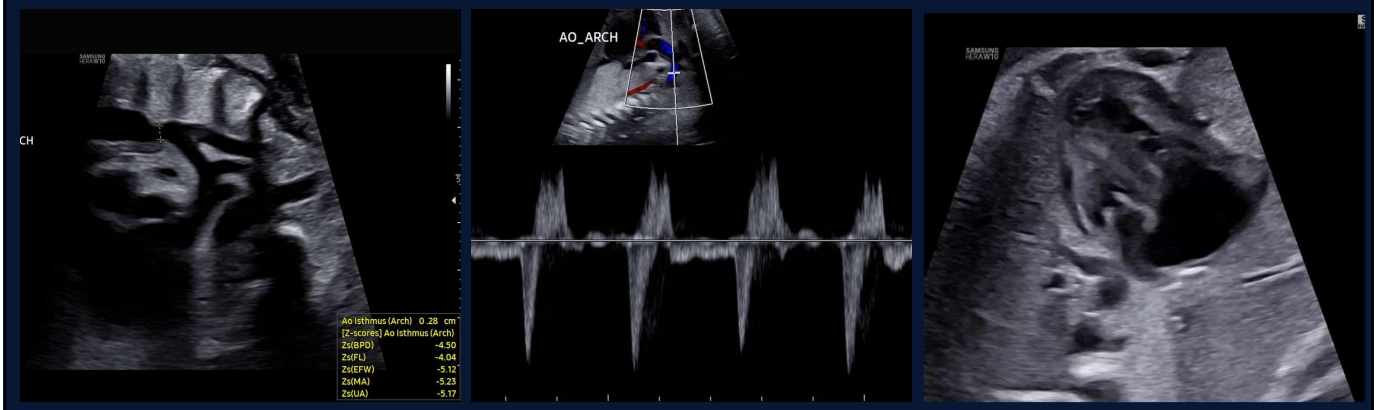

From personal files of Werth C. (on file with author).

57

Hyperoxygenation Test



Maternal Hyperoxygenation (MHO) Study

- Simulates oxygenation conditions more similar to the postnatal environment
- Used to help predict behaviors of circulation and anatomic structures postnatally

Physiology:

- Higher oxygen concentration in fetal blood causes a decrease in vascular resistance in the lungs, which increases blood flow returning to the left atria via pulmonary veins, improving LV filling, and altering geometry of the PFO flap.[24]



58

© Copyright. Society of Diagnostic Medical Sonography. All Rights Reserved.

Case Review - MHO



From personal files of Werth C. (on file with author).

59

Final Thoughts

07

60

© Copyright. Society of Diagnostic Medical Sonography. All Rights Reserved.

Why the Arches Matter

#1

CHD is the number one birth defect.[5]

PGE

Arch abnormalities compatible with fetal circulation may not be compatible postnatally.

Early dx drives decisions to initiate empirical prostaglandin.

↑Dx

At the 20 week scan, coarchs are missed up to 70% of the time.[25]

Systematic imaging significantly improves diagnostic accuracy!

61

5 Big Take Aways

1. Master the 3VT view: it is a powerful arch screening tool but it's time to look beyond the "three vessels."
2. Familarize yourself with branch patterns, they makes a difference, especially in vascular rings!
3. Variants can still have significance on prognosis, even if surgical/medical intervention won't be needed. Genetic workup must be offered.
4. Careful evaluation of the aortic arch is critical as ductal dependent circulation is not compatible with postnatal life without medical and/or surgical intervention.
5. Your imaging shapes not just the delivery plan, but the entire trajectory of care for families.

62

© Copyright. Society of Diagnostic Medical Sonography. All Rights Reserved.

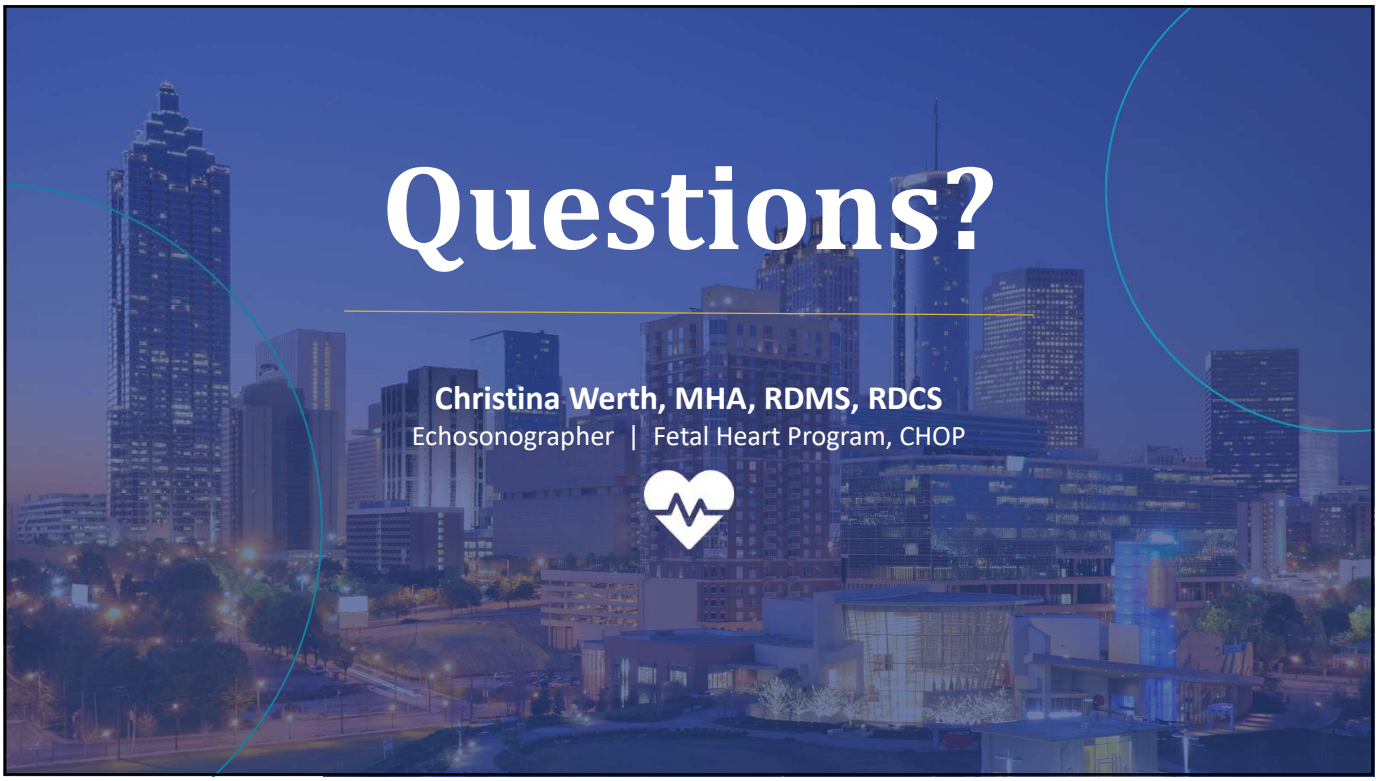

63

Refenced Works

1.Bravo C, Gámez F, Pérez R, et al. Fetal aortic arch anomalies. J Ultrasound Med. 2016;35(2):237-251. doi:10.7863/ultra.15.02063
2.Etesami M, Aswath R, Kanne J, Gilkeson R, Rajiah P. Computed tomography in the evaluation of vascular rings and slings. Insights Imaging. 2014;5(4):507-521. doi:10.1007/s13244-014-0343-3
3.Drake RL, Vogl AW, Mitchell AWM. Gray's Anatomy for Students. 4th ed. Elsevier Health Sciences; 2019.
4.Leeds Teaching Hospitals NHS Trust. Patent ductus arteriosus (PDA) in newborn infants. Leeds Teaching Hospitals NHS Trust website. Published May 15, 2026. Accessed September 2, 2026. https://www.leedsth.nhs.uk/patients/resources/patent-ductus-arteriosus-pda-in-newborn-infants/
5.Wu Q, Li M, Ju L, et al. Application of the 3-vessel view in routine prenatal sonographic screening for congenital heart disease. J Ultrasound Med. 2009;28(10):1319-1324. doi:10.7863/jum.2009.28.10.1319
6.The three-vessel-trachea view and upper mediastinum. ObgynKey website. Published August 27, 2016. Accessed September 5, 2026. https://obgynkey.com/the-three-vessel-trachea-view-and-upper-mediastinum/
7.Iacovache T. Left brachiocephalic vein - intrathymic course. TheFetus.net website. Published October 12, 2015. Accessed September 5, 2026. https://thefetus.net/content/left-brachiocephalic-vein-intrathymic-course
8.Biały ŁH, Talar T, Gulczyńska E, Strzelecka I, Respondek-Liberska M. Prenatal diagnosis of ductal constriction in normal heart anatomy—are there any neonatal consequences? J Clin Med. 2025;14(10):3388. doi:10.3390/jcm14103388
9.Nguyen CP, Michelfelder EC, Kreeger J, Jergel A, Ro SS. The significance of ductal tortuosity in late gestation fetuses with normal hearts: is there a relation to ductal flow changes or right ventricular functional findings? Am J Perinatol. Published online August 21, 2026. doi:10.1055/a-2935-6547
10.Ganesan S, Hutchinson DP, Sampson AJ. Prenatal diagnosis of ductus arteriosus aneurysm. Ultrasound. 2015;23(4):251-253. doi:10.1177/1742271X15587931
11.Bannan B, Aly S, Yoo SJ, Seed M, Lam CZ. The many faces of neonatal ductus arteriosus aneurysms: multimodality imaging with an emphasis on CT and MRI appearance. Radiol Cardiothorac Imaging. 2021;3(3):e210017. Published June 17, 2021. doi:10.1148/ryct.2021210017
12.Fulton DR, Prosnitz AR. Vascular rings and slings. In: Triedman JK, Armsby C, eds. UpToDate. Wolters Kluwer; 2022. Accessed September 5, 2026. https://www.uptodate.com/contents/vascular-rings-and-slings
setting: are we there yet? Prenat Diagn. 2023;43(5):620-628. doi:10.1002/pd.6291

64

© Copyright. Society of Diagnostic Medical Sonography. All Rights Reserved.

Refenced Works

13. Raimundo EC, Guedes MDS, Pereira MFP, et al. Anomalies and anatomical variants of the aortic arch and origin of the neck vessels. Electronic Presentation Online System, European Congress of Radiology; 2019. Poster C-1656. doi:10.26044/ecr2019/C-1656
14. Rembouskos G, Volpe P. Aberrant right subclavian artery. VISUOG website. Published July 2014. Accessed September 5, 2026. https://www.isuog.org/education/visuog/obstetrics/heart/abnormal-3-vessels-view/aberrant-right-subclavian-artery.html
15. Volpe P, Fanelli T, De Robertis V. Right aortic arch. VISUOG website. Published October 2018. Accessed September 5, 2026. https://www.isuog.org/education/visuog/obstetrics/heart/abnormal-3-vessels-view/right-aortic-arch.html
16. Bhimji S. Right aortic arch with mirror-image branching and retroesophageal ligamentum arteriosum [illustration]. In: StatPearls [Internet]. Treasure Island, FL: StatPearls Publishing; 2026. Accessed September 5, 2026. nih.gov
17. Bronshtein M, Zimmer EZ, Blazer S, Blumenfeld Z. Right ductus arteriosus: facts and theory. Eur J Obstet Gynecol Reprod Biol. 2011;159(2):282-288. doi:10.1016/j.ejogrb.2011.07.047
18. Li X, Jiamin L, Junmei W. Cases of ultrasound-diagnosed right aortic arch with right arterial duct and the treatment. Comput Math Methods Med. 2022;2022:1-4. doi:10.1155/2022/8252808
19. Jadhav M, Makam A, Pancholi A. Double aortic arch. VISUOG website. Published September 2022. Accessed September 5, 2026. https://www.isuog.org/education/visuog/obstetrics/heart/abnormal-3-vessels-view/double-aortic-arch.html
20. Tarmahomed A, Umapathi KK. Double aortic arch. In: StatPearls. StatPearls Publishing; Updated August 8, 2023. Accessed September 5, 2026. https://www.ncbi.nlm.nih.gov/books/NBK558934/
21. Margarint IM, Youssef T, Robu M, et al. The management of aortic coarctation associated with hypoplastic arches and particular arch anatomies: a literature review. J Pers Med. 2024;14(7):732. Published July 6, 2024. doi:10.3390/jpm14070732
22. Volpe P, Pilu G. Interrupted aortic arch. VISUOG website. Published June 17, 2014. Accessed September 5, 2026. https://www.isuog.org/education/visuog/obstetrics/heart/abnormal-4-chamber-view/cardiac-disproportion/interrupted-aortic-arch.html
23. Prendergast CJ, Nicholson GT. Left-sided obstructive congenital heart lesions: including hypoplastic left heart. In: Encyclopedia of Cardiovascular Research and Medicine. Elsevier; 2018. doi:10.1016/B978-0-12-809657-4.64112-1
24. Channing A, Szwast A, Natarajan S, Degenhardt K, Tian Z, Rychik J. Maternal hyperoxygenation improves left heart filling in fetuses with atrial septal aneurysm causing impediment to left ventricular inflow. Ultrasound Obstet Gynecol. 2015;45(6):664-669. doi:10.1002/uog.14688
25. Zwanenburg F, Ten Harkel ADJ, Snoep MC, et al. Prenatal detection of aortic coarctation in a well-organized screening setting: are we there yet? Prenat Diagn. 2023;43(5):620-628. doi:10.1002/pd.6291

© Copyright. Society of Diagnostic Medical Sonography. All Rights Reserved.