2026 SDMS Annual Conference

SDMS ANNUAL CONFERENCE · 2026

The Hidden Hernia

Diagnostic Imaging for Core Muscle Injuries

Colin Rigney, PT, DPT, RMSK
CEO-Co-Founder · Advanced MSK Ultrasound Center

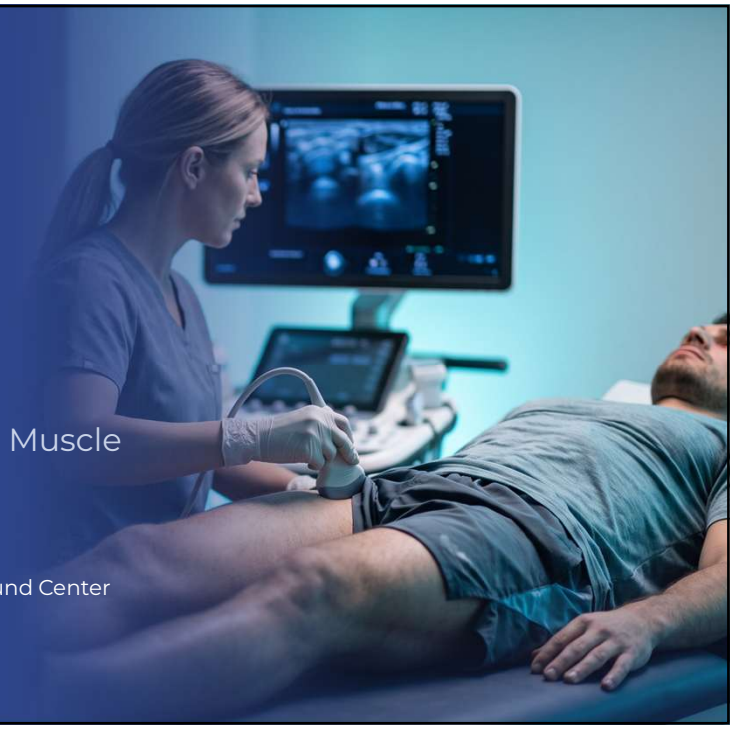

1

SPEAKER PRESENTATION DISCLAIMER

The content and views presented are made available for educational purposes only. The information presented are the opinions of the presenter and do not necessarily represent the views of the Society of Diagnostic Medical Sonography (SDMS) or its affiliated organizations, officers, Boards of Directors, or staff members.

The presenter is responsible for ensuring balance, independence, objectivity, scientific rigor, and avoiding commercial bias in their presentation. Before making the presentation, the presenter is required to disclose to the audience any relevant financial interests or relationships with manufacturers or providers of medical products, services, technologies, and programs.

The SDMS and its affiliated organizations, officers, Board of Directors, and staff members disclaim any and all liability for all claims that may arise out of the use of this educational activity.

2

© Copyright. Society of Diagnostic Medical Sonography. All Rights Reserved.

RESEARCH DISCLAIMER

The information presented in this presentation is based on research conducted to the best of the presenters' abilities and knowledge. Research involves uncertainty and is subject to limitations. The findings and conclusions presented herein may be influenced by various factors including but not limited to data quality, methodology, assumptions, and interpretation.

Research outcomes may not always accurately predict real-world scenarios or future events. While the presenter may make efforts to ensure the accuracy and reliability of the information presented, completeness or absolute correctness is not guaranteed. This presentation is intended for informational purposes only and should not be construed as professional advice. Participants are encouraged to independently verify any information provided and consult relevant experts or professionals where appropriate.

The SDMS and its affiliated organizations, officers, Board of Directors, and staff members disclaim any and all liability for all claims that may arise out of the use of this educational activity.

3

GENERATIVE AI DISCLAIMER

The presenter utilized the use of large language models (LLMs) and generative artificial intelligence (AI) as a productivity tool to assist in drafting and refining content in this presentation.

While these tools can aid in structuring ideas, summarizing, paraphrasing, and language polishing, they have inherent limitations and cannot replace human creativity, critical thinking, or expert judgment. AI-generated content may contain errors, biases, or gaps in knowledge.

This presentation is intended for informational purposes only and should not be construed as definitive or authoritative guidance. Participants are encouraged to critically evaluate the information presented and consult relevant experts as needed. The SDMS and its affiliated organizations, officers, Board of Directors, and staff members disclaim any and all liability for claims that may arise from the use or interpretation of this educational material.

4

© Copyright. Society of Diagnostic Medical Sonography. All Rights Reserved.

ABOUT THE PRESENTER

Colin Rigney, PT, DPT, RMSK

- Co-Founder, Advanced MSK Ultrasound Center
- Professor Radiology and Imaging A.T. Still University (Mesa, AZ)
- Registered in Musculoskeletal Sonography (RMSK)
- Focus: point-of-care MSK ultrasound for diagnosis and dynamic evaluation
- Clinical instructor in sports and orthopedic ultrasound

ADVANCED MSK ULTRASOUND CENTER



5

5

ROADMAP

What We'll Cover

1. **What the hidden hernia is**
   Athletic pubalgia / core muscle injury
2. **Clinical presentation**
   History, mechanism, differential diagnosis
3. **Why musculoskeletal ultrasound**
   Portable, dynamic, high-resolution
4. **A structured scan protocol**
   Six regions, one systematic sweep
5. **Normal vs pathologic findings**
   What the transducer reveals
6. **Clinical takeaways**
   Bringing it back to the patient

6

6

© Copyright. Society of Diagnostic Medical Sonography. All Rights Reserved.

DEFINITION

What Is the Hidden Hernia?

A painful soft-tissue injury of the groin, provoked by explosive twisting and change of direction.

Because a true hernia often does not exist, the injury is best called athletic pubalgia, a core muscle injury.

Most commonly involves the rectus abdominis, adductor longus, and the fascia they share at the pubis.



7

7

ANATOMY

The Tissues Involved

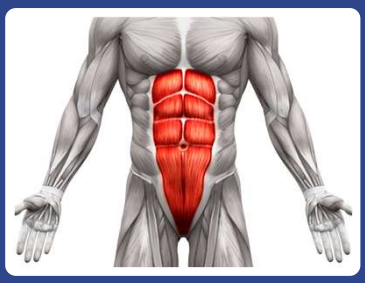

Rectus Abdominis



External Oblique

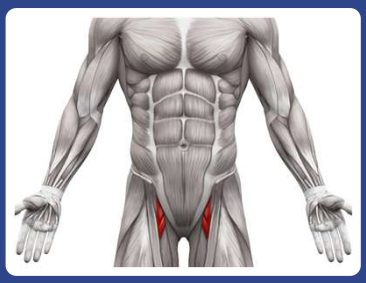

Adductor Longus

8

8

© Copyright. Society of Diagnostic Medical Sonography. All Rights Reserved.

PRESENTATION

Symptomatology: History & Mechanism

- A thorough history is the key to diagnosis.
- Injury mechanism is highly variable.
- Occurs in athletes who repetitively load three planes of movement explosively.
  - Lunging, running, pivoting, cutting
- Diffuse pain in the lower abdomen, superior to the inguinal ring, frequently with no palpable bulge.

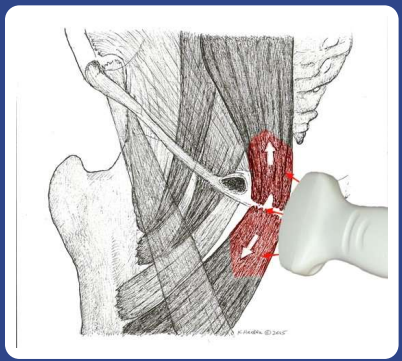

9

9

EPIDEMIOLOGY

Who It Affects

- Occurs in a small, highly athletic subset of patients.
- High kinesthetic awareness and explosive demands.
- Historically described more often in male athletes; reported in roughly 5-15% of female athletes.
- Symptoms often ease with rest but return immediately on return to sport.

5-15%

of athletic pubalgia cases are reported in female athletes

10

10

© Copyright. Society of Diagnostic Medical Sonography. All Rights Reserved.

CLINICAL PRESENTATION

How It Shows Up

- Groin pain most commonly develops insidiously, but may present acutely with a sudden tearing sensation.
- Pain during exercise over the distal rectus abdominis and inguinal region, sometimes radiating to the perineum or testicles.
- On exam: pain with resisted hip adduction and/or a resisted partial crunch; local tenderness at the tendinous attachments.
- The Valsalva maneuver often does not reproduce the primary symptoms.

Omar IM, Zoga AC, Kavanagh EC, et al. RadioGraphics. 2008;28(5):1415-1438.

11

11

PHYSICAL EXAM

Clinical Signs on Examination

- Patients often present after months of vague, deep groin or lower-abdominal pain, usually unilateral and suprainguinal.
- Pain is exacerbated by sprinting, cutting, and sit-ups, and relieved with rest.
- Palpable tenderness over the pubic ramus at the rectus abdominis / conjoint tendon insertion.
- Pain with resisted hip adduction at 0°, 45°, and 90° of hip flexion, and with a resisted abdominal curl-up.

Ellsworth AA, Zoland MP, Tyler TF. Int J Sports Phys Ther. 2014;9(6):774-784.

12

12

© Copyright. Society of Diagnostic Medical Sonography. All Rights Reserved.

DIFFERENTIAL DIAGNOSIS

MSK Origins to Consider

1. **Pubic Symphysis-Osteitis pubis**
2. **Femoral-acetabular labral tear**
3. **Inguinal hernia (direct vs. indirect)**
4. **Isolated adductor tendinopathy vs. tear**

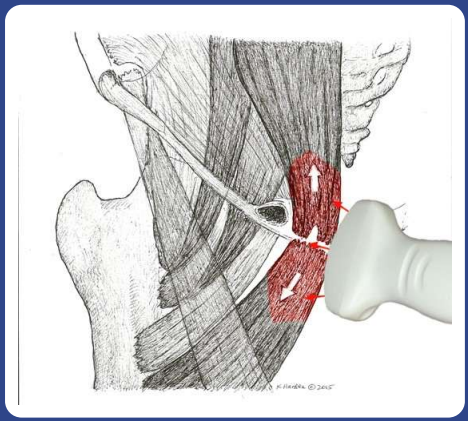

13

13

RATIONALE

Why Musculoskeletal Ultrasound?

ADVANTAGES

- Portable and point-of-care
- Low cost (~1/10 of MRI)
- High soft-tissue and tendon resolution
- Dynamic: images contraction and movement

LIMITATIONS

- Operator dependent (the key limiting factor)
- Poor intra-articular window due to bony acoustic impedance

14

14

© Copyright. Society of Diagnostic Medical Sonography. All Rights Reserved.

SYSTEMATIC APPROACH

The Six-Point Scan Protocol

1. **Femoral-acetabular structures**
   Iliopsoas, joint capsule, labrum
2. **Rectus femoris origin**
3. **Pubic symphysis**
4. **Inguinal hernia**
5. **Conjoint tendon**
   Rectus abdominis + adductor longus
6. **Rectus abdominis / oblique fascia**

15

15

SCAN PROTOCOL · 1 OF 6

Femoral-Acetabular Structures



Personal Archive: Colin Rigney

16

16

© Copyright. Society of Diagnostic Medical Sonography. All Rights Reserved.

SCAN PROTOCOL · 2 OF 6

Rectus Femoris Origin

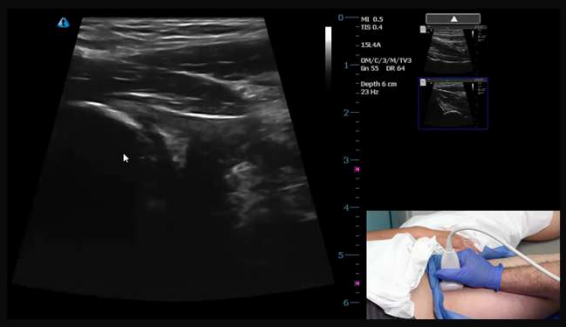

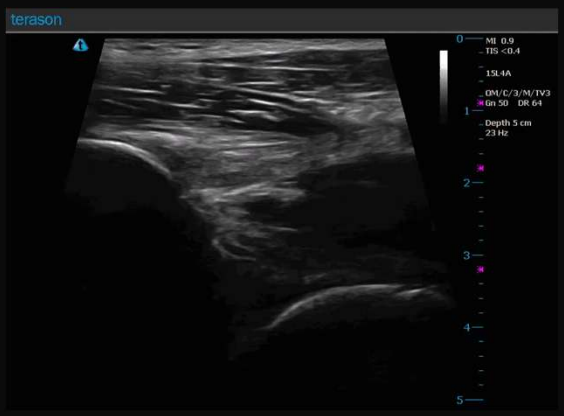

17

17

SCAN PROTOCOL · 3 OF 6

Pubic Symphysis



Osteitis pubis is best confirmed on radiograph/MRI; ultrasound helps by excluding conjoint-tendon and adductor pathology.

18

18

© Copyright. Society of Diagnostic Medical Sonography. All Rights Reserved.

SCAN PROTOCOL · 4 OF 6

Inguinal Hernia



Personal Archive: Colin Rigney

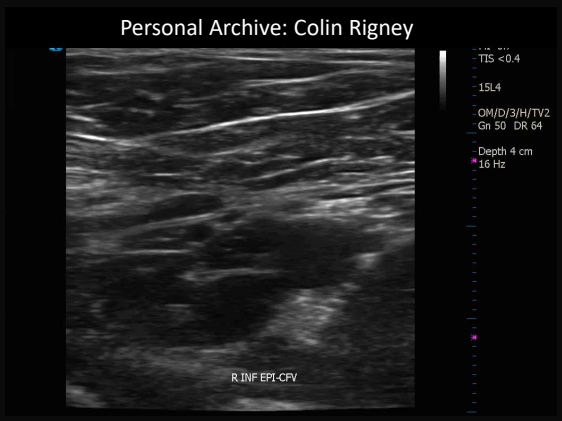

Personal Archive: Colin Rigney

19

19

SCAN PROTOCOL · 5 OF 6

Conjoint Tendon: Long Axis (Normal)

Personal Archive: Colin Rigney



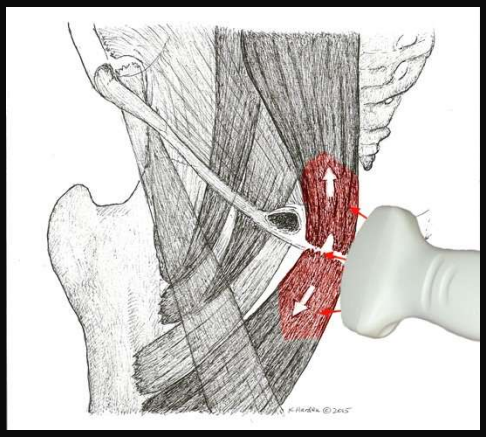

20

20

© Copyright. Society of Diagnostic Medical Sonography. All Rights Reserved.

SCAN PROTOCOL · 5 OF 6 (CONT.)

Conjoint Tendon: Abnormal Cortical Surface



Personal Archive: Colin Rigney



Personal Archive: Colin Rigney

21

21

SCAN PROTOCOL · 5 OF 6 (CONT.)

Conjoint Tendon: Thickening & Chronic Disruption



Personal Archive: Colin Rigney

22

22

© Copyright. Society of Diagnostic Medical Sonography. All Rights Reserved.

SCAN PROTOCOL · ADDUCTOR COMPLEX

Adductor Muscle Group: Probe Positions



23

23

SCAN PROTOCOL · ADDUCTOR COMPLEX

Adductor Muscle Group: Long Axis



24

24

© Copyright. Society of Diagnostic Medical Sonography. All Rights Reserved.

SCAN PROTOCOL · ADDUCTOR COMPLEX

Adductor Longus Tendinopathy





25

25

SCAN PROTOCOL · Adductor Complex

Adductor Longus Origin: Chronic Disruption



22

26

© Copyright. Society of Diagnostic Medical Sonography. All Rights Reserved.

SCAN PROTOCOL · ADDUCTOR COMPLEX

Adductor Brevis: Chronic Tendinopathy



26

27

SCAN PROTOCOL · 6 OF 6

Rectus Abdominis / External Oblique (Normal)



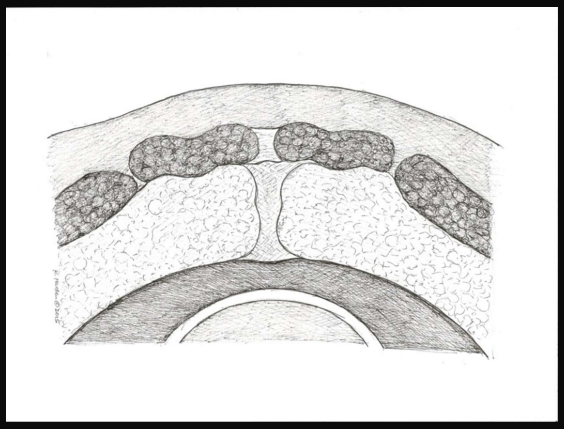

27

28

© Copyright. Society of Diagnostic Medical Sonography. All Rights Reserved.

SCAN PROTOCOL · 6 OF 6 (CONT.)

Rectus Abdominis / Oblique: Normal vs. Abnormal





28

29

SCAN PROTOCOL · 6 OF 6 (CONT.)

Rectus Abdominis / Oblique: Abnormal Fascial Disruption

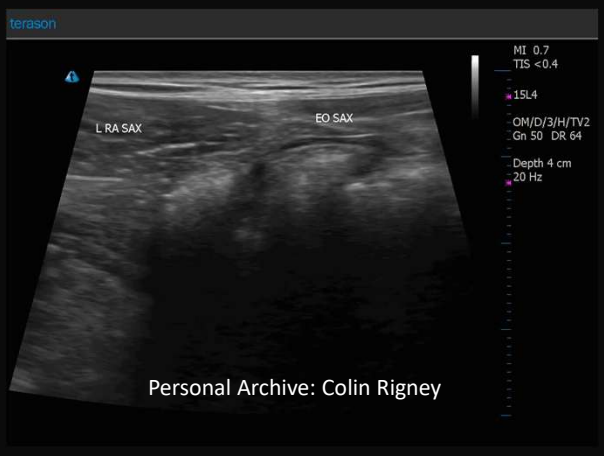

29

30

© Copyright. Society of Diagnostic Medical Sonography. All Rights Reserved.

CLINICAL BOTTOM LINE

Takeaways

1. Chronic athletic groin pain with a lower-abdominal / supra-inguinal component located well lateral to the midline.
2. Provoked by contraction of the lower-quadrant abdominals, adductors, and rectus abdominis, and the fascia they share.
3. Most cases involve BOTH the conjoint tendon AND lower-quadrant abdominal musculature, reflecting acquired pubic instability from repetitive strain.

SOURCES

References

Omar IM, Zoga AC, Kavanagh EC, et al. Athletic Pubalgia and "Sports Hernia": Optimal MR Imaging Technique and Findings. RadioGraphics. 2008;28(5):1415-1438.

Ellsworth AA, Zoland MP, Tyler TF. Athletic pubalgia and associated rehabilitation. Int J Sports Phys Ther. 2014;9(6):774-784.

American Academy of Orthopaedic Surgeons (AAOS). Sports Hernia (Athletic Pubalgia). OrthoInfo.

© Copyright. Society of Diagnostic Medical Sonography. All Rights Reserved.



33

© Copyright. Society of Diagnostic Medical Sonography. All Rights Reserved.