That Scar Needs Attention

Debra L. Krukowski BS, RDMS
Advocate Medical Group OB

1

SPEAKER PRESENTATION DISCLAIMER

The content and views presented are made available for educational purposes only. The information presented are the opinions of the presenter and do not necessarily represent the views of the Society of Diagnostic Medical Sonography (SDMS) or its affiliated organizations, officers, Boards of Directors, or staff members.

The presenter is responsible for ensuring balance, independence, objectivity, scientific rigor, and avoiding commercial bias in their presentation. Before making the presentation, the presenter is required to disclose to the audience any relevant financial interests or relationships with manufacturers or providers of medical products, services, technologies, and programs.

The SDMS and its affiliated organizations, officers, Board of Directors, and staff members disclaim any and all liability for all claims that may arise out of the use of this educational activity.

2

© Copyright. Society of Diagnostic Medical Sonography. All Rights Reserved.

RESEARCH DISCLAIMER

The information presented in this presentation is based on research conducted to the best of the presenters' abilities and knowledge. Research involves uncertainty and is subject to limitations. The findings and conclusions presented herein may be influenced by various factors including but not limited to data quality, methodology, assumptions, and interpretation.

Research outcomes may not always accurately predict real-world scenarios or future events. While the presenter may make efforts to ensure the accuracy and reliability of the information presented, completeness or absolute correctness is not guaranteed. This presentation is intended for informational purposes only and should not be construed as professional advice. Participants are encouraged to independently verify any information provided and consult relevant experts or professionals where appropriate.

The SDMS and its affiliated organizations, officers, Board of Directors, and staff members disclaim any and all liability for all claims that may arise out of the use of this educational activity.

3

GENERATIVE AI DISCLAIMER

The presenter utilized the use of large language models (LLMs) and generative artificial intelligence (AI) as a productivity tool to assist in drafting and refining content in this presentation.

While these tools can aid in structuring ideas, summarizing, paraphrasing, and language polishing, they have inherent limitations and cannot replace human creativity, critical thinking, or expert judgment. AI-generated content may contain errors, biases, or gaps in knowledge.

This presentation is intended for informational purposes only and should not be construed as definitive or authoritative guidance. Participants are encouraged to critically evaluate the information presented and consult relevant experts as needed. The SDMS and its affiliated organizations, officers, Board of Directors, and staff members disclaim any and all liability for claims that may arise from the use or interpretation of this educational material.

4

© Copyright. Society of Diagnostic Medical Sonography. All Rights Reserved.

GOAL

This presentation will discuss the role of ultrasound in evaluation of the Cesarean Section Scar, and the pathology and complications that may arise in patients with that scar .

5

OBJECTIVES

1. List the role of the sonographer in evaluation of a C Section scar.
2. List and describe the Gyne Complications in patients with history of a C Section scar.
3. List and describe the Obstetric complications that may arise in patients with a history of a S Section scar.
4. Evaluate Case Studies related to a patient with the history of a C Section.

6

© Copyright. Society of Diagnostic Medical Sonography. All Rights Reserved.

The Role of Ultrasound

- Sonographers must obtain a proper history in patients prior to starting a scan.
- Sonographers must no just scan to the patient's symptoms but evaluate the patient fully.
- A history of cesarean section with previous pregnancy should be noted and the sonographer must be aware to evaluate that region.

7

Address the Patient History

- Documentation of the images is necessary for the reading doctor.
- Sonographers role is to describe what they see not diagnose.

Patient Age

Pregnancy History

Gravida

Para

00000

Spontaneous

Vaginal or C Section

8

© Copyright. Society of Diagnostic Medical Sonography. All Rights Reserved.

Identification of the Scar

If we see it, we should comment on it?

Should we comment that we don't see it, if history is present?

Why is it necessary?

9

- To add additional slides, right click on the current slide and select "duplicate slide". This action will carry over all formatting.

10

© Copyright. Society of Diagnostic Medical Sonography. All Rights Reserved.

Does a C Section affect fertility

- Having a prior cesarean-section can lead to fertility troubles
- Caused by a "niche," a small unhealed pouch in the uterine scar tissue.
- Often referred to as an isthmocele
- This niche can trap fluid and blood, creating chronic inflammation that makes it harder for an embryo to implant.
- Also if blood and debris caught in scar defect can make environment toxic

11

How Long is Ideal to Wait Till Next Pregnancy

- Most doctors recommend waiting at least 12 to 18 months before the next pregnancy
- This gives the uterine scar adequate time to heal and regain strength
- Shorter gaps, under 6 months, are linked to a higher risk of uterine rupture and other complications
- The exact recommended gap can vary based on the individual's healing and any complications from the previous surgery

12

© Copyright. Society of Diagnostic Medical Sonography. All Rights Reserved.

Risks associated with History of C Sections with future with future pregnancy

What are Risks Once pregnancy Occurs

- Miscarriage due to poor implantation
- Placenta Abruption
- The primary concern is uterine scar rupture, as the scar from the previous C-section may become weak and, in rare cases, rupture during labor or pregnancy.
- Placenta accreta or previa, where the placenta may attach too low or too deeply in the scarred uterine wall, putting the mother at higher risk of bleeding
- Increased risk of having another caesarean section (C-section); however, if conditions are right, many women can have a vaginal birth after caesarean (VBAC)
- Ectopic pregnancy, although very rare, may embed itself into the C-section scar. Hence, early detection is

13

Let's start with identification of C Section Scar

- Once the position of the uterus is documented look at anterior surface
- Try and identify scan on patient as you begin to scan
- Is there mor that one scar?.
- Remember if uterus position has changed the scar may be noted posteriorly.

14

© Copyright. Society of Diagnostic Medical Sonography. All Rights Reserved.

Isthmocele

- An Isthmocele also referred to as a C Section Defect
- Small pouch or indentation that forms the front of the wall of the uterus at the site of the incision.
- Occurs when the incision fails to heal completely or incorrectly
- Leaves a niche where menstration blood secretions or mucous can get trapped

15

Patient Signs and Symptoms of an Isthmocele

- Asymptomatic
  Could be found incidentally
- Irregular Bleeding
- Dysmenorrhea
- Persistent brown spotting following menses
- Dyspareunia
- Pain cramping
- Urinary pressure and complications
- IUD complications
  Insertion difficulty
  Malposition of the IUD
- Fluid accumulation within cavity
- Severe Complication: Uterus perforation?/

16

© Copyright. Society of Diagnostic Medical Sonography. All Rights Reserved.

Complications of Isthmocele

- Seconday Infertility
  Trouble conceiving or implanting an embryo
- Irregular Menses
- Dysmenorrhea
- Dyspareunia

- We will get to OB later……

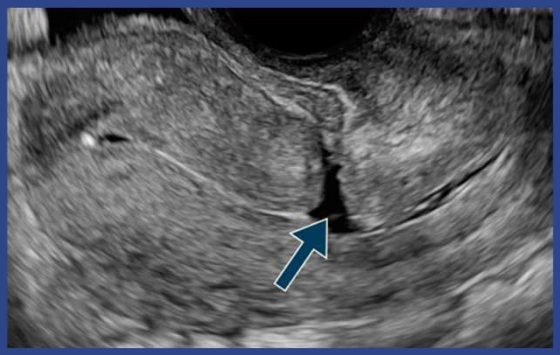

17

Diagnosis and Evaluation of an Isthmocele

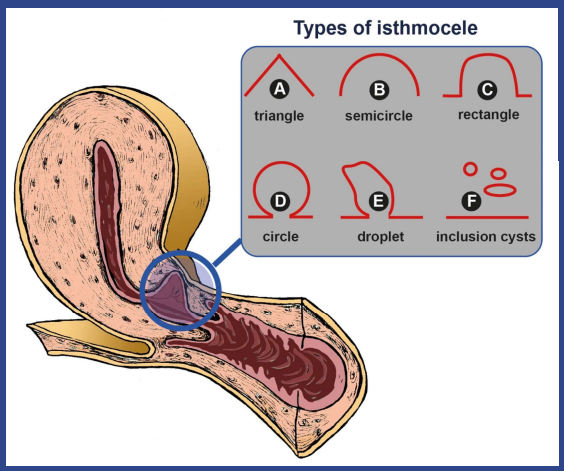

- Transvaginal Ultrasound
- Sonohysterogram
- Hysteroscopy

Shape, Depth and Length should be evaluated

18

© Copyright. Society of Diagnostic Medical Sonography. All Rights Reserved.

Diagnosis and Evaluation

- Transvaginal Ultrasound
  Often 1st step is evaluation
  Non-Invasive
  Lowest Cost

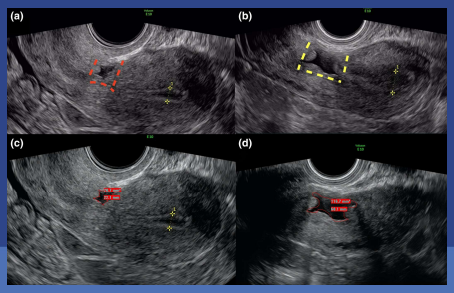

- Sonohysterogram
  Saline Infusion
  Fills the endometrial cavity with fluid to evaluation lining and cavity
  This will help to evaluate the depth and size of the defect

19

Evaluate region from endometrial canal to serosal layer



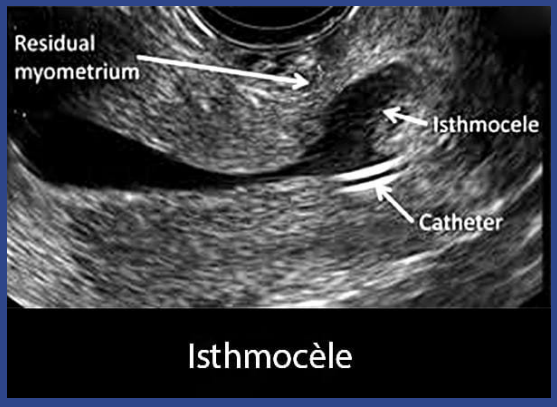

20

© Copyright. Society of Diagnostic Medical Sonography. All Rights Reserved.

2026 SDMS Annual Conference

D1 distance between inner cervical os and intact scar. Dotted line from IO to surface of anterior cervical lip perpendicular to cx canal. Showing thickness of myometrium and then distance from top of lne to top of sca

D2 distance between inner cx os an defect scar . Length and geight of de thickness of remaining myometrium defect ® and thickness of myometriu (m) closer to fundal porotion of defe

Ten ratio calculated

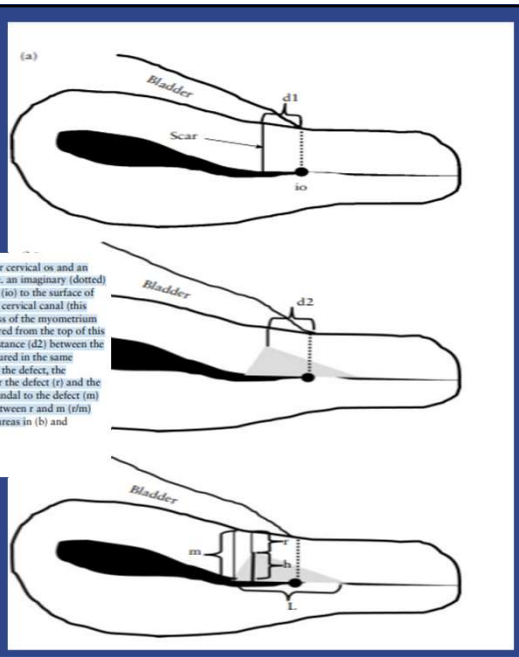

Figure 2 The distance (d1) between the inner cervical os and an intact scar was measured as shown in (a), i.e. an imaginary (dotted) line was drawn from the internal cervical os (io) to the surface of the anterior cervical lip perpendicular to the cervical canal (this imaginary dotted line represents the thickness of the myometrium in the isthmus), and the distance was measured from the top of this imaginary line to the top of the scar. The distance (d2) between the inner cervical os and a defect scar was measured in the same manner (b). The length (L) and height (h) of the defect, the thickness of the remaining myometrium over the defect (r) and the thickness of the myometrium close to and fundal to the defect (m) were measured as shown in (c). The ratio between r and m (r/m) was calculated. The gray shaded triangular areas in (b) and (c) represent a scar defect.

RESULTS

Ultrasound Obstet Gynecol 2009; **34**: 90–97
Published online 4 June 2009 in Wiley InterScience (www.interscience.wiley.com). **DOI:** 10.1002/uog.6395

21

Intact Scar

Small defect

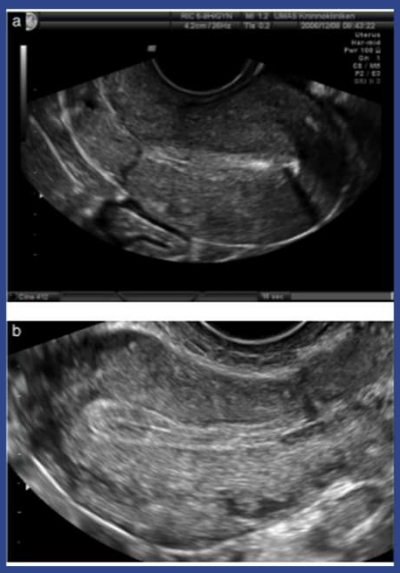



Large defect

22

© Copyright. Society of Diagnostic Medical Sonography. All Rights Reserved.

What is an Isthmoplasty

Isthmocele Repair

- Hysteroscope
- Laporatomy
- Adhesiolysis

https://esse.care/isthmoplasty-isthmocele-repair-what-it-is-and-what-to-expect/

23

Isthmocele Repair

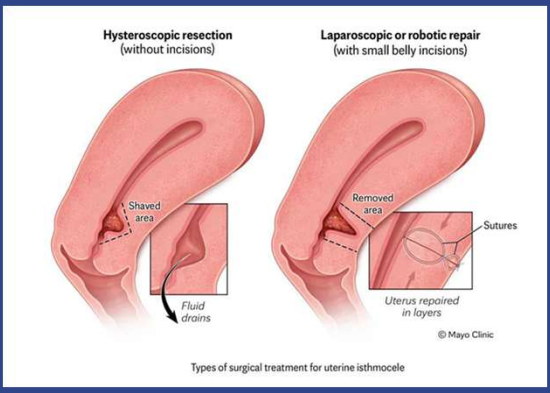

Types of surgical treatment for uterine isthmocele

Hysteroscopic Resection
Without Incisions

Laparoscopic or robotic repair
Small abdominal (periumbilical) incisions

24

© Copyright. Society of Diagnostic Medical Sonography. All Rights Reserved.

Hysteroscopy

- A thin camera is inserted through the vagina and cervix.
- Evaliate the size, shape, and depth of the defect from inside the uterine cavity.
- Small niches can be treated with this method alone, meaning no abdominal incisions are required.
- Risk of creating a deeper defect

25

Laposcopic or Robotic-Assisted Resection and closure

For larger or deeper defects, laparoscopy or robotic assistance utilized to excise the niche and perform a full-thickness, multi-layered uterine wall repair, restoring muscular integrity and support.

- Adhesiolysis

✓Scar tissue & entire isthmocele site is first removed to ensure normal healthy uterine tissue is left behind.

✓ To for a strong repair with healthy tissue all the scarring is removed first.

✓Any adhesions involving the uterus, bladder, or surrounding structures removed to improve pelvic anatomy and reduce pain or distortion from prior surgeries or endometriosis.

26

© Copyright. Society of Diagnostic Medical Sonography. All Rights Reserved.

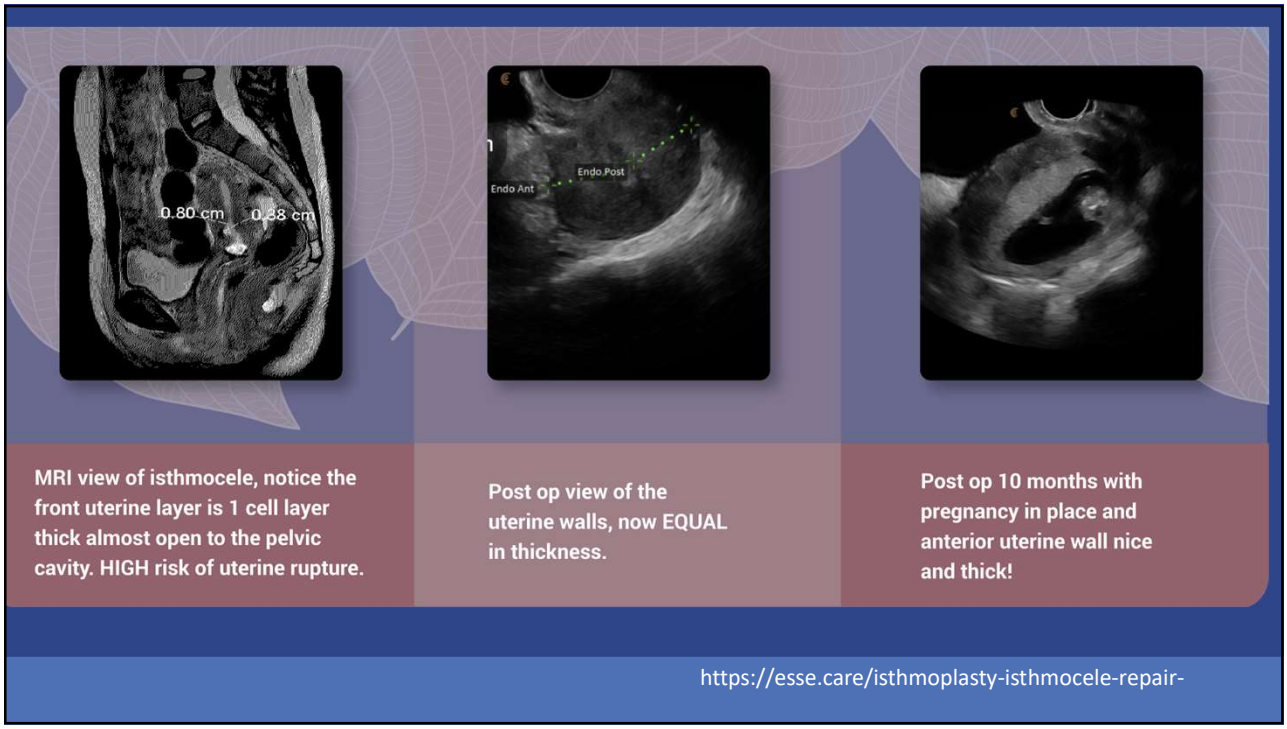

27

How big is the window?

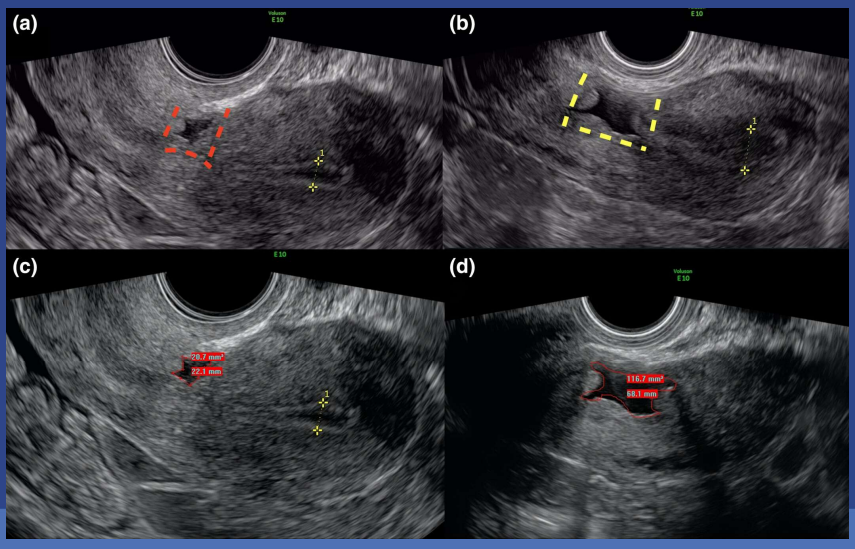

28

© Copyright. Society of Diagnostic Medical Sonography. All Rights Reserved.

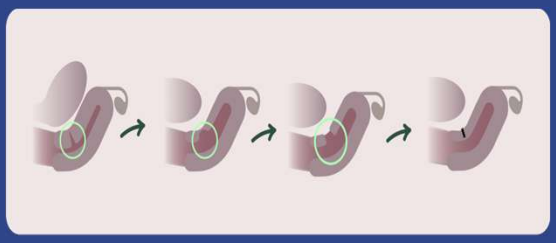

- 70% of women with cesarean sections will develop an Isthmocele
- Exact percentage unknow, many are found incidentally

29

How Do We Measure

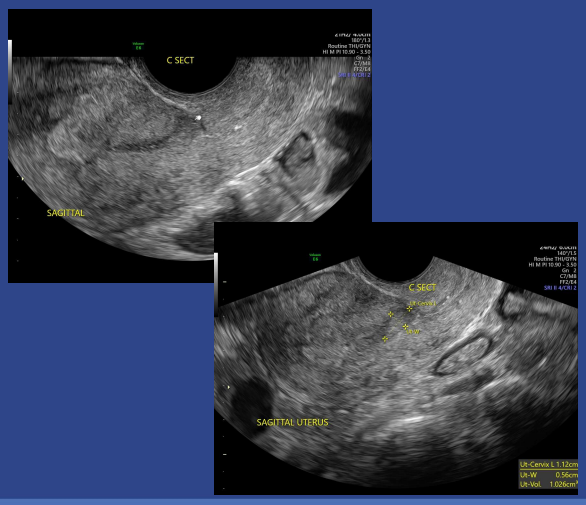

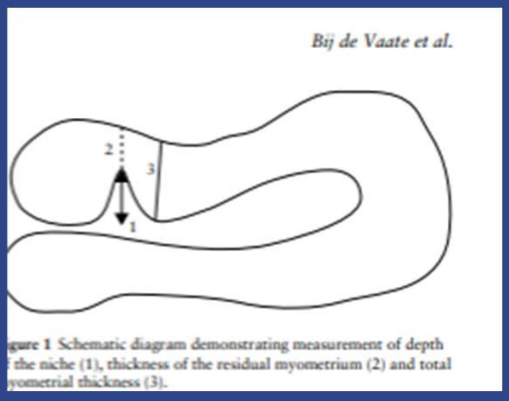

gure 1 Schematic diagram demonstrating measurement of depth
the niche (1), thickness of the residual myometrium (2) and total
yometrial thickness (3).

30

© Copyright. Society of Diagnostic Medical Sonography. All Rights Reserved.

Remember uterine position where scar is located

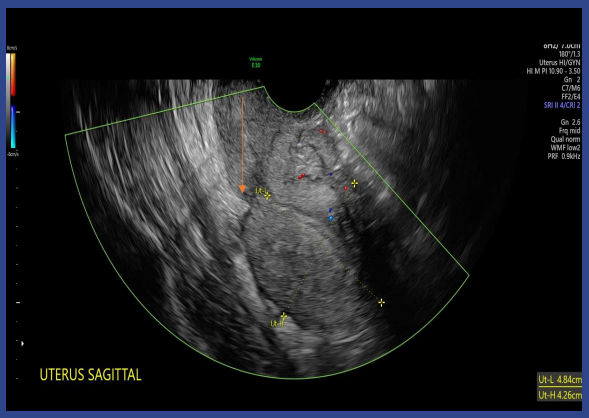

- Retroverted uterus
- Remember at term uterus isn't in this position
- Scar is noted on posterior surface of uterus.

31

Give it time and change angles

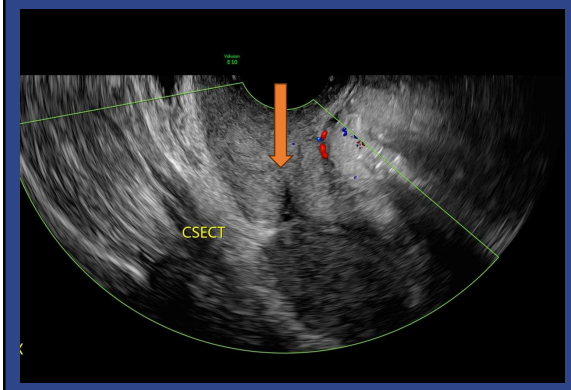

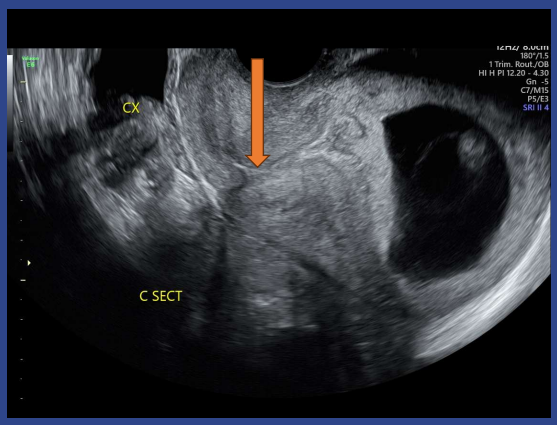

32

© Copyright. Society of Diagnostic Medical Sonography. All Rights Reserved.

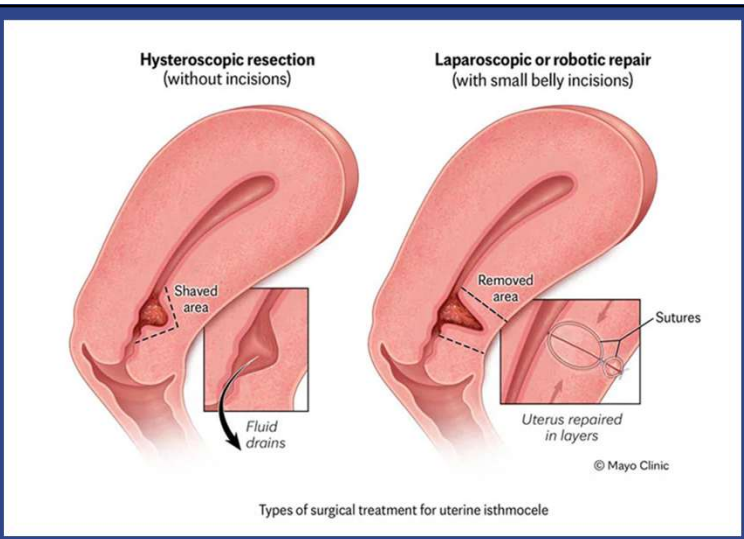

Types of surgical treatment for uterine isthmocele

33

Ectopic Pregnancy Risk and Occurrence

- Embryo attaches to the scar tissue left from a previous C-section rather than uterine wall.
- The scar tissue is weaker than the uterine wall.
- May tear and may result in hemorrhage.
- The placenta will grow in the wrong place, causing bleeding and potentially leading to a hysterectomy, damage to surrounding organs, or death of the pregnant patient.

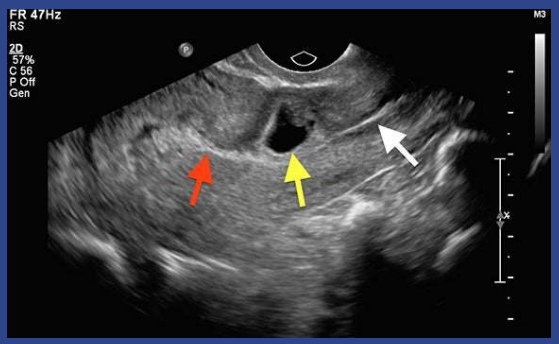

34

© Copyright. Society of Diagnostic Medical Sonography. All Rights Reserved.

Placenta Complications Post C Section

- Shot Intervals
- Abruptio
- Low implantation
- Previa
- Acreta, Increta , Percreta

35

Why does Short Interval Pregnancy Present Risks

What is a Short Interval Pregnancy

Does Risk increase the shorter the interval

36

© Copyright. Society of Diagnostic Medical Sonography. All Rights Reserved.

Implantation complications

37

Placenta Abruption

A C-section leaves a scar on the uterus.

While this scar is usually strong, it can be a site for placental attachment and, in some cases, for abnormal placental positioning or separation.

The scar tissue may also be more prone to injury during labor, which can contribute to abruption

Other risk factors

38

© Copyright. Society of Diagnostic Medical Sonography. All Rights Reserved.

Placenta Abruptio

Placental abruption can occur in about 0.7% of pregnancies overall, but risk is higher in women with:

- Prior abruption
- Smoking
- Preeclampsia
- Trauma during pregnancy
- Short interpregnancy interval
- Multiple prior C-sections

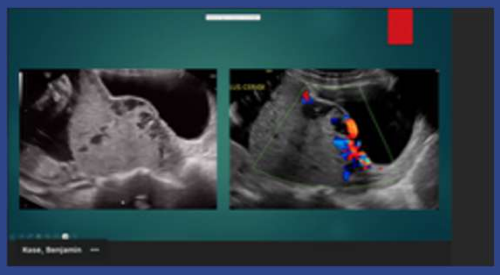

39

Placenta Acreta Spectrum

ACOG's Obstetric Care Consensus No. 7 (2018) defines placenta accreta spectrum as:

abnormal placental adherence—including accreta, increta, and percreta—and recommends antenatal diagnosis with planned delivery at a level III or IV maternal care center, typically via cesarean hysterectomy with the placenta left in situ.

40

© Copyright. Society of Diagnostic Medical Sonography. All Rights Reserved.

Placenta Acreta Spectrum

- **Etiology**
- ***PAS likely results from a defect at the endometrial–myometrial interface, often at a uterine scar, leading to failure of normal decidualization and deep trophoblast invasion.***
- **Risk Factors**
- **Previous cesarean delivery** — risk increases with number of prior cesareans.
- **Placenta previa**, especially with prior cesarean.
- AMA, multiparity, prior uterine surgery, Asherman syndrome.
- Placenta Accreta Spectrum | ACOG

- **Diagnosis**
- **Antenatal diagnosis is strongly preferred.**
- **Ultrasound** is the primary modality; findings may appear in the first trimester.
- **Color Doppler** improves detection.
- MRI may be used for complex cases.
- Absence of ultrasound findings does not exclude PAS; clinical risk factors remain critical.

41

Placenta Acreta

- Acreta – adherence of the placenta into the decidua basilis (partial or complete)

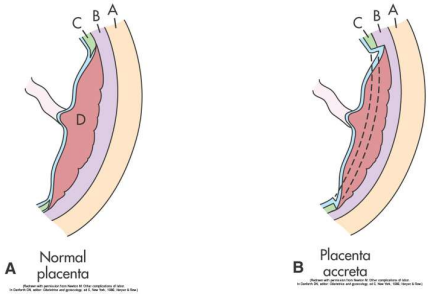

A – myometrium; B – decidua basalis; C – decidua spongiosa; D - placenta

42

© Copyright. Society of Diagnostic Medical Sonography. All Rights Reserved.

Placenta Acreta





43

Placenta Increta

- Increta – extension into the myometrium

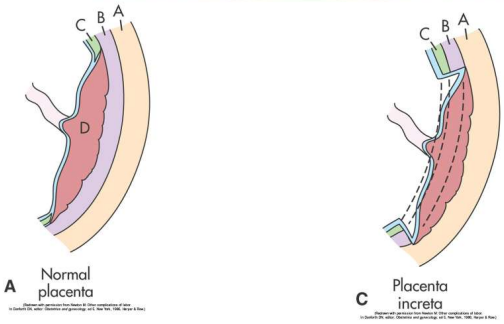

A – myometrium; B – decidua basalis; C – decidua spongiosa; D - placenta

44

© Copyright. Society of Diagnostic Medical Sonography. All Rights Reserved.

Placenta Percreta

- Percreta – extension into the uterine serosa
- Gone through the myometrium
- Most dangerous form

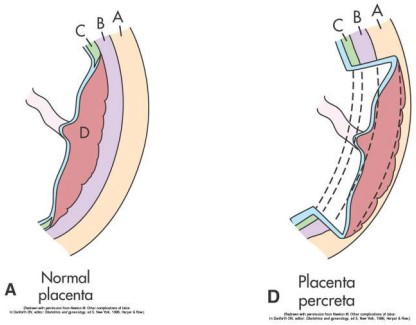

– A myometrium; B – decidua basalis; C – decidua spongiosa; D - placenta

45

Placenta Abruptio

- Pre mature placental detachment
- 2 types
- Retroplacental
- Marginal
- Clinical symptoms
- Painful vaginal bleeding
- Possible shock
- Prognosis
- Premature labor & delivery
- Fetal demise

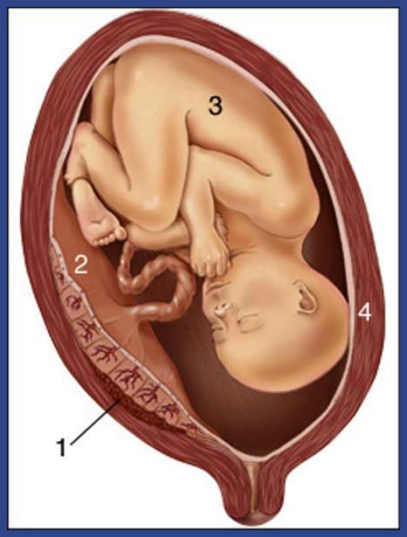

46

© Copyright. Society of Diagnostic Medical Sonography. All Rights Reserved.

Clinical Indications for Abruptio

- **C Section**
- **Isthmocele**
- Adenomyosis
- Abdominal Trauma
- GDM
- HTN
- Thrombophilia
- Fibroids
- PROM, Chorioamnionitis
- AMA
- Smoking

47

Case Study

- 33w0D Patient presented with
- Tight rigid uterus
- Painful
- No known trauma
- Prev C Section X2

- Whats the next clinical step in management?

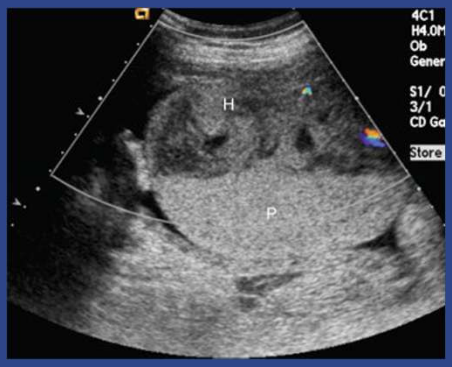

48

© Copyright. Society of Diagnostic Medical Sonography. All Rights Reserved.

Case Study #1:
SAB Feb then again April
Hx c section. Brownish discharge, and clots in menses then heavy periods.

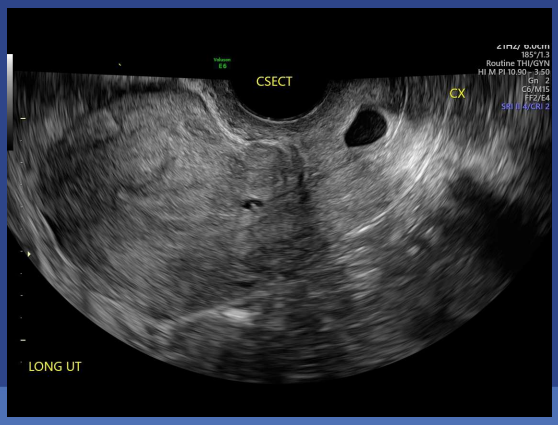

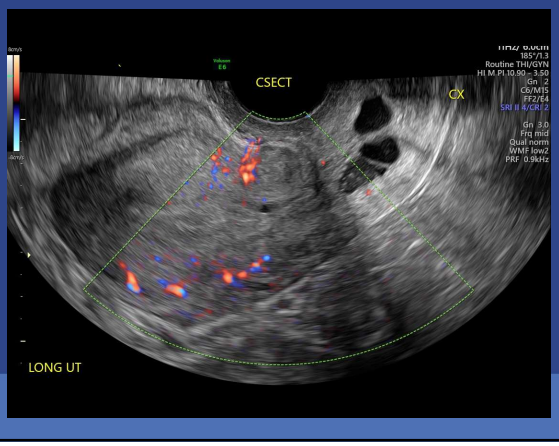

49

US Results

- Arcuate uterus w/depth of 1.23 suggesting septum
- Suggestion of Polyp
- Near Scar an echogenic buldge
- Suggesting isthmocele with debris or myometrial buldge
- Suggesting SIS
- Referred to Minimally invasive surgeon

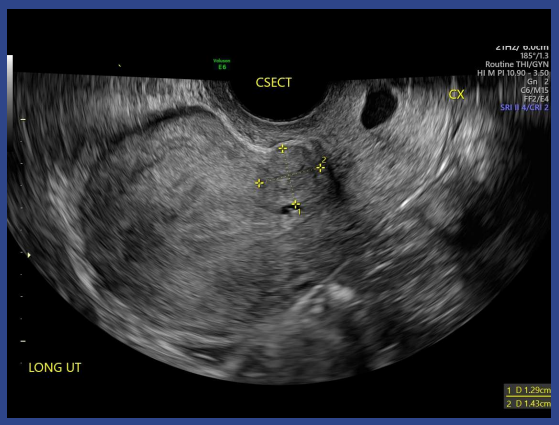

50

© Copyright. Society of Diagnostic Medical Sonography. All Rights Reserved.

35 y/o post C Section , incision pain discharge pelvic pain, patient describes similar to contrations

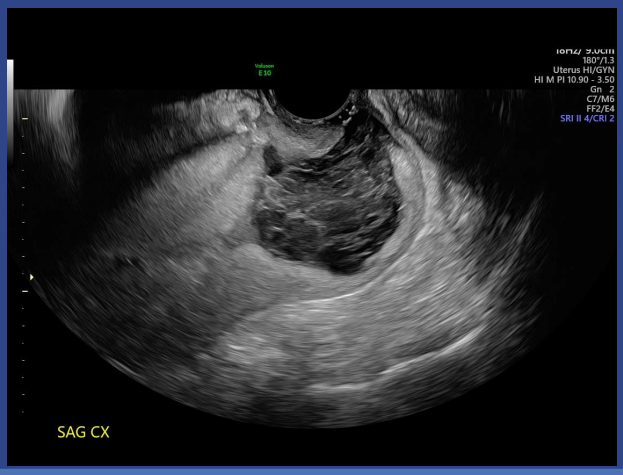

51

Disruption of would, service to wound care
Isthmocele with debris
Suggestive RPOC
Given Misoprostol

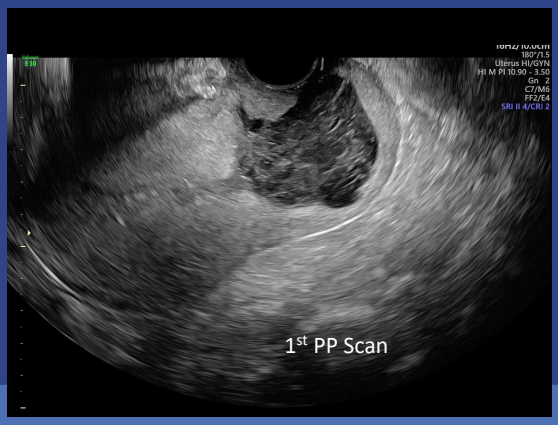



52

© Copyright. Society of Diagnostic Medical Sonography. All Rights Reserved.

Case Study #2: 35 y/o TOP and irreg bleeding. Imaging 10 days post Milaprox.

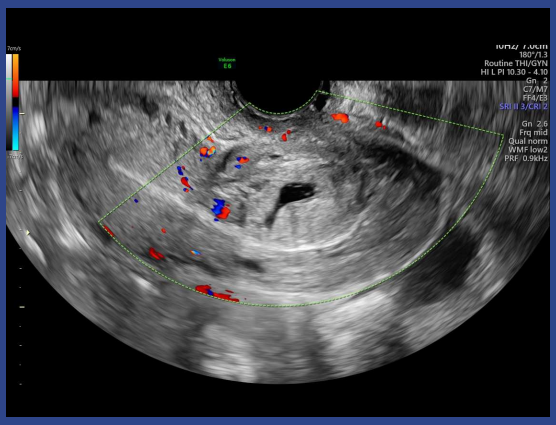

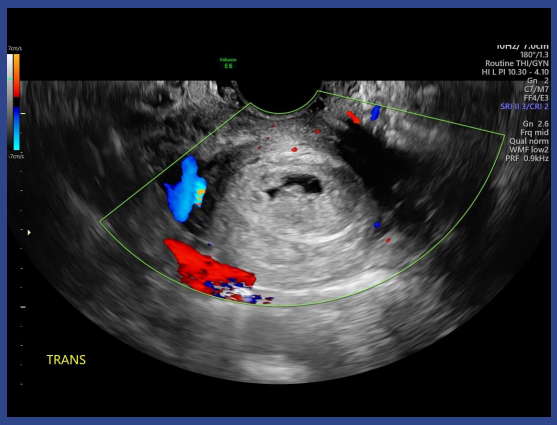

53

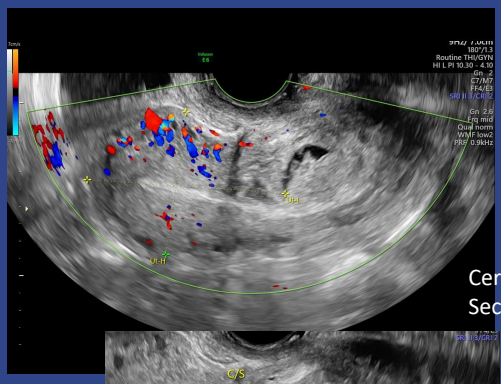

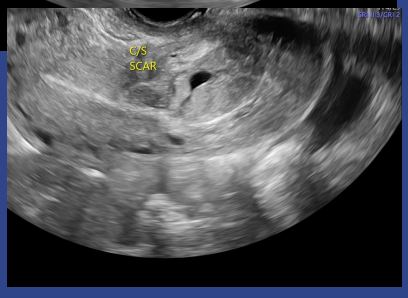

Cervical Pregnancy vs C Section Scar Pregnancy

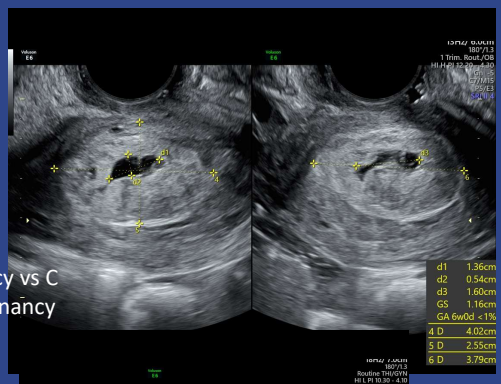

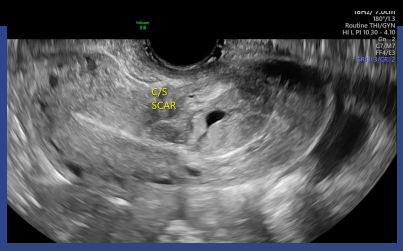

54

© Copyright. Society of Diagnostic Medical Sonography. All Rights Reserved.

Steps after two dosages

- Sent to In Patient , given a does of Methotrexate, then placed Cook Catheter.
- External Os was closed, but dilate with slight pressure
- Sac palpated within Cervix.
- Will remove catheter in 24 hours
- Balloon allowing for RPOC to excavate.
- Removed catheter patient discharged.
- 2 day post discharge passed large clot like structure
- F/U in office , bHCG, TVUS in 5 days post procedure

55

Follow up US, bHCG and exam

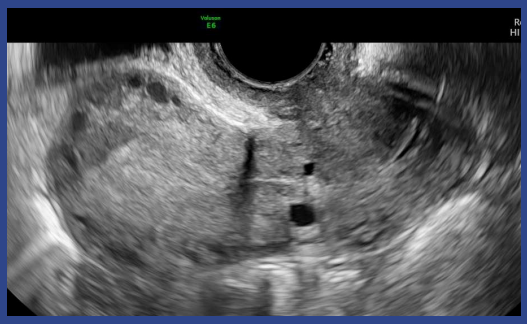

All normal.

Still unsure if implantation was in scar defect or cervix proper.

Decided to begin OBCP and questioning another pregnancy in future.

Suggestion of SIS prior to that to evaluate isthmocele

56

© Copyright. Society of Diagnostic Medical Sonography. All Rights Reserved.

Case Study #3: LAPAROSCOPY, LYSIS OF ADHESIONS, HYSTEROSCOPY, SHAVING OF ISTHMOCELE, TUBAL LAVAGE 6 months prior for (IVF preparation)

- 39 y/o 9 weeks 5 days
- History of C section
- BMI of 42
- 2025 post scar defect repair
- High risk so early TVUS



57



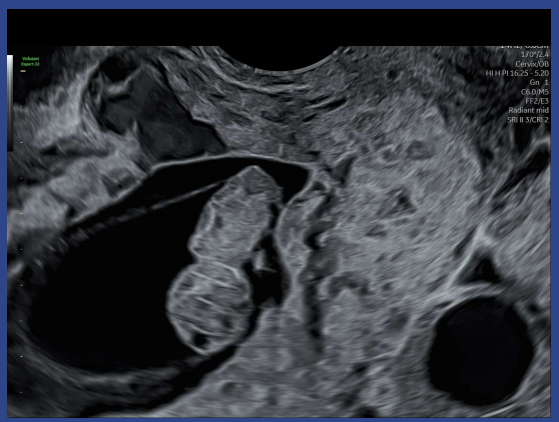

58

© Copyright. Society of Diagnostic Medical Sonography. All Rights Reserved.

MRI

- Anterior placenta completely coveing ICO.
- Invasion of placental tissue outside of myometrium
- Uterine bulging anteriorly and widening of LUS
- Heterogeneous Place
- Flow with 6mm diameter abn
- Loss of fat plane, no bladder invastion at this time

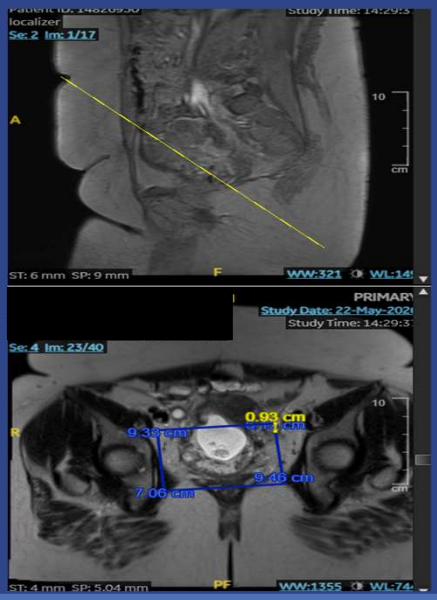

59

Final Diagnosis: Ectopic Pregnancy in C Sect Scar and placenta percreta

- PREOPERATIVE DIAGNOSIS: Placenta increta at the C-section defect (isthmocele).
-
- POSTOPERATIVE DIAGNOSIS: This is an ectopic pregnancy at the cesarean section site, essentially ready to rupture.
-

- ROBOTIC ASSISTED LAPAROSCOPY EVACUATION OF ISTHMOCELE ECTOPIC PREGANCY, LATERAL CLIPPING OF BILATERAL UTERINE ARTERIES, BILATERAL URETEROLYSIS , EXCISION OF PERCRETA, HYSTEROSCOPIC AND SUCTION EVACUATION OF THE PREGNANCY WITH UTERINE REPAIR
-
-

60

© Copyright. Society of Diagnostic Medical Sonography. All Rights Reserved.

Case Study #4

- 42 y/o AMA
- History of C Section X 2
- Complete previa
- At risk and suspicion for acreta
- No abnormal bleeding
- Referred to MFM
- Placenta Acreta
- Scheduled for C Sect with possible hysterectomy depending on what they see

61

Images

- Abnormal Vascularity noted over Lower uterine segment and bladder

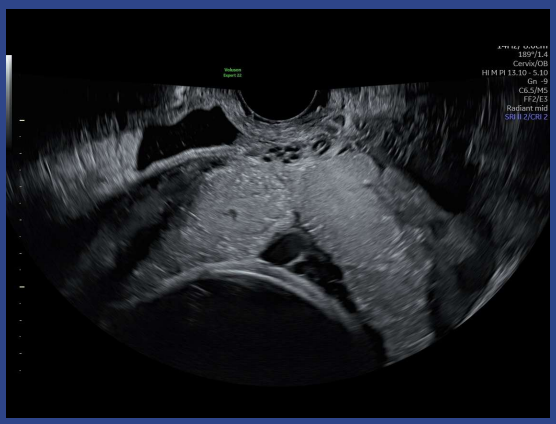

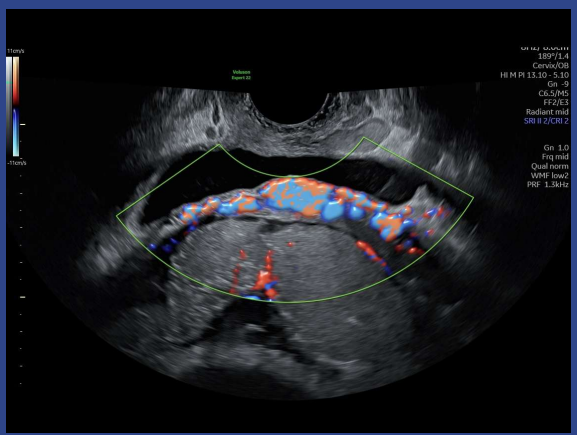

62

© Copyright. Society of Diagnostic Medical Sonography. All Rights Reserved.

Multiple views needed look for signs

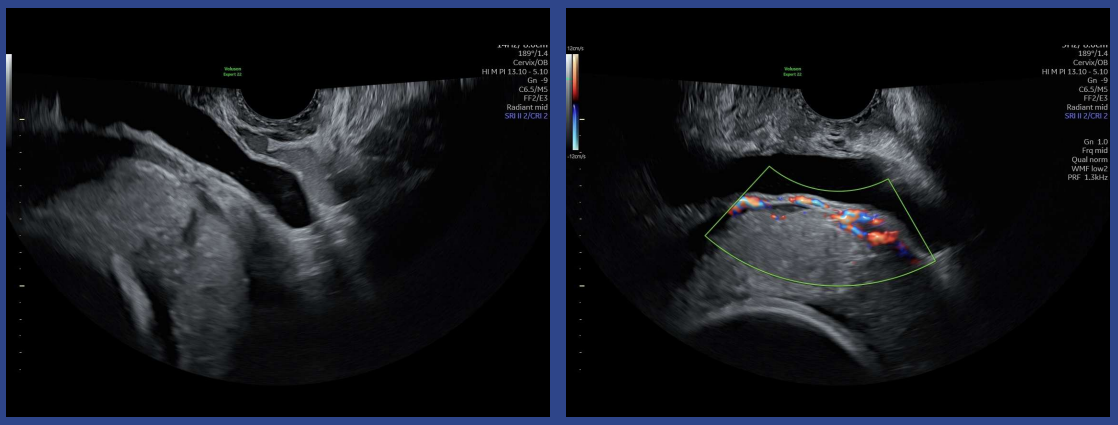

63

Operative notes

- Placenta was noted to be intact, below the level of the hysterotomy. The fetal buttocks were pulled to the hysterotomy level.
- Gentle traction was applied onto the uterus, however, dimpling noted over bladder noted when applying gentle traction to umbilical cord. At this point, a decision to proceed with a hysterectomy was made.
- The visual inspection as well as retraction of the lower uterine segment noted on traction of the cord, was clinical evidence of the presence of placenta accreta spectrum.
- A combination of blunt and sharp dissection were used to create the bladder flap bilaterally. An area of bleeding on the bladder was repaired in a figure of 8 fashion.
-

64

© Copyright. Society of Diagnostic Medical Sonography. All Rights Reserved.

Case Study #5



65

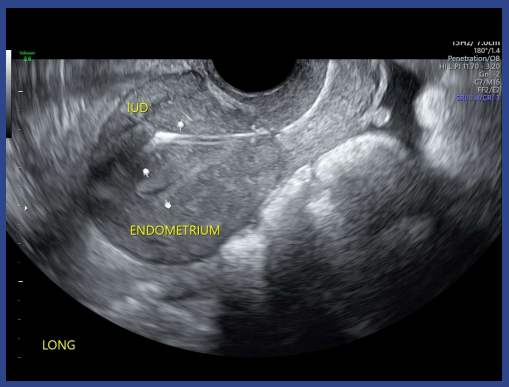

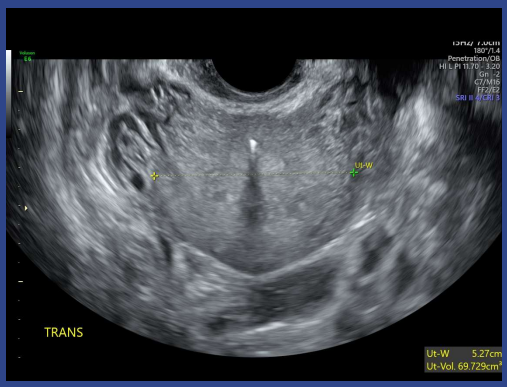

66

© Copyright. Society of Diagnostic Medical Sonography. All Rights Reserved.

Saw Provider, same back to do removal and re insertion under US guidance. Successful

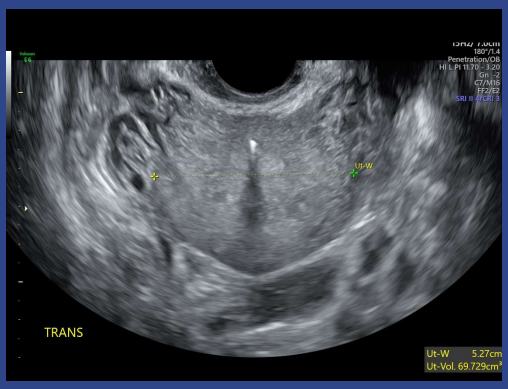

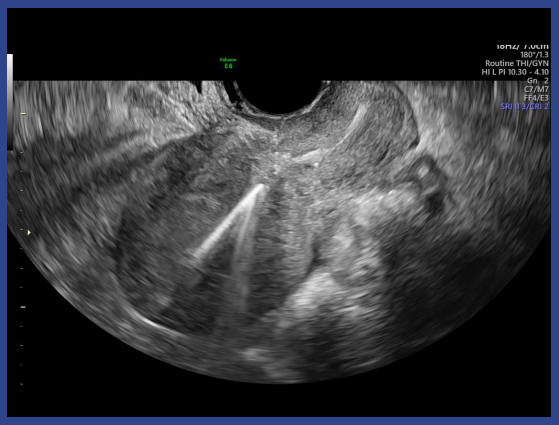

67

Last little tip

- Watch for the little bump near C Section scar. Often that is myometrial tissue being pulled into the defect. Do not mistake for a fibroid.

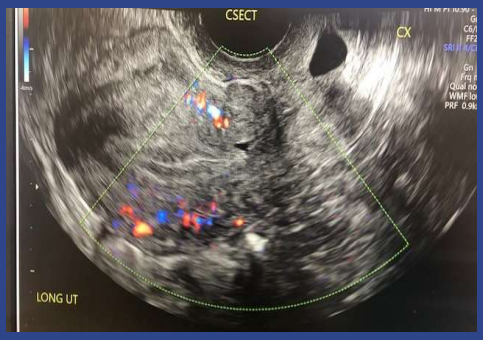

68

© Copyright. Society of Diagnostic Medical Sonography. All Rights Reserved.

In Conclusion

History of C Sections important

Be aware of Number of C Sections

Was there short intervals

Affects both pregnancy and Gyn

- Evaluate the scar as a structure required for exam, even if asymptomatic
- Three out of the four Acretas where asymptomatic
- US raised suspicion

69

Thanks for your time





70

© Copyright. Society of Diagnostic Medical Sonography. All Rights Reserved.