RIGHT VENTRICLE, NO LONGER FORGOTTEN

Georgeanne Lammertin, MBA, RDCS, RCS, FASE

September 26, 2026

SDMS Annual Conference, Atlanta, Georgia

1

SPEAKER PRESENTATION DISCLAIMER

The content and views presented are made available for educational purposes only. The information presented are the opinions of the presenter and do not necessarily represent the views of the Society of Diagnostic Medical Sonography (SDMS) or its affiliated organizations, officers, Boards of Directors, or staff members.

The presenter is responsible for ensuring balance, independence, objectivity, scientific rigor, and avoiding commercial bias in their presentation. Before making the presentation, the presenter is required to disclose to the audience any relevant financial interests or relationships with manufacturers or providers of medical products, services, technologies, and programs.

The SDMS and its affiliated organizations, officers, Board of Directors, and staff members disclaim any and all liability for all claims that may arise out of the use of this educational activity.

2

© Copyright. Society of Diagnostic Medical Sonography. All Rights Reserved.

RESEARCH DISCLAIMER

The information presented in this presentation is based on research conducted to the best of the presenters' abilities and knowledge. Research involves uncertainty and is subject to limitations. The findings and conclusions presented herein may be influenced by various factors including but not limited to data quality, methodology, assumptions, and interpretation.

Research outcomes may not always accurately predict real-world scenarios or future events. While the presenter may make efforts to ensure the accuracy and reliability of the information presented, completeness or absolute correctness is not guaranteed. This presentation is intended for informational purposes only and should not be construed as professional advice. Participants are encouraged to independently verify any information provided and consult relevant experts or professionals where appropriate.

The SDMS and its affiliated organizations, officers, Board of Directors, and staff members disclaim any and all liability for all claims that may arise out of the use of this educational activity.

3

GENERATIVE AI DISCLAIMER

The presenter utilized the use of large language models (LLMs) and generative artificial intelligence (AI) as a productivity tool to assist in drafting and refining content in this presentation.

While these tools can aid in structuring ideas, summarizing, paraphrasing, and language polishing, they have inherent limitations and cannot replace human creativity, critical thinking, or expert judgment. AI-generated content may contain errors, biases, or gaps in knowledge.

This presentation is intended for informational purposes only and should not be construed as definitive or authoritative guidance. Participants are encouraged to critically evaluate the information presented and consult relevant experts as needed. The SDMS and its affiliated organizations, officers, Board of Directors, and staff members disclaim any and all liability for claims that may arise from the use or interpretation of this educational material.

4

© Copyright. Society of Diagnostic Medical Sonography. All Rights Reserved.

Objectives

- Anatomy of Right Ventricle
- Anatomy of Tricuspid Valve
- Understand how to perform a comprehensive echocardiographic assessment of the tricuspid valve
- Assessment of severe TR
- Assessment of Right Ventricular dysfunction in Pulmonary Embolism
- TEER

5

ANATOMY OF RIGHT VENTRICLE AND TRICUSPID VALVE

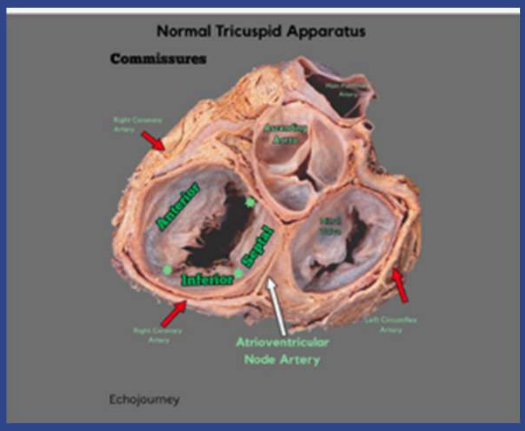

6

© Copyright. Society of Diagnostic Medical Sonography. All Rights Reserved.

ANATOMY OF RIGHT VENTRICLE AND TRICUSPID VALVE

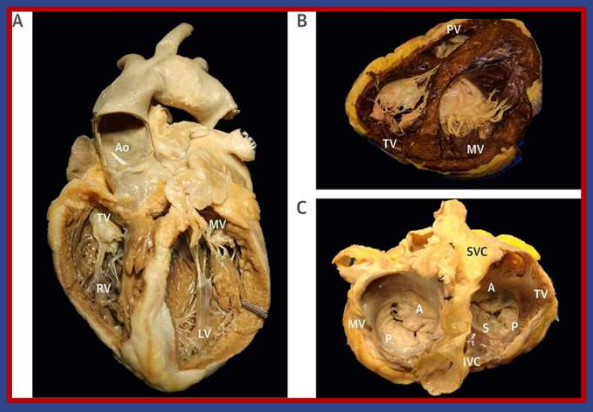

Abdellaziz Dahou et al. JIMG 2019;12:458-468

7

ANATOMY OF RIGHT VENTRICLE AND TRICUSPID VALVE

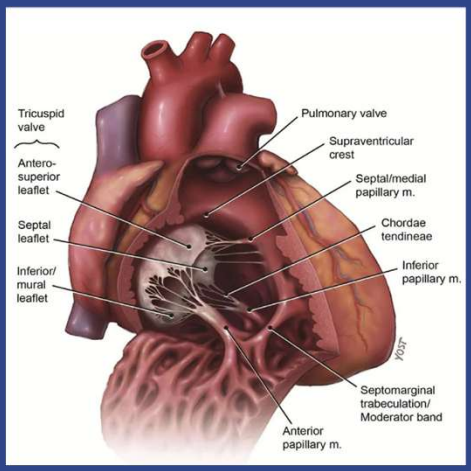

8

© Copyright. Society of Diagnostic Medical Sonography. All Rights Reserved.

ANATOMY OF RIGHT VENTRICLE AND TRICUSPID VALVE

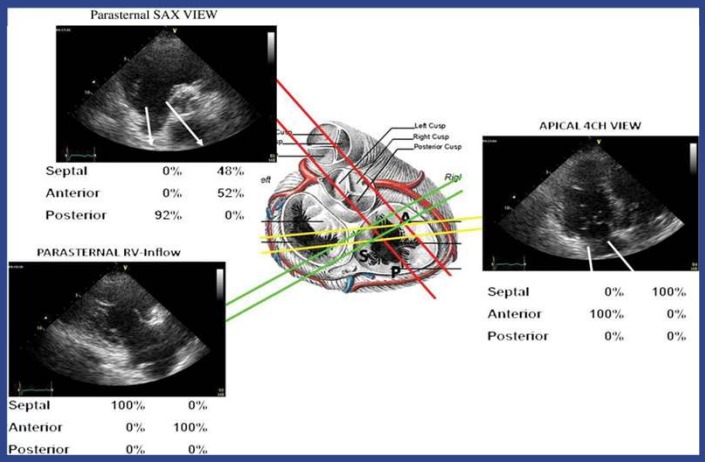

EJE 2009; 10: 477-84.

9

ANATOMY OF RIGHT VENTRICLE AND TRICUSPID VALVE

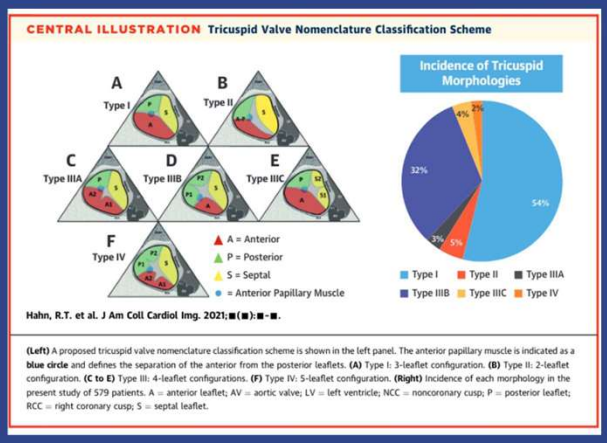

10

© Copyright. Society of Diagnostic Medical Sonography. All Rights Reserved.

ANATOMY OF RIGHT VENTRICLE AND TRICUSPID VALVE

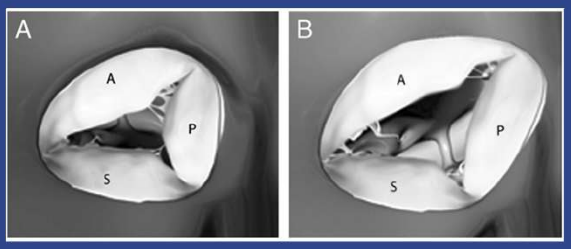

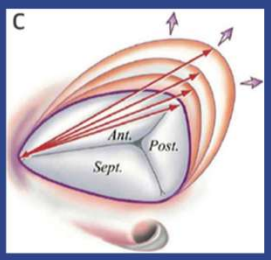

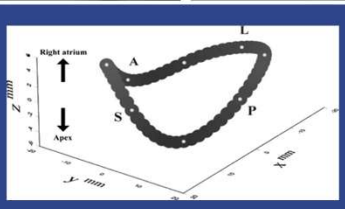

Taramasso JACC 2012
Dreyfus ATS 2005
Rogers JH, Bolling SF. Circulation 2009;119:2718-25.
Rodes-Cabau J et al. JACC 2016;67:1829-45

11

ANATOMY OF RIGHT VENTRICLE AND TRICUSPID VALVE

1 atrioventricular node

2 aortic valve

3 right coronary artery

4 coronary sinus

5 inferior vena cava

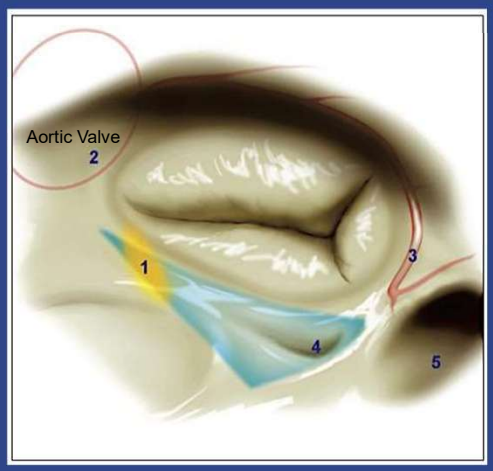

12

© Copyright. Society of Diagnostic Medical Sonography. All Rights Reserved.

ANATOMY OF RIGHT VENTRICLE AND TRICUSPID VALVE

Mid to lower esophageal views at 0 degrees

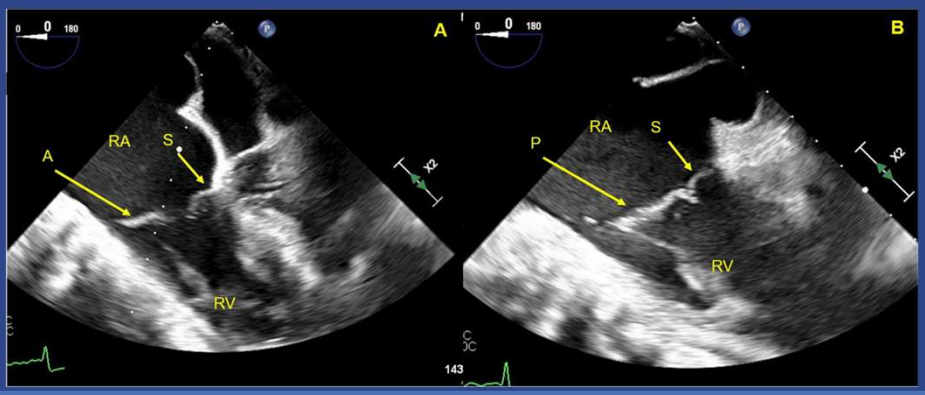

Mid esophageal

Lower esophageal

13

ANATOMY OF RIGHT VENTRICLE AND TRICUSPID VALVE

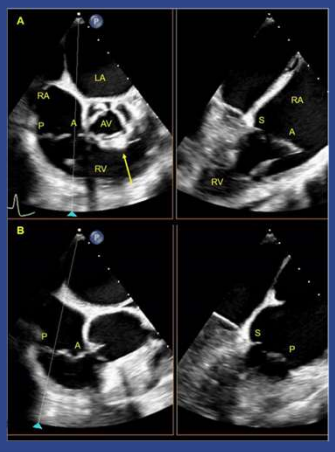

Biplane Image

Transgastric view

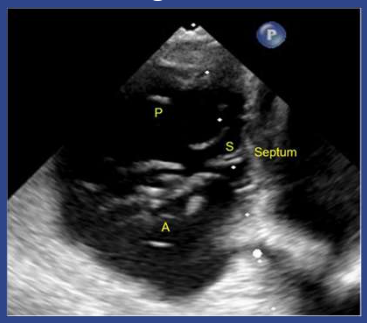

14

© Copyright. Society of Diagnostic Medical Sonography. All Rights Reserved.

ANATOMY OF RIGHT VENTRICLE AND TRICUSPID VALVE

3D Images

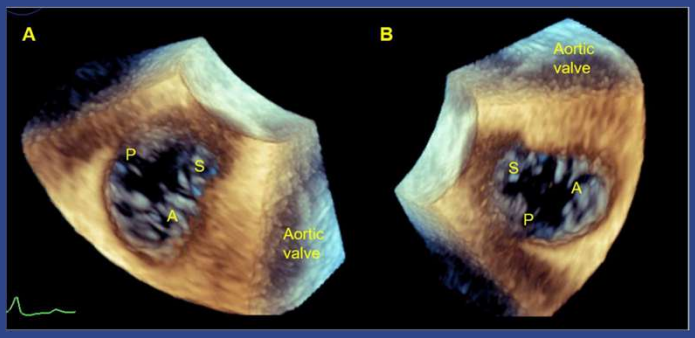

15

COMPREHENSIVE ASSESSMENT OF RV AND TRICUSPID VALVE

Guidelines for the Echocardiographic Assessment of the Right Heart in Adults and Special Considerations in Pulmonary Hypertension: Recommendations from the American Society of Echocardiography

Mukherjee, M., et al (2025). Guidelines for the Echocardiographic Assessment of the Right Heart in Adults and Special Considerations in Pulmonary Hypertension: Recommendations from the American Society of Echocardiography. Journal of the American Society of Echocardiography, 38(3), 141–186. https://doi.org/10.1016/j.echo.2025.01.006

16

© Copyright. Society of Diagnostic Medical Sonography. All Rights Reserved.

COMPREHENSIVE ASSESSMENT OF RV AND TRICUSPID VALVE

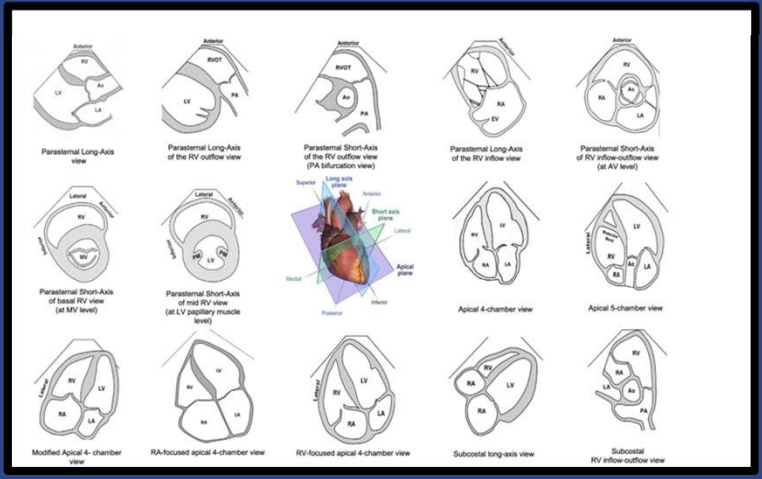

Mukherjee, M., et al (2025). Guidelines for the Echocardiographic Assessment of the Right Heart in Adults and Special Considerations in Pulmonary Hypertension: Recommendations from the American Society of Echocardiography. Journal of the American Society of Echocardiography, 38(3), 141–186. https://doi.org/10.1016/j.echo.2025.01.006

17

COMPREHENSIVE ASSESSMENT OF RV AND TRICUSPID VALVE

- The RA is best imaged from the apical four-chamber view at the end of ventricular systole and tilting upwards to maximize visualization of the superior aspect of the chamber. The single plane MOD is the best approach to assess RAV.
- Normal thresholds are RA area < 19 cm^2, RAV index (MOD) < 30 mL/m^2, and RAV index (area-length) < 32 mL/m^2.
- An enlarged RA chamber can be seen in normal subjects, even after indexing to BSA. When abnormal, RA dilatation reflects chronic elevations in filling pressures and RV diastolic dysfunction.

- Quantitative measures of RV chamber size are readily obtained using standard parasternal short-axis (PSAX) and PLAX views and from the apical RV-focused view.
- RVWT should be obtained from the anteromedial aspect of the free wall using the subcostal view by direct 2DE measures and/or M-mode imaging. If technically difficult, the PLAX view can also be used for RVWT measurements.
- The normal value for RVWT is <5 mm.
- 3DE-derived RV volumes can be can be obtained using dedicated software from a full-volume data set, although they may be underestimated compared with CMR.

1. RV chamber quantification should be performed from the parasternal windows and the apical RV-focused view, ensuring that the RVFW is visualized throughout the cardiac cycle.
2. Critical measures for reporting include at least one quantitative measure of RV chamber size, typically the basal dimension obtained from the RV-focused apical four-chamber view. However, multiple measures may be necessary in select populations.
3. RVWT should be reported if abnormal.

Mukherjee, M., et al (2025). Guidelines for the Echocardiographic Assessment of the Right Heart in Adults and Special Considerations in Pulmonary Hypertension: Recommendations from the American Society of Echocardiography. Journal of the American Society of Echocardiography, 38(3), 141–186. https://doi.org/10.1016/j.echo.2025.01.006

18

© Copyright. Society of Diagnostic Medical Sonography. All Rights Reserved.

COMPREHENSIVE ASSESSMENT OF RV AND TRICUSPID VALVE

RA major dimension (long-axis, longitudinal), cm	From the dedicated RA-focused apical 4Ch view, linear RA dimensions are measured at the end of ventricular systole. The major (long-axis longitudinal, yellow line) dimension of the RA is from the center of the TVA to the center of the superior RA wall, parallel to the interatrial septum.
RA minor dimension, (short axis, transverse), cm	The RA minor (transverse, red line) dimension is obtained from the midlevel of the RA free wall to the interatrial septum, perpendicular to the long axis of the chamber, excluding the RA appendage and venae cavae.



Mukherjee, M., et al (2025). Guidelines for the Echocardiographic Assessment of the Right Heart in Adults and Special Considerations in Pulmonary Hypertension: Recommendations from the American Society of Echocardiography. Journal of the American Society of Echocardiography, 38(3), 141–186. https://doi.org/10.1016/j.echo.2025.01.006

19

COMPREHENSIVE ASSESSMENT OF RV AND TRICUSPID VALVE

RA end-systolic area, cm^2	The RA area is measured from the lateral aspect of the TVA to the septal aspect following the RA endocardium and excluding the IVC and superior vena cava and RA appendage.
RA volume (2D and 3D), cm^3	2DE volumes are obtained from the dedicated RA-focused apical 4Ch view at the end of ventricular systole and can be calculated either by the single-plane Simpson's method or the area-length method. 2DE-derived RAV is typically smaller than those obtained by 3DE. Volumes should be indexed to BSA. 3DE datasets are usually obtained from the apical approach using a multi-beat full-volume acquisition.



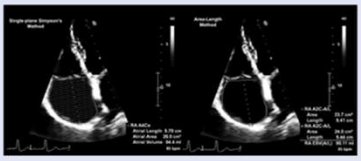

Mukherjee, M., et al (2025). Guidelines for the Echocardiographic Assessment of the Right Heart in Adults and Special Considerations in Pulmonary Hypertension: Recommendations from the American Society of Echocardiography. Journal of the American Society of Echocardiography, 38(3), 141–186. https://doi.org/10.1016/j.echo.2025.01.006

20

© Copyright. Society of Diagnostic Medical Sonography. All Rights Reserved.

COMPREHENSIVE ASSESSMENT OF RV AND TRICUSPID VALVE

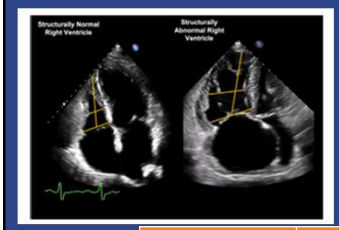

1. TAPSE is obtained from the RV-focused view by placing the M-mode cursor along the lateral TV annulus and is a core component of the standard echocardiographic assessment of RV systolic function.
2. TAPSE values should be reported in the context of overall RV functional assessment.

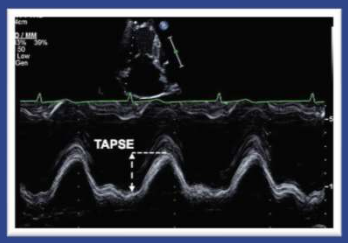

NORMAL VALUES		
LEVEL	MALE	FEMALE
BASAL	≤ 47 MM	≤43 MM
MID	≤42 MM	≤35 MM
LENGTH	≤87 MM	≤80 MM

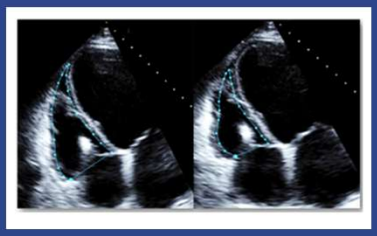

FAC MEASUREMENT

Mukherjee, M., et al (2025). Guidelines for the Echocardiographic Assessment of the Right Heart in Adults and Special Considerations in Pulmonary Hypertension: Recommendations from the American Society of Echocardiography. Journal of the American Society of Echocardiography, 38(3), 141–186. https://doi.org/10.1016/j.echo.2025.01.006

21

COMPREHENSIVE ASSESSMENT OF RV AND TRICUSPID VALVE

3D volumes	An ECG-gated 3DE dataset is acquired from an RV-focused apical 4Ch view by combining sub-volumes generated from 4 to 6 consecutive cardiac cycles. From the apical 4Ch view, the entire RVFW and apex should be included and breath holding can be used to avoid stitching artifact. If the RV-focused view is suboptimal, the subcostal view can also be used. If the rhythm is irregular, using a two-beat full-volume acquisition can also be used to avoid stitching artifact, although a two-beat acquisition may reduce temporal resolution. UEA should be considered when imaging quality is suboptimal.

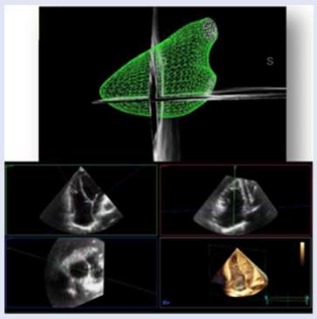

Mukherjee, M., et al (2025). Guidelines for the Echocardiographic Assessment of the Right Heart in Adults and Special Considerations in Pulmonary Hypertension: Recommendations from the American Society of Echocardiography. Journal of the American Society of Echocardiography, 38(3), 141–186. https://doi.org/10.1016/j.echo.2025.01.006

22

© Copyright. Society of Diagnostic Medical Sonography. All Rights Reserved.

COMPREHENSIVE ASSESSMENT OF RV AND TRICUSPID VALVE

- LVEI is the ratio of LV anteroposterior and LV septolateral dimensions measured from the PSAX view at the level of the papillary muscles and has prognostic value in PH.
- LVEI = 1 in both end-systole and end-diastole reflects a circular LV profile throughout the cardiac cycle and normal RV hemodynamic conditions.
- LVEI > 1 at end-diastole suggests RV volume overload.
- LVEI > 1 in end-systole suggests RV pressure overload.
- LVEI > 1 in end-systole and end-diastole suggests RV pressure overload with or without concomitant volume overload.

1. LVEI should be measured to evaluate the presence and extent of RV volume and/or pressure overload.
2. Quantification and reporting of LVEI should be included when abnormal.

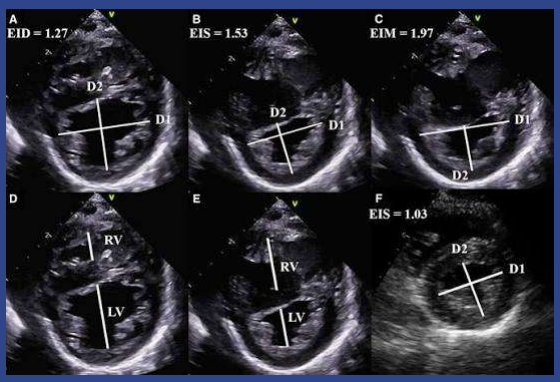

Mukherjee, M., et al (2025). Guidelines for the Echocardiographic Assessment of the Right Heart in Adults and Special Considerations in Pulmonary Hypertension: Recommendations from the American Society of Echocardiography. Journal of the American Society of Echocardiography, 38(3), 141–186. https://doi.org/10.1016/j.echo.2025.01.006

23

COMPREHENSIVE ASSESSMENT OF RV AND TRICUSPID VALVE

- RA strain is quantified from an RA-focused apical four-chamber view, optimized to visualize the entire RA chamber. Measurements can be made during image acquisition or post-processing using dedicated STE software.
- The three main phases of RA strain are the reservoir phase, conduit phase, and booster phase, each of which reflects the dynamic RA-RV relationship.
- Although largely a research tool, 3DE-derived total, passive, and emptying volumes and emptying fractions can also be used to assess RA phasic function.

Recommendations

1. Both STE- and 3DE-derived measures of RA phasic function have not yet been widely incorporated into clinical practice. However, these methods are important areas of active investigation and may have prognostic implications in PH and at-risk populations.
2. Although STE-derived RA strain is a promising tool for the assessment of dynamic RA phasic function, variability in normative values has limited its widespread clinical use.

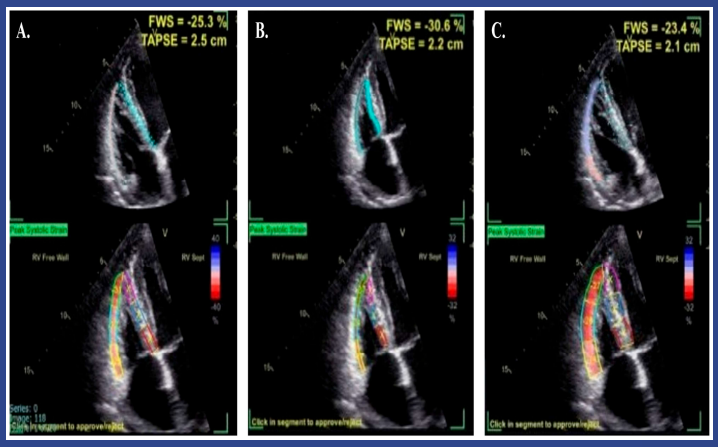

Mukherjee, M., et al (2025). Guidelines for the Echocardiographic Assessment of the Right Heart in Adults and Special Considerations in Pulmonary Hypertension: Recommendations from the American Society of Echocardiography. Journal of the American Society of Echocardiography, 38(3), 141–186. https://doi.org/10.1016/j.echo.2025.01.006

24

© Copyright. Society of Diagnostic Medical Sonography. All Rights Reserved.

COMPREHENSIVE ASSESSMENT OF RV AND TRICUSPID VALVE

FIGURE 9 Proposed New Grading Scheme

Parameters	MILD	MODERATE	SEVERE	MASSIVE	TORRENTIAL
Vena Contracta width (biplane average)	<3 mm	3-6.9 mm	7 mm - 13 mm	14-20 mm	≥21 mm
EROA by PISA	<20 mm^2	20-39 mm^2	40-59 mm^2	60-79 mm^2	≥80 mm^2
3D Vena Contracta Area or Quantitative Doppler EROA	-	-	75-94 mm^2	95-114 mm^2	≥115 mm^2
Example:	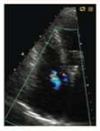	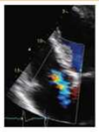		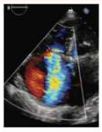	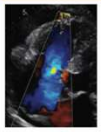

J Am Coll Cardiol Img 2019;12:469–90
European Heart Journal - Cardiovascular Imaging 2017;18(12):1342–1343

25

COMPREHENSIVE ASSESSMENT OF RV AND TRICUSPID VALVE

RVSP is calculated from the peak TR jet velocity, using the simplified Bernoulli equation, and adding this value to the RAP estimate. RVSP is equivalent to PASP in the absence of RVOT obstruction, PS, and/or proximal PA stenosis. To avoid overestimation of the spectral envelope, ensure that the peak systolic measurement is from the dense aspect of the spectral Doppler envelope. The optimal CW Doppler signal of the TR jet is characterized by a dense envelope, indicating a complete Doppler profile. To ensure accuracy and account for respirophasic variation, RVSP should be calculated by averaging at least three consecutive beats from the window with the highest velocities and the clearest Doppler envelope.

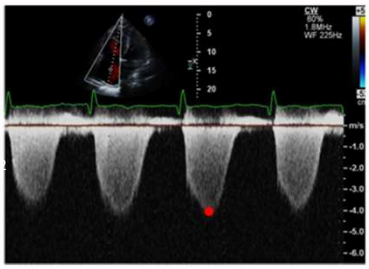

$4V^2 + RAP = RVSP$

Mukherjee, M., et al (2025). Guidelines for the Echocardiographic Assessment of the Right Heart in Adults and Special Considerations in Pulmonary Hypertension: Recommendations from the American Society of Echocardiography. Journal of the American Society of Echocardiography, 38(3), 141–186. https://doi.org/10.1016/j.echo.2025.01.006

26

© Copyright. Society of Diagnostic Medical Sonography. All Rights Reserved.

COMPREHENSIVE ASSESSMENT OF RV AND TRICUSPID VALVE

PVR WOODS UNITS

Calculated by VTI_{RVOT} and the peak TR velocity, or by mPAP and PCWP.

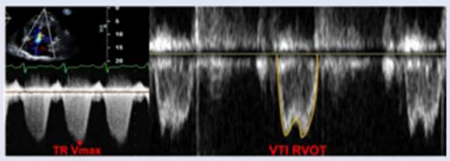

$PVR = [(\text{Peak TR velocity} / VTI_{RVOT}) \times 10] + 0.16$

$PVR = (RVSP - PCWP)/CO$

$RVSP = [4 \times (\text{peak TR velocity})^2 + RAP]$

$PCWP = [1.24 \times (\text{mitral E/e' ratio}) + 1.9]$

$CO = [(\pi r^2) \times VTI_{RVOT}] \times HR$

Mukherjee, M., et al (2025). Guidelines for the Echocardiographic Assessment of the Right Heart in Adults and Special Considerations in Pulmonary Hypertension: Recommendations from the American Society of Echocardiography. Journal of the American Society of Echocardiography, 38(3), 141–186. https://doi.org/10.1016/j.echo.2025.01.006

27

COMPREHENSIVE ASSESSMENT OF RV AND TRICUSPID VALVE

RAP is assessed by measuring IVC size and the collapsibility during normal breathing. IVC diameter is measured at end-expiration, approximately 0.5-3.0 cm proximal to the RA ostium, from the subcostal view. Collapsibility is determined by the change in IVC diameter during sniffing and quiet respiration.

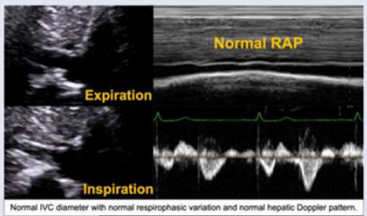

Normal IVC diameter with normal respirophasic variation and normal hepatic Doppler pattern.

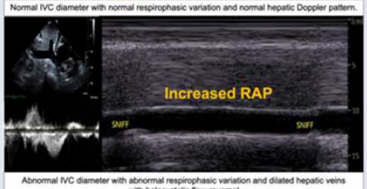

Abnormal IVC diameter with abnormal respirophasic variation and dilated hepatic veins with holosystolic flow reversal

3 mm Hg (range 0-5 mm Hg), IVC diameter ≤ 21 mm and ≥ 50% inspiratory collapse

8 mm Hg (range 5-10 mm Hg), IVC diameter ≤ 21 mm and < 50% collapse or an IVC diameter >21 mm and ≥ 50% collapse

15 mm Hg (range 10-20 mm Hg), IVC diameter > 21 mm and < 50% collapse

20 mm Hg, IVC diameter > 25 mm and < 50% collapse with dilated hepatic veins and adjunctive evidence of spontaneous echo contrast or color flow reflux within the vessel is suggestive of markedly elevated RAP, severe TR, or impaired venous return due to conditions such as right heart failure, RV diastolic dysfunction, or constrictive physiology.

Mukherjee, M., et al (2025). Guidelines for the Echocardiographic Assessment of the Right Heart in Adults and Special Considerations in Pulmonary Hypertension: Recommendations from the American Society of Echocardiography. Journal of the American Society of Echocardiography, 38(3), 141–186. https://doi.org/10.1016/j.echo.2025.01.006

28

© Copyright. Society of Diagnostic Medical Sonography. All Rights Reserved.

PULMONARY HYPERTENSION

Definition, classification and diagnosis of pulmonary hypertension

Gabor Kovacs[1,2], Sonja Bartolome[3], Christopher P. Denton[4], Michael A. Gatzoulis[5,6], Sue Gu[7], Dinesh Khanna[8], David Badesch[7] and David Montani[9,10,11]

European Respiratory Journal 2024 64(4): 2401324; DOI: https://doi.org/10.1183/13993003.01324-2024

29

PULMONARY HYPERTENSION

TABLE 1 Haemodynamic criteria of pulmonary hypertension (PH)

	Haemodynamic characteristics
PH	mPAP >20 mmHg
Pre-capillary PH	mPAP >20 mmHg PAWP ⩽15 mmHg PVR >2 WU
Isolated post-capillary PH (ipcPH)	mPAP >20 mmHg PAWP >15 mmHg PVR ⩽2 WU
Combined post- and pre-capillary PH (cpcPH)	mPAP >20 mmHg PAWP >15 mmHg PVR >2 WU
Exercise PH	mPAP/CO slope >3 mmHg/L/min between rest and exercise

mPAP: mean pulmonary arterial pressure; PAWP: pulmonary arterial wedge pressure; PVR: pulmonary vascular resistance; WU: Wood Units; CO: cardiac output.

European Respiratory Journal 2024 64(4): 2401324; DOI: https://doi.org/10.1183/13993003.01324-2024

30

© Copyright. Society of Diagnostic Medical Sonography. All Rights Reserved.

PULMONARY HYPERTENSION

- LVEI is the ratio of LV anteroposterior and LV septolateral dimensions measured from the PSAX view at the level of the papillary muscles and has prognostic value in PH.
- LVEI = 1 in both end-systole and end-diastole reflects a circular LV profile throughout the cardiac cycle and normal RV hemodynamic conditions.
- LVEI > 1 at end-diastole suggests RV volume overload.
- LVEI > 1 in end-systole suggests RV pressure overload.
- LVEI > 1 in end-systole and end-diastole suggests RV pressure overload with or without concomitant volume overload.

1. LVEI should be measured to evaluate the presence and extent of RV volume and/or pressure overload.
2. Quantification and reporting of LVEI should be included when abnormal.

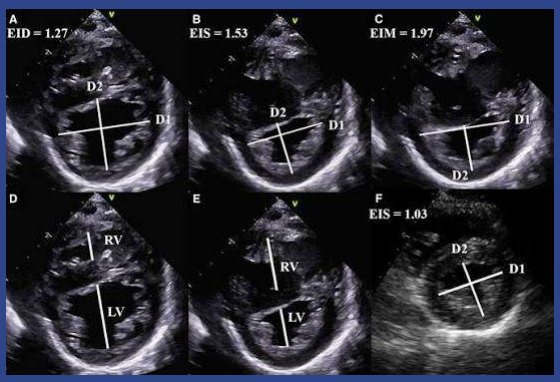

Mukherjee, M., et al (2025). Guidelines for the Echocardiographic Assessment of the Right Heart in Adults and Special Considerations in Pulmonary Hypertension: Recommendations from the American Society of Echocardiography. Journal of the American Society of Echocardiography, 38(3), 141–186. https://doi.org/10.1016/j.echo.2025.01.006

31

PULMONARY HYPERTENSION

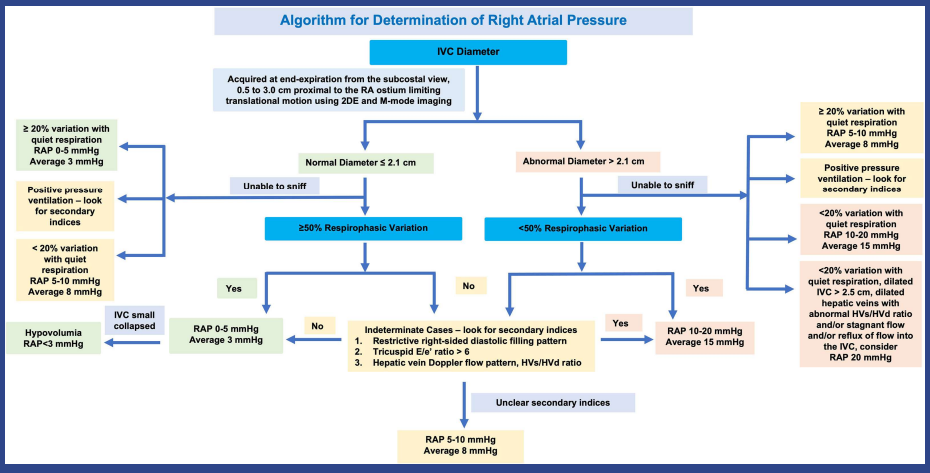

Mukherjee, M., et al (2025). Guidelines for the Echocardiographic Assessment of the Right Heart in Adults and Special Considerations in Pulmonary Hypertension: Recommendations from the American Society of Echocardiography. Journal of the American Society of Echocardiography, 38(3), 141–186. https://doi.org/10.1016/j.echo.2025.01.006

32

© Copyright. Society of Diagnostic Medical Sonography. All Rights Reserved.

PULMONARY HYPERTENSION

Table 10 Recommendations for key echocardiographic imaging parameters

Screening for PH	Established PH
At a minimum, screening PH echocardiography should include Hemodynamics • Peak TRV • RVSP • LV E/e' ratio Structure • Left atrial volume index • RA area and/or volume index • RV basal dimension: if abnormal, complete RV chamber assessment including quantification and grading of size (mild, moderate, severely dilated), presence or absence of septal flattening (diastole only suggestive of volume overload vs systole and diastole suggestive of pressure and volume overload) Function • LV ejection fraction (biplane from apical 4Ch, 2Ch) • RV systolic function (TAPSE, TDI, RVFWS'): if abnormal and/or there is evidence of RV structural abnormality such as dilation and presence of apical traction, calculate FAC Valves • Comprehensive assessment of ≥ moderate regurgitant lesions (mitral, tricuspid, aortic), aortic and mitral stenosis Other • Presence/absence of any pericardial effusion and if present, size and location in end-diastole, signs of cardiac tamponade	At a minimum, established PH echocardiography should include Hemodynamics • Peak TRV • RVSP with RAP and compare with prior • LV E/e' ratio for group 2 PH or mixed pre- and postcapillary PH Structure • RA area and/or volume index • RV basal dimension: if abnormal, complete RV chamber assessment including quantification and grading of size (mild, moderate, severely dilated), presence or absence of septal flattening (diastole only suggestive of volume overload vs systole and diastole suggestive of pressure and volume overload) • RV volumes using 3DE if feasible Function • LV ejection fraction (biplane from 4Ch, 2Ch) • RV systolic function (TAPSE, TDI, RVFWS'): if abnormal and/or there is evidence of RV structural abnormality such as dilation and presence of apical traction, calculate FAC Valves • Change in valvular severity from prior (regurgitant lesions [mitral, tricuspid, aortic], aortic and mitral stenosis) • For FTR, evaluation of etiologies, presence of malcoaptation, presence of leaflet tethering, quantitative measures (annular size, tethering distance and length), presence of HVs reversal Other • Presence/absence of moderate or greater pericardial effusion and if present, size and location in end-diastole, signs of cardiac tamponade

Mukherjee, M., et al (2025). Guidelines for the Echocardiographic Assessment of the Right Heart in Adults and Special Considerations in Pulmonary Hypertension: Recommendations from the American Society of Echocardiography. Journal of the American Society of Echocardiography, 38(3), 141–186. https://doi.org/10.1016/j.echo.2025.01.006

33

PULMONARY HYPERTENSION

Understanding Pulmonary Hypertension in Echo: What Every Clinician Should Know Beforehand

Author: Judith Buckland, MBA, RDCS, FASE

October 6, 2025

Group	Where the Problem Starts	Easy Way to Remember
1. Pulmonary Arteries	Disease of the pulmonary vessels themselves (idiopathic, connective-tissue disease)	**"The pipes are the problem."**
2. Left Heart	Backup pressure from LV or mitral valve disease	**"The drain is clogged."**
3. Lungs / Oxygen	Chronic lung disease or low oxygen (COPD, interstitial lung disease, sleep apnea)	**"Bad air = high pressure."**
4. Clots	Old blood clots blocking flow (Chronic Thromboembolic Pulmonary Hypertension.)	**"The plumbing is blocked."**
5. Other / Mixed	Rare or multiple causes (sarcoid, metabolic, etc.)	**"Everything else."**

34

© Copyright. Society of Diagnostic Medical Sonography. All Rights Reserved.

PULMONARY HYPERTENSION

Prognostic Power of Echo Findings

Echo Marker	What It Predicts
↑ RA area or RAVI	Hospitalization / mortality risk
↓ TAPSE / S′ / FAC	RV failure, poor outcomes
Short RVOT AccT	High pulmonary vascular resistance, worse survival
↑ TR velocity + supportive findings	Higher Pulmonary Hypertension probability

35

PULMONARY HYPERTENSION

Common Pitfalls

Myth	Reality
"High TR jet = PH."	Not always — verify with supportive signs.
"PH = Pulmonary Arterial Hypertension."	Only Group 1 fits that term.
"Normal TAPSE = normal RV."	Early PH can exist with preserved TAPSE.
"High RVSP = PH."	Only if TR velocity and RAP are accurate.

36

© Copyright. Society of Diagnostic Medical Sonography. All Rights Reserved.

PULMONARY HYPERTENSION

Accuracy of Doppler-Echocardiographic Mean Pulmonary Artery Pressure for Diagnosis of Pulmonary Hypertension

Fikret Er, Stefan Ederer, Amir M. Nia, Evren Caglayan, Kristina M. Dahlem, Nasser Semmo, Natig Gassanov

Published: December 17, 2010 • https://doi.org/10.1371/journal.pone.0015670

The validity of Doppler echocardiographic (DE) measurement of systolic pulmonary artery pressure (sPAP) has been questioned. Recent studies suggest that mean pulmonary artery pressure (mPAP) might reflect more accurately the invasive pressures.

Er F, Ederer S, Nia AM, Caglayan E, Dahlem KM, Semmo N, et al. (2010) Accuracy of Doppler-Echocardiographic Mean Pulmonary Artery Pressure for Diagnosis of Pulmonary Hypertension. PLoS ONE 5(12): e15670. https://doi.org/10.1371/journal.pone.0015670

37

PULMONARY HYPERTENSION

CHEMLA FORMULA

mPAP = 0.61 X sPAP + 2mmHG

SYYED FORMULA

mPAP = 0.65 X sPAP + 0.55mmHG

Both methods for determining mean PAP were found to correlate well with RHC

38

© Copyright. Society of Diagnostic Medical Sonography. All Rights Reserved.

PULMONARY HYPERTENSION vs PE

ECHO SIGNS IN ACUTE PE

- RV dilation
- RV hypokinesis (with sparing of apex)
- Abnormal IVS motion (D shape LV)

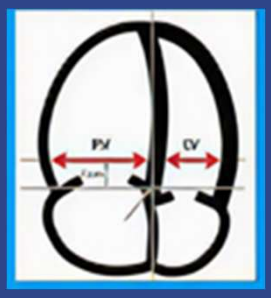

TRICUSPID REGURGITATION

- Pulmonary arterial hypertension
- Lack of decreased inspirator collapse of IVC
- Direct visualization of thrombus

39

PULMONARY HYPERTENSION vs PE

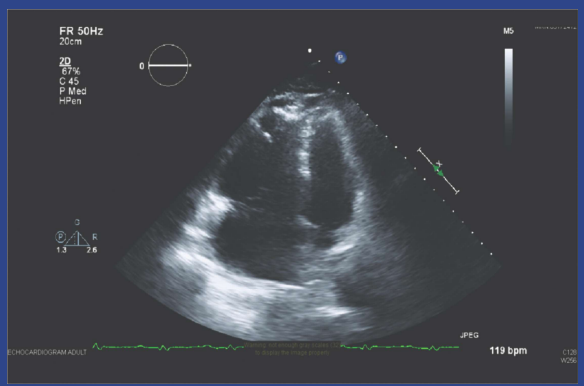

40

© Copyright. Society of Diagnostic Medical Sonography. All Rights Reserved.

PULMONARY HYPERTENSION vs PE

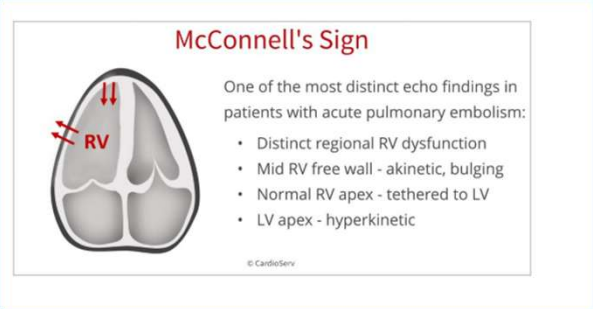

41

PULMONARY HYPERTENSION & PE

- RA strain is quantified from an RA-focused apical four-chamber view, optimized to visualize the entire RA chamber. Measurements can be made during image acquisition or post-processing using dedicated STE software.
- The three main phases of RA strain are the reservoir phase, conduit phase, and booster phase, each of which reflects the dynamic RA-RV relationship.
- Although largely a research tool, 3DE-derived total, passive, and emptying volumes and emptying fractions can also be used to assess RA phasic function.

Recommendations

1. Both STE- and 3DE-derived measures of RA phasic function have not yet been widely incorporated into clinical practice. However, these methods are important areas of active investigation and may have prognostic implications in PH and at-risk populations.
2. Although STE-derived RA strain is a promising tool for the assessment of dynamic RA phasic function, variability in normative values has limited its widespread clinical use.

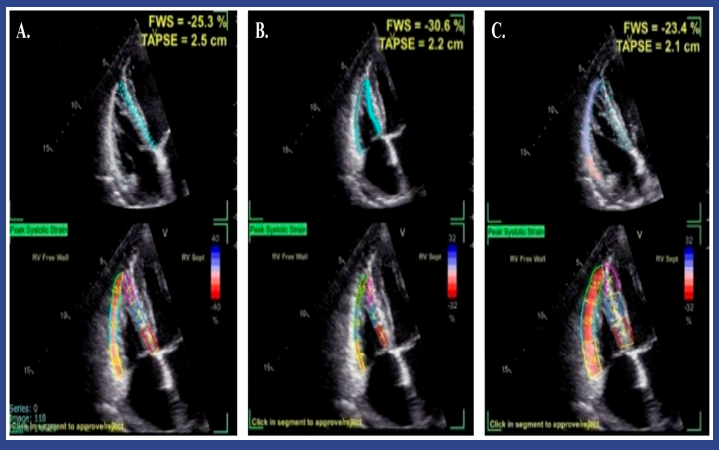

Mukherjee, M., et al (2025). Guidelines for the Echocardiographic Assessment of the Right Heart in Adults and Special Considerations in Pulmonary Hypertension: Recommendations from the American Society of Echocardiography. Journal of the American Society of Echocardiography, 38(3), 141–186. https://doi.org/10.1016/j.echo.2025.01.006

42

© Copyright. Society of Diagnostic Medical Sonography. All Rights Reserved.

PULMONARY HYPERTENSION & PE

FINDINGS GENERALLY:

RV ENLARGEMENT	27%
RV FREE WALL HYPOKINESIS	27%
McCONNELL SIGN	20%
IVS FLATTENING	18%
60/60 SIGN	13%

Kurnicka K, Lichodziejewska B, Goliszek S ...
Echocardiographic Pattern of Acute Pulmonary Embolism: Analysis of 511 Consecutive Patients
Journal of the American Society of Echocardiography, 2016; 29, 907-913

43

PULMONARY HYPERTENSION & PE

- WHAT IS THE 60/60 SIGN?

- PULMONARY ACCELERATION TIME (PAT): <60 MS AT RVOT (pw)
- TR GRADIENT: 30-60 mmHg
- CLIICAL DISTINCTION: <60 mmHg DIFFERENTIATES ACUTE PE AND PHTN

44

© Copyright. Society of Diagnostic Medical Sonography. All Rights Reserved.

TEER

GUIDELINES AND STANDARDS

Recommended Standards for the Performance of Transesophageal Echocardiographic Screening for Structural Heart Intervention: From the American Society of Echocardiography

Rebecca T. Hahn, MD, FASE (Chair), Muhamed Saric, MD, PhD, FASE (Co-Chair), Francesco Fulvio Faletra, MD, Ruchira Garg, MD, FASE, Linda D. Gillam, MD, MPH, FASE, Kenneth Horton, ACS, RCS, FASE, Omar K. Khalique, MD, FASE, Stephen H. Little, MD, FASE, G. Burkhard Mackensen, MD, PhD, FASE, Jae Oh, MD, FASE, Nishath Quader, MD, FASE, Lucy Safi, DO, FASE, Gregory M. Scalia, MBBS, FASE, and Roberto M. Lang, MD, FASE, *New York, New York; Lugano, Switzerland; Los Angeles, California; Morristown, New Jersey; Murray, Utah; Houston, Texas; Seattle Washington; Rochester, Minnesota; St. Louis, Missouri; Hackensack, New Jersey; Brisbane, Australia; and Chicago, Illinois*

Hahn, R. et al (2021 From the American Society of Echocardiography. *Journal of the American Society of Echocardiography*, 34(10), 1-76. https://doi.org/10.1016/j.echo.2021.07.006

45

TEER

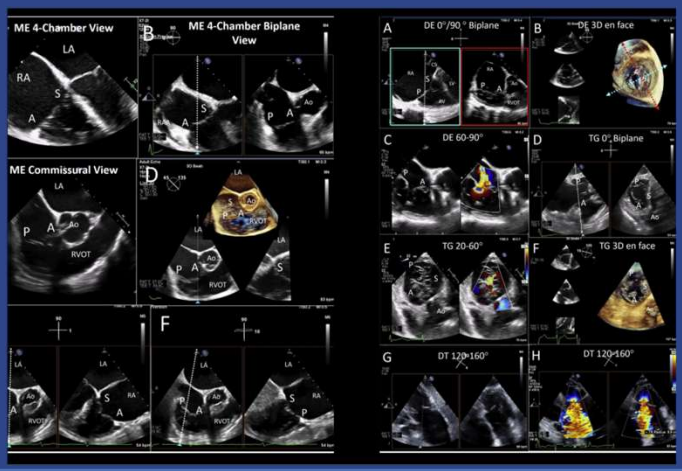

Hahn, R. et al (2021 From the American Society of Echocardiography. *Journal of the American Society of Echocardiography*, 34(10), 1-76. https://doi.org/10.1016/j.echo.2021.07.006

46

© Copyright. Society of Diagnostic Medical Sonography. All Rights Reserved.

TEER

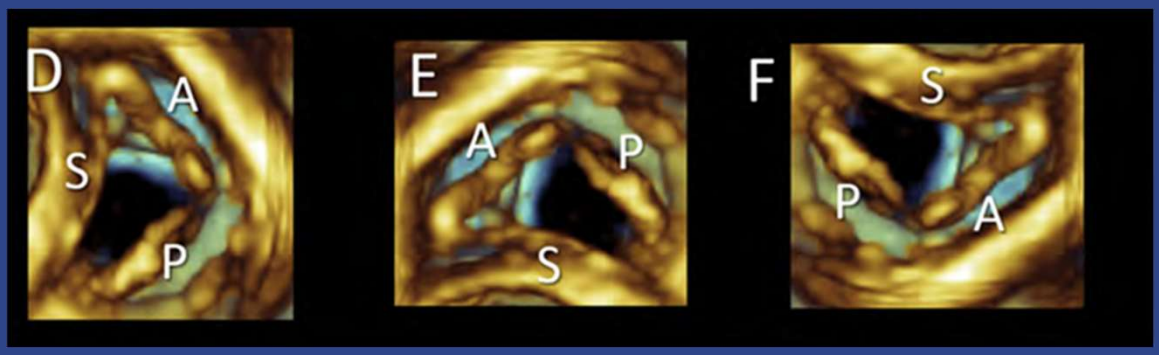

Hahn, R. et al (2021 From the American Society of Echocardiography. *Journal of the American Society of Echocardiography*, 34(10), 1-76. https://doi.org/10.1016/j.echo.2021.07.006

47

TEER



Hahn, R. et al (2021 From the American Society of Echocardiography. *Journal of the American Society of Echocardiography*, 34(10), 1-76. https://doi.org/10.1016/j.echo.2021.07.006

48

© Copyright. Society of Diagnostic Medical Sonography. All Rights Reserved.

TEER

Triluminate Trial



- 572 pts with severe TR (285 randomized to TEER; 287 randomized to medical tx)
- 65 centers in US, Canada, Europe
- TriClip Transcatheter Tricuspid Valve Repair system
- Primary endpoint: composite of death or TV surgery, HF hospitalization, improved QOL after 1 year
- Severity of TR and safety also assessed
- Triclip FDA approved in April 2024

N Engl J Med 2023;388:1833-1842
JACC 2025, 85:235-246

49

SUMMARY

- RV imaging and examination is a process of accurate measurements
- The TV has complex anatomy the must be appreciated to safely and successfully treat TR
- Prognosis of severe TR is poor regardless of etiology
- Functional TR is more common than primary TR
- - Most commonly due to left heart disease
- Quantification is challenging but important
- Treatment of TR is dependent on severity, symptoms, etiology, RV function, concomitant left heart surgery
- Percutaneous TV repair is in its infancy but will likely change the landscape of TR treatment in the near future
- Who will benefit most, when the time is right to intervene, longevity of current devices are yet to be fully determined

50

© Copyright. Society of Diagnostic Medical Sonography. All Rights Reserved.