Vascular Ultrasound Case Study Review: Understanding the Role and Responsibility of the Sonographer

Heather Niewald, BS, RVT

1

SPEAKER PRESENTATION DISCLAIMER

The content and views presented are made available for educational purposes only. The information presented are the opinions of the presenter and do not necessarily represent the views of the Society of Diagnostic Medical Sonography (SDMS) or its affiliated organizations, officers, Boards of Directors, or staff members.

The presenter is responsible for ensuring balance, independence, objectivity, scientific rigor, and avoiding commercial bias in their presentation. Before making the presentation, the presenter is required to disclose to the audience any relevant financial interests or relationships with manufacturers or providers of medical products, services, technologies, and programs.

The SDMS and its affiliated organizations, officers, Board of Directors, and staff members disclaim any and all liability for all claims that may arise out of the use of this educational activity.

2

© Copyright. Society of Diagnostic Medical Sonography. All Rights Reserved.

Role of a Sonographer

- Problem solving in ultrasound case studies
- Being attentive to other findings
- Obtaining accurate information and communicating it
- Continuous learning

3

SDMS Clinical Standards and Scope

- Perform exam per protocol using appropriate diagnostic criteria
- Be aware of history, previous exams and symptoms
- Report any limitations to protocol
- Obtain additional images when needed
- Notify provider of urgent results

4

© Copyright. Society of Diagnostic Medical Sonography. All Rights Reserved.

Case 1

5

Background

- Male in late 40's with history of bicuspid aortic valve
- Presented to emergency room with cardiogenic shock
- Echocardiogram showed ejection fraction of 15%
- Placed on extracorporeal membrane oxygenation (ECMO)

6

© Copyright. Society of Diagnostic Medical Sonography. All Rights Reserved.

- 1 month into his ICU stay c/o toe pain and discoloration
- Obtained arterial duplex
- Unable to visualize right Common Femoral Artery (CFA) and Deep Femoral Artery (DFA) due to patient body habitus and edema
- Distally flow was normal
- 10 days later Computed Tomography (CT) with contrast showed pseudoaneurysm off the Superficial Femoral Artery (SFA) measuring 2.1cm and fistula at level of the pseudo

7

What is a pseudoaneurysm?

- Pseudoaneurysm is also known as a false aneurysm.
- Injuries are most commonly from an insertion site
  - Usually in the groin from a catheter
- Large pseudoaneurysms are at risk for rupture
- Depending on size providers may monitor them, compress them, or inject them

8

© Copyright. Society of Diagnostic Medical Sonography. All Rights Reserved.

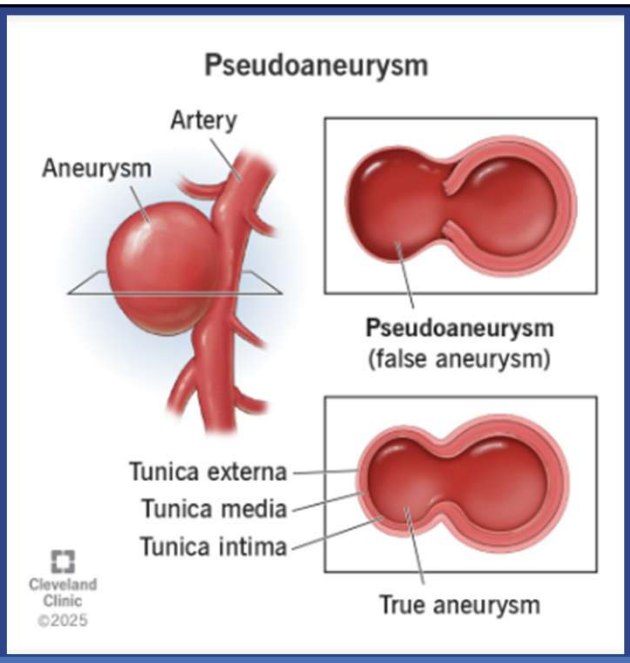

Image [7]

9

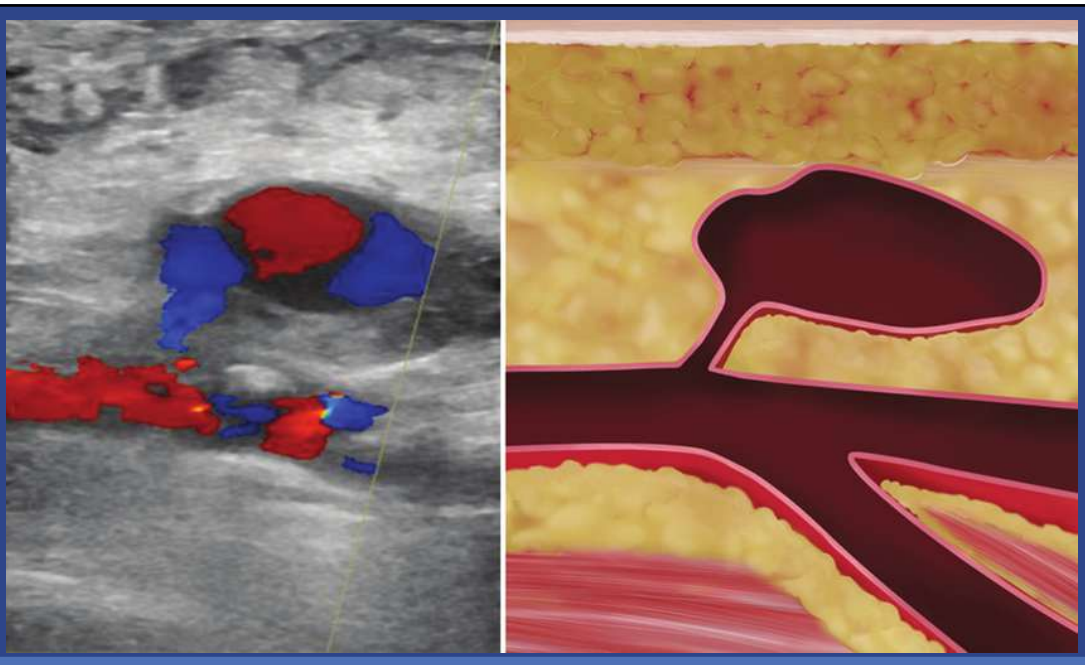

Image [1]

10

© Copyright. Society of Diagnostic Medical Sonography. All Rights Reserved.

What is a fistula?

- Fistula is a connection between the artery and vein
- Flow can move from the artery to the vein
- Different types of fistulas.
  - Congenital
  - Dialysis
  - Traumatic
- Complications may include issues for the heart. It may work harder because the blood is not flowing correctly around the fistula. In severe cases it could cause congestive heart failure.[6]

11



Image [9]

12

© Copyright. Society of Diagnostic Medical Sonography. All Rights Reserved.

Case 1 Continued

- Repeat ultrasound reported pseudoaneurysm but no mention of fistula
- Over the course of the next 2 months, the patient received several more ultrasounds that again reported a pseudoaneurysm but no mention of a fistula

13

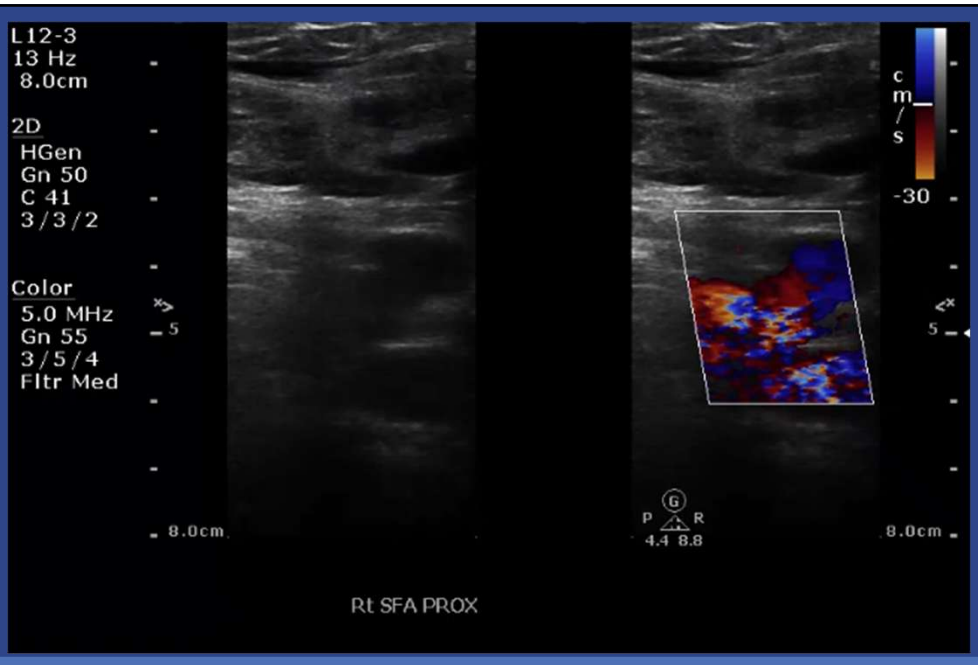

Images on file with Niewald, H.

14

© Copyright. Society of Diagnostic Medical Sonography. All Rights Reserved.

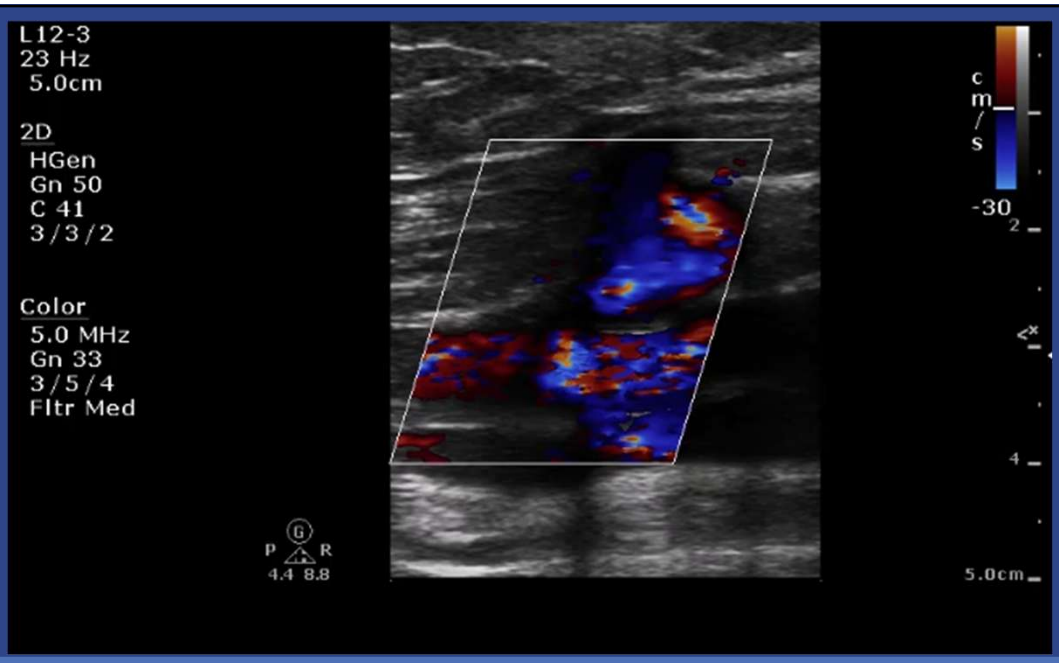

Images on file with Niewald, H.

15

- One month later patient had another ultrasound that showed both the pseudoaneurysm and fistula
- Provider followed the case at 6 months and then yearly
- Thrombin injection was contraindicated due to the presence of a fistula

16

© Copyright. Society of Diagnostic Medical Sonography. All Rights Reserved.

2026 SDMS Annual Conference

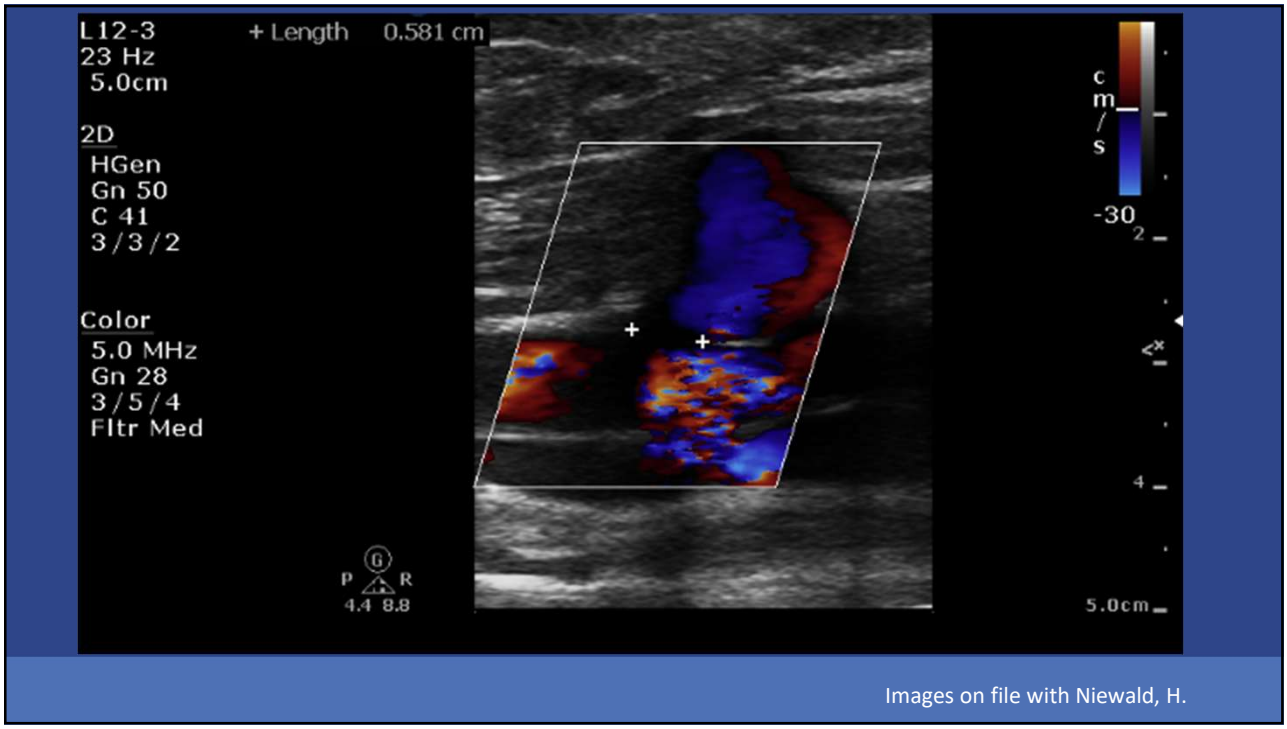

Images on file with Niewald, H.

17

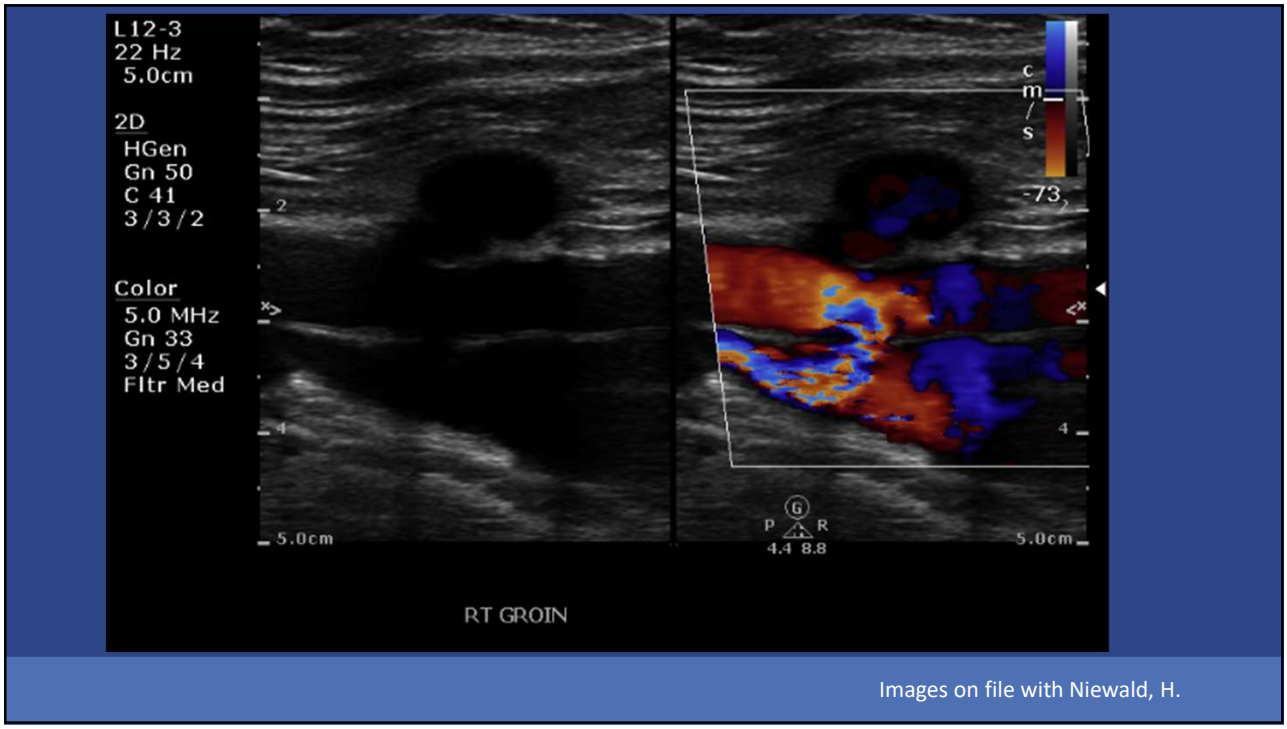

Images on file with Niewald, H.

18

© Copyright. Society of Diagnostic Medical Sonography. All Rights Reserved.

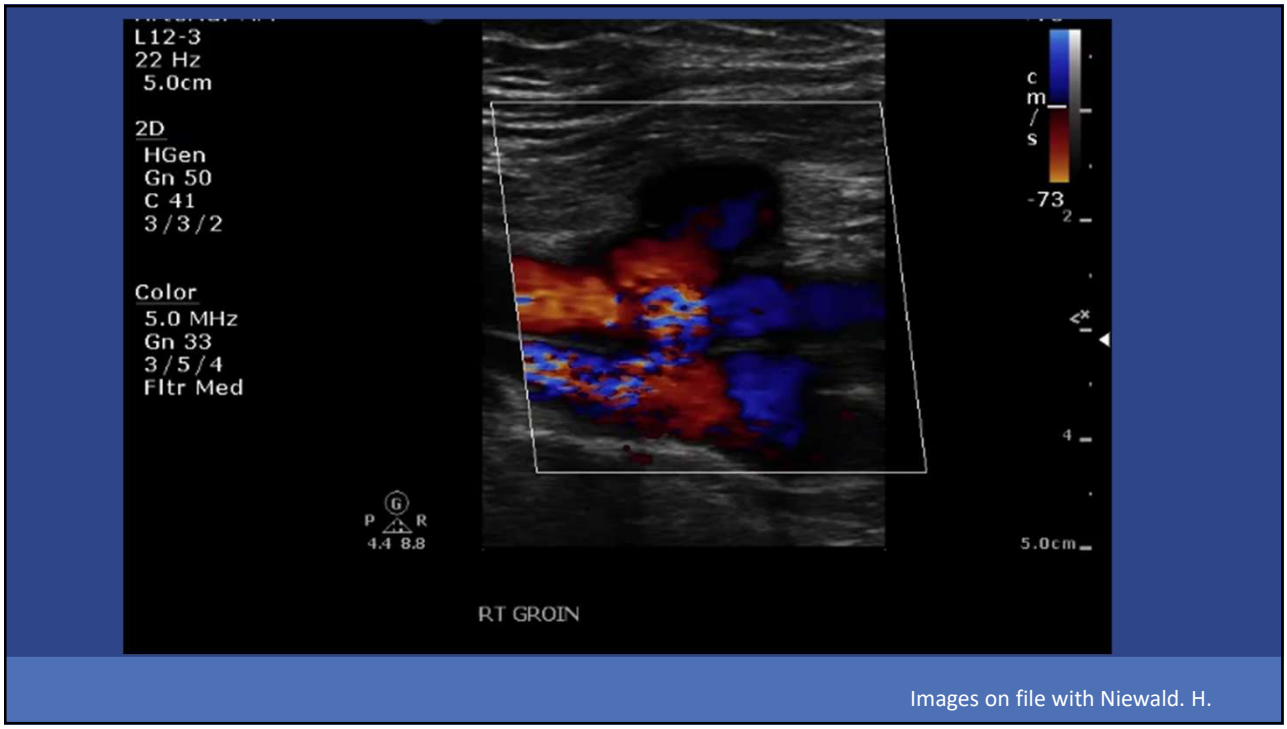

Images on file with Niewald. H.

19

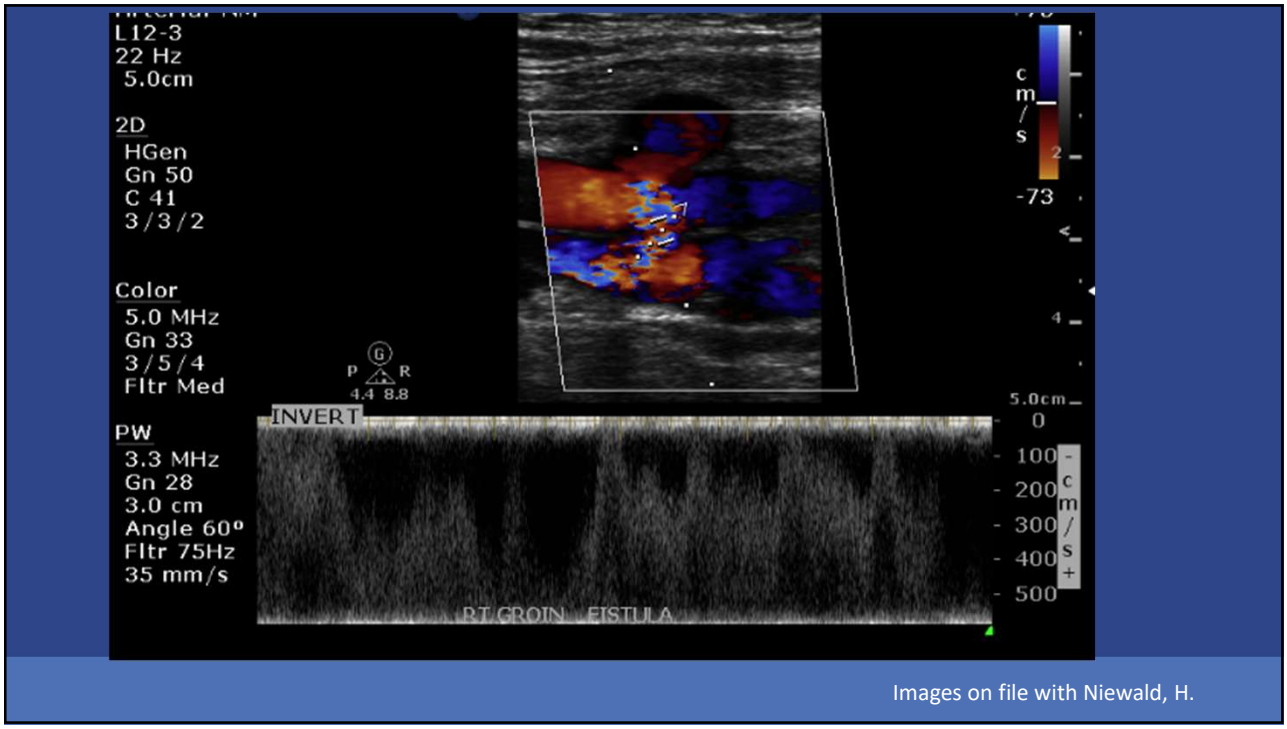

Images on file with Niewald, H.

20

© Copyright. Society of Diagnostic Medical Sonography. All Rights Reserved.

Obstacles in Ultrasound

- Use clues within your imaging
- Review any other imaging that you can compare to
- See something, say something

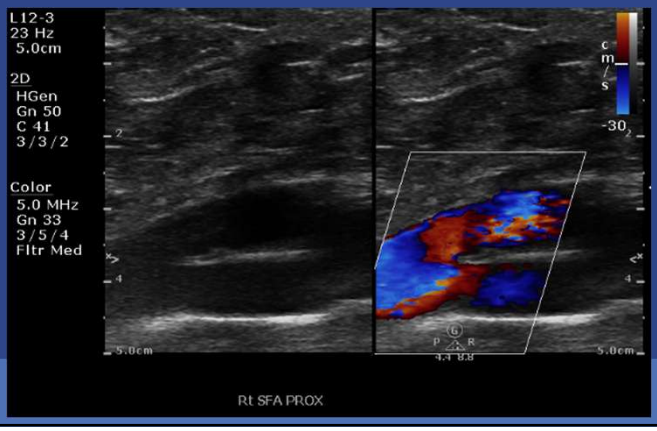

Images on file with Niewald, H.

21

Case 2

22

© Copyright. Society of Diagnostic Medical Sonography. All Rights Reserved.

Background

- Female in 80's seen after a ground level fall no symptoms
- Obtained an ankle fracture and right frontal soft tissue swelling
- No evidence of intracranial hemorrhage
- Temporal artery ultrasound obtained.
- Pseudoaneurysm noted off the distal temporal artery measuring 1.12 x 1.16cm (active flow .73cm x .65cm)

23

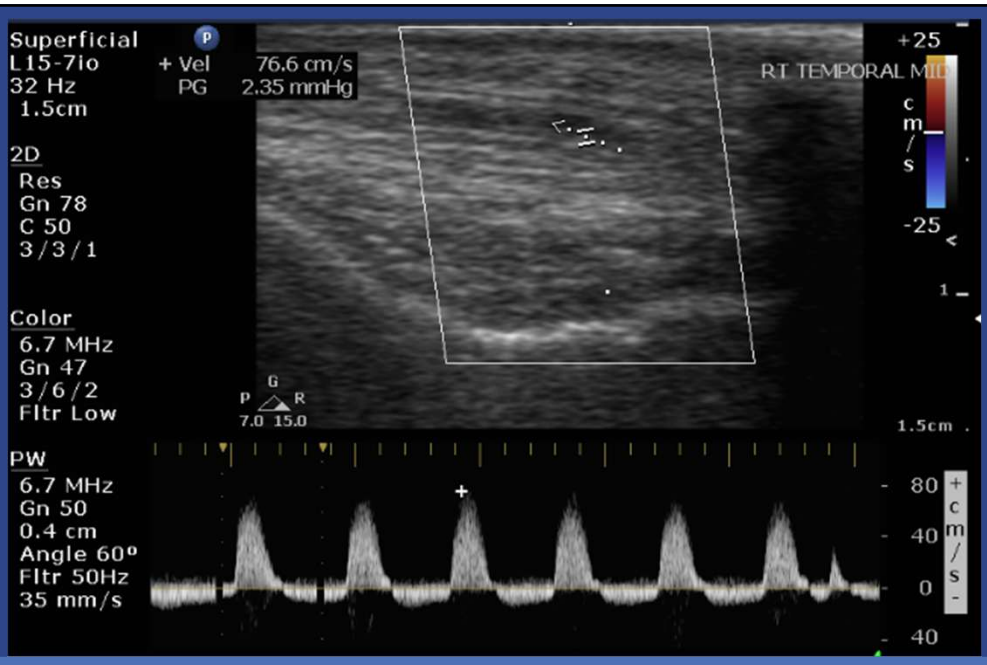

Images on file with Niewald, H.

24

© Copyright. Society of Diagnostic Medical Sonography. All Rights Reserved.

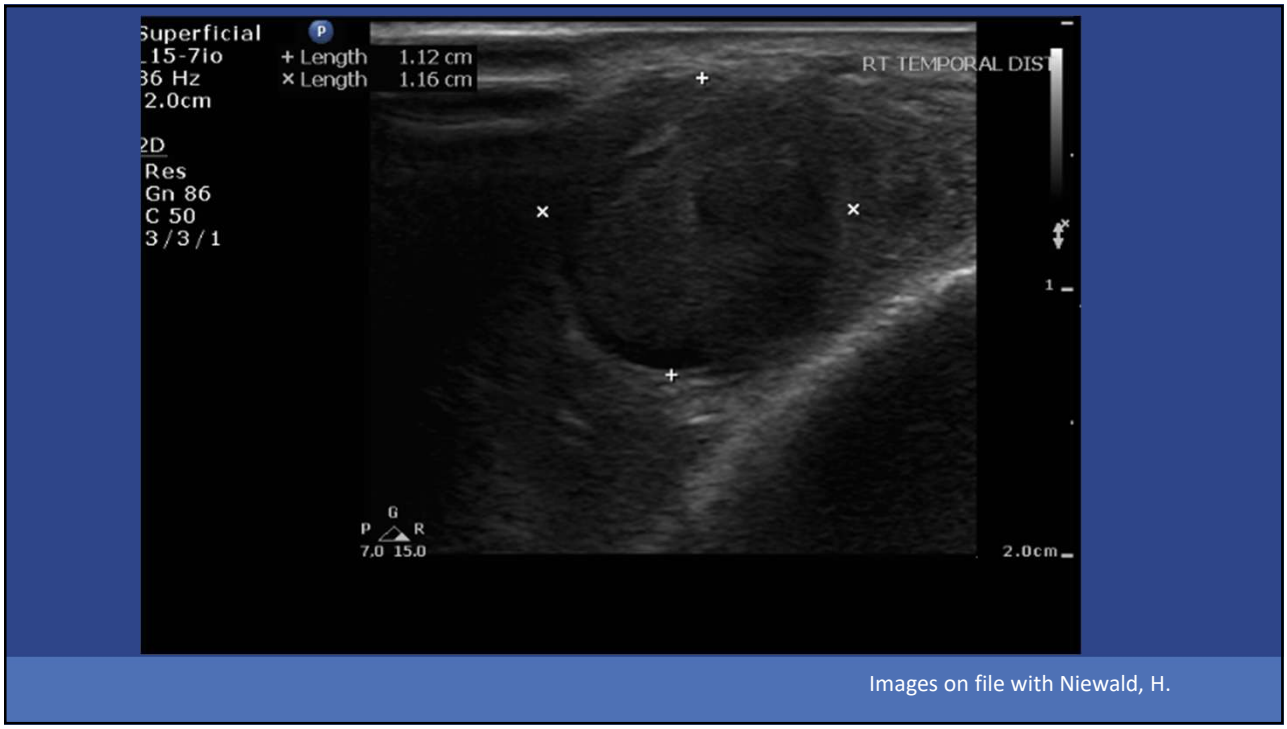

Images on file with Niewald, H.

25

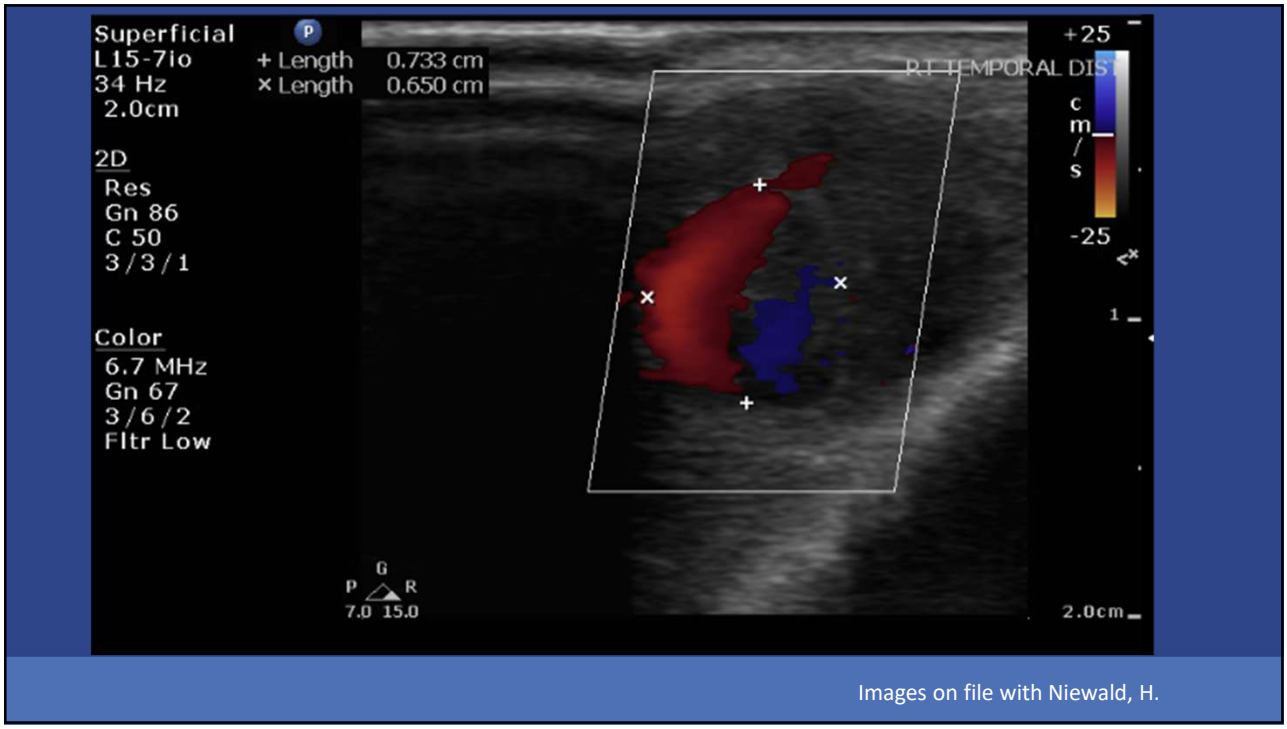

Images on file with Niewald, H.

26

© Copyright. Society of Diagnostic Medical Sonography. All Rights Reserved.

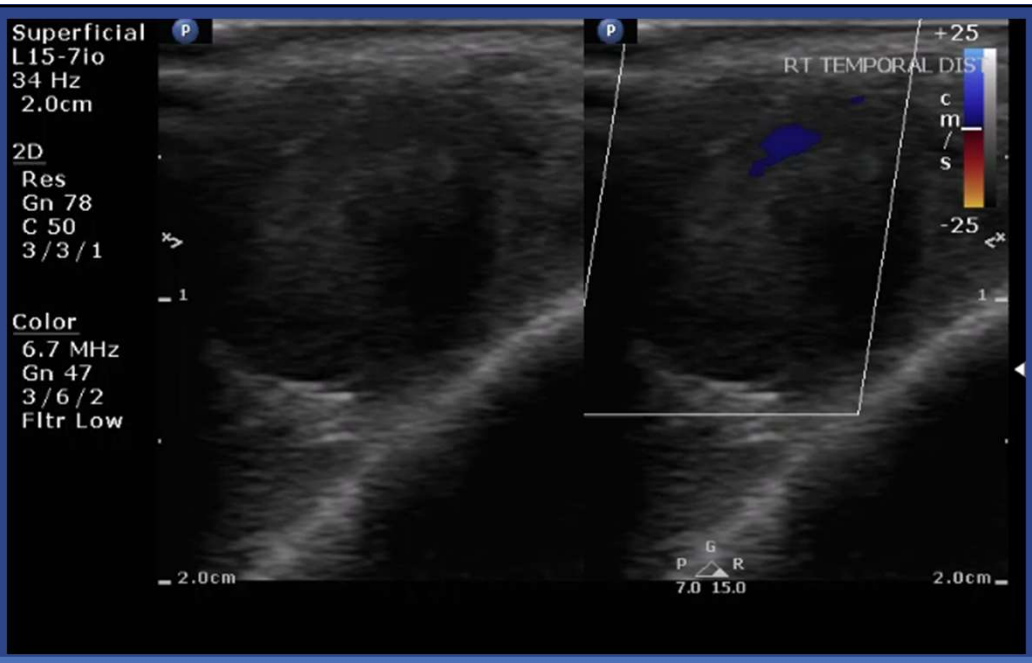

Images on file with Niewald, H.

27

Treatment

- Resection of pseudoaneurysm and evacuation of hematoma
- Nerve bundles present in temple and cheek

28

© Copyright. Society of Diagnostic Medical Sonography. All Rights Reserved.

Case 3

29

Background

- Female late twenties
- History of hypotension and anemia.
- Presented at outside hospital for elective thyroidectomy
- Went into ventricular tachycardia (VT) for 15 seconds and cardiogenic shock
- Abnormal CT showed large vessel vasculitis including carotids and subclavian artery
- Diagnosed with Takyasu's Disease

30

© Copyright. Society of Diagnostic Medical Sonography. All Rights Reserved.

What is Takyasu's disease?

- Type of vasculitis (likely autoimmune condition)
- Commonly of the aorta and it's primary branches
- Leads to thickened walls which narrows the blood vessels
  - Subclavian arteries in 90% of cases
  - Common Carotid Artery (CCA) in 60% of cases
- Affects mainly females younger than 40
- Most common in Asia
- Symptoms include: vertigo, transient ischemic attack (TIA), upper extremity claudication
- Can lead to high blood pressure, heart failure or stroke

31

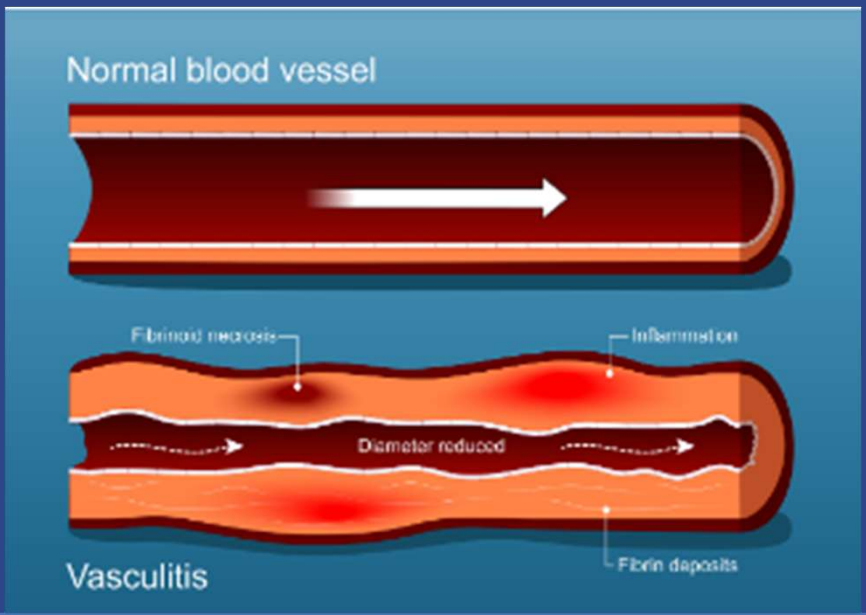

Image [10]

32

© Copyright. Society of Diagnostic Medical Sonography. All Rights Reserved.

Case 3 Continued

- Initial carotid duplex
- Thickened walls with <50% narrowing in bilateral CCA's
- Bilateral Internal Carotid Arteries (ICA) with low flow but no narrowing
- Bilateral subclavian arteries with monophasic flow indicating a proximal obstruction

33

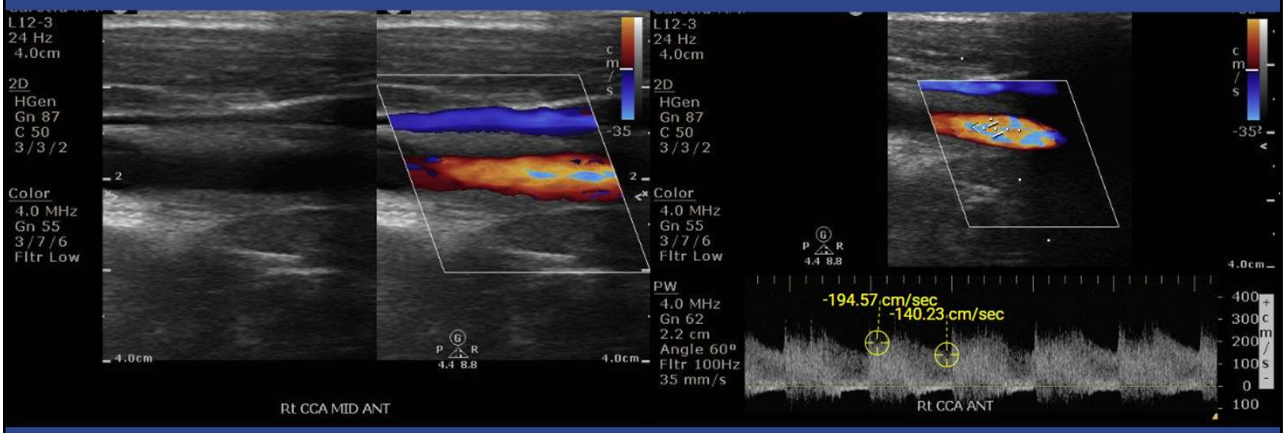

Images on file with Niewald, H.

34

© Copyright. Society of Diagnostic Medical Sonography. All Rights Reserved.



Images on file with Niewald, H.

35

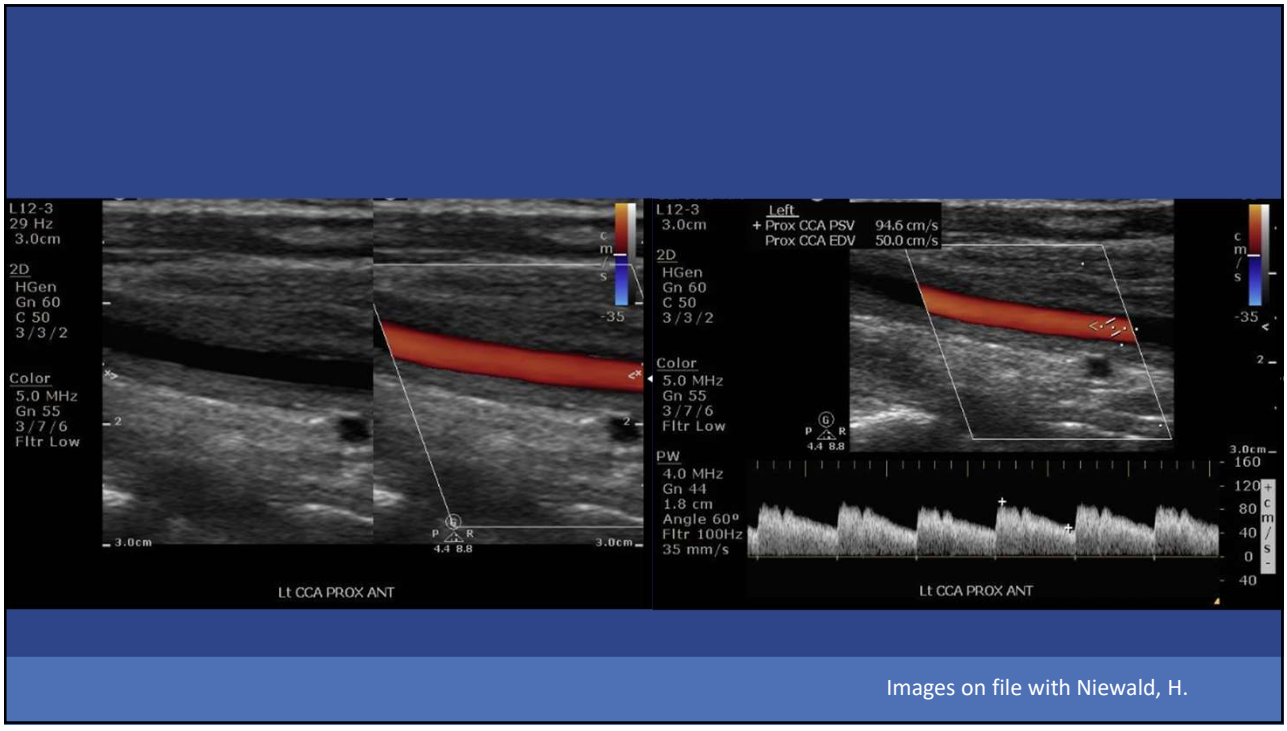

Images on file with Niewald, H.

36

© Copyright. Society of Diagnostic Medical Sonography. All Rights Reserved.

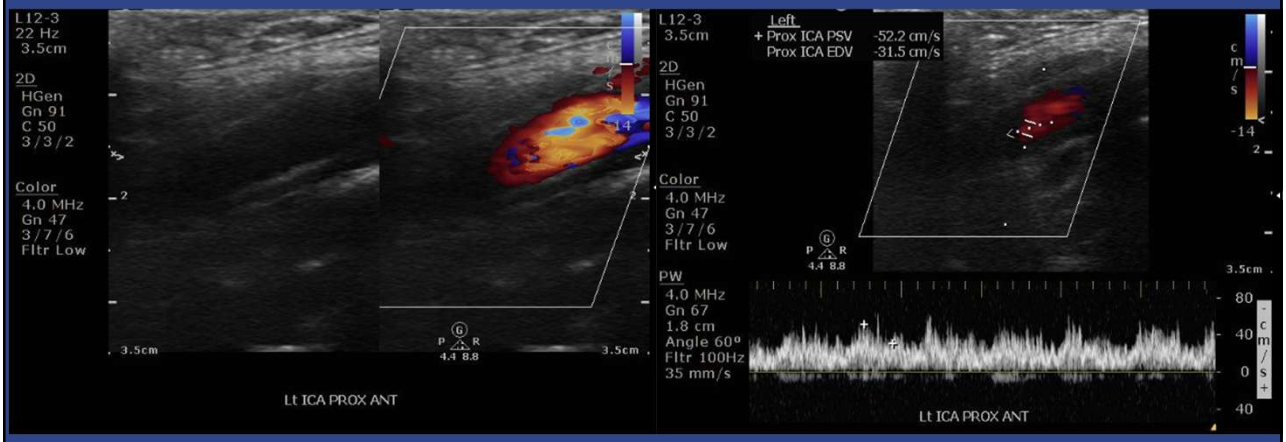

Images on file with Niewald, H.

37

- Ultrasound was repeated 9 months later
- TIA symptoms but no infarct noted on CTA
- Bilateral CCA's were >50% stenosed
- Bilateral ICA's were <50% stenosed
- Bilateral subclavian arteries had monophasic flow indicating a proximal obstruction.

- CTA showed right subclavian near occlusion and left subclavian occluded
- Bil CCA's with high grade stenosis

38

© Copyright. Society of Diagnostic Medical Sonography. All Rights Reserved.

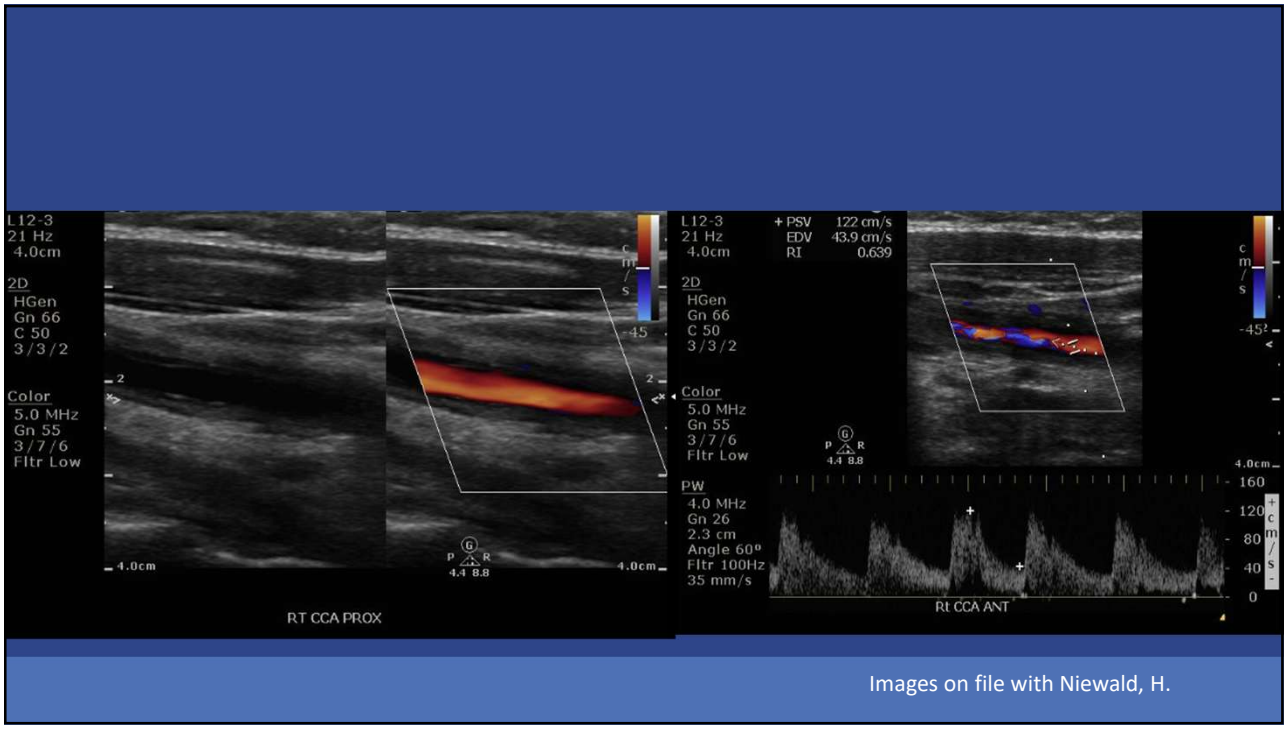

Images on file with Niewald, H.

39

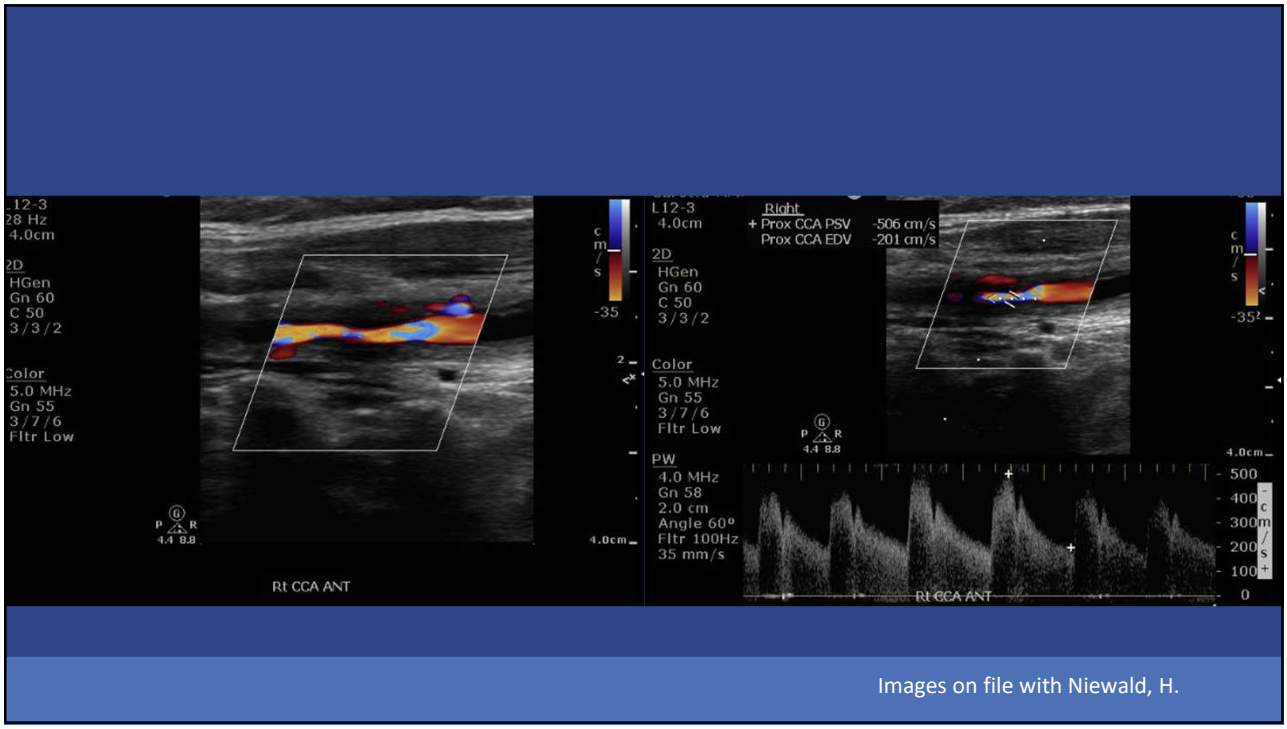

Images on file with Niewald, H.

40

© Copyright. Society of Diagnostic Medical Sonography. All Rights Reserved.

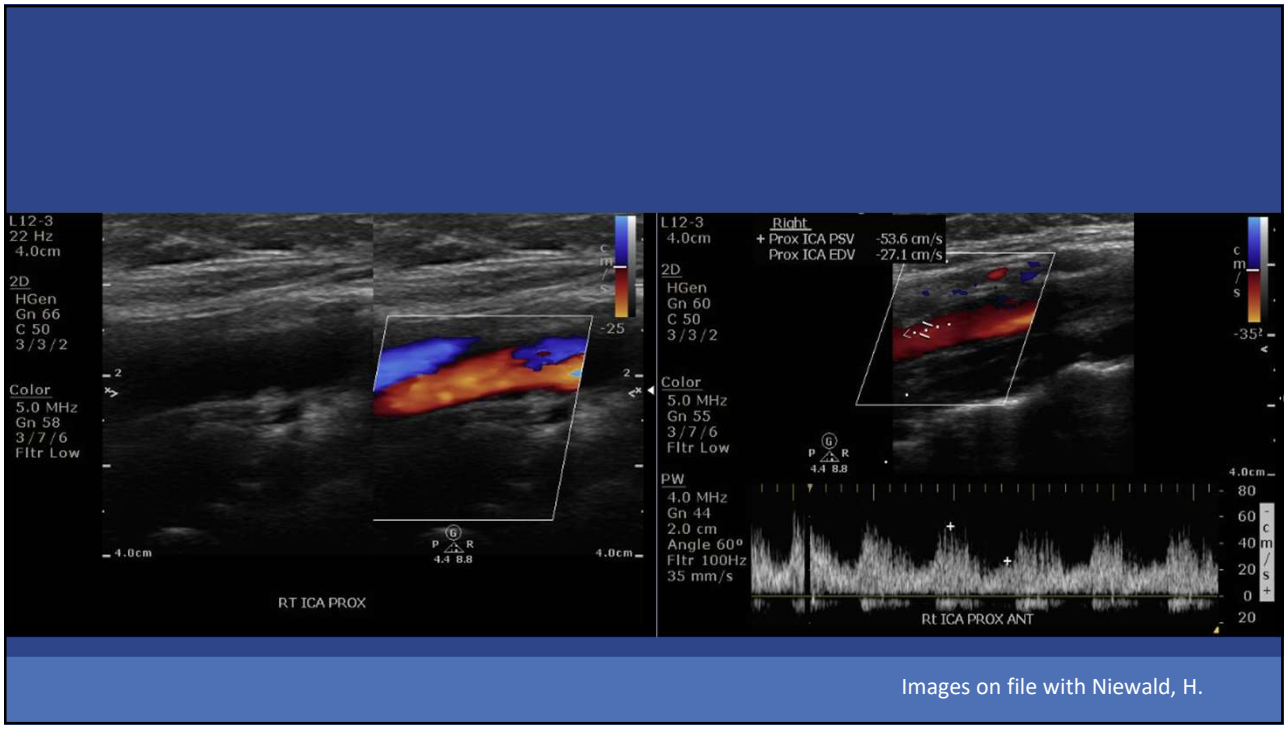

Images on file with Niewald, H.

41

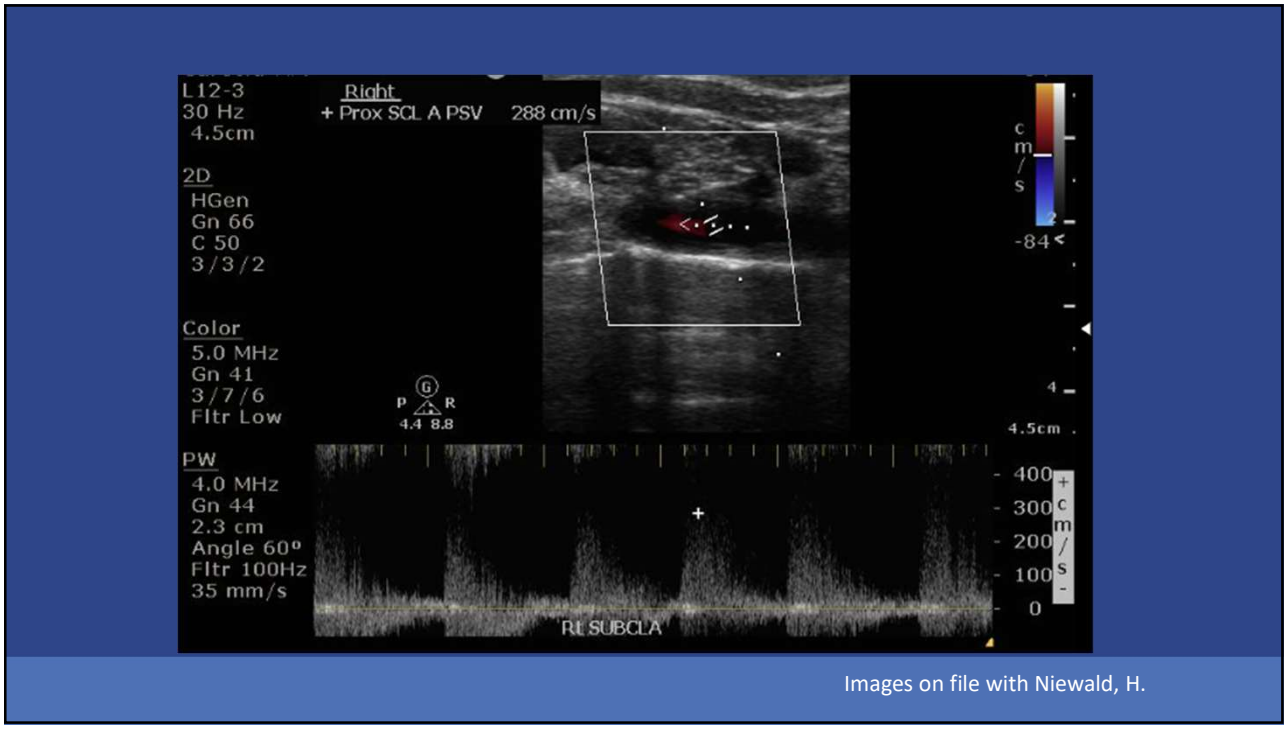

Images on file with Niewald, H.

42

© Copyright. Society of Diagnostic Medical Sonography. All Rights Reserved.

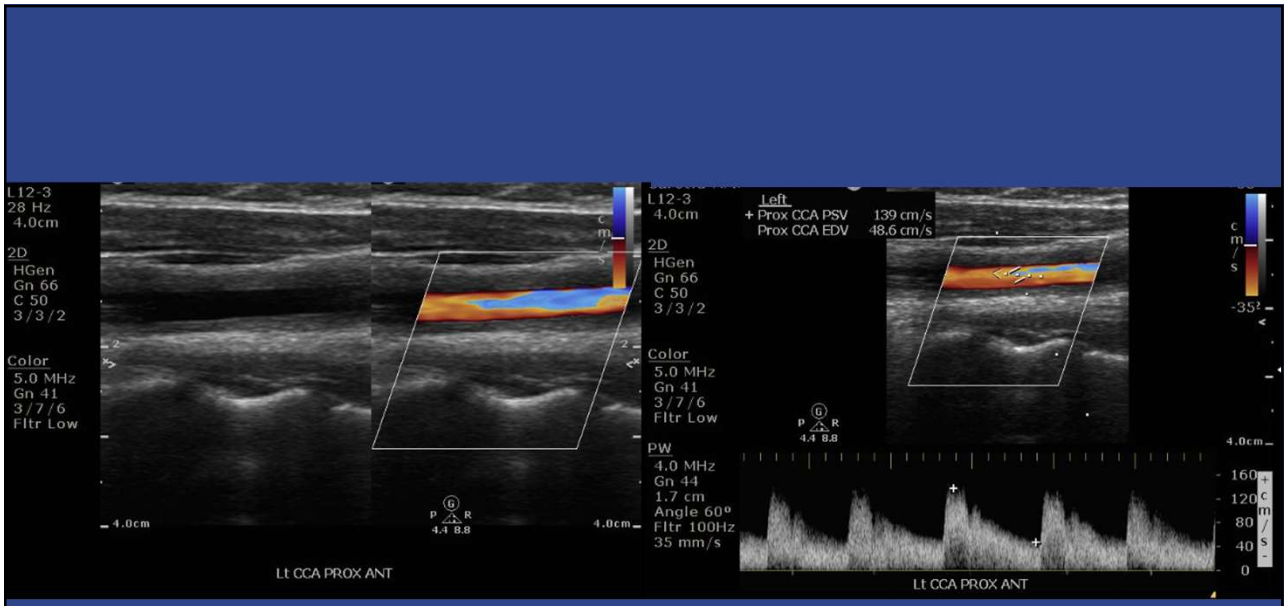

Images on file with Niewald, H.

43

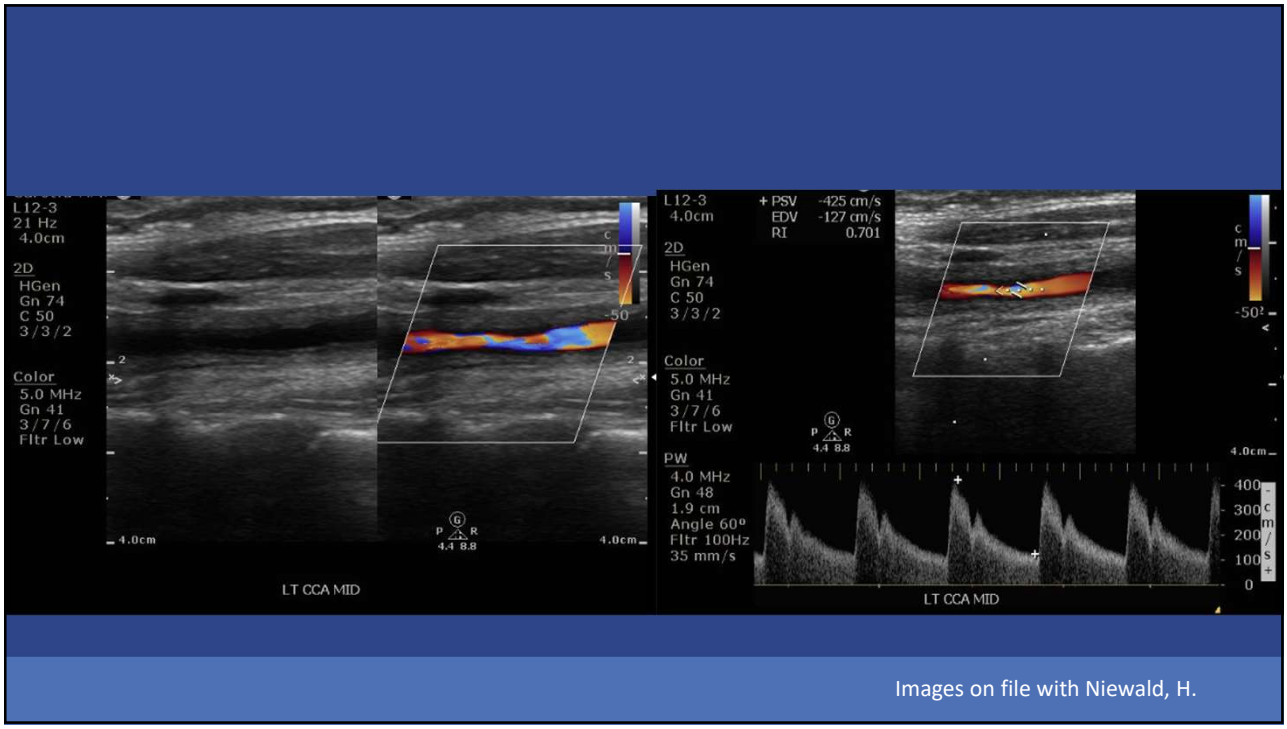

Images on file with Niewald, H.

44

© Copyright. Society of Diagnostic Medical Sonography. All Rights Reserved.

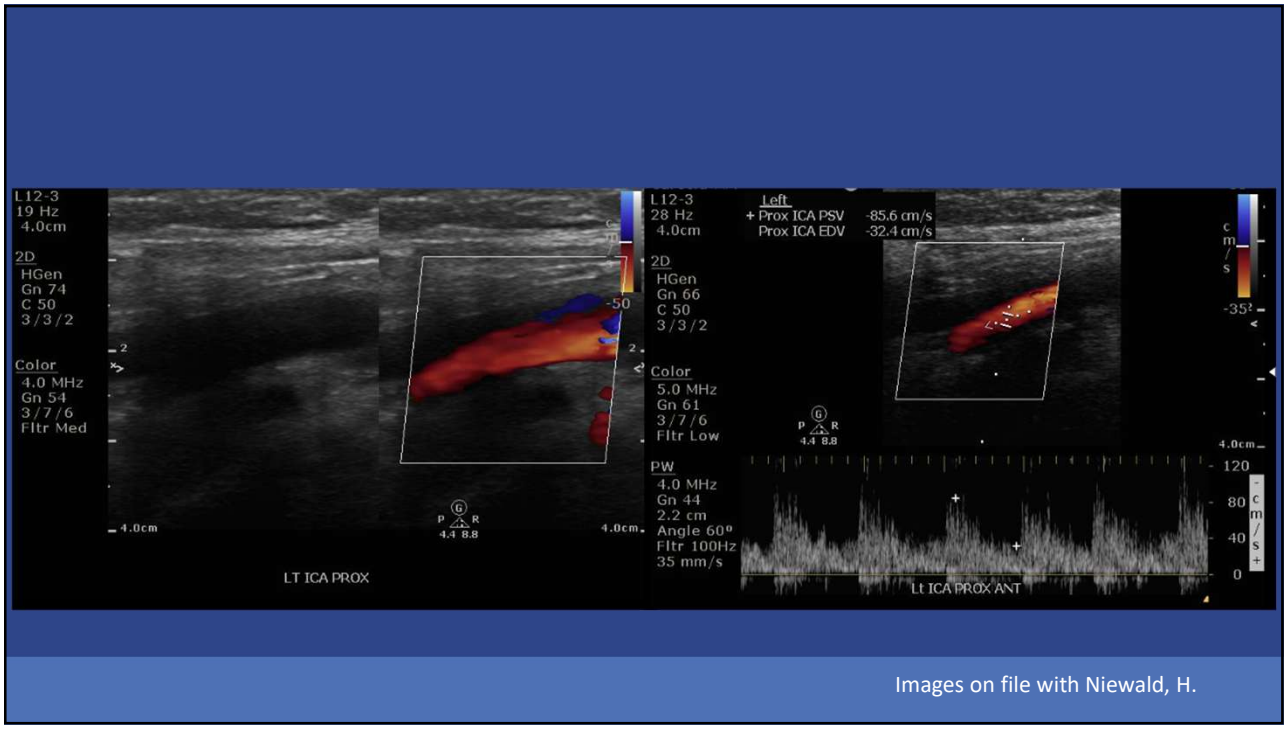

Images on file with Niewald, H.

45



Images on file with Niewald, H.

46

© Copyright. Society of Diagnostic Medical Sonography. All Rights Reserved.

Treatment

- Ultrasound results significantly changed over 9 months
- Vascular surgeon planned to continue anticoagulation and start Plavix
- Set up with Rheumatology for re-initiation of steroids

- Sonographer should call results of critical findings

47

Case 4

48

© Copyright. Society of Diagnostic Medical Sonography. All Rights Reserved.

Background

- Female in 70's presented with altered mental status and hypoxia
- Denied SOB or chest pain
- CTA found saddle pulmonary embolism (PE)
- Venous Doppler showed acute thrombus
- Patient underwent mechanical thrombectomy
- Went through right CFV for thrombectomy

49



Images on file with Niewald, H.

50

© Copyright. Society of Diagnostic Medical Sonography. All Rights Reserved.

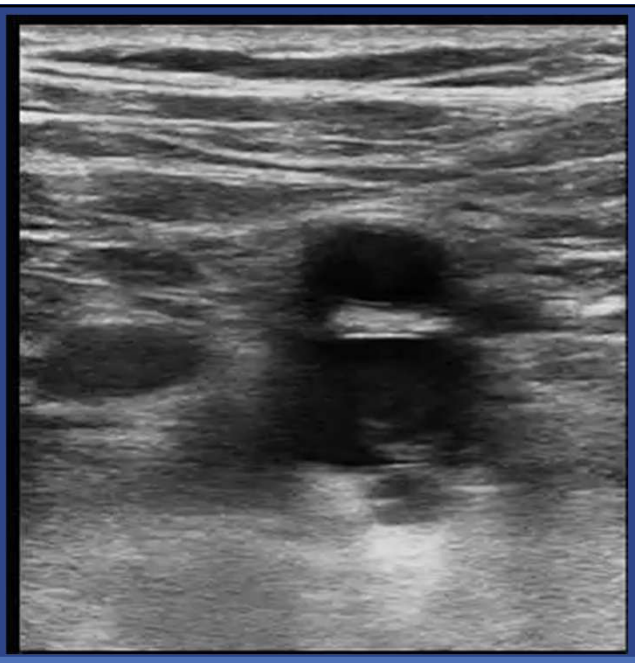

Images on file with Niewald, H.

51

Thrombectomy

- Surgical (open) or percutaneous (catheter) procedure to remove thrombus
- May need to be done within a few hours to days
- Important to decrease risk of causing thrombus elsewhere

52

© Copyright. Society of Diagnostic Medical Sonography. All Rights Reserved.

Thrombus From Right Pulmonary Artery



Images on file with Niewald, H.

53

Case 5

54

© Copyright. Society of Diagnostic Medical Sonography. All Rights Reserved.

Background

- Male in upper 50's with known malignancy
- Presented to the ER abdominal pain and weakness
- CT showed pulmonary embolism
- Ultrasound showed acute partial Deep Venous Thrombosis (DVT) in Popliteal vein and acute occluding thrombus of the Gastrocnemius and Peroneal veins. The Gastrocnemius vein thrombus was mobile

55

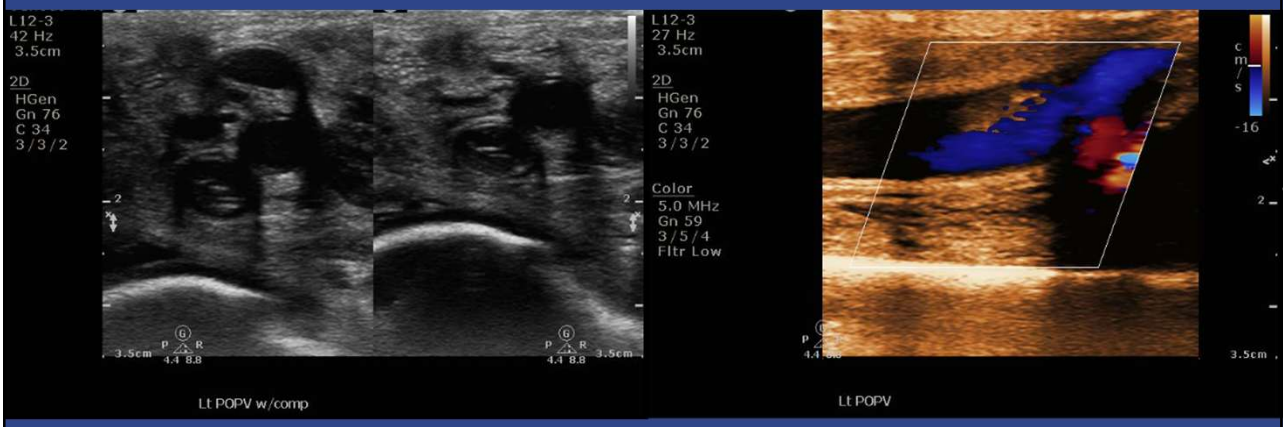

Images on file with Niewald, H.

56

© Copyright. Society of Diagnostic Medical Sonography. All Rights Reserved.

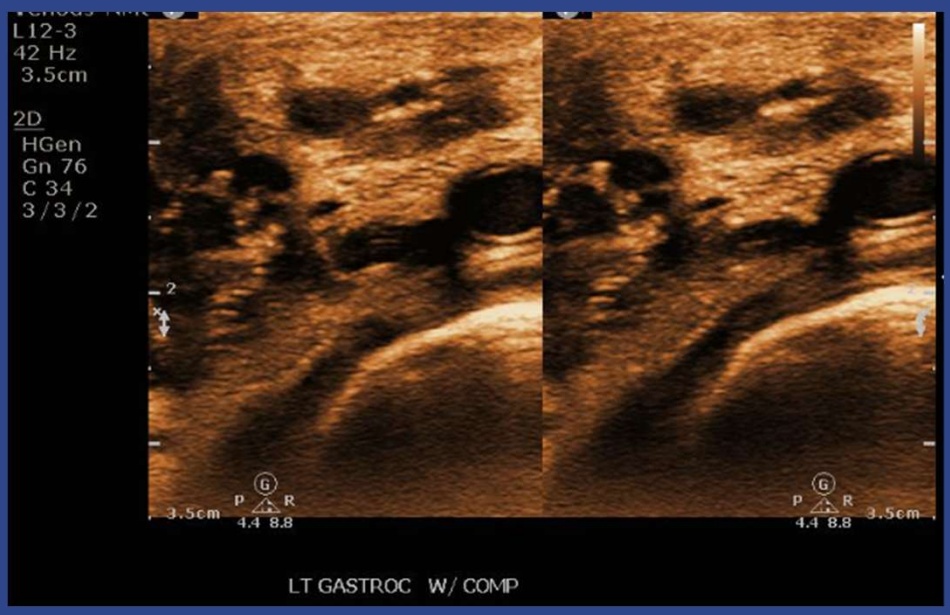

Images on file with Niewald, H.

57

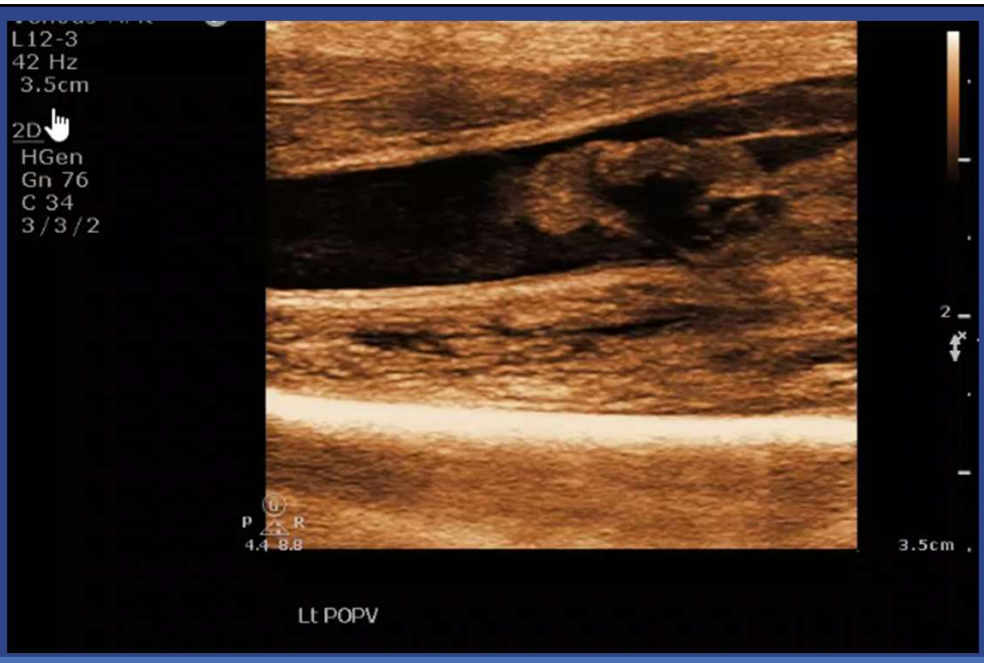

Images on file with Niewald, H.

58

© Copyright. Society of Diagnostic Medical Sonography. All Rights Reserved.

Treatment

- No IVC filter placed due to patient's lack of compliance and other medical issues as well as location of DVT
- Placed on anticoagulation

59

Case 6

60

© Copyright. Society of Diagnostic Medical Sonography. All Rights Reserved.

Background

- Male late 30's presented with acute onset of left arm pain
- History of fistula that had not been used in years
- No provoking event to cause pain
- Arterial duplex ultrasound images showed mobile ulnar artery thrombus, occlusion radial artery
- Venous duplex ultrasound showed thrombosed brachial cephalic fistula. No evidence of DVT elsewhere
- Venogram showed occlusion of the innominate vein

61

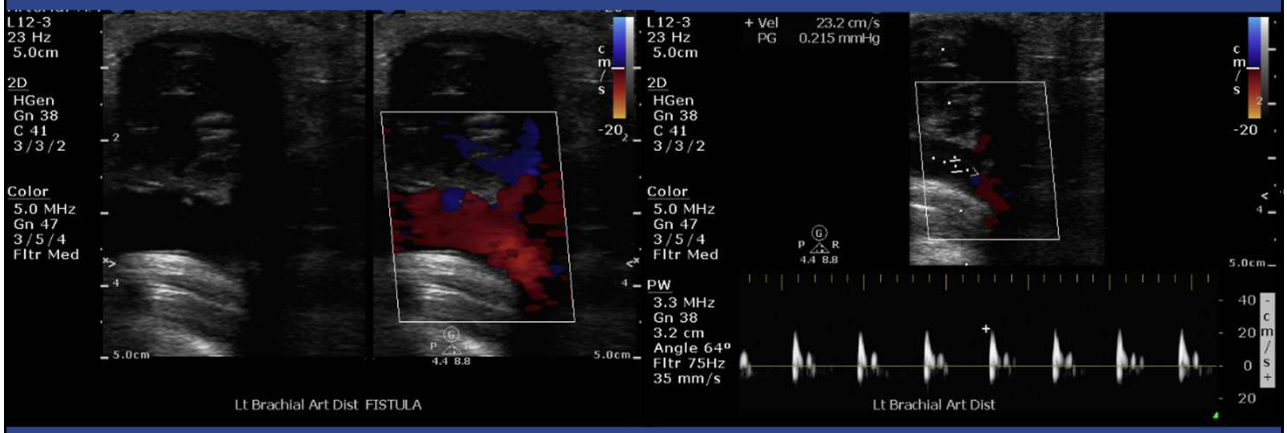

Images on file with Niewald, H.

62

© Copyright. Society of Diagnostic Medical Sonography. All Rights Reserved.



Images on file with Niewald, H.

63

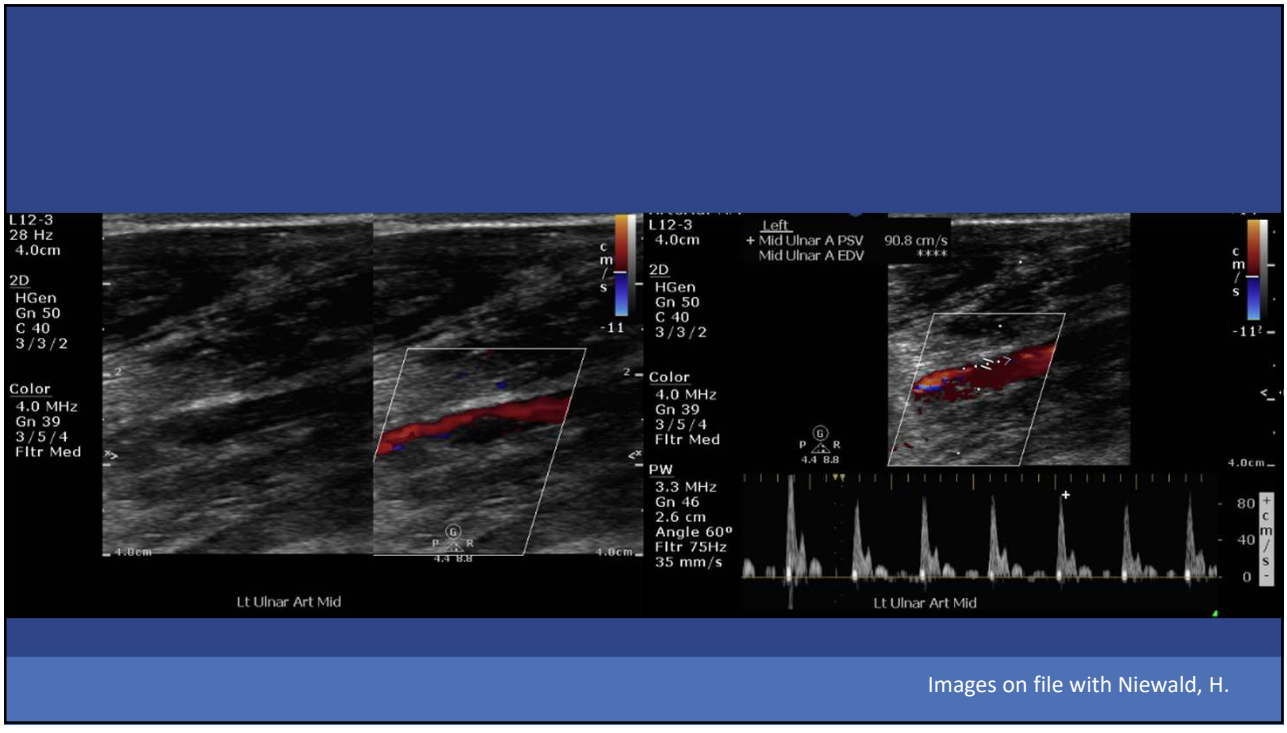

Images on file with Niewald, H.

64

© Copyright. Society of Diagnostic Medical Sonography. All Rights Reserved.

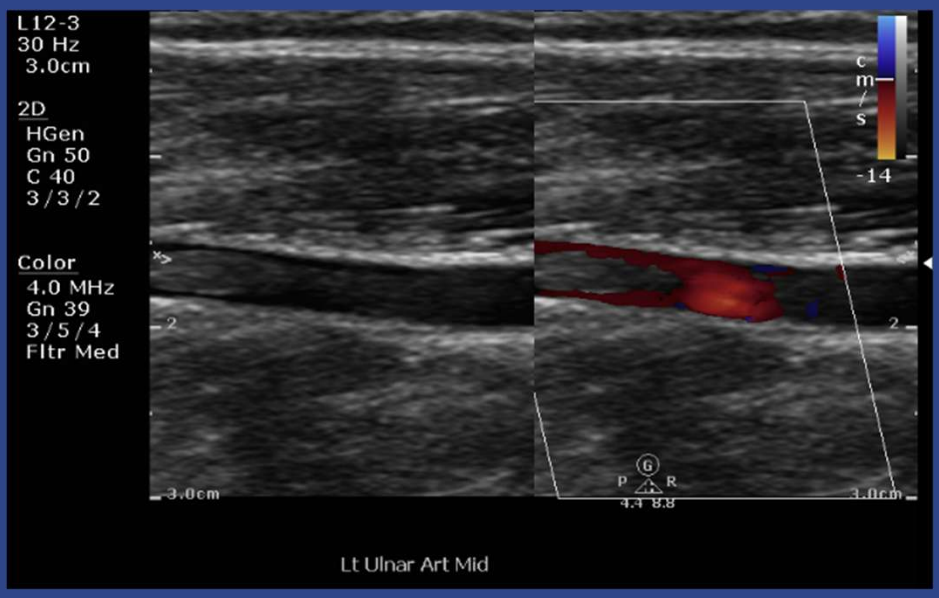

Images on file with Niewald, H.

65



Images on file with Niewald, H.

66

© Copyright. Society of Diagnostic Medical Sonography. All Rights Reserved.



Images on file with Niewald, H.

67

Treatment

- Patient was started on heparin, and Interventional Radiology performed a balloon angioplasty of the superior vena cava, innominate, and left subclavian vein.

68

© Copyright. Society of Diagnostic Medical Sonography. All Rights Reserved.

Case 7

69

Background

- Male in 50's presented to Family Medicine clinic with 3-week calf pain
- History of diabetes, hypertension, hyperlipidemia, and tobacco use
- Venous Doppler performed with negative results

70

© Copyright. Society of Diagnostic Medical Sonography. All Rights Reserved.

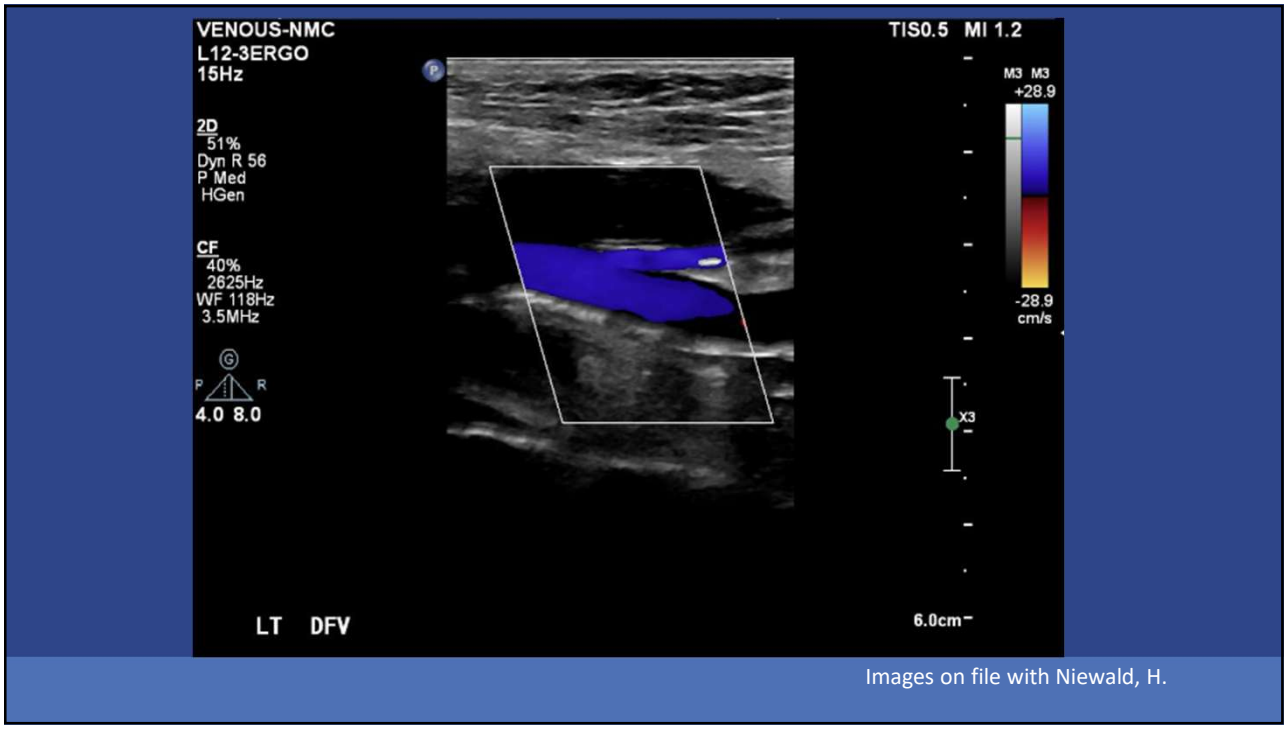

Images on file with Niewald, H.

71

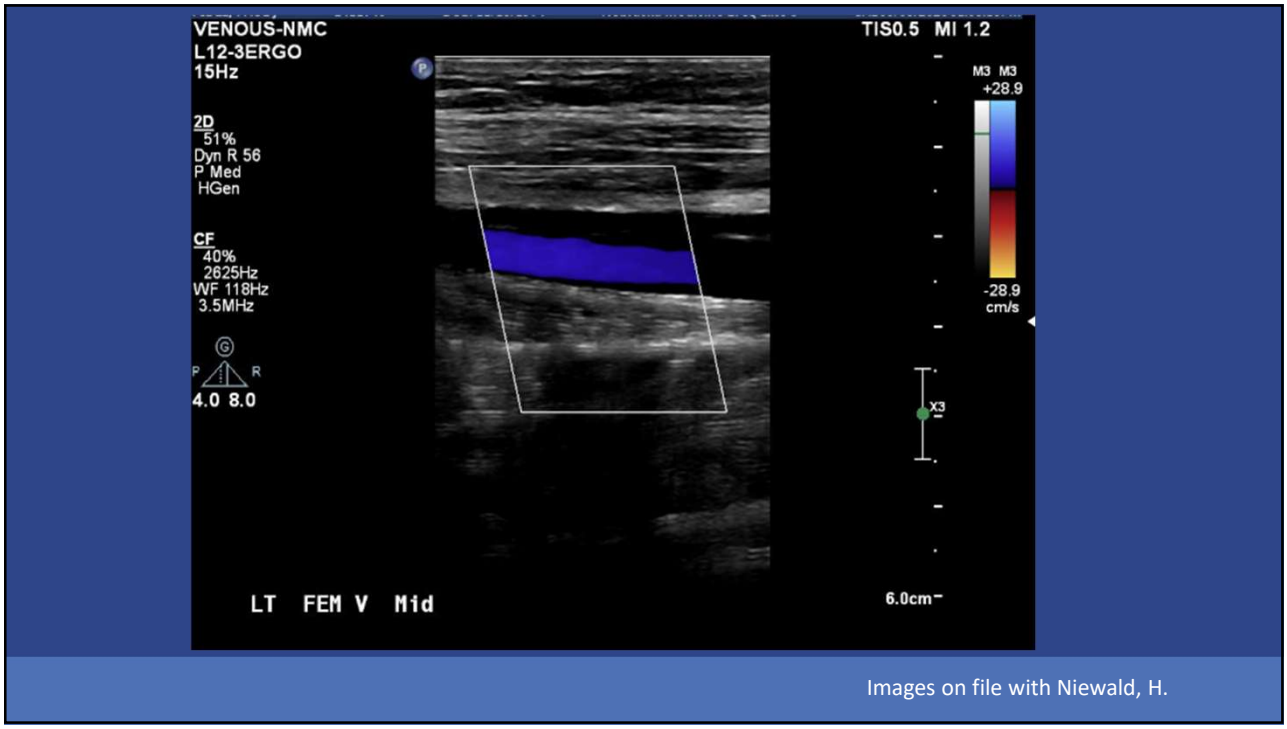

Images on file with Niewald, H.

72

© Copyright. Society of Diagnostic Medical Sonography. All Rights Reserved.

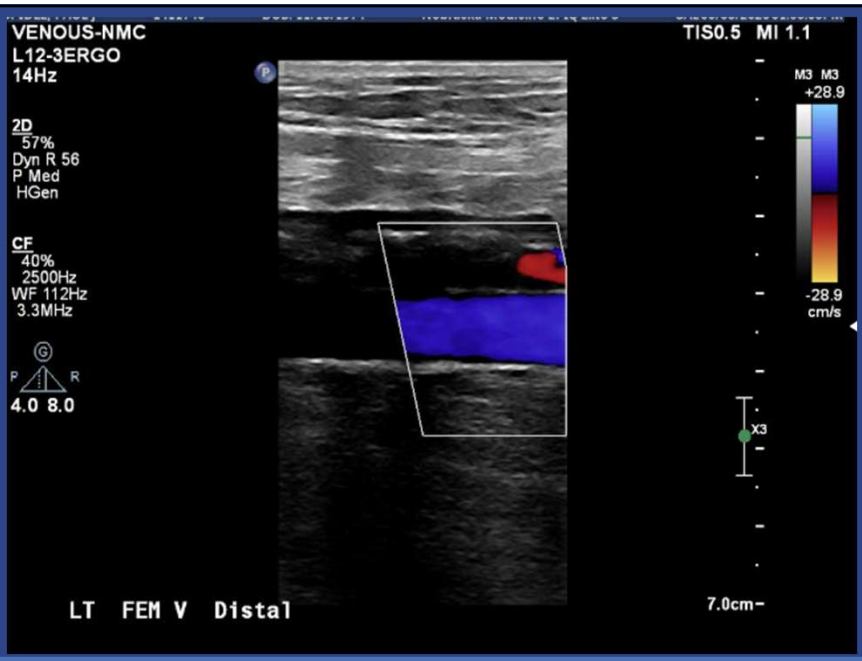

Images on file with Niewald, H.

73

- Next day Family Medicine ordered an ankle brachial index (ABI) and arterial duplex
- ABI results were Right 1.10 and Left .27
- Arterial duplex showed acute arterial thrombus of superficial femoral artery (SFA)
- CTA confirmed SFA occlusion
- Started on heparin
- Thrombolysis

74

© Copyright. Society of Diagnostic Medical Sonography. All Rights Reserved.

2026 SDMS Annual Conference

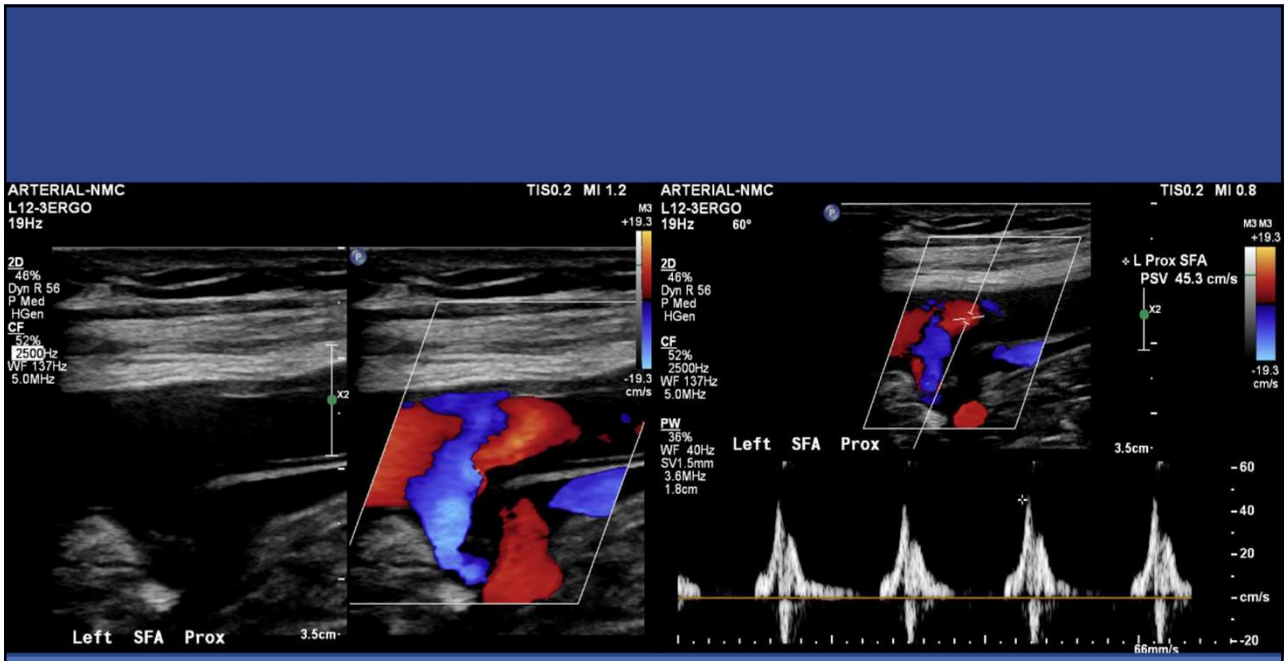

Images on file with Niewald, H.

75

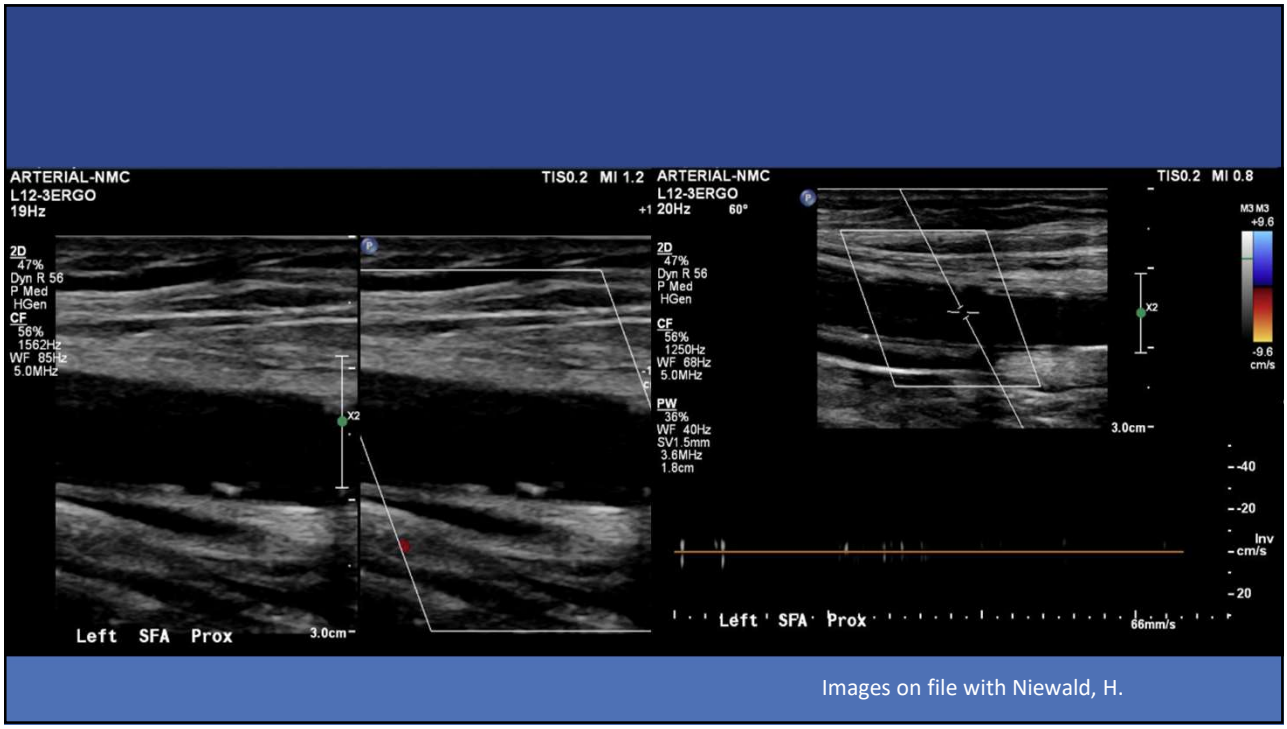

Images on file with Niewald, H.

76

© Copyright. Society of Diagnostic Medical Sonography. All Rights Reserved.

2026 SDMS Annual Conference

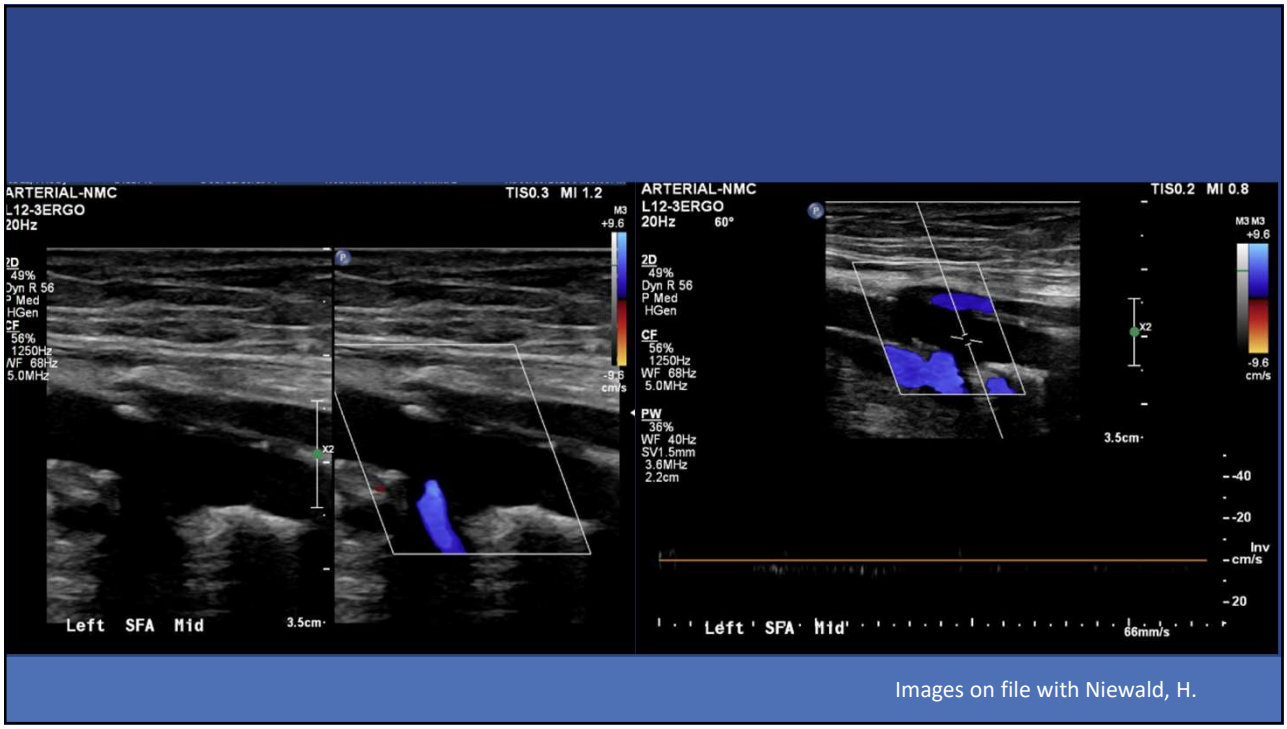

Images on file with Niewald, H.

77

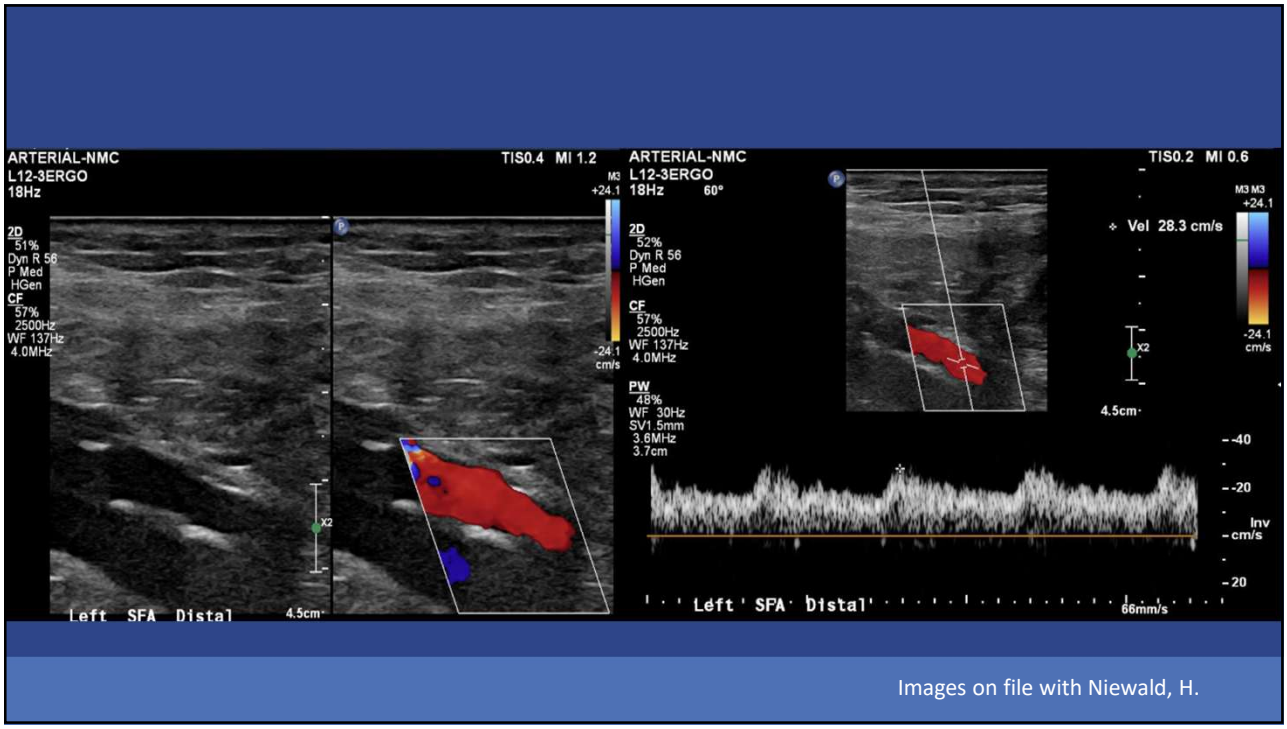

Images on file with Niewald, H.

78

© Copyright. Society of Diagnostic Medical Sonography. All Rights Reserved.

Two-Week Follow-up

- Arterial duplex was ordered by vascular surgery
- Showed patent SFA with multiphasic flow

79

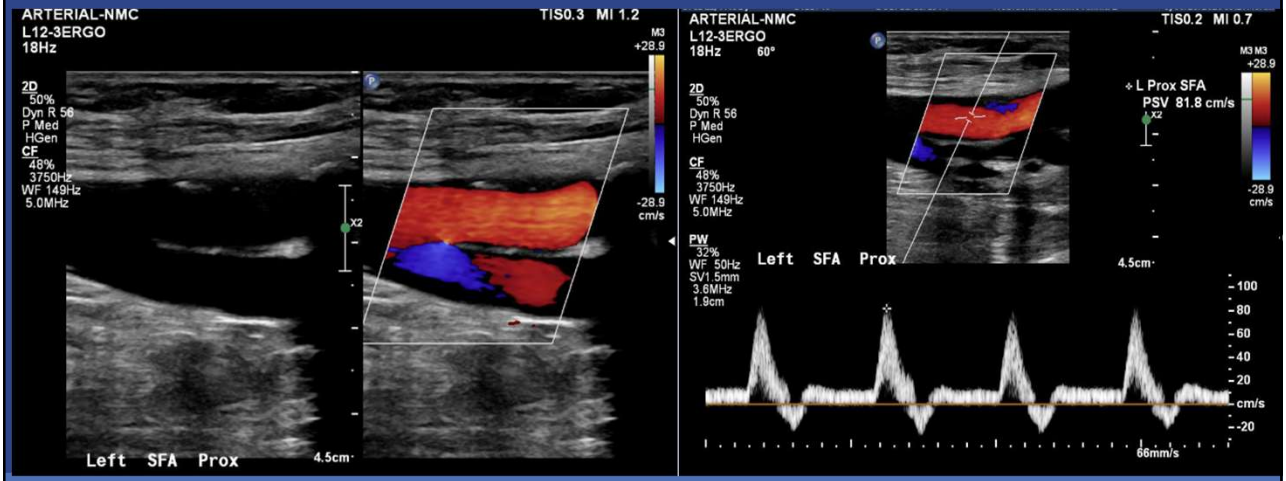

Images on file with Niewald, H.

80

© Copyright. Society of Diagnostic Medical Sonography. All Rights Reserved.

2026 SDMS Annual Conference

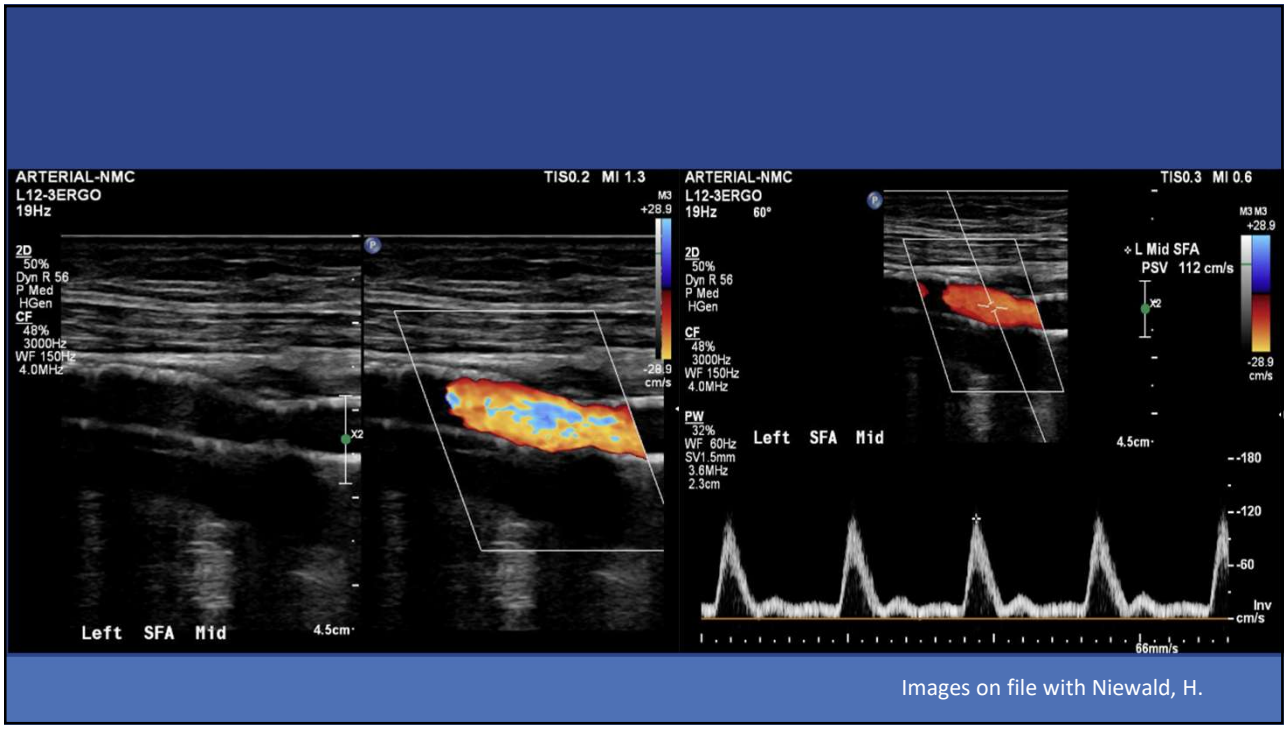

Images on file with Niewald, H.

81

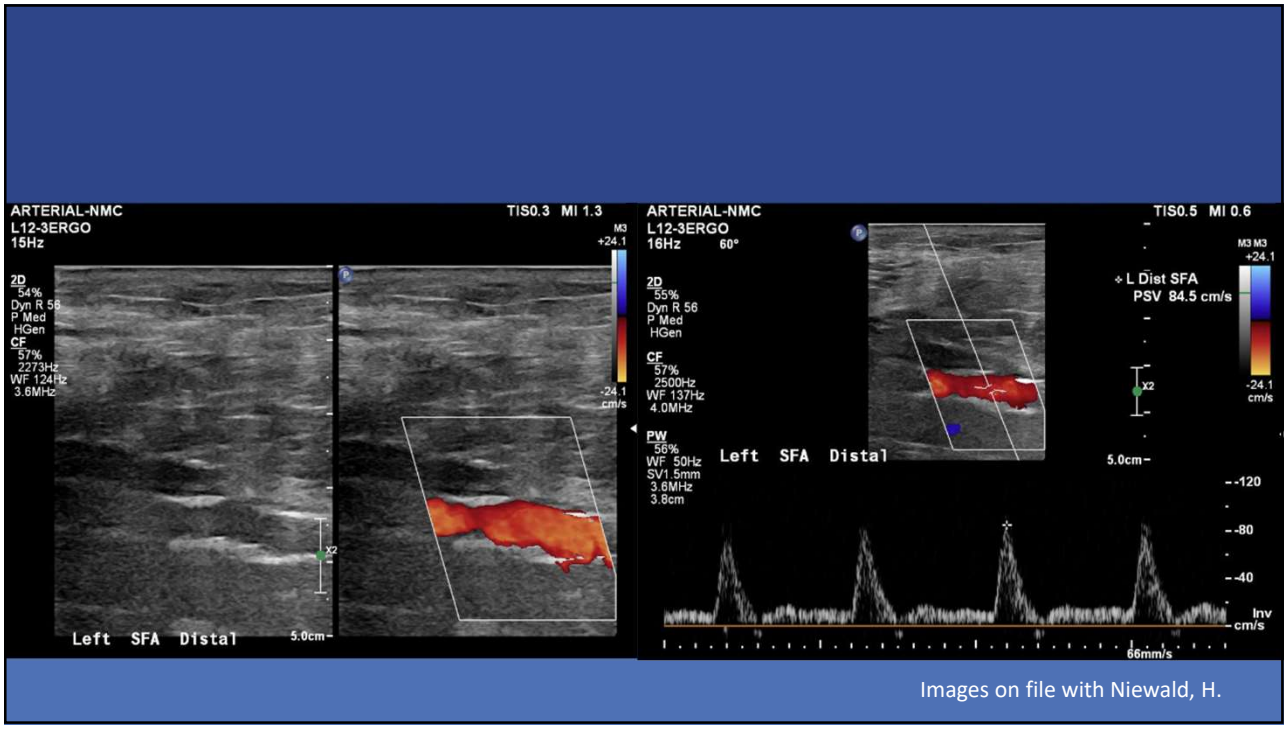

Images on file with Niewald, H.

82

© Copyright. Society of Diagnostic Medical Sonography. All Rights Reserved.

Conclusion

- Sonographers aren't just picture takers
- Role is to critically think through the whole case
- Communicate significant findings with the provider

Think about what kind of sonographer you want to be:
A Doer or a Thinker

83

Questions?

84

© Copyright. Society of Diagnostic Medical Sonography. All Rights Reserved.

Citations

1. Bin Dahmash, A., Al Qahtani, A., & Alshehri, S. (2020). Angio-seal-assisted closure of femoral arterial pseudoaneurysm in a case of uncorrectable coagulation and potential allergy to thrombin. *The Arab Journal of Interventional Radiology*, *4*(2), 138–140. https://doi.org/10.4103/ajir.ajir_13_20

2. Dudzińska-Szczerba K, Piotrowski R, Zaborska B, et al. Iatrogenic Arteriovenous Fistula and Atrial Septal Defect Following Cryoballoon Ablation for Atrial Fibrillation – Two Correctable Causes of Right Heart Failure. *American Journal of Case Reports*2019;20:971-974. doi:10.12659/ajcr.916205

3. Fukudome Y, Abe I, Onaka U, Fujii K, Ohya Y, Fukuhara M, et al. Regression of carotid wall thickening after corticosteroid therapy in Takayasu's arteritis evaluated by B-mode ultrasonography: report of 2 cases. J Rheumatol. 1998 Oct;25(10) 2029-2032. PMID: 9779864.

85

Citations

4. Scope of Practice and Clinical Standards for the Diagnostic Medical Sonographer. *Journal of Diagnostic Medical Sonography*2015;31(4):198-209. doi:10.1177/8756479315593311

5. Cleveland Clinic. *Thrombectomy: What It Is and Procedure Details.* 2022. Accessed August 17, 2026. https://my.clevelandclinic.org/health/treatments/22897-thrombectomy

6. *Arteriovenous (AV) Fistula: Symptoms & Treatment*. Accessed August 17, 2026. https://my.clevelandclinic.org/health/diseases/23450-arteriovenous-fistula

7. *What is a pseudoaneurysm?* (2026) *Cleveland Clinic*. Available at: https://my.clevelandclinic.org/health/diseases/23250-pseudoaneurysm (Accessed: 17 August 2026).

8. Kupinski, AM. *The Vascular System*. Third Edition. Lippincott Williams & Wilkins; 2013

9. Dudzińska-Szczerba K, Piotrowski R, Zaborska B, et al. Iatrogenic Arteriovenous Fistula and Atrial Septal Defect Following Cryoballoon Ablation for Atrial Fibrillation – Two Correctable Causes of Right Heart Failure. *American Journal of Case Reports*2019;20:971-974. doi:10.12659/ajcr.916205

86

© Copyright. Society of Diagnostic Medical Sonography. All Rights Reserved.

Citations

10. *Malformations of the blood vessels and Vasculitis*. Greater Waterbury Imaging Center. (2025, November 25). https://greaterwaterburyimagingcenter.org/magnetic-resonance-imaging/body-mri/malformations-of-the-blood-vessels-and-vasculitis/

11. Contributors WE. What Is Takayasu's Arteritis? WebMD. Accessed September 11, 2026. https://www.webmd.com/heart-disease/takayasus-arteritis

12. Inferior Vena Cava (IVC) Filter Placement and Removal. Yale Medicine. Accessed September 11, 2026. https://www.yalemedicine.org/conditions/ivc-filter-placement-and-removal

13. Lee HF, Su HC, Chuang C. Catheter-Directed Thrombolysis for Superficial Femoral Artery Thrombosis via the Ipsilateral Dorsalis Pedis Artery. *Acta Cardiol Sin*2024;40(5):656-658. doi:10.6515/ACS.202409_40(5).20240617B

14. Cleveland Clinic. Thrombolytics and Thrombolytic Therapy. Cleveland ClinicJune 12, 2022. Accessed September 11, 2026. https://my.clevelandclinic.org/health/treatments/23238-thrombolytics

© Copyright. Society of Diagnostic Medical Sonography. All Rights Reserved.