Autosomal Dominant vs. Recessive: A Review of Sonographic Manifestations

Jenna N. Laquerre, MEd, RT(R)(ARRT), RDMS (AB, OB/GYN, PS, BR), RVT
Program Director of Diagnostic Medical Sonography,
Program Director of Bachelor of Science in Medical Imaging,
Palm Beach State College

1

SPEAKER PRESENTATION DISCLAIMER

The content and views presented are made available for educational purposes only. The information presented are the opinions of the presenter and do not necessarily represent the views of the Society of Diagnostic Medical Sonography (SDMS) or its affiliated organizations, officers, Boards of Directors, or staff members.

The presenter is responsible for ensuring balance, independence, objectivity, scientific rigor, and avoiding commercial bias in their presentation. Before making the presentation, the presenter is required to disclose to the audience any relevant financial interests or relationships with manufacturers or providers of medical products, services, technologies, and programs.

The SDMS and its affiliated organizations, officers, Board of Directors, and staff members disclaim any and all liability for all claims that may arise out of the use of this educational activity.

2

© Copyright. Society of Diagnostic Medical Sonography. All Rights Reserved.

GENERATIVE AI DISCLAIMER

The presenter utilized the use of large language models (LLMs) and generative artificial intelligence (AI) as a productivity tool to assist in drafting and refining content in this presentation.

While these tools can aid in structuring ideas, summarizing, paraphrasing, and language polishing, they have inherent limitations and cannot replace human creativity, critical thinking, or expert judgment. AI-generated content may contain errors, biases, or gaps in knowledge.

This presentation is intended for informational purposes only and should not be construed as definitive or authoritative guidance. Participants are encouraged to critically evaluate the information presented and consult relevant experts as needed. The SDMS and its affiliated organizations, officers, Board of Directors, and staff members disclaim any and all liability for claims that may arise from the use or interpretation of this educational material.

3

Course Description

- This session provides an overview of autosomal dominant and autosomal recessive inheritance patterns with emphasis on sonographic relevance. Participants will review characteristic imaging findings across organ systems and explore how genetic patterns influence disease presentation. In this presentation we will review the role of family history, syndromic features, and abnormal findings in shaping scan strategy and documentation, supporting accurate interpretation and appropriate follow-up in clinical practice.

4

© Copyright. Society of Diagnostic Medical Sonography. All Rights Reserved.

Learning Objectives

- Define autosomal dominant and autosomal recessive inheritance patterns as they relate to sonographically assessable disease.
- Identify ultrasound findings associated with selected autosomal dominant and recessive conditions to support pattern recognition.
- Explain how family history, clinical presentation, and syndromic features influence scan strategy and diagnostic considerations.

5

The Pattern Beneath the Image

- Sonography demonstrates the **phenotype**, which is the observable features that may reflect an underlying genetic disorder.
- A finding in one organ system may be isolated; abnormalities across multiple systems may suggest a broader syndrome or genetic process.
- Inheritance pattern and family history provide the clinical context that can help refine what we look for and how we document the examination.



USDAgov, Public domain, via Wikimedia Commons

6

© Copyright. Society of Diagnostic Medical Sonography. All Rights Reserved.

An Overview of Genetics

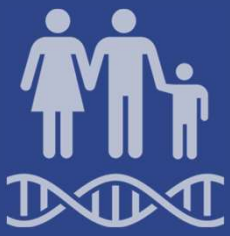

- **Genes** are units of inherited information carried within DNA and organized along chromosomes.
- An **allele** is one version of a DNA sequence at a particular genomic location; one allele is generally inherited from each parent.
- A **genetic variant** is a difference in DNA sequence. Variants may be benign, pathogenic, or have uncertain clinical significance.
- The location and behavior of a pathogenic variant helps to determine its inheritance pattern.

https://commons.wikimedia.org/wiki/File:Genetics_-_The_Noun_Project.svg

7

What Does "Autosomal" Mean?

Humans normally have **22 pairs of autosomes**, numbered chromosomes 1–22, plus one pair of sex chromosomes.

An autosomal disorder results from a gene located on one of these numbered chromosomes rather than the X or Y chromosome.

Because the gene is autosomal, **males and females can both inherit and transmit the condition**.

Autosomal inheritance can include transmission from father to son, which helps distinguish it from X-linked inheritance.

8

© Copyright. Society of Diagnostic Medical Sonography. All Rights Reserved.

Autosomal Dominant Inheritance

- An autosomal dominant disorder can occur when **one copy of a gene contains a pathogenic variant**.
- Affected individuals are commonly **heterozygous**, carrying one altered allele and one other allele.
- Familial disease often produces a **vertical pattern**, with affected individuals in successive generations.
- With one heterozygous affected parent and one unaffected parent, each pregnancy typically has a **50% chance of inheriting the pathogenic variant**.

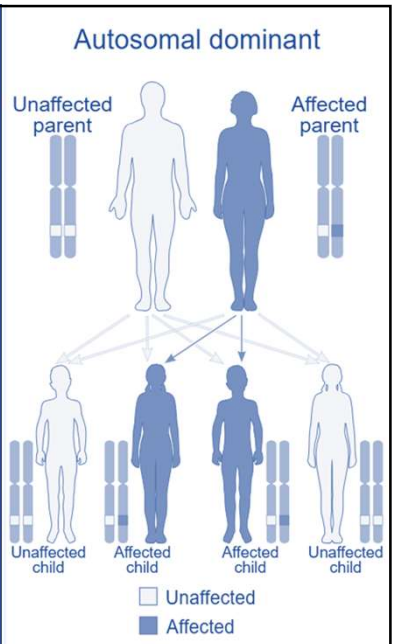

Domaina, CC BY-SA 3.0 <https://creativecommons.org/licenses/by-sa/3.0>, via Wikimedia Commons

9

Dominant Does Not Always Mean Obvious

- **Reduced penetrance:** a person may carry the pathogenic variant without demonstrating recognizable manifestations.
- **Variable expressivity:** this means individuals with the same disorder may have different findings or markedly different disease severity.
- **De novo variants** can produce an affected individual without a previous family history.
- Some disorders demonstrate **age-dependent expression**, so findings may not be present early in life.

10

© Copyright. Society of Diagnostic Medical Sonography. All Rights Reserved.

Autosomal Recessive Inheritance

- Autosomal recessive disease generally requires **pathogenic variants affecting both copies of the gene**.
- An affected individual may be **homozygous** for the same variant or **compound heterozygous** for two different pathogenic variants in the same gene.
- Parents of an affected child are often clinically unaffected **carriers**.
- When both parents are carriers: **25% affected, 50% carrier, and 25% neither affected nor a carrier** (unaffected) with each pregnancy.

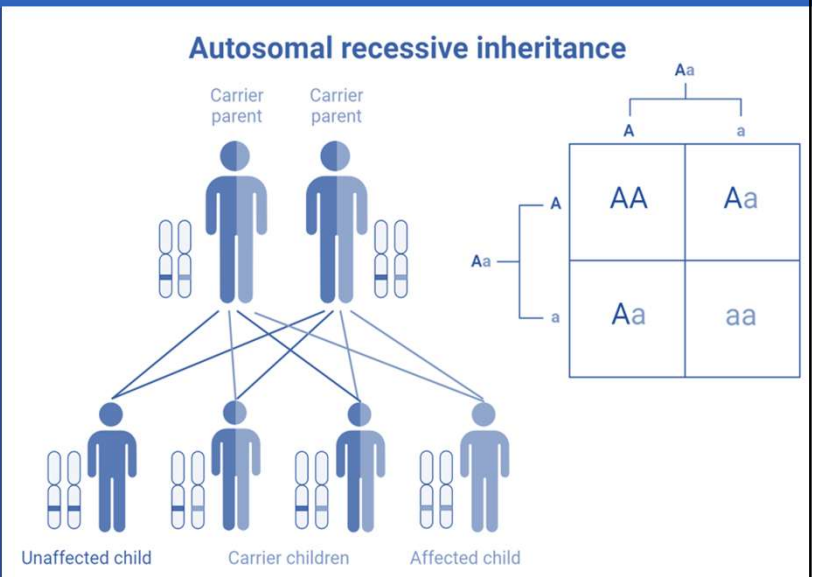

https://www.biorender.com/template/autosomal-recessive-inheritance

11

Autosomal Recessive Disease May Skip Generations

Autosomal recessive disorders commonly demonstrate a **horizontal family pattern**, with affected siblings and unaffected parents.

Disease may appear without a known family history because carriers usually do not demonstrate the full phenotype.

Consanguinity increases the probability that both parents may carry the same rare pathogenic variant.

Severe recessive disorders may present prenatally or during childhood, although recessive inheritance itself does not determine age of onset.

12

© Copyright. Society of Diagnostic Medical Sonography. All Rights Reserved.

Gathering a Family History

- The sonographer should ask the patient about **known genetic diagnoses** and family histories (e.g., renal failure or transplant, cystic kidney or liver disease, recurrent pancreatitis, and unexplained infant or childhood deaths when genetic disease process is suspected).
- Clarify **which relative was affected**, the age at diagnosis, and major complications such as dialysis, transplantation, or premature death.
- Family history can reveal a recognizable inheritance pattern and change the significance of an otherwise nonspecific sonographic finding.
- A negative family history does **not** exclude inherited disease because de novo variants and reduced penetrance can occur.



https://www.pexels.com/photo/people-woman-sitting-technology-7088526/

13

From Protocol to Pattern Recognition

The protocol defines the examination but the **clinical and genetic history provides context** for what we find.

If the patient has a known multisystem disease, this should prompt further investigation for findings that may belong to the same disorder.

Consider **number, bilaterality, distribution, organ involvement, and associated abnormalities** rather than evaluating each finding in isolation.

When findings suggest involvement beyond the ordered examination, the interpreting provider may recommend an additional assessment.

14

© Copyright. Society of Diagnostic Medical Sonography. All Rights Reserved.

The Sonographer's Role



- Obtain and document relevant **clinical and family history** before interpreting the imaging pattern.
- Characterize abnormalities by their **location, number, size, morphology, echogenicity, vascularity, distribution, and associated findings**.
- Compare findings with prior imaging and known diagnoses when that information is available.
- Document findings on the technologist worksheet so the interpreting physician can integrate the complete clinical and imaging picture.

Goleisureintl, CC BY 4.0 <https://creativecommons.org/licenses/by/4.0>, via Wikimedia Commons

15

Autosomal Dominant Disorders

16

© Copyright. Society of Diagnostic Medical Sonography. All Rights Reserved.

Dominant Disease

Autosomal dominant disease results when **one pathogenic allele** on an autosome may be sufficient to produce the disorder.

With a heterozygous affected parent, each pregnancy generally has a **50% chance of inheriting the pathogenic variant**, although penetrance and disease expression may vary.

We will review **tuberous sclerosis complex, autosomal dominant polycystic kidney disease, familial neuroblastoma susceptibility, autosomal dominant tubulointerstitial kidney disease, and PRSS1-related hereditary pancreatitis**.

For each condition, we will connect the **inheritance pattern, clinical presentation, family history, and sonographic phenotype**.

17

Tuberous Sclerosis Complex: What Is It?

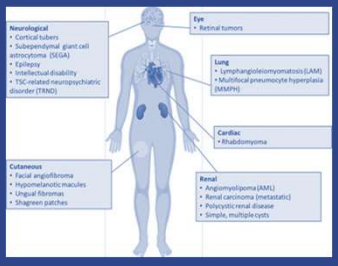

- **Tuberous sclerosis complex (TSC)** is an autosomal dominant multisystem genetic disorder associated with pathogenic variants in **TSC1 or TSC2**.
- Loss of normal TSC1/TSC2 function disrupts regulation of cell growth, contributing to development of **hamartomas and other tumors** in multiple organs.
- Commonly involved systems include the **brain, skin, kidneys, heart, lungs, and eyes**.
- Clinical expression is highly variable, and many patients have no affected parent because TSC frequently results from a **de novo pathogenic variant**.

Dahmoush, H. M., Melhem, E. R., & Vossough, A. (2016). Metabolic, endocrine, and other genetic disorders. In J. C. Masdeu & R. G. González (Eds.), *Handbook of clinical neurology* (Vol. 136, pp. 1221–1259). Elsevier. https://doi.org/10.1016/B978-0-444-53486-6.00063-6

18

© Copyright. Society of Diagnostic Medical Sonography. All Rights Reserved.

TSC: Sonographic Manifestations

- Renal involvement commonly includes **angiomyolipomas and epithelial renal cysts**; TSC-associated angiomyolipomas are often multiple and bilateral.
- Deletion involving adjacent **TSC2 and PKD1** genes can produce an early and severe polycystic kidney phenotype that may be evident prenatally or during infancy.
- **Hepatic angiomyolipomas** may occur; hepatic cystic disease may accompany the polycystic phenotype when PKD1 is also involved.
- **Cardiac rhabdomyomas** are an important fetal and neonatal manifestation and may provide the first prenatal clue to TSC.



Case courtesy of Fabien Ho, Radiopaedia.org, rID: 58999 and Case courtesy of Hani M. Al Salam, Radiopaedia.org, rID: 9150

19

Renal Angiomyolipoma

- A renal angiomyolipoma (AML) is a typically benign renal neoplasm composed of varying proportions of **blood vessels, smooth muscle, and adipose tissue**.
- Classic fat-rich AMLs usually appear as **well-defined hyperechoic cortical masses**, often with posterior acoustic attenuation or shadowing.
- TSC-associated AMLs tend to occur **earlier, bilaterally, and in greater numbers** than sporadic AMLs.
- Fat-poor AMLs may be less characteristically echogenic and can overlap sonographically with renal cell carcinoma; ultrasound alone may not provide definitive characterization.

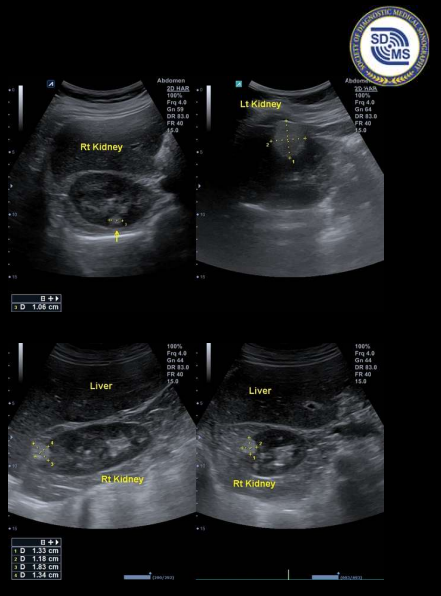

Case courtesy of Omar M. Sultan, Radiopaedia.org, rID: 62363

20

© Copyright. Society of Diagnostic Medical Sonography. All Rights Reserved.

Autosomal Dominant Polycystic Kidney Disease (Adult Polycystic Kidney Disease): What Is It?

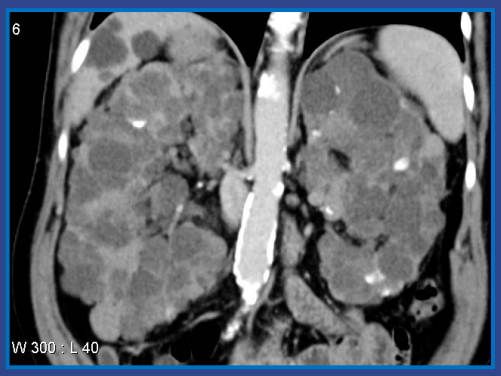

- **Autosomal dominant polycystic kidney disease (ADPKD)** is a progressive inherited multisystem disorder characterized primarily by development of bilateral renal cysts.
- Most affected families have a heterozygous pathogenic variant in **PKD1 or PKD2**, although less common ADPKD-associated genes are recognized.
- Disease expression is **age-dependent and variable**; cyst burden typically increases over time.
- Although usually recognized in adulthood, childhood, neonatal, and occasionally **prenatal renal abnormalities** can occur.

Case courtesy of Frank Gaillard, Radiopaedia.org, rID: 5203

21

PKD1 vs. PKD2

- **Autosomal dominant polycystic kidney disease (ADPKD)** is a progressive inherited multisystem disorder characterized primarily by development of bilateral renal cysts.
- Most affected families have a heterozygous pathogenic variant in **PKD1 or PKD2**, although less common ADPKD-associated genes are recognized.
- Disease expression is **age-dependent and variable**; cyst burden typically increases over time.
- Although usually recognized in adulthood, childhood, neonatal, and occasionally **prenatal renal abnormalities** can occur.



Case courtesy of Frank Gaillard, Radiopaedia.org, rID: 9719

22

© Copyright. Society of Diagnostic Medical Sonography. All Rights Reserved.

ADPKD: Sonographic Manifestations

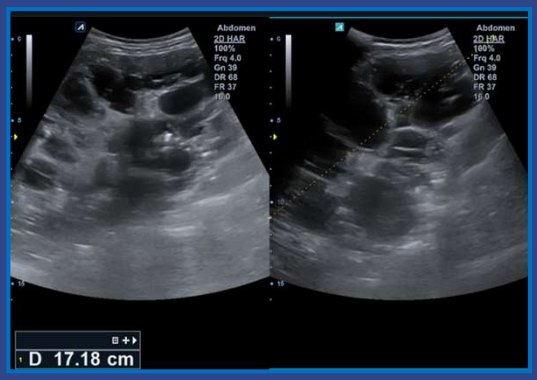

- Renal findings include **multiple bilateral cysts**, progressive renal enlargement, and increasing cyst number and size with advancing age.
- Cysts may develop throughout the renal parenchyma and progressively distort the normal renal architecture.
- Extrarenal cysts occur most commonly in the **liver** and may also involve the **pancreas**.
- Clinical presentation may include **hypertension, hematuria, flank pain, nephrolithiasis, declining renal function, and family history of cystic kidney disease or renal failure**.

Case courtesy of Ali Abdullah Obaid, Radiopaedia.org, rID: 196722

23

Case Example

- Bilateral renal enlargement with multiple simple cysts of varying sizes.
- This 40-year-old male patient has additional small cysts present in both hepatic lobes and along the peribiliary region.
- The pancreas and spleen were normal in appearance without cystic involvement.
- The overall pattern was consistent with ADPKD.

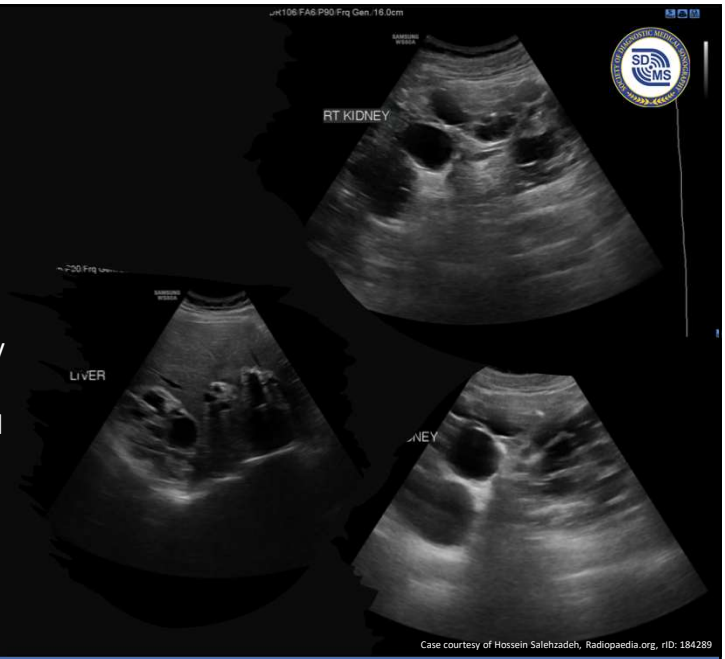

Case courtesy of Hossein Salehzadeh, Radiopaedia.org, rID: 184289

24

© Copyright. Society of Diagnostic Medical Sonography. All Rights Reserved.

Autosomal Dominant Tubulointerstitial Kidney Disease (ADTKD): What Is It?

- **Uremic medullary cystic disease** and **medullary cystic kidney disease** are historical terms for disorders now classified as **autosomal dominant tubulointerstitial kidney disease (ADTKD)**.
- ADTKD includes genetically distinct disorders such as **ADTKD-UMOD and ADTKD-MUC1**.
- These conditions cause slowly progressive **tubulointerstitial kidney disease and chronic kidney failure** with autosomal dominant inheritance.
- The modern term is preferred because **medullary cysts may be absent and are not diagnostic of the disease**.

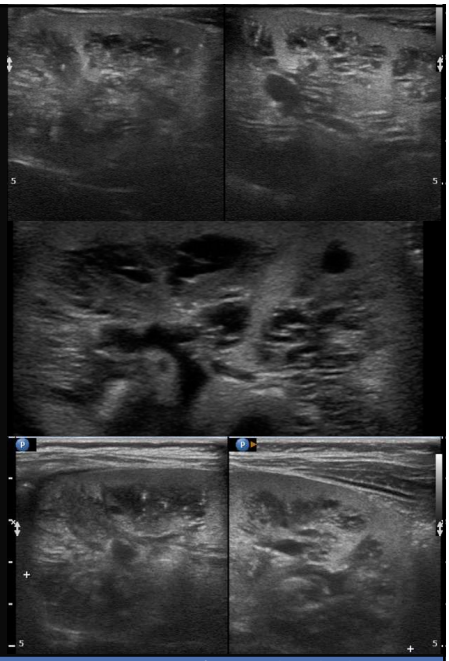

Case courtesy of Jose Antonio Habana, Radiopaedia.org, rID: 91596

25

ADTKD: What Do We Look For?

- Renal ultrasound may be **normal early in the disease**, despite progressive loss of kidney function.
- Later findings may include **normal-to-small kidneys, increased parenchymal echogenicity, and decreased corticomedullary differentiation**.
- Small renal or corticomedullary cysts may occur, but **cysts are neither required nor specific** for ADTKD.
- Clinical clues include a dominant family history of chronic kidney disease or renal failure; **hyperuricemia and early gout are particularly associated with ADTKD-UMOD**.



Case courtesy of Hani M. Al Salam, Radiopaedia.org, rID: 9667

26

© Copyright. Society of Diagnostic Medical Sonography. All Rights Reserved.

ADPKD vs. ADTKD vs. TSC: Distinguishing Dominant Renal Patterns

Autosomal Dominant Polycystic Kidney Disease (ADPKD)	Autosomal Dominant Tubulointerstitial Kidney Disease (ADTKD)	Tuberous Sclerosis Complex (TSC)
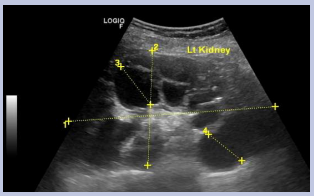		

Case courtesy of Satish Kumar Gupta, Radiopaedia.org, rID: 174650, Hani M. Al Salam, Radiopaedia.org, rID: 9667, and Mohammad Osama Hussein Yonso, Radiopaedia.org, rID: 17308

27

Neuroblastoma (Adrenal Medullary Neoplasm): What Is It?

- **Neuroblastoma** is a malignant embryonal tumor arising from neural crest-derived cells of the sympathetic nervous system.
- It may arise anywhere along the sympathetic chain, but the **adrenal region is the most common primary site**.
- While most neuroblastomas are **sporadic** and are not inherited as autosomal dominant disorders, a small subset reflects inherited tumor susceptibility; **ALK-related neuroblastic tumor susceptibility is autosomal dominant with reduced penetrance**.

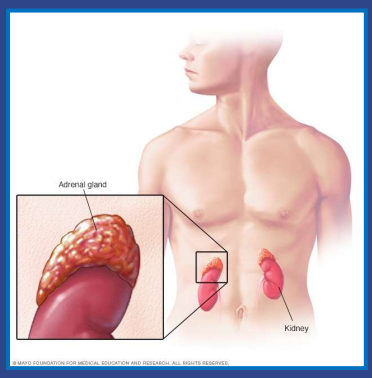

https://www.mayoclinic.org/diseases-conditions/neuroblastoma/symptoms-causes/syc-20351017

28

© Copyright. Society of Diagnostic Medical Sonography. All Rights Reserved.

Sonographic Manifestations of Neuroblastoma



- Typically appears as a **solid, suprarenal mass**, sometimes containing necrotic or hemorrhagic areas.
- **Calcifications** may appear as echogenic foci, and color Doppler commonly demonstrates internal vascularity.
- Adrenal tumors characteristically **displace the ipsilateral kidney inferiorly** and may cross the midline or encase major vessels.
- The sonographer should evaluate for associated adenopathy and **hepatic metastases**; distinguish neuroblastoma from renal Wilms tumor and neonatal adrenal hemorrhage.

https://www.researchgate.net/figure/At-diagnosis-neuroblastoma-of-the-left-adrenal-gland-2024-cm-dilatation-of-the_fig2_8325552

29

Hereditary Pancreatitis: What Is It?

PRSS1-related hereditary pancreatitis is an autosomal dominant disorder caused by heterozygous gain-of-function pathogenic variants in **PRSS1**.

It is characterized by **recurrent episodes of acute pancreatitis**, often beginning earlier in life than more common acquired forms.

Repeated pancreatic injury can progress to **chronic pancreatitis**, with permanent structural and functional changes.

Reduced penetrance can occur, so carrying a pathogenic PRSS1 variant does not always produce clinical disease.

30

© Copyright. Society of Diagnostic Medical Sonography. All Rights Reserved.

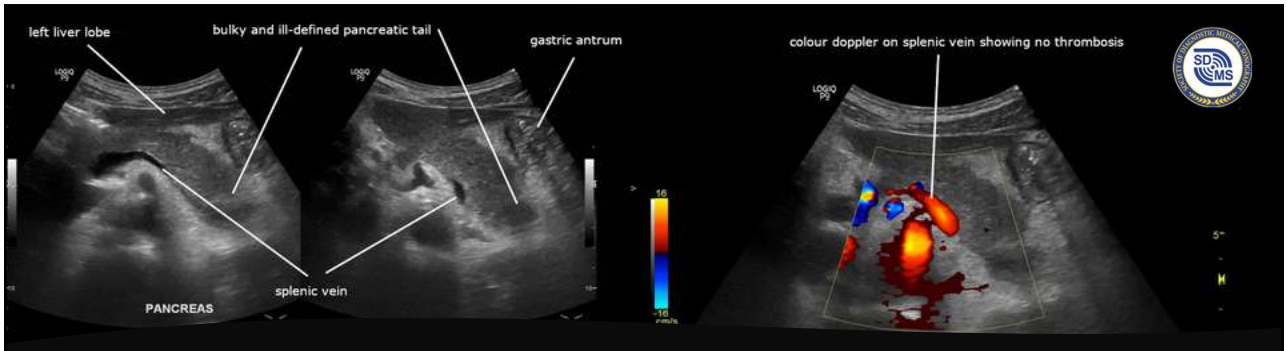

Hereditary Pancreatitis: Sonographic Manifestations

- During an acute episode, the pancreas may appear **enlarged, edematous, and hypoechoic**, although ultrasound findings can be subtle or nonspecific.
- Chronic pancreatitis may produce **parenchymal atrophy, calcifications, and an irregular or dilated pancreatic duct**.
- Complications can include **pancreatic or peripancreatic fluid collections and pseudocysts**.
- Transabdominal visualization may be limited by bowel gas or body habitus; CT, MRI/MRCP, and endoscopic ultrasound may provide additional characterization.

Cerevisae, CC BY-SA 4.0 <https://creativecommons.org/licenses/by-sa/4.0>, via Wikimedia Commons

31

When the Patient Already Has the Diagnosis

The sonographer should review the indication, chart, prior imaging, and known genetic diagnosis before scanning whenever possible.

Knowing which organs and complications are associated with that condition can help the sonographer to assess the relevant structures included within the ordered examination.

Depending on the disease and examination, this may include the **kidneys, liver, pancreas, adrenal regions, vessels, and bladder**.

Document expected manifestations, unexpected abnormalities, and important interval changes; communicate findings that may warrant additional assessment.

32

© Copyright. Society of Diagnostic Medical Sonography. All Rights Reserved.

Checkpoint: Test Your Knowledge!

Q&A — Which Dominant Pattern?

A 42-year-old patient with a strong family history of renal failure has **bilaterally enlarged kidneys containing numerous cortical and medullary cysts of varying sizes**. Which diagnosis best fits this pattern?

- A. Autosomal dominant tubulointerstitial kidney disease
- B. Autosomal dominant polycystic kidney disease
- C. Tuberous sclerosis complex
- D. NPHP1-related nephronophthisis

33

Checkpoint: Test Your Knowledge!

Q&A — Recognizing the Association

During a renal ultrasound, you identify **multiple bilateral hyperechoic cortical masses consistent with angiomyolipomas**. Which associated inherited disorder should be considered?

- A. Hereditary pancreatitis
- B. Tuberous sclerosis complex
- C. ADTKD-MUC1
- D. Wilson disease

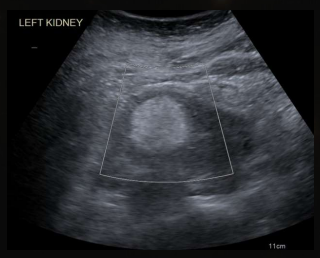

Case courtesy of Bruno Di Muzio, Radiopaedia.org, rID: 53755

34

© Copyright. Society of Diagnostic Medical Sonography. All Rights Reserved.

Autosomal Recessive Disorders

35

Recessive Disease: Conditions We Will Review

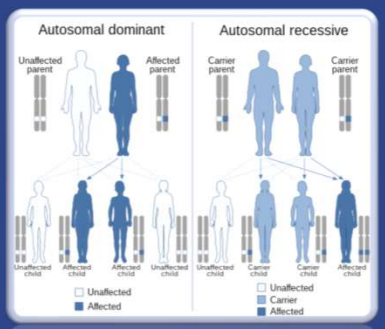

- Autosomal recessive disease generally requires **pathogenic variants affecting both copies of a gene**, with parents often being unaffected carriers.
- When both parents carry a pathogenic variant in the same gene, each pregnancy typically has a **25% chance of being affected, 50% chance of being a carrier, and 25% chance of inheriting neither familial variant**.
- We will review **ARPKD, cystic fibrosis, congenital adrenal hyperplasia, Wilson disease, selected glycogen storage diseases, galactosemia, NPHP1-related juvenile nephronophthisis, and infantile-onset lysosomal acid lipase deficiency**.
- For each disease, we will connect the **inheritance pattern and disease process to the sonographic manifestations we may encounter**.

Combination: SUM1File:Autosomal dominant - en.svg: Domaina, Angelito7 and SUM1File:Autosomal recessive - en.svg: Domaina, Kashmiri and SUM1, CC BY-SA 4.0 <https://creativecommons.org/licenses/by-sa/4.0>, via Wikimedia Commons

36

© Copyright. Society of Diagnostic Medical Sonography. All Rights Reserved.

Recessive Disease on Ultrasound

Autosomal recessive disorders do **not** share one sonographic appearance; the phenotype depends on the organ system and underlying disease.

In the conditions we will review, recurring patterns include **prenatal or neonatal presentation, enlarged or echogenic kidneys, hepatomegaly or hepatosplenomegaly, and metabolic or fibrotic liver disease**.

Other clues may involve the **bowel, pancreas, gallbladder, or adrenal glands**.

Age at presentation, associated abnormalities, laboratory findings, and family history help place these findings into the correct clinical context.

37



Autosomal Recessive Polycystic Kidney Disease (Infantile Polycystic Kidney Disease): What Is It?

- **Autosomal recessive polycystic kidney disease (ARPKD)** is most commonly caused by biallelic pathogenic variants in **PKHD1**.
- It is a **fibrocystic disease of the kidneys and liver**, with presentation ranging from prenatal life through adulthood.
- Renal disease results primarily from abnormal development and dilation of the **collecting ducts**.
- Hepatic involvement reflects abnormal biliary development and may produce **congenital hepatic fibrosis, portal hypertension, and Caroli disease**.

Case courtesy of Ammar Haouimi, Radiopaedia.org, rID: 84727

38

© Copyright. Society of Diagnostic Medical Sonography. All Rights Reserved.

ARPKD: Sonographic Manifestations

- Prenatally and in infancy, the kidneys are typically **bilaterally enlarged and hyperechoic with decreased corticomedullary differentiation**.
- Innumerable collecting-duct microcysts may be only **1–2 mm** and may not appear as individually visible macrocysts.
- Severe fetal renal involvement can reduce urine production, producing **oligohydramnios or anhydramnios and secondary pulmonary hypoplasia**.
- Hepatic disease may produce **hepatomegaly, heterogeneous liver parenchyma, bile duct abnormalities, splenomegaly, and Doppler signs of portal hypertension**.

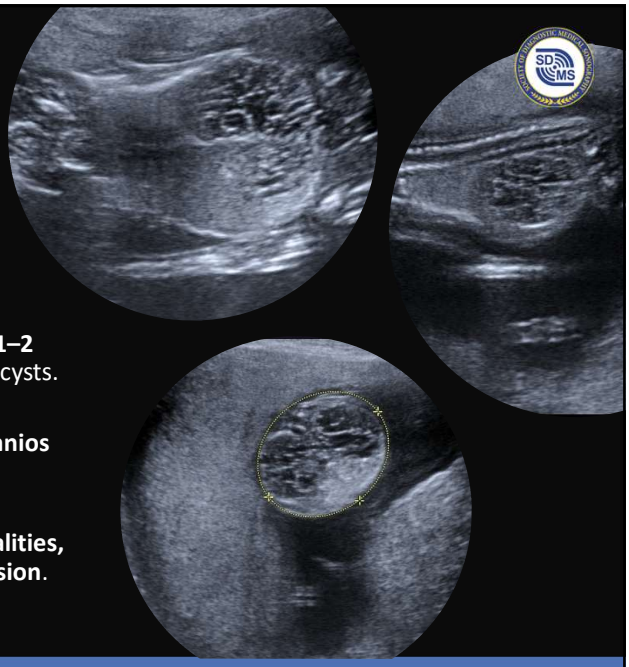

Case courtesy of Imran Ahmad Khan, Radiopaedia.org, rID: 66807

39

Cystic Fibrosis: What Is It?

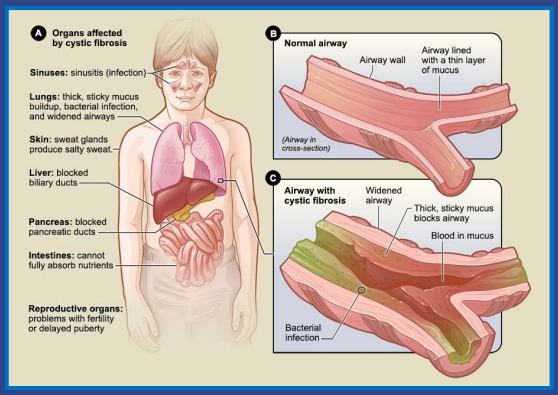

- **Cystic fibrosis (CF)** is an autosomal recessive multisystem disorder caused by biallelic pathogenic variants in **CFTR**.
- CFTR dysfunction alters chloride and bicarbonate transport across epithelial surfaces, producing **dehydrated, abnormally viscous secretions**.
- Major organ systems include the **respiratory tract, exocrine pancreas, intestine, hepatobiliary system, and reproductive tract**.
- Abdominal disease may include **pancreatic insufficiency, meconium ileus, hepatobiliary disease, and intestinal obstruction**.

National Heart Lung and Blood Institute, National Institutes of Health (NIH), Public domain, via Wikimedia Commons

40

© Copyright. Society of Diagnostic Medical Sonography. All Rights Reserved.

Cystic Fibrosis: Sonographic Manifestations

- Prenatal clues include **echogenic bowel, dilated bowel, and meconium ileus**, although echogenic bowel is nonspecific and has a broad differential.
- Pancreatic fibrosis and fatty replacement may produce a **small, atrophic, hyperechoic pancreas**; fatty pseudohypertrophy or pancreatic cystosis may occasionally occur.
- Hepatobiliary findings include **hepatic steatosis or fibrosis, microgallbladder, sludge or cholelithiasis, and biliary abnormalities**.
- Advanced CF-associated liver disease may produce **portal hypertension, splenomegaly, collateral vessels, altered portal flow, and ascites**.



Case courtesy of Yaïr Glick, Radiopaedia.org, rID: 95909

41

Congenital Adrenal Hyperplasia (CAH): What Is It?

Congenital adrenal hyperplasia (CAH) describes a group of inherited disorders affecting adrenal steroid synthesis; most forms are autosomal recessive.

The most common cause is **21-hydroxylase deficiency** which results from biallelic pathogenic variants in **CYP21A2**.

Impaired cortisol synthesis leads to increased ACTH stimulation and adrenal androgen production; severe forms may also impair aldosterone production.

Classic disease may present with **virilization, atypical genital development, or life-threatening neonatal salt-wasting**.

42

© Copyright. Society of Diagnostic Medical Sonography. All Rights Reserved.

CAH: Sonographic Manifestations

- Ultrasound is **not the primary diagnostic test for CAH**; diagnosis relies on clinical, biochemical, and genetic evaluation.
- The adrenal glands may appear **bilaterally enlarged**, with thickened limbs and a lobulated or **cerebriform appearance**.
- Normal-appearing adrenal glands do **not exclude CAH**.
- In an infant with atypical genitalia, pelvic ultrasound can help identify **internal reproductive anatomy**, including the presence of a uterus, and assess the kidneys and adrenal glands.

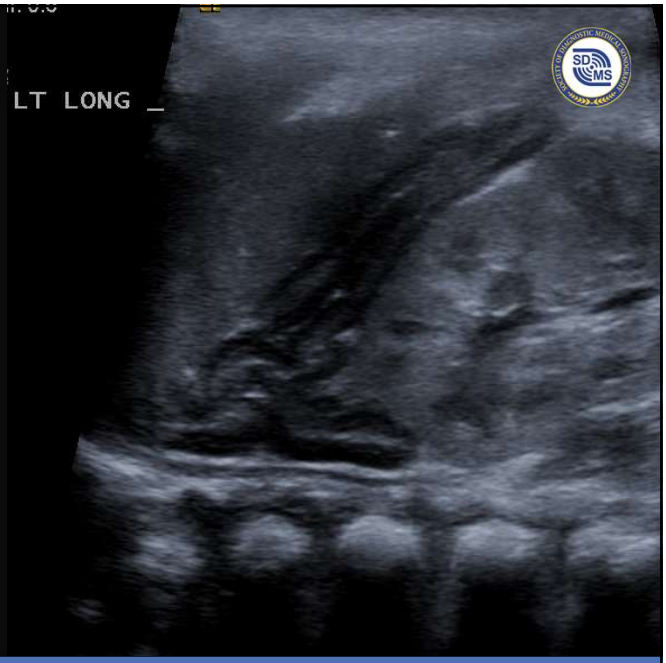

Case courtesy of Yusra Sheikh, Radiopaedia.org, rID: 72419

43

Case Example

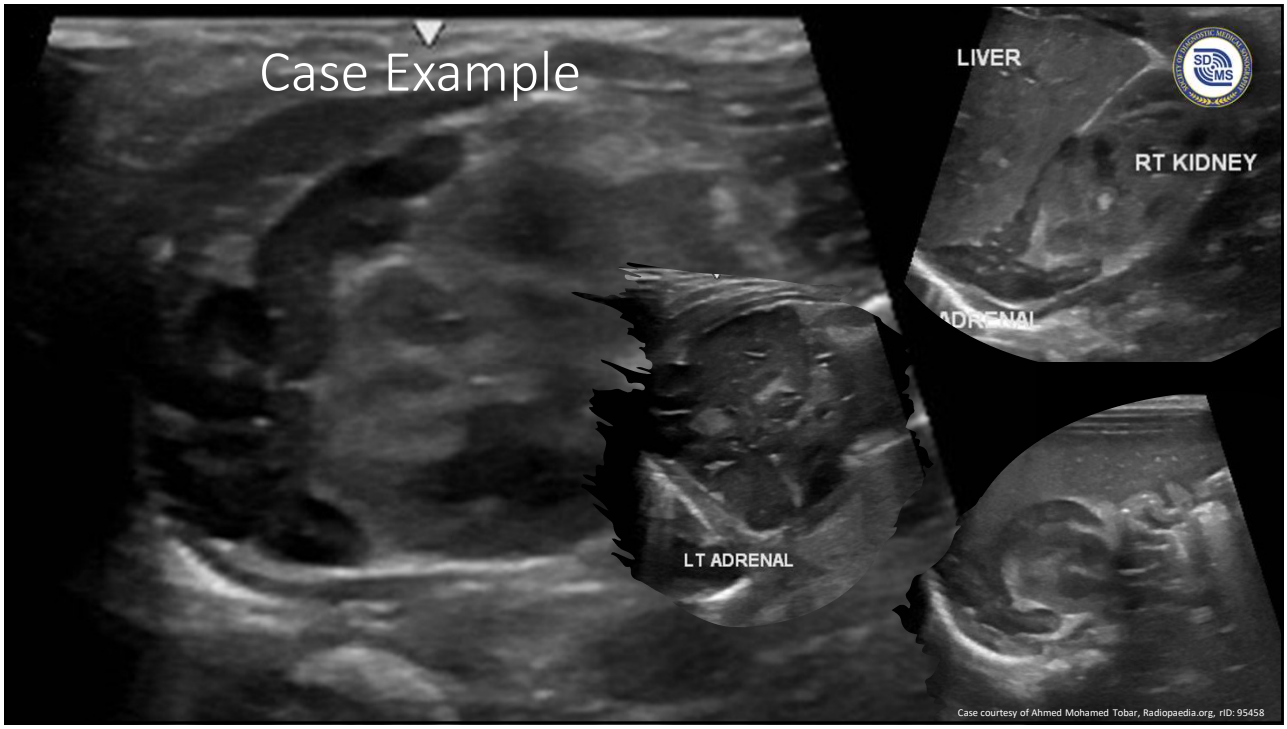

Case courtesy of Ahmed Mohamed Tobar, Radiopaedia.org, rID: 95458

44

© Copyright. Society of Diagnostic Medical Sonography. All Rights Reserved.

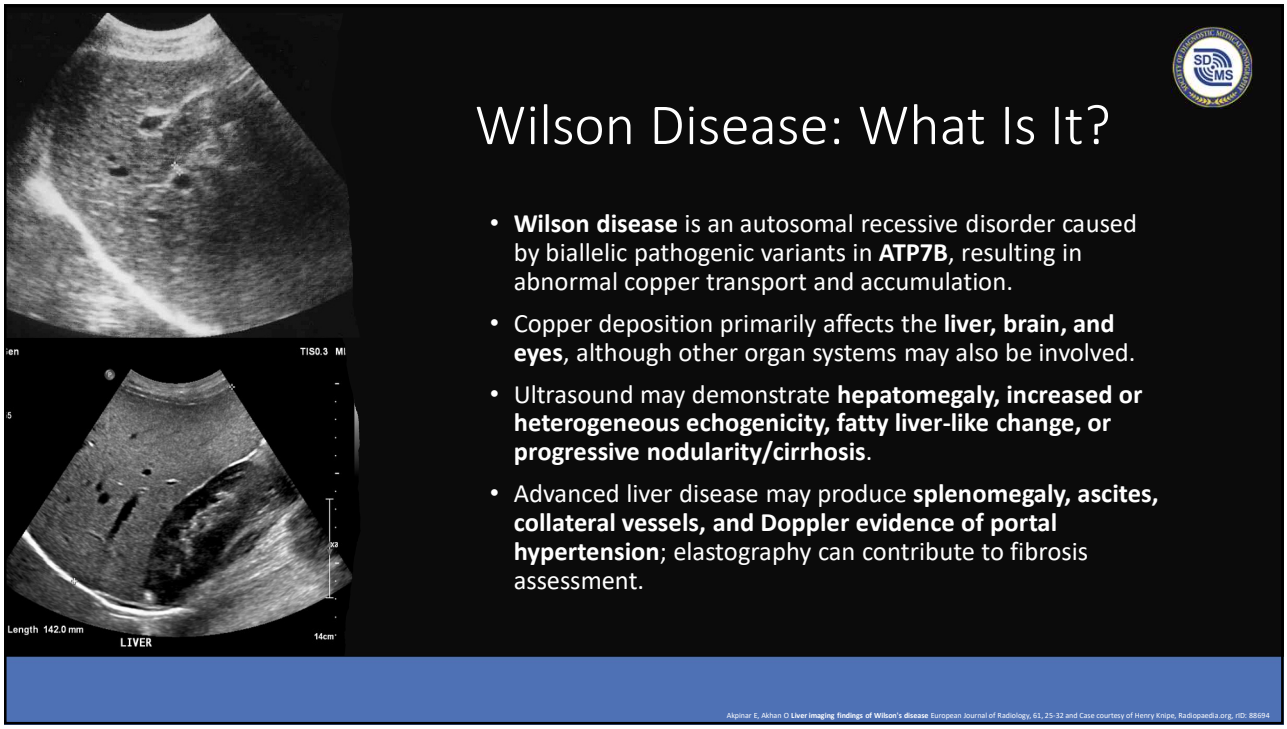

45

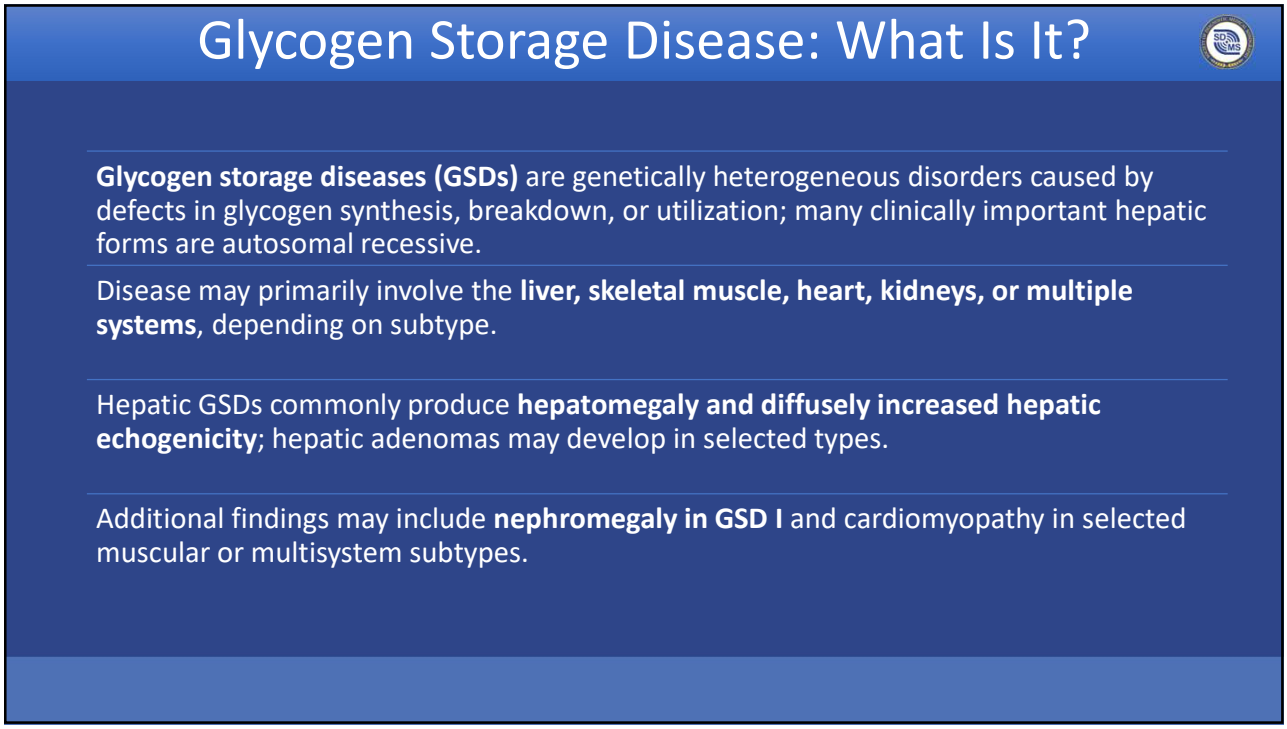

46

© Copyright. Society of Diagnostic Medical Sonography. All Rights Reserved.

Galactosemia: What Is It?

- **Classic galactosemia** is an autosomal recessive disorder of galactose metabolism caused by biallelic pathogenic variants in **GALT**.
- Without early dietary treatment, toxic metabolite accumulation can produce severe **neonatal hepatocellular injury, jaundice, feeding difficulty, coagulopathy, and liver failure**.
- Sonography may demonstrate **hepatomegaly and ascites** in symptomatic infants and can evaluate the liver when hepatic dysfunction is present.
- Splenomegaly or other portal-hypertensive findings may occur with advanced liver disease but are **not specific for galactosemia**.

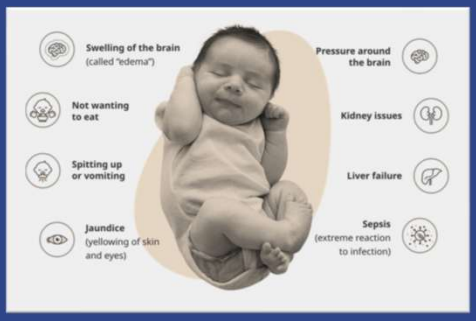

https://galactosemia.org/living-with-galactosemia/newborns/

47

NPHP1-Related Juvenile Nephronophthisis: What Is It?

Nephronophthisis (NPH) is an autosomal recessive tubulointerstitial kidney disease within the group of **nephronophthisis-related ciliopathies**.

NPHP1 stands for nephrocystin 1, and NPHP1 is the most commonly implicated gene in juvenile nephronophthisis.

Disease primarily affects the renal tubules and interstitium, producing a progressive **urine-concentrating defect and chronic kidney disease**.

Juvenile disease commonly presents during childhood or adolescence and may progress to **end-stage kidney disease during the second decade of life**.

48

© Copyright. Society of Diagnostic Medical Sonography. All Rights Reserved.

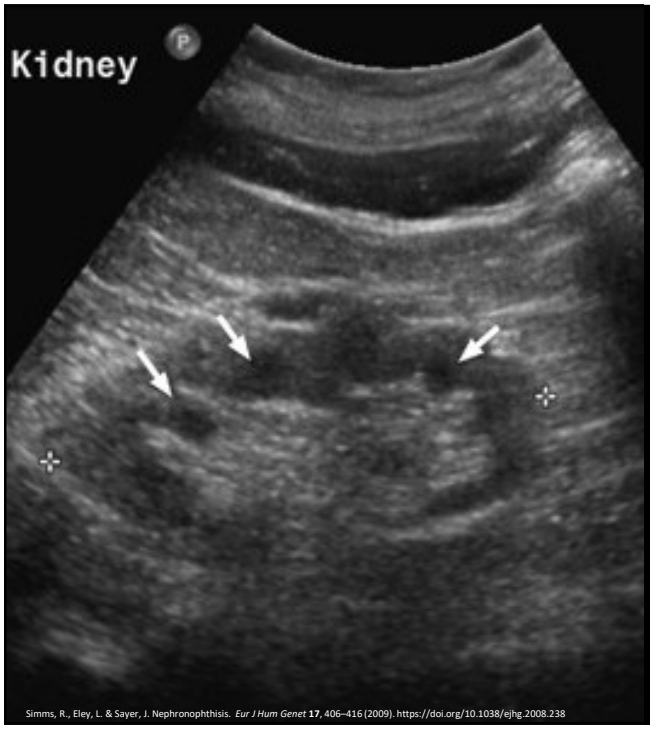

Simms, R., Eley, L. & Sayer, J. Nephronophthisis. *Eur J Hum Genet* **17**, 406–416 (2009). https://doi.org/10.1038/ejhg.2008.238

NPHP1-Related Nephronophthisis: Sonographic Manifestations

- Kidneys are typically **normal-to-small in size** rather than enlarged.
- Progressive disease may demonstrate **increased parenchymal echogenicity and reduced corticomedullary differentiation**.
- Small cysts may develop along the **corticomedullary junction**, particularly later in the disease course.
- Extrarenal findings may provide a syndromic clue, including **retinal, neurologic, or hepatic abnormalities** in selected nephronophthisis-related ciliopathies.

49

Wolman Disease: What Is It?

- **Wolman disease** is the historical name for **infantile-onset lysosomal acid lipase deficiency (LAL-D)**.
- It is an autosomal recessive lysosomal storage disorder caused by biallelic pathogenic variants in **LIPA**.
- Deficient lysosomal acid lipase causes accumulation of **cholesteryl esters and triglycerides** within tissues.
- Severe infantile disease prominently affects the **liver, spleen, gastrointestinal tract, and adrenal glands** and can progress rapidly without treatment.

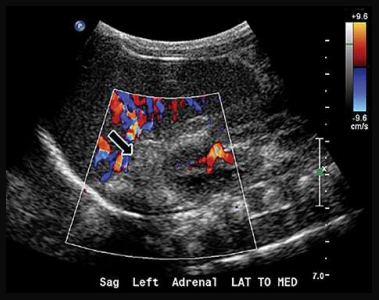

https://www.appliedradiology.com/articles/wolman-disease

50

© Copyright. Society of Diagnostic Medical Sonography. All Rights Reserved.

Wolman Disease: Sonographic Manifestations



LAL-D Source / Alexion, CC BY-SA 2.5 <https://creativecommons.org/licenses/by-sa/2.5>, via Wikimedia Commons

- **Hepatomegaly and splenomegaly** are common, with the liver often demonstrating diffusely increased echogenicity from steatosis.
- The adrenal glands may be **bilaterally enlarged while retaining their characteristic adrenal configuration**.
- **Bilateral adrenal calcifications** are a particularly important imaging clue and may produce echogenic foci with posterior acoustic shadowing.
- Additional abdominal findings may include **bowel wall involvement, lymphadenopathy, or ascites** in advanced disease.

51

The Role of Ultrasound

Ultrasound can identify a **phenotype and pattern of organ involvement**, but generally cannot establish the underlying genetic diagnosis.

Findings should be interpreted with the **patient's age, family history, clinical presentation, laboratory results, and prior imaging**.

Recognizing associated manifestations can guide a more targeted examination and help identify disease complications.

Biochemical, molecular genetic, and other disease-specific testing remain necessary when confirmation of an inherited disorder is required.

52

© Copyright. Society of Diagnostic Medical Sonography. All Rights Reserved.

Checkpoint: Test Your Knowledge!

Q&A — The Adrenal Clue

An infant with failure to thrive demonstrates **hepatosplenomegaly and bilateral enlarged adrenal glands containing coarse calcifications with posterior acoustic shadowing**. Which diagnosis should move high on the differential?

- A. Congenital adrenal hyperplasia
- B. Neuroblastoma
- C. Wolman disease
- D. Cystic fibrosis

53

Game Time:

Lets finish with a round of Q&A!



https://www.vecteezy.com/free-vector

54

© Copyright. Society of Diagnostic Medical Sonography. All Rights Reserved.

Q&A #1: Prenatal Clue

A second-trimester ultrasound demonstrates **echogenic fetal bowel**. Which inherited disorder should be included among the differential considerations?

- A. Tuberous sclerosis complex
- B. Congenital adrenal hyperplasia
- C. Cystic fibrosis
- D. Autosomal dominant polycystic kidney disease

55

Q&A #2: Inheritance

One parent is **heterozygous for an autosomal dominant pathogenic variant**, and the other parent is unaffected and does not carry the variant. What is the probability that **each pregnancy** will inherit the pathogenic variant?

- A. 25%
- B. 50%
- C. 75%
- D. 100%

56

© Copyright. Society of Diagnostic Medical Sonography. All Rights Reserved.

Q&A #3: Wilson Disease Progression

A patient with known Wilson disease has a **heterogeneous, nodular liver** on ultrasound. Which additional finding would most strongly support progression to **portal hypertension**?

- A. Mildly increased hepatic echogenicity
- B. Recanalized paraumbilical vein with portosystemic collateral flow
- C. Focal fatty sparing adjacent to the gallbladder
- D. Mild gallbladder wall thickening after a nonfasting examination

57

Q&A #4: Vascular, Suprarenal Finding

Ultrasound demonstrates a **heterogeneous suprarenal mass with calcifications and internal vascularity that displaces the ipsilateral kidney inferiorly**. Which diagnosis is most likely?

- A. Wilms tumor
- B. Adrenal hemorrhage
- C. Renal angiomyolipoma
- D. Neuroblastoma

58

© Copyright. Society of Diagnostic Medical Sonography. All Rights Reserved.

Q&A #5: Tuberous Sclerosis Complex

Which ultrasound finding is most characteristic of tuberous sclerosis complex?

- A. Multiple bilateral renal angiomyolipomas
- B. Bilaterally enlarged kidneys filled with renal calculi
- C. Small echogenic kidneys with corticomedullary cysts
- D. Bilateral adrenal enlargement with calcification

59

References

- Aderotimi TS, Kraft JK. Ultrasound of the adrenal gland in children. Ultrasound. 2021 Feb;29(1):48-56. doi: 10.1177/1742271X20951915. Epub 2020 Aug 20. PMID: 33552228; PMCID: PMC7844468.
- Balwani M, Vijay S. Lysosomal Acid Lipase Deficiency. 2015 Jul 30 [Updated 2026 Jan 15]. In: Adam MP, Bick S, Mirzaa GM, et al., editors. GeneReviews® [Internet]. Seattle (WA): University of Washington, Seattle; 1993-2026.
- Bin Shlhoob R, Tanaka J. Genetics: Inheritance Patterns. [Updated 2026 Aug 16]. In: StatPearls [Internet]. Treasure Island (FL): StatPearls Publishing; 2026 Jan-. Available from: https://www.ncbi.nlm.nih.gov/books/NBK557512/
- Bleyer AJ, Živná M, Kidd K, et al. Autosomal Dominant Tubulointerstitial Kidney Disease – MUC1. 2013 Aug 15 [Updated 2021 Oct 21]. In: Adam MP, Bick S, Mirzaa GM, et al., editors. GeneReviews® [Internet]. Seattle (WA): University of Washington, Seattle; 1993-2026.
- Burgmaier K, Gimpel C, Schaefer F, et al. Autosomal Recessive Polycystic Kidney Disease – PKHD1. 2001 Jul 19 [Updated 2024 Apr 4]. In: Adam MP, Bick S, Mirzaa GM, et al., editors. GeneReviews® [Internet]. Seattle (WA): University of Washington, Seattle; 1993-2026.
- Chung K, Thayalan K, Kothari A. Echogenic bowel in the second trimester - Where to from here? Australas J Ultrasound Med. 2017 Nov 15;21(1):49-54. doi: 10.1002/ajum.12074. PMID: 34760501; PMCID: PMC8409811.
- GeneReviews. (n.d.). *GeneReviews glossary*. University of Washington, Seattle.
- Gillespie CD, O'Reilly MK, Allen GN, McDermott S, Chan VO, Ridge CA. Imaging the Abdominal Manifestations of Cystic Fibrosis. Int J Hepatol. 2017;2017:5128760. doi: 10.1155/2017/5128760. Epub 2017 Jan 29. PMID: 28250993; PMCID: PMC5303593.
- Goosenberg E, Lappin SL. Chronic Pancreatitis. [Updated 2025 Apr 4]. In: StatPearls [Internet]. Treasure Island (FL): StatPearls Publishing; 2026 Jan-.
- Gümüş E, Özen H. Glycogen storage diseases: An update. World J Gastroenterol. 2023 Jul 7;29(25):3932-3963. doi: 10.3748/wjg.v29.i25.3932. PMID: 37476587; PMCID: PMC10354582.
- Harris PC, Torres VE. Polycystic Kidney Disease, Autosomal Dominant. 2002 Jan 10 [Updated 2022 Sep 29]. In: Adam MP, Bick S, Mirzaa GM, et al., editors. GeneReviews® [Internet]. Seattle (WA): University of Washington, Seattle; 1993-2026. Available from: https://www.ncbi.nlm.nih.gov/books/NBK1246/
- National Human Genome Research Institute. (n.d.). *Talking glossary of genetic terms*. National Institutes of Health.
- Niño JC, Caicedo CA, Cárdenas J. Bilateral Adrenal Calcifications as an Imaging Clue to Wolman Disease in Early Infancy: A Case Report. Cureus. 2026 Feb 17;18(2):e103790. doi: 10.7759/cureus.103790. PMID: 41869254; PMCID: PMC13002258.
- Nimkarn S, Gangishetti PK, Yau M, et al. 21-Hydroxylase-Deficient Congenital Adrenal Hyperplasia. 2002 Feb 26 [Updated 2016 Feb 4]. In: Adam MP, Bick S, Mirzaa GM, et al., editors. GeneReviews® [Internet]. Seattle (WA): University of Washington, Seattle; 1993-2026.
- Northrup H, Koenig MK, Pearson DA, et al. Tuberous Sclerosis Complex. 1999 Jul 13 [Updated 2024 Aug 1]. In: Adam MP, Bick S, Mirzaa GM, et al., editors. GeneReviews® [Internet]. Seattle (WA): University of Washington, Seattle; 1993-2026. Available from: https://www.ncbi.nlm.nih.gov/sites/books/NBK1220/
- Odabaşı Güneş S, Peltek Kendirci HN, Ünal E, Buluş AD, Dündar İ, Şıklar Z. Clinical, Biochemical and Molecular Characteristics of Congenital Adrenal Hyperplasia Due to 21-hydroxylase Deficiency. J Clin Res Pediatr Endocrinol. 2025 Jan 10;17(Suppl 1):3-11. doi: 10.4274/jcrpe.galenos.2024.2024-6-6-S. Epub 2024 Dec 23. PMID: 39713855; PMCID: PMC11730093.
- Rout P, Leslie SW. Renal Angiomyolipoma. [Updated 2024 May 2]. In: StatPearls [Internet]. Treasure Island (FL): StatPearls Publishing; 2026 Jan-.
- Shenoy P, Karegowda L, Sripathi S, Mohammed N. Wolman disease in an infant. BMJ Case Rep. 2014 Feb 12;2014:bcr2014203656. doi: 10.1136/bcr-2014-203656. PMID: 24521666; PMCID: PMC3926402.
- Stokman M, Lilien M, Knoers N. Nephronophthisis-Related Ciliopathies. 2016 Jun 23 [Updated 2023 Mar 2]. In: Adam MP, Bick S, Mirzaa GM, et al., editors. GeneReviews® [Internet]. Seattle (WA): University of Washington, Seattle; 1993-2026.
- Weiss KH, Schilsky M. Wilson Disease. 1999 Oct 22 [Updated 2023 Jan 12]. In: Adam MP, Bick S, Mirzaa GM, et al., editors. GeneReviews® [Internet]. Seattle (WA): University of Washington, Seattle; 1993-2026.
- Whitcomb DC. PRSS1-Related Hereditary Pancreatitis. 2012 Mar 1 [Updated 2025 Mar 27]. In: Adam MP, Bick S, Mirzaa GM, et al., editors. GeneReviews® [Internet]. Seattle (WA): University of Washington, Seattle; 1993-2026.

60

© Copyright. Society of Diagnostic Medical Sonography. All Rights Reserved.

Thank You!

Jenna N. Laquerre is the program director for the Diagnostic Medical Sonography and Bachelor of Science in Medical Imaging programs at Palm Beach State College, where she also serves as adjunct faculty for the Radiography program. She is registered in multiple sonography specialties, including abdomen, obstetrics and gynecology, pediatric sonography, breast, and vascular technology, and holds radiography certification. Jenna Laquerre is an active member of the Society of Diagnostic Medical Sonography, the American Society of Radiologic Technologists, and Lambda Nu National Honor Society. She contributes to the profession as a manuscript peer reviewer for Radiologic Technology and the Journal of Diagnostic Medical Sonography and is a published author and national speaker. Her clinical experience includes work at Nemours Children's Hospital and AdventHealth. She is also the author of *Lange Review: The Fundamentals of Pediatric Sonography: A Registry Review and Protocol Guide*.



61

© Copyright. Society of Diagnostic Medical Sonography. All Rights Reserved.