Placenta & the Umbilical Cord: "Is This Normal?"

Jenna N. Laquerre, MEd, RT(R)(ARRT), RDMS (AB, OB/GYN, PS, BR), RVT
Program Director of Diagnostic Medical Sonography
and Bachelor of Science in Medical Imaging,
Palm Beach State College

1

1

SPEAKER PRESENTATION DISCLAIMER

The content and views presented are made available for educational purposes only. The information presented are the opinions of the presenter and do not necessarily represent the views of the Society of Diagnostic Medical Sonography (SDMS) or its affiliated organizations, officers, Boards of Directors, or staff members.

The presenter is responsible for ensuring balance, independence, objectivity, scientific rigor, and avoiding commercial bias in their presentation. Before making the presentation, the presenter is required to disclose to the audience any relevant financial interests or relationships with manufacturers or providers of medical products, services, technologies, and programs.

The SDMS and its affiliated organizations, officers, Board of Directors, and staff members disclaim any and all liability for all claims that may arise out of the use of this educational activity.

2

2

© Copyright. Society of Diagnostic Medical Sonography. All Rights Reserved.

RESEARCH DISCLAIMER

The information presented in this presentation is based on research conducted to the best of the presenters' abilities and knowledge. Research involves uncertainty and is subject to limitations. The findings and conclusions presented herein may be influenced by various factors including but not limited to data quality, methodology, assumptions, and interpretation.

Research outcomes may not always accurately predict real-world scenarios or future events. While the presenter may make efforts to ensure the accuracy and reliability of the information presented, completeness or absolute correctness is not guaranteed. This presentation is intended for informational purposes only and should not be construed as professional advice. Participants are encouraged to independently verify any information provided and consult relevant experts or professionals where appropriate.

The SDMS and its affiliated organizations, officers, Board of Directors, and staff members disclaim any and all liability for all claims that may arise out of the use of this educational activity.

3

3

GENERATIVE AI DISCLAIMER

The presenter utilized the use of large language models (LLMs) and generative artificial intelligence (AI) as a productivity tool to assist in drafting and refining content in this presentation.

While these tools can aid in structuring ideas, summarizing, paraphrasing, and language polishing, they have inherent limitations and cannot replace human creativity, critical thinking, or expert judgment. AI-generated content may contain errors, biases, or gaps in knowledge.

This presentation is intended for informational purposes only and should not be construed as definitive or authoritative guidance. Participants are encouraged to critically evaluate the information presented and consult relevant experts as needed. The SDMS and its affiliated organizations, officers, Board of Directors, and staff members disclaim any and all liability for claims that may arise from the use or interpretation of this educational material.

4

4

© Copyright. Society of Diagnostic Medical Sonography. All Rights Reserved.

2026 SDMS Annual Conference

Course Description

This session provides a case-based review of placental and findings that influence clinical management in obstetric sonography. Participants will explore key distinctions among placental abnormalities, cord insertion variations, and associated risks, including conditions linked to fetal growth restriction and hemorrhage. Emphasis is placed on identifying features that warrant further evaluation and applying imaging insights to support clinical decision-making and patient care.

5

5

Learning Objectives

- Describe placental and umbilical cord abnormalities that influence clinical decision-making.
- Identify sonographic features of abnormal placental and cord anatomy using imaging criteria to support further evaluation.
- Differentiate normal variants from high-risk findings to support appropriate clinical assessment and follow-up.

6

6

© Copyright. Society of Diagnostic Medical Sonography. All Rights Reserved.

The Lifeline

- The placenta serves as the primary interface for **gas exchange, nutrient transfer, waste removal, and hormonal support** throughout pregnancy.
- The umbilical cord provides the vascular connection between the fetus and placenta, normally containing **two arteries and one vein surrounded by protective Wharton jelly**.
- Together, the placenta and cord form a dynamic fetal support system whose structure and function directly influence **growth, oxygenation, and pregnancy outcome**.

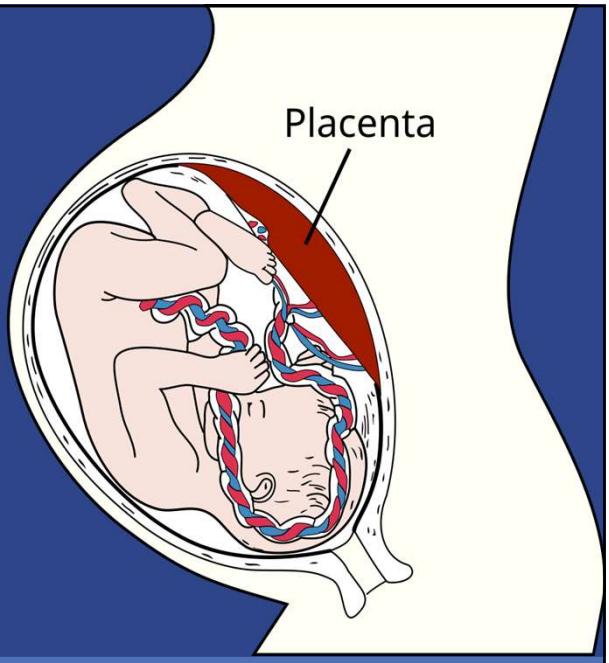

Gray38.png: User Magnus Manske on en.wikipediaderivative work: Amada44 talk to me, Public domain, via Wikimedia Commons

7

7

Embryology: Beginning with Implantation

- Following fertilization and cleavage, the developing conceptus progresses from a **morula to a blastocyst**, containing an inner cell mass and an outer trophoblastic layer.
- The trophoblast facilitates implantation into the endometrium and contributes to the developing **placental–maternal interface**.
- In response to implantation, the endometrium undergoes **decidualization**, forming specialized regions that support and surround the early pregnancy.

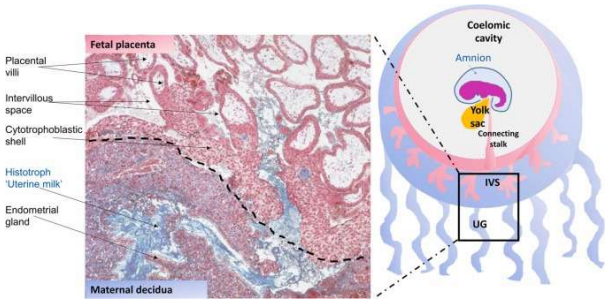

**Developing placenta during embryonic development.*

Tereza Cindrova-Davies, nd Amanda N. Sferruzi, CC BY-SA 4.0 <https://creativecommons.org/licenses/by-sa/4.0>, via Wikimedia Commons

8

© Copyright. Society of Diagnostic Medical Sonography. All Rights Reserved.

Chorion, Amnion, and Villous Development

- The developing chorion differentiates into the **chorion frondosum**, where villi persist and proliferate, and the smoother **chorion laeve**, where villi regress.
- Chorionic villi create the branching fetal component of the placenta and contain fetal capillaries that participate in maternal–fetal exchange.
- As the amniotic cavity enlarges, the amnion expands around the developing fetus and ultimately contributes to the membranes covering the fetal surface and umbilical cord.

9

9

Basal Plate

- The **basal plate forms the maternal surface of the placenta** and lies at the interface between placental tissue and the uterine wall.
- Maternal spiral arteries deliver blood into the intervillous space, where it circulates around the chorionic villi to support maternal–fetal exchange.
- Understanding the normal basal plate and retroplacental interface is essential when assessing for **hemorrhage, abnormal placental adherence, and other placental pathology**.

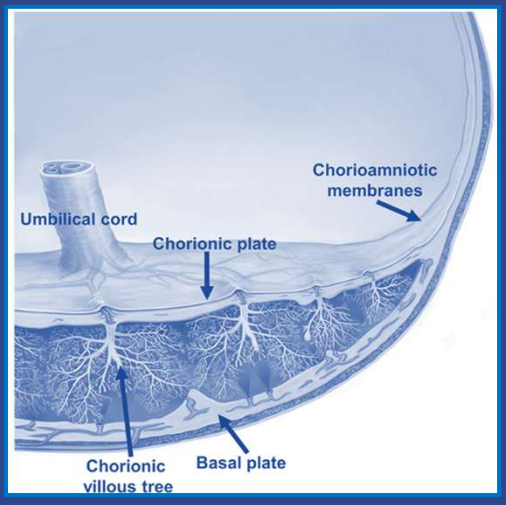

Kim CJ, Romero R, Chaemsaithong P, Kim JS. Chronic inflammation of the placenta: definition, classification, pathogenesis, and clinical significance. Am J Obstet Gynecol. 2015 Oct;213(4 Suppl):S53-69. doi: 10.1016/j.ajog.2015.08.041. PMID: 26428503; PMCID: PMC4782598.

10

© Copyright. Society of Diagnostic Medical Sonography. All Rights Reserved.

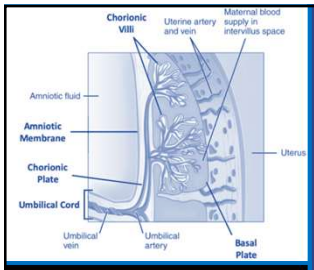



Chorionic Plate

- The **chorionic plate forms the fetal surface of the placenta** and faces the amniotic cavity.
- It is covered by amnion, while fetal vessels branch from the umbilical cord and course across its surface before entering the placental villous circulation.
- In contrast to the maternal basal plate, the chorionic plate provides a useful sonographic landmark for recognizing the **fetal placental surface and its vascular architecture**.

Image: Frontiers in Microbiology, via FAPESP (de Pierro, 2021) and Mme Mim, CC BY-SA 4.0 <https://creativecommons.org/licenses/by-sa/4.0>, via Wikimedia Commons

11

11

Formation of the Chorion:

- The chorion is formed from the extraembryonic mesoderm and the trophoblast.
- It plays a role in the exchange of nutrients and waste between the mother and the fetus.

Composition of the Chorionic Plate:

- The chorionic plate consists of the amnion, extraembryonic tissue, and chorionic villi.
- These components contribute to the structure and function of the placenta.

Basal Plate:

- The basal plate is the peripheral region of the maternal side of the placenta in contact with the uterine wall.
- It facilitates the transfer of nutrients and gases between the maternal blood supply and the placenta.

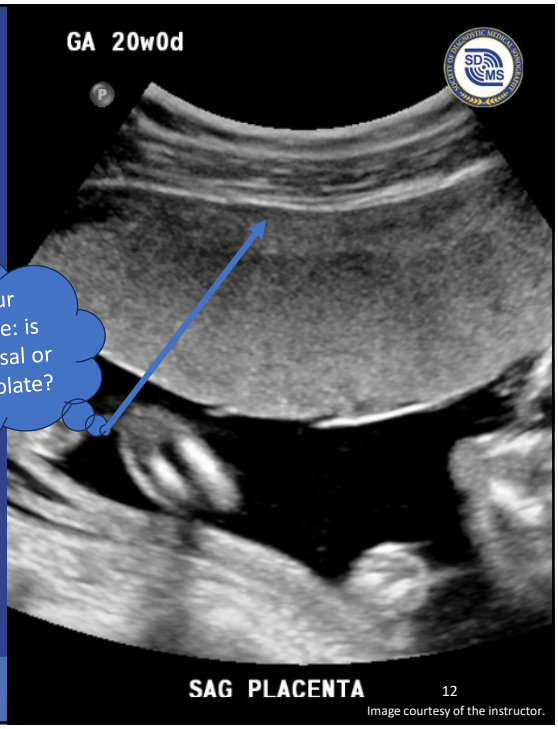

12

Image courtesy of the instructor.

12

© Copyright. Society of Diagnostic Medical Sonography. All Rights Reserved.

Cotyledons and Intervillous Space

- The maternal surface of the placenta is organized into **placental lobules, or cotyledons**, containing branching chorionic villi that form the functional exchange surface.
- Maternal blood enters the **intervillous space through the spiral arteries**, where it circulates around the chorionic villi before returning through the maternal venous system.
- Within the villi, fetal capillaries remain separate from maternal blood, allowing **oxygen, nutrients, and waste products to cross the placental membrane without direct mixing of the two circulations**.

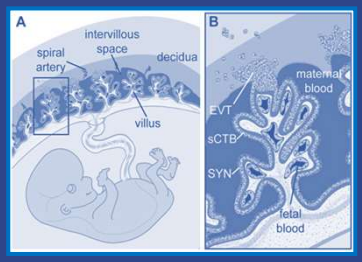

13

Figure posted on 2011-03-02, 20:08 authored by Varvara B. Zeldovich, Jennifer R. Robbins, Mirhan Kapidzic, Peter Lauer, Anna I. Bakardjiev

13

Umbilical Cord Development

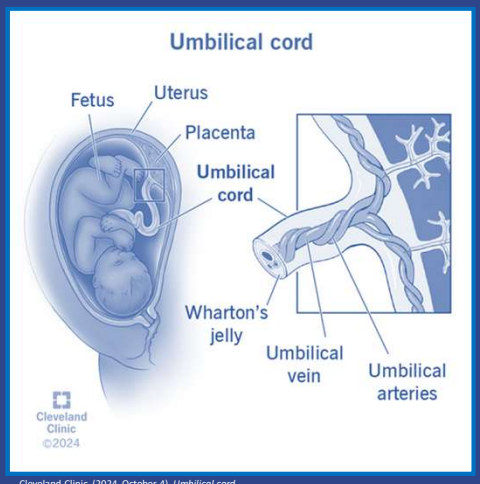

Cleveland Clinic. (2024, October 4). *Umbilical cord*.

- The umbilical cord develops during early embryogenesis as the **connecting or body stalk, yolk stalk, and allantoic structures are brought together** by embryonic folding and expansion of the amnion.
- The **allantoic vessels develop into the umbilical vessels**, while the enlarging amniotic cavity envelops the developing cord with an amniotic covering.
- The vessels become surrounded by **Wharton jelly**, a specialized connective tissue that cushions and protects them throughout pregnancy.

14

14

© Copyright. Society of Diagnostic Medical Sonography. All Rights Reserved.

Normal Cord Anatomy

- A normal umbilical cord contains **two smaller umbilical arteries and one larger umbilical vein** surrounded by Wharton jelly.
- The paired arteries carry blood **away from the fetus toward the placenta**, while the umbilical vein returns oxygenated, nutrient-rich blood to the fetus.
- An outer amniotic covering and protective Wharton jelly help maintain vessel integrity as the cord **coils, bends, and moves throughout pregnancy**.

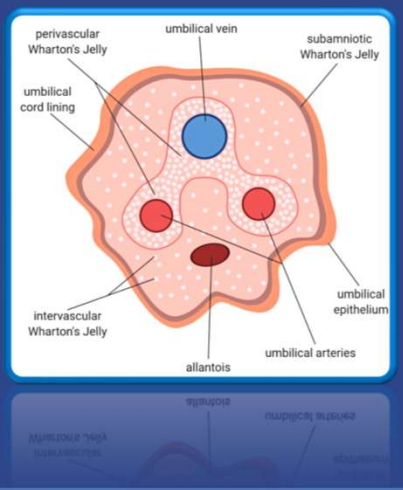

Stefańska K, Ożegowska K, Hutchings G, et al., CC BY 4.0 <https://creativecommons.org/licenses/by/4.0>, via Wikimedia Commons

15

15

Function of the Placenta

- The placenta supports fetal **respiration, nutrition, and excretion** by facilitating the exchange of oxygen, nutrients, carbon dioxide, and metabolic waste between maternal and fetal circulations.
- It also functions as an important **endocrine organ**, producing hormones that support pregnancy and regulate maternal physiology.
- Together, these functions allow the placenta to serve as a temporary physiologic support system for the fetus while its own organs continue to develop and mature.



16

Image courtesy of the author.

16

© Copyright. Society of Diagnostic Medical Sonography. All Rights Reserved.

Function of the Cord

- The umbilical cord provides the **vascular bridge between the fetal circulation and the placenta**, allowing continuous exchange throughout pregnancy.
- The single umbilical vein carries **oxygenated, nutrient-rich blood from the placenta toward the fetus**, while the paired arteries return less oxygenated blood and metabolic waste to the placenta.
- Maintaining uninterrupted blood flow through these vessels is essential for **fetal oxygenation, growth, and overall well-being**.

17

17

Normal Flow Pattern

The **umbilical vein carries oxygenated, nutrient-rich blood from the placenta toward the fetus**.

The paired **umbilical arteries return less oxygenated blood and fetal metabolic waste from the fetus back to the placenta**.

This continuous circuit connects the fetal and placental circulations while keeping fetal and maternal blood **physically separate within the placenta**.

18

18

© Copyright. Society of Diagnostic Medical Sonography. All Rights Reserved.

Normal Doppler Findings

- The normal placenta develops into a **low-resistance vascular bed**, allowing blood to continue moving through the umbilical arteries during both systole and diastole.
- Umbilical artery waveforms normally demonstrate **forward end-diastolic flow**, with placental vascular resistance decreasing as pregnancy advances.
- Progressive increases in diastolic flow reflect the expanding placental vascular network and provide an important baseline for identifying **abnormal placental resistance**.

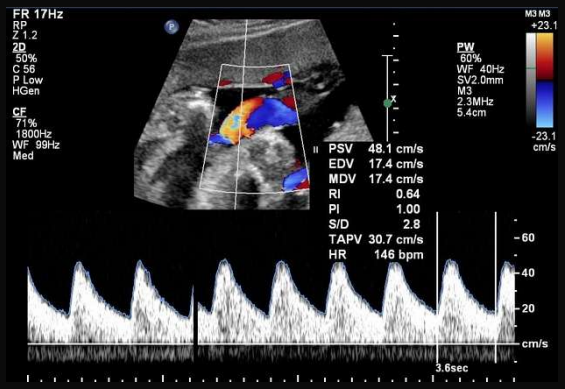

Case courtesy of Henry Knipe, Radiopaedia.org, rID: 37831

19

19

The Sonographic Checklist



https://www.vecteezy.com/free-vector

- Placental evaluation should include **location, morphology, thickness when indicated, and overall echotexture or maturation**.
- The **placental cord insertion** should be identified and characterized whenever technically possible.
- The inferior placental edge should also be assessed in relation to the **internal cervical os**, with additional imaging performed when that relationship is uncertain.

20

20

© Copyright. Society of Diagnostic Medical Sonography. All Rights Reserved.

Placental Location

Singleton Placenta: The Baseline

- In a typical singleton pregnancy, **one fetus is supported by one primary placental unit**.
- The placenta should be surveyed as a complete structure to establish its **location, contour, morphology, and relationship to the uterine wall**.
- Establishing this normal baseline makes it easier to recognize findings such as **accessory lobes, bilobed morphology, abnormal cord insertion, or low placental implantation**.

© Copyright. Society of Diagnostic Medical Sonography. All Rights Reserved.

Noting Placental Location

- Placental location should be described according to its relationship to the uterine walls as **anterior, posterior, fundal, right or left lateral, or a combination of these locations**.
- When placental tissue extends into the lower uterine segment, its relationship to the **internal cervical os** becomes more clinically important than the descriptive location alone.
- A placenta that appears low earlier in pregnancy may later appear farther from the cervix as the uterus enlarges and the lower uterine segment develops.

23

23

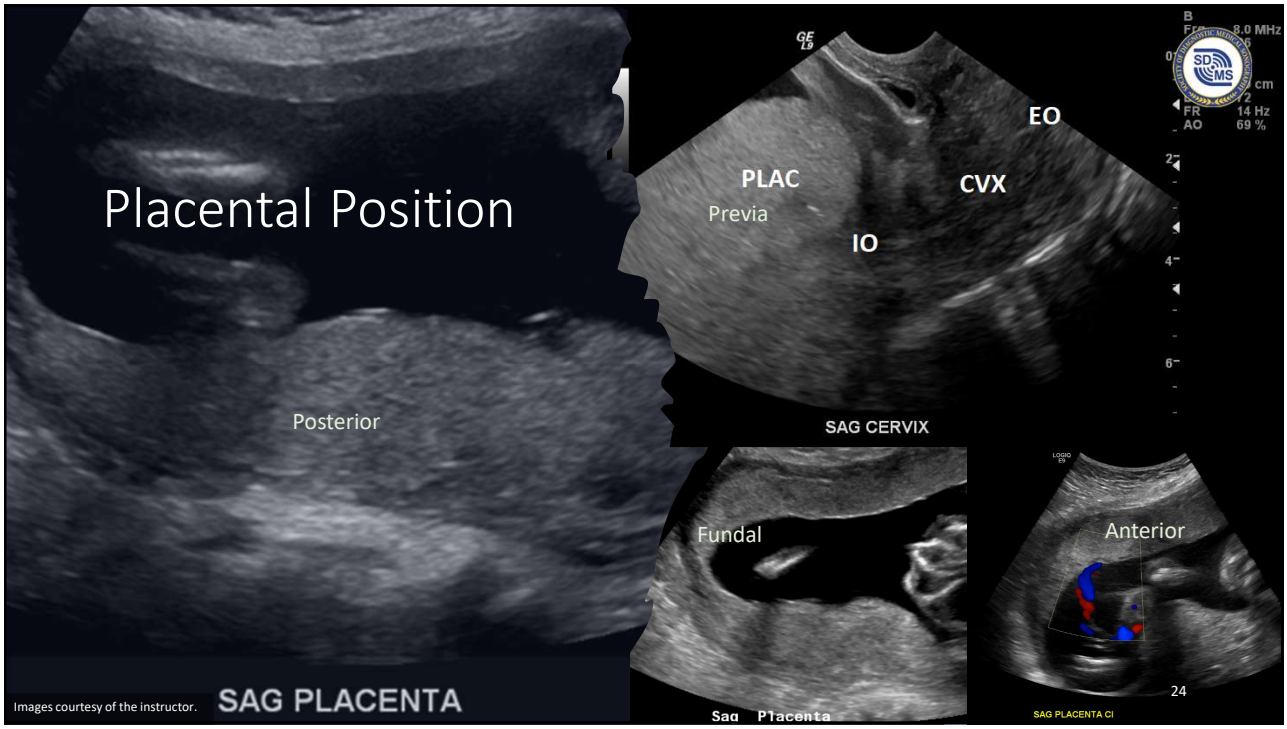

24

© Copyright. Society of Diagnostic Medical Sonography. All Rights Reserved.

The Internal Os Relationship

- The relationship between the **inferior placental edge and the internal cervical os** should be clearly documented whenever the placenta extends into the lower uterine segment.
- Measurement should be obtained along the shortest distance from the placental edge to the internal os, with **transvaginal ultrasound used when the relationship cannot be confidently assessed transabdominally**.
- Accurate assessment is important because the measured relationship determines whether placental location is considered **normal, low-lying, or placenta previa**.

25

25

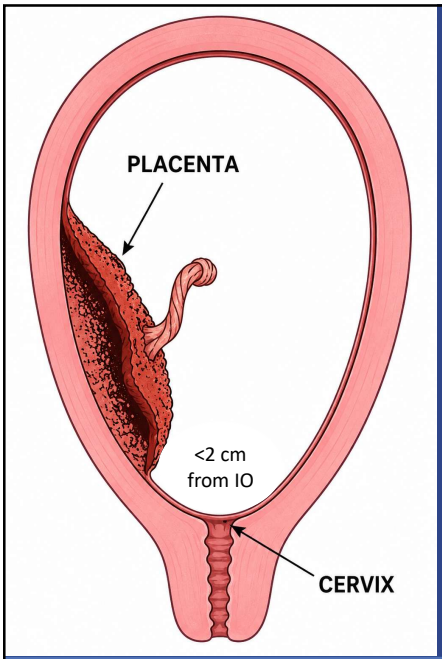

Low-Lying Placenta

- A **low-lying placenta** extends into the lower uterine segment with the placental edge close to, but not covering, the internal cervical os.
- A commonly used sonographic threshold is a placental edge **less than 2 cm from the internal os**, with the actual edge-to-os distance documented whenever possible.
- Many low-lying placentas identified in the second trimester no longer remain low later in pregnancy as the **lower uterine segment develops and the uterus enlarges**.

OpenAI. (2026). AI-generated illustration of placental location relative to the internal cervical os. ChatGPT Images 2.0.

26

26

© Copyright. Society of Diagnostic Medical Sonography. All Rights Reserved.

Placenta Previa

- **Placenta previa** occurs when placental tissue reaches or overlies the internal cervical os and may obstruct the cervical opening.
- Previa may be described as **marginal, partial, or complete** depending on the degree of involvement of the internal cervical os.
- Identification of the placental relationship to the internal os is important because placenta previa is associated with increased risk for **antepartum hemorrhage, preterm delivery, and placenta accreta spectrum**.

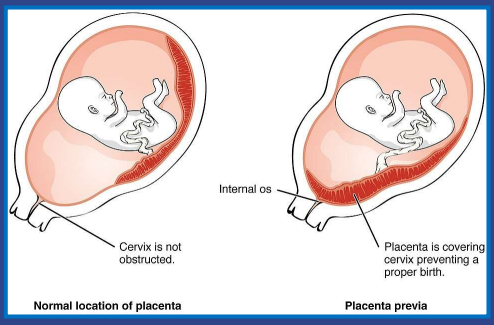

27

OpenStax College, CC BY 3.0 <https://creativecommons.org/licenses/by/3.0>, via Wikimedia Commons

27

Follow-Up and Transvaginal Imaging

- **Transvaginal ultrasound is the preferred method of assessment** when the placental edge and internal cervical os cannot be confidently defined transabdominally.
- Because placental position identified earlier in pregnancy may change relative to the cervix, **repeat imaging later in gestation** is commonly performed for persistent low-lying placenta or previa.
- Follow-up assessment should also evaluate for associated findings such as **abnormal cord insertion or fetal vessels near the internal os**, particularly when vasa previa is a concern.

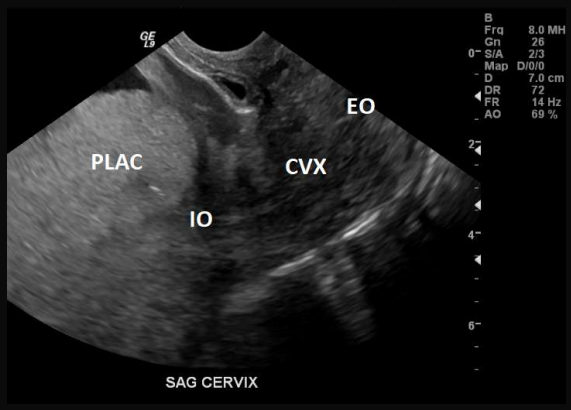

28

Image courtesy of the instructor.

28

© Copyright. Society of Diagnostic Medical Sonography. All Rights Reserved.

Placental Grading

a Visual Assessment

29

29

Grade 0 Placenta

- A Grade 0 placenta demonstrates a **homogeneous echotexture with a smooth, uninterrupted chorionic plate**.
- Calcification is absent or minimal, and the placental substance lacks the echogenic densities seen with later maturation.
- This appearance is characteristic of the **least mature end of the Grannum grading spectrum** and is most commonly encountered earlier in gestation.



30

Image courtesy of the instructor.

30

© Copyright. Society of Diagnostic Medical Sonography. All Rights Reserved.

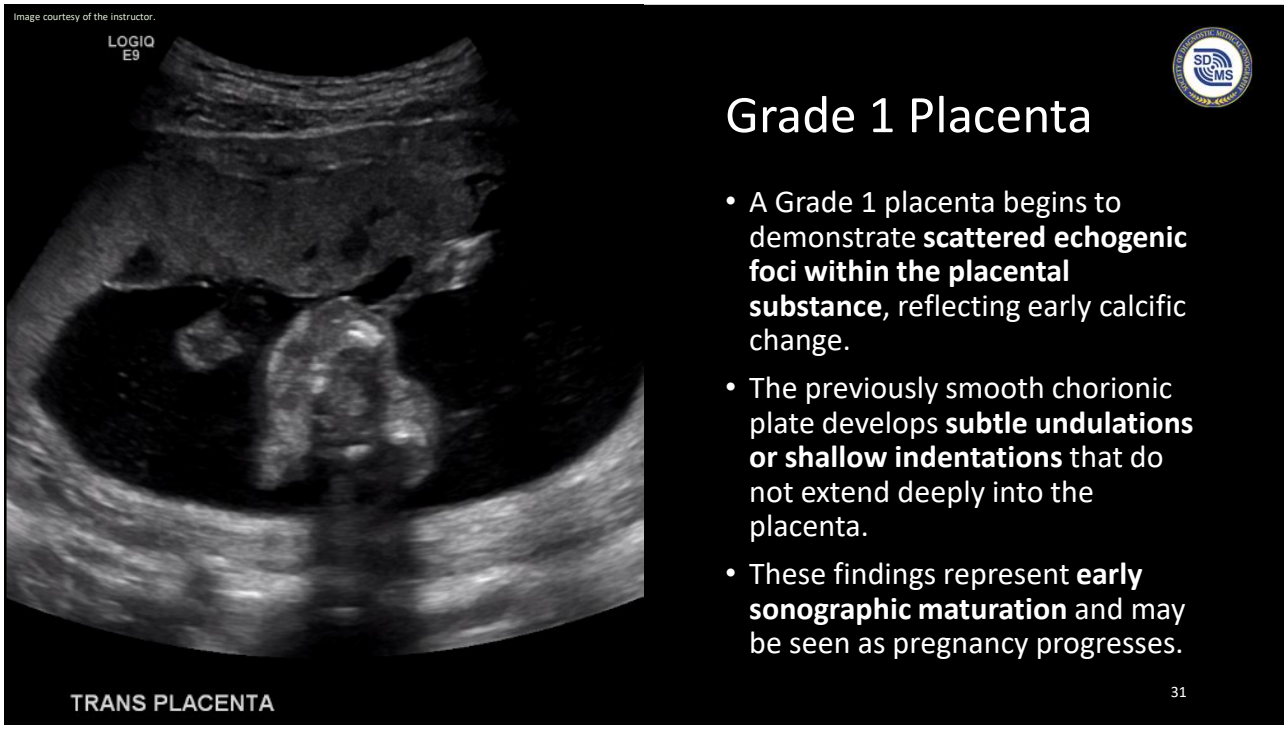

31

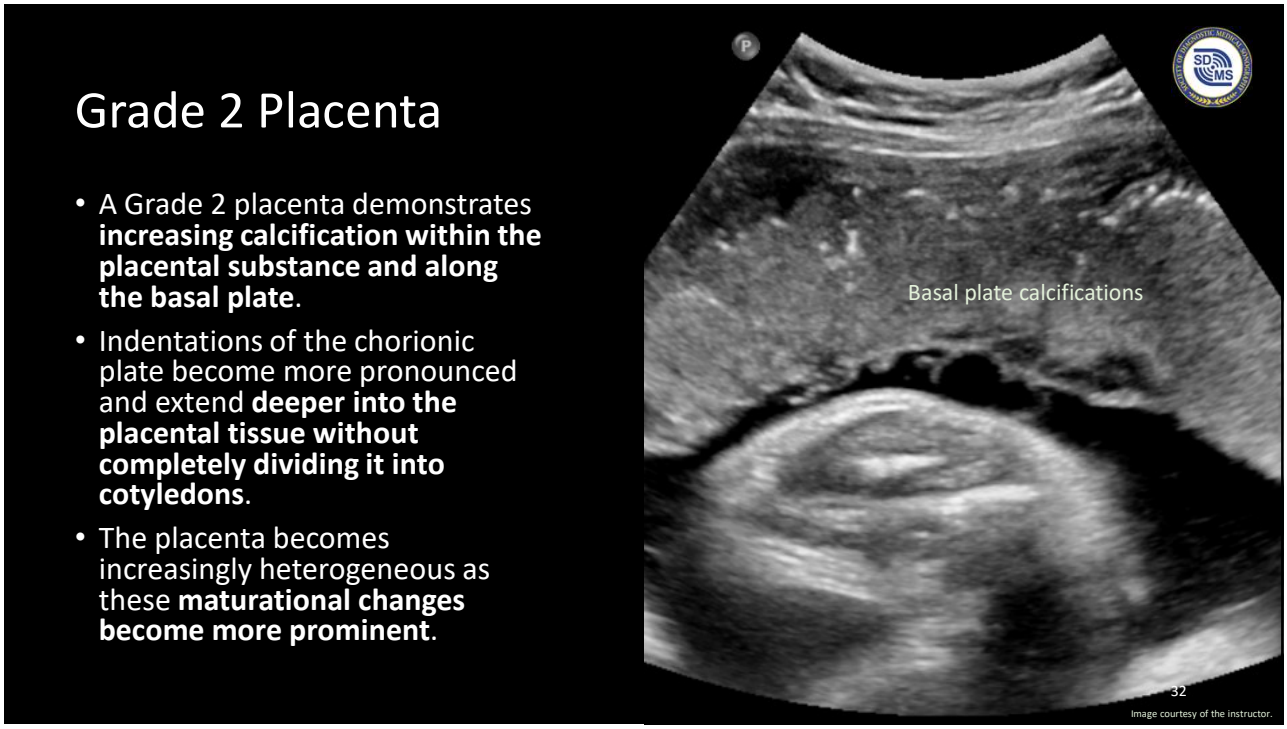

32

© Copyright. Society of Diagnostic Medical Sonography. All Rights Reserved.

2026 SDMS Annual Conference

Grade 3 Placenta

- A Grade 3 placenta demonstrates more **extensive calcification**, particularly along the basal plate, with marked heterogeneity of the placental substance.
- Deep chorionic plate indentations extend toward or reach the basal plate, creating the characteristic appearance of **cotyledon-like segmentation**.
- Grade 3 represents the **most advanced sonographic maturation pattern** in the Grannum classification and may be an expected finding near term.



33

Image courtesy of the instructor.

33

Important To Note



A Grade 3 placental appearance **before approximately 36–37 weeks** is considered premature placental calcification and warrants closer clinical correlation.



Premature Grade 3 maturation has been associated with increased risk of **fetal growth restriction, small-for-gestational-age birth, preeclampsia, and other adverse perinatal outcomes**.



Placental grade should **not be interpreted in isolation**; fetal growth, amniotic fluid, Doppler findings, maternal risk factors, and the overall clinical picture remain essential.

Image courtesy of the instructor and Indiramani, Y. , Ratnakumari, V. and Jyothirmayi, B. (2016) Colour Doppler Study of Umbilical Artery in Antenatal Women with Severe Preeclampsia and Foetal Outcome. Open Journal of Obstetrics and Gynecology, 6, 129-135. doi: 10.4236/ojog.2016.62016., and Ricmart01 CC BY-SA 4.0 <https://creativecommons.org/licenses/by-sa/4.0>, via Wikimedia Commons

34

34

© Copyright. Society of Diagnostic Medical Sonography. All Rights Reserved.

Placental Thickness Assessment

- Placental thickness normally **increases with gestational age** and should be measured perpendicular to the uterine wall, ideally near the cord insertion while excluding the myometrium.
- A **thickened placenta** may be associated with maternal diabetes or anemia, fetal hydrops, infection, aneuploidy, hemorrhage, or other placental and fetal abnormalities.
- A **thin placenta** may be seen with fetal growth restriction, low birth weight, or polyhydramnios, so thickness should always be interpreted in relation to gestational age and the remainder of the examination.

35

35



36

© Copyright. Society of Diagnostic Medical Sonography. All Rights Reserved.

Lakes vs. Lacunae

- **Placental lakes** are typically smooth or well-defined maternal blood spaces with slow flow and are commonly found within otherwise normal placental tissue.
- **PAS-associated lacunae** tend to be numerous, irregular, and located deeper near the placental bed, often demonstrating turbulent high-velocity flow and identifiable feeder vessels on Doppler.
- The distinction depends on **morphology, location, vascularity, and clinical risk factors**, because a hypoechoic placental space by itself does not establish placenta accreta spectrum.



Case courtesy of Jatin Sehrawat, Radiopaedia.org, rID: 238561 (PAS) and Inubashiri, E., Deguchi, K., Abe, K. *et al.* Three-dimensional high-definition flow in the diagnosis of placental lakes. *J Med Ultrasonics* **41**, 491–494 (2014). https://doi.org/10.1007/s10396-014-0535-y

37

37

Placental Cysts and Hematomas

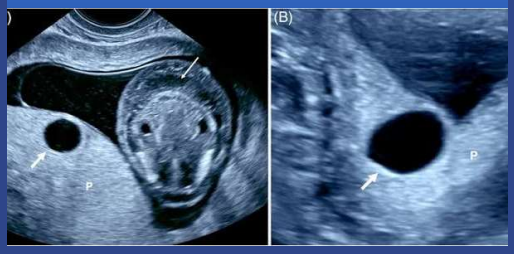

- True placental cysts are usually **anechoic, avascular structures along the fetal surface or chorionic plate** and are often associated with a favorable outcome when small and isolated.
- Placental hematomas represent **collections of blood whose appearance changes with age**, ranging from echogenic or nearly isoechoic when acute to increasingly hypoechoic or complex as the blood evolves.
- Their location matters: **subchorionic or marginal collections lie near the placental edge or beneath the chorion, while retroplacental hematomas form behind the basal plate and may accompany placental separation**.

Sepulveda, W., Stern, J., von Bischhoffshausen, S., Tonni, G., & Meagher, S. (2025). Placental cysts and atypical sonolucencies at 11–13 weeks' gestation: Sonographic features and clinical significance. *Journal of Clinical Ultrasound, 53*(6), 1234–1239. https://doi.org/10.1002/jcu.23964

38

38

© Copyright. Society of Diagnostic Medical Sonography. All Rights Reserved.

Circumvallate Placenta

- A circumvallate placenta is an **extrachorial placenta in which the chorionic plate is smaller than the basal plate**, causing the membranes to fold back over the fetal placental surface.
- Sonographically, the placental margin may appear **thickened, elevated, or rolled**, producing a linear ridge or characteristic shelf-like membrane projecting from the placental edge.
- Although historically associated with bleeding, preterm birth, FGR, and abruption, **recent data suggest that a prenatal sonographic diagnosis alone may not predict an adverse pregnancy outcome**.

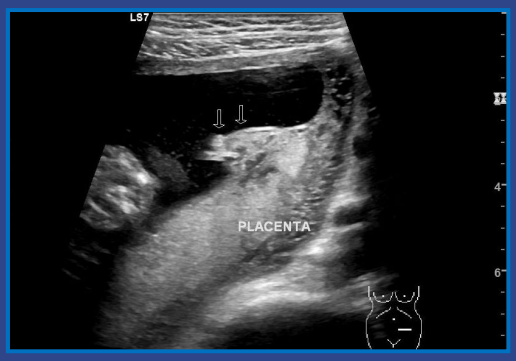

Case courtesy of Maulik S Patel, Radiopaedia.org, rID: 53147

39

39

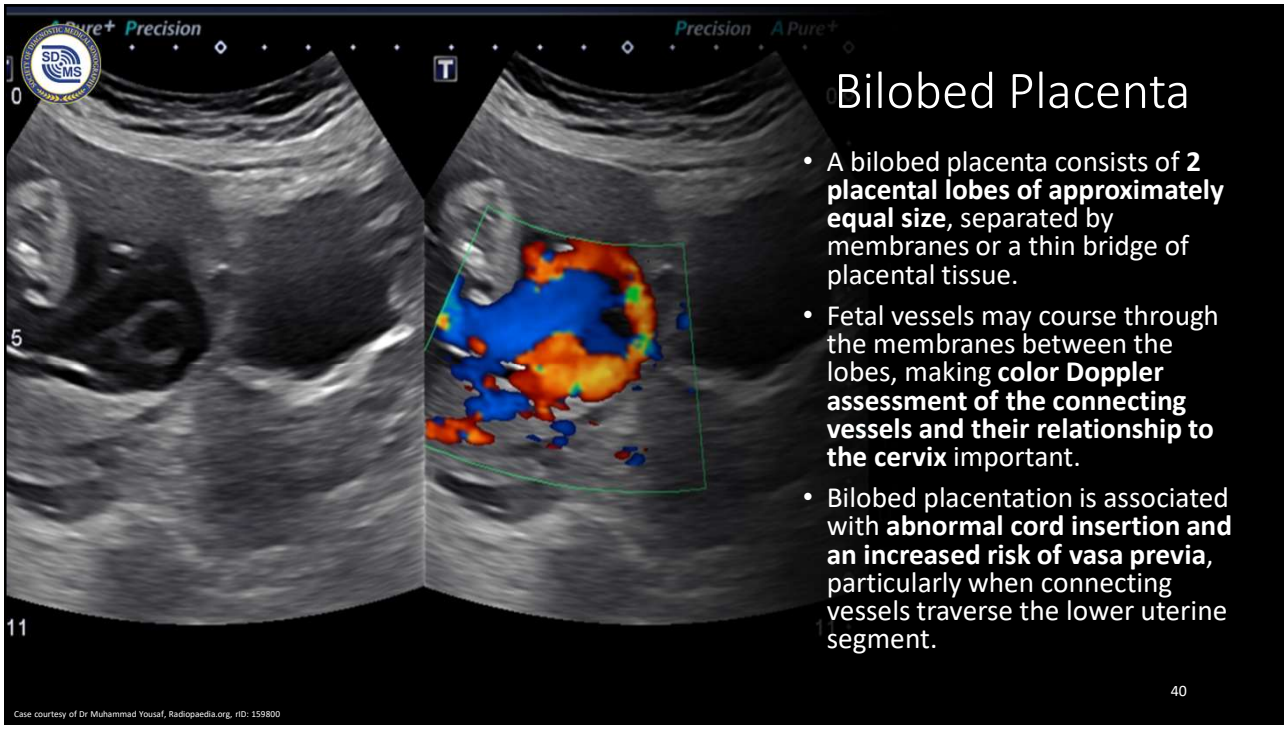

Bilobed Placenta

- A bilobed placenta consists of **2 placental lobes of approximately equal size**, separated by membranes or a thin bridge of placental tissue.
- Fetal vessels may course through the membranes between the lobes, making **color Doppler assessment of the connecting vessels and their relationship to the cervix** important.
- Bilobed placentation is associated with **abnormal cord insertion and an increased risk of vasa previa**, particularly when connecting vessels traverse the lower uterine segment.

Case courtesy of Dr Muhammad Yousaf, Radiopaedia.org, rID: 159800

40

40

© Copyright. Society of Diagnostic Medical Sonography. All Rights Reserved.

Succenturiate Lobe

- A succenturiate placenta contains **one or more smaller accessory lobes separate from the main placental body** and connected by fetal vessels coursing through the membranes.
- If these unprotected connecting vessels pass over or near the internal cervical os, they may produce **Type II vasa previa**.
- An accessory lobe may also remain within the uterus after delivery, increasing the risk of **retained placental tissue, postpartum hemorrhage, and infection**.



41

Case courtesy of Subash Thapa, Radiopaedia.org, rID: 92031

41

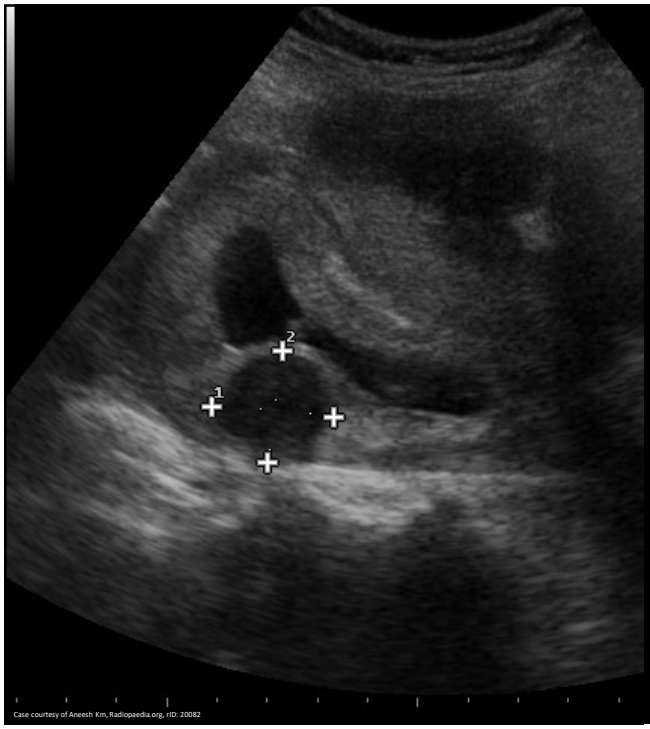

Case courtesy of Aneesh Km, Radiopaedia.org, rID: 20082

Chorioangioma

- A chorioangioma is a **benign, non-trophoblastic vascular lesion of the placenta**, most often arising beneath the chorionic plate near the fetal surface or cord insertion.
- Sonographically, it typically appears as a **well-circumscribed placental mass with internal vascularity and identifiable feeding vessels on color Doppler**.
- Most small lesions are clinically insignificant, while **large chorioangiomas—particularly ≥4 cm—may cause polyhydramnios, fetal anemia, cardiomegaly, high-output cardiac failure, hydrops, and adverse pregnancy outcome**.

42

42

© Copyright. Society of Diagnostic Medical Sonography. All Rights Reserved.

Placental Abruption

- Placental abruption is the **premature separation of a normally implanted placenta from the uterine wall before delivery**, with hemorrhage occurring at the maternal–placental interface.
- Sonographic findings may include a **retroplacental hematoma, placental thickening or heterogeneity, separation from the uterine wall, and marginal or subchorionic hemorrhage**.
- The appearance of hemorrhage changes with time, and an acute collection may be **isoechoic to the placenta and therefore difficult to recognize sonographically**.

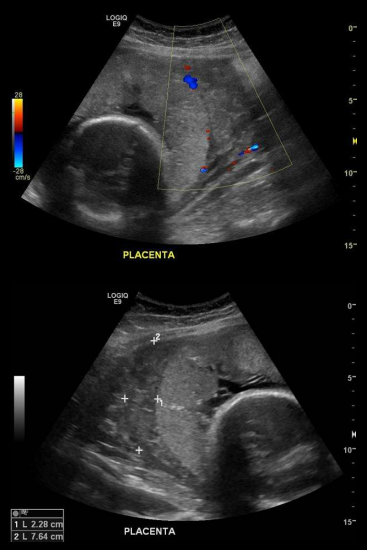

43

Case courtesy of Andrew Dixon, Radiopaedia.org, rID: 14281

43

Placental Abruption

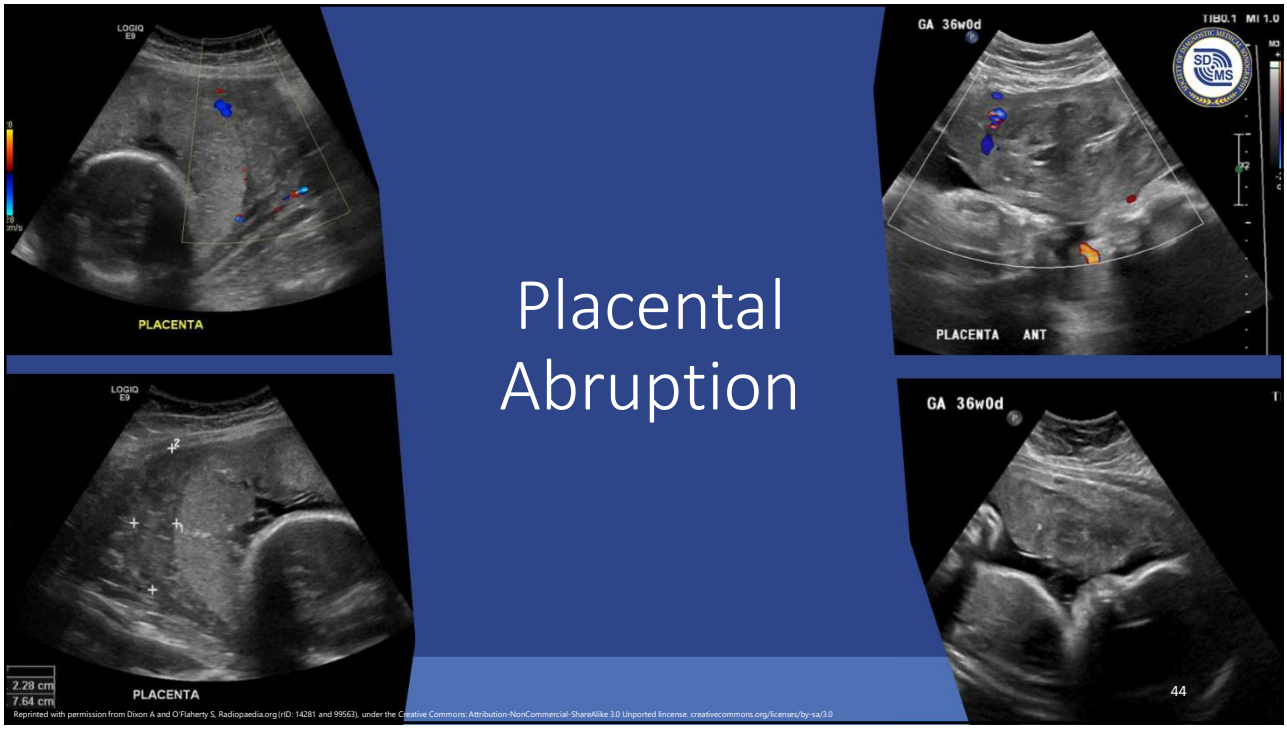

Reprinted with permission from Dixon A and O'Flaherty S. Radiopaedia.org (rID: 14281 and 99563), under the Creative Commons: Attribution-NonCommercial-ShareAlike 3.0 Unported license. creativecommons.org/licenses/by-sa/3.0

44

44

© Copyright. Society of Diagnostic Medical Sonography. All Rights Reserved.

When Ultrasound Looks Normal

- **A normal ultrasound does not exclude placental abruption**, because acute hemorrhage may be small, concealed, or sonographically indistinguishable from adjacent placental tissue.
- Clinical findings may include **vaginal bleeding, abdominal or back pain, uterine tenderness or hypertonicity, frequent contractions, and abnormal fetal heart rate patterns**, although presentation varies.
- When abruption is suspected, sonographic findings must be interpreted alongside the **maternal history, physical findings, fetal status, and hemodynamic condition** rather than used to rule the diagnosis in or out alone.

45

45

Placenta Accreta Spectrum: What Is It?

- Placenta accreta spectrum (PAS) describes **abnormal adherence or invasion of chorionic villi into the uterine wall** resulting from disruption of the normal decidual interface.
- **Placenta accreta** refers to villi abnormally attached to the myometrium, while **placenta increta** describes villous invasion into the myometrium.
- **Placenta percreta** represents the most extensive form, with placental tissue extending through the myometrium and uterine serosa and potentially involving adjacent structures such as the bladder.

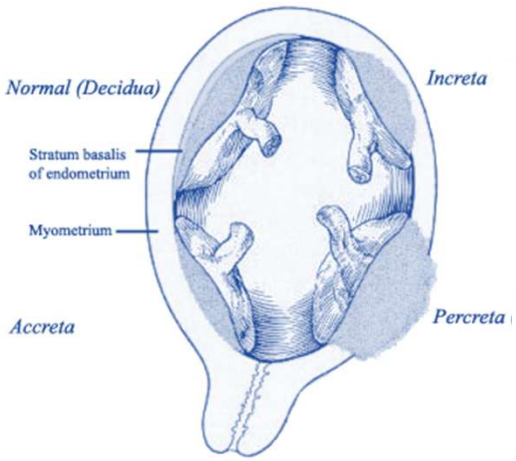

TheNewMessiah at English Wikipedia, Public domain, via Wikimedia Commons

46

© Copyright. Society of Diagnostic Medical Sonography. All Rights Reserved.

PAS Risk Factors

The strongest recognized risk factor for PAS is **prior cesarean delivery**, with risk increasing as the number of previous cesarean deliveries rises.

Placenta previa or a low anterior placenta overlying a prior uterine scar should heighten concern because abnormal placentation is more likely where the endometrial–myometrial interface has been disrupted.

Additional risk factors include **prior uterine surgery or curettage, Asherman syndrome, multiparity, and advanced maternal age**.

47

47

PAS Sonographic Signs

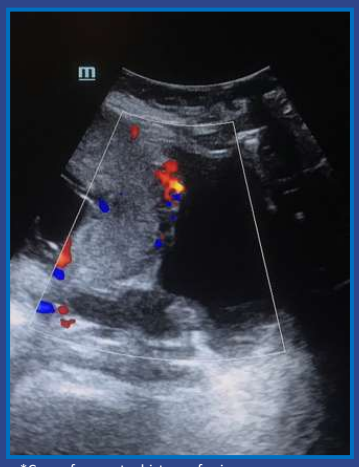

*Case of percreta, history of prior cesarean.

- Grayscale findings associated with PAS include **multiple irregular placental lacunae, loss of the normal retroplacental clear zone, and marked thinning of the underlying myometrium**.
- Additional findings may include **placental bulging, disruption of the uterine serosa–bladder interface, and abnormal extension of placental tissue toward surrounding structures**.
- Color Doppler may demonstrate **turbulent flow within lacunae, increased subplacental or uterovesical vascularity, and bridging vessels extending beyond the placental margin**.

Case courtesy of Aws Qahtan Hamdi, Radiopaedia.org, rID: 149552

48

48

© Copyright. Society of Diagnostic Medical Sonography. All Rights Reserved.

Twin Pregnancies: Additional Considerations

49

49

Zygosity vs. Chorionicity vs. Amnionicity

- **Zygosity** describes genetic origin—whether twins arise from two independently fertilized ova (**dizygotic**) or division of a single fertilized ovum (**monozygotic**).
- **Chorionicity** describes the number of chorions and therefore the placental arrangement, distinguishing **dichorionic from monochorionic** pregnancies.
- **Amnionicity** describes the number of amniotic sacs surrounding the fetuses, distinguishing **diamniotic from monoamniotic** pregnancies.

50

50

© Copyright. Society of Diagnostic Medical Sonography. All Rights Reserved.

Dizygotic vs. Monozygotic Twins

- **Dizygotic twins** result from fertilization of two separate ova by two separate sperm and are therefore **dichorionic diamniotic**, with each fetus developing its own chorion and amnion.
- **Monozygotic twins** result when a single fertilized ovum divides into two embryos and may develop as **dichorionic diamniotic, monochorionic diamniotic, or monochorionic monoamniotic twins**.
- Because monozygotic twins can have several placental configurations, **zygosity cannot be determined reliably from placental number alone**.

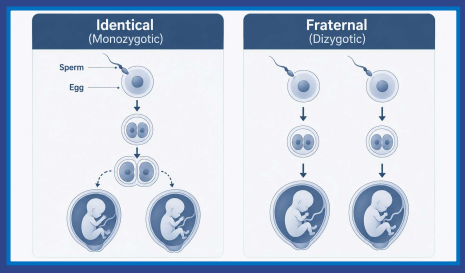

51

AI-generated image created with OpenAI ChatGPT (GPT-5.6 Sol), 2026.

51

Dichorionic Diamniotic Twins

- Dichorionic diamniotic (DCDA) twins have **two chorions and two amniotic sacs**, with each fetus supported by its own placental circulation.
- The dividing membrane contains **two amnions and two chorionic layers**, creating a relatively thick intertwin septum.
- Extension of chorionic tissue between the membrane layers produces the characteristic **lambda, or twin-peak, sign** at the placental insertion.

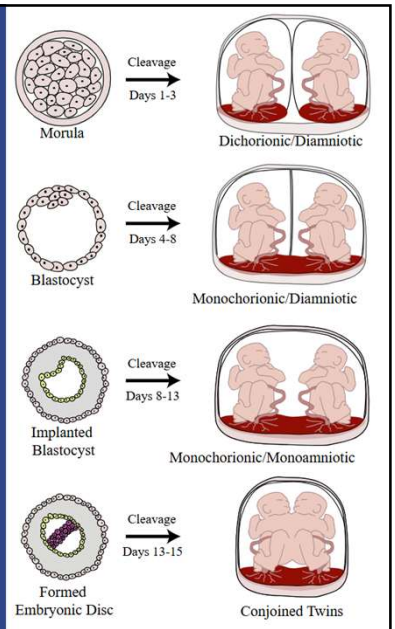

Placentation.svg: Kevin Dufendachderivative work: Addicted04, CC BY 3.0 <https://creativecommons.org/licenses/by/3.0>, via Wikimedia Commons

52

52

© Copyright. Society of Diagnostic Medical Sonography. All Rights Reserved.

Monochorionic Diamniotic Twins

- Monochorionic diamniotic (MCDA) twins share **one chorion and one placenta but occupy two separate amniotic sacs**.
- Their thin intertwin membrane consists primarily of the **two opposing amniotic layers** and meets the placental surface in the characteristic **T-sign**.
- Because the twins share placental vascular connections, MCDA pregnancies require **closer surveillance for complications such as TTTS, TAPS, and selective fetal growth restriction**.

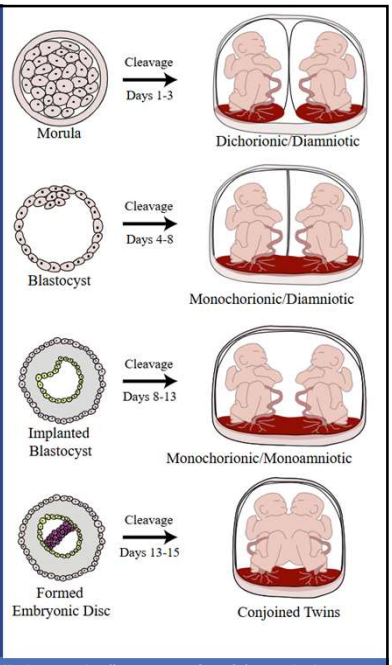

Placentation.svg: Kevin Dufendachderivative work: Addicted04, CC BY 3.0 <https://creativecommons.org/licenses/by/3.0>, via Wikimedia Commons

53

53

Monochorionic Monoamniotic Twins

- Monochorionic monoamniotic (MCMA) twins share **one chorion, one placenta, and one amniotic cavity**, with no normal intertwin membrane separating the fetuses.
- Sharing a single amniotic space allows the two umbilical cords to cross and intertwine, making **cord entanglement a characteristic finding and major pregnancy concern**.
- MCMA pregnancies carry substantially greater fetal risk and require **specialist surveillance and management in a center experienced with monochorionic pregnancy**.

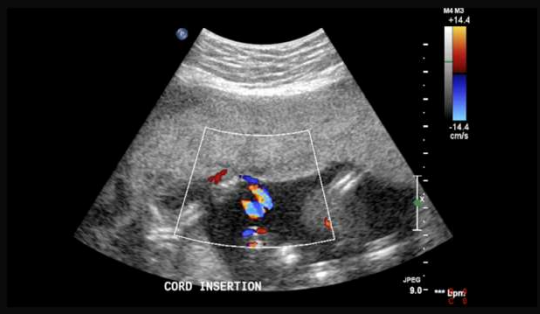

**Cord entanglement in a MCMA pregnancy.*

Case courtesy of Alexandra Stanislavsky, Radiopaedia.org, rID: 68977

54

54

© Copyright. Society of Diagnostic Medical Sonography. All Rights Reserved.

Higher-Order Multiples



*Trichorionic triplet pregnancy.

- In triplet and higher-order pregnancies, **chorionicity and amnionicity must be determined for each fetus and each fetal pairing**, rather than assigning one description to the pregnancy as a whole.
- Assessment should include the **number and relationship of placental masses, gestational and amniotic sacs, dividing membranes, and individual cord insertions**.
- Identifying any **monochorionic component** is particularly important because that shared placental circulation introduces risks beyond those associated with fetal number alone.

Case courtesy of Kalyan S Chilwant, Radiopaedia.org, rID: 63222

55

55

Fetal Documentation

- Each fetus should be assigned a **consistent label—Fetus A and Fetus B—and mapped by a reproducible anatomic relationship** that can be followed throughout pregnancy.
- Documentation should include **placental number and location, chorionicity and amnionicity, the intertwin membrane and its placental insertion, and the cord insertion for each fetus**.
- **Fetal sex, presentation, and other stable distinguishing features** should also be recorded when known to help maintain correct fetal identity on subsequent examinations.

56

56

© Copyright. Society of Diagnostic Medical Sonography. All Rights Reserved.

Shared Placenta Complications

- Shared placental vascular connections can produce **twin-to-twin transfusion syndrome (TTTS)** with characteristic amniotic fluid imbalance or **twin anemia–polycythemia sequence (TAPS)** with discordant fetal hemoglobin states.
- **Selective fetal growth restriction (sFGR)** may develop when placental territory and vascular supply are distributed unequally between the twins.
- In **twin reversed arterial perfusion (TRAP) sequence**, the structurally normal "pump" twin perfuses the abnormal co-twin through placental vascular connections, placing additional strain on the pump twin's cardiovascular system.



Case courtesy of James Harvey, Radiopaedia.org, rID: 88890

57

57

Cord Insertion

58

58

© Copyright. Society of Diagnostic Medical Sonography. All Rights Reserved.

Normal Cord Insertion

- A normal umbilical cord typically inserts **centrally or paracentrally into the placental disk**, away from the placental margin.
- The cord enters the placental surface directly, with the umbilical vessels remaining **supported by Wharton jelly until they reach the chorionic plate and branch across the fetal surface**.
- Gray-scale and color Doppler imaging can confirm the insertion site and demonstrate the **three-vessel cord entering the placenta without an intervening membranous course**.

59

59

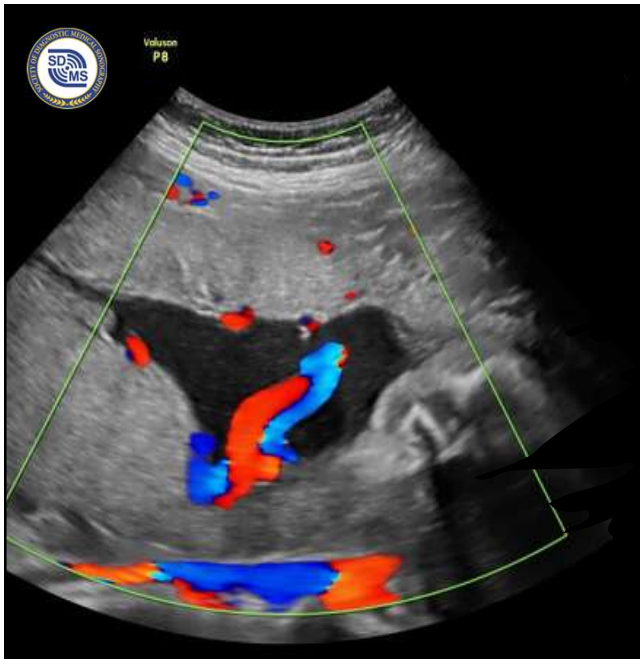

Marginal Cord Insertion (Battledore Placenta)

- With marginal insertion, the umbilical cord attaches **at or very near the placental margin rather than within the more central placental disk**.
- The vessels still enter the placenta as a cord and therefore retain **Wharton jelly protection up to the insertion site**, distinguishing marginal insertion from a velamentous insertion.
- Marginal insertion has been associated with **fetal growth abnormalities and other adverse pregnancy outcomes**, with added concern when the insertion lies near the lower uterine segment or internal cervical os.

60

Elfeky M, Marginal umbilical cord insertion. Case study, Radiopaedia.org (Accessed on 02 Sep 2026) https://doi.org/10.53347/rID-79021

60

© Copyright. Society of Diagnostic Medical Sonography. All Rights Reserved.

Velamentous Cord Insertion

- In velamentous cord insertion, the umbilical cord inserts into the **chorioamniotic membranes rather than directly into the placental disk**.
- The umbilical vessels then travel through the membranes before reaching the placenta, leaving them **without the mechanical protection of Wharton jelly** along this exposed segment.
- Velamentous insertion is associated with **fetal growth abnormalities, vessel compression or rupture, and vasa previa when exposed fetal vessels course over or near the internal cervical os**.

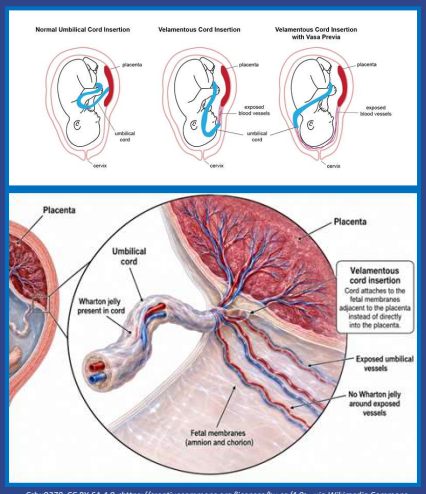

Cchu9279, CC BY-SA 4.0 <https://creativecommons.org/licenses/by-sa/4.0>, via Wikimedia Commons , OpenAI. (2026). Velamentous cord insertion anatomy [AI-generated image]. ChatGPT (GPT-5.6 Sol).

61

61

Vasa Previa

- Vasa previa occurs when **unprotected fetal vessels course through the membranes over or near the internal cervical os**, without the protection of placental tissue or Wharton jelly.
- **Transvaginal ultrasound with color and pulsed Doppler** is particularly valuable for confirming that the structure near the cervix represents a fetal vessel and defining its relationship to the os.
- Prenatal recognition is critical because rupture of these vessels during **membrane rupture or labor can result in rapid fetal hemorrhage, exsanguination, and death**.

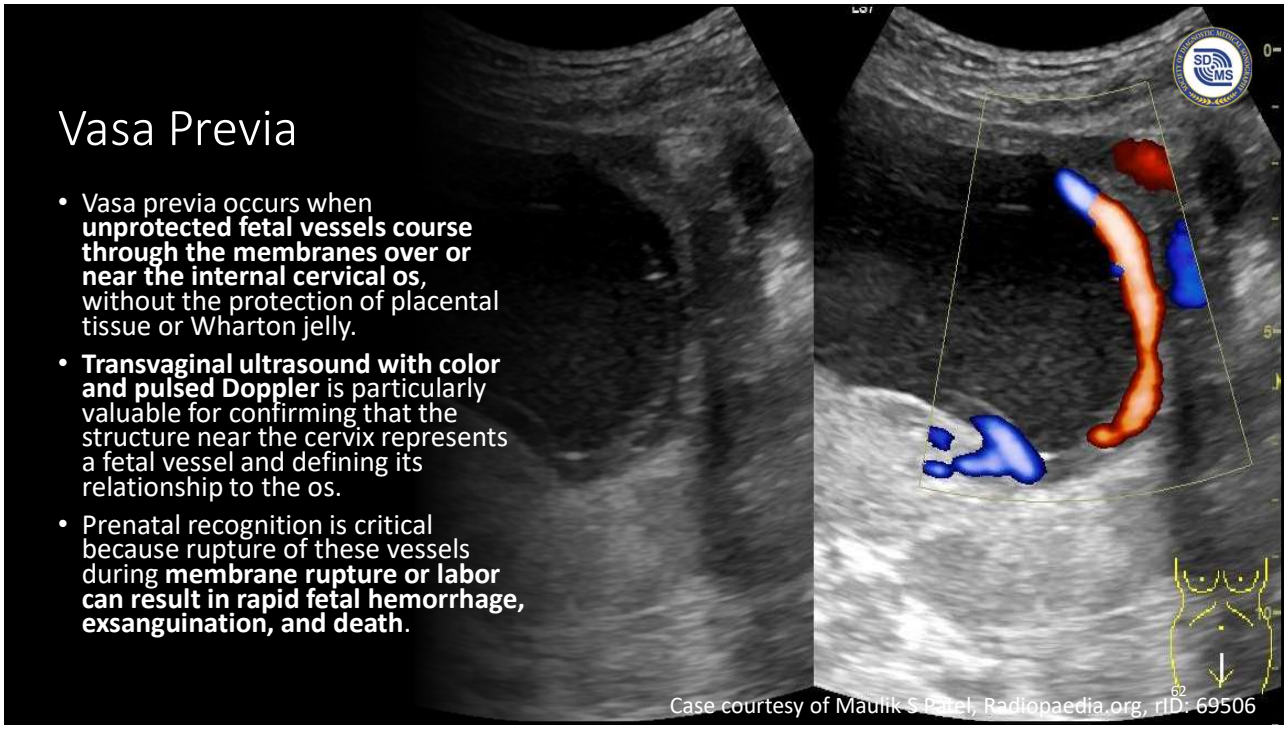

Case courtesy of Maulik S Patel, Radiopaedia.org, rID: 69506

62

62

© Copyright. Society of Diagnostic Medical Sonography. All Rights Reserved.



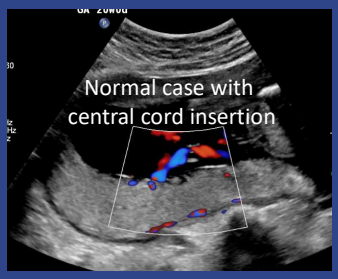

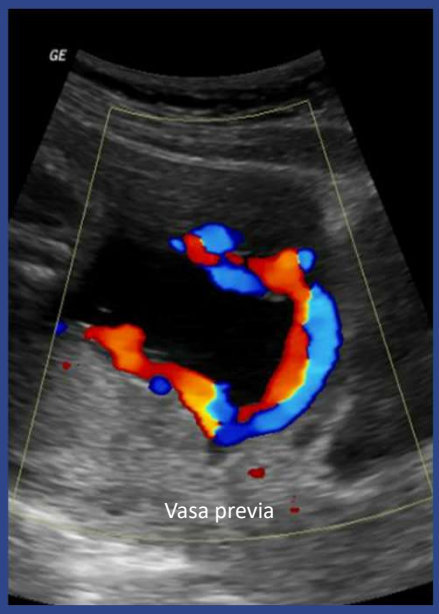



Image courtesy of the instructor (images on the left) and reprinted with permission from Patel M, Radiopaedia.org (rID: 21311), under the Creative Commons: Attribution-NonCommercial-ShareAlike 3.0 Unported lincense. creativecommons.org/licenses/by-sa/3.0 (middle and right images).

63

63

Types of Vasa Previa

- **Type I vasa previa** results from a velamentous cord insertion, with exposed fetal vessels traveling through the membranes before reaching the placenta and coursing over or near the cervix.
- **Type II vasa previa** occurs when fetal vessels connecting the main placenta to a **succenturiate lobe or second lobe of a bilobed placenta** traverse the region of the internal os.
- Both patterns leave fetal vessels **unsupported by Wharton jelly**, so identifying the cord insertion, placental morphology, connecting vessels, and their relationship to the cervix is central to recognition.

64

64

© Copyright. Society of Diagnostic Medical Sonography. All Rights Reserved.

Single Umbilical Artery

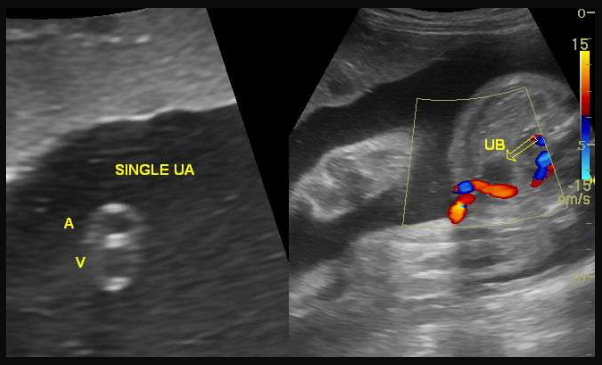

- A single umbilical artery (SUA) produces a **two-vessel cord containing one umbilical vein and one umbilical artery instead of the normal three vessels**.
- Once identified, the fetus should receive a **careful anatomic survey**, with particular attention to the cardiovascular, genitourinary, gastrointestinal, musculoskeletal, and central nervous systems.
- When SUA is truly isolated, current SMFM guidance recommends **third-trimester assessment of fetal growth** and consideration of antenatal surveillance beginning at 36 weeks rather than additional aneuploidy testing solely for the SUA.

Case courtesy of Maulik S Patel, Radiopaedia.org, rID: 13542

65

65

Cord Cysts, Knots, and Coiling

- **Umbilical cord cystic lesions** are often incidental and many first-trimester cysts resolve, but persistent, multiple, or large lesions warrant characterization and correlation with fetal anatomy.
- A suspected **true cord knot** should be evaluated with grayscale and Doppler imaging for vessel continuity and flow, recognizing that many knots remain undetected prenatally and not every knot compromises circulation.
- **Hypocoiling or hypercoiling** has been associated with adverse pregnancy outcomes in some studies, but antenatal coiling measurements have inconsistent predictive value and should not be interpreted as a diagnosis by themselves.



66

Tbsdy lives, CC BY-SA 3.0 <https://creativecommons.org/licenses/by-sa/3.0>, via Wikimedia Commons

66

© Copyright. Society of Diagnostic Medical Sonography. All Rights Reserved.

Abdominal Wall Defects & the Umbilical Cord

Omphalocele
- **Midline abdominal wall defect** at the umbilicus
- Herniated organs are **covered by a membrane**
- May contain **bowel ± liver**
- **Umbilical cord inserts into the apex of the defect/sac**
- Frequently associated with additional fetal and chromosomal abnormalities



Sonographic Distinction: Follow the cord insertion! Into the sac? Omphalocele. Separate from the defect? Gastroschisis

Gastroschisis
- Abdominal wall defect typically **right of the umbilical cord insertion**
- **Normal/intact umbilical cord insertion**
- Herniated bowel is **not membrane covered** and floats freely in the amniotic fluid
- Usually contains **bowel**, while the liver remains intra-abdominal



Case courtesy of Rania Adel Anan, Radiopaedia.org, rID: 80274 (Omphalocele)
Case courtesy of Simon Meagher, Radiopaedia.org, rID: 25751 (Gastroschisis)

67

67

Umbilical Artery Doppler: Technique

- Umbilical artery Doppler is conventionally obtained from a **free loop of cord**, because impedance varies between the fetal, free-loop, and placental portions of the umbilical artery.
- The vessel should be sampled with **good alignment to blood flow**, an appropriately low wall filter and velocity scale, and during an interval without fetal breathing or significant movement.
- Record several **uniform, reproducible waveforms** that clearly display systole, the baseline, and end-diastolic flow before calculating PI, RI, or S/D ratio.

68

68

© Copyright. Society of Diagnostic Medical Sonography. All Rights Reserved.

Normal UA Doppler

A normal umbilical artery waveform demonstrates **forward flow throughout systole and diastole**, reflecting the normally low-resistance placental circulation.

As gestation advances and the placental vascular bed expands, **end-diastolic flow increases while PI, RI, and S/D ratio generally decrease**.

Interpretation should always use **gestational-age-appropriate reference ranges and the correct sampling-site reference**, rather than relying on one universal numerical cutoff.

69

69

Abnormal UA Doppler

- **Elevated placental resistance** is suggested by decreased end-diastolic velocity and a UA PI, RI, or S/D ratio above the expected range for gestational age; SMFM considers flow ratios **above the 95th percentile** abnormal in FGR surveillance.
- **Absent end-diastolic flow (AEDF)** means forward flow reaches the baseline at end diastole, while **reversed end-diastolic flow (REDF)** crosses the baseline and travels in the opposite direction.
- Progressive loss of diastolic flow—**reduced → absent → reversed**—should raise increasing concern for significant placental vascular resistance and fetal compromise, particularly when accompanied by FGR or other signs of placental dysfunction.

70

70

© Copyright. Society of Diagnostic Medical Sonography. All Rights Reserved.

Abnormal UA Doppler Progression

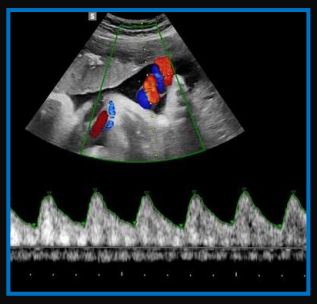

For Comparison: Normal UA Doppler Tracing
Case courtesy of A. Stanislavsky, Radiopaedia.org, rID: 62292



Absent Diastolic Flow, IUGR
Case courtesy of V. Anand, Radiopaedia.org, rID: 13867

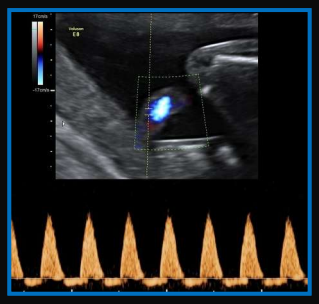

Reversed Diastolic Flow, Severe IUGR
239g at 21W, Expected 500g by this GA
Case courtesy of F. Ho, Radiopaedia.org, rID: 59231

71

71

Single Umbilical Artery

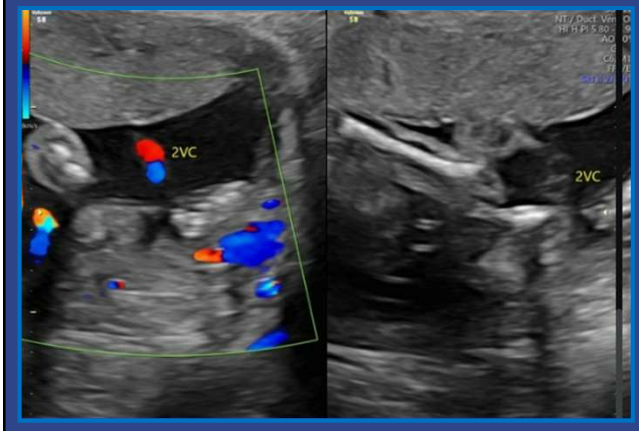

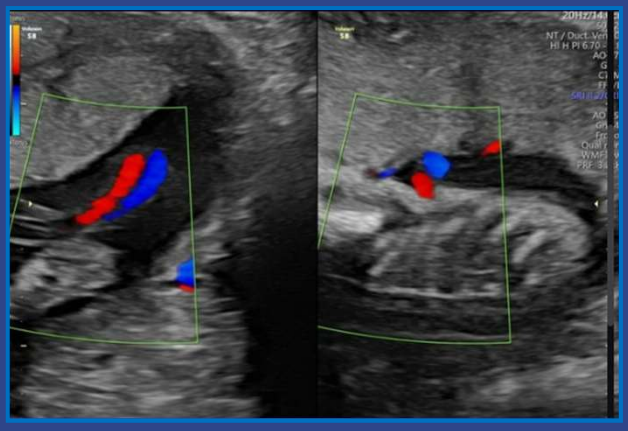

Reprinted with permission from Awal S, Radiopaedia.org (rID: 95453), under the Creative Commons: Attribution-NonCommercial-ShareAlike 3.0 Unported lincense. creativecommons.org/licenses/by-sa/3.0

72

72

© Copyright. Society of Diagnostic Medical Sonography. All Rights Reserved.

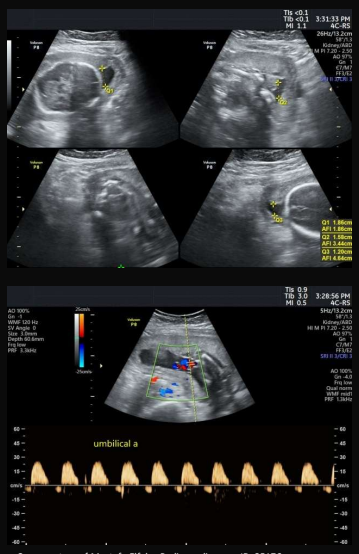

Case courtesy of Mostafa Elfeky, Radiopaedia.org, rID: 85176

IUGR/FGR and Placental Insufficiency

- **Fetal growth restriction (FGR)** is currently defined by SMFM as an estimated fetal weight or abdominal circumference **below the 10th percentile**, with EFW below the 3rd percentile considered severe FGR.
- Placental insufficiency may limit fetal oxygen and nutrient delivery, producing **poor growth, abnormal umbilical artery Doppler, and sometimes decreased amniotic fluid**.
- A small fetus is not automatically growth restricted; **growth trajectory, placental appearance, Doppler findings, fluid volume, fetal anatomy, and maternal clinical factors** help distinguish constitutional smallness from pathologic FGR.

73

73

Macrosomia/LGA and Placental Context

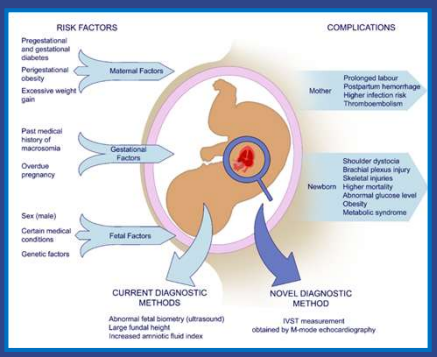

- **Large for gestational age (LGA)** generally describes an EFW above the 90th percentile, while **macrosomia refers to excessive absolute fetal weight regardless of gestational age**.
- Maternal diabetes may produce **accelerated fetal growth—often with a disproportionately large abdominal circumference—and may coexist with placental thickening and polyhydramnios**.
- When excessive fetal growth is suspected, the sonographic picture should include **EFW and growth trajectory, abdominal circumference, amniotic fluid volume, placental appearance, and relevant maternal history**, rather than fetal size alone.

Bartosz Szmyd,Małgorzata Biedrzycka,Filip Franciszek Karuga, Magdalena Rogut, Iwona Strzelecka, Maria Respondek-Liberska, CC BY 4.0 <https://creativecommons.org/licenses/by/4.0>, via Wikimedia Commons

74

74

© Copyright. Society of Diagnostic Medical Sonography. All Rights Reserved.

Game Time:
Lets finish with a round of Q&A!



https://www.vecteezy.com/free-vector

75

75

Q&A #1: Normal, Variant, or Red Flag?

- Color Doppler shows unprotected fetal vessels crossing near the internal cervical os.
- A. Normal
- B. Variant
- C. Red Flag

76

76

© Copyright. Society of Diagnostic Medical Sonography. All Rights Reserved.

Q&A #2: Normal, Variant, or Red Flag?

Umbilical artery Doppler demonstrates persistent forward flow during diastole, with indices appropriate for gestational age.

- A. Normal
- B. Variant
- C. Red Flag

77

77

Q&A #3: Normal, Variant, or Red Flag?

The umbilical cord inserts at the placental margin, but the vessels remain bundled within the cord and protected by Wharton jelly until reaching the placenta.

- A. Normal
- B. Variant
- C. Red Flag

78

78

© Copyright. Society of Diagnostic Medical Sonography. All Rights Reserved.

Q&A #4: Normal, Variant, or Red Flag?

Two nearly equal placental lobes are separated by membranes, with fetal vessels traveling between them.

- A. Normal
- B. Variant
- C. Red Flag

79

79

Q&A #5: Normal, Variant, or Red Flag?

A well-circumscribed placental mass near the fetal surface demonstrates prominent internal vascularity and a feeding vessel on color Doppler.

- A. Normal
- B. Variant
- C. Red Flag

80

80

© Copyright. Society of Diagnostic Medical Sonography. All Rights Reserved.

References

- American Pregnancy Association. (2019, October 16). Placental abruption: risks, causes, symptoms and treatment. Retrieved from https://americanpregnancy.org/pregnancy-complications/placental-abruption/
- Hagen-Ansert, S. L. (2023). *Textbook of diagnostic sonography* (9th ed., 2-vol. set). Elsevier.
- Holloway, S. (n.d.). *Ultrasound appearances of the abnormal placenta & umbilical cord* [Presentation slides]. British Medical Ultrasound Society.
- Hubinont, C., Lewi, L., Bernard, P., Marbaix, E., Debiève, F., & Jauniaux, E. (2015). Anomalies of the placenta and umbilical cord in twin gestations. *American Journal of Obstetrics & Gynecology, 213*(4 Suppl.), S91–S102. doi:10.1016/j.ajog.2015.06.054
- Jauniaux, E., Ebbing, C., Oyelese, Y., Maymon, R., Prefumo, F., & Bhide, A. (2024). European Association of Perinatal Medicine (EAPM) position statement: Screening, diagnosis and management of congenital anomalies of the umbilical cord. *European Journal of Obstetrics & Gynecology and Reproductive Biology, 298*, 61–65. doi:10.1016/j.ejogrb.2024.04.044
- Khoshnaw, K., & Weerakkody, Y. (n.d.). Circumvallate placenta. Retrieved from https://radiopaedia.org/articles/circumvallate-placenta?lang=us
- Laquerre, J. N. *Prenatal imaging of multiple gestations* [Directed reading]. American Society of Radiologic Technologists.
- Laquerre, J. N. *High-risk obstetrics* [ASRT Live presentation]. American Society of Radiologic Technologists.
- Laquerre, J. N. *Sonography of the second and third trimesters* [ASRT Live presentation]. American Society of Radiologic Technologists.
- Laquerre, J. N. *Obstetrical second trimester* [ASRT Live presentation]. American Society of Radiologic Technologists.
- Leal, P. V., Brock, M. F., Brandão, A. C., Cardia, P. P., de Souza, L. R. M. F., Novis, M. I., Bassols, F., Franco, L., Moshiri, M., & Ghezzi, C. L. A. (2026). Imaging of the placenta and umbilical cord: What radiologists in common practice need to know. *RadioGraphics, 46*(6), e250044. doi:10.1148/rg.250044
- Oyelese, Y., Perez, M., & Sepulveda, W. (2025). Ultrasound evaluation of the placenta, umbilical cord and membranes: Normal and abnormal findings. *The Global Library of Women's Medicine, 18*. doi:10.3843/GLOWM.419203
- PUSH Pregnancy. (2025, February 14). *Umbilical cord imaging* [Blog post].
- Rocha, J., Carvalho, J., Costa, F., Meireles, I., & Do Carmo, O. (2012). Velamentous cord insertion in a Singleton pregnancy: An obscure cause of emergency cesarean—A case report. Case Reports in Obstetrics and Gynecology, 2012, 1-4. https://doi.org/10.1155/2012/308206
- Schenone, C. V., Aghajani, F., Javinani, A., Krispin, E., Oyelese, Y., Papanna, R., Chmait, R. H., & Shamshirsaz, A. A. (2025). Vasa previa: Prenatal diagnosis and the rationale behind using a 5 cm distance from internal os. *Journal of Clinical Medicine, 14*(3), 1009. doi:10.3390/jcm14031009

Thank You!

Jenna N. Laquerre is the program director for the Diagnostic Medical Sonography and Bachelor of Science in Medical Imaging programs at Palm Beach State College, where she also serves as adjunct faculty for the Radiography program. She is registered in multiple sonography specialties, including abdomen, obstetrics and gynecology, pediatric sonography, breast, and vascular technology, and holds radiography certification. Jenna Laquerre is an active member of the Society of Diagnostic Medical Sonography, the American Society of Radiologic Technologists, and Lambda Nu National Honor Society. She contributes to the profession as a manuscript peer reviewer for Radiologic Technology and the Journal of Diagnostic Medical Sonography and is a published author and national speaker. Her clinical experience includes work at Nemours Children's Hospital and AdventHealth. She is also the author of *Lange Review: The Fundamentals of Pediatric Sonography: A Registry Review and Protocol Guide*.



© Copyright. Society of Diagnostic Medical Sonography. All Rights Reserved.