The Beats Beneath: Uncovering Secrets with Echo

Jessica "Jesse" Umbra, MHPTT, ACS, RDCS, RVT

Assistant Professor, University of Nebraska Medical Center

1

SPEAKER PRESENTATION DISCLAIMER

The content and views presented are made available for educational purposes only. The information presented are the opinions of the presenter and do not necessarily represent the views of the Society of Diagnostic Medical Sonography (SDMS) or its affiliated organizations, officers, Boards of Directors, or staff members.

The presenter is responsible for ensuring balance, independence, objectivity, scientific rigor, and avoiding commercial bias in their presentation. Before making the presentation, the presenter is required to disclose to the audience any relevant financial interests or relationships with manufacturers or providers of medical products, services, technologies, and programs.

The SDMS and its affiliated organizations, officers, Board of Directors, and staff members disclaim any and all liability for all claims that may arise out of the use of this educational activity.

2

© Copyright. Society of Diagnostic Medical Sonography. All Rights Reserved.

Disclosures

- No disclosures

3

Objectives

- Identify when there is a need to assess further from the standard imaging protocol
- Discuss unusual cardiac findings, pathology, and its appearance on ultrasound scans
- Show the importance of asking history questions to help determine next steps during an exam

4

© Copyright. Society of Diagnostic Medical Sonography. All Rights Reserved.

Case 1

5

- Background:
- Late 30s Male
- Works hard labor
- No prior medical history & no family history
- Murmur heart during routine physical
- Asymptomatic
- Echo ordered

6

© Copyright. Society of Diagnostic Medical Sonography. All Rights Reserved.

Parasternal Long Axis

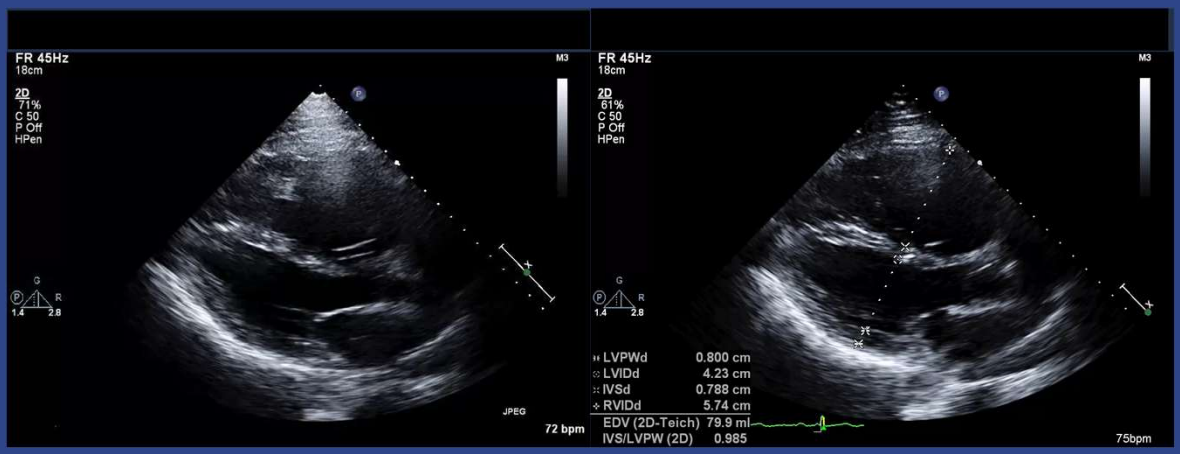

From personal files of Umbra, J.

7

Parasternal Short Axis



From personal files of Umbra, J.

8

© Copyright. Society of Diagnostic Medical Sonography. All Rights Reserved.

Apical 4 Chamber

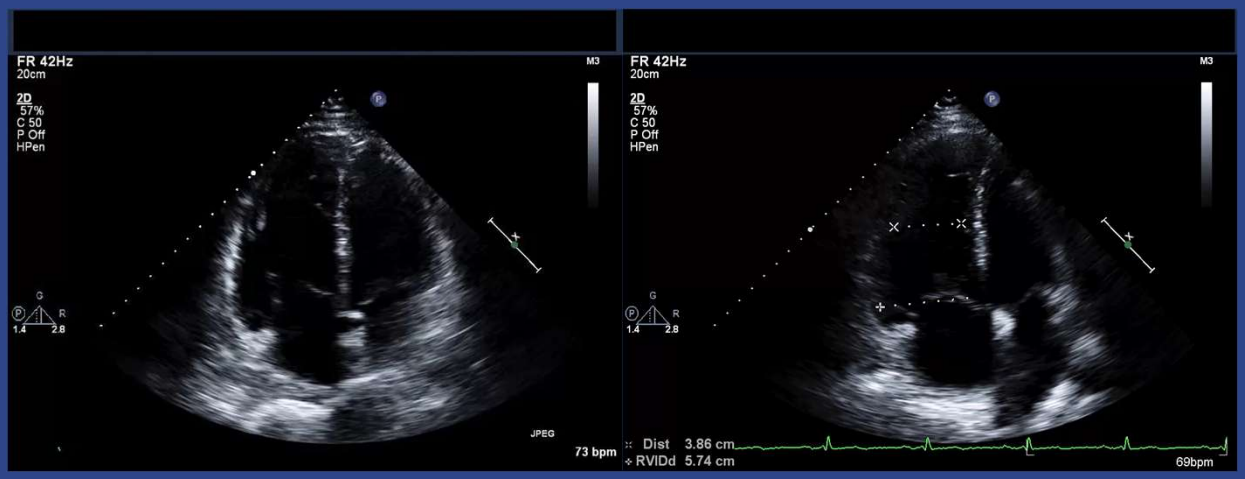

From personal files of Umbra, J.

9

Left Ventricle > Right Ventricle

Right Ventricle > Left Ventricle

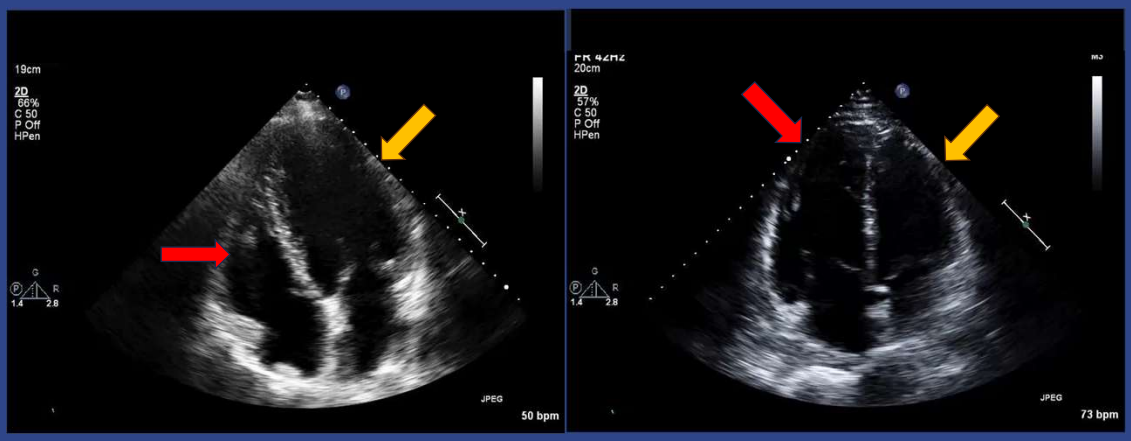

From personal files of Umbra, J.

10

© Copyright. Society of Diagnostic Medical Sonography. All Rights Reserved.

Color Doppler

Interventricular Septum

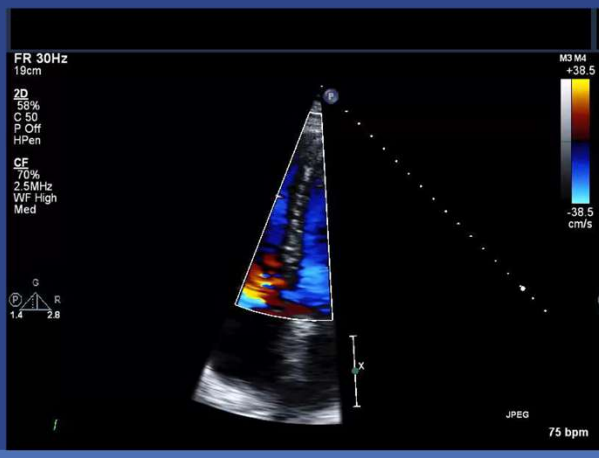

Interatrial Septum

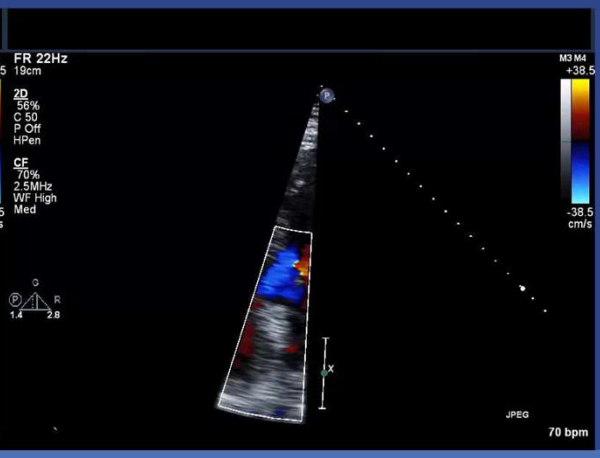

From personal files of Umbra, J.

11

BiCaval Subxiphoid

Normal Anatomy

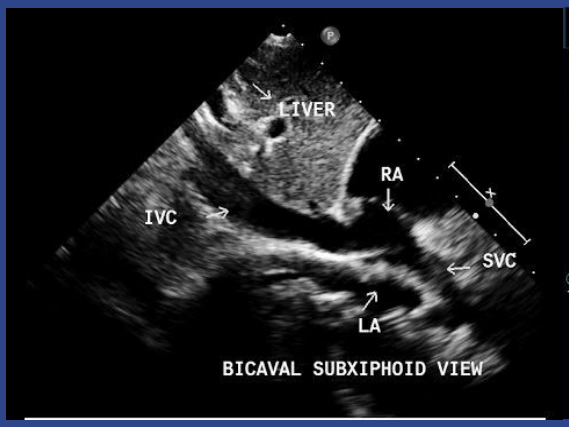

Still image from: Bicaval view by 2D ECHO Subxiphoid (youtube.com)

Abnormal Anatomy



From personal files of Umbra, J.

12

© Copyright. Society of Diagnostic Medical Sonography. All Rights Reserved.

Interatrial Septum

Sinus Venosus Atrial Septal Defect (ASD)



From personal files of Umbra, J.

13

3 Main Types of ASDs

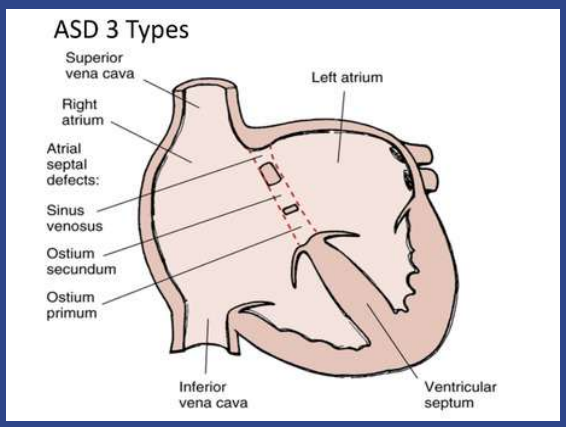

- Ostium Primum – 20% of cases
  - Occur closest to the AV valves
- Ostium Secundum – 75% of cases
  - Occur in the middle
- Sinus Venosus – 5% of cases
  - Occur at the top near the superior vena cava

14

© Copyright. Society of Diagnostic Medical Sonography. All Rights Reserved.

Bubble Study

9 cc of Saline
+
1 cc of Air
+
Manual Agitation
=
Microbubbles

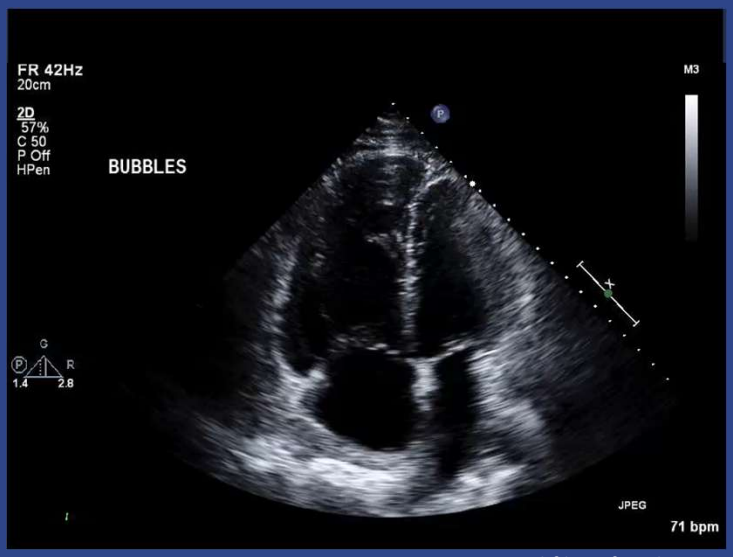

From personal files of Umbra, J.

15

Transesophageal Echocardiogram

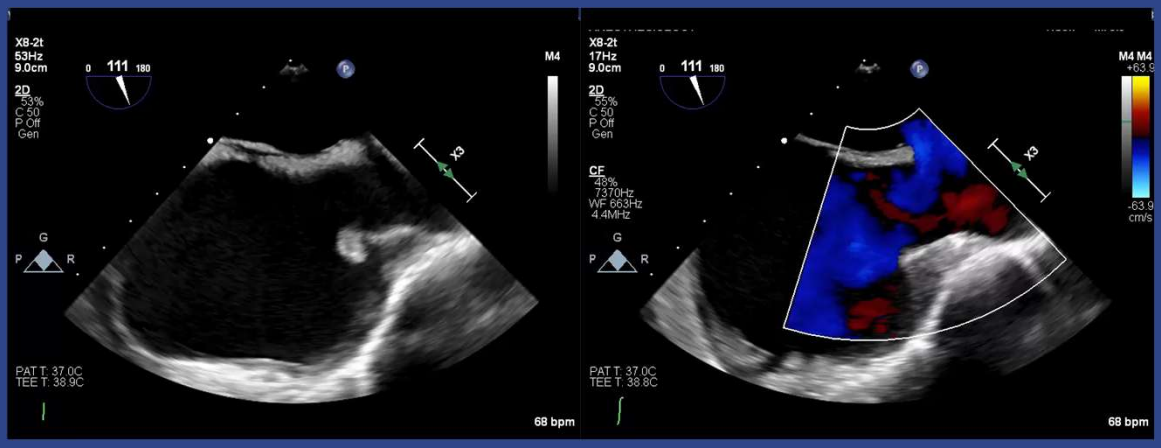

From personal files of Umbra, J.

16

© Copyright. Society of Diagnostic Medical Sonography. All Rights Reserved.

Transesophageal 3D Echocardiogram

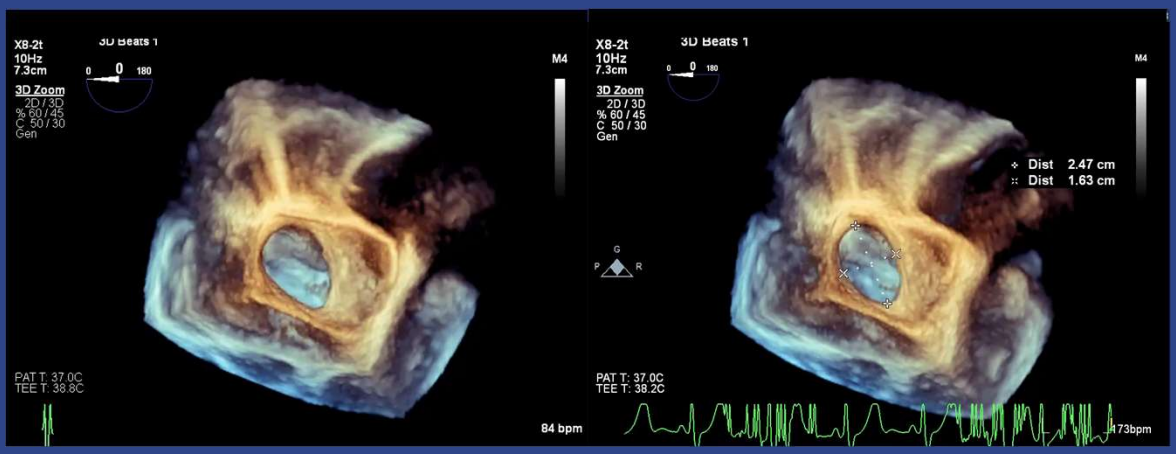

From personal files of Umbra, J.

17

Sinus Venosus Patch Repair



From personal files of Umbra, J.

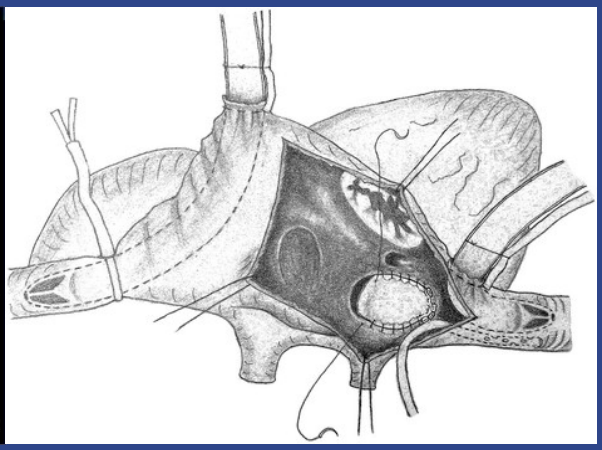

Surgical repair of inferior sinus venosus defects: a novel approach with unsnared inferior vena cava | Journal of Cardiothoracic Surgery | Full Text (biomedcentral.com)

18

© Copyright. Society of Diagnostic Medical Sonography. All Rights Reserved.

Apical 4 Chamber 1 Year Later

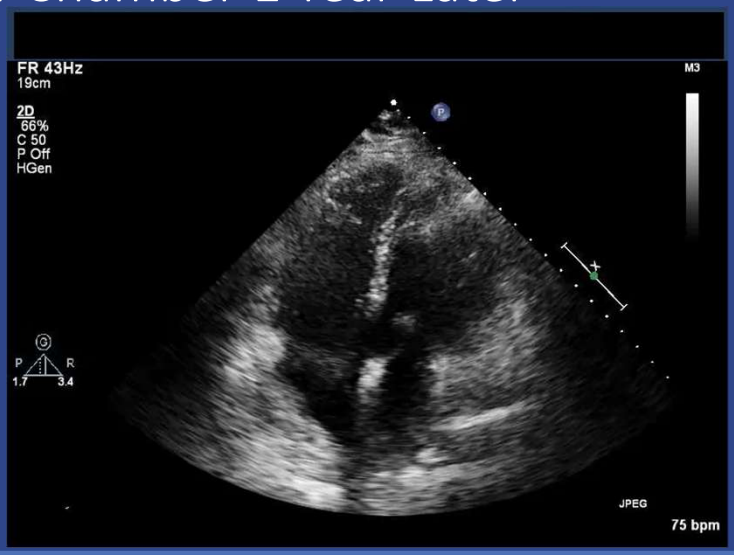

From personal files of Umbra, J.

19

Case 2

20

© Copyright. Society of Diagnostic Medical Sonography. All Rights Reserved.

- Background:
- Mid 50s Female
- Indication: Low Blood Pressure Post-Watchman Procedure
- History: Atrial Fibrillation
- Symptoms: Hypotension & Shortness of Breath
- Prior Studies: Prior transthoracic echo normal with 50-55% EF
- Transthoracic echo ordered

21

Pericardial Effusion

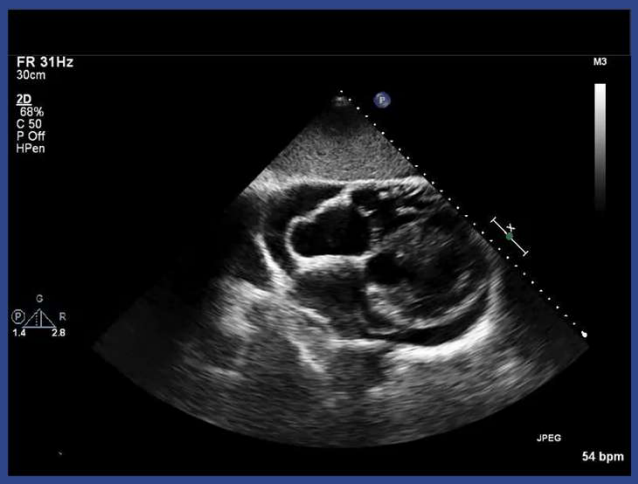

From personal files of Umbra, J.

- Accumulation of fluid in the pericardial sac
- Causes:
  - Trauma
  - Malignancy
  - Inflammation
  - Iatrogenic
  - Infection
  - Idiopathic

22

© Copyright. Society of Diagnostic Medical Sonography. All Rights Reserved.

Pericardial Anatomy

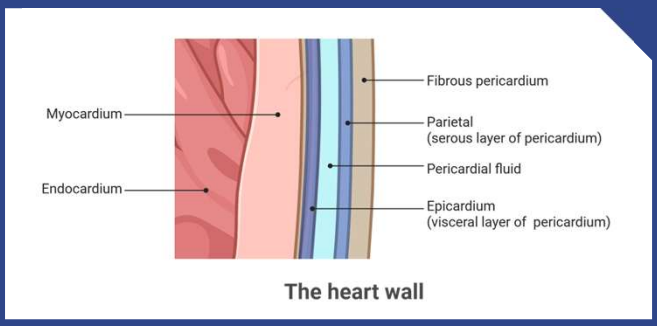

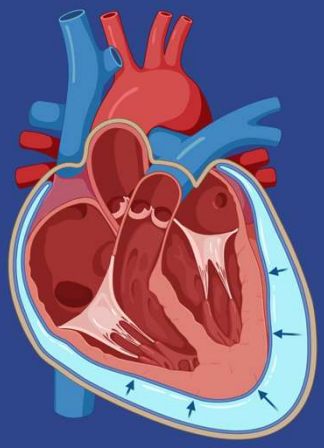

23

Tamponade

- **True Medical Emergency!**
- Prevents the heart from filling
- Amount of fluid matters less than the accumulation speed
  - Small amount quickly



24

© Copyright. Society of Diagnostic Medical Sonography. All Rights Reserved.

Diagnosis

- Tamponade is a Clinical Diagnosis that can be supported by ultrasound findings
- Primary Findings:
  - Hypotension
  - Pericardial Effusion
  - Inferior Vena Cava Plethora

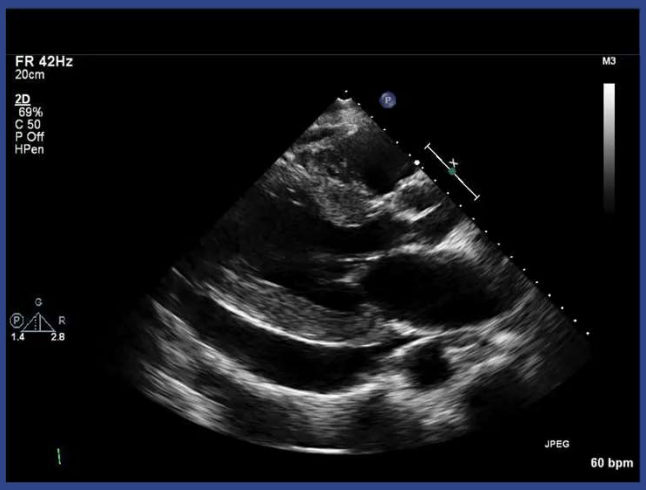

From personal files of Umbra, J.

25

Pericardial Effusion

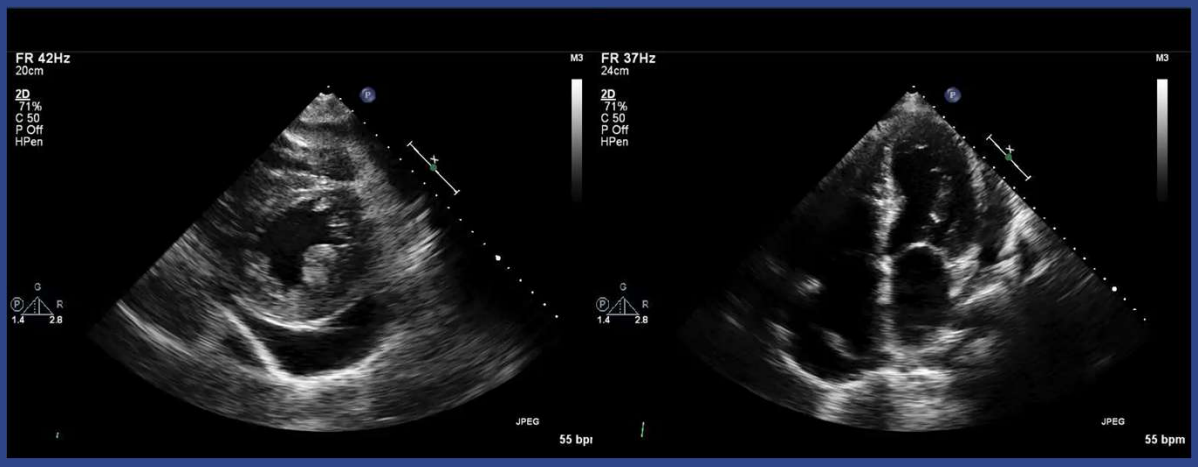

From personal files of Umbra, J.

26

© Copyright. Society of Diagnostic Medical Sonography. All Rights Reserved.

IVC Plethora

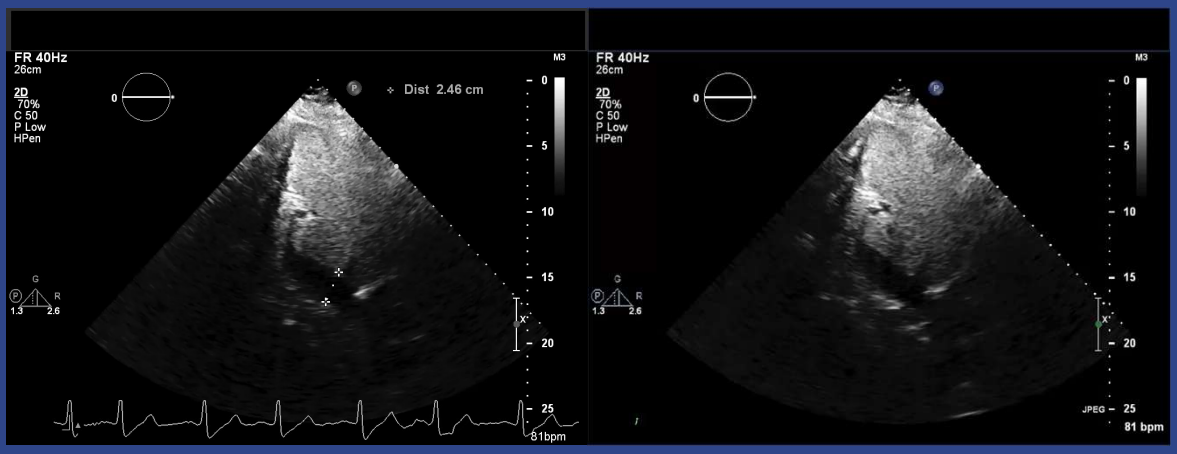

From personal files of Umbra, J.

27

Diagnosis

- Secondary Findings:
  - Respiratory Inflow Velocity Variation >30%
  - Chamber Collapse
  - Interventricular Dependence

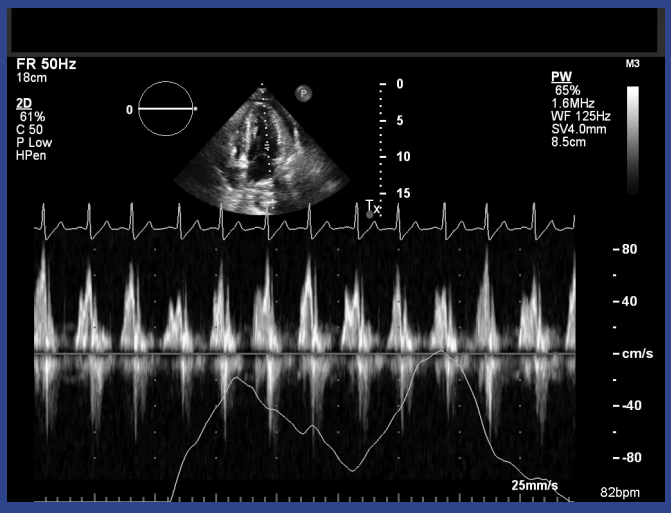

From personal files of Umbra, J.

28

© Copyright. Society of Diagnostic Medical Sonography. All Rights Reserved.

Chamber Collapse

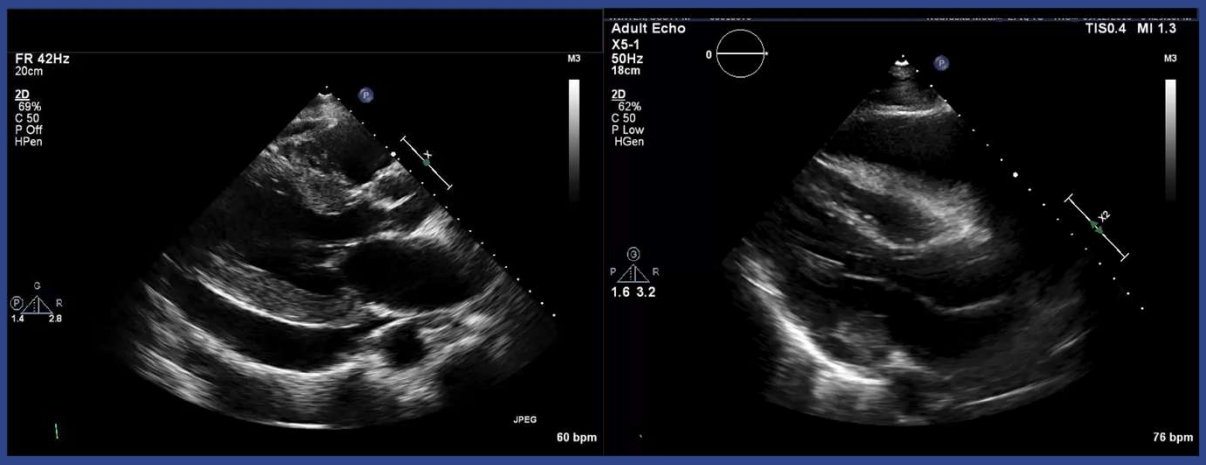

No Tamponade

Tamponade

From personal files of Umbra, J.

29

Chamber Collapse

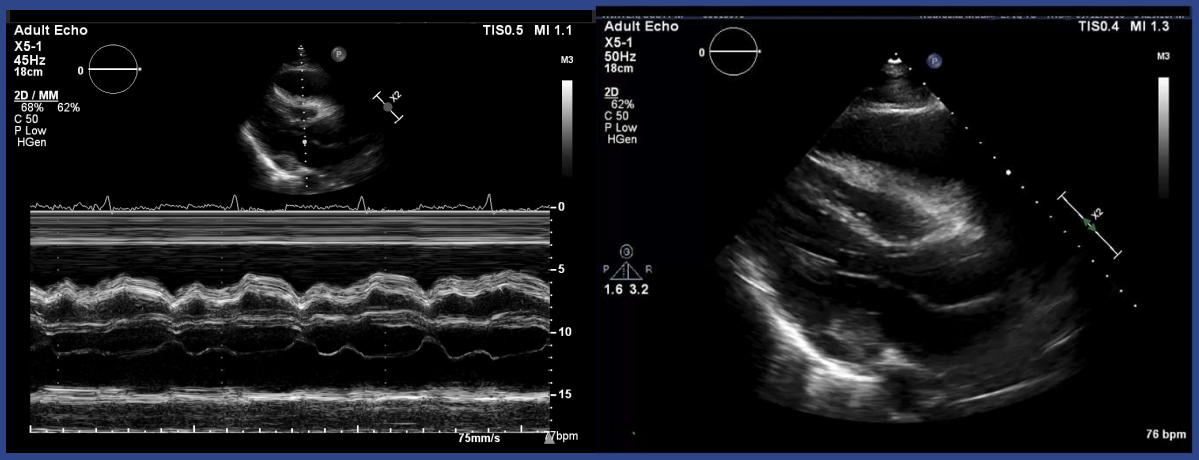

From personal files of Umbra, J.

30

© Copyright. Society of Diagnostic Medical Sonography. All Rights Reserved.

Interventricular Dependence

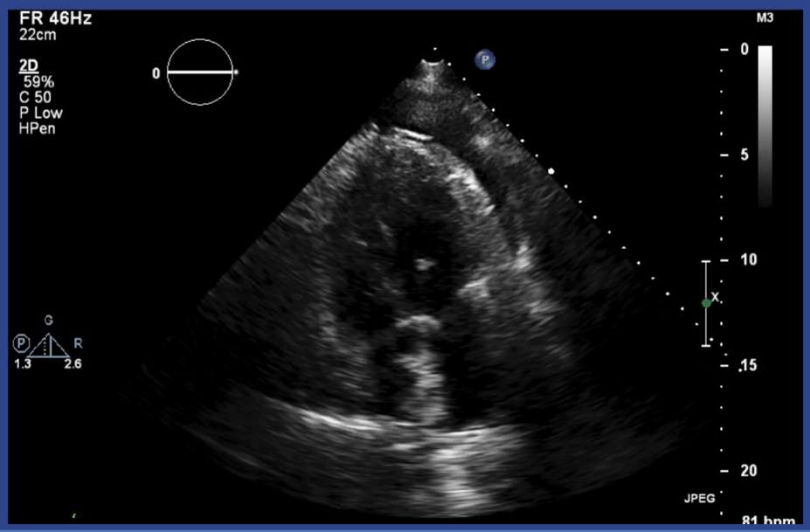

From personal files of Umbra, J.

31

Post Pericardiocentesis

- Patient tolerated the procedure well
- Immediate relief of symptoms
- Discharged 4 days later with no reaccumulation of fluid

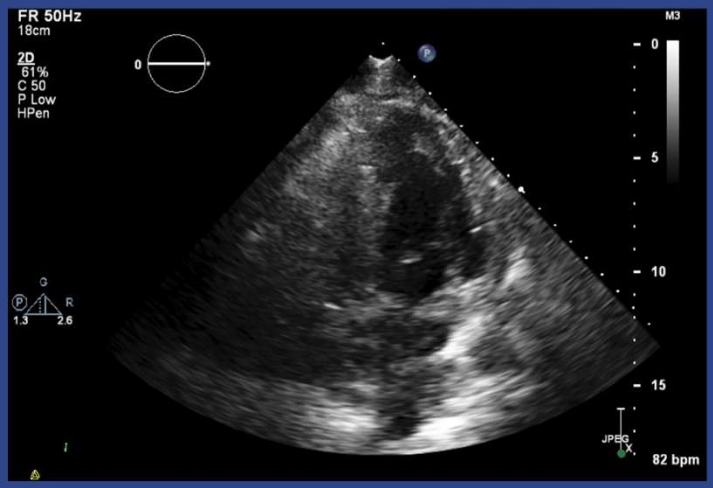

From personal files of Umbra, J.

32

© Copyright. Society of Diagnostic Medical Sonography. All Rights Reserved.

Case 3

33

- Background:
- Late 90s Female
- Indication: Increasing Shortness of Breath
- History: Arrythmia with Biventricular Pacemaker
  - Pacemaker placed 6 years prior with a repositioning 12 days after placement
- Prior Studies: Echo from 5 years prior showed mild tricuspid regurgitation, normal cardiac function
- Transthoracic echo ordered

34

© Copyright. Society of Diagnostic Medical Sonography. All Rights Reserved.

Parasternal Views

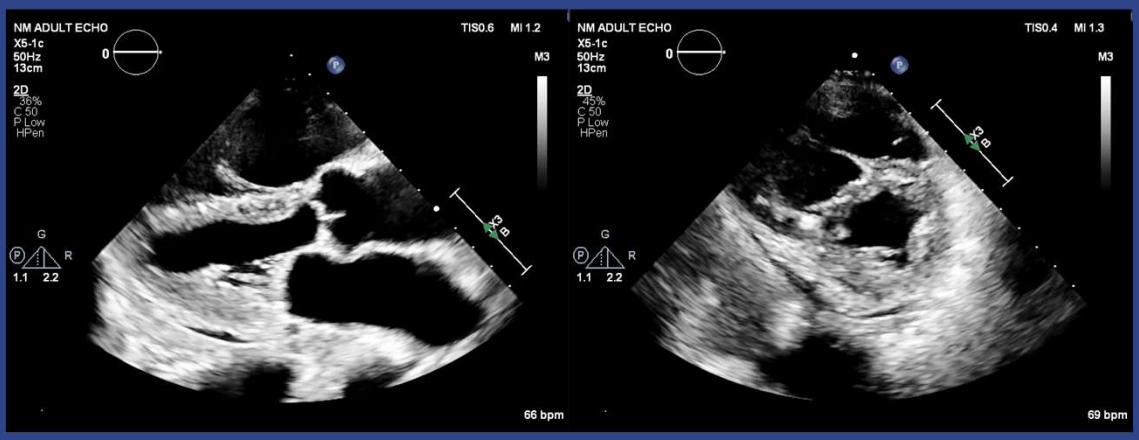

From personal files of Umbra, J.

35

Tricuspid Valve

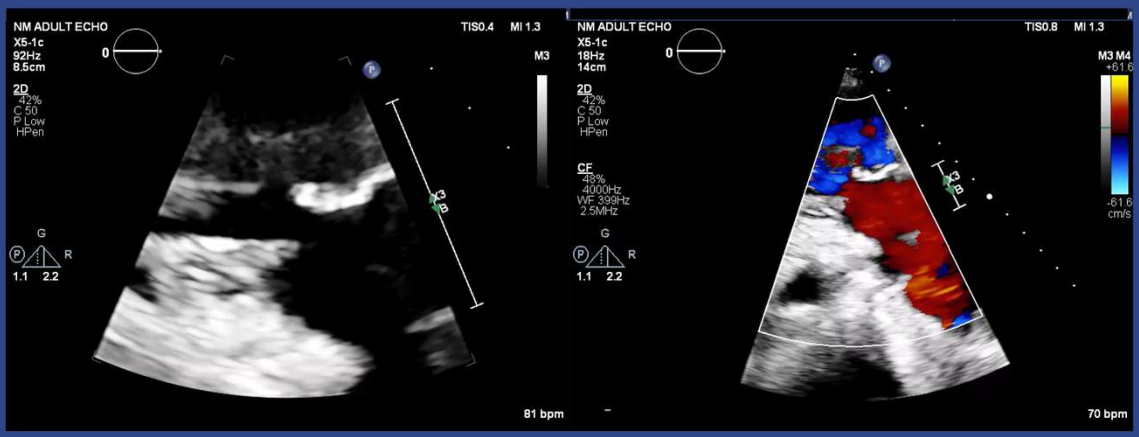

From personal files of Umbra, J.

36

© Copyright. Society of Diagnostic Medical Sonography. All Rights Reserved.

Right Ventricular Function

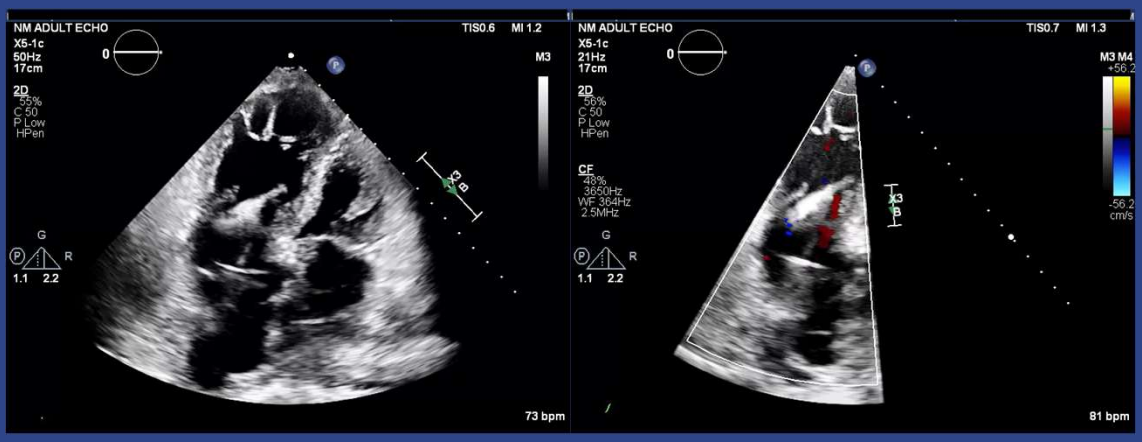

From personal files of Umbra, J.

37

IVC Status

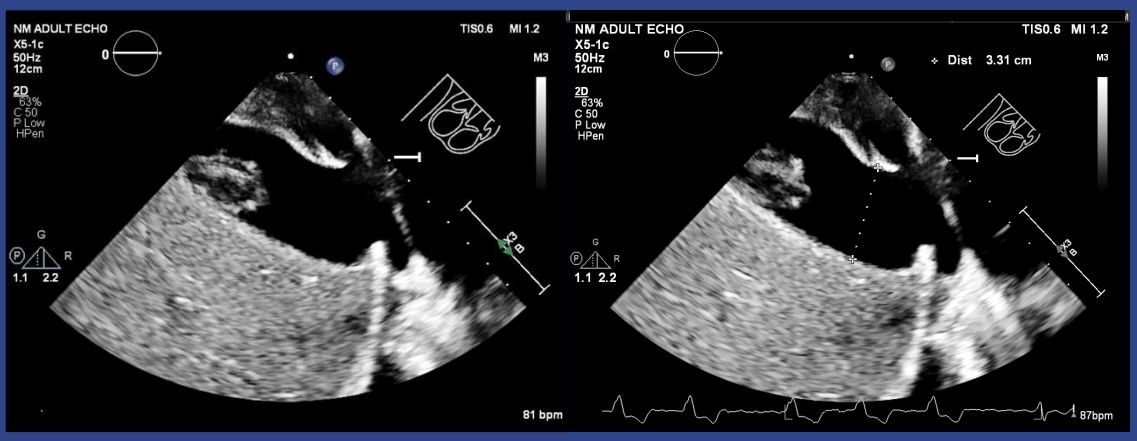

From personal files of Umbra, J.

38

© Copyright. Society of Diagnostic Medical Sonography. All Rights Reserved.

IVC and Hepatic Vein Flow

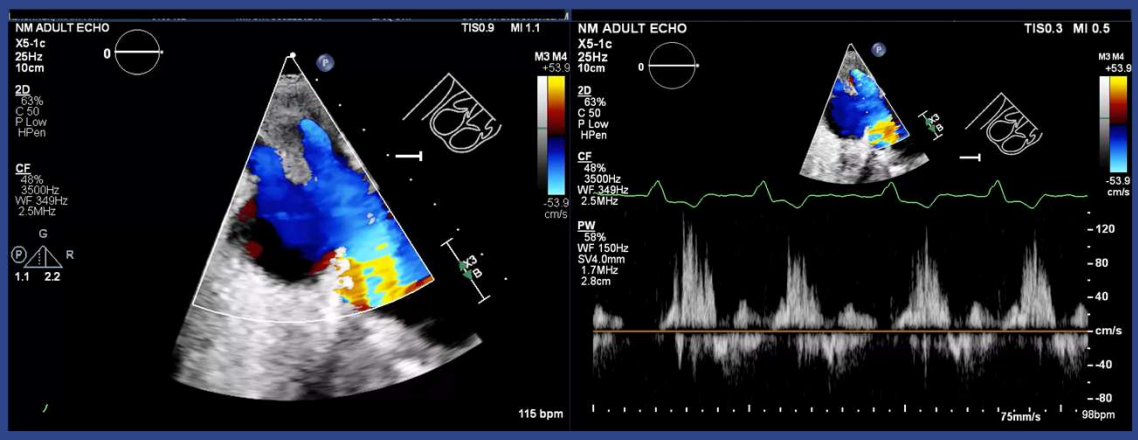

From personal files of Umbra, J.

39

Image Enhancing Agent

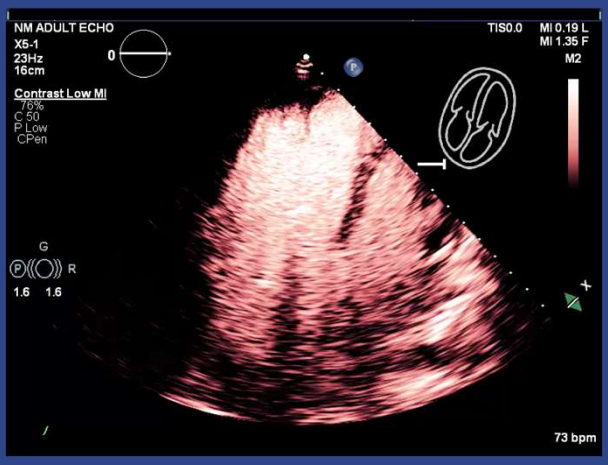

- Severe right atrial enlargement
- Right ventricle enlargement with reduced function
- Dilated IVC with hepatic venous flow reversal
- Torrential tricuspid regurgitation

From personal files of Umbra, J.

40

© Copyright. Society of Diagnostic Medical Sonography. All Rights Reserved.

Transesophageal Echo

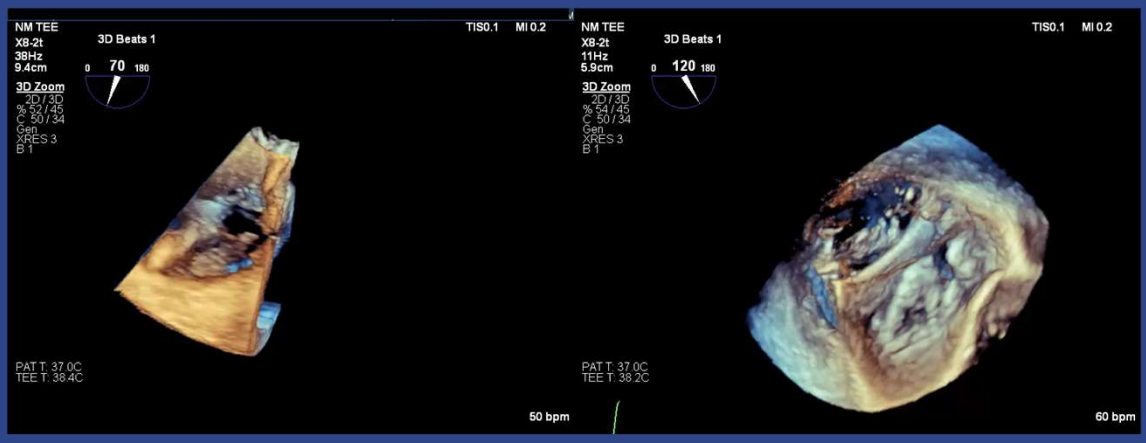

From personal files of Umbra, J.

41

Right Heart Function

- Right heart failure increases CVP due to poor function
- This decreases the blood that can return into the right side
- Eventually increases pressures at the capillaries
- Increases peripheral resistance
- Which increases the afterload



From personal files of Umbra, J.

42

© Copyright. Society of Diagnostic Medical Sonography. All Rights Reserved.

Venous Congestion



From personal files of Umbra, J.

- Venous Insufficiency
- Hypervolemia
- Backup of blood could be due to heart function
- Congestive Heart Failure = high right heart pressures
  - Visualize this as pulsatility in the venous waveform

43

Case 4

44

© Copyright. Society of Diagnostic Medical Sonography. All Rights Reserved.

- Background:
- Prior history of bioprosthetic aortic valve
- Symptoms: ripping chest pain radiating to back
- Echo ordered

45

Parasternal Long Axis

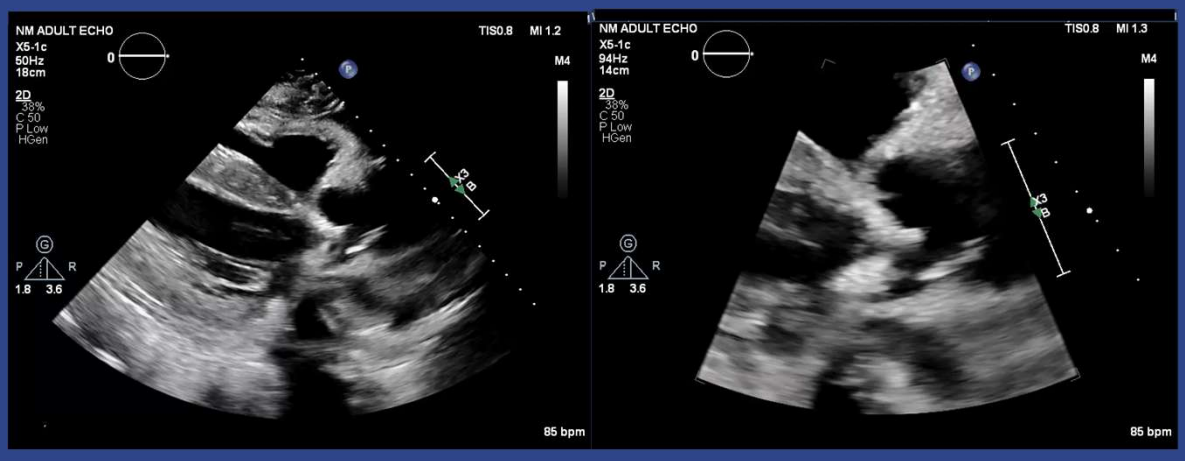

From personal files of Umbra, J.

46

© Copyright. Society of Diagnostic Medical Sonography. All Rights Reserved.

Ascending Aorta

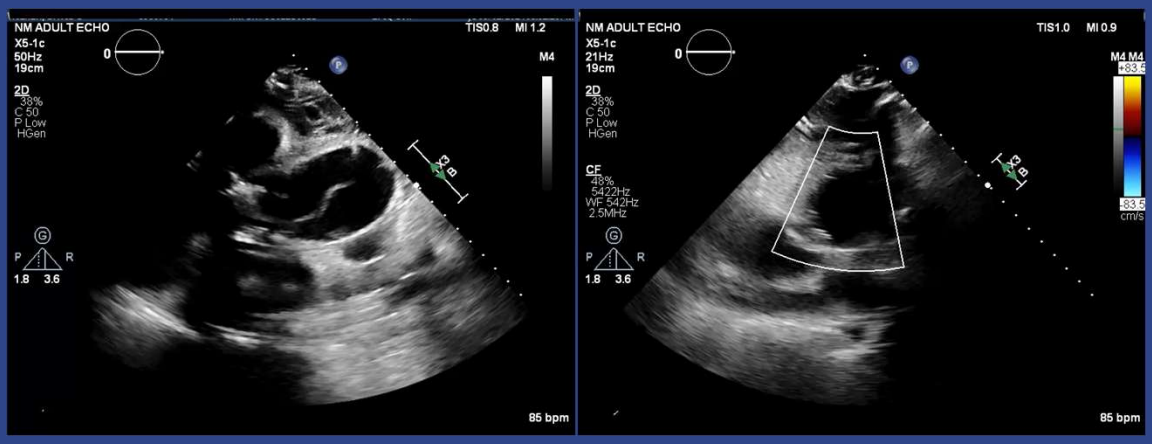

From personal files of Umbra, J.

47

Parasternal Short Axis



From personal files of Umbra, J.

48

© Copyright. Society of Diagnostic Medical Sonography. All Rights Reserved.

Apical 2C & Subcostal 4C



From personal files of Umbra, J.

49

Abdominal Aorta

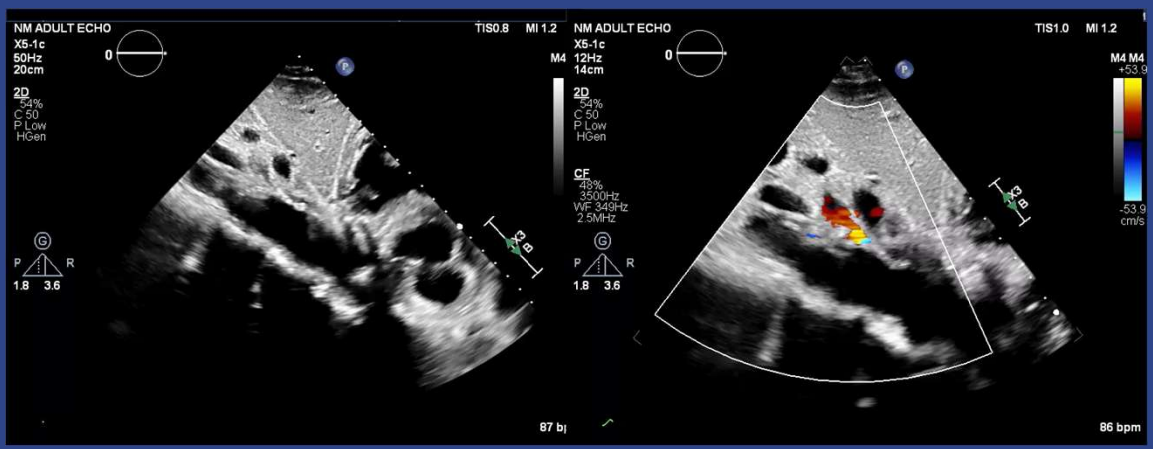

From personal files of Umbra, J.

50

© Copyright. Society of Diagnostic Medical Sonography. All Rights Reserved.

Abdominal Aorta



From personal files of Umbra, J.

51

TTE report

- Mild aortic root dilatation. Root measures 4.3 cm at the sinuses of Valsalva. Severely dilated ascending aorta measuring 5.1 cm in maximal dimension.
- There is evidence of Stanford Type A aortic dissection which seems to extend from the right coronary cusp to below the mesenteric vessels. Subcostal Doppler images are suggestive of significant ostial SMA and celiac axis narrowing vs. stenosis.

52

© Copyright. Society of Diagnostic Medical Sonography. All Rights Reserved.

Transesophageal Echo

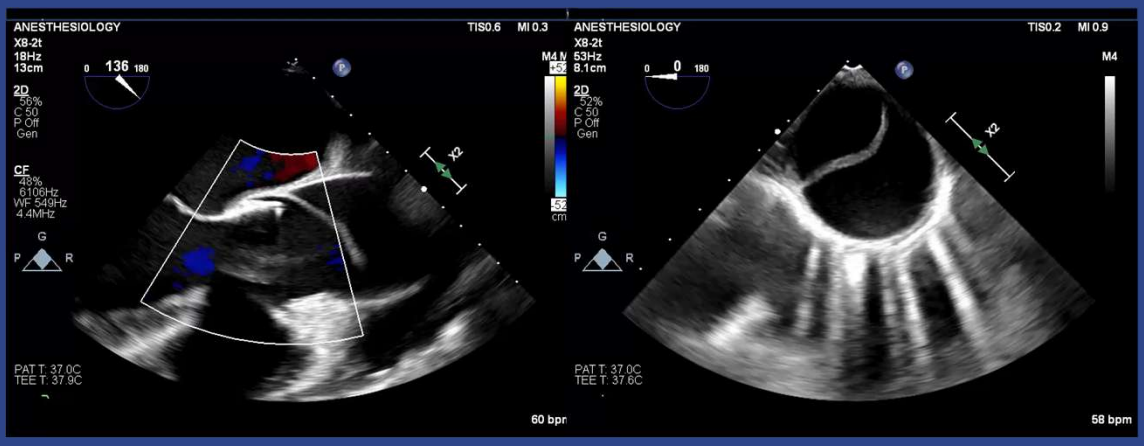

From personal files of Umbra, J.

53

Case 5

54

© Copyright. Society of Diagnostic Medical Sonography. All Rights Reserved.

- Background:
- Early 70s Female
- History: Septic vs hypovolemic shock, acute pancreatitis, choledocholithiasis with multiple comorbidities
- Elevated troponin, hypotension, fever, ekg changes
- No prior echo
- Stat TTE ordered

55

Parasternal Long & Short Axis

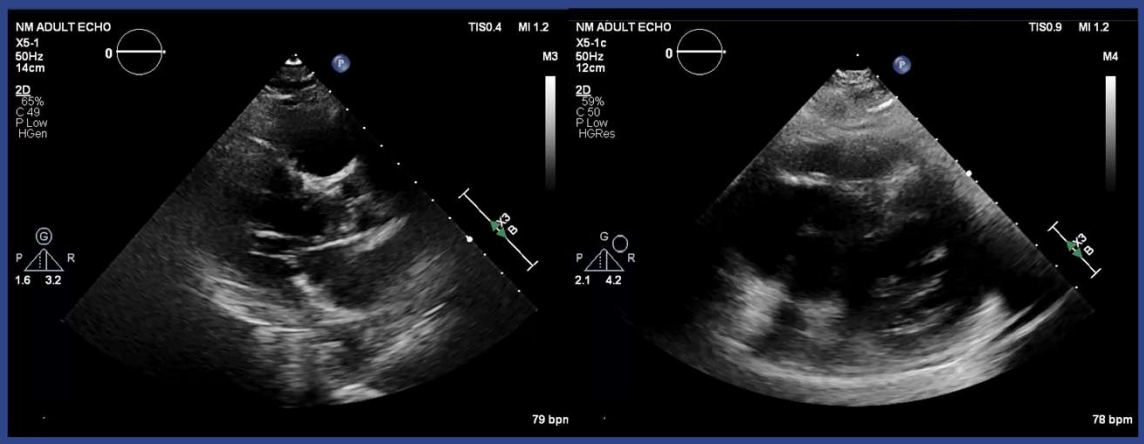

From personal files of Umbra, J.

56

© Copyright. Society of Diagnostic Medical Sonography. All Rights Reserved.

Parasternal Short Axis

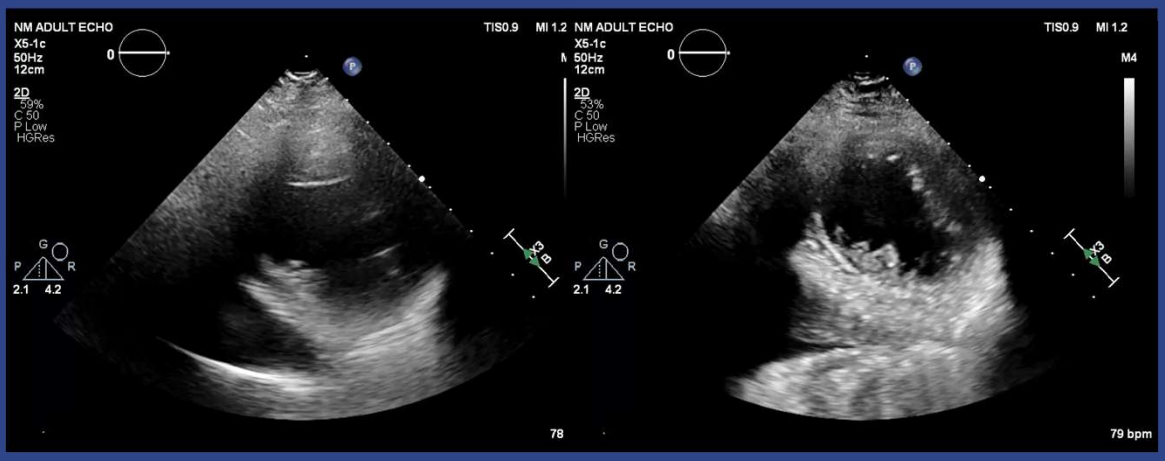

From personal files of Umbra, J.

57

Apical 4 Chamber

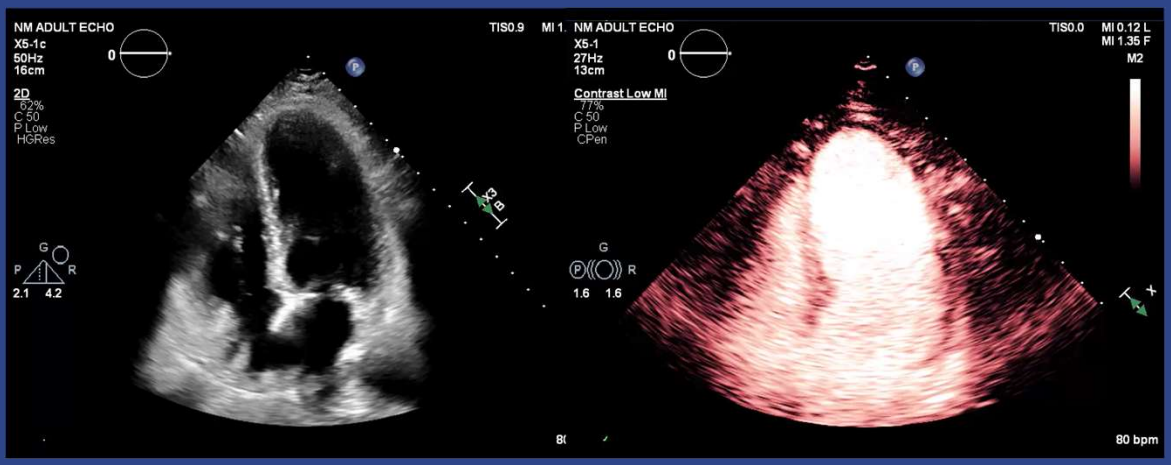

From personal files of Umbra, J.

58

© Copyright. Society of Diagnostic Medical Sonography. All Rights Reserved.

Apical 2 Chamber

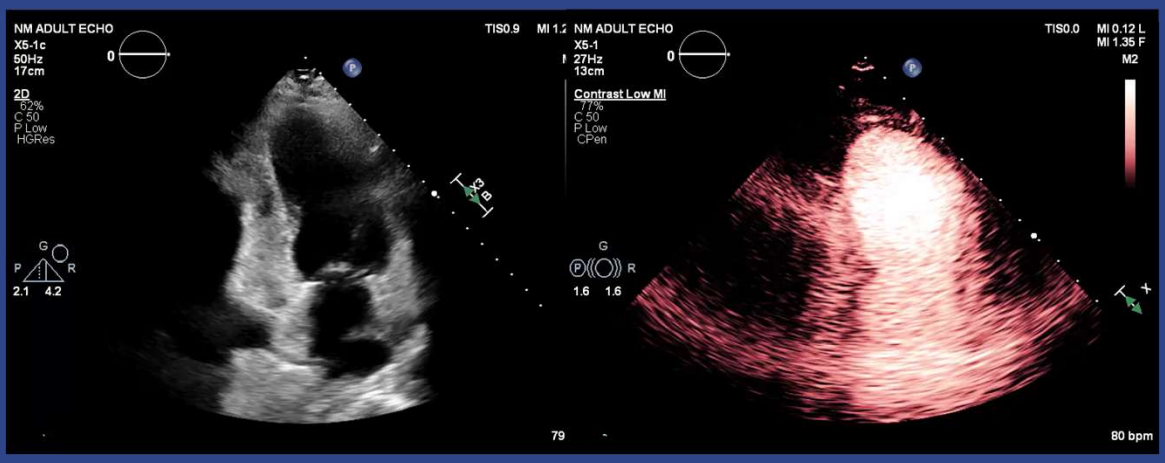

From personal files of Umbra, J.

59

Apical 3 Chamber

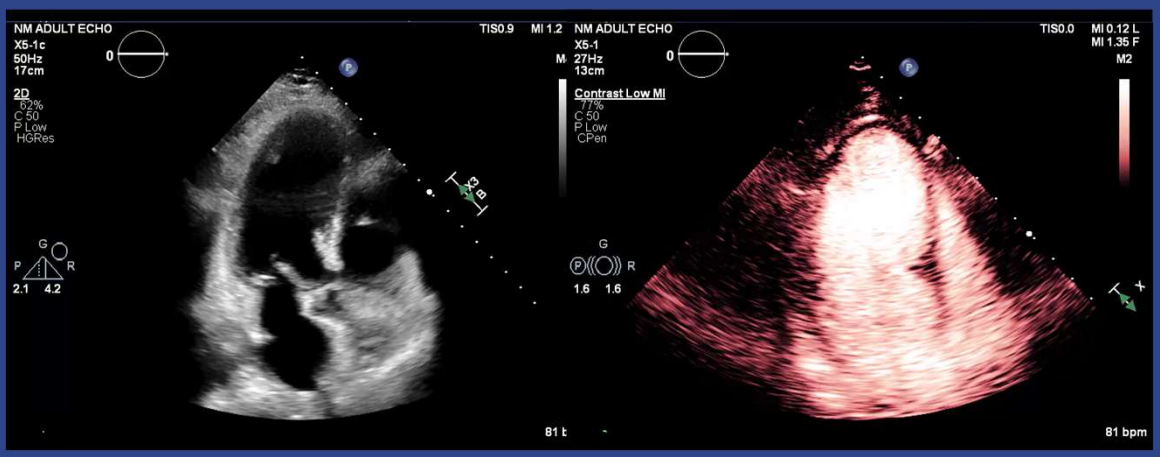

From personal files of Umbra, J.

60

© Copyright. Society of Diagnostic Medical Sonography. All Rights Reserved.

TTE Report

- Concentric left ventricular remodeling with mildly reduced systolic function, LVEF 40-45%
- The basal segments are hyperdynamic with akinesis of the remaining mid, apical, and true apex segments
- Findings are more likely to be due to Takotsubo cardiomyopathy but LAD territory infarct can not be ruled out definitively.
- Slow flow in the apex with no discrete thrombus but high risk from thrombus formation
- Moderate tricuspid regurgitation & PASP 47 mmHg

61

Takotsubo Cardiomyopathy

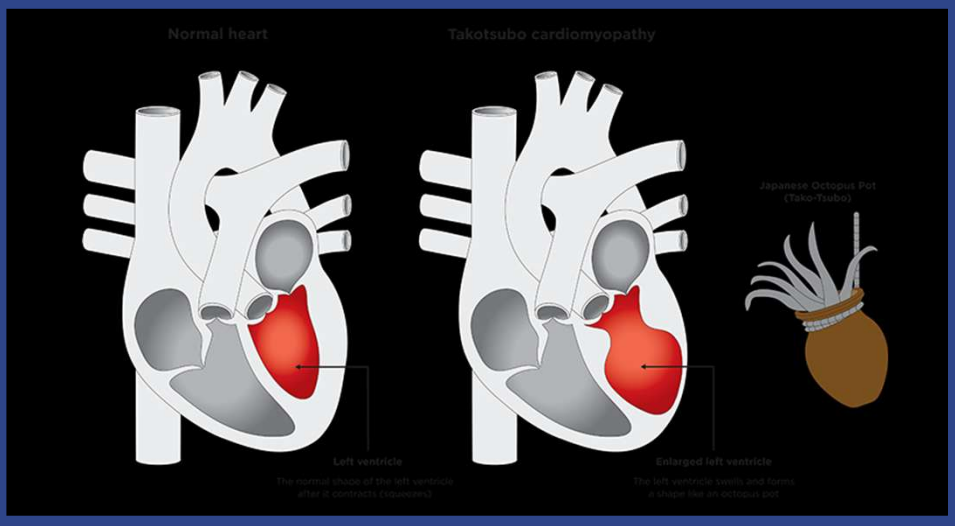

Takotsubo Cardiomyopathy | Heart Conditions - Heart Foundation NZ

62

© Copyright. Society of Diagnostic Medical Sonography. All Rights Reserved.

Cardiogenic Shock

- The heart is no longer functioning normally and Cardiac Output is decreased
- Common causes:
  - Iatrogenic
  - Myocardial Infarction
    - Accounts for up to 75% of all cardiogenic shock cases
  - Acute Myocarditis
  - End-stage cardiomyopathies
  - Complications from cardiopulmonary bypass

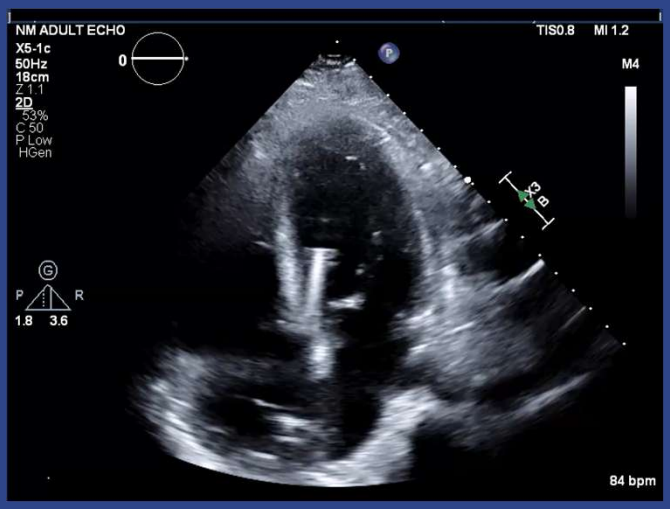

From personal files of Umbra, J.

63

Cardiogenic Shock

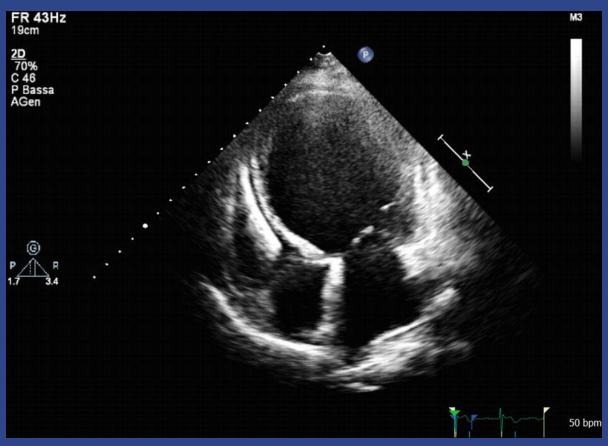

From personal files of Umbra, J.

- Impacts:
  - Hypotension
  - Systemic Vasoconstriction
    - Initially helps!
    - Leads to end-organ failure eventually & makes the heart work harder
  - Cardiac Ischemia

64

© Copyright. Society of Diagnostic Medical Sonography. All Rights Reserved.

Takotsubo Cath

- Left Heart Cath
- 70% focal stenosis mid LAD
- RCA: No obstructive CAD
- LCX: No obstructive CAD

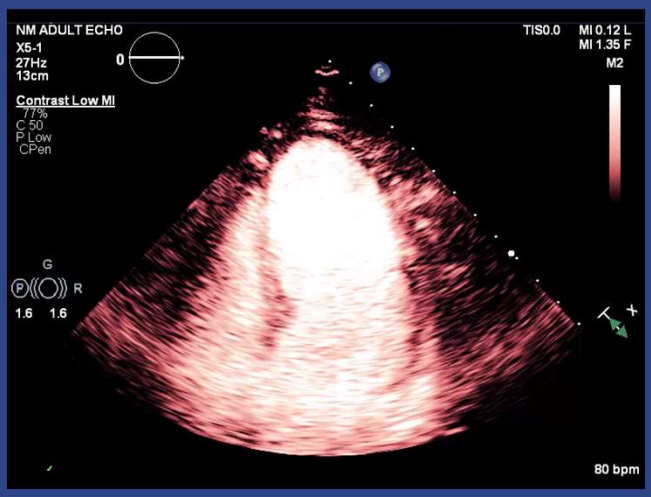

From personal files of Umbra, J.

65

Follow-up TTE

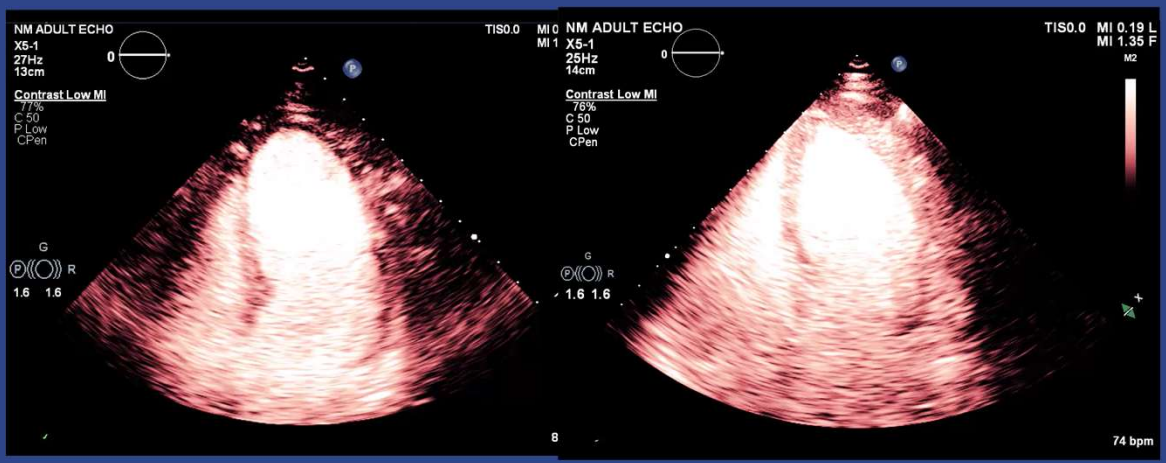

Original Echo

4 Days Later

From personal files of Umbra, J.

66

© Copyright. Society of Diagnostic Medical Sonography. All Rights Reserved.

Case 6

67

- Background:
- Mid 30s Female
- History: Elevated troponin,
- Symptoms: Several days N/V, hematemesis, hypotensive, hypoxia, tachycardic (140s), severe chest pain, positive for rhinovirus
- No prior
- Stat TTE ordered

68

© Copyright. Society of Diagnostic Medical Sonography. All Rights Reserved.

Parasternal Long Axis

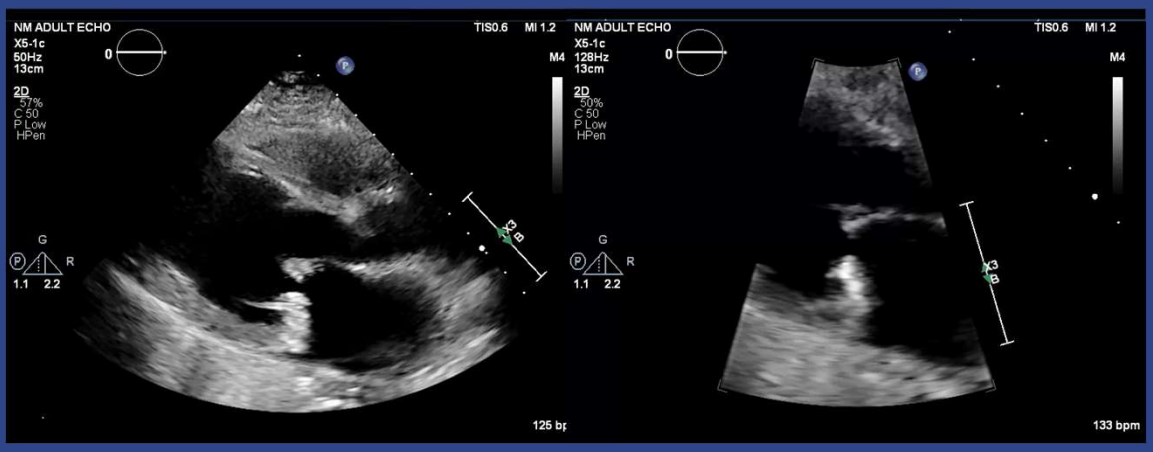

From personal files of Umbra, J.

69

PSAX and Apical 4 Chamber

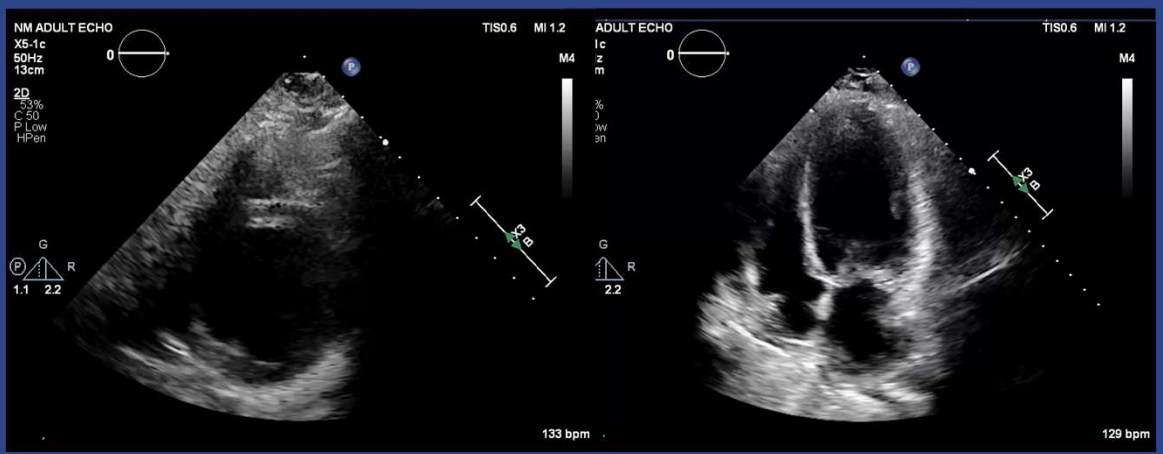

From personal files of Umbra, J.

70

© Copyright. Society of Diagnostic Medical Sonography. All Rights Reserved.

Apical 2 & 3 Chamber

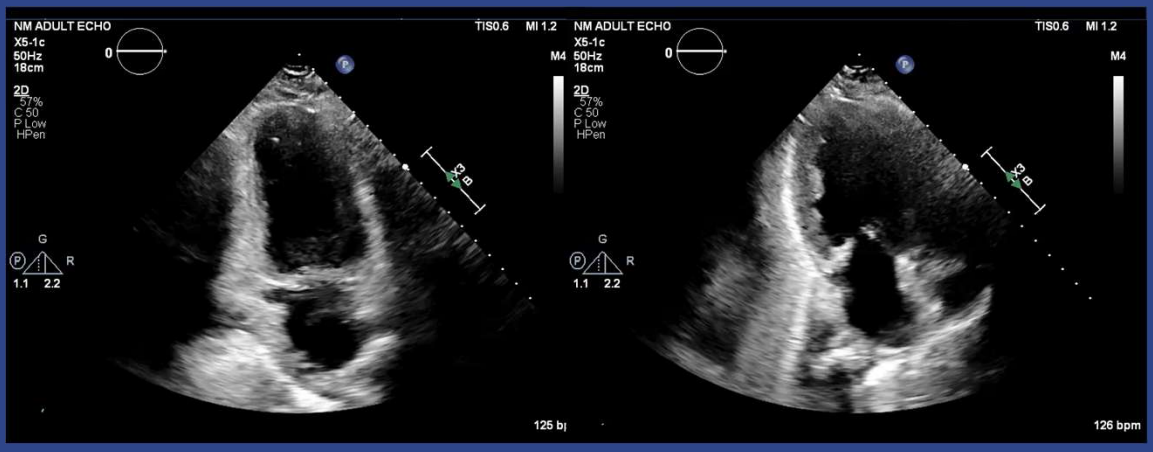

From personal files of Umbra, J.

71

Apical 4 & 2 Chamber



From personal files of Umbra, J.

72

© Copyright. Society of Diagnostic Medical Sonography. All Rights Reserved.

Apical 3 Chamber & PLAX

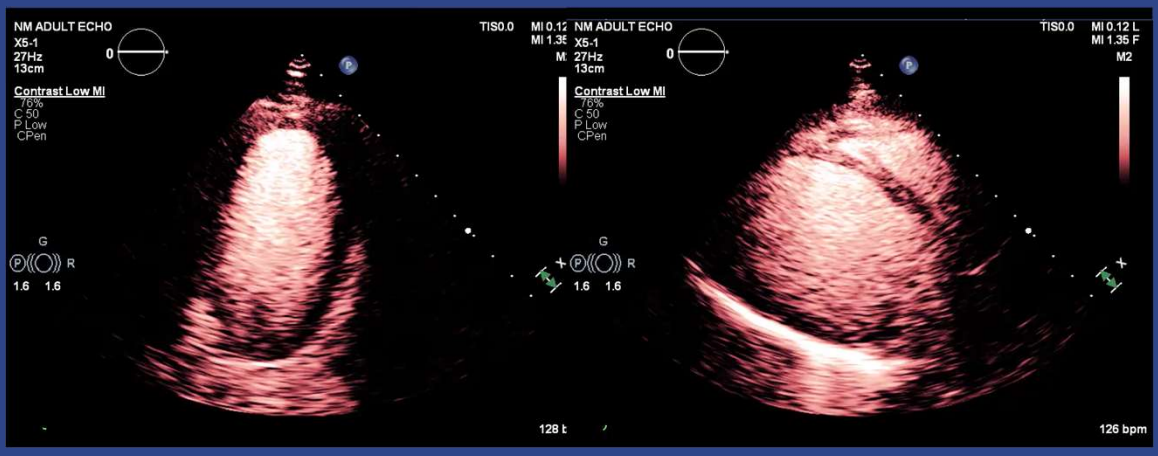

From personal files of Umbra, J.

73

TTE Report

- Dilated left ventricle
- Severely reduced systolic function LVEF ~25%
- Apex and all apical segments have normal contractility while the mid to basal segments are severely hypokinetic to akinetic
- Findings are suggestive of possible reverse Takotsubo if fits clinical picture

74

© Copyright. Society of Diagnostic Medical Sonography. All Rights Reserved.

Variants

Type I : Apical
Typical & Most Common
Type II : Mid Ventricular Atypical
Type III : Basal Atypical
Type IV : Focal Atypical
Type V : Isolated Right Ventricular or Biventricular

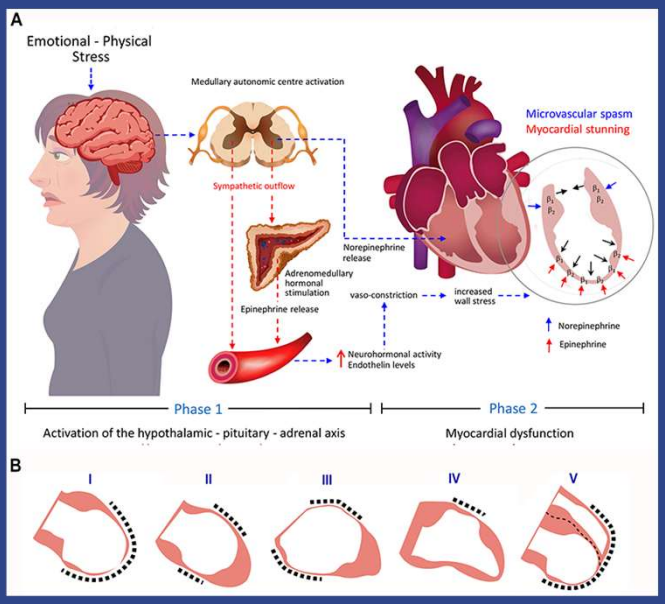

Takotsubo syndrome: the broken-heart syndrome

75

Follow-up TTE

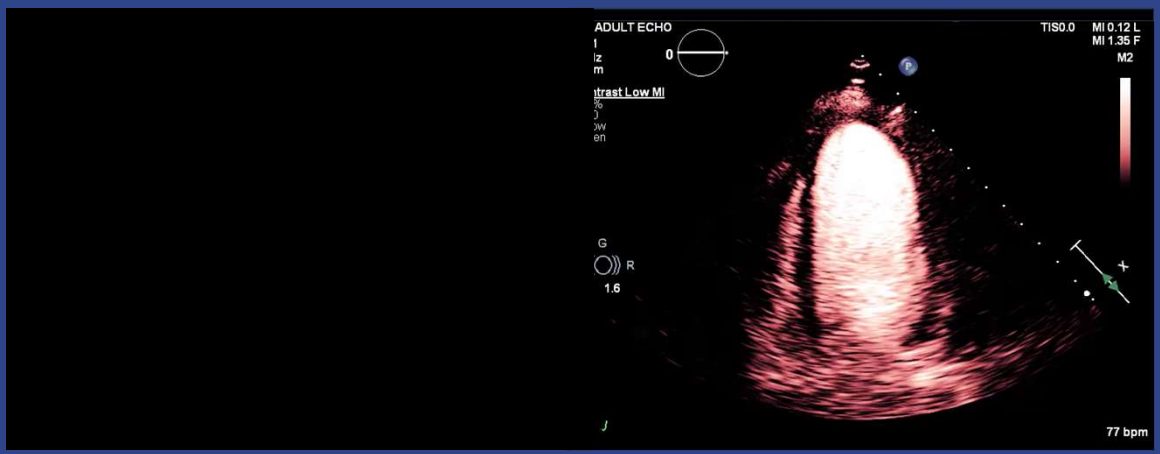

Original Echo

4 Days Later

From personal files of Umbra, J.

76

© Copyright. Society of Diagnostic Medical Sonography. All Rights Reserved.

“Be disciplined and careful. As one day, you'll be the last person standing between the man and his grave. ”

-Unknown

77

Questions?

jumbra@unmc.edu

78

© Copyright. Society of Diagnostic Medical Sonography. All Rights Reserved.

References

1. *Cardiovascular Medicine: Medical Knowledge Self Assessment Program, MKSAP 15. (2009). . American College of Physicians.*
2. *Daigle, R. J. (2022). Techniques in noninvasive vascular diagnosis: An Encyclopedia of Vascular Testing. Summer Publishing.*
3. *Klabunde, R. E. (2022). Cardiovascular Physiology Concepts. Wolters Kluwer.*
4. *Size GP, Lozanski L, Russo T, French-Sherry E, Skelly CL. Inside ultrasound vascular reference guide. Pearce, AZ: Inside Ultrasound, Inc; 2013.*
5. *Surgical repair of inferior sinus venosus defects: a novel approach with unsnared inferior vena cava | Journal of Cardiothoracic Surgery | Full Text (biomedcentral.com)*
6. *Still image from: Bicaval view by 2D ECHO Subxiphoid (youtube.com)* https://www.heartfoundation.org.nz/your-heart/heart-conditions/takotsubo-cardiomyopathy
7. https://bjcardio.co.uk/2021/03/takotsubo-syndrome-the-broken-heart-syndrome/

© Copyright. Society of Diagnostic Medical Sonography. All Rights Reserved.