Ultrasound Evaluation of Upper Extremity Peripheral Nerves

PHILIPS

GI Ultrasound North America

2025

1

Ultrasound Evaluation of Peripheral Nerves Objectives

- Describe the function and basic anatomy of peripheral nerves
- Define proper ultrasound equipment to visualize nerves
- Establish image attributes of nerves
- Outline what anatomy contributes to a neurovascular bundle
- Describe potential variations between normal and abnormal nerves
- Identify how ultrasound is incorporated for needle localization procedures

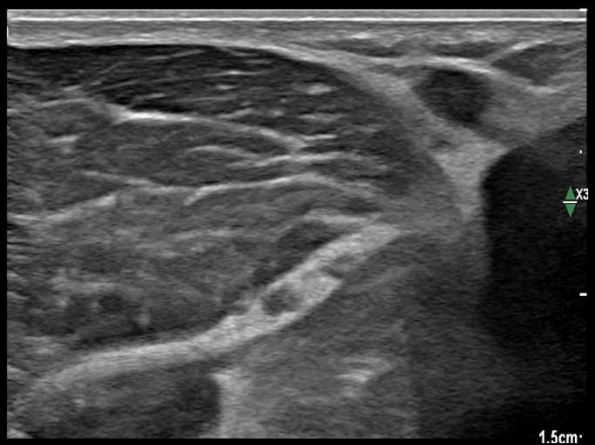

2

© 2024 Koninklijke Philips N.V. All rights reserved.

PHILIPS

2

© Copyright. Society of Diagnostic Medical Sonography. All Rights Reserved.

Why Perform Ultrasound Exams of Peripheral Nerves?

- Interventional procedures
- Isolate and inject or “bathe” a nerve for a procedural block
- Brachial plexus injections for orthopedic procedures of the arm
- Acute injuries
- Trauma / penetrating injuries
- Loss of sensation or pain in extremities after repetitive movements
- Inflammation of median nerve
- Entrapment neuropathies
- Infections
- Palpable lesions
- Malignant or nonmalignant tumors

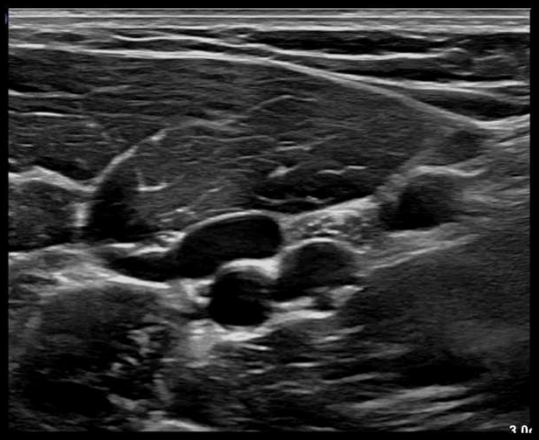

3

© 2024 Koninklijke Philips N.V. All rights reserved.

PHILIPS

3

Ultrasound Evaluation of Peripheral Nerves

Equipment

- Highest MHz transducer for superficial nerves – 15MHz or higher
  - Brachial Plexus
  - Distal extremities
- Can utilize lower frequency transducers when evaluating deeper nerves
- Patient should be positioned to best access area of interest
- Supine or semi-decubitus depending upon region of interest
- Sitting with arm rotating in various positions
- Machine should be positioned to best accommodate proper body mechanics
- Bring patient closer to machine
- Adjust console to center of gravity
- Swing monitor to reduce neck fatigue
- Roll towels under arm to better evaluate superficial nerves

4

© 2024 Koninklijke Philips N.V. All rights reserved.

PHILIPS

4

© Copyright. Society of Diagnostic Medical Sonography. All Rights Reserved.

Upper Extremity Nerve Breakdown

- Cable-like structures that transmit nerve impulses from one part of the body to another
- Normal nerves decrease in size as they travel distally
- Nerves are composed of fibers called axions, which are insulated by a tissue called myelin
- Surrounding the axion fibers include fat tissue, as well as a connective tissue called endoneurium
- Fibers are bundled together by a perineural sheath to form fascicles
- The entire nerve structure is then surrounded by another layer of connective tissue called epineurium
- Fascicular bundles can be visualized by ultrasound

5

© 2024 Koninklijke Philips N.V. All rights reserved.

PHILIPS

5

Fascicles

As nerve bundles travel proximally –the nerve bundle increase in size

Fascicles within larger groups will divide and reunite to form a plexus bundle (ex. Brachial or Lumbar Plexus)

Nerves will vary in shape and appearance throughout a patient population

Short axis views of a nerve can be tracked from a proximal to distal location by following the structure in real-time with ultrasound



6

© 2024 Koninklijke Philips N.V. All rights reserved.

PHILIPS

6

© Copyright. Society of Diagnostic Medical Sonography. All Rights Reserved.

Peripheral Nerve Image Attributes

- Standard to image the nerve in the short axis
- Easier to follow in the short axis when tracking towards area of interest
- Utilize anatomy landmarks to isolate nerve and track proximal/distal during interrogation
- Long axis views are utilized to demonstrate changes to size or echogenicity
- Inflamed nerves will demonstrate bulbous changes proximal to area of pain



7

© 2024 Koninklijke Philips N.V. All rights reserved.

PHILIPS

7

Areas to Image Peripheral Nerves of the Upper Extremities

- Multiple levels of the Brachial Plexus
- Axillary nerve for anesthesia procedures
- Median nerve at the level of the carpal tunnel
- Radial nerve near Guyon's Canal in the wrist
- Ulnar nerve at the posterior elbow
- Posterior interosseous nerve in the forearm

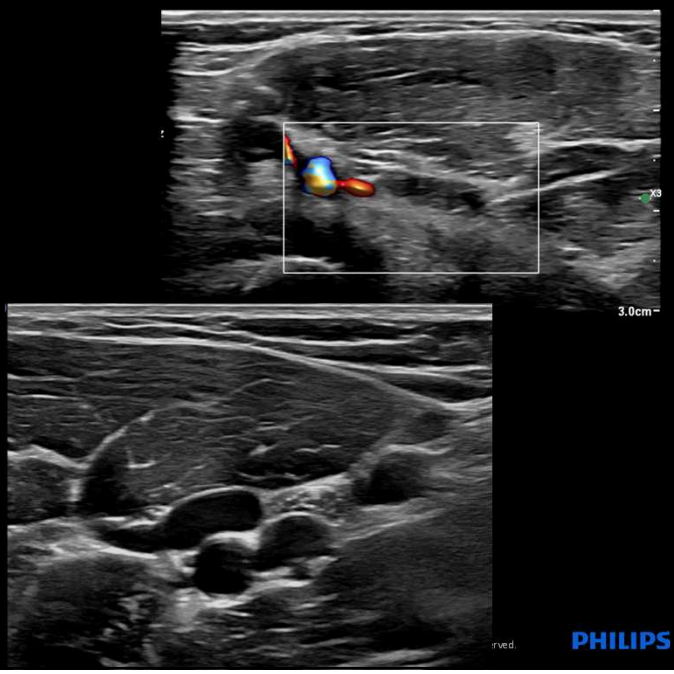

8

PHILIPS

8

© Copyright. Society of Diagnostic Medical Sonography. All Rights Reserved.

Image Attributes of Normal Peripheral Nerves

- Nerves above the clavicle are more hypoechoic, can be irregularly shaped, and larger compared to distal nerves
- In the short axis, nerves can appear as a “honeycomb” appearance
  - Involves hypoechoic fascicles surrounded by hyperechoic epineurium and perineurium
- In the long axis, nerves appear with “train-track” appearance
  - Results from hypoechoic fascicle with hyperechoic edges
- Remember to use anisotropy to distinguish between surrounding structures
- Nerves have low anisotropy with minimal echogenicity changes with the angle of transducer
- Tendon and ligaments have higher anisotropic changes with angulation, so rocking the transducer will cause a shimmering effect on these structures, nerves will remain the same relative echogenicity
- Vessels will compress or pulsate and have Doppler flow
- Nerves will sometimes be associated with a neurovascular bundle
  - Nerve, artery, vein

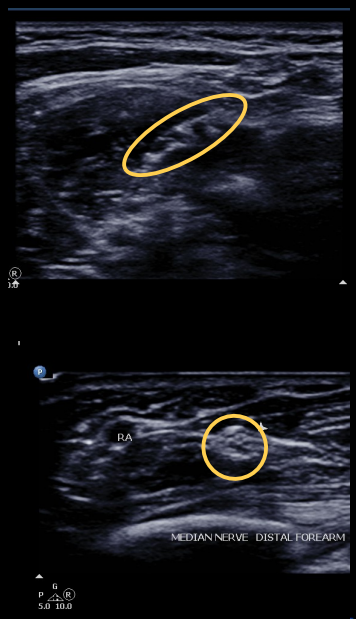

© 2024 Kc

9

9

What is a Neurovascular Bundle

A collection of multiple structures depending on location

- nerve, artery, and vein

Typically, will be held together with connective tissue

- This can cause entrapment of the nerve if it gets inflamed

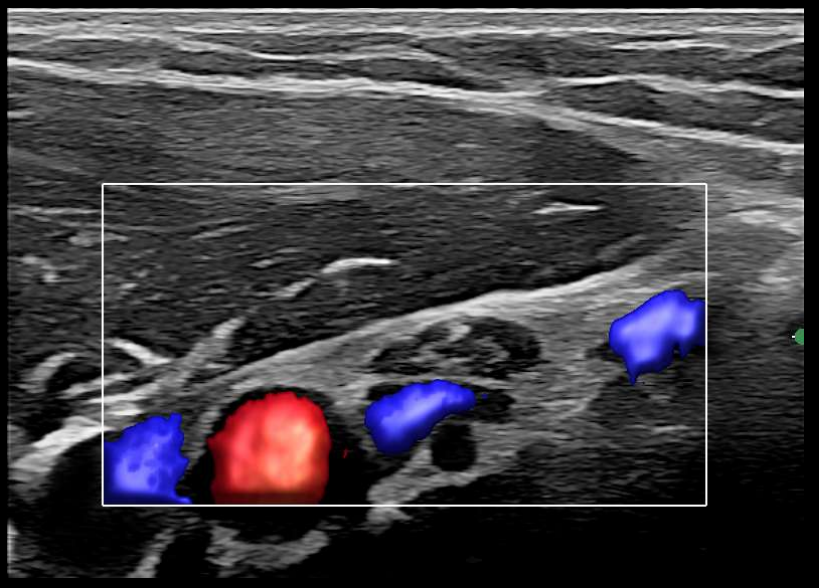

© 2024 Koninklijke Philips N.V. All rights reserved.

PHILIPS

10

10

© Copyright. Society of Diagnostic Medical Sonography. All Rights Reserved.

Sonography of Upper Extremity Peripheral Nerves

© 2024 Koninklijke Philips N.V. All rights reserved.
PHILIPS

Brachial Plexus and Terminal Branches

- Critical to identify surrounding anatomy
- Nerves will change identification based on surrounding anatomy
- From a sonography standpoint,

© 2024 Koninklijke Philips N.V. All rights reserved.
PHILIPS

© Copyright. Society of Diagnostic Medical Sonography. All Rights Reserved.

Brachial Plexus

- Very complex network of connecting nerves originating from multiple levels within cervical spine
- Important to recognize muscle structures, and vascular anatomy as imaging landmarks
- Brachial plexus anatomy can involve anatomical variations
- Each segment transition is functional
  - Critical to reference surrounding body landmarks to reference each location

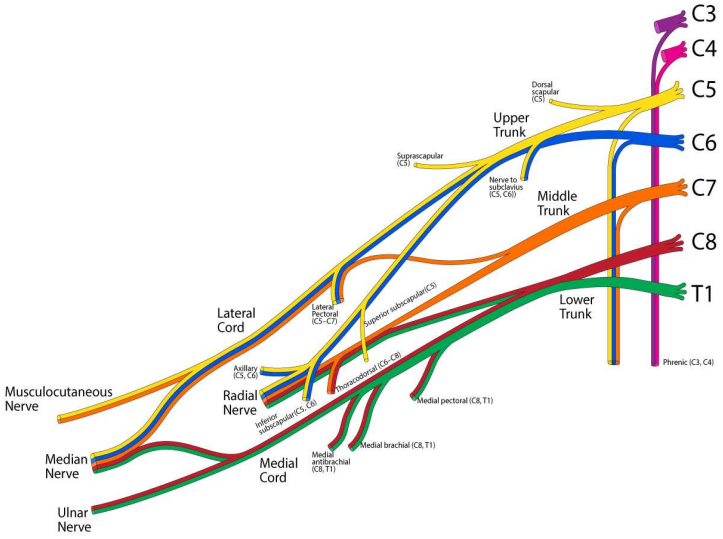

This Photo by Unknown Author is licensed under CC BY-SA

© 2024 Koninklijke Philips N.V. All rights reserved.

PHILIPS

13

Brachial Plexus Anatomy

- Each segment is redefined at specific anatomical landmarks
- Arises from spinal nerves at the C5 – T1 level of the spine at 5 levels (roots)
- 3 trunks
- 6 divisions
- 3 cords
- 5 terminal branches
- (RTDCB)
  - Remember To Drink Cold Beer

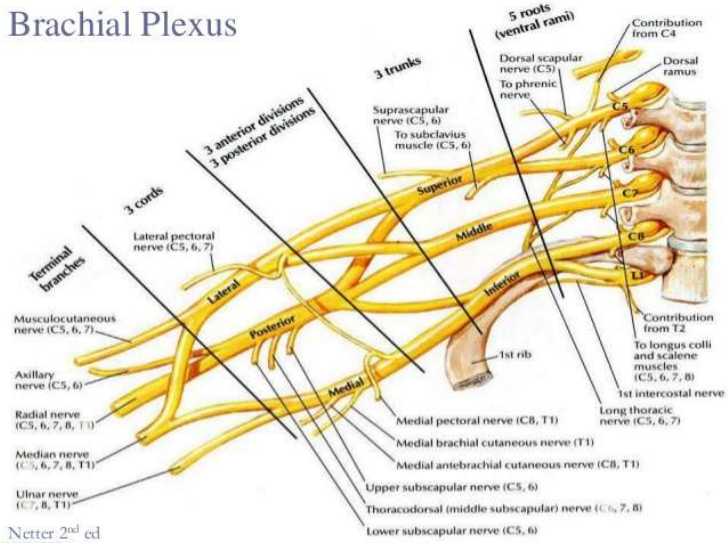

This Photo is licensed under CC BY-SA

© 2024 Koninklijke Philips N.V. All rights reserved.

PHILIPS

14

© Copyright. Society of Diagnostic Medical Sonography. All Rights Reserved.

Brachial Plexus Roots

- Each root arises at levels of the C5-T1 region of the spine
  - Origin is not visualized due to cervical spine shadowing
- Since the C7 vertebra does not have an anterior tubercle, this bony landmark creates starting point to isolate other root structures
  - Rock transducer superiorly/inferiorly in short axis to image remaining root structures

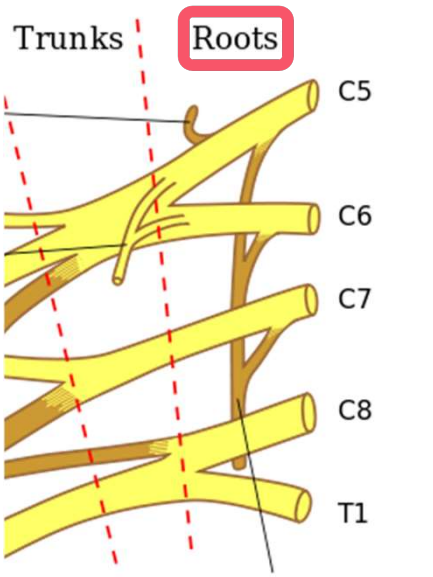

This Photo is licensed under CC BY-SA

© 2024 Koninklijke Philips N.V. All rights reserved.
PHILIPS

15

Brachial Plexus Trunks

- Consists of 3 structures:
  - Superior, middle, inferior
- All three can be imaged between the anterior and medial scalene muscles
  - Always in the inter-scalene triangle area
  - Will be located superiorly to subclavian artery

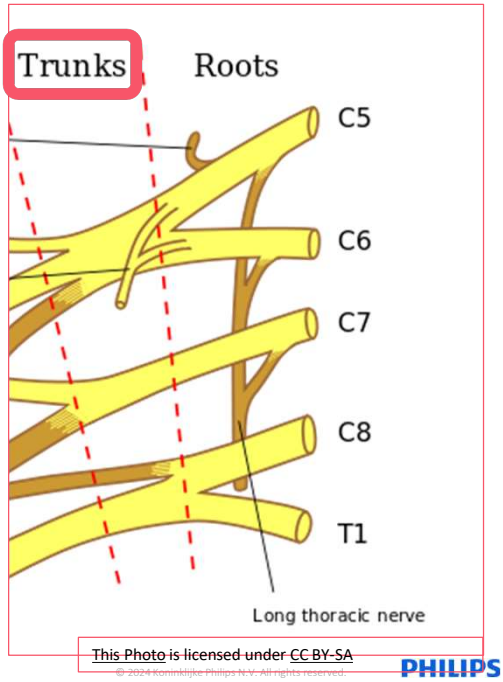

This Photo is licensed under CC BY-SA

© 2024 Koninklijke Philips N.V. All rights reserved.
PHILIPS

16

© Copyright. Society of Diagnostic Medical Sonography. All Rights Reserved.

Brachial Plexus Imaging Technique

- Pt is supine, with head 45 degrees to opposite side of cricoid cartilage in transverse plane
  - Sternocleidomastoid muscle – anterior
  - Carotid artery and jugular vein – medial
  - Anterior scalene muscle - medial
  - Posterior scalene muscle – lateral
- Tip probe slightly caudad
  - 1) scan inferior to supraclavicular region and follow nerves superiorly to visualize the roots or 2) locate carotid artery and IJV scan laterally

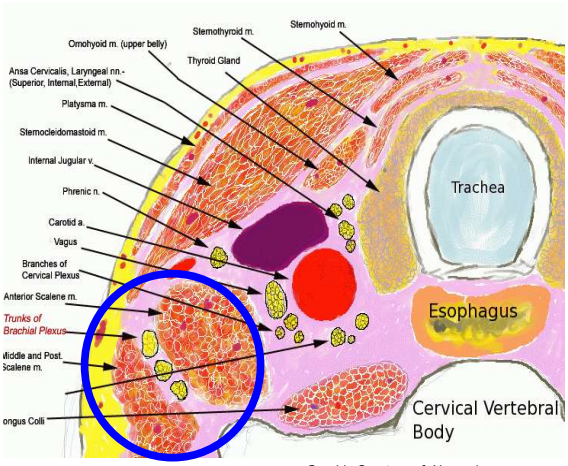

Graphic Courtesy of: Neuraxiom.com
Jack Vander Beek
jack@neuraxiom.com

© 2024 Koninklijke Philips N.V. All rights reserved.
PHILIPS

17

Interscalene Examples

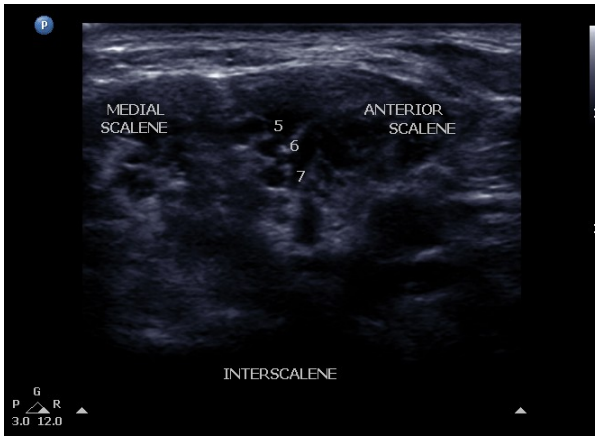

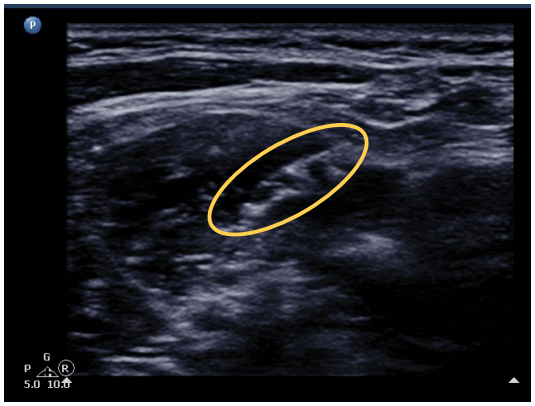

© 2024 Koninklijke Philips N.V. All rights reserved.
PHILIPS

18

© Copyright. Society of Diagnostic Medical Sonography. All Rights Reserved.

Brachial Plexus Division

- Consists of 6 divisions
- Can be isolated at the lateral aspect of the supraclavicular fossa
- Note how each individual trunk networks at this level

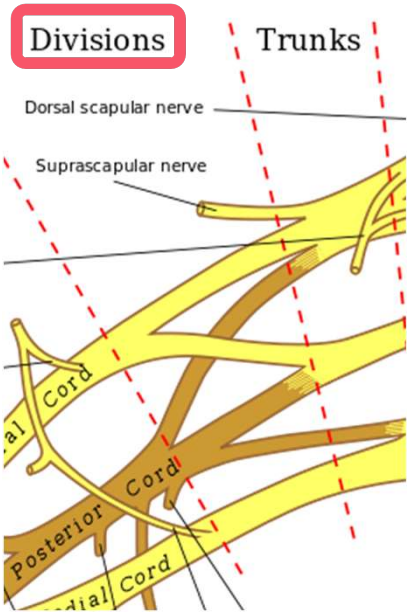

This Photo is licensed under CC BY-SA

19

© 2024 Koninklijke Philips N.V. All rights reserved.

PHILIPS

19

Supraclavicular Nerve Imaging Technique

- Pt is supine, with head turned 45 degrees to opposite side
- Transducer placed supraclavicular fossa in oblique position
- Tip probe slightly caudad
- Rotate probe anterior or posterior to bring nerves into view



Image courtesy of Philips Healthcare

20

© 2024 Koninklijke Philips N.V. All rights reserved.

PHILIPS

20

© Copyright. Society of Diagnostic Medical Sonography. All Rights Reserved.

Brachial Plexus Cords

- Posterior, medial, lateral cords
- Occurs at the costoclavicular space

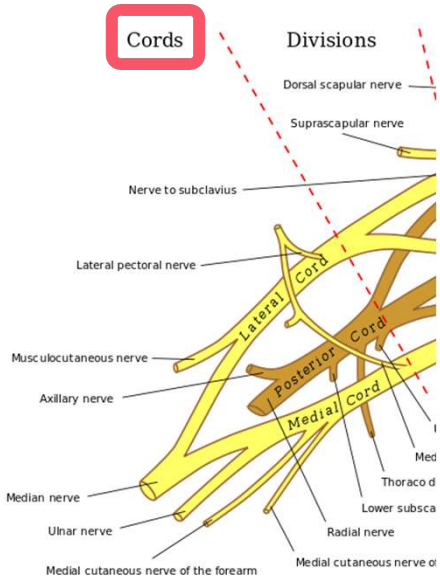

This Photo is licensed under CC BY-SA

© 2024 Koninklijke Philips N.V. All rights reserved.
PHILIPS

21

Brachial Plexus Terminal Branches

- Axillary, radial, ulnar, median, and musculocutaneous nerves
- Patient supine, arm abducted 90 degrees
  - Helpful to supinate and abduct forearm 90 degrees as well
- Critical to utilize axillary vessel anatomy to isolate each terminal branch
  - Median nerve anterior to axillary artery
  - Ulnar nerve located between axillary artery and vein
  - Radial nerve located posterior to axillary artery

© 2024 Koninklijke Philips N.V. All rights reserved.
PHILIPS

22

© Copyright. Society of Diagnostic Medical Sonography. All Rights Reserved.

Brachial Plexus Abnormalities

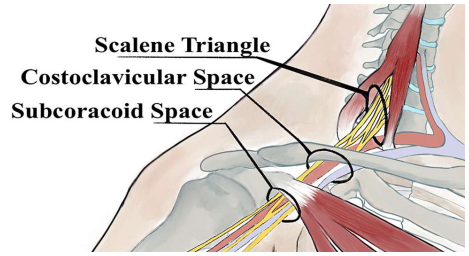

- Scalenus Syndrome (neurogenic Thoracic Outlet Syndrome)
- Potential area that can entrap the nerve, causing pain/numbness
- Involves C5, C6, & C7 nerve roots
- Consider patients with history of upper body physical exercise

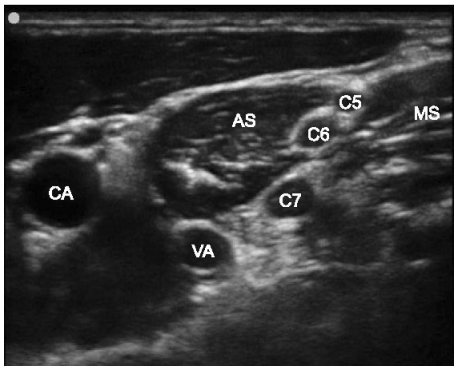

Image courtesy of Philips Healthcare

23 https://www.semanticscholar.org/paper/Risk-of-Encountering-Dorsal-Scapular-and-Long-Block-Kim-Yu/671534fd95484a9e89c9207dda9ff8a10f70401e

© 2024 Koninklijke Philips N.V. All rights reserved.

PHILIPS

23

Brachial Plexus Terminal Branches

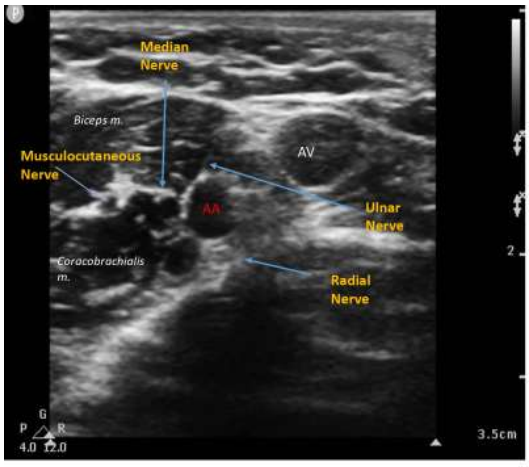

Fig 2: Brachial Plexus Sonoanatomy around the Axillary Artery (AA)

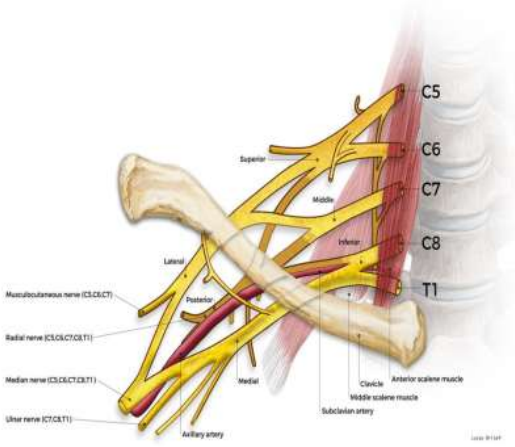

Fig 1: Brachial Plexus schematic diagram

24 https://www.ncbi.nlm.nih.gov/books/NBK537201/figure/article-18055.image.f1/?report=objectonly

© 2024 Koninklijke Philips N.V. All rights reserved.

PHILIPS

24

© Copyright. Society of Diagnostic Medical Sonography. All Rights Reserved.

Axillary Nerve

- Supplies sensation to the deltoid muscle primarily
  - Also branches to shoulder joint capsule and teres minor
- On the posterior aspect of the shoulder the axillary nerve passes through the Quadrangular space.
  - Important landmark for surgical nerve blocks
    - Borders include Teres Minor, Teres Major, surgical neck of the humerus, and long head of the triceps brachii

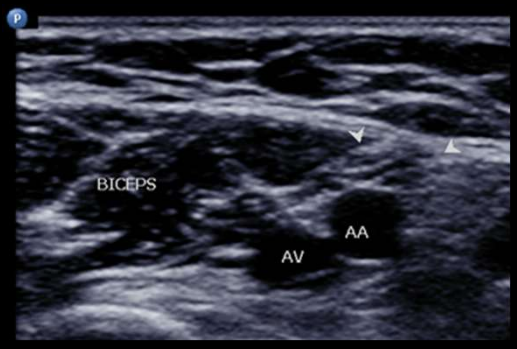

25

© 2024 Koninklijke Philips N.V. All rights reserved.

PHILIPS

25

Axillary Nerve Imaging Technique

- Pt is supine
- Nerves are typically round or oval at this level
  - Median nerve anterior to axillary artery
  - Ulnar nerve located between axillary artery and vein
  - Radial nerve located posterior to axillary artery
- Transducer placed in transverse plane along axillary crease
    - Abduct arm to 90 degrees
    - Humerus - posterior
    - Axillary artery – the nerves will be positioned adjacent
    - Axillary vein – easy to compress while imaging
    - Biceps – lateral
    - Triceps – medial

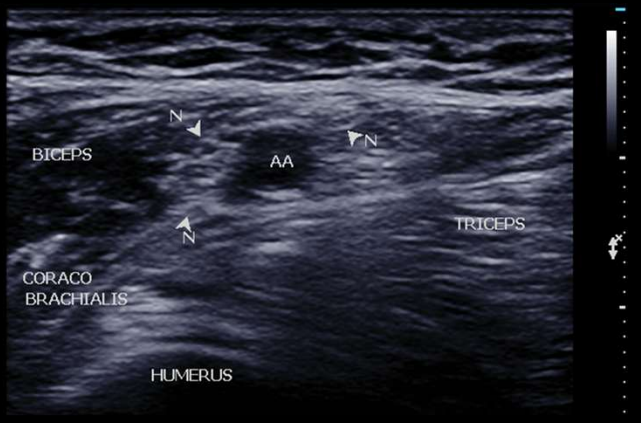

26

© 2024 Koninklijke Philips N.V. All rights reserved.

PHILIPS

26

© Copyright. Society of Diagnostic Medical Sonography. All Rights Reserved.

Radial Nerve

- Innervates multiple areas throughout the arm
  - Consists of several smaller branches to evaluate based on clinical presentation
- The deep branch of the radial nerve, or sometimes called posterior interosseous nerve (PIN) transverses along the forearm and can be found to innervate the posterior aspect of the hand



27

© 2024 Koninklijke Philips N.V. All rights reserved.

PHILIPS

27

Radial Nerve



28

© 2024 Koninklijke Philips N.V. All rights reserved.

PHILIPS

28

© Copyright. Society of Diagnostic Medical Sonography. All Rights Reserved.

Posterior Interosseous Nerve

- Journeys between and divides the superficial (S1) and deep (S2) Supinator muscles
  - Muscles that supinate/pronate the hand
  - Potential site of nerve entrapment
  - Main trunk between BR and Brachialis
  - Pierces Supinator and enters the Arcade of Frohse

29

© 2024 Koninklijke Philips N.V. All rights reserved.

PHILIPS

29

Posterior Interosseous Nerve

- Radial Nerve
  - Transducer in TRV position
  - View between the Brachioradialis and the Brachialis muscle
- Ends at bifurcation
- Superficial Sensory Branch
- Posterior Interosseous Nerve
  - Travels between and divides the superficial (S1) and deep (S2) Supinator muscles

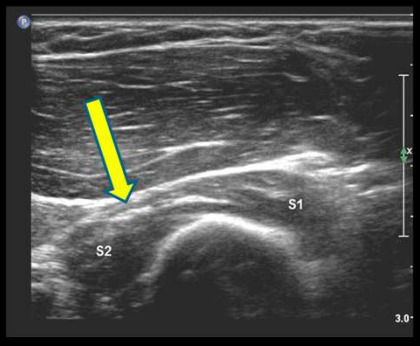

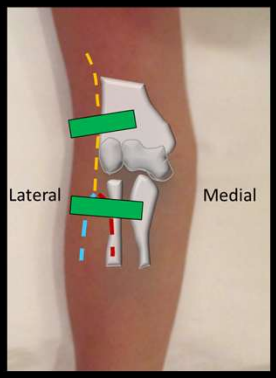

30

© 2024 Koninklijke Philips N.V. All rights reserved.

PHILIPS

30

© Copyright. Society of Diagnostic Medical Sonography. All Rights Reserved.

Ulnar Nerve

- Multiple areas that can be evaluated based on clinical presentation
- Posterior elbow the ulnar nerve can become entrapped along posterior aspect of elbow, causing numbness and pain.
  - Condition termed Cubital Tunnel Syndrome

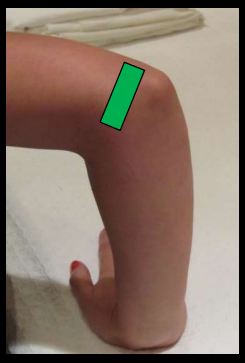



31

© 2024 Koninklijke Philips N.V. All rights reserved.

PHILIPS

31

Ulnar Nerve

- Multiple areas that can be evaluated based on clinical presentation
- Posterior elbow the ulnar nerve can become entrapped along posterior aspect of elbow, causing numbness and pain.
  - Condition termed Cubital Tunnel Syndrome





32

© 2024 Koninklijke Philips N.V. All rights reserved.

PHILIPS

32

© Copyright. Society of Diagnostic Medical Sonography. All Rights Reserved.

Ulnar Nerve



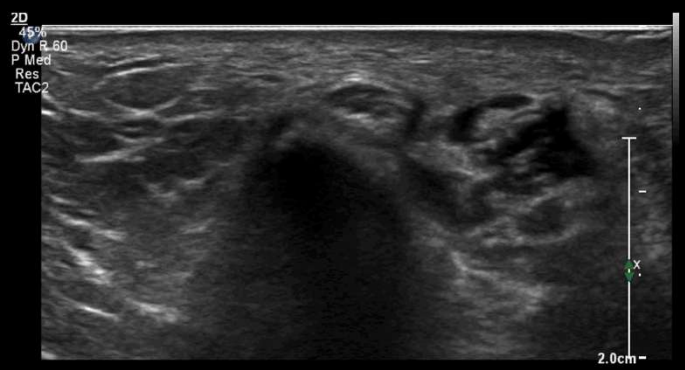

33

© 2024 Koninklijke Philips N.V. All rights reserved.

PHILIPS

33

Ulnar Nerve

- Guyon's Canal
  - Neurovascular bundle adjacent to hook of the hamate bone
  - Potential site for nerve entrapment
    - Bicyclists
    - Walkers



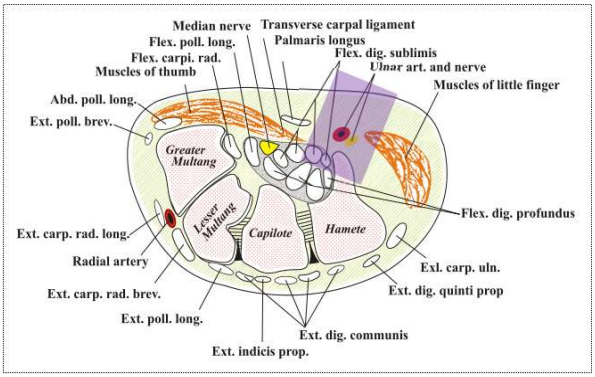

34

© 2024 Koninklijke Philips N.V. All rights reserved.

PHILIPS

34

© Copyright. Society of Diagnostic Medical Sonography. All Rights Reserved.

Ulnar Nerve

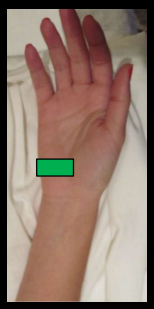

- Can be compressed at the wrist causing pain and numbness of 5th digit and ring finger
- Condition termed Guyon's Canal Syndrome
- Seen by people who grip handles over long periods of time (bicyclists, wheelchairs, etc)
- Nerve gets compressed and inflamed within the neurovascular bundle at the level of the wrist

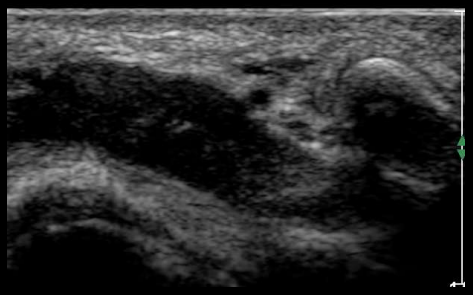

© 2024 Koninklijke Philips N.V. All rights reserved.
PHILIPS

35

Median Nerve

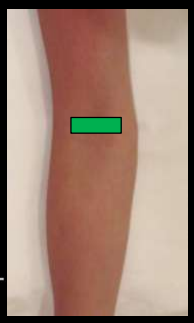

- Located medial side of humerus at elbow flexion line
- The peripheral nerves such as median, ulnar, radial will have a well-defined fascia plane that separates them from muscle fascia
- Arm abducted and in supination position
- Dorsum of hand lying on the table
- Transducer placed in transverse position across from brachial artery about 2-3 cm above elbow crease
- Follow nerve by scanning distal and proximally
- Identify the brachial artery and then tilt transducer to ID vein

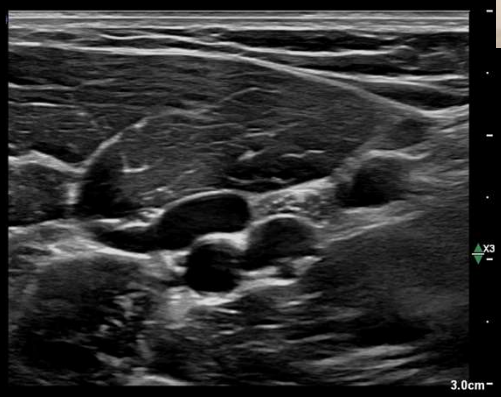

© 2024 Koninklijke Philips N.V. All rights reserved.
PHILIPS

36

© Copyright. Society of Diagnostic Medical Sonography. All Rights Reserved.

Median Nerve

- Major area to evaluate median nerve for carpal tunnel syndrome
  - Tunnel contains bones and connective tissue along with median nerve
  - If swelling occurs, then nerve becomes entrapped or compressed

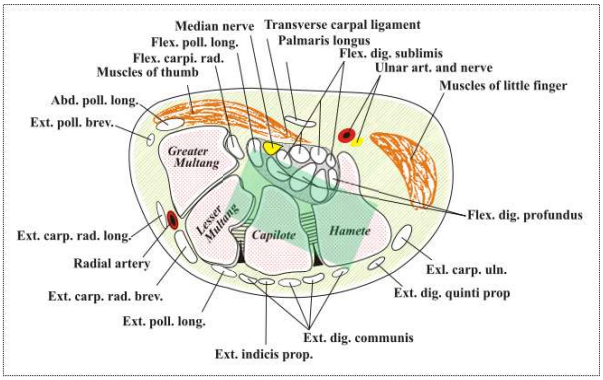

© 2024 Koninklijke Philips N.V. All rights reserved.
PHILIPS

37

Median Nerve

Major area to evaluate median nerve for carpal tunnel syndrome

- Tunnel contains bones and connective tissue along with median nerve
- If swelling occurs then nerve becomes entrapped or compressed

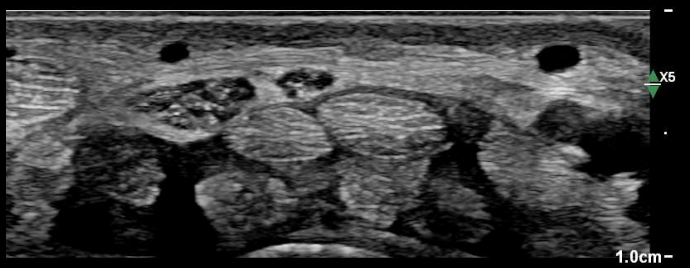

© 2024 Koninklijke Philips N.V. All rights reserved.
PHILIPS

38

© Copyright. Society of Diagnostic Medical Sonography. All Rights Reserved.

Nerve Abnormalities

- Can occur from trauma, entrapment, malignant/nonmalignant tumors
- Excessive or repetitive motions can cause nerves to become inflamed
  - Symptoms can be pain, numbness to digits, tingling sensation to hand
  - Critical to obtain detailed history from patient to isolate area of interest
- Inflamed nerves will typically become bulbous and hypoechoic at level of pain
  - Remember to compare contralateral side for comparison

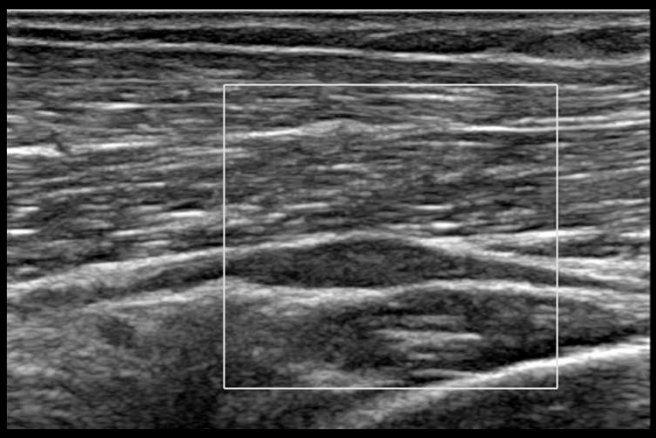

39 © 2024 Koninklijke Philips N.V. All rights reserved. PHILIPS

39

Nerve Abnormalities

- Inflamed nerves will typically become bulbous and hypoechoic at level of pain
  - Remember to compare contralateral side for comparison



40 © 2024 Koninklijke Philips N.V. All rights reserved. PHILIPS

40

© Copyright. Society of Diagnostic Medical Sonography. All Rights Reserved.

Interventional Nerve Imaging

© 2024 Koninklijke Philips N.V. All rights reserved.
PHILIPS

Ultrasound Guided Nerve Imaging

- Direct visualization of the nerve and needle location in real time
  - Can document spread of anesthetic during nerve block procedures
  - Used to isolate specific nerves for surgical procedures
- Assists healthcare provider to avoid injections into critical surrounding structures

© 2024 Koninklijke Philips N.V. All rights reserved.
PHILIPS

© Copyright. Society of Diagnostic Medical Sonography. All Rights Reserved.

Ultrasound Guided Nerve Imaging

- Conventional Nerve Blocks using nerve stimulation
  - High false negative rate
    - Nerve stimulator 20%
- Also false positive rate
- Some blocks are dangerous – risk of puncturing the lung or injecting anesthetic into vessels
- Nerve stimulation tells nothing about the spread of local anesthetic
- Nerve stimulation tells nothing about anatomical anomalies



- Ultrasound provides
- Direct visualization of the nerve, the needle, and the spread of the anesthetic
- Visualization of variable anatomy and surrounding structures
- There may be dangerous structures near the nerves (for example vessels and lungs)

© 2024 Koninklijke Philips N.V. All rights reserved.
PHILIPS

43

Ultrasound Guided Nerve Imaging

Nerves above the clavicle tend to be hypoechoic; nerves below the clavicle (peripheral nerves) have a more echogenic “honeycomb” appearance

Depending on nerve location they may be round, triangular or oval

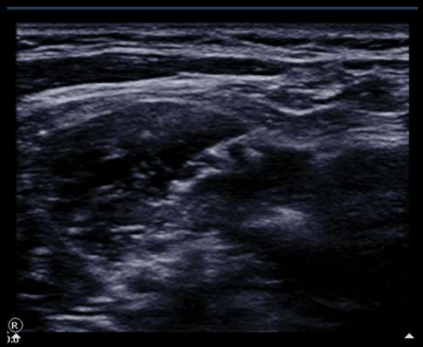

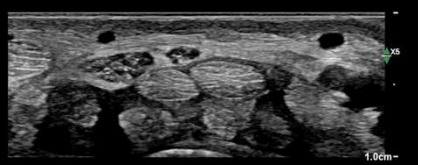

© 2024 Koninklijke Philips N.V. All rights reserved.
PHILIPS

44

© Copyright. Society of Diagnostic Medical Sonography. All Rights Reserved.

Needle to Transducer Alignment

- Best approach is for needle to be parallel to transducer (in-plane)
  - Rock transducer to localize entirety of needle within tissue
- If transducer is out-plane to the needle, will only see the short-axis of the needle shaft

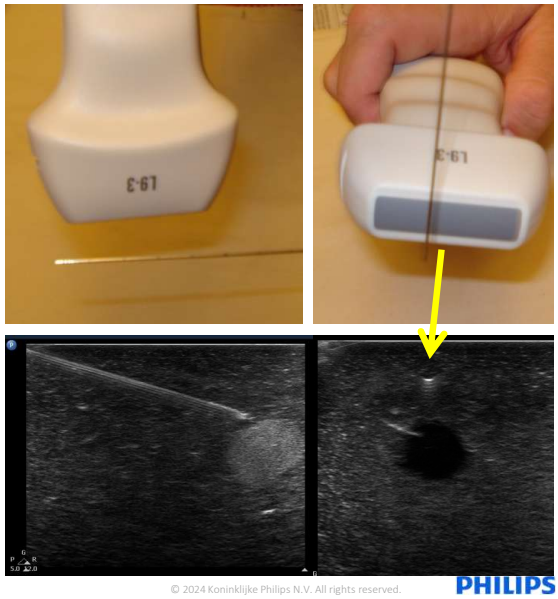

© 2024 Koninklijke Philips N.V. All rights reserved.

PHILIPS

45

45

Examples of Anesthetic Injections

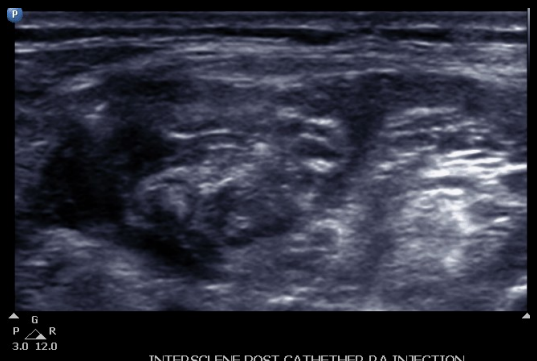

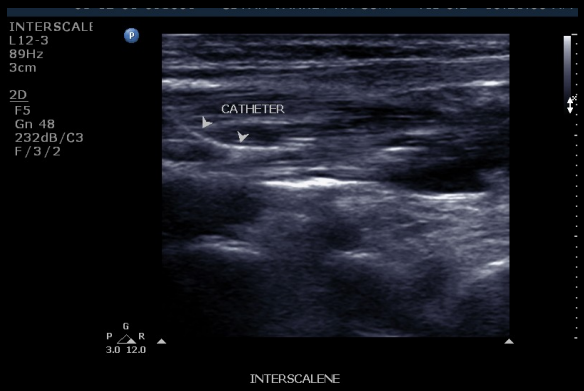

© 2024 Koninklijke Philips N.V. All rights reserved.

PHILIPS

46

46

© Copyright. Society of Diagnostic Medical Sonography. All Rights Reserved.

Conclusion

- Reference surrounding anatomy to distinguish different nerves
  - The transition between nerves is largely functional as you image the brachial plexus and will transition at specific anatomy regions
  - Terminal nerves will have multiple branches as they course towards the hand
- When confirming specific nerves, remember to track the course of the nerve proximal-distal for confirmation
- Acute inflammation of nerves will typically demonstrate a bulbous change at the site of pain
  - Compare contralateral side

47

© 2024 Koninklijke Philips N.V. All rights reserved.

PHILIPS

47

PHILIPS

48

© Copyright. Society of Diagnostic Medical Sonography. All Rights Reserved.