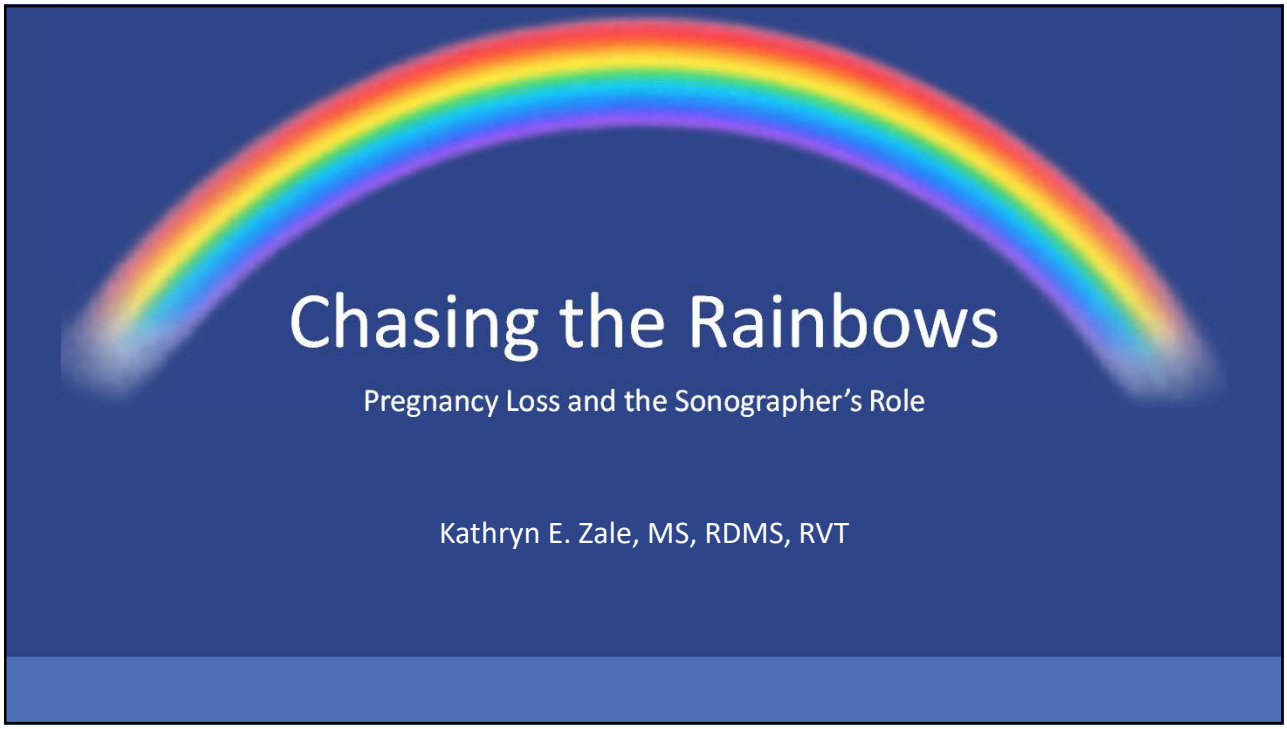

1

SPEAKER PRESENTATION DISCLAIMER

The content and views presented are made available for educational purposes only. The information presented are the opinions of the presenter and do not necessarily represent the views of the Society of Diagnostic Medical Sonography (SDMS) or its affiliated organizations, officers, Boards of Directors, or staff members.

The presenter is responsible for ensuring balance, independence, objectivity, scientific rigor, and avoiding commercial bias in their presentation. Before making the presentation, the presenter is required to disclose to the audience any relevant financial interests or relationships with manufacturers or providers of medical products, services, technologies, and programs.

The SDMS and its affiliated organizations, officers, Board of Directors, and staff members disclaim any and all liability for all claims that may arise out of the use of this educational activity.

2

© Copyright. Society of Diagnostic Medical Sonography. All Rights Reserved.

GENERATIVE AI DISCLAIMER

The presenter utilized the use of large language models (LLMs) and generative artificial intelligence (AI) as a productivity tool to assist in drafting and refining content in this presentation.

While these tools can aid in structuring ideas, summarizing, paraphrasing, and language polishing, they have inherent limitations and cannot replace human creativity, critical thinking, or expert judgment. AI-generated content may contain errors, biases, or gaps in knowledge.

This presentation is intended for informational purposes only and should not be construed as definitive or authoritative guidance. Participants are encouraged to critically evaluate the information presented and consult relevant experts as needed. The SDMS and its affiliated organizations, officers, Board of Directors, and staff members disclaim any and all liability for claims that may arise from the use or interpretation of this educational material.

3

Learning Objectives

- Identify current diagnostic criteria and guidelines for early pregnancy loss to support accurate clinical assessment.
- Recognize sonographic findings that differentiate normal early pregnancy from nonviable gestations to improve diagnostic confidence.
- Explain appropriate clinical judgment and communication strategies for managing sensitive patient interactions in OB/GYN ultrasound.



4

© Copyright. Society of Diagnostic Medical Sonography. All Rights Reserved.

Why "Chasing the Rainbows"?

RAINBOW

rainbow baby

A baby born after pregnancy loss.

BEFORE THE RAINBOW

There was a pregnancy, **and a story that changed.**

REMEMBER

We see one examination.

The patient is living an entire story.

5

Early Pregnancy Loss is Common

~1 in 10

clinically recognized pregnancies end in early pregnancy loss.*

~50%

of early pregnancy losses are due to fetal chromosomal abnormalities that disrupt normal embryonic development.*

In almost every case, miscarriage is not caused by something the patient did.*

Common does not mean routine to the person experiencing it.

* American College of Obstetricians and Gynecologists (ACOG). Early Pregnancy Loss.

6

© Copyright. Society of Diagnostic Medical Sonography. All Rights Reserved.

WHAT WE SEE MATTERS.

The sonographer's role of knowing the criteria

7

Know the Criteria

Certainty matters when the next step may be irreversible.



MILLIMETERS + DAYS

can separate "too early to know" from diagnostic certainty.



2013 SRU

Conservative thresholds designed to prevent false-positive diagnosis.



2023/2024 UPDATE

2023 multisociety consensus → First-Trimester US Lexicon published 2024

Greater precision in both terminology and diagnosis.



Accuracy is not separate from compassion.

8

© Copyright. Society of Diagnostic Medical Sonography. All Rights Reserved.

The Criteria Didn't Change. The Language Did.

OLDER / AVOID	CURRENT / PREFERRED
Pregnancy failure	Early pregnancy loss (EPL)
Suspicious for pregnancy failure	Concerning for EPL
Diagnostic of pregnancy failure	Diagnostic of EPL
Heartbeat / heart motion / live / living / viable	Cardiac activity
Viability scan	First-trimester / early pregnancy US
Blighted ovum	Anembryonic pregnancy

2013 SRU diagnostic criteria remain unchanged.
- 2023 multisociety consensus → First-Trimester US Lexicon published 2024

Precision in language is part of precision in care.

9

Three Questions in the First Trimester



1. Is this pregnancy normal?



2. Is there diagnostic evidence of early pregnancy loss?



3. Are there findings concerning for early pregnancy loss?

10

© Copyright. Society of Diagnostic Medical Sonography. All Rights Reserved.

5 Categories of Early Pregnancy Loss (EPL)

Same umbrella. Different sonographic questions.

1. **Diagnostic for EPL**
   Criteria are met.
2. **EPL in progress**
   Loss is actively occurring.
3. **Incomplete EPL**
   Some products remain.
4. **Completed EPL**
   Previously seen pregnancy is no longer present.
5. **Concerning for EPL**
   Findings raise concern but are not diagnostic.

11

Diagnostic of Early Pregnancy Loss*

CRL ≥ 7 mm
+ NO CARDIAC ACTIVITY

MSD ≥ 25 mm
+ NO EMBRYO

Serial criteria:

- ≥ 2 weeks after GS without yolk sac → no embryo with cardiac activity
- ≥ 11 days after GS with yolk sac → no embryo with cardiac activity

*SRU diagnostic criteria (2013); criteria retained in the 2024 First-Trimester US Lexicon.

12

© Copyright. Society of Diagnostic Medical Sonography. All Rights Reserved.

Patient Perspectives

What do grieving parents tell you they remember most about the ultrasound itself?

13

Anembryonic Pregnancy

Criteria
MSD ≥ 25 mm
+ No Embryo



Source: Murugan VA, et al. Ultrasonography. 2020;39(2):178–189. CC BY-NC 4.0.

Large empty gestational sac without a yolk sac, amnion, or embryo

Diagnostic of EPL

14

© Copyright. Society of Diagnostic Medical Sonography. All Rights Reserved.

Measure Thrice. Diagnose Once.

The threshold is only as trustworthy as the measurement used to reach it.

Precision protects people.

Measure Accurately

Use correct planes and calipers.

Verify Before You Decide

Confirm findings and recheck when needed.

Every Measurement Matters

Your precision informs care and outcomes.

15

Embryonic Demise

Criteria

CRL ≥ 7 mm + No Cardiac Activity

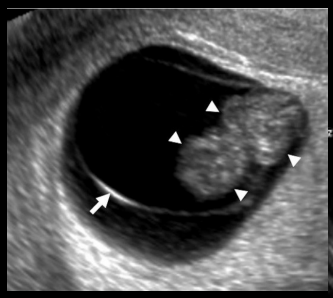

Early pregnancy loss with hydropic changes of the embryo (arrowheads)

CRL=1.1 cm (7w2d)

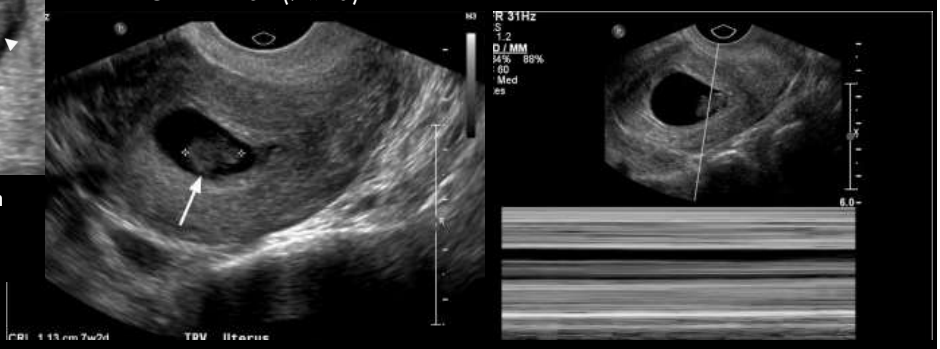

Source: Murugan VA, et al. Ultrasonography. 2020;39(2):178–189. CC BY-NC 4.0.

Diagnostic of EPL

16

© Copyright. Society of Diagnostic Medical Sonography. All Rights Reserved.

Before You Call Cardiac Activity Absent

1 OPTIMIZE

Optimize real-time B-mode

- ✓ Magnify the embryo
- ✓ Optimize depth, gain & focal zone
- ✓ Confirm the structure you're evaluating

2 CONFIRM

Document cardiac activity when present

- ✓ 2D cine or M-mode when appropriate
- ✓ Use adjunct techniques when uncertainty remains

3 KNOW THE LIMIT

Color can help confirm presence.

- ✓ Absence of color alone does not confirm absence.

Follow ALARA principles and departmental protocol.

17

Early Pregnancy Loss in Progress

Patient presented with abdominal pain and bleeding, gestational sac (arrow) is intrauterine, arrowheads point to an open cervix

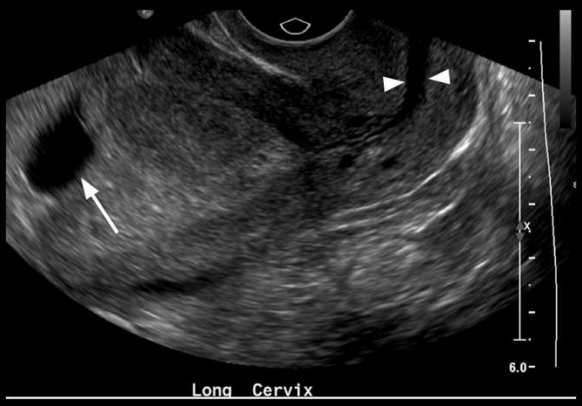

Next day follow-up shows the gestational sac (arrowheads) in the cervix



Source: Murugan VA, et al. Ultrasonography. 2020;39(2):178–189. CC BY-NC 4.0.

EPL in progress

18

© Copyright. Society of Diagnostic Medical Sonography. All Rights Reserved.

Incomplete Early Pregnancy Loss

Source: Hagen-Ansert SL. Textbook of Diagnostic Sonography. 9th ed. Elsevier; 2023. Fig. 50.2 Used with permission.



Patient presented with pain, fever, and bleeding secondary to an abortion 2 days prior. Endometrial canal is distended and retained products of conception cast shadows into the myometrial cavity.



Endometrium > 8 mm and increased vascularity can support concern for retained tissue.

Incomplete EPL

19

Complete Early Pregnancy Loss

Previously documented IUP of 6 weeks no longer visualized after heavy bleeding. There is some widening between the uterine walls (measurement 7.1 mm) but no sign of any gestational sac.



Source: Häggström M. Medical Gallery of Mikael Häggström 2014. WikiJournal of Medicine. 2014;1(2). CC0/Public Domain.

Complete EPL

20

© Copyright. Society of Diagnostic Medical Sonography. All Rights Reserved.

WHAT WE DON'T SEE MATTERS.

The sonographer's role of recognizing what is not yet diagnostic

21

Concerning for EPL ≠ Diagnostic of EPL

These findings raise concern for early pregnancy loss but are not diagnostic on their own.

- CRL below the definitive threshold with no cardiac activity
- MSD 16–24 mm with no embryo
- Shorter serial follow-up intervals
- Expanded amnion
- Enlarged or morphologically abnormal yolk sac
- Small gestational sac relative to embryo

Use appropriate follow-up and clinical context.
One ultrasound does not make the diagnosis in these cases.

22

© Copyright. Society of Diagnostic Medical Sonography. All Rights Reserved.

Patient Perspectives

How should a sonographer manage their demeanor when they become concerned during an exam?

23

CRL below threshold

Concern
CRL < 7 mm + No Cardiac Activity

First seen at 5.5 to 6 weeks

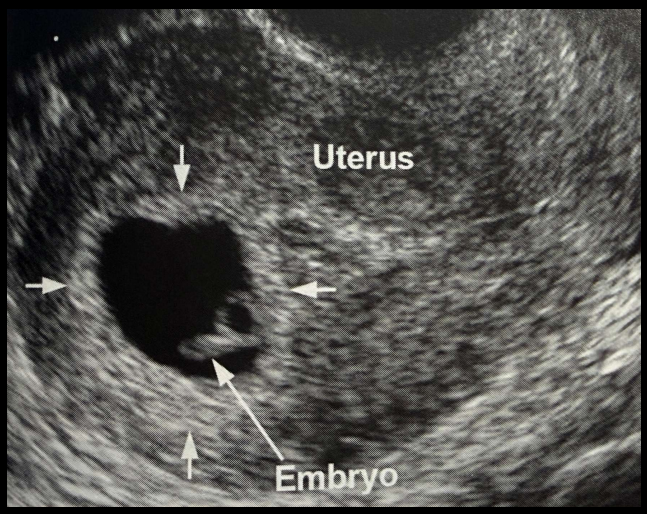

Source: Hagen-Ansert SL. Textbook of Diagnostic Sonography. 9th ed. Elsevier; 2023. Fig. 49.13. Used with permission.

Concerning for EPL

24

© Copyright. Society of Diagnostic Medical Sonography. All Rights Reserved.

MSD below threshold

Concern
MSD 16-24 mm & No Embryo



Source: Hagen-Ansert SL. Textbook of Diagnostic Sonography. 9th ed. Elsevier; 2023. Fig. 50.4-B. Used with permission.

Concerning for EPL

25

Expanded Amnion
Abnormal Yolk Sac

Concern
Enlarged Yolk Sac over 6 mm

Expanded amnion



Source: Hagen-Ansert SL. Textbook of Diagnostic Sonography. 9th ed. Elsevier; 2023. Fig. 50.4-C. Used with permission.

Concerning for EPL

26

© Copyright. Society of Diagnostic Medical Sonography. All Rights Reserved.

Other Early Pregnancy Considerations

Not every concerning first-trimester scan is an early pregnancy loss.

BLEEDING / SCH	Bleeding does not equal loss.
PUL	Location is not yet established.
ECTOPIC	Look deliberately outside the uterus.
β-hCG	Context—not a stand-alone diagnosis.

27

Bleeding Does Not Equal Loss: Subchorionic Hemorrhage

Hypoechoic collection extending along the placental margin/uterine wall



Source: Hagen-Ansert SL. Textbook of Diagnostic Sonography. 9th ed. Elsevier; 2023. Fig. 50.1-C. Used with permission.

Other EPL Considerations: Bleeding/SCH

28

© Copyright. Society of Diagnostic Medical Sonography. All Rights Reserved.

Pregnancy of Unknown Location (PUL)

Positive pregnancy test with no definite/probable IUP or ectopic pregnancy on TVUS

Possible explanations

- VERY EARLY IUP
- ECTOPIC PREGNANCY
- COMPLETED EPL

↓

FOLLOW-UP ESTABLISHES LOCATION + PROGRESSION

In a stable patient, uncertainty is not an invitation to force a diagnosis.

Other EPL Considerations: Unknown Location

29

Ectopic: What Can You Actually Demonstrate?

START WITH LOCATION

- ? Is there a definite intrauterine pregnancy?
- ? Were both ovaries identified?

INTERROGATE THE ADNEXA

- ? Were both tubal/adnexal regions deliberately evaluated?
- ? Is an adnexal mass separate from the ovary?
- ? Is there a definite extrauterine gestational sac / yolk sac / embryo?

ASSESS SUPPORTING FINDINGS

- ? Is there free fluid or hemoperitoneum?
- ? What does color Doppler add—and what does it not prove?

Describe what you can demonstrate. Don't let one sign do more diagnostic work than it can support.

Other EPL Considerations: Ectopic Pregnancy

30

© Copyright. Society of Diagnostic Medical Sonography. All Rights Reserved.

Don’t Skip the Adnexa

TRANSVERSE. UTERUS + OVARY. BOTH SIDES. EVERY TIME.

Document the relationship. Then make a deliberate sweep through each adnexa at the level of the broad ligament and expected tubal course.

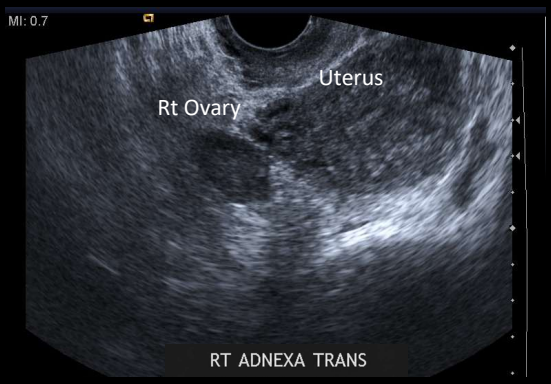

Source: K.E. Zale, personal teaching files.

Finding both ovaries does not complete the adnexal evaluation.

Other EPL Considerations: Ectopic Pregnancy

31

Tubal Ectopic Pregnancy

Tubal ectopic gestation and surrounding hyperechoic “tubal ring” (bagel sign).

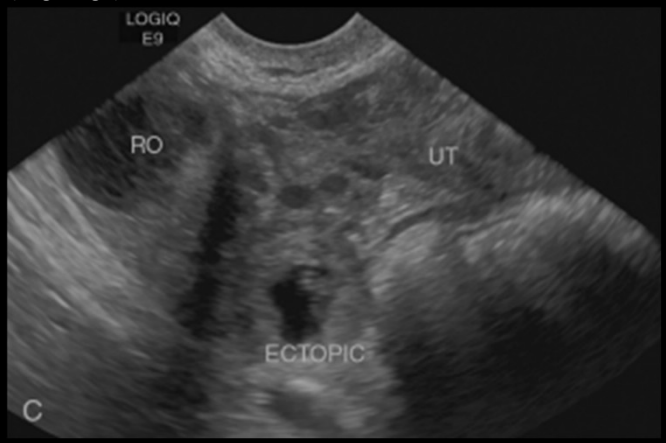

Source: Hagen-Ansert SL. Textbook of Diagnostic Sonography. 9th ed. Elsevier; 2023. Fig. 50.12-C. Used with permission.

Other EPL Considerations: Ectopic Pregnancy

32

© Copyright. Society of Diagnostic Medical Sonography. All Rights Reserved.

The "Ring of Fire"

HYPERVASCULARITY IS A CLUE - NOT A DIAGNOSIS.

Corpus luteum

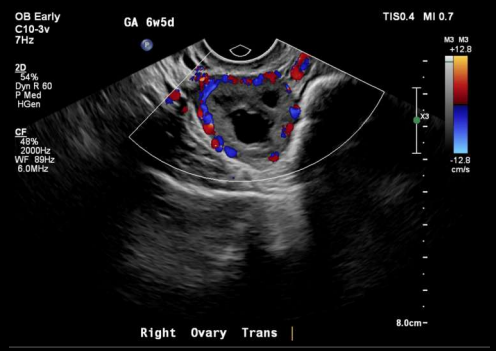

Source: Adams CP, Zabel A, Hannick V. Cureus. 2022;14(9):e29452. CC BY 4.0.

Ectopic pregnancy



Source: Hagen-Ansert SL. Textbook of Diagnostic Sonography. 9th ed. Elsevier; 2023. Fig. 50.11-C. Used with permission.

Both can demonstrate prominent peripheral vascularity.

Find the ovary. Find the mass. Establish their relationship.

Other EPL Considerations: Ectopic Pregnancy

33

Other Ectopic Pregnancy Locations

- Tubal is most common - but not the only location.

- Interstitial
- Cervical
- Cesarean scar
- Ovarian
- Abdominal
- Heterotopic (IUP + ectopic)

Heterotopic pregnancy



Arrows point to an intrauterine pregnancy (IUP) and to an ectopic cornual (C) or interstitial pregnancy.

NOTE: Interstitial ectopic pregnancy carries a particularly high risk of severe hemorrhage.

Cervical ectopic pregnancy



Sources: Hagen-Ansert SL. Textbook of Diagnostic Sonography. 9th ed. Elsevier; 2023. Fig. 50.16-A & C. Used with permission.

Other EPL Considerations: Ectopic Pregnancy

34

© Copyright. Society of Diagnostic Medical Sonography. All Rights Reserved.

One hCG Number Cannot Date a Pregnancy

Published reference ranges overlap substantially across gestational ages.

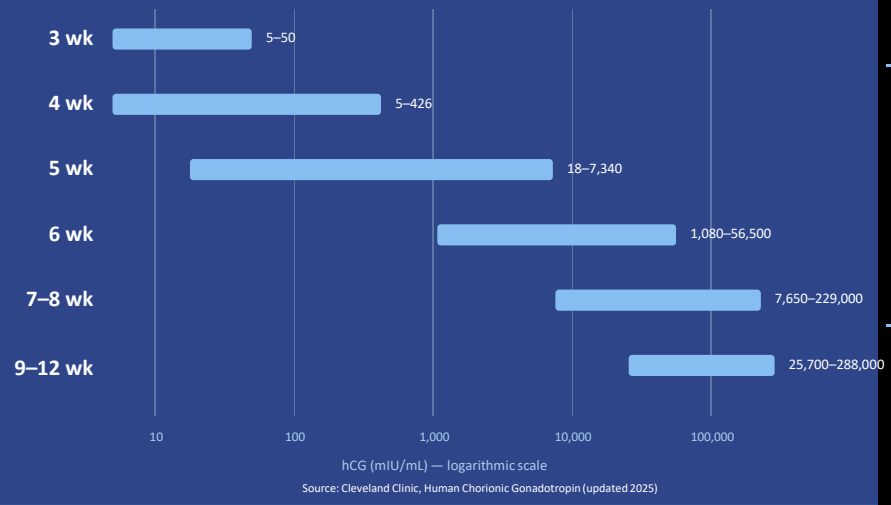

LOOK AT THE OVERLAP

30,000 mIU/mL
falls within published ranges for 6, 7–8, and 9–12 weeks

50,000 mIU/mL
also falls within published ranges for 6, 7–8, and 9–12 weeks

A single value cannot establish location, exact gestational age, or pregnancy progression.

hCG is context — not a verdict.

Other EPL Considerations: hCG

35

HOW WE RESPOND MATTERS, TOO.

The sonographer's role in communicating appropriately

36

© Copyright. Society of Diagnostic Medical Sonography. All Rights Reserved.

What Compassion Is - and Is Not

Compassion is not the same thing as reassurance.

NOT

- False reassurance
- Breaking scope
- Filling every silence
- Promising an outcome
- "I know exactly how you feel"

IS

- Presence
- Accuracy
- Respect
- Appropriate honesty
- Preserving dignity

37

Often, We Know Before the Patient Does

THE ROOM CHANGES.

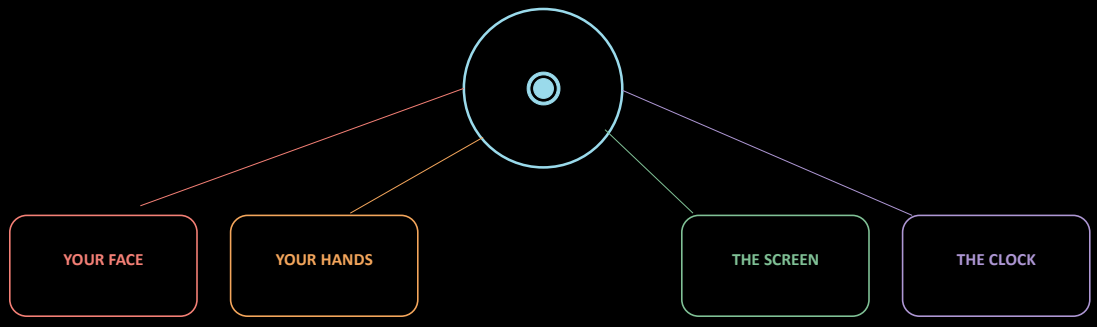

The patient may be watching all four.

38

© Copyright. Society of Diagnostic Medical Sonography. All Rights Reserved.

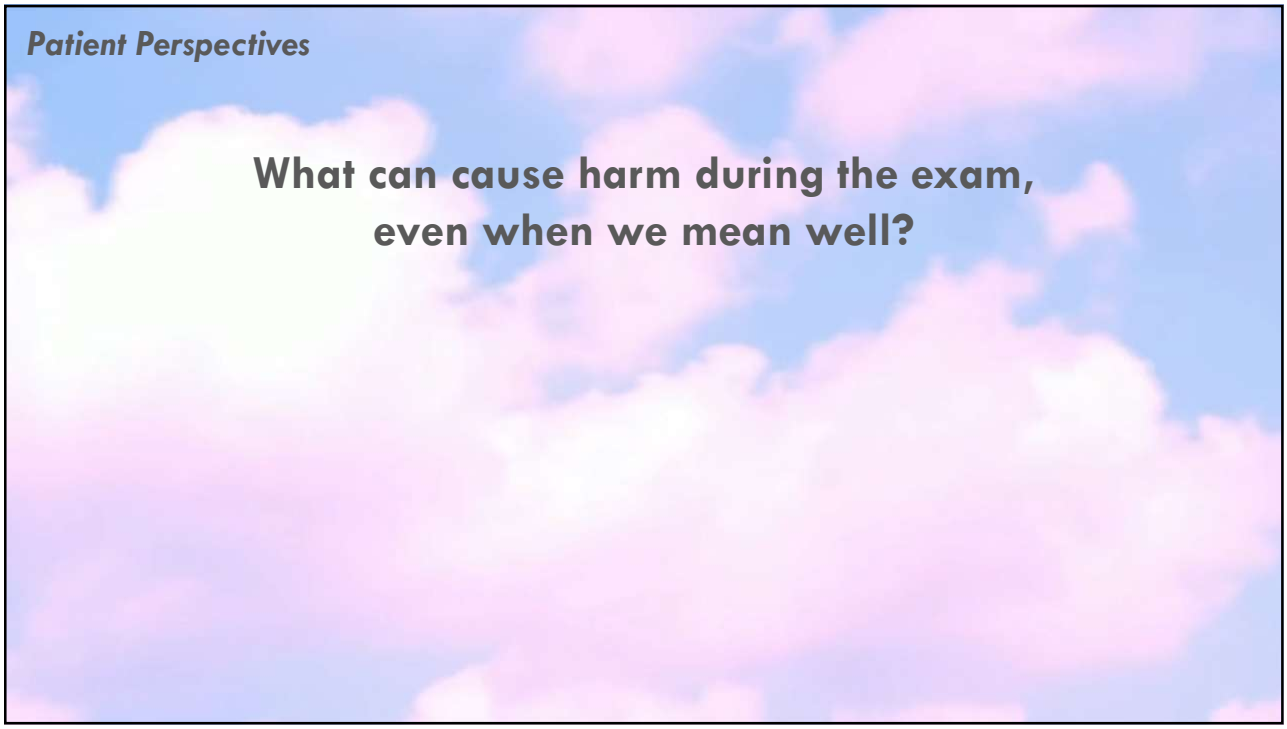

39

What We Should Stop Saying

"It's probably just too early."	when you do not know
"Everything looks fine."	before the study is complete
"Your numbers should double."	an absolute that oversimplifies
Outdated or blaming terminology	especially patient-facing
"At least…"	often minimizes the loss

40

© Copyright. Society of Diagnostic Medical Sonography. All Rights Reserved.

Silence Is Also Communication

PATIENTS INTERPRET WHAT WE DON'T SAY, TOO.

ABRUPT SILENCE

can be interpreted as bad news.

OVER-CHEERFULNESS

can feel discordant or dismissive.

LEAVING WITHOUT EXPLANATION

increases uncertainty.

Compassion often lives in the small things:

Tone. Pacing. Privacy. Tissues. Silence. Support.

41

What Can the Sonographer Say During the Exam?

"I need to take a few very careful measurements."

"I'm going to have the physician review these images."

"I know the waiting is difficult."

"I'm sorry this is taking longer than expected."

Acknowledge the process without overstepping scope.

42

© Copyright. Society of Diagnostic Medical Sonography. All Rights Reserved.

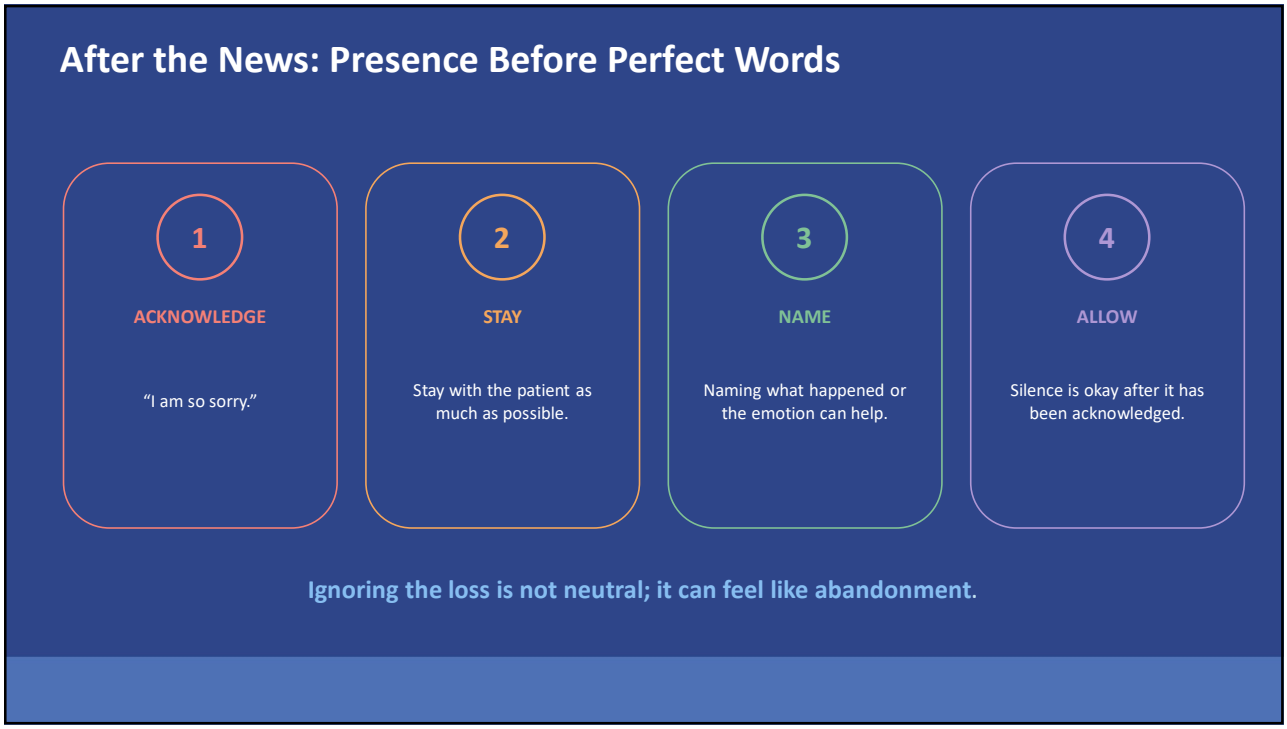

43



44

© Copyright. Society of Diagnostic Medical Sonography. All Rights Reserved.

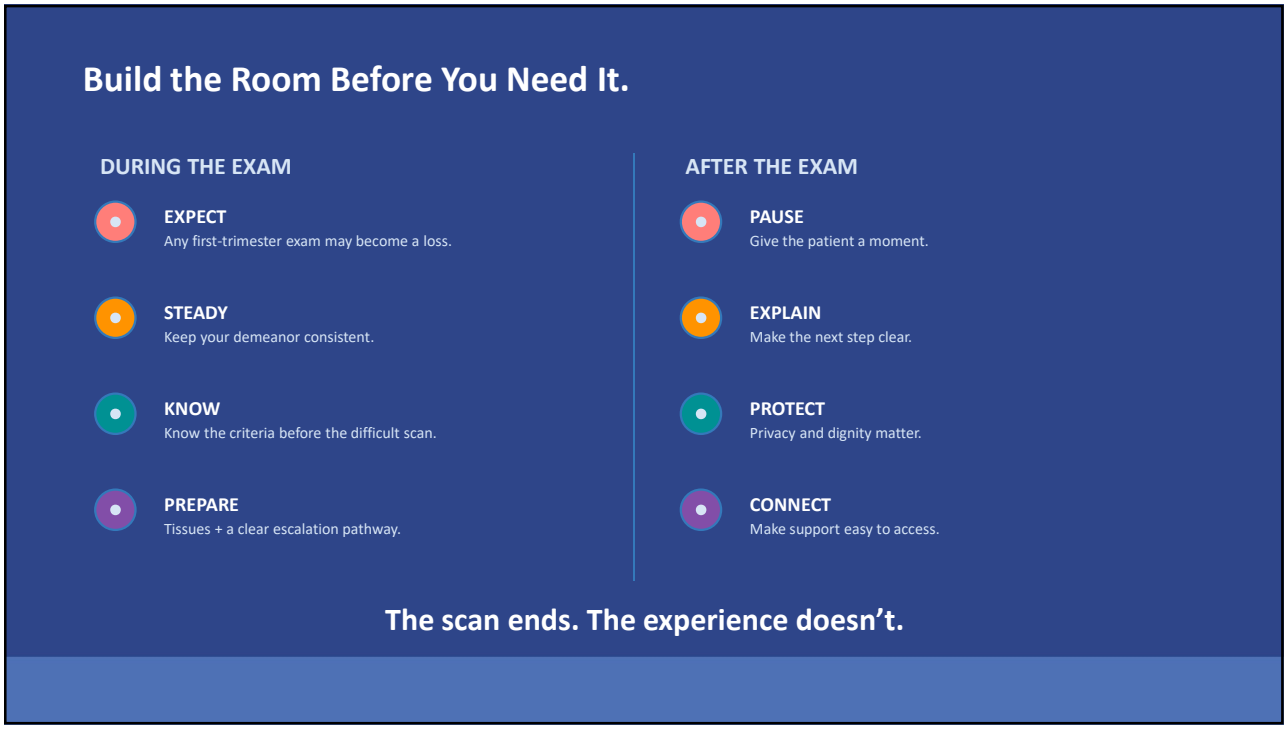

45



46

© Copyright. Society of Diagnostic Medical Sonography. All Rights Reserved.

Resources After Pregnancy Loss

Make support easy to find.

CHASING THE RAINBOWS

Pregnancy & infant loss support

Pregnancy-after-loss support

Peer connection / mentoring

Infertility support

www.chasingtherainbows.org

Support continues after the ultrasound room.

SCAN FOR PREGNANCY-LOSS RESOURCES

Chasing the Rainbows

Supporting & Uniting Baby Loss Survivors

SCAN HERE

Point your phone camera here to save the resources.

Also: Share Pregnancy & Infant Loss Support • Postpartum Support International • March of Dimes

47

What Can We Change Monday Morning?

CRITERIA	Keep definitive EPL criteria visible + standardized.
LANGUAGE	Update terminology to current SRU language.
hCG	Interpret trends in clinical and ultrasound context.
ESCALATION	Standardize borderline-measurement and limited-study pathways.
RESOURCES	Create a vetted pregnancy-loss resource card / QR sheet.
TEAM	Talk about what compassionate uncertainty sounds like.

Small systems changes make compassionate care reproducible.

48

© Copyright. Society of Diagnostic Medical Sonography. All Rights Reserved.

Our role isn't to promise the rainbow.

It's to care for the person standing in the rain.

What we see matters.

What we don't see matters.

How we respond matters, too.



49

Thank you.

Questions & Discussion

Kathryn E. Zale, MS, RDMS, RVT

50

© Copyright. Society of Diagnostic Medical Sonography. All Rights Reserved.

Selected References

Adams CP, Zabel A, Hannick V. Ring of Fire: The Case of Mistaken Identity. Cureus. 2022;14(9):e29452. doi:10.7759/cureus.29452.

American College of Obstetricians and Gynecologists. Early Pregnancy Loss. Practice Bulletin No. 200. Obstet Gynecol. 2018;132(5):e197–e207.

Barnhart KT. Early pregnancy failure: beware of the pitfalls of modern management. Fertil Steril. 2012;98(5):1061–1065.

Breanna. Personal interview with Kathryn E. Zale; 2026. Used with permission.

Doubilet PM, Benson CB, Bourne T, et al. Diagnostic criteria for nonviable pregnancy early in the first trimester. N Engl J Med. 2013;369(15):1443–1451. doi:10.1056/NEJMra1302417.

Hagen-Ansert SL. Textbook of Diagnostic Sonography. 9th ed. St. Louis (MO): Elsevier; 2023.

Haven L, Roe SJ. Educational Case: Ectopic pregnancy and its relation to pelvic infections. Acad Pathol. 2025;12(1):100168.

Murugan VA, Murphy BO, Dupuis C, Goldstein A, Kim YH. Role of ultrasound in the evaluation of first-trimester pregnancies in the acute setting. Ultrasonography. 2020;39(2):178–189. doi:10.14366/usg.19043.

Rodgers SK, Horrow MM, Doubilet PM, et al. A lexicon for first-trimester US: Society of Radiologists in Ultrasound consensus conference recommendations. Radiology. 2024;312(2):e240122. doi:10.1148/radiol.240122.

© Copyright. Society of Diagnostic Medical Sonography. All Rights Reserved.