# Rory's Story

A Missed TGA Diagnosis and the Critical Role of Knowing (and Trusting) Normal Fetal Heart Views

Kathryn E. Zale, MS, RDMS, RVT

1

## SPEAKER PRESENTATION DISCLAIMER

The content and views presented are made available for educational purposes only. The information presented are the opinions of the presenter and do not necessarily represent the views of the Society of Diagnostic Medical Sonography (SDMS) or its affiliated organizations, officers, Boards of Directors, or staff members.

The presenter is responsible for ensuring balance, independence, objectivity, scientific rigor, and avoiding commercial bias in their presentation. Before making the presentation, the presenter is required to disclose to the audience any relevant financial interests or relationships with manufacturers or providers of medical products, services, technologies, and programs.

The SDMS and its affiliated organizations, officers, Board of Directors, and staff members disclaim any and all liability for all claims that may arise out of the use of this educational activity.

2

© Copyright. Society of Diagnostic Medical Sonography. All Rights Reserved.

## GENERATIVE AI DISCLAIMER

The presenter utilized the use of large language models (LLMs) and generative artificial intelligence (AI) as a productivity tool to assist in drafting and refining content in this presentation.

While these tools can aid in structuring ideas, summarizing, paraphrasing, and language polishing, they have inherent limitations and cannot replace human creativity, critical thinking, or expert judgment. AI-generated content may contain errors, biases, or gaps in knowledge.

This presentation is intended for informational purposes only and should not be construed as definitive or authoritative guidance. Participants are encouraged to critically evaluate the information presented and consult relevant experts as needed. The SDMS and its affiliated organizations, officers, Board of Directors, and staff members disclaim any and all liability for claims that may arise from the use or interpretation of this educational material.

3

## Learning Objectives

- Identify essential fetal cardiac views, including outflow tract evaluation, to support accurate screening for transposition of the great arteries.
- Recognize common pitfalls in fetal heart imaging to improve diagnostic awareness and reduce missed findings.
- Apply a structured approach to evaluating normal fetal cardiac anatomy to enhance diagnostic accuracy in clinical practice.

4

© Copyright. Society of Diagnostic Medical Sonography. All Rights Reserved.

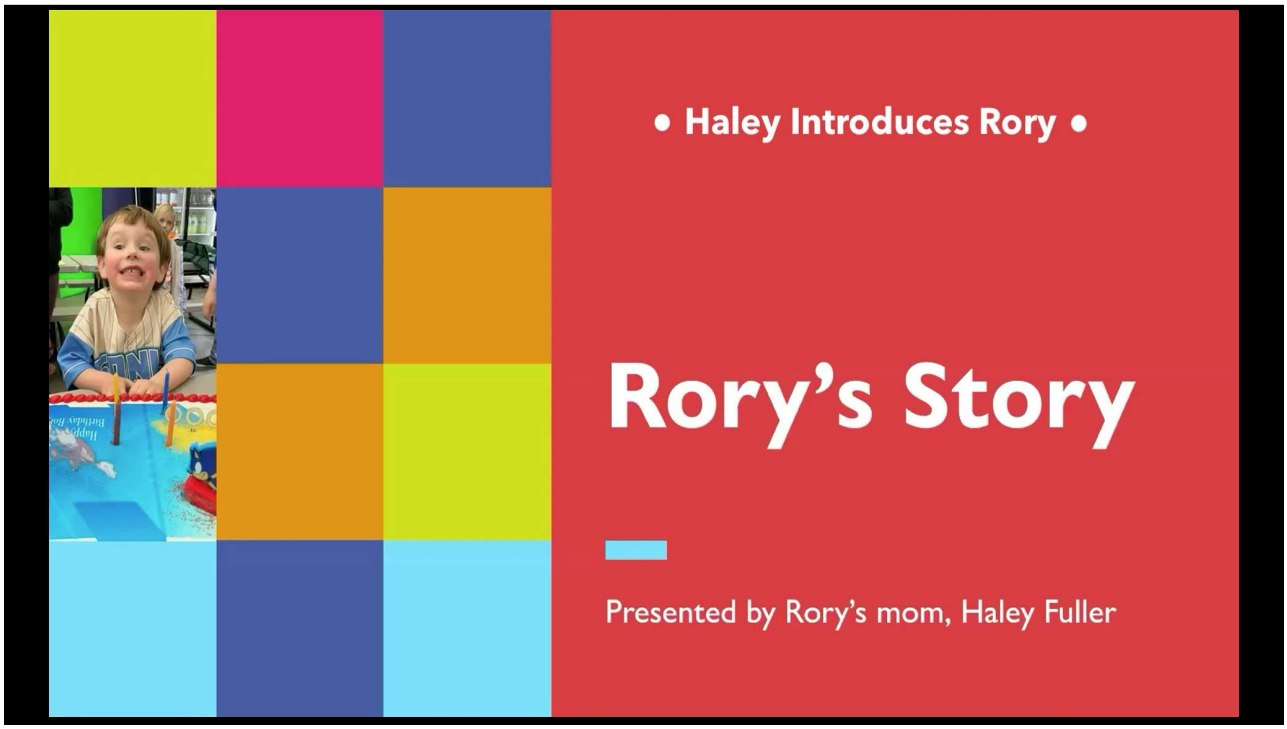


5

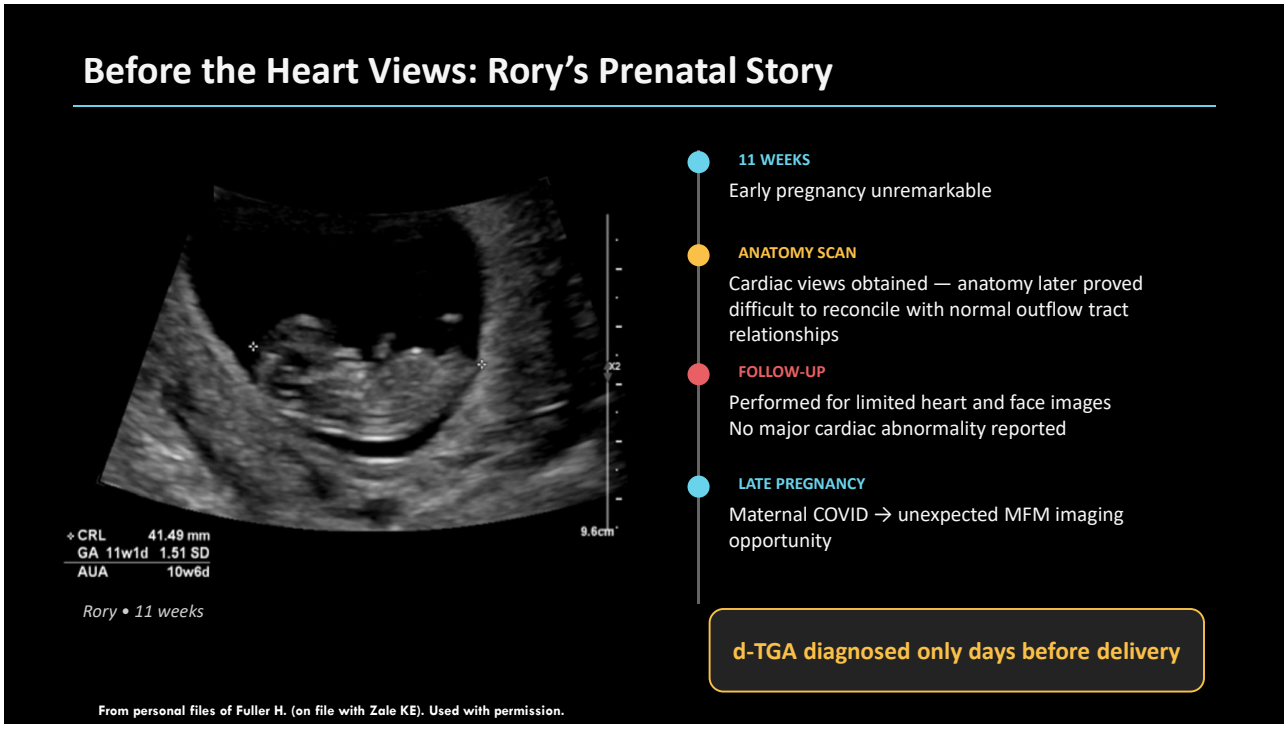


6

© Copyright. Society of Diagnostic Medical Sonography. All Rights Reserved.

## d-TGA: The Relationship That Matters

Rory had simple d-TGA — one discordance, two parallel circulations.

**d-TGA • dextro-TGA**

**AV CONCORDANT**

RA → RV • LA → LV

**VA DISCORDANT**

RV → Aorta • LV → Pulmonary artery

**SINGLE discordance**

**Great arteries run in PARALLEL**

Simple d-TGA: typically intact ventricular septum, without major associated cardiac abnormalities.

**L-TGA / ccTGA • Levo-TGA**

**AV DISCORDANT**

RA → LV • LA → RV

**VA DISCORDANT**

LV → Pulmonary artery • RV → Aorta

**DOUBLE discordance**

**Circulation remains in SERIES**

Useful contrast — but not Rory's anatomy.

**Sanity check: Which atrium → which ventricle → which great artery?**

7

## d-TGA: Why Mixing Matters

**Survival depends on mixing of the parallel circulations**

In utero, the FO and PDA permit mixing between the circulations.

**After Birth**

As fetal shunts become restrictive, mixing decreases and profound hypoxemia can develop rapidly.

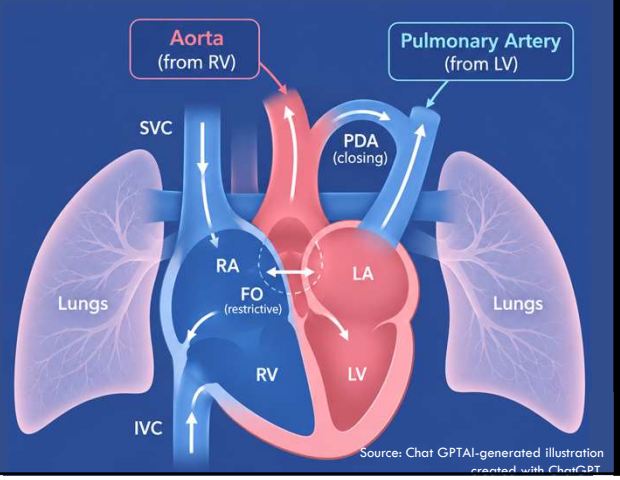


Source: Chat GPTAI-generated illustration created with ChatGPT

**Rory's Birth Story**

- Born via urgent C-section
- Apgar score: 1
- Profoundly cyanotic → immediate resuscitation
- Photos after resuscitation and on oxygen



**Rory after resuscitation and supplemental oxygen**

From personal files of Fuller H. (on file with Zale KE). Used with permission.

8

© Copyright. Society of Diagnostic Medical Sonography. All Rights Reserved.

# KNOW NORMAL

"You must know the normal to recognize the abnormal."

Normal is not the picture you expected to obtain.
**Normal is the anatomy you can demonstrate.**

"I got the view." ≠ "I demonstrated normal anatomy."



9

## Normal Starts Before the Four Chambers: SITUS

**Before interpreting the heart, prove orientation.**
One still image can anchor stomach + four-chamber position.

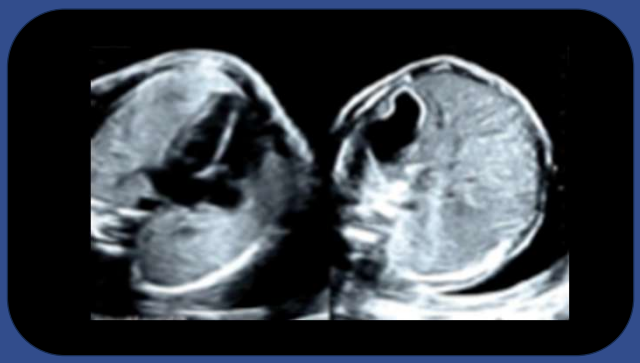

Source: Meagher S. ISUOG Fetal Cardiac Handbook, 2026. Used with permission.

**Orient First**

Fetal lie — cephalic or breech

Fetal spine — should be included in all cardiac images

**Then ask:**
**Are the stomach and cardiac apex on the expected fetal left?**

Confirm fetal right and left

10

© Copyright. Society of Diagnostic Medical Sonography. All Rights Reserved.

## SITUS: Rule of Thumb

**Palm on the spine • Fingers toward the anterior abdomen • Thumb identifies fetal left**

**CEPHALIC**

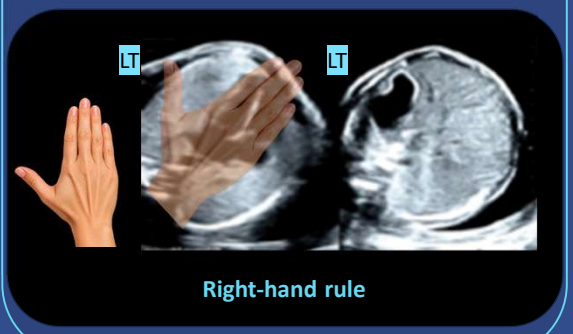


Right-hand rule

**BREECH**

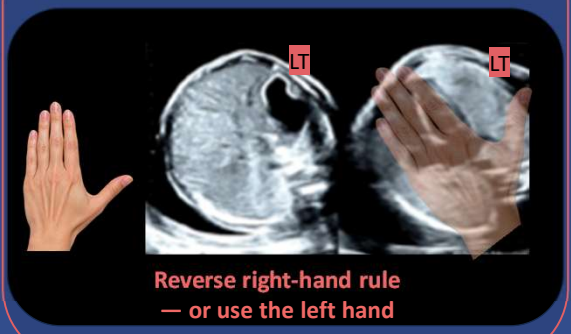


Reverse right-hand rule
— or use the left hand

Sources: Meagher S. ISUOG Fetal Cardiac Handbook, 2026. Used with permission.

11

REFERENCE SLIDE ONLY

## Four-Chamber (4CH) View

**In addition to situs/location, axis, and size**

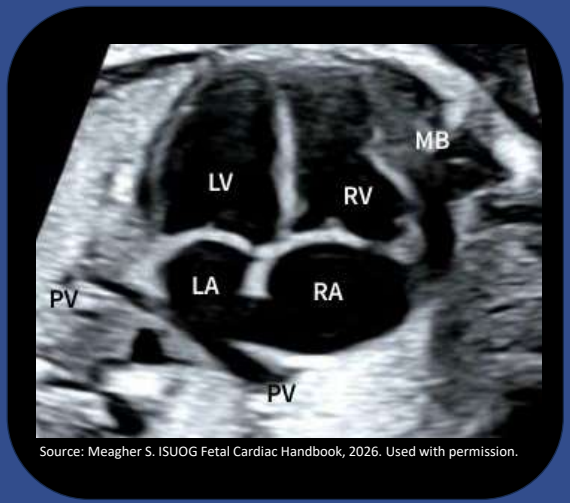


Source: Meagher S. ISUOG Fetal Cardiac Handbook, 2026. Used with permission.

- **Chamber Symmetry:** The two atria are roughly equal in size, and the two ventricles are roughly equal in size.
- **Atrial Septum & Foramen Ovale:** Flap of the foramen ovale opens into the left atrium.
- **Moderator Band:** In the apex of the right ventricle.
- **Septal Continuity:** Interventricular septum is contiguous.
- **AV Valve Offset:** Tricuspid valve (right side) inserts slightly closer to the apex than the mitral valve (left side).
- **Pulmonary Veins:** At least two pulmonary veins seen draining into the left atrium.
- **Heart Rate & Rhythm:** Normal, regular rhythm (120–160 bpm).

12

© Copyright. Society of Diagnostic Medical Sonography. All Rights Reserved.

## 4CH: Optimize 2D Imaging

REFERENCE SLIDE ONLY

**Optimize grayscale first — before adding Color Doppler.**

**1 SIZE THE HEART**

Reduce depth • Narrow sector width
Magnify so the heart occupies most of the screen

**2 RESOLUTION**

Use the highest practical frequency
Harmonics as needed • Speckle reduction/compound imaging as appropriate

**3 FOCUS + CONTRAST**

Single focal zone at the level of interest
Adjust overall gain • Use dynamic range to optimize tissue contrast

**4 PRESERVE MOTION**

Low persistence • Keep frame rate high
Narrow sector + reduced depth to help preserve temporal resolution

**Goal: maximize spatial + temporal resolution before deciding whether anatomy is normal.**

13

## 4CH: Optimize Color Doppler

REFERENCE SLIDE ONLY

**And routinely utilize in the second trimester**

- **Optimize grayscale first**
- **Smallest color box possible**
- **Set PRF first**
  - **1st Tri (25-35 cm/sec)**
  - **2nd Tri (55-65 cm/sec)**
  - **3rd Tri (65-75 cm/sec)**
- **Power output (increase/decrease)**
- **Color gain (increase/decrease)**
- **Wall Filter: 1st Tri (low), 2nd Tri (mid)**



4CH View with proper color Doppler settings

Source: Meagher S. ISUOG Fetal Cardiac Handbook, 2026. Used with permission.

*Be sure to follow ALARA principles.*

14

© Copyright. Society of Diagnostic Medical Sonography. All Rights Reserved.

## Why TGA is a Screening Trap:

- **Normal 4CH View:** In simple d-TGA, the 4-chamber view is reassuringly normal.
- **The Great Escape:** Outflow tract abnormalities do not affect the chambers in utero because the fetal circulation is shunted. This contributes to making d-TGA a classic screening trap.
- **The Screening Mandate:** Sonographers cannot rely on a reassuring 4CH view to exclude transposition. The screening task is strictly relational: evaluating origin, branching, crossover, and spatial arrangement.

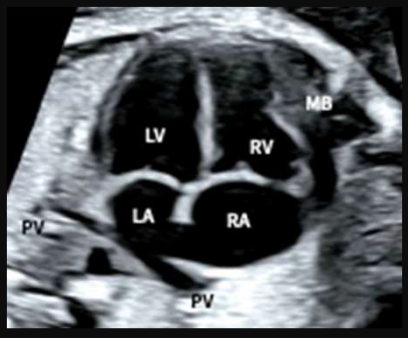


Source: Meagher S. ISUOG Fetal Cardiac Handbook, 2026. Used with permission.

15




16

© Copyright. Society of Diagnostic Medical Sonography. All Rights Reserved.

## First Opportunity: The Anatomy Scan

- 10/22/2021, 20w6d.
- Indication: Anatomy Survey
- 4CH, LVOT, and RVOT documented as imaged.
- Report: Limited heart and face views. Follow-up recommended.

17

## Rory: First Opportunity — Start With Situs

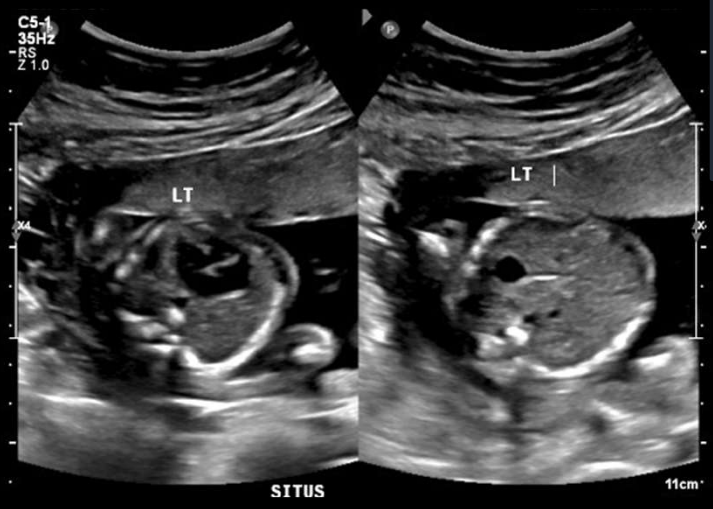





Rory is vertex

From personal files of Fuller H. (on file with Zale KE). Used with permission.

18

© Copyright. Society of Diagnostic Medical Sonography. All Rights Reserved.

## Four-Chamber View Attempts




- Taken by an early-career sonographer
- Notice ribs are oblique
- Image 1 is cropped for presentation
- Image 2 shows the original scan is not as zoomed in




From personal files of Fuller H. (on file with Zale KE). Used with permission.

19

## A Reassuring Four-Chamber View Can Be True — and Incomplete




- Notice ribs are no longer oblique
- Anatomy is more zoomed in and more reassuring

From personal files of Fuller H. (on file with Zale KE). Used with permission.

20

© Copyright. Society of Diagnostic Medical Sonography. All Rights Reserved.

## The Image That Did Not Make Sense

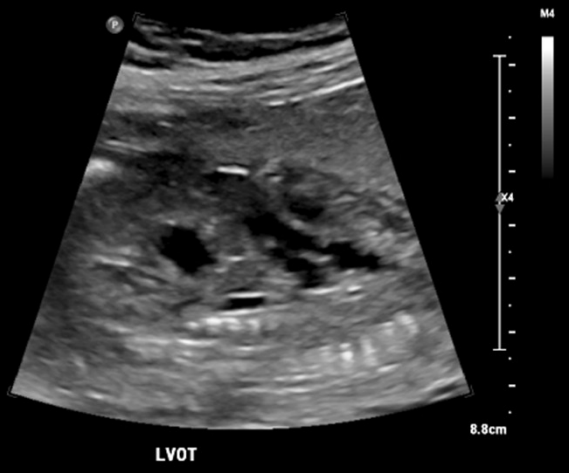


**Intended Left Ventricular Outflow Tract (LVOT)**

- But the vessel branches
- Branching identifies pulmonary artery—not aorta
- The image may be better than the sonographer thought
- The mismatch between expectation and anatomy is the clue

From personal files of Fuller H. (on file with Zale KE). Used with permission.

21

## LVOT: Followed Correctly, but There is Doubt

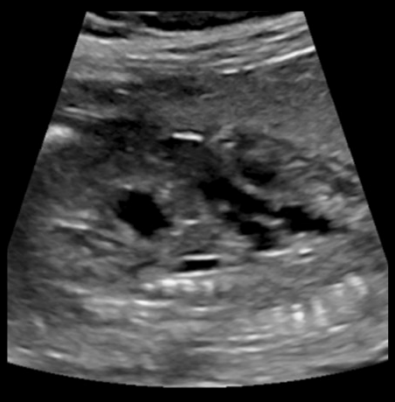


From personal files of Fuller H. (on file with Zale KE). Used with permission.




Source: Meagher S. ISUOG Fetal Cardiac Handbook, 2026. Used with permission.

LVOT

1. Which ventricle does it leave?

2. Where does it go?

3. Does it cross the other great artery?

4. Does it continue into the aortic arch?

22

© Copyright. Society of Diagnostic Medical Sonography. All Rights Reserved.

## More LVOT Attempts

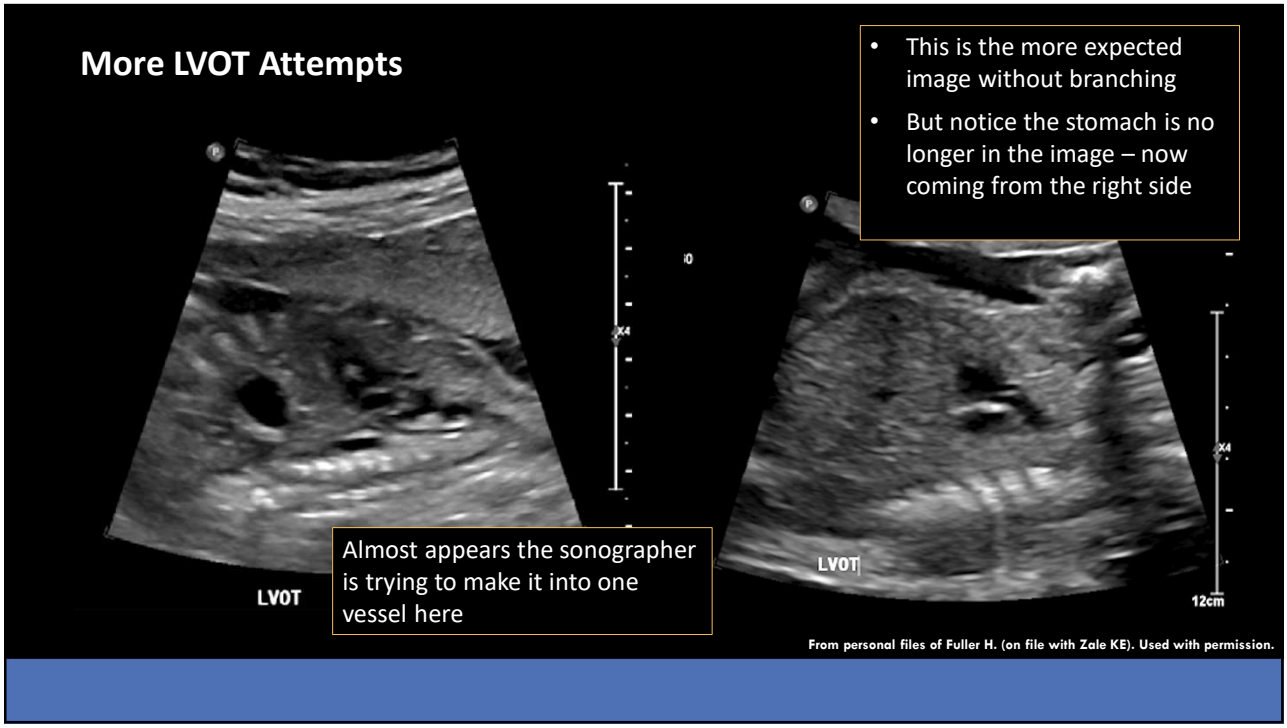


- This is the more expected image without branching
- But notice the stomach is no longer in the image – now coming from the right side

Almost appears the sonographer is trying to make it into one vessel here

From personal files of Fuller H. (on file with Zale KE). Used with permission.

23

## RVOT Attempts

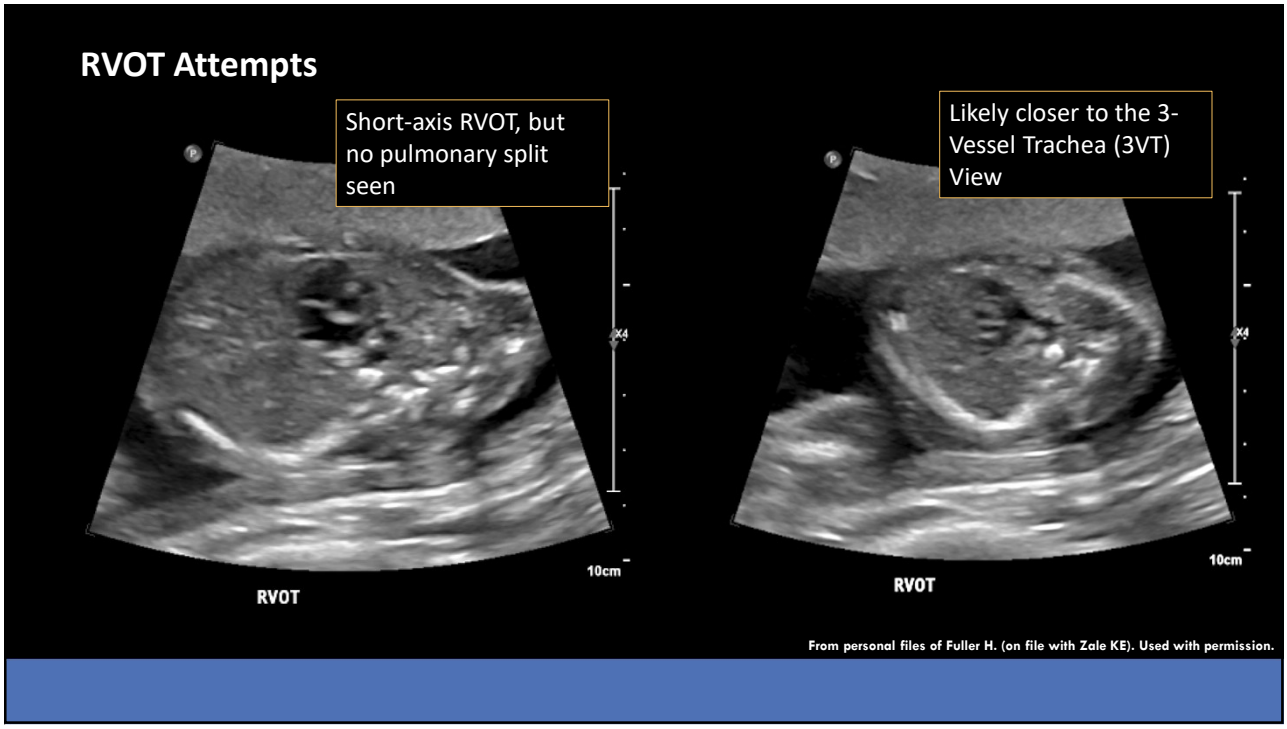


Short-axis RVOT, but no pulmonary split seen

Likely closer to the 3-Vessel Trachea (3VT) View

From personal files of Fuller H. (on file with Zale KE). Used with permission.

24

© Copyright. Society of Diagnostic Medical Sonography. All Rights Reserved.

## RVOT: Short-Axis View

- Missing the split of the main pulmonary artery (MPA) into the ductus arteriosus (DA) and right pulmonary artery (RPA)
- Instead seeing a single vessel, which is the ascending aorta (AAo)

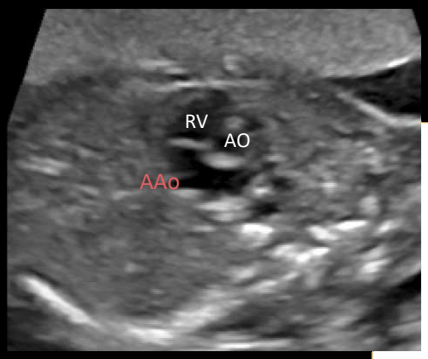


From personal files of Fuller H. (on file with Zale KE). Used with permission.

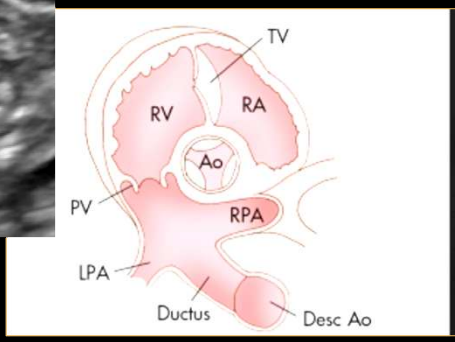


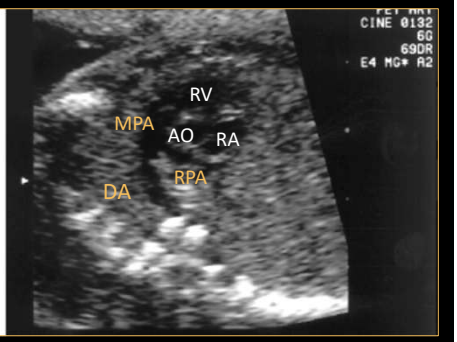


Source: Hagen-Ansert SL. Textbook of Diagnostic Sonography. 9th ed. Elsevier; 2023. Fig. 35.29-C. Used with permission.

25

## RVOT Long-Axis View/3VV?

- At first glance, may imagine a split of the main vessel
- However, would put the aorta on the right side
- Color Doppler would help distinguish if same vessel, but most likely one




From personal files of Fuller H. (on file with Zale KE). Used with permission.




Three-Vessel View (3VV) View: Normal Relationship

Source: Meagher S. ISUOG Fetal Cardiac Handbook, 2026. Used with permission.

26

© Copyright. Society of Diagnostic Medical Sonography. All Rights Reserved.

## Likely a Three-Vessel Trachea View




From personal files of Fuller H. (on file with Zale KE). Used with permission.

- Ductus and Aorta are not coming together left of the spine in a normal "V" configuration
- Likely the 3-Vessel Trachea (3VT) View

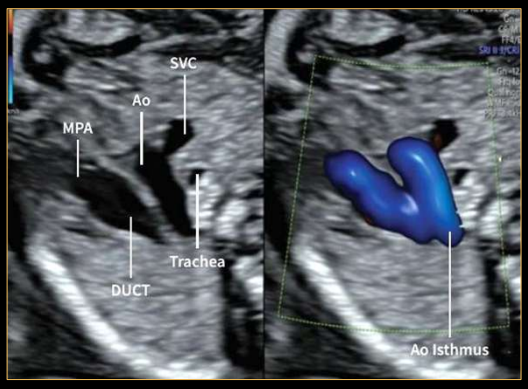


3VT View: Normal Relationship

Source: Meagher S. ISUOG Fetal Cardiac Handbook, 2026. Used with permission.

27

## 3VT View – The "Boomerang" Sign?

- Likely see the trachea (T); see arrow
- Again, vessels are not forming a "V" left of the aorta/spine
- May represent the "boomerang" sign – which shows (oftentimes) a single vessel arching away from midline towards the right side
- That vessel is the pulmonary artery
- In this case, possible to see the pulmonary split, if slightly below the 3VT view or slightly oblique to the normal 3VT view

Shown on a breech fetus



Source: Meagher S. ISUOG Fetal Cardiac Handbook, 2026. Used with permission.

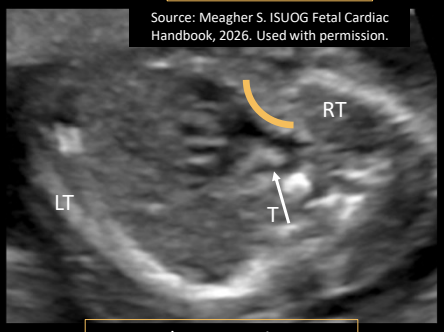


Remember: Rory is vertex

From personal files of Fuller H. (on file with Zale KE). Used with permission.

28

© Copyright. Society of Diagnostic Medical Sonography. All Rights Reserved.

## RVOT to Sagittal View by Following the Vessel

- Rotated properly from the right ventricle
- Now in a sagittal plane showing the classic “candy cane” aortic arch
- Head vessels clearly seen
- Color Doppler helpful to identify them

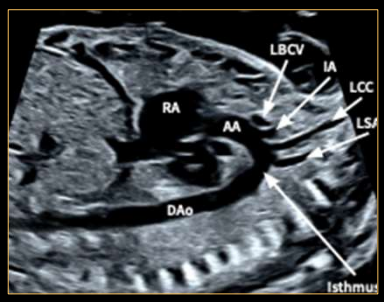


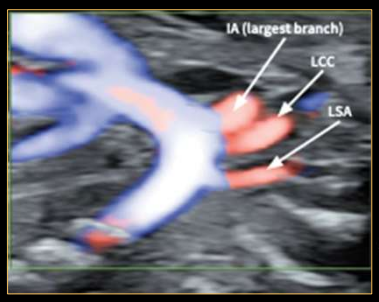


Source: Meagher S. ISUOG Fetal Cardiac Handbook, 2026. Used with permission.




From personal files of Fuller H. (on file with Zale KE). Used with permission.

*Don’t just get a candy-cane arch. Prove where that candy cane came from.*

29

## TRUST THE **PAUSE**

The pause is active clinical data.

**“This does not look like what I expected.”**

That sentence is not failure.
**It is information.**

**TRUST → VERIFY → ESCALATE**



When expectation and anatomy disagree, the mismatch deserves attention.

30

© Copyright. Society of Diagnostic Medical Sonography. All Rights Reserved.

## What Should Happen at the Pause?

**Actionable Workflow**

**1. TRUST THE MISMATCH**

"This does not look like what I expected"

is clinical data.

Don't explain away anatomy that doesn't fit.

**2. VERIFY**

Optimize. Reacquire. Change planes.

Prove origin + branching + continuity + crossover.

**3. ESCALATE**

Document what you cannot prove.

Bring in another set of eyes.

Follow departmental escalation pathways.

31




32

© Copyright. Society of Diagnostic Medical Sonography. All Rights Reserved.

## Second Opportunity: The Follow-Up

- 11/8/2021, 23w2d.
- Indication: limited heart and face pictures on the prior study.
- 4CH and RVOT documented as imaged.
- Report: isolated LV echogenic intracardiac focus; otherwise no sonographic abnormalities.

33

## Second Opportunity: Again, the 4CH Heart Looks Reassuring




Still in a cephalic lie

From personal files of Fuller H. (on file with Zale KE). Used with permission.

34

© Copyright. Society of Diagnostic Medical Sonography. All Rights Reserved.

## Second Opportunity: Again, the 4CH Heart Looks Reassuring

Only an echogenic intracardiac focus in the left ventricle is noted

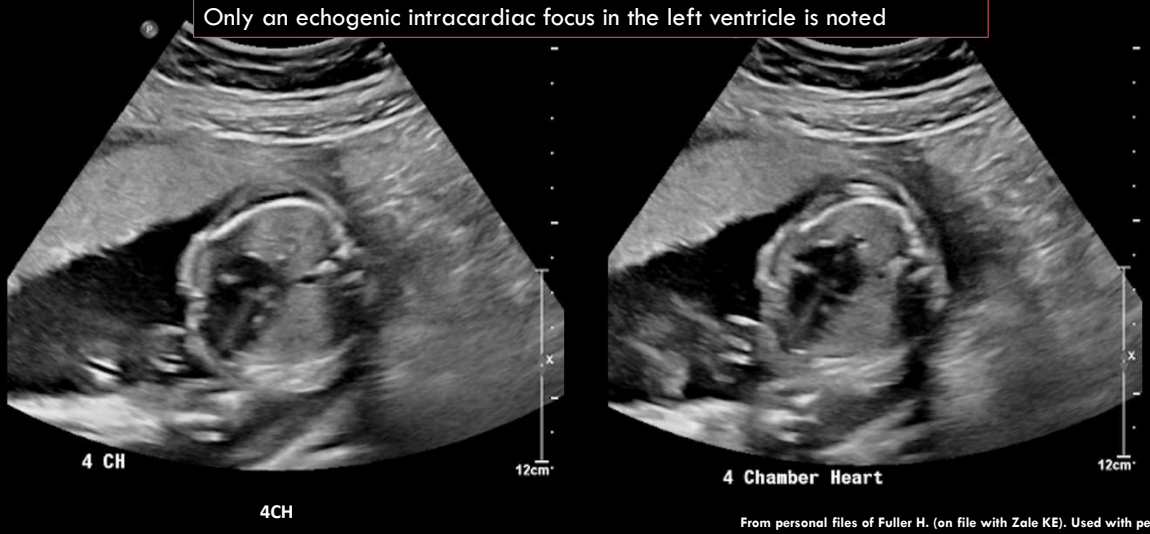


4CH

From personal files of Fuller H. (on file with Zale KE). Used with permission.

35

## Another RVOT Attempt

- Oblique view, see a split, but no clues of the vessel followed
- Normally, would expect the split to be coming back towards the spine







Source: Meagher S. ISUOG Fetal Cardiac Handbook, 2026. Used with permission.

From personal files of Fuller H. (on file with Zale KE). Used with permission.

36

© Copyright. Society of Diagnostic Medical Sonography. All Rights Reserved.

## Another RVOT Attempt

Again, see part of the RVOT, but not the expected pulmonary split







From personal files of Fuller H. (on file with Zale KE). Used with permission.

37

## Another RVOT Attempt

- The "Boomerang" Sign again?
- At the level between the Long-Axis RVOT and the 3VT View?




Follow-Up Study Image of the RVOT




Initial Anatomy Scan Study of the RVOT

From personal files of Fuller H. (on file with Zale KE). Used with permission.

38

© Copyright. Society of Diagnostic Medical Sonography. All Rights Reserved.

## What the Record Can — and Cannot — Tell Us

- It can tell us why the patient returned and which views were documented.
- It can tell us the final interpretation.
- It cannot tell us every dynamic plane seen during the examination.
- It cannot reliably tell us what an individual sonographer suspected or felt.

39




40

© Copyright. Society of Diagnostic Medical Sonography. All Rights Reserved.

## A Miss Is Rarely One Hole

Rory's case had multiple places where the chain could have been interrupted.

| | | |
|---|---|---|
| 1 | ACQUISITION | Diagnostic anatomy was present. |
| 2 | RECOGNITION | Something did not fit expected normal anatomy. |
| 3 | VERIFICATION | The mismatch was not resolved. |
| 4 | COMMUNICATION / ESCALATION | A concern only helps if it is communicated. |
| 5 | SYSTEM / PROTOCOL | Screening standards and required views matter. |

**Each layer is another opportunity to catch the miss.**

*Experience should refine uncertainty, not silence it.*

41

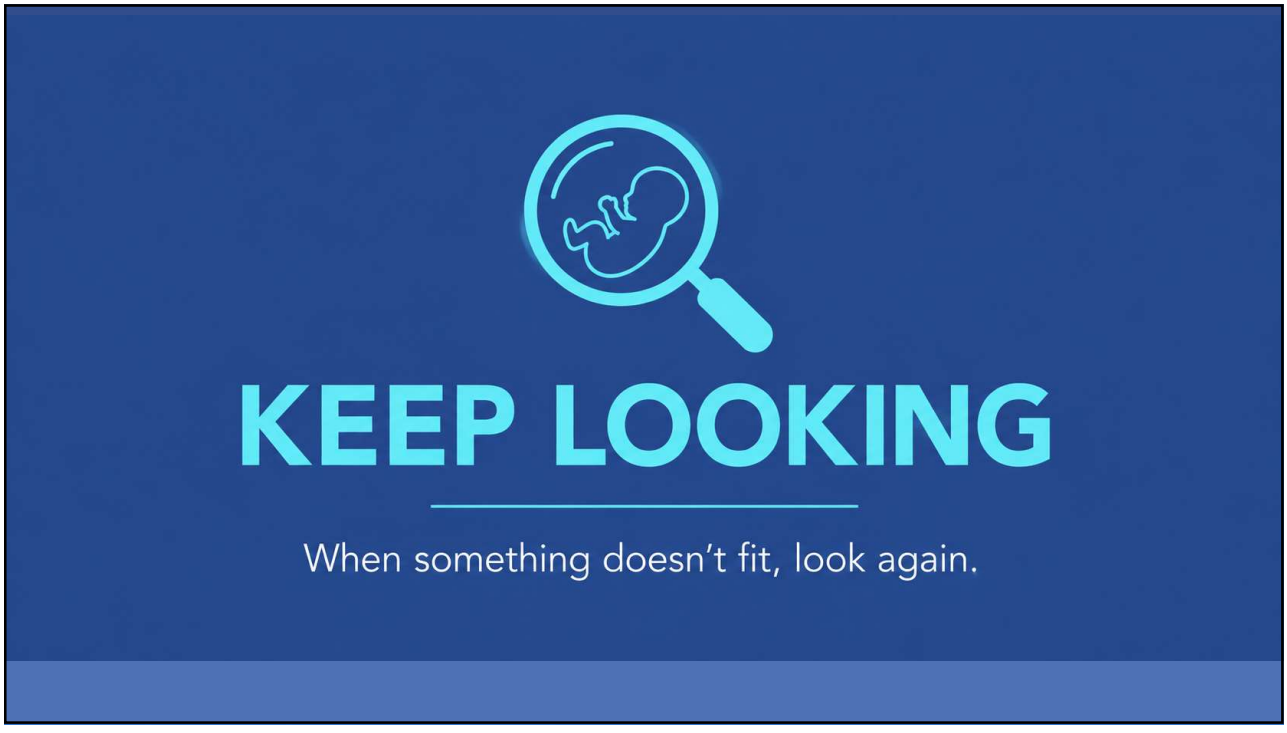


42

© Copyright. Society of Diagnostic Medical Sonography. All Rights Reserved.

## Sixteen Weeks Later: An Unexpected Third Opportunity

- 02/15/2022, 37w3d.
- This MFM study was prompted by Haley having COVID late in pregnancy—not by a suspected fetal heart defect.
- In other words, the third prenatal opportunity to see Rory's heart was incidental.
- During that broader MFM examination, the cardiac finding prompted escalation and physician review.
- The anatomy had not suddenly changed. The care pathway had.

43

## Cephalic lie




Still vertex, head down

Late MFM study, 37w3d

From personal files of Fuller H. (on file with Zale KE). Used with permission.

44

© Copyright. Society of Diagnostic Medical Sonography. All Rights Reserved.

## Situs

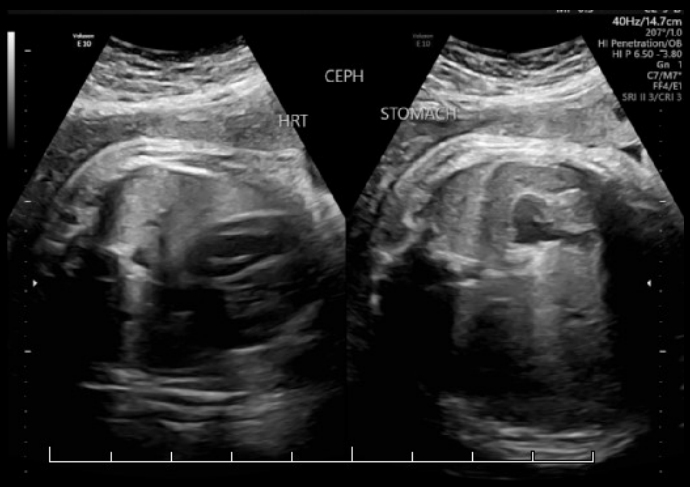


Normal situs – situs solitus

Late MFM study, 37w3d

From personal files of Fuller H. (on file with Zale KE). Used with permission.

45

## Basal Four-Chamber View

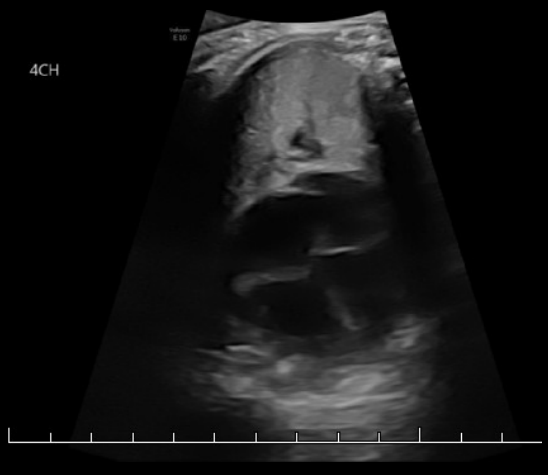


Normally this view may provide better image of the pulmonary veins draining into the left atrium but limited by late pregnancy

From personal files of Fuller H. (on file with Zale KE). Used with permission.

46

© Copyright. Society of Diagnostic Medical Sonography. All Rights Reserved.

## Parasternal Four-Chamber View



This view gives a clearer view of the interventricular septum, which is intact

From personal files of Fuller H. (on file with Zale KE). Used with permission.

47

## Apical Four-Chamber View

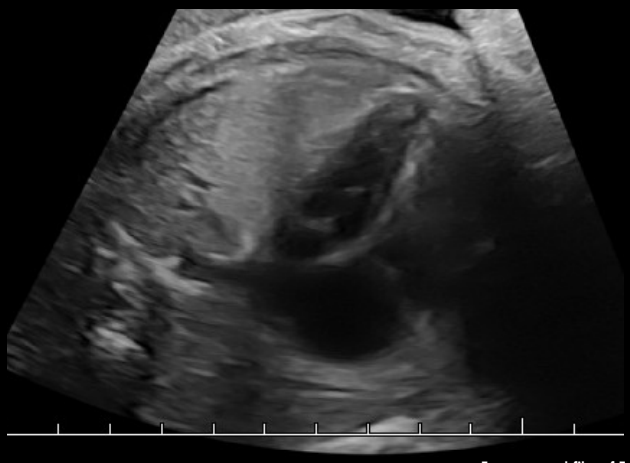

- Pulmonary vein seen leading from the left atrium, as normal
- So far, everything appears normal

From personal files of Fuller H. (on file with Zale KE). Used with permission.

48

© Copyright. Society of Diagnostic Medical Sonography. All Rights Reserved.

## LVOT Attempts

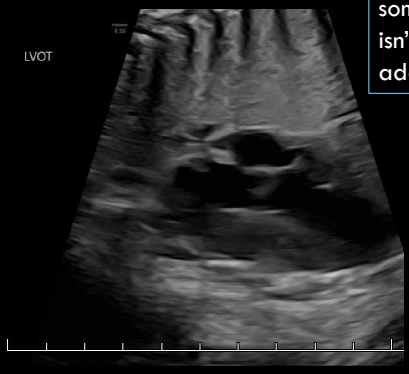


First LVOT attempt, something isn't quite adding up

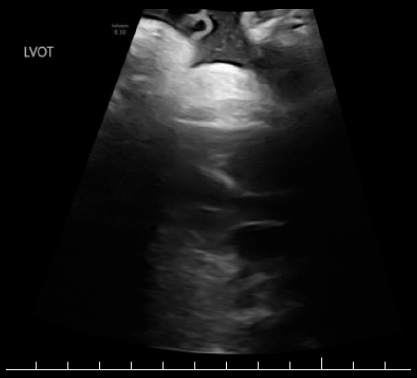


Another attempt from another angle, but limited

From personal files of Fuller H. (on file with Zale KE). Used with permission.

49

## IVC

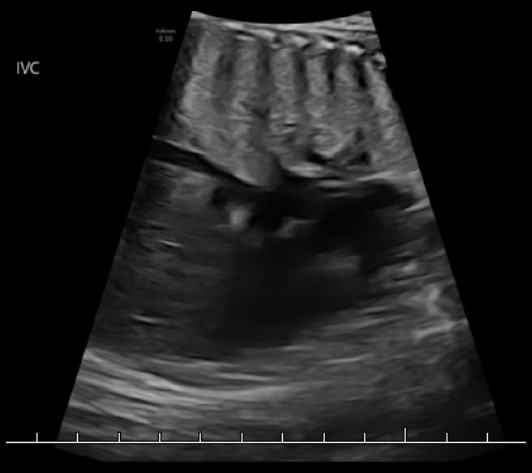


Note: Venous return remains normal and unchanged in TGA

From personal files of Fuller H. (on file with Zale KE). Used with permission.

50

© Copyright. Society of Diagnostic Medical Sonography. All Rights Reserved.

## Ductal Arch?

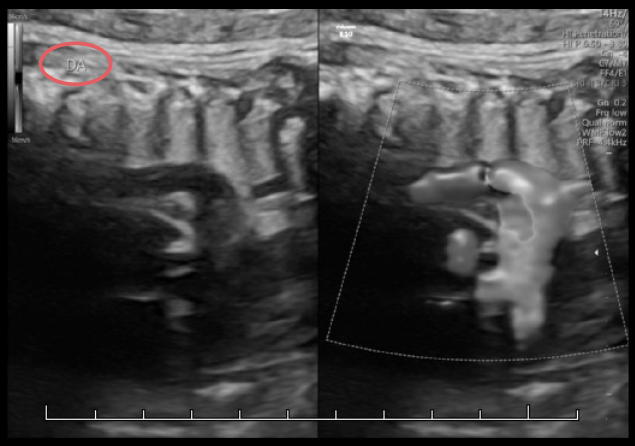


- Adding color Doppler gave the sonographer pause
- Now seeing more clearly the head vessels in what should be the ductal arch

From personal files of Fuller H. (on file with Zale KE). Used with permission.

51

## Nope. It's the Aortic Arch




- Same view, now a different label
- And getting closer to a diagnosis

From personal files of Fuller H. (on file with Zale KE). Used with permission.

52

© Copyright. Society of Diagnostic Medical Sonography. All Rights Reserved.

## Oblique Longitudinal Views

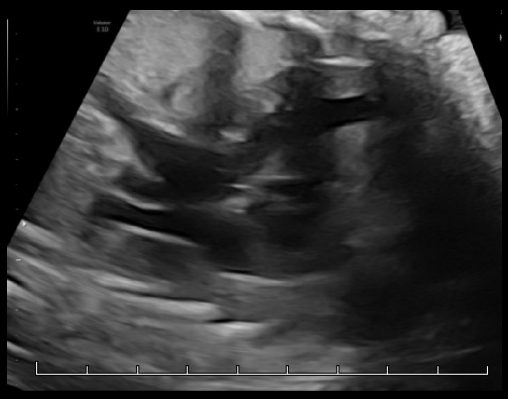

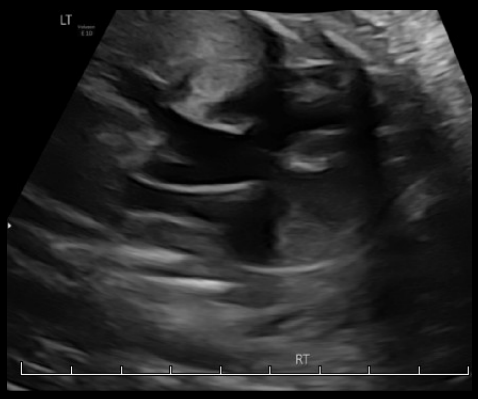


Most likely an attempt to obtain the RVOT

Now reconcile the anatomy:

WHAT IS NOT NORMAL?

From personal files of Fuller H. (on file with Zale KE). Used with permission.

53

## Parallel course of the great arteries in d-TGA

Oblique longitudinal view = not just two arteries, but that they don't cross!

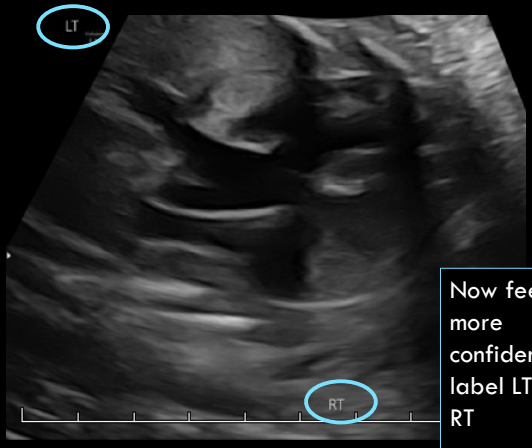


Now feeling more confident to label LT and RT

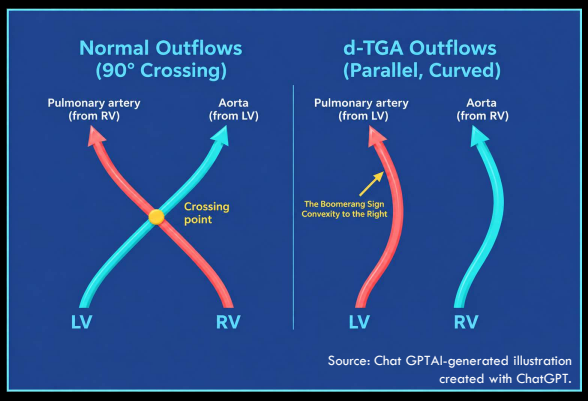


From personal files of Fuller H. (on file with Zale KE). Used with permission.

54

© Copyright. Society of Diagnostic Medical Sonography. All Rights Reserved.

## What Rory's Images Teach Us

- A normal appearing four-chamber view does not exclude TGA.
- Outflow and great-vessel views must demonstrate relationships, not merely produce images.
- If anatomy does not match what you expect, pause, optimize, and prove it.
- If you cannot demonstrate normal, you have not demonstrated normal.

Suggested takeaway: Create a reproducible sequence
situs/axis → 4CH → LVOT → RVOT → 3VV/3VT → confirm normal great-vessel relationship.

55




56

© Copyright. Society of Diagnostic Medical Sonography. All Rights Reserved.

## The Diagnosis Was Only the Beginning

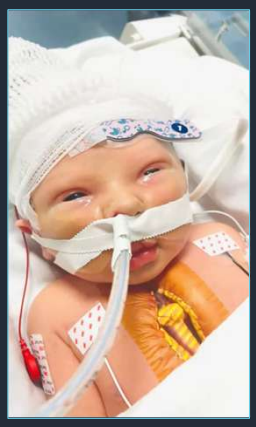

Rory after his LaCompte (arterial switch) Procedure

**2 DAYS OLD**

**Arterial switch operation**

**POSTOPERATIVE COURSE**

Cardiac arrest • open chest
prolonged hospitalization

**AND THEN…**

**Rory's journey continued.**

From personal files of Fuller H. (on file with Zale KE). Used with permission.

57

## Rory Today: A Lifelong Journey




**Rory is doing well.**

**But "repaired" does not mean "finished."**

- Ongoing cardiology surveillance
- OT • PT • speech / neurodevelopmental follow-up
- Future cardiac intervention anticipated

**CHD & NEURODEVELOPMENT**

**~2× higher odds of autism • ~3× higher odds of ADHD**

Risk is multifactorial.

From personal files of Fuller H. (on file with Zale KE). Used with permission.

58

© Copyright. Society of Diagnostic Medical Sonography. All Rights Reserved.

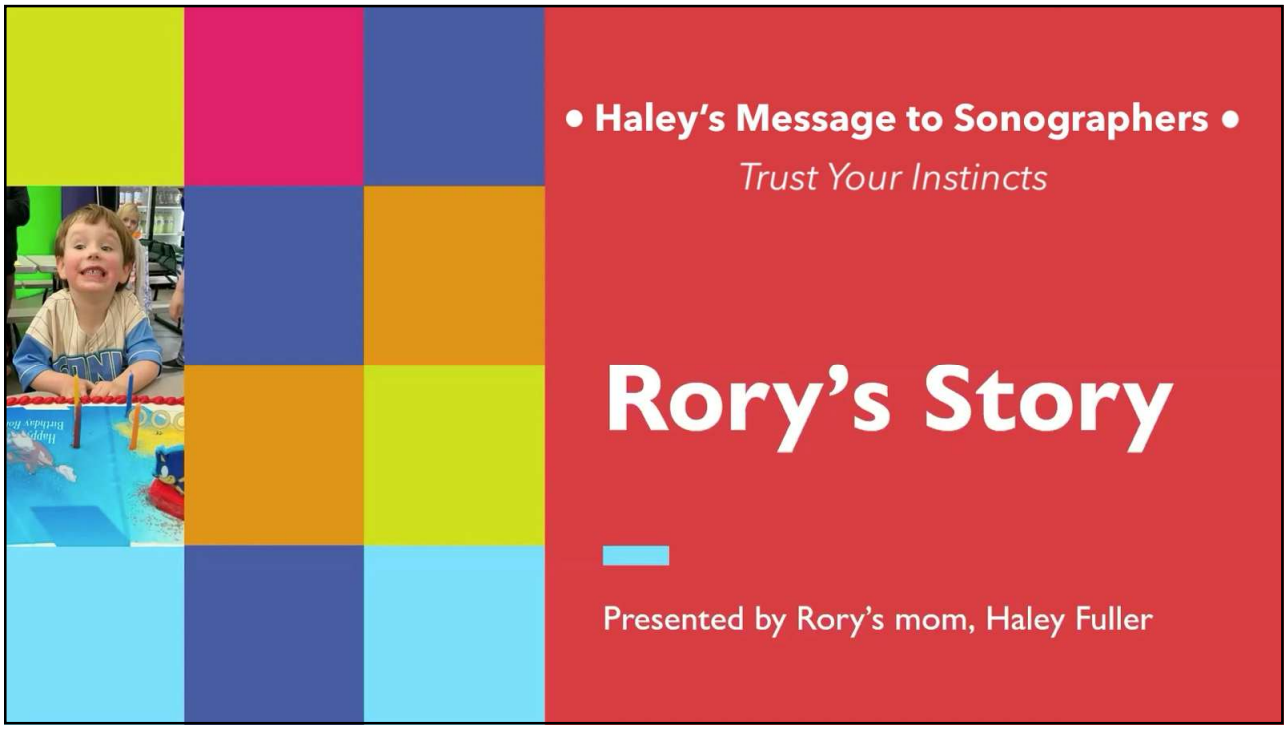


59

## Take-Home

**Know normal.**

**Trust the mismatch.**

**Verify what you see.**

**Speak when something doesn't fit.**

**The pause is data.**

Rory's story reminds us why it matters.

60

© Copyright. Society of Diagnostic Medical Sonography. All Rights Reserved.

## Fetal Cardiac Screening Resources

*Keep learning. Keep proving normal.*

**ISUOG — Every Little Heart Matters**

Fetal Cardiac Handbook, screening tools, pocket resources, VISUOG material and Fetal Heart Bites.

isuog.org/every-little-heart-matters/resources.html

**Tiny Hearts Project**

Sonographer-focused fetal cardiac screening education built around a systematic approach to essential views.

tinyheartsproject.org

**ISUOG Practice Guidelines**

Updated fetal cardiac screening guideline.

isuog.org

**AIUM**

Fetal echocardiography practice resources and normal imaging checklist.

aium.org

**ASE**

2023 fetal echocardiography recommendations.

asecho.org

**One-page Checklist**

Mayer C, Letourneau K; BC Fetal Echo Group. Fetal heart screening views: Minimal standards image acquisition and interpretation checklists (19–22 weeks routine scan). BC Women's Hospital + Health Centre; 2019.

61

## Selected References


- Carvalho JS, Axt-Fliedner R, Chaoui R, et al. ISUOG Practice Guidelines (updated): fetal cardiac screening. *Ultrasound Obstet Gynecol.* 2023;61(6):788–803. doi:10.1002/uog.26224.
- Freud LR, Simpson LL. Fetal cardiac screening: 1st trimester and beyond. *Prenat Diagn.* 2024;44(6-7):679–687. doi:10.1002/pd.6571.
- Gu S, Katyal A, Zhang Q, Chung W, Franciosi S, Sanatani S. The association between congenital heart disease and autism spectrum disorder: a systematic review and meta-analysis. *Pediatr Cardiol.* 2023;44(5):1092–1107. doi:10.1007/s00246-023-03146-5.
- **Hagen-Ansert SL. Textbook of Diagnostic Sonography. 9th ed. Elsevier; 2023.**
- Meagher S. *Fetal Cardiac Handbook*. ISUOG: Every Little Heart Matters. Updated 2026.
- Moon-Grady AJ, Donofrio MT, Gelehrter S, et al. Guidelines and recommendations for performance of the fetal echocardiogram: 2023 update from the American Society of Echocardiography. J Am Soc Echocardiogr. 2023;36(7):679–723. doi:10.1016/j.echo.2023.04.014.
- Sood E, Newburger JW, Anixt JS, et al. Neurodevelopmental outcomes for individuals with congenital heart disease: updates in neuroprotection, risk-stratification, evaluation, and management: a scientific statement from the American Heart Association. *Circulation.* 2024;149(13):e997–e1022. doi:10.1161/CIR.0000000000001211.


62

© Copyright. Society of Diagnostic Medical Sonography. All Rights Reserved.