Vasculopathy or Vasculitis

An overview of unusual vascular diseases

1

SPEAKER PRESENTATION DISCLAIMER

The content and views presented are made available for educational purposes only. The information presented are the opinions of the presenter and do not necessarily represent the views of the Society of Diagnostic Medical Sonography (SDMS) or its affiliated organizations, officers, Boards of Directors, or staff members.

The presenter is responsible for ensuring balance, independence, objectivity, scientific rigor, and avoiding commercial bias in their presentation. Before making the presentation, the presenter is required to disclose to the audience any relevant financial interests or relationships with manufacturers or providers of medical products, services, technologies, and programs.

The SDMS and its affiliated organizations, officers, Board of Directors, and staff members disclaim any and all liability for all claims that may arise out of the use of this educational activity.

2

© Copyright. Society of Diagnostic Medical Sonography. All Rights Reserved.

RESEARCH DISCLAIMER

The information presented in this presentation is based on research conducted to the best of the presenters' abilities and knowledge. Research involves uncertainty and is subject to limitations. The findings and conclusions presented herein may be influenced by various factors including but not limited to data quality, methodology, assumptions, and interpretation.

Research outcomes may not always accurately predict real-world scenarios or future events. While the presenter may make efforts to ensure the accuracy and reliability of the information presented, completeness or absolute correctness is not guaranteed. This presentation is intended for informational purposes only and should not be construed as professional advice. Participants are encouraged to independently verify any information provided and consult relevant experts or professionals where appropriate.

The SDMS and its affiliated organizations, officers, Board of Directors, and staff members disclaim any and all liability for all claims that may arise out of the use of this educational activity.

3

GENERATIVE AI DISCLAIMER

The presenter utilized the use of large language models (LLMs) and generative artificial intelligence (AI) as a productivity tool to assist in drafting and refining content in this presentation.

While these tools can aid in structuring ideas, summarizing, paraphrasing, and language polishing, they have inherent limitations and cannot replace human creativity, critical thinking, or expert judgment. AI-generated content may contain errors, biases, or gaps in knowledge.

This presentation is intended for informational purposes only and should not be construed as definitive or authoritative guidance. Participants are encouraged to critically evaluate the information presented and consult relevant experts as needed. The SDMS and its affiliated organizations, officers, Board of Directors, and staff members disclaim any and all liability for claims that may arise from the use or interpretation of this educational material.

4

© Copyright. Society of Diagnostic Medical Sonography. All Rights Reserved.

Objectives

1. Define vasculopathy/vasculitis and associated terms
2. Describe the categories and subtypes of vasculitis
3. Identify the underlying causes of vasculitis and vasculopathy
4. Recognize supporting imaging characteristics across modalities
5. Describe the treatments for vasculitis
6. Vasculitis and the patient

5

Terms to know…

Vasculopathy

- ANY "disease" of a blood vessel

Vasculitides

- Categorization of vascular inflammatory responses[1]

Vasculitis

- Inflammatory response of a vessel

6

© Copyright. Society of Diagnostic Medical Sonography. All Rights Reserved.

Vasculo**pathy** Categories

Functional/Dynamic/Impingement

- Thoracic outlet syndrome (TOS) Median arcuate ligament syndrome (MALS), Nutcracker

Degenerative / Embolic

- Atherosclerosis
- Pulmonary emboli (PE), stroke, occlusions

Dysplastic:

- Fibromuscular dysplasia (FMD), Segmental arterial mediolysis (SAM)

Coagulative:

- Disseminated intravascular coagulation (DIC)

Inflammatory:

- Vasculitis

From personal files of Schmalz L. (on file with author)

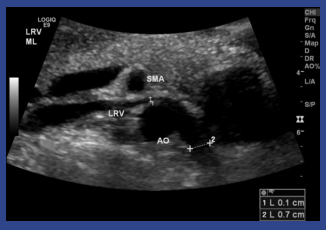

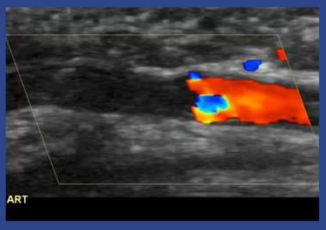



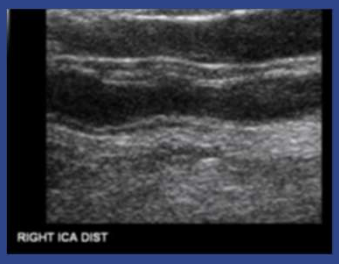

7

Vasculitides

- *First described over 150 years ago.*[1]
- *Define the type of vasculitis via histological identification of the active leukocytic inflammatory response present.*[2]

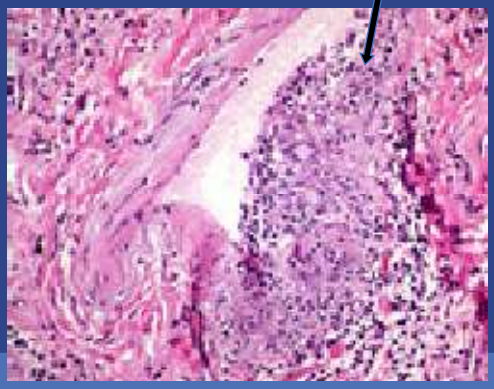

Figure 1. Histopathologic image demonstrating hypersensitivity pneumonitis with granulomatous vasculitis. Image by Pulmonary Pathology, Flickr, licensed under CC BY-SA 2.0. Adapted from Pulmonary Pathology.[3]

8

© Copyright. Society of Diagnostic Medical Sonography. All Rights Reserved.

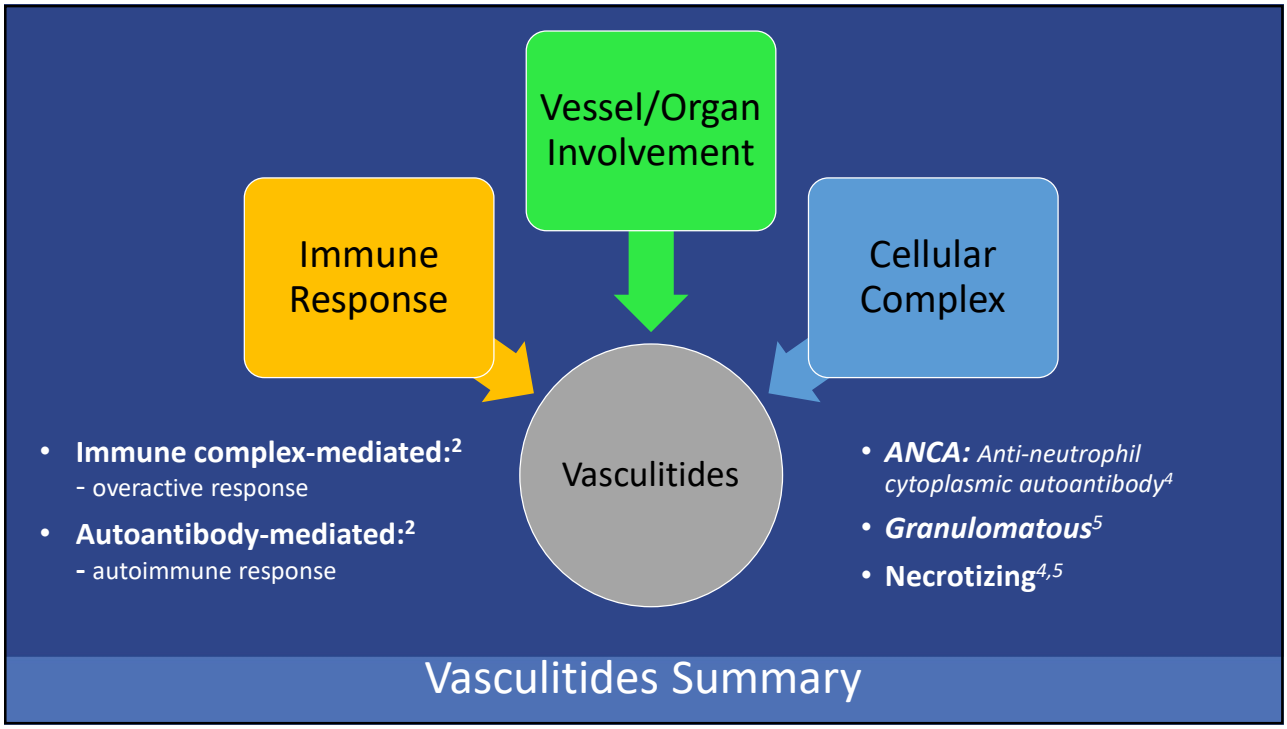

9

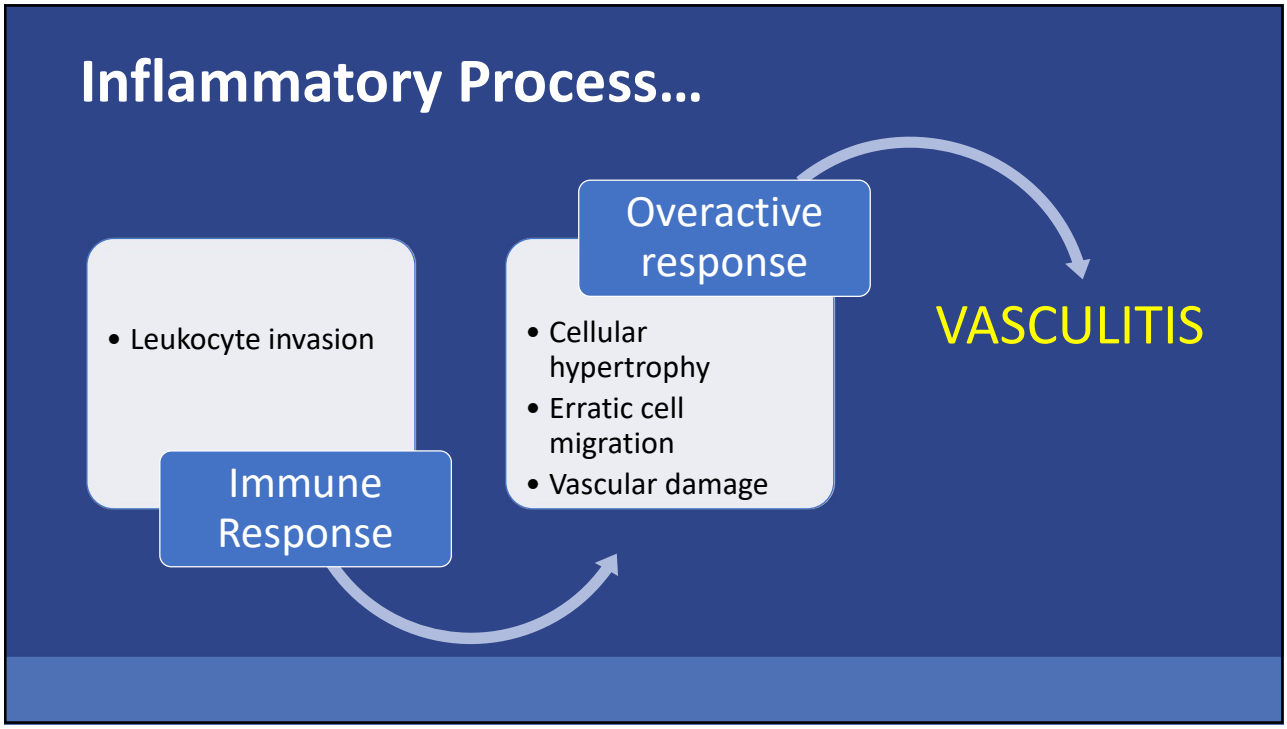

10

© Copyright. Society of Diagnostic Medical Sonography. All Rights Reserved.

Vasculitides

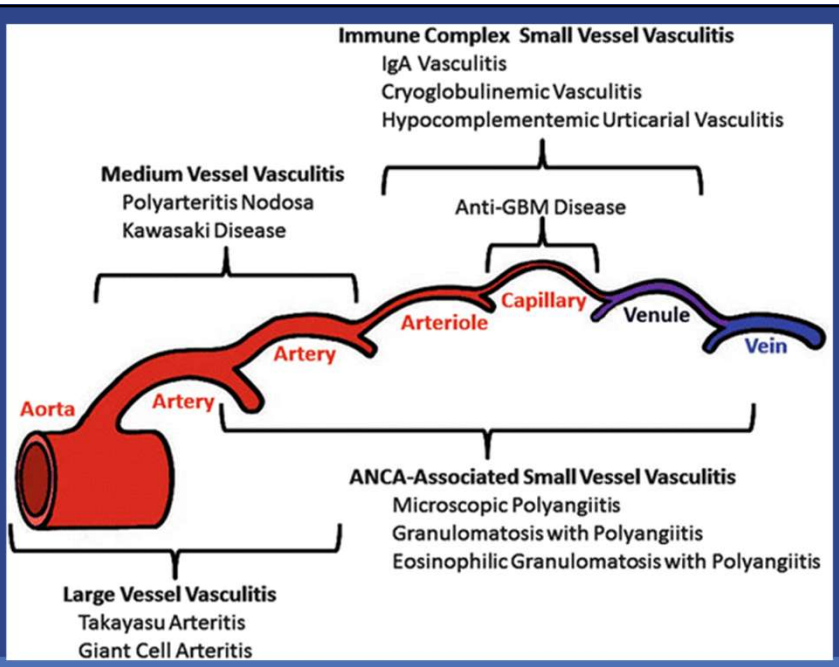

Adapted from Goudreau et al, Vasculitis, in Vascular Disease in Women*. 2021.[1]

11

- Vasculitis -

Defined by:

- **Type** of inflammatory response
  - Genetic
  - Hypersensitivity
  - Autoimmune or underlying disorder
- **Size** of vessel (artery/vein) affected
- **Location/system** affected
- **Complication** association

Statistics[6]

- > 30 types
- 50 of 1million / year
- > 50 yrs of age

12

© Copyright. Society of Diagnostic Medical Sonography. All Rights Reserved.

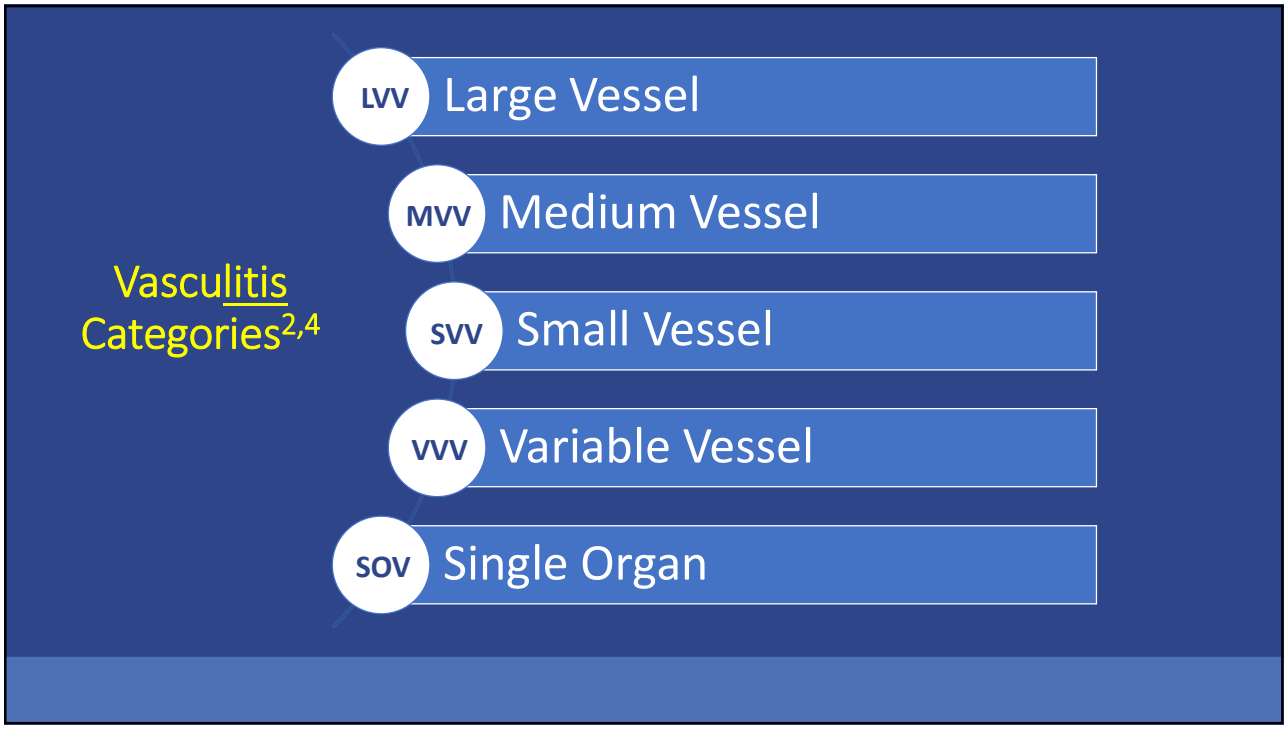

13

- Vasculitis -
"Diagnostics"

Lab tests:
- Erythrocyte sedimentation rate (ESR)*
- C-reactive protein test (CRP)*
- Complete blood count (CBC)
- ANCA
- Urinalysis

Imaging/Histology:
- Angiography
  - Magnetic resonance (MRA)
  - Computed tomography (CTA)
- Sonography (US)
- Positron emission tomography (PET)
- Biopsy

Prompt recognition is critical

Paired diagnostics is key: labs + imaging

14

© Copyright. Society of Diagnostic Medical Sonography. All Rights Reserved.

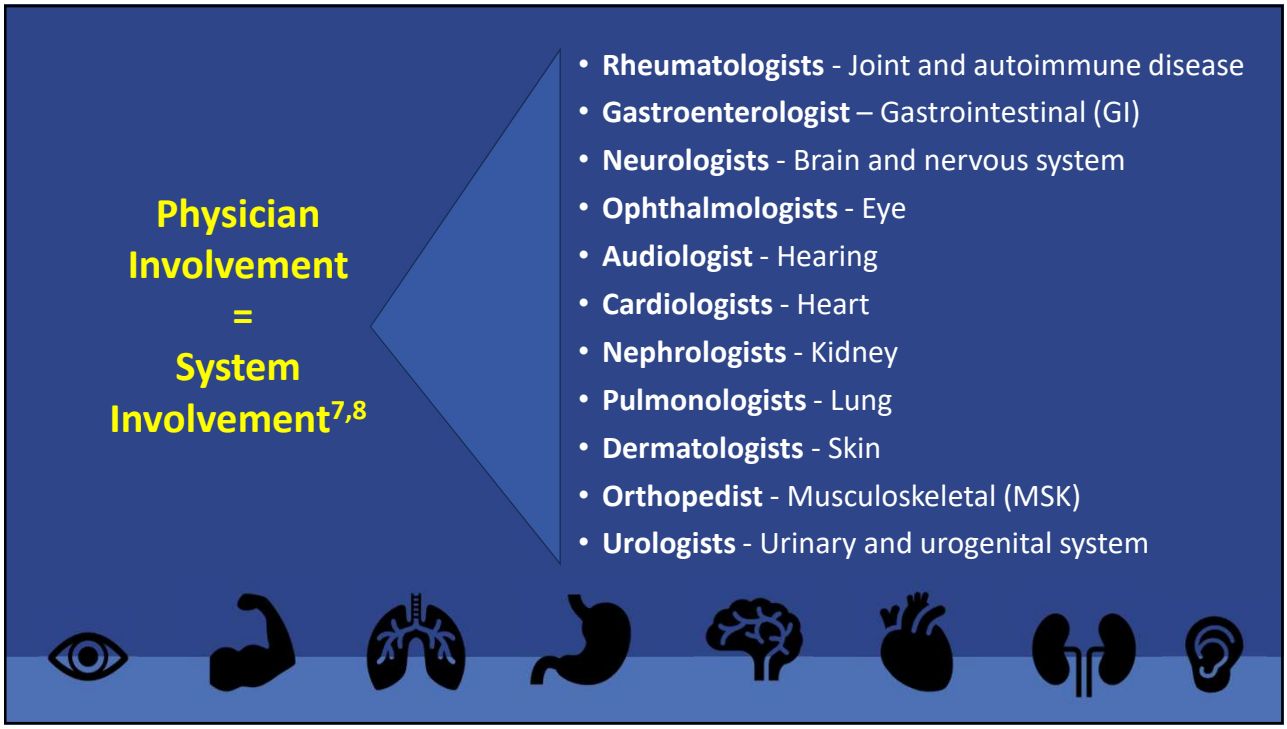

15

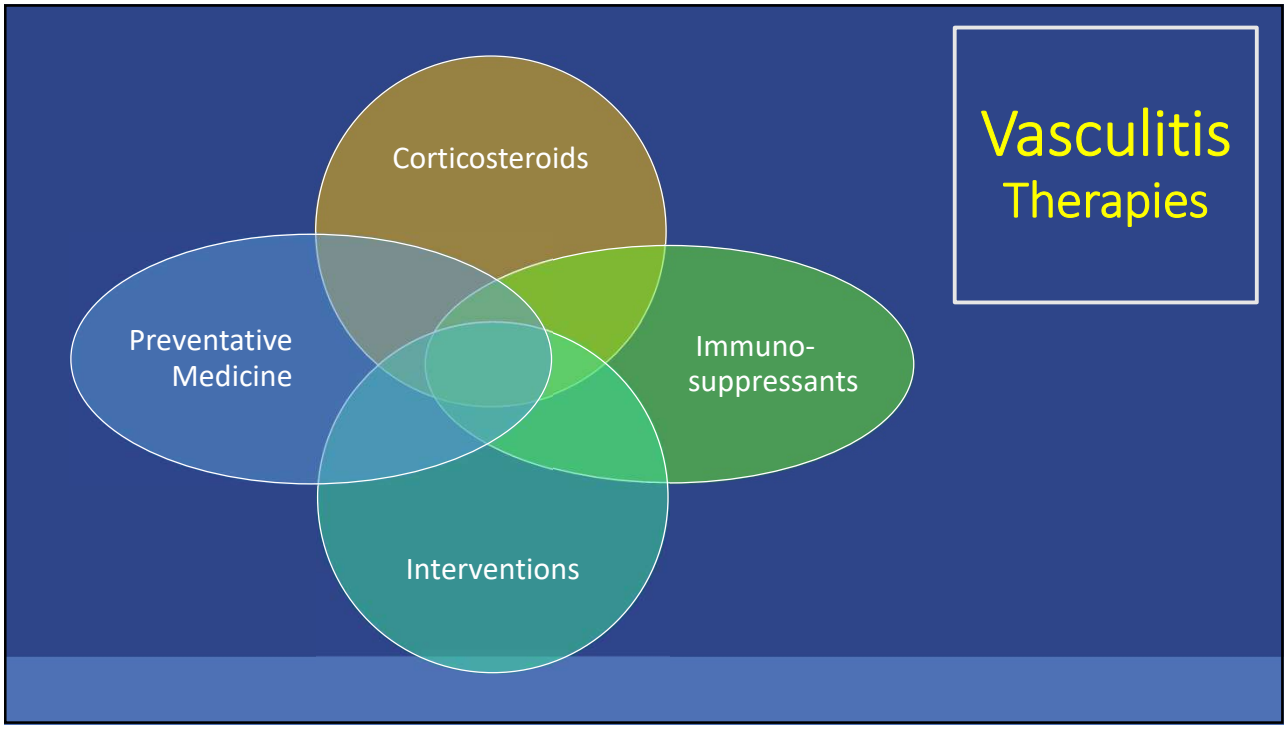

16

© Copyright. Society of Diagnostic Medical Sonography. All Rights Reserved.

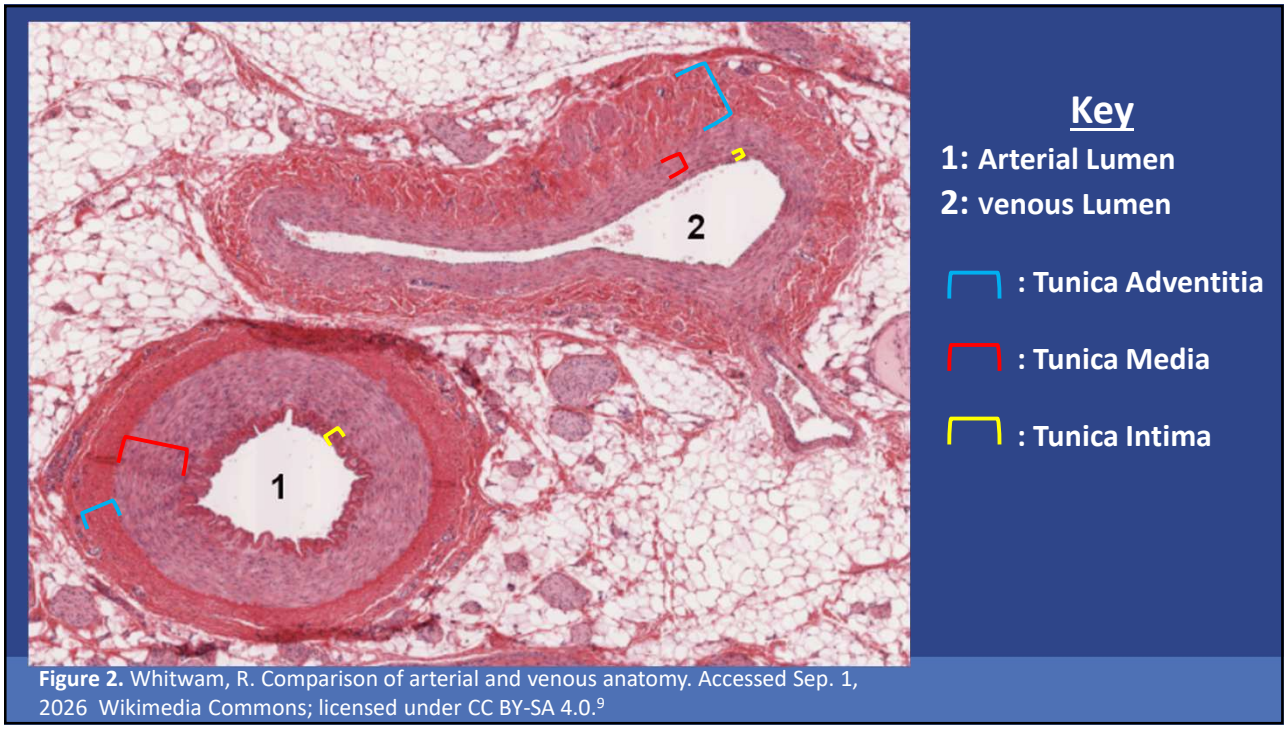

Figure 2. Whitwam, R. Comparison of arterial and venous anatomy. Accessed Sep. 1, 2026 Wikimedia Commons; licensed under CC BY-SA 4.0.[9]

17

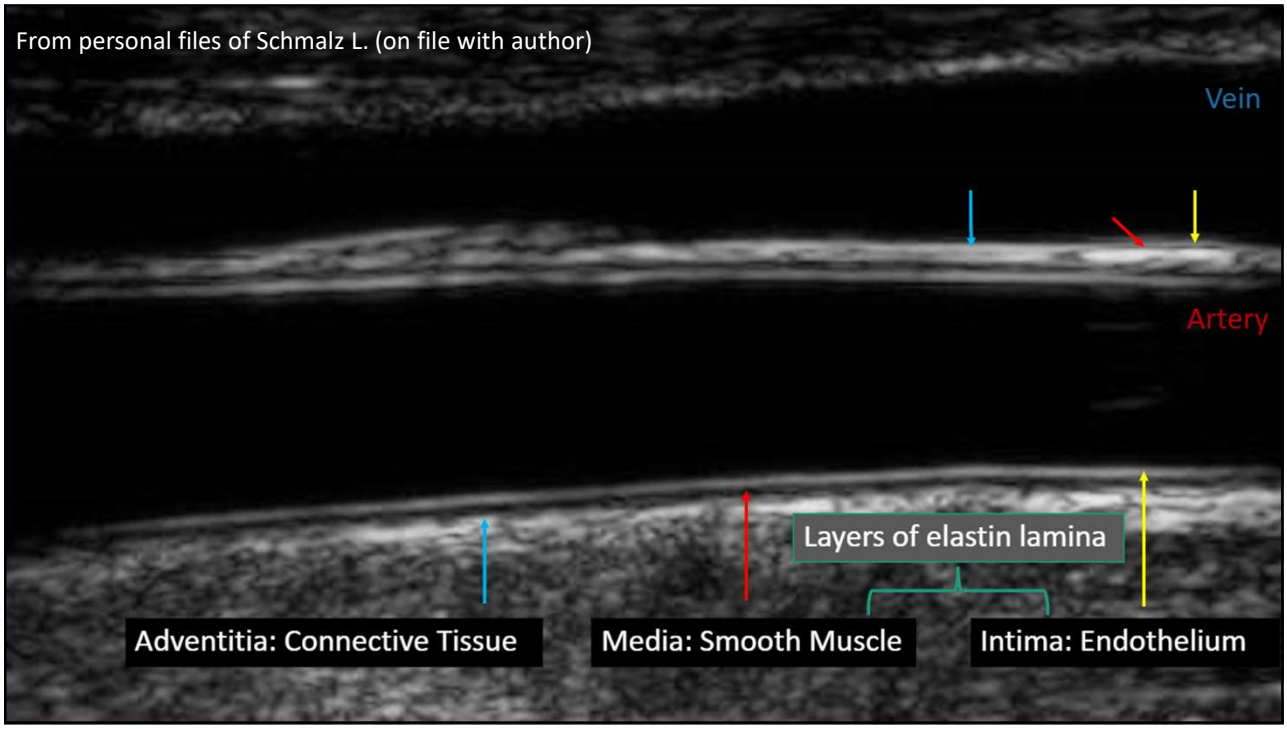

18

© Copyright. Society of Diagnostic Medical Sonography. All Rights Reserved.

Large Vessel Vasculitis

- **Giant Cell Arteritis** -*"Temporal Arteritis"*
- **Takayasu Arteritis –** *"Pulselessness Disease"*

Aorta + primary branches; IVC + primary tributaries

19

Giant Cell Arteritis (GCA)

"Temporal Arteritis"



Figure 3. Frontal branch of the superficial temporal artery. Image courtesy of Opzwartbeek, Wikimedia Commons; licensed under CC BY-SA 4.0. Adapted from Wikimedia Commons[10]

Common Vessel Involvement

- Superficial Temporal
  - Frontal branch
  - Parietal branch

Signs/Symptoms

- Clinical Triad[2]
  - Headache
  - Jaw Pain
  - Bilateral scalp tenderness
- Diplopia or vision loss

20

© Copyright. Society of Diagnostic Medical Sonography. All Rights Reserved.

Giant Cell Arteritis (GCA)
"Temporal Arteritis"

Risk Factors/Associations
- AGE
  - 50 years old; peak incidence at 80[2]
- Women 2:1
- 50% with coinciding polymyalgia rheumatica[11]

Complications
- Blindness
- Aneurysms
- Stroke (uncommon)
- Ischemia vs thrombosis

21

Giant Cell Arteritis (GCA)
Diagnostics



Temporal Artery Biopsy

Autoimmune granulomatous inflammatory markers



Imaging

Sonography: 96% - specificity[12]
MRA: 100% - specificity[12]
PET: 89 – 98%- specificity[12]



+ Lab Markers

ESR: elevated
CRP: elevated

22

© Copyright. Society of Diagnostic Medical Sonography. All Rights Reserved.

Giant Cell Arteritis (GCA)

"Temporal Arteritis"

Vessel Wall Involvement[13]

Adventitial layer:

- Infiltration of abnormal WBCs

Media layer:

- Scaring and thinning disrupts elastin

Intima layer:

- Cellular hyperplasia

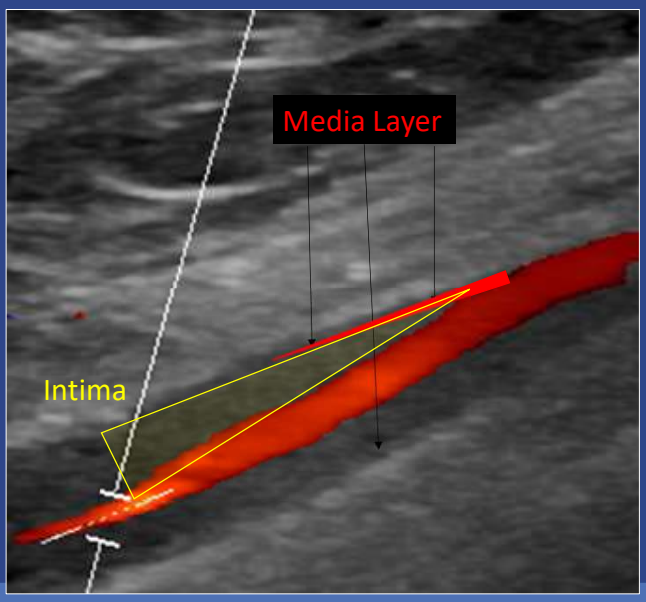

From personal files of Schmalz L. (on file with author)

23

GCA Case Study

Sonographic Findings

From personal files of Schmalz L. (on file with author)

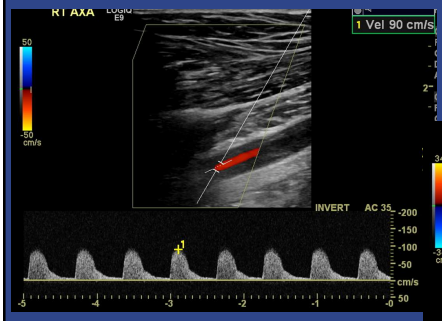

Pre-stenotic Zone:
Monophasic versus multiphasic (normal) peripheral waveform with noted spectral broadening

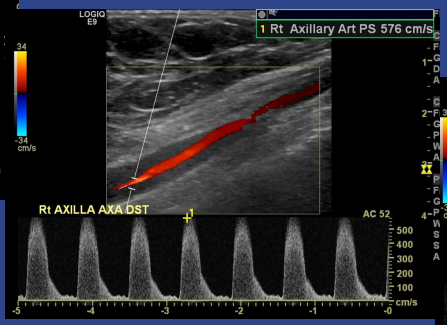

Stenotic Zone:
Elevated peak systolic velocity (PSV) of 576cm/sec

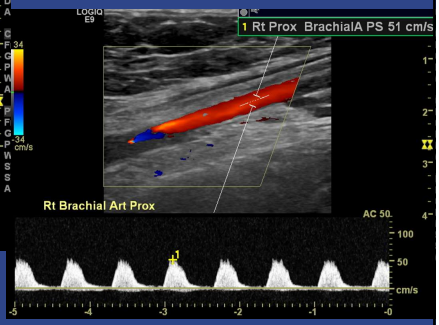

Post-stenotic Zone:
Turbulence with normalized PSV of 51cm/sec

From personal files of Schmalz L. (on file with author)

24

© Copyright. Society of Diagnostic Medical Sonography. All Rights Reserved.

Takayasu's Arteritis

"Pulselessness Disease"

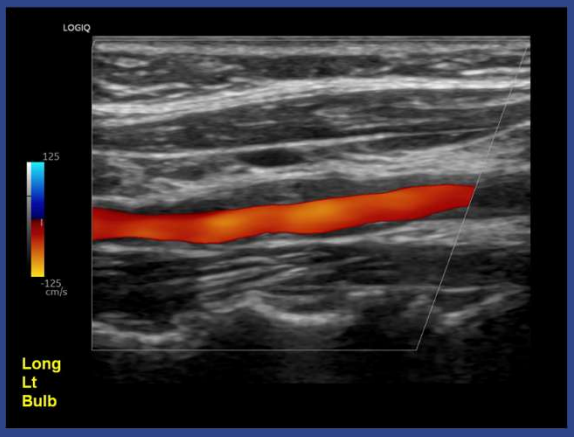

Risk Factors/Associations

- Women (80-90% of cases)[14]
- Onset 10 - 40 years old[14]
- Asian descent

Complications

- Ischemia / stroke
- Heart failure, attack, myocarditis
- Aneurysms

From personal files of Schmalz L. (on file with author)

25

Takayasu's Arteritis

Signs/Symptoms

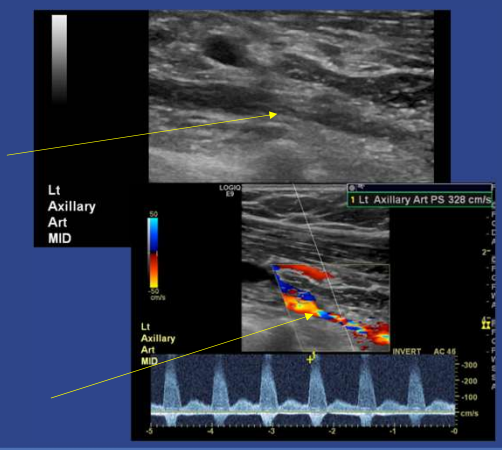

Stage 1: "Systemic Stage"[14,15]

- General malaise and fatigue
- Mild fever

Stage 2: "Occlusive Stage"[14,15]

- Loss of or weak peripheral pulses
- Limb claudication
- Blood pressure discrepancies, hypertension
- Shortness of breath, chest pain
- Lightheaded, dizzy, faint, memory alterations
- Vision changes, headaches

From personal files of Schmalz L. (on file with author)

26

© Copyright. Society of Diagnostic Medical Sonography. All Rights Reserved.

Takayasu's Arteritis

Angiographic Types + Vessel Involvement[16]

- **Type I:** Aortic Arch branches
- **Type IIa/b:** Ascending aorta, aortic arch and branches
- **Type IIb:** Ascending aorta, aortic arch and branches, and descending thoracic aorta
- **Type III:** Thoracic descending aorta, abdominal, and/or renal arteries
- **Type IV:** Abdominal aorta and/or renal arteries, pulmonary arteries
- **Type V:** Combination of Types IIb and IV

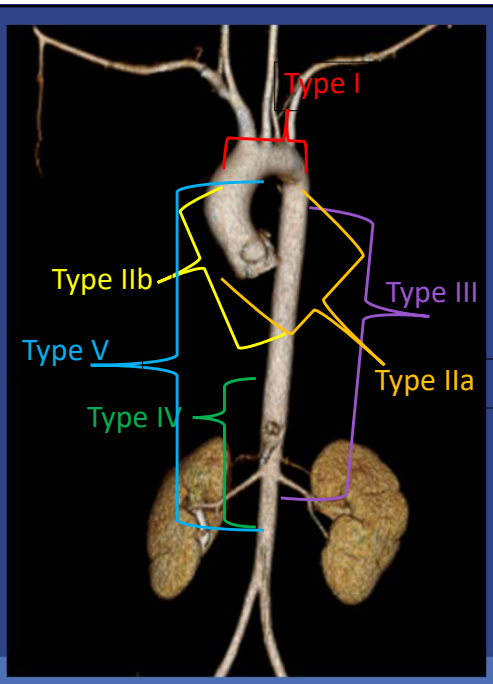

From personal files of Schmalz L. (on file with author)

27

Takayasu's Arteritis

Diagnostics

Biopsy

Contraindicated unless surgical intervention is required
Granulomatous inflammatory markers

Imaging

CTA/MRA: 100% - specificity[12]
PET: 73-84%- specificity[12]
Sonography: unknown specificity

Lab Markers

Nonspecific
ESR: elevated in stage 1
CRP

28

© Copyright. Society of Diagnostic Medical Sonography. All Rights Reserved.

Takayasu's Arteritis
"Pulselessness Disease"

Vessel Wall Involvement[17]

Adventitial layer:
- Granulomatous inflammatory infiltration

Media layer:
- Granulomatous inflammatory infiltration

Intima layer:
- Cellular hyperplasia

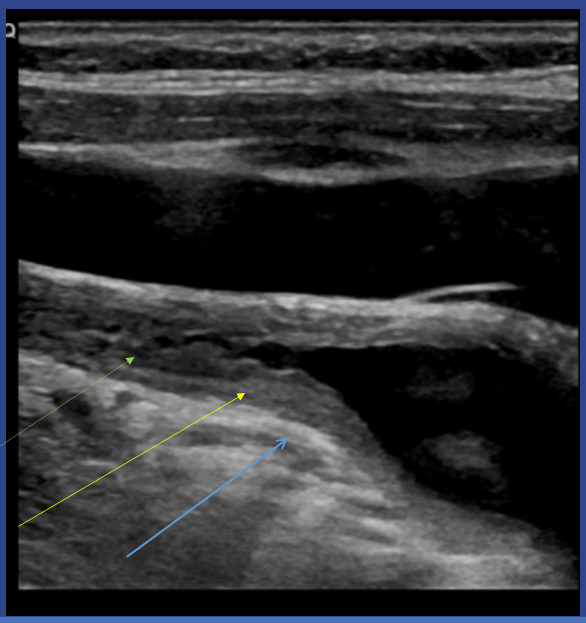

From personal files of Schmalz L. (on file with author)

29

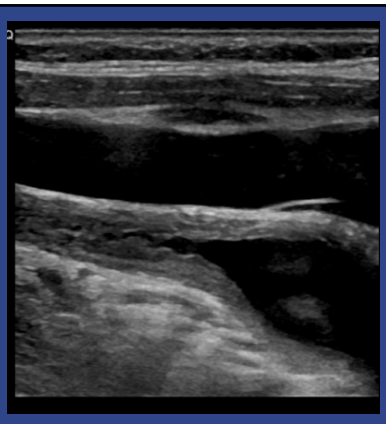

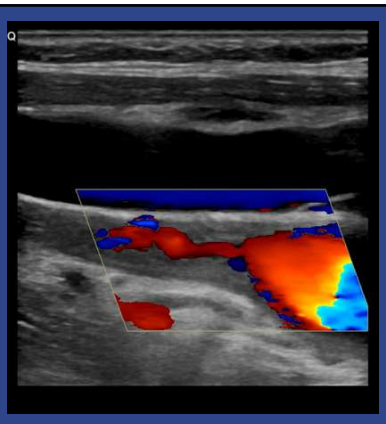

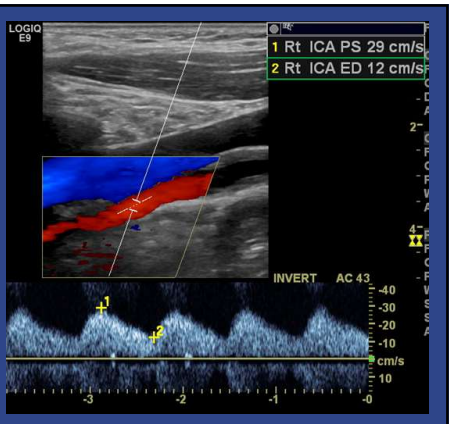

- Tapering of vessel lumen
- Intimal proliferation
- Perivascular infiltration of the adventitia
- Dampened (tardus parvus) waveform distal to the severe stenosis

Takayasu's Case Study
Sonographic Findings
From personal files of Schmalz L. (on file with author)

30

© Copyright. Society of Diagnostic Medical Sonography. All Rights Reserved.

LVV Imaging

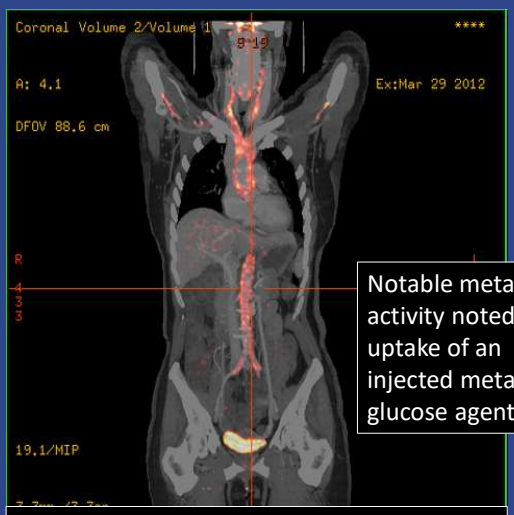

Notable metabolic activity noted via uptake of an injected metabolic glucose agent[13]

Figure 4. Adapted from Hg6996, *Vasculitis FDG PET-CT*, Wikimedia Commons, CC BY-SA 3.0[18]

Classic hypoechoic "Halo Sign"[12] secondary to edema, noted with GCA

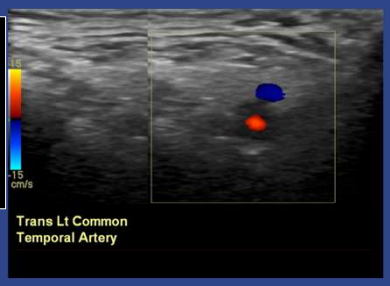



Thickened hypoechoic arterial wall, encroaching the vessel lumen

From personal files of Schmalz L. (on file with author)

31

Medium Vessel Vasculitis

- **Polyarteritis nodosa**
- **Kawasaki disease**

Main visceral vasculature + primary branches and tributaries

32

© Copyright. Society of Diagnostic Medical Sonography. All Rights Reserved.

Polyarteritis Nodosa *(PAN)*

Figure 5. Livedo reticularis of the left lower extremity. Adapted from Nantsupawat T et al, Wikimedia Commons; licensed under CC BY-SA 3.0.[19]



Risk Factors/Associations[13]

- 1 - 10/million
- Gender neutral
- Onset: 40-60 years old
- Viral hepatitis B

Signs/Symptoms

- Skin (cutaneous form)[13]
  - Ulcerations
  - Livedo reticularis - rash
- Peripheral neuropathy
- Hypertension

33

Polyarteritis Nodosa *(PAN)*

Vessel Involvement

- Visceral vasculature

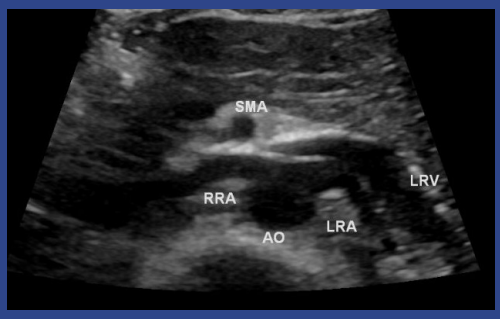

Complications

- Microaneurysms - ruptures
- Thrombosis
- Stenoses - infarcts
- Impaired organ functions
- 2-year relapse – 50%[13]

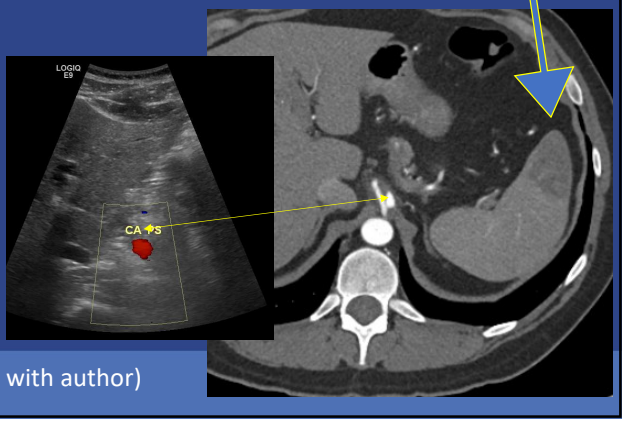

From personal files of Schmalz L. (on file with author)

34

© Copyright. Society of Diagnostic Medical Sonography. All Rights Reserved.

Polyarteritis Nodosa
Diagnostics



Biopsy

Autoimmune Response
Necrotizing Cell Complexes



Imaging

Angiography



+ Lab Markers

ESR: elevated
CRP: elevated
Hepatitis B markers

35

Kawasaki's Disease

Which Vessels

- Medium and Small Arteries[2]
  - Coronary aneurysms



Risk Factors/Associations[20]

- Pediatrics < 5 yr. old
- Male
- Asian/Pacific Island descent
- Winter/early spring onset

Key Features

- Most common pediatric vasculitis
- "Strawberry Tongue"[21]
- Often treatable without complications
- Acute artheritis[21]

36

© Copyright. Society of Diagnostic Medical Sonography. All Rights Reserved.

Kawasaki's Disease
Signs/Symptoms[20]

Fever + 4 additional coinciding symptoms, clinical indication of Kawasaki's Disease

- Fever: >100.4° for ≥5 days
- "Strawberry Tongue"[21]
  - Significant mucous membrane swelling and cracking (lips, tongue)
- Rash: genital and/or large surface area
- Conjunctivitis
- Rubor and swelling of hands/feet + peeling skin
- Lymphadenopathy – cervical/neck



Figure 6. Clinical manifestations of Kawasaki disease. Image by Dong Soo Kim; derivative work by Natr. Wikimedia Commons; licensed under CC BY 2.0[22]

37

Kawasaki's Disease
Diagnostics



CLINICAL FINDINGS

Primary diagnostic criteria: Weighed more than a biopsy or imaging



Imaging

Echocardiogram
ECG

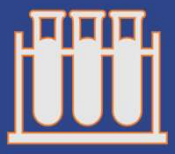

+/- Lab Markers

Early onset: CRP, ESR, Ferritin
CBC fluctuations throughout stages of disease

38

© Copyright. Society of Diagnostic Medical Sonography. All Rights Reserved.

Small Vessel Vasculitis

- Churg- Strauss
- Wegener's
- Goodpasture's
- Henoch-Schönlein Purpura

Intraparenchymal vessels, arterioles, capillaries, and venules

39

SVV

Goodpasture's

Bleeds
Lung and Kidney

Wegener's Disease

Granulomatous cell complexes
Lung
Kidney
Ear, Nose, Throat

Churg-Strauss

Adult onset of asthma[23]
GI: Bleeds
ENT: Allery/Sinus
Dermatology: Rashes
MSK/Nerve: Hand/Foot Pain/numbness
Currently known as: EGPA[23]

Henoch-Schönlein Purpura

Pediatric (<10 yrs) onset[24]
Post respiratory infection
GI: Obstructions
MSK: Joint Pain

40

© Copyright. Society of Diagnostic Medical Sonography. All Rights Reserved.

Various Vessel Vasculitis

- **Behçet's Syndrome**
- **Cogan's Syndrome**

Non-specific size or type of vessel

41

Various Vessel Vasculitis

- **Behçet's Syndrome**
  - Mouth and genital sores, inflamed eyes, and rashes
  - Clinical > diagnostic diagnosis *(Pathergy Test)*[25]
  - Treat symptoms
  - 20s-30s non gender specific
  - Middle East, East Asia
- **Cogan's Syndrome**
  - Sensorineural hearing loss
  - Inflammatory eye changes
  - Vertigo



Figure 7. Cutaneous vasculitis involving the ankle region. Image by Rosser1954, Wikimedia Commons; licensed under CC BY-SA 4.0.[26]

42

© Copyright. Society of Diagnostic Medical Sonography. All Rights Reserved.

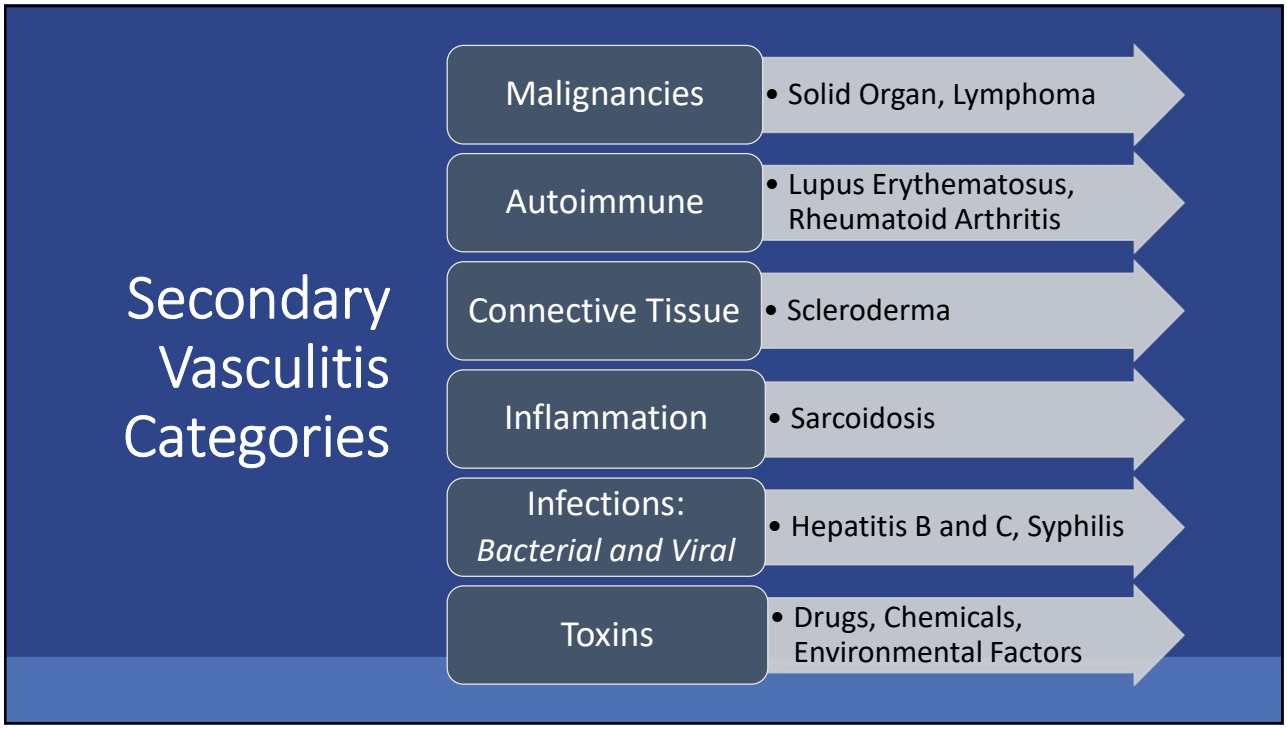

43

Vasculitis and the patient

Many, many, MANY angsts

Appointments
Mental/Physical Changes
Family
Reliance
Immunosuppression
Aches - Pains
Fatigue
Outlook
Helplessness
Life balance
Why/What
FEAR
TIME

The care needed is that of great detail, concern, optimism, and confidence

44

© Copyright. Society of Diagnostic Medical Sonography. All Rights Reserved.

Care received makes a differences in the patients' experiences

- Life saving
- Validation
- Mental reset

Care comes from **YOU!**

- Indirect
- Direct

If it weren't for **YOU,** patients

- Wouldn't come
- Unsettled angst
- Unanswered questions

Respect, Integrity, Compassion, Healing
Teamwork, Innovation, Excellence, Stewardship[27]

45



46

© Copyright. Society of Diagnostic Medical Sonography. All Rights Reserved.

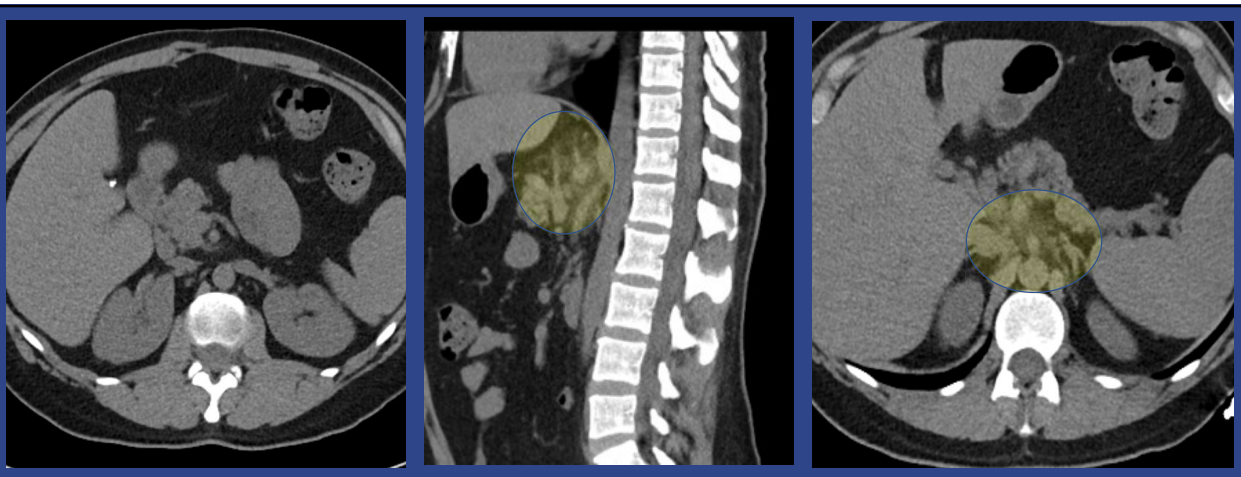

Initial CT (no contrast) findings:

- NO STONES
- Incidental "Fat Stranding"
  - "…when present, it directs … attention to the site of pathology."[28(p1)]

From personal files of Schmalz L. (on file with author)

47

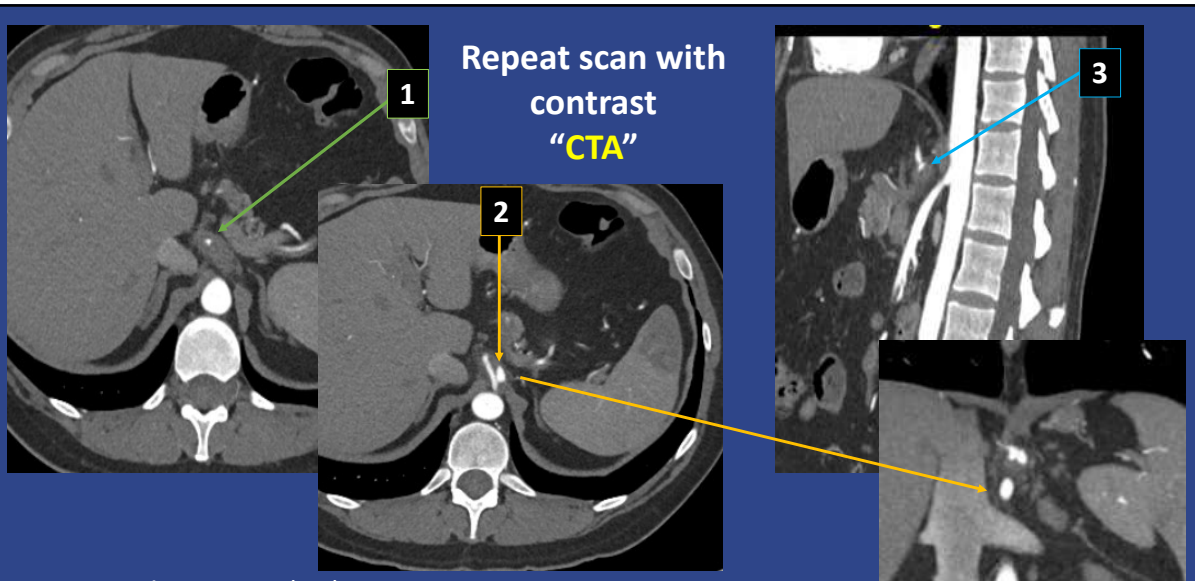

1. Severe celiac artery (CA) stenosis
2. CA pseudoaneurysm
3. Common hepatic artery (CHA) stenosis

From personal files of Schmalz L. (on file with author)

48

© Copyright. Society of Diagnostic Medical Sonography. All Rights Reserved.

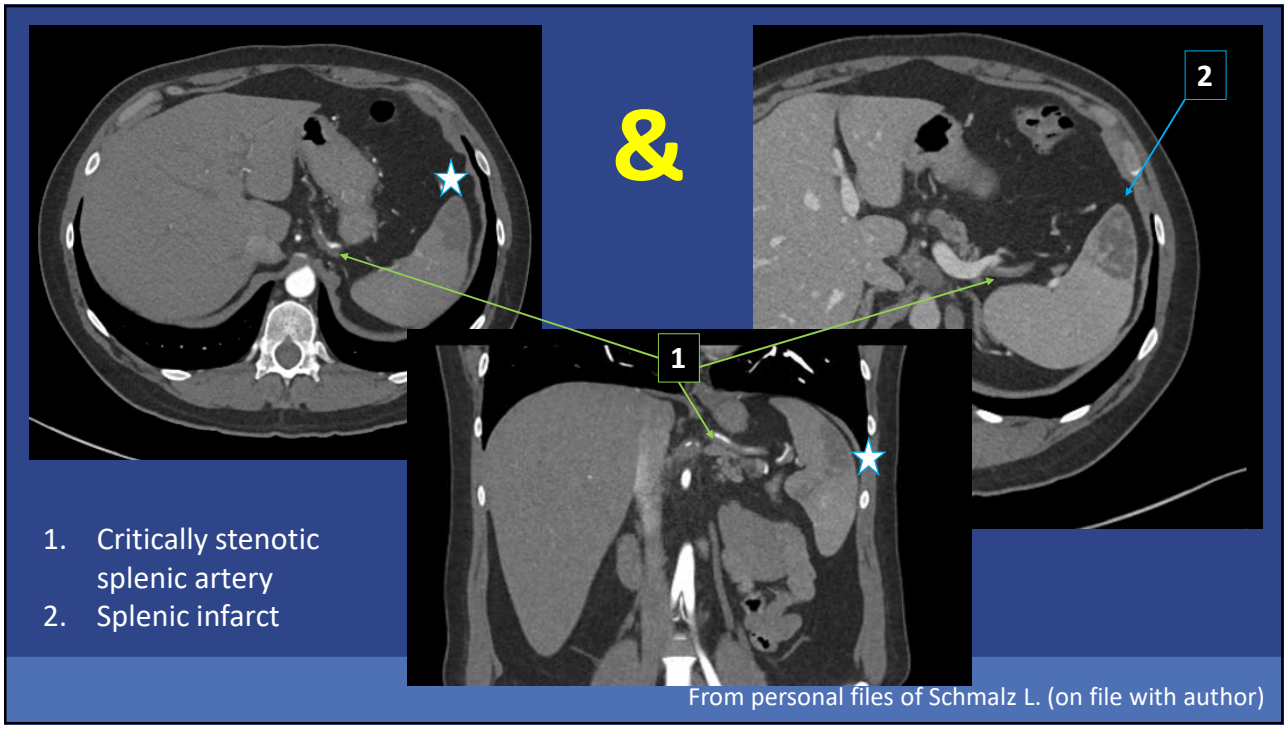

49

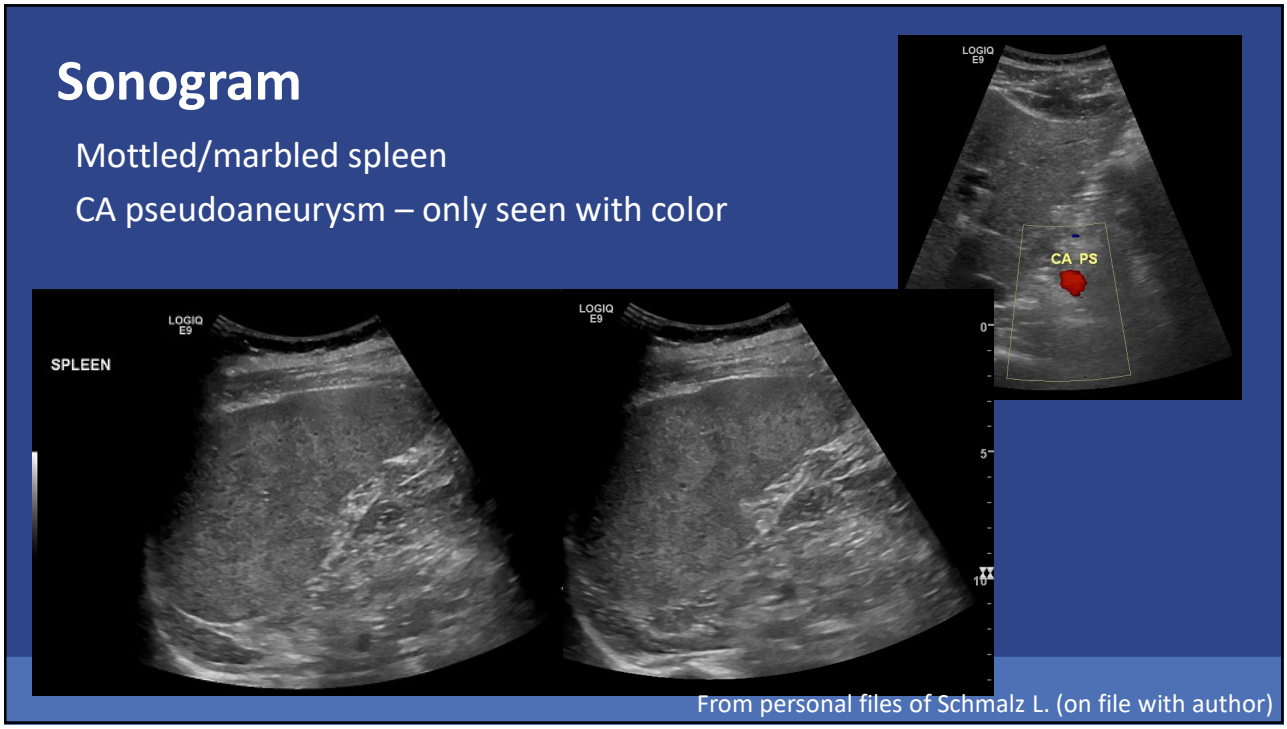

50

© Copyright. Society of Diagnostic Medical Sonography. All Rights Reserved.

What is going on?

- **Medium vessel involvement**
  - ~~Segmental Arterial Mediolysis~~: pseudoaneurysm of CA + mesenteric involvement ~~—~~ No renal involvement
  - ~~FMD~~ — No lab markers (ANCA, Hep B)
  - ~~Polyarteritis Nodosa~~ — Not pediatric
  - ~~Kawasaki~~ — Great peripheral pulses, no hypertension
  - ?
- **Lab work**
  - Significantly elevated ESR and CRP
  - Negative ANCA & Hep B
- **Biopsy**
  - Not applicable



Now what?

51





14 rad/sedation imaging scans 6 months



Radiation
Medication Side Effects
Many pokes/sticks



From personal files of Schmalz L. (on file with author)

52

© Copyright. Society of Diagnostic Medical Sonography. All Rights Reserved.

COIL embolization of CA

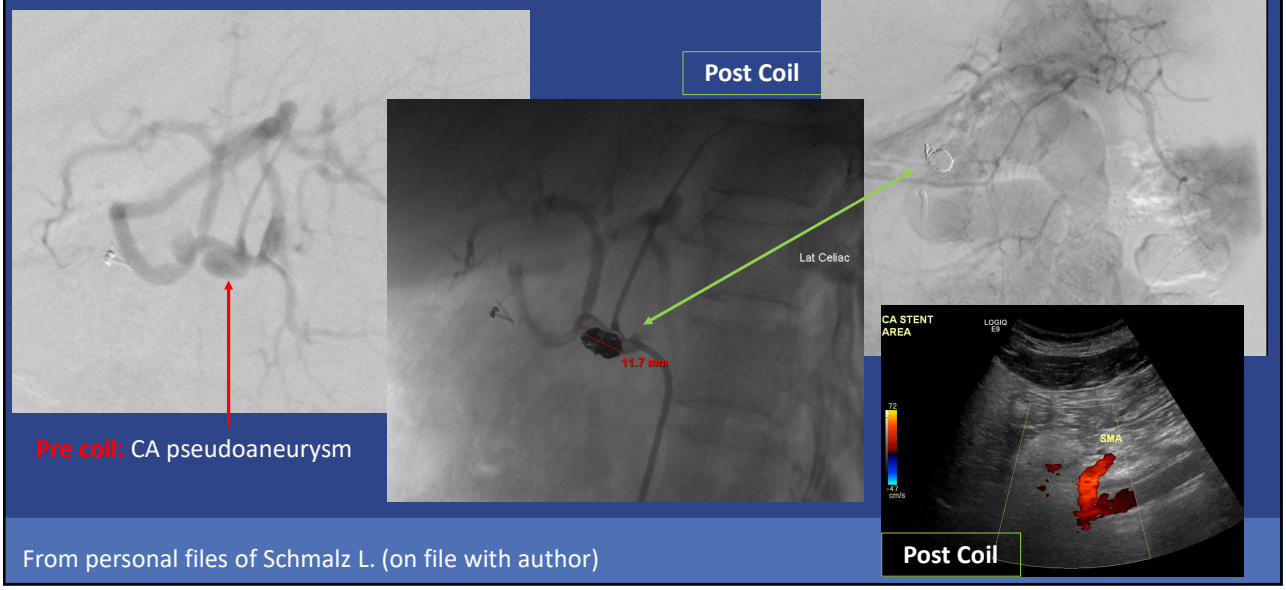

From personal files of Schmalz L. (on file with author)

53

Collateralization

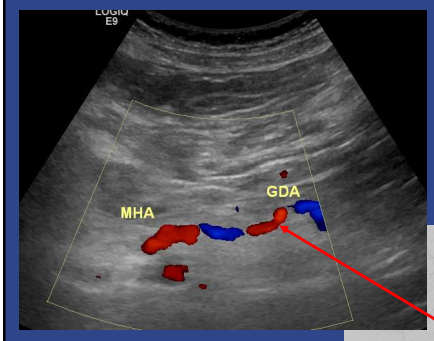

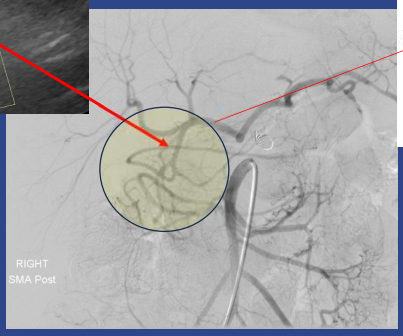

MHA: Main Hepatic Artery
GDA: Gastroduodenal Artery

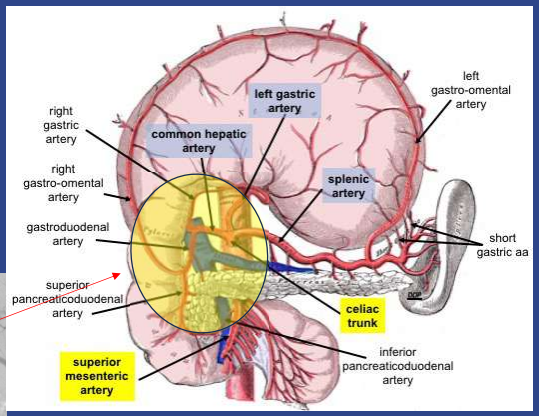

Figure 8. Adapted from DePace DM. *Celiac trunk and branches* [image]. Wikimedia Commons. Published April 2, 2019. Licensed under CC BY-SA 4.0.[29]

From personal files of Schmalz L. (on file with author)

54

© Copyright. Society of Diagnostic Medical Sonography. All Rights Reserved.

Case Study Recap

Vascular Component:

- Mesenteric ischemia
- Closest presentation to PAN, despite:
  - Negative hepatitis B results
  - < 40 yrs of age

Differential diagnosis: SAM

- Not likely due to:
  - Persistent inflammatory markers
  - Favorable response to corticosteroid and immunosuppressant treatment

Rheumatology Aspect:

- No coinciding symptoms or markers for specific rheumatologic conditions
- Autoimmune condition = rheumatology care



55

Vasculitis Overview

> 30

- Rare but can happen to anyone
- Commonly and autoimmune disorder
- Vessel size and organ involvement is a useful distinguishing feature
- Triggers are often unknown: autoimmune
- Relapse and remission
- Many follow-up and routine monitoring
- Serious and life threatening
- Many potential complications



56

© Copyright. Society of Diagnostic Medical Sonography. All Rights Reserved.



57

Resources

1. Goudreau B, Kanneganti M, Tracci M. Vasculitis. In: Hicks CW, Harris LM, eds. *Vascular Disease in Women*. Academic Press; 2021:273-294. doi:10.1016/B978-0-12-822959-0.00009-2
2. Merkel PA. Overview of and approach to the vasculitides in adults. In: UpToDate. Warrington KJ, Seo P, eds. UpToDate; updated May 12, 2025. Accessed August 30, 2026. https://www.uptodate.com/contents/overview-of-and-approach-to-the-vasculitides-in-adults
3. **Figure 1.** Pulmonary Pathology. *Hypersensitivity pneumonitis-granulomatous vasculitis Case 129*. Flickr. Accessed September 4, 2026. https://www.flickr.com/photos/30950973@N03/7724198008
4. **Jennette JC.** Overview of the 2012 revised International Chapel Hill Consensus Conference nomenclature of vasculitides. *Clin Exp Nephrol.* 2013;17(5):603-606. doi:10.1007/s10157-013-0869-6
5. Shah KK, Pritt BS, Alexander MP. Histopathologic review of granulomatous inflammation. *J Clin Tuberc Other Mycobact Dis.* 2017;7:1-12. doi:10.1016/j.jctube.2017.02.001
6. Cleveland Clinic. Vasculitis: symptoms, types, and treatment. Updated August 17, 2023. Accessed September 1, 2026. https://my.clevelandclinic.org/health/diseases/12101-vasculitis
7. American College of Rheumatology. Vasculitis. Updated February 2025. Accessed August 30, 2026. https://rheumatology.org/patients/vasculitis

58

© Copyright. Society of Diagnostic Medical Sonography. All Rights Reserved.

Resources

8. Mayo Clinic Staff. Vasculitis: diagnosis and treatment. Mayo Clinic. Updated February 5, 2025. Accessed September 1, 2026. https://www.mayoclinic.org/diseases-conditions/vasculitis/diagnosis-treatment/drc-20363485
9. Figure 2. Comparison of arterial and venous anatomy. Adapted from RWhitwam. *Arteries vs veins identify*. Wikimedia Commons. Accessed September 1, 2026. https://commons.wikimedia.org/w/index.php?title=Special%3AMediaSearch&type=image&search=comparison+of+artery+and+vein
10. Figure 3. Frontal branch of the superficial temporal artery. Image courtesy of Opzwartbeek. Wikimedia Commons. Licensed under CC BY-SA 4.0. Accessed September 1, 2026. https://commons.wikimedia.org/w/index.php?title=Special%3AMediaSearch&type=image&search=temporal+artery
11. Mayo Clinic Staff. Giant cell arteritis: symptoms and causes. Mayo Clinic. Updated June 2, 2026. Accessed September 1, 2026. https://www.mayoclinic.org/diseases-conditions/giant-cell-arteritis/symptoms-causes/syc-20372758
12. Friedrich J, Schulz P, Heine L, Klank D, Bergner R. MRI and ultrasound in giant cell arteritis: complementary strengths and combined diagnostic value. *Semin Arthritis Rheum.* 2026;79:153021. doi:10.1016/j.semarthrit.2026.153021
13. Farrah TE, Basu N, Dweck M, Calcagno C, Fayad ZA, Dhaun N. Advances in therapies and imaging for systemic vasculitis. *Arterioscler Thromb Vasc Biol*. 2019;39(8):1520-1541. doi:10.1161/ATVBAHA.118.310957

59

Resources

14. Kerr GS, Stone JH. Clinical features and diagnosis of Takayasu arteritis. In: Post TW, ed. UpToDate. UpToDate; updated September 9, 2025. Accessed September 4, 2026. https://www.uptodate.com/contents/clinical-features-and-diagnosis-of-takayasu-arteritis
15. Mayo Clinic Staff. Takayasu's arteritis: symptoms and causes. Mayo Clinic. Updated June 13, 2025. Accessed September 3, 2026. https://www.mayoclinic.org/diseases-conditions/takayasus-arteritis/symptoms-causes/syc-20351335
16. Verma A, Kumar I, Aggarwal P, Shukla R. Imaging spectrum of pediatric nonspecific aortoarteritis on CT angiography: a retrospective study. *Ann Natl Acad Med Sci (India).* 2019;55(3):145-150. doi:10.1055/s-0039-1697238
17. de Souza AW, de Carvalho JF. Diagnostic and classification criteria of Takayasu arteritis. *J Autoimmun.* 2014;48-49:79-83. doi:10.1016/j.jaut.2014.01.012
18. Figure 4. Severe vasculitis of the major vessels demonstrated on FDG-PET/CT. Adapted from Hg6996. *Vasculitis FDG PET-CT* [image]. Wikimedia Commons. Published March 29, 2012. Licensed under CC BY-SA 3.0. Accessed September 1, 2026. https://commons.wikimedia.org/w/index.php?title=Special%3AMediaSearch&type=image&search=vasculitis
19. **Figure 5.** Livedo reticularis involving the left lower extremity. Image by Nantsupawat T et al. Wikimedia Commons. Licensed under CC BY-SA 3.0. Accessed September 1, 2026. https://commons.wikimedia.org/w/index.php?title=Special%3AMediaSearch&type=image&search=livedo+reticularis

60

© Copyright. Society of Diagnostic Medical Sonography. All Rights Reserved.

Resources

20. Mayo Clinic Staff. Kawasaki disease: symptoms and causes. Mayo Clinic. Updated June 12, 2026. Accessed September 3, 2026. https://www.mayoclinic.org/diseases-conditions/kawasaki-disease/symptoms-causes/syc-20354598
21. Sundel R. Kawasaki disease: clinical features and diagnosis. In: UpToDate. Updated June 29, 2020. Accessed September 3, 2026. https://www.uptodate.com/contents/kawasaki-disease-clinical-features-and-diagnosis
22. Figure 6. Kim DS, Natr. *Kawasaki symptoms B*. Wikimedia Commons. Accessed August 30, 2026. https://commons.wikimedia.org/w/index.php?title=Special%3AMediaSearch&type=image&search=Kawasaki+disease
23. Mayo Clinic Staff. EGPA (formerly Churg-Strauss syndrome): symptoms and causes. Mayo Clinic. Updated September 15, 2025. Accessed September 4, 2026. https://www.mayoclinic.org/diseases-conditions/churg-strauss-syndrome/symptoms-causes/syc-20353760
24. Mayo Clinic Staff. Henoch-Schönlein purpura: symptoms and causes. Mayo Clinic. Updated September 19, 2025. Accessed September 4, 2026. https://www.mayoclinic.org/diseases-conditions/henoch-schonlein-purpura/symptoms-causes/syc-20354040
25. Yeung WWY, Wong SM, Au EYL, Li PH. Behçet's disease diagnosed by allergy skin testing and positive pathergy test. *J Allergy Clin Immunol Pract.* 2021;9(4):1715-1716. doi:10.1016/j.jaip.2020.11.029.

61

Resources

26. Figure 7. Cutaneous vasculitis of the ankle region. Adapted from Rosser1954. *Cutaneous vasculitis, ankle area*. Wikimedia Commons. Accessed August 30, 2026. https://commons.wikimedia.org/w/index.php?title=Special%3AMediaSearch&type=image&search=cutaneous+vasculitis
27. Brown RJ Jr, Trueman T. Mayo Clinic values [video]. Mayo Clinic History & Heritage. Accessed September 3, 2026. https://history.mayoclinic.org/mayo-clinic-values
28. Thornton E, Mendiratta-Lala M, Siewert B, Eisenberg RL. Patterns of fat stranding. *AJR Am J Roentgenol*. 2011;197(1):W1-W14. doi:10.2214/AJR.10.4375
29. Figure 8. Adapted from DePace DM. *Celiac trunk and branches* [image]. Wikimedia Commons. Published April 2, 2019. Licensed under CC BY-SA 4.0. Accessed September 2, 2026. https://commons.wikimedia.org/w/index.php?title=Special%3AMediaSearch&type=image&search=Celiac+trunk+and+branches

62

© Copyright. Society of Diagnostic Medical Sonography. All Rights Reserved.