2026 SDMS Annual Conference

Ectopic Pregnancies: Inside and Outside the Uterus

Lindsay Akers, RDMS
Advance Practice Sonographer
Michigan Medicine, University of Michigan
Lead, APS & Sonographer Special Interest Group
Society of Radiologists in Ultrasound
Go Blue!

1

No Disclosures.

2

© Copyright. Society of Diagnostic Medical Sonography. All Rights Reserved.

SPEAKER PRESENTATION DISCLAIMER

The content and views presented are made available for educational purposes only. The information presented are the opinions of the presenter and do not necessarily represent the views of the Society of Diagnostic Medical Sonography (SDMS) or its affiliated organizations, officers, Boards of Directors, or staff members.

The presenter is responsible for ensuring balance, independence, objectivity, scientific rigor, and avoiding commercial bias in their presentation. Before making the presentation, the presenter is required to disclose to the audience any relevant financial interests or relationships with manufacturers or providers of medical products, services, technologies, and programs.

The SDMS and its affiliated organizations, officers, Board of Directors, and staff members disclaim any and all liability for all claims that may arise out of the use of this educational activity.

3

Learning Objectives

Upon Completion You Will Be Able To:

Apply
SRU 1st Tri Lexicon
Better Assess Pregnancy Location

Differentiate
Normal IUPs
EPs
PUL

Recognize
Tubal
Interstitial
C- Sec Scar

Use
Diagnostic Signs Improve Detection & Characterization of EP

Avoid
Pitfalls in Early Pregnancy Imaging

4

© Copyright. Society of Diagnostic Medical Sonography. All Rights Reserved.

2026 SDMS Annual Conference

White Paper Discussion







Rodgers SK, Horrow MM, Doubilet PM, Frates MC, Kennedy AM, Morgan TA, Kamaya A, Maturen KE, et al. A Lexicon for First-Trimester US: Society of Radiologists in Ultrasound Consensus Conference Recommendations. Radiology. 2024;312(2). doi:10.1148/radiol.240122

5

First-Trimester Ultrasound (US) Lexicon 4 Major Categories:



Rodgers SK, Horrow MM, Doubilet PM, Frates MC, Kennedy AM, Morgan TA, Kamaya A, Maturen KE, et al. A lexicon for first-trimester US: Society of Radiologists in Ultrasound Consensus Conference recommendations. Radiology. 2024;312(2). doi.10.1148/radiol.240122.

6

© Copyright. Society of Diagnostic Medical Sonography. All Rights Reserved.

Intrauterine Pregnancy: Definitive versus Probable

GS visualized around 5 weeks GA (hyperechoic rim of trophoblastic tissue)

Probable



(-) YS/Embryo
- Round, *DDS* or *IDS*
- β-hCG: 3,000 mIU/mL

Definitive

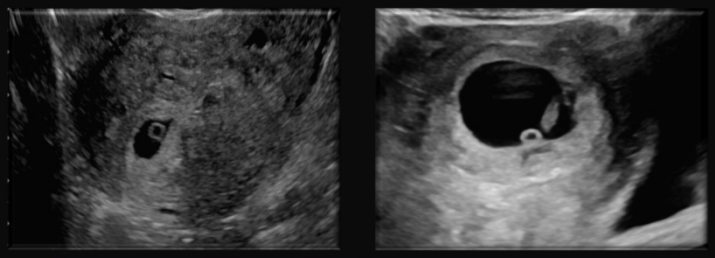

(+) YS/Embryo
- β-hCG: 7,000 mIU/mL (YS), 11,000 mIU/mL (embryo)
- MSD: 8 mm (YS) and 16 mm (embryo)

Bree RL, Edwards M, Böhm-Vélez M, Beyler S, Roberts J, Mendelson EB. Transvaginal sonography in the evaluation of normal early pregnancy: correlation with HCG level. AJR Am J Roentgenol. 1989;153(1):75-79. doi:10.2214/AJR.153.1.75.

7

Probable GS Helpful Identifier: Intradecidual Sign

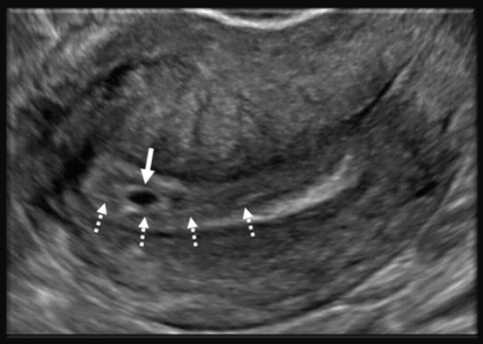

- GS is located to side of the inner interface
- Within the endometrial wall
- *Not in the endometrial cavity*

Rodgers S, et al. A Lexicon for First-Trimester US: Society of Radiologists in Ultrasound Consensus Conference Recommendations. Radiology Volume 312 Number 2 , August 27 2024. doi 10.1148/radiol.240122

8

© Copyright. Society of Diagnostic Medical Sonography. All Rights Reserved.

Probable GS Helpful Identifier: Double Decidual Sign



Two Concentric Rings Around an Oval Fluid Collection:

- Inner-echogenic ring is the trophoblastic chorion and decidua capsularis.
- Outer-echogenic ring is the decidual vera and endometrial lining.

Rodgers SK, Horrow MM, Doubilet PM, Frates MC, Kennedy AM, Morgan TA, Kamaya A, Maturen KE, et al. A lexicon for first-trimester US: Society of Radiologists in Ultrasound Consensus Conference recommendations. Radiology. 2024;312(2). doi:10.1148/radiol.240122.

9

DD Sign: Practical Application

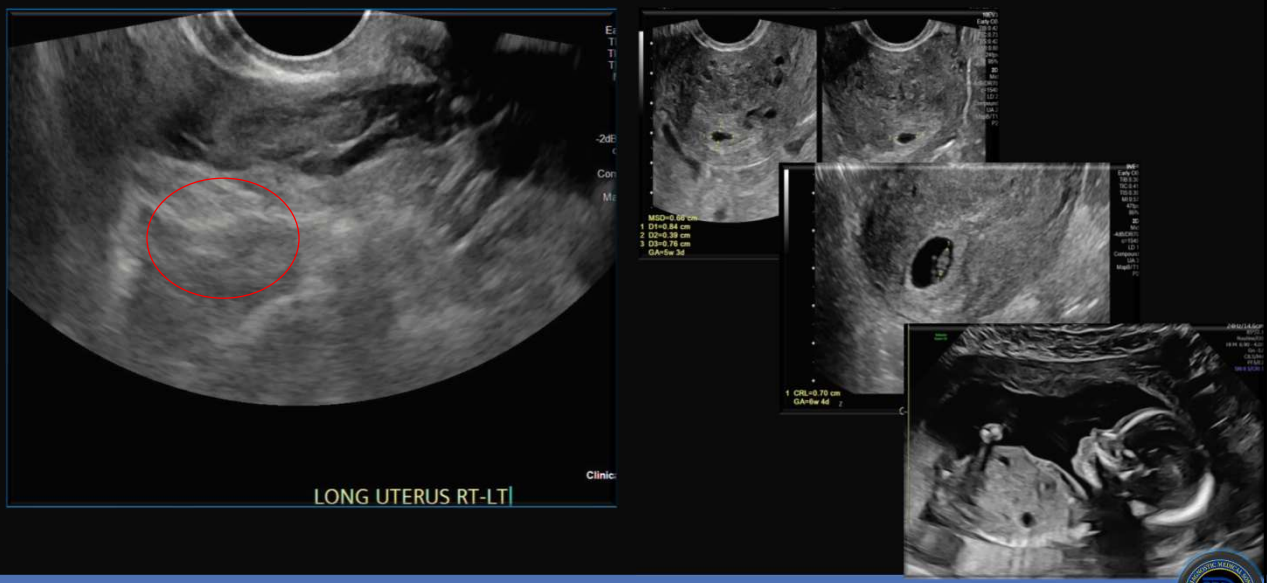

Stay cool…Adenomyosis in Pregnancy

10

© Copyright. Society of Diagnostic Medical Sonography. All Rights Reserved.

Understanding Term: Pregnancy of Unknown Location (PUL)

- Positive β-hCG *(Remember GS often seen around 3000 or higher)*
- No definitive or probable IUP
- No definitive or probable ectopic pregnancy
- *Correlate with β-hCG levels*
- *Short-term follow-up ultrasound*
- *Ectopic precautions*

Rodgers SK, Horrow MM, Doubilet PM, Frates MC, Kennedy AM, Morgan TA, Kamaya A, Maturen KE, et al. A lexicon for first-trimester US: Society of Radiologists in Ultrasound Consensus Conference recommendations. Radiology. 2024;312(2). doi:10.1148/radiol.240122.

11

Pregnancy Location:
Ectopic Pregnancies

Occur in 2% of all pregnancies

Vadakekut ES, Gnugnoli DM. Ectopic Pregnancy. In: StatPearls. Treasure Island (FL): StatPearls Publishing; March 27, 2025

12

© Copyright. Society of Diagnostic Medical Sonography. All Rights Reserved.

Ectopic Pregnancy Locations:

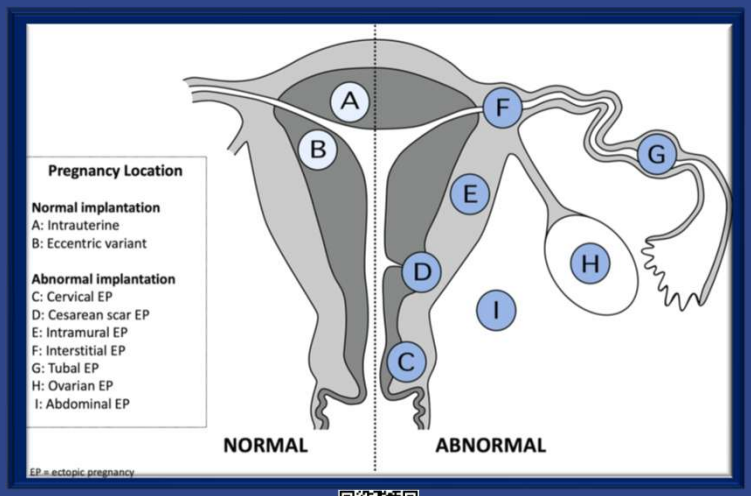

Rodgers SK, Horrow MM, Doubilet PM, Frates MC, Kennedy AM, Morgan TA, Kamaya A, Maturen KE, et al. A lexicon for first-trimester US: Society of Radiologists in Ultrasound Consensus Conference recommendations. Radiology. 2024;312(2). doi:10.1148/radiol.240122.

13

Tubal Ectopic: Most Common Location of EP

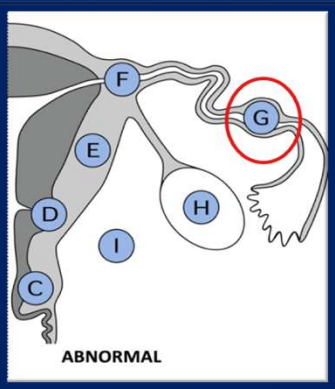

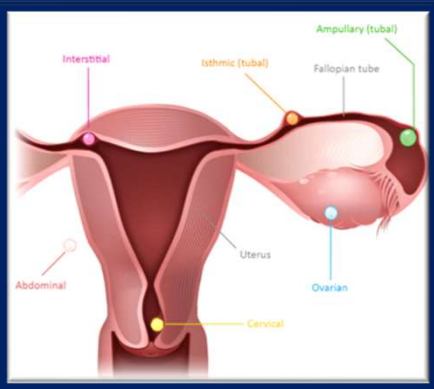

Tubal EP: 90%

- Ampulla: 70%
- Isthmus: 12%
- Fimbrae: 11%

Rodgers SK, Horrow MM, Doubilet PM, Frates MC, Kennedy AM, Morgan TA, Kamaya A, Maturen KE, et al. A lexicon for first-trimester US: Society of Radiologists in Ultrasound Consensus Conference recommendations. Radiology. 2024;312(2). doi:10.1148/radiol.240122.

The Ectopic Pregnancy Trust. Sites of ectopic pregnancy. Accessed August 10, 2026. https://www.ectopicpregnancy.co.uk/for-patients/sites-of-ectopic-pregnancy/

Cleveland Clinic. Ectopic pregnancy.. https://my.clevelandclinic.org/health/diseases/9687-ectopic-pregnancy . Accessed August 10, 2026

14

© Copyright. Society of Diagnostic Medical Sonography. All Rights Reserved.

Case 1

15

History:

Pregnant

GA by LMP: 6w 5d

No β-hCG levels

16

© Copyright. Society of Diagnostic Medical Sonography. All Rights Reserved.

Images: What do you think?



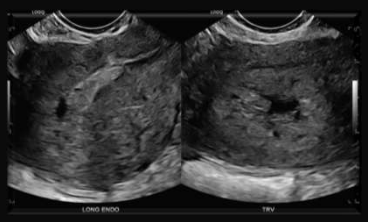





Is there an IUP?

Do you see the finding?



17

If you thought ectopic, you were right.



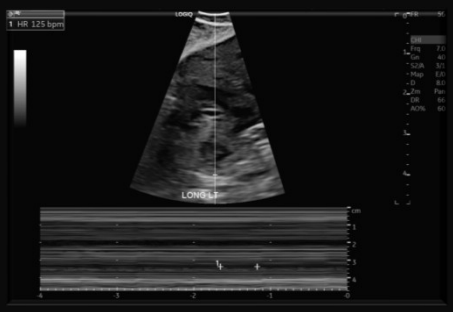

18

© Copyright. Society of Diagnostic Medical Sonography. All Rights Reserved.

Diagnosis

Definitive Tubal Ectopic Pregnancy:

- *Tubal Ring Sign*
- + YS and Embryo (CM)

Rodgers SK, Horrow MM, Doubilet PM, Frates MC, Kennedy AM, Morgan TA, Kamaya A, Maturen KE, et al. A lexicon for first-trimester US: Society of Radiologists in Ultrasound Consensus Conference recommendations. Radiology. 2024;312(2). doi:10.1148/radiol.240122.

19

Endometrial Cavity Fluid vs Gestational Sac

If you thought this was an early GS, look again.

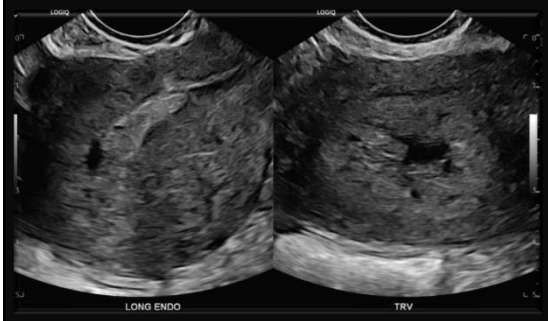

Key Point - No Definitive or Probable GS.

No *definitive* or *probable* GS

No Intra-Decidual Sign

No Double Decidual Sign

ECTOPIC
EPL
PUL





Rodgers SK, Horrow MM, Doubilet PM, Frates MC, Kennedy AM, Morgan TA, Kamaya A, Maturen KE, et al. A lexicon for first-trimester US: Society of Radiologists in Ultrasound Consensus Conference recommendations. Radiology. 2024;312(2). doi:10.1148/radiol.240122.

20

© Copyright. Society of Diagnostic Medical Sonography. All Rights Reserved.

Case 2

21

History

- Pregnant
- β-hCG - 7,771
- Recent bleeding

22

© Copyright. Society of Diagnostic Medical Sonography. All Rights Reserved.

Images



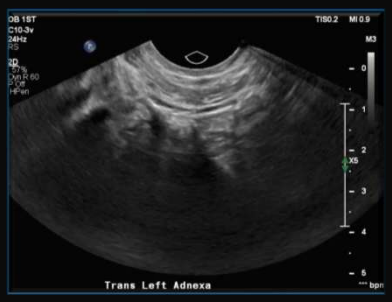

Gestational Sac or EC Fluid?

- ✓ EC Fluid

What 3 things do you see?

- ✓ Corpus Lutem
- ✓ Ectopic
- ✓ Hydrosalpinx





Helpful Distinction

- ✗ Peripheral vascularity
- ✓ Tubal Ring--Hyperechoic
- ✓ Corpus Lutem--Hypoechoic

Rodgers SK, Horrow MM, Doubilet PM, Frates MC, Kennedy AM, Morgan TA, Kamaya A, Maturen KE, et al. A lexicon for first-trimester US: Society of Radiologists in Ultrasound Consensus Conference recommendations. Radiology. 2024;312(2). doi:10.1148/radiol.240122.

23

What Else can help CL vs EP?

Sliding Sign!



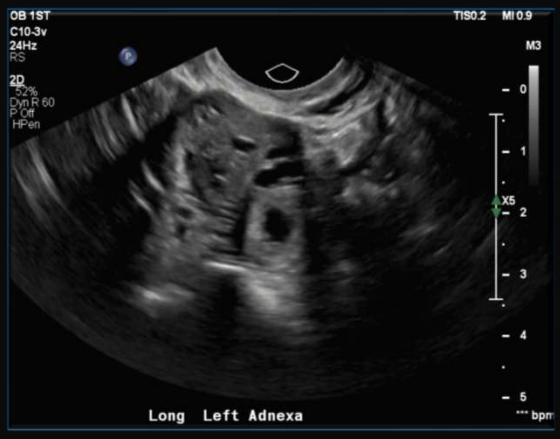

Literature Example

Case Example

Rodgers SK, Horrow MM, Doubilet PM, Frates MC, Kennedy AM, Morgan TA, Kamaya A, Maturen KE, et al. A lexicon for first-trimester US: Society of Radiologists in Ultrasound Consensus Conference recommendations. Radiology. 2024;312(2). doi:10.1148/radiol.240122.

24

© Copyright. Society of Diagnostic Medical Sonography. All Rights Reserved.

Diagnosis

Probable Tubal Ectopic Pregnancy:

- *Tubal Ring Sign*
- -YS and Embryo

25

Pitfall Case Coming! Don't Sink in the Quicksand…



Crane D. Pitfall! [video game]. Activision; 1982.

26

© Copyright. Society of Diagnostic Medical Sonography. All Rights Reserved.

Case 3

27

History

- Pregnant
- Evaluate for IUP

28

© Copyright. Society of Diagnostic Medical Sonography. All Rights Reserved.

Images









IMPRESSION:

1. Findings of heterotopic pregnancy, as described.

2. Intrauterine pregnancy with estimated gestational age of 7 weeks 1 day. Fetal cardiac activity with heart rate of 136 bpm.

3. Left ovarian ectopic pregnancy. Gestational sac and embryo in the left ovary, without cardiac activity. No definite findings of rupture at this time, though trace free fluid surrounds the left ovary.

++++++++++++++++++++++++++++

Results notification initiated in MiChart Results Tracking.

++++++++++++++++++++++++++++

Today's differential diagnosis reviewed, including left ovarian heterotopic pregnancy vs complex left corpus luteal cyst. While cardiac activity is not present, and definitive fetal pole and yolk sac not seen, today's imaging characteristics favor left ovarian heterotopic pregnancy within the left ovary due to possible early amnion and fetal pole. There is a vascular ring surrounding this structure, which is non-specific and can be seen with either diagnosis.

29

Discussion

Risk of Heterotopic Pregnancy: 0.006 to 0.025% (0.6 – 2.5 in 10,000 pregnancies)

Risk of Ovarian Ectopic: 0.5% to 1% of all ectopics (1 in 7000 - 40,000)



Bouab M, et al. Diagnosis and management of ectopic pregnancy: a rare case report. Int J Surg Case Rep. 2021;91:106742. doi:10.1016/j.ijscr.2021.106742.

Noor N, Firdous N, Bilal S. Heterotopic pregnancy with successful outcome. J Hum Reprod Sci. 2012;5(2):213-214. doi:10.4103/0974-1208.101024.

Step Brothers [motion picture]. Columbia Pictures; 2008.

30

© Copyright. Society of Diagnostic Medical Sonography. All Rights Reserved.

Discussion

ADDENDUM- (general USN)

After discussion with the clinical team and review of the images, the differential diagnosis for the left ovarian finding could include a corpus luteum. Factors that would be suggestive for a corpus luteum include the lack of a detectable embryonic cardiac rate and no abnormal free fluid within the pelvis.

Noor N. et al. Heterotopic Pregnancy with Successful Outcome. J Hum Reprod Sci. 2021 May-Aug; 5(2):213-214. doi:104103/0974-1208.101024

Bouab M et al. Diagnosis and Management of Ectopic Pregnancy: A Rare Case Report. Int J Surg Rep.2021 Dec 29;91:106742.doi:10/1016/j.jscr.2021.106742

31

Discussion

- Patient Desired Surgical Management with Laparoscopic Ovarian wedge resection
- Pathology report - Corpus Luteum Cyst
- Additional Note - Seen at Outside ED 18 days Later. Reported Heavy Bleeding. Stopped Progesterone After Surgery (suicidal feelings).
- Lost to Follow-Up

32

© Copyright. Society of Diagnostic Medical Sonography. All Rights Reserved.

Diagnosis

- Normal Definitive IUP
- Left Ovarian Corpus Luteal Cyst with Focal Clot

33

One last thought about a pregnancy in the adnexa:

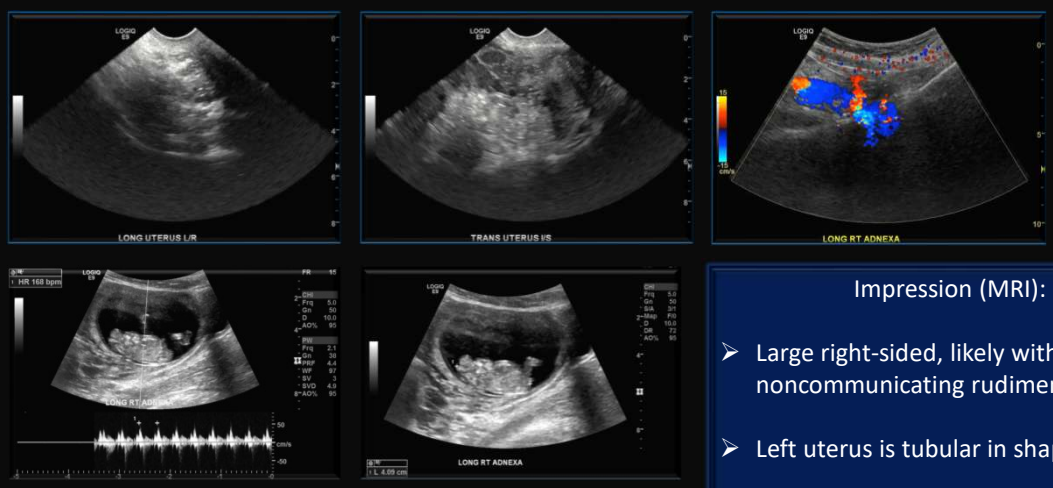

Impression (MRI):

- Large right-sided, likely within a noncommunicating rudimentary horn.
- Left uterus is tubular in shape.
- No signs of ectopic rupture.

34

© Copyright. Society of Diagnostic Medical Sonography. All Rights Reserved.

Diagnosis

Unicornuate Uterus with GS in Right Rudimentary Horn



Hysteronews. Unicornuate uterus. Published April 17, 2019. https://hysteroscopynewsletter.com/2019/04/17/unicornuate-uterus/ Accessed August 10, 2026.

35

Interstitial Ectopic: Rare

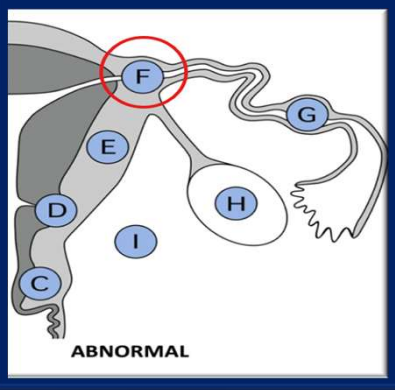

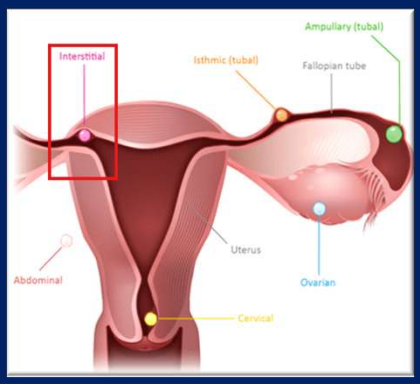

IEPs: 2-6%

- Mortality rate: 2-5%
- Not many cases/year
- Challenge: High!

Rodgers SK, Horrow MM, Doubilet PM, Frates MC, Kennedy AM, Morgan TA, Kamaya A, Maturen KE, et al. A lexicon for first-trimester US: Society of Radiologists in Ultrasound Consensus Conference recommendations. Radiology. 2024;312(2).doi:10.1148/radiol.240122

Cleveland Clinic. Ectopic pregnancy. Cleveland Clinic. Accessed August 11, 2026. https://my.clevelandclinic.org/health/diseases/9687-ectopic-pregnancy

The Ectopic Pregnancy Trust. Sites of ectopic pregnancy. The Ectopic Pregnancy Trust. Accessed August 11, 2026. https://www.ectopicpregnancy.co.uk/for-patients/sites-of-ectopic-pregnancy/

Brincat M, Bryant-Smith A, Holland TK. The diagnosis and management of interstitial ectopic pregnancies: a review. Gynecol Surg. 2019;16(1):2. doi:10.1186/s10397-018-1054-4.

36

© Copyright. Society of Diagnostic Medical Sonography. All Rights Reserved.

Helpful Identifier: Interstitial Line Sign



- Rarely Encountered
- Myometrium Between GS and Endometrium

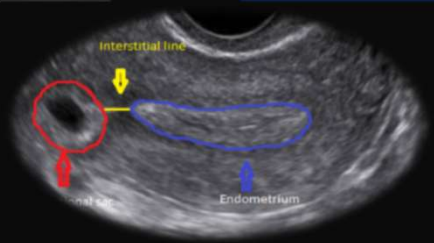

Radiopaedia. Interstitial line sign.. https://radiopaedia.org/articles/interstitial-line-sign. Accessed August 10, 2026
Rodgers SK, Horrow MM, Doubilet PM, Frates MC, Kennedy AM, Morgan TA, Kamaya A, Maturen KE, et al. A lexicon for first-trimester US: Society of Radiologists in Ultrasound Consensus Conference recommendations. Radiology. 2024;312(2). doi:10.1148/radiol.240122.

37

Helpful IP Identifier: Claw Sign



- 3D reformat is helpful
- Myometrium partly surrounds GS indicating implantation is at interstitial part of the tube

Rodgers SK, Horrow MM, Doubilet PM, Frates MC, Kennedy AM, Morgan TA, Kamaya A, Maturen KE, et al. A lexicon for first-trimester US: Society of Radiologists in Ultrasound Consensus Conference recommendations. Radiology. 2024;312(2). doi:10.1148/radiol.240122.

38

© Copyright. Society of Diagnostic Medical Sonography. All Rights Reserved.

Helpful IEP Identifier: 5 mm of Myometrium

Endo-myometrial Mantle (EMM): Myometrium surrounding the GS

- EMM < 5 mm is highly suspicious for interstitial pregnancy.
- Measurement taken from the outer edge of the sac's decidua to the uterine serosa.



Image contributed by: Dr Laughlin Dawes

Lewiss RE, Shaukat N, Saul T. The endomyometrial thickness measurement for abnormal implantation evaluation by pelvic sonography. J Ultrasound Med. 2014;33(7):1143-1146. doi:10.7863/ultra.33.7.1143.

39

Helpful IEP Identifier: Why <5 mm Matters

Normal IUPs → Thick, Protective Myometrial Layer

IEPs Implant Interstitial Tube → Thin Myometrium

EMM < 5 mm Strongly Indicates → Interstitial Implantation

40

© Copyright. Society of Diagnostic Medical Sonography. All Rights Reserved.

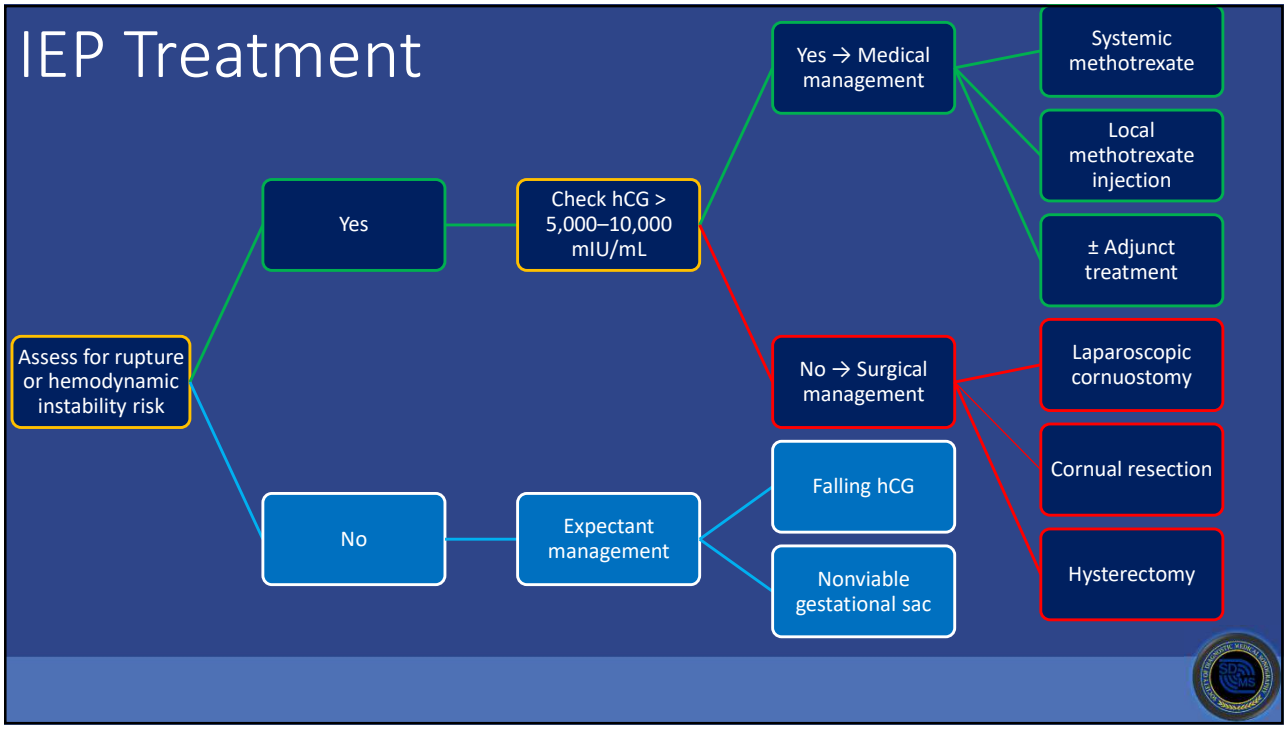

41

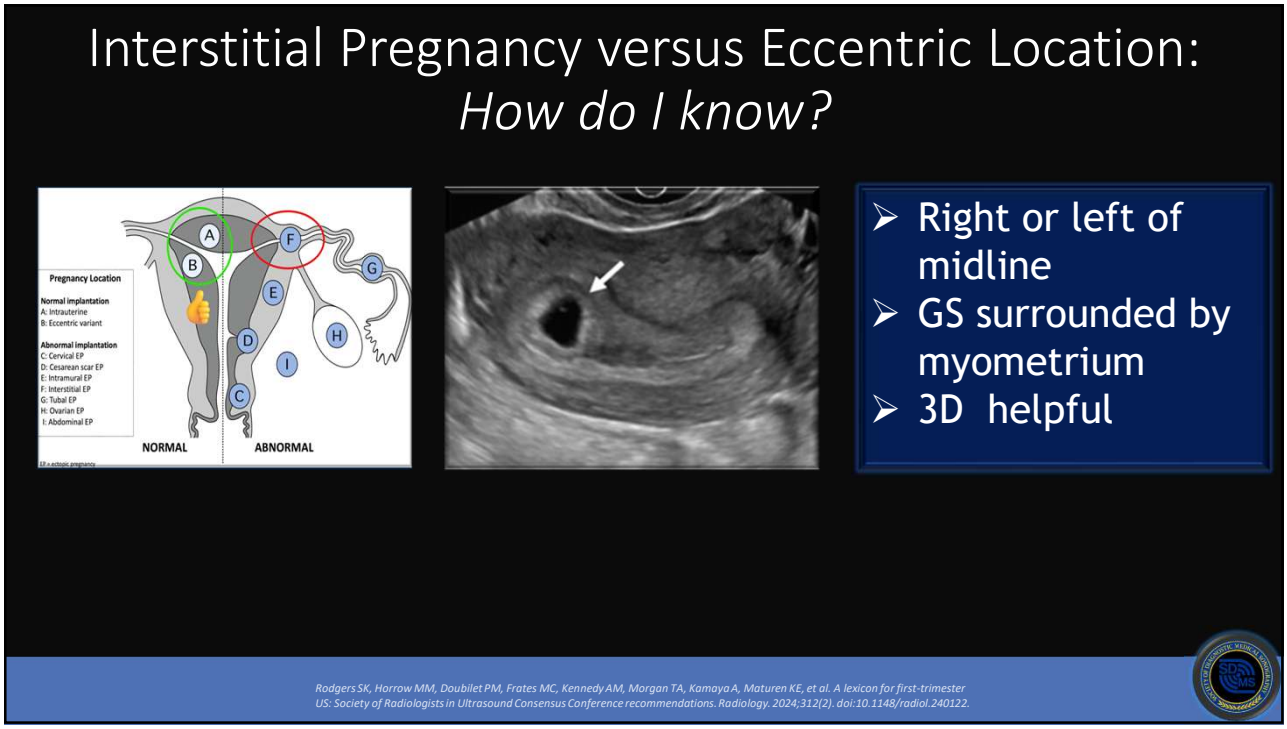

42

© Copyright. Society of Diagnostic Medical Sonography. All Rights Reserved.

Case 4

43

History

- Pregnant
- Suprapubic pain, pressure

44

© Copyright. Society of Diagnostic Medical Sonography. All Rights Reserved.

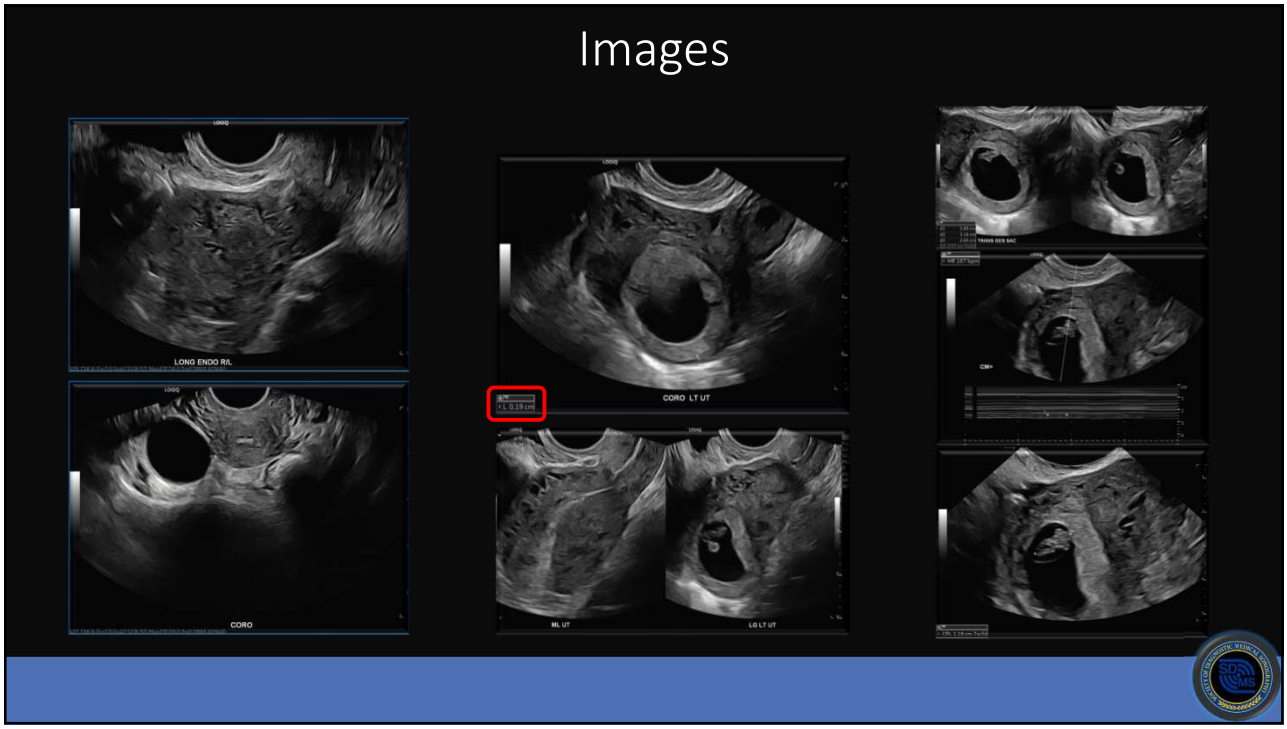

45

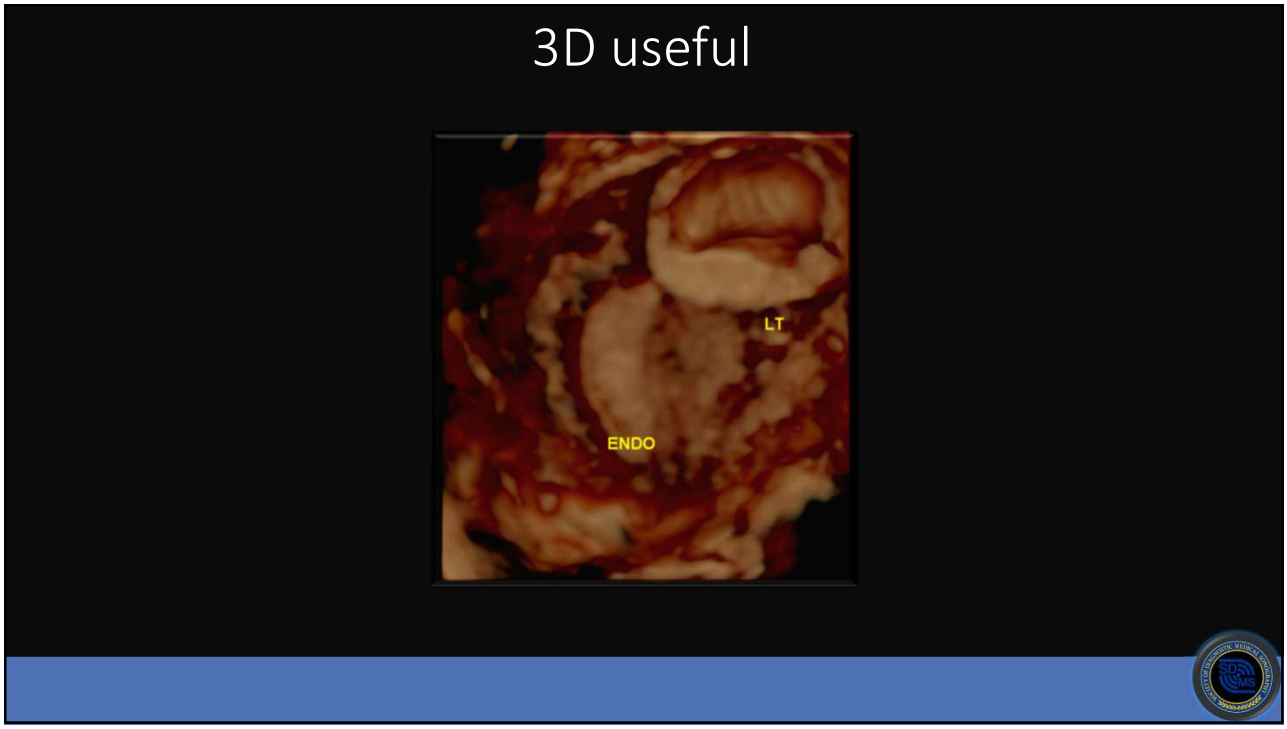

46

© Copyright. Society of Diagnostic Medical Sonography. All Rights Reserved.

Diagnosis

Definitive Left Interstitial Ectopic Pregnancy

- GS, +YS and embryo
- CRL, 7 weeks 3 days (CRL)
- Cardiac rate, 167 bpm



Treatment: Left cornual wedge resection and left salpingectomy

47

Case 5

48

© Copyright. Society of Diagnostic Medical Sonography. All Rights Reserved.

History

Abnormal Rise of β-hCG levels. Concern for ectopic.

β-hCG Trend Summary

Date	β-hCG Level (mIU/mL)
Jan 29	510
Feb 4	290
Feb 5	317
Feb 8	505
Feb 10	667
Feb 12	869

49

Images

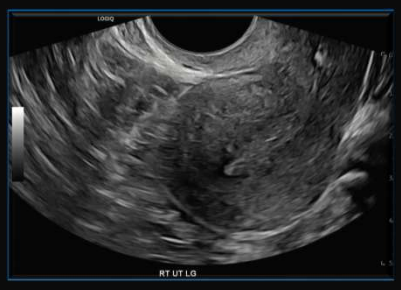

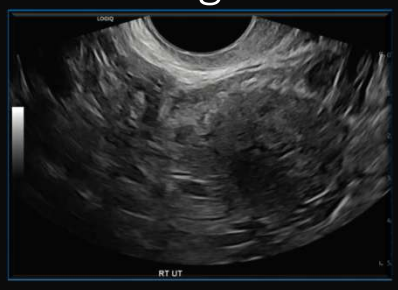



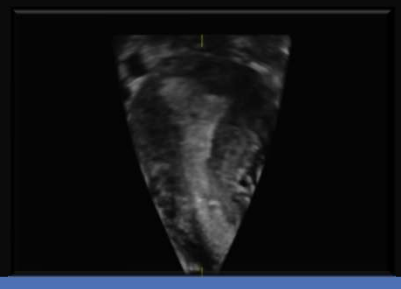
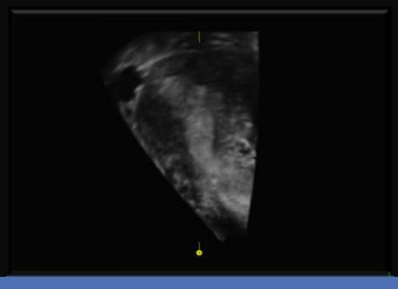


50

© Copyright. Society of Diagnostic Medical Sonography. All Rights Reserved.

Report Comparison:

Ultrasound

Impression:

- No intrauterine pregnancy identified.
- Small right cornual soft-tissue thickening with hypervascularity → possible early interstitial ectopic.
- Patient directed to the emergency department.

Outside MRI (11 days later)

Impression:

- T2-hyperintense lesion in the right interstitial fallopian tube, compatible with an ectopic pregnancy.

51

Diagnosis

Probable Right Interstitial Ectopic Pregnancy

- YS and Embryo

(Nice pick-up Christine!)



Admitted and Daily Methotrexate (β-hCG 3172)

52

© Copyright. Society of Diagnostic Medical Sonography. All Rights Reserved.

Key Points: Interstitial Ectopic Discussion

5 mm of Myometrium (sac to surface)

Interstitial Line Sign

Eccentric Location

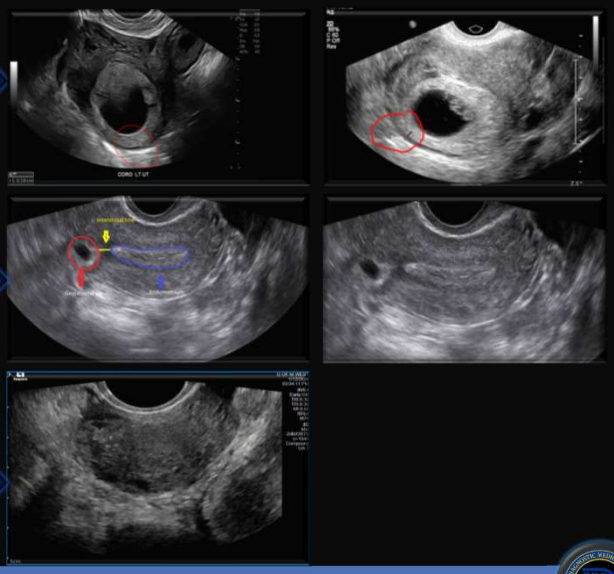

Gaillard F, et al. Interstitial ectopic pregnancy. Radiopaedia.org. Accessed September 7, 2026. https://radiopaedia.org

53

Cervical and Caesarean Scar Ectopic: Rare

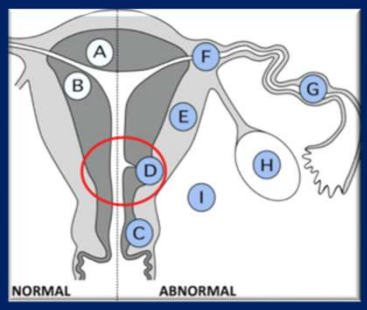

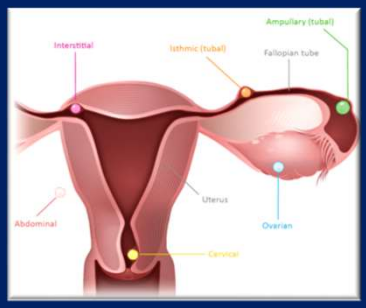

C-Sec EP: 4-6 % of all EP

- Cervical EP (No CS) - 1 in 1800-2656
- Cervical EP (C-Sec) - 1 in 500-2000
- Increased bleeding risk, if ruptures
- Diagnosis difficult!

Kennedy AM, et al. Cesarean scar ectopic pregnancy: a do-not-miss diagnosis. RadioGraphics. 2024;44(7). doi:10.1148/rg.230199.

The Ectopic Pregnancy Trust. Sites of ectopic pregnancy https://www.ectopicpregnancy.co.uk/for-patients/sites-of-ectopic-pregnancy/. Accessed August 11, 2026.

54

© Copyright. Society of Diagnostic Medical Sonography. All Rights Reserved.

Case 6

55

History

- Vaginal bleeding
- β-hCG 7652 (3 days prior)
- Prior c-section

56

© Copyright. Society of Diagnostic Medical Sonography. All Rights Reserved.

Images

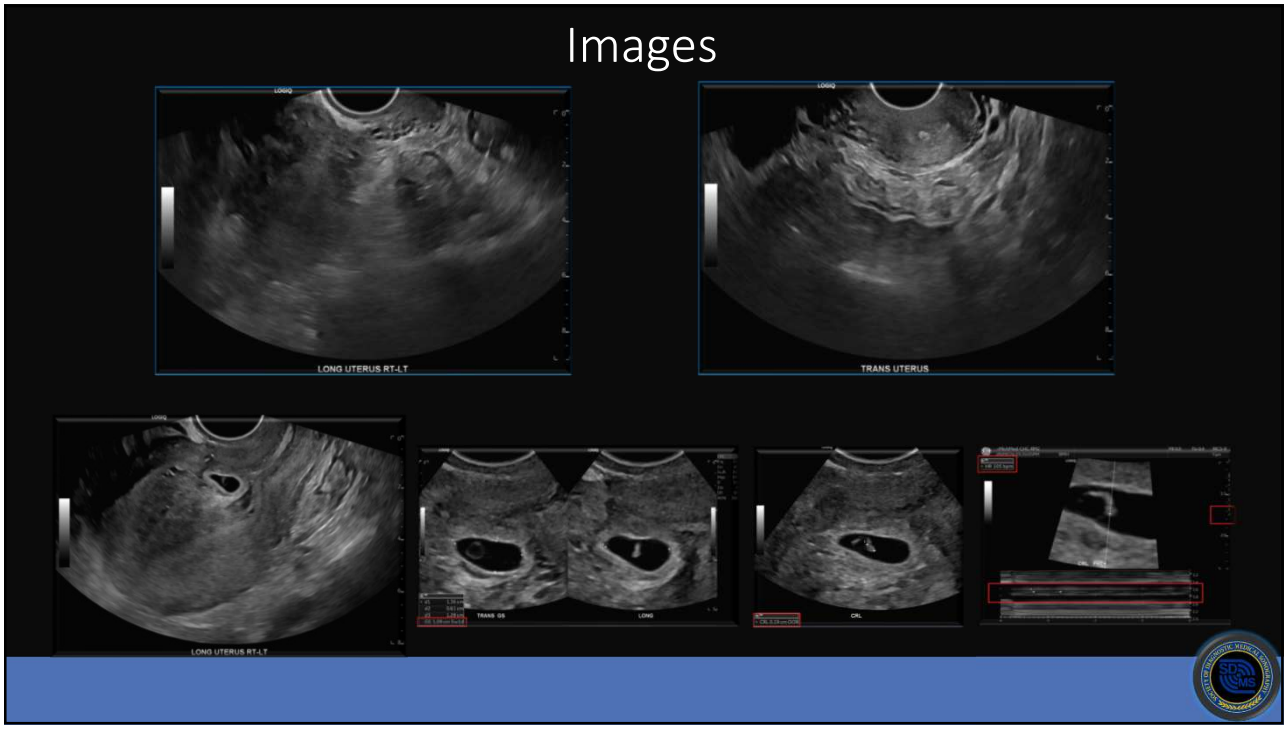

57

Differential Diagnosis

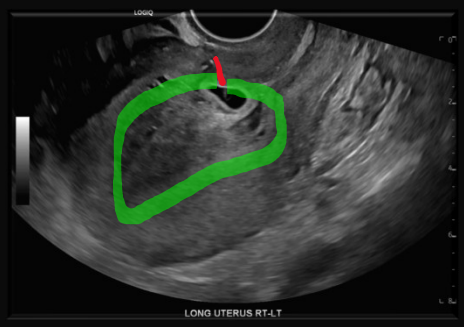

Cesarean Scar Ectopic Pregnancy

or

Low Lying Pregnancy Displaced by Bleed vs EPL in Progress

58

© Copyright. Society of Diagnostic Medical Sonography. All Rights Reserved.

Treatment:

Manual Vacuum Aspiration (MVA) Without Complication

59

Case 7

60

© Copyright. Society of Diagnostic Medical Sonography. All Rights Reserved.

History

- Pregnant with spotting
- LMP 6 weeks ago
- Prior C-Section

61

Images







- Possible Dichorionic Twins (Lambda Sign)
  - Superior Sac + Embryo and CM
  - Lower Sac Near C-section Scar: Small, No POC → Concern for EPL vs CSEP
- Repeat Ultrasound in 7–10 Days to Reassess and Confirm Location

62

© Copyright. Society of Diagnostic Medical Sonography. All Rights Reserved.

3 days later scanned in FDC…

- Evaluated for possible cesarean scar pregnancy
- Two intrauterine gestational sacs identified
  - ✓ One empty (maternal left)
  - ✓ One with yolk sac, embryo, and cardiac motion
- Ample surrounding myometrium
- No concern for cesarean scar pregnancy; findings reassuring

63

Images





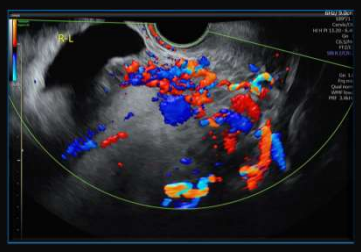

Placenta Previa
Placenta Accreta Spectrum:

On Grey-Scale:
- Abnormal Placental Lacunae (Swiss cheese)
- Loss of the "Clear Zone"
- Placental Bulge

On Color Doppler:
- Uterovesical Hypervascularity
- Sub-Placental Hypervascularity

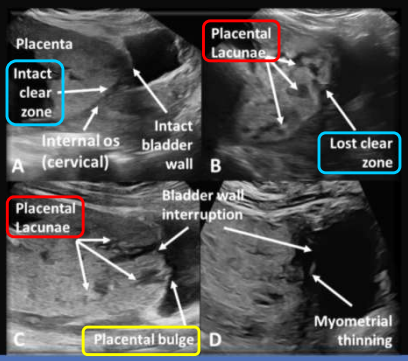

Srinivasan D, et al. Expert opinion: stepwise ultrasound assessment of suspected placenta accreta spectrum using 2D, Doppler, and 3D imaging. Eur J Obstet Gynecol Reprod Biol. 2022;270:181-189.

64

© Copyright. Society of Diagnostic Medical Sonography. All Rights Reserved.

Additional Info:

- Massive Hemorrhage
- Emergency Cesarean Section
- Complicated by Accreta and Previa
- REBOA (Resuscitative Endovascular Balloon Occlusion of the Aorta)- Used to stop hemorrhage, buy surgeons time, and preserve blood to the brain and heart
- Massive Transfusion Protocol
  - 10 u RBC
  - 9 u Frozen Plasma
  - 3 g Fibrogen
  - TXA (transexamic Acid) - Prevents breakdown of clots
- Hysterectomy and Bilateral Salpingectomy

65

Let's pause and briefly discuss this paper, to better understand this case.





Kennedy AM, et al. Cesarean scar ectopic pregnancy: a do-not-miss diagnosis. RadioGraphics. 2024;44(7). doi:10.1148/rg.230199

66

© Copyright. Society of Diagnostic Medical Sonography. All Rights Reserved.

Cesarean and Cervical GS Implantations: Abnormal and Ectopic

Exogenic Growth

- Deep implantation with growth beyond the uterine serosa (serosa line red)
- Extends toward the bladder or abdominal cavity
- Higher risk of early rupture
- Increased association with placenta accreta spectrum (PAS)



Endogenic Growth

- Implantation at prior hysterotomy site
- Growth extends toward the uterine cavity
- Often delayed diagnosis; possible live birth
- Increased risk of PAS, severe hemorrhage, and hysterectomy

Kennedy AM, et al. Cesarean scar ectopic pregnancy: a do-not-miss diagnosis. RadioGraphics. 2024;44(7). doi:10.1148/rg.230199

67

Now, let's revisit our case…

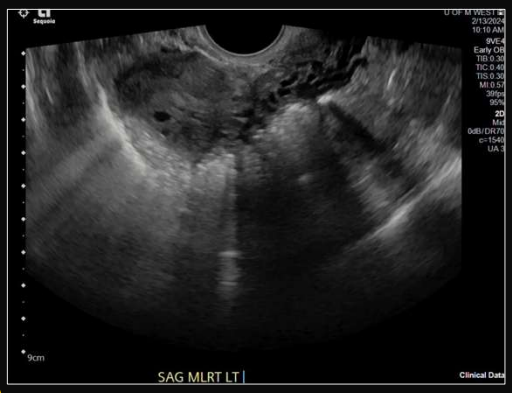

Hmmmm
Normal or CSEP?



68

© Copyright. Society of Diagnostic Medical Sonography. All Rights Reserved.

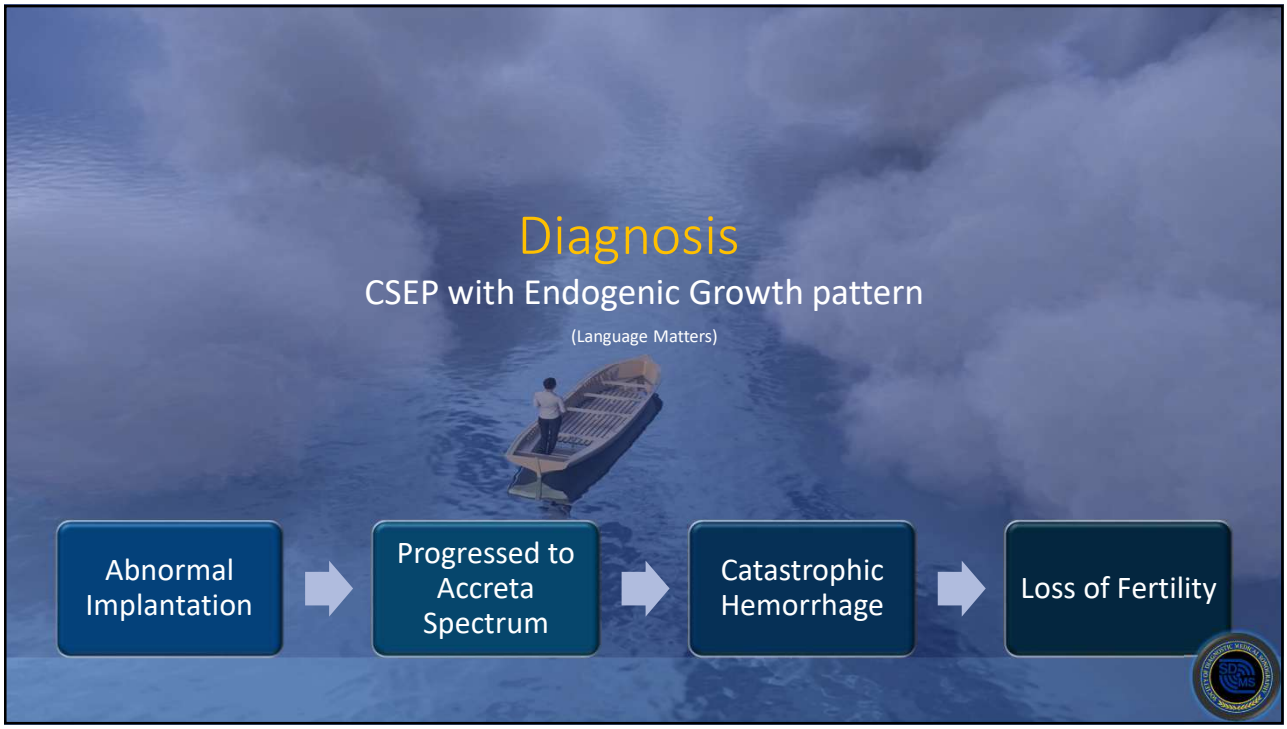

69



70

© Copyright. Society of Diagnostic Medical Sonography. All Rights Reserved.

Differential Diagnosis of CSEP

- Low Implantation of Normal Pregnancy
- Cervical Ectopic
- Evolving Pregnancy Loss

Kennedy AM, et al. Cesarean scar ectopic pregnancy: a do-not-miss diagnosis. RadioGraphics. 2024;44(7). doi:10.1148/rg.230199

71

Scanning and Reading TIPS :

CSEP vs CEP vs EPL in progress

- Ask about c-sec history
- Identify c-sec scar separate from GS
- Identify GS location in relation to scar
  - Superior to scar - Normal or low implantation
  - Inferior to scar and internal os – Cervical EP
- Measure myometrial thickness from edge of GS to edge of bladder serosa (<2mm)
- Look for hyperechoic rim of tissue surrounding GS
- Use doppler to look for GS peripheral flow and flow patterns around scar
  - Flow may be increased, mosaic, yin yang, reversed (AVF, pseudoaneurysm, large diameter arteries, vessels only/no myometrium-all reported with CSEP especially around 8-9 wks GA)
- GS shape
  - Flat with collapsed endometrial cavity, mobile/slides, no flow, or GS moved since prior study; suggests EPL in progress

Kennedy AM, et al. Cesarean scar ectopic pregnancy: a do-not-miss diagnosis. RadioGraphics. 2024;44(7). doi:10.1148/rg.230199.

72

© Copyright. Society of Diagnostic Medical Sonography. All Rights Reserved.

Caesarean Scar EP Doppler Example:

Exogenic growth with trophoblast beyond serosa

Severe enhanced myometrial vascularity

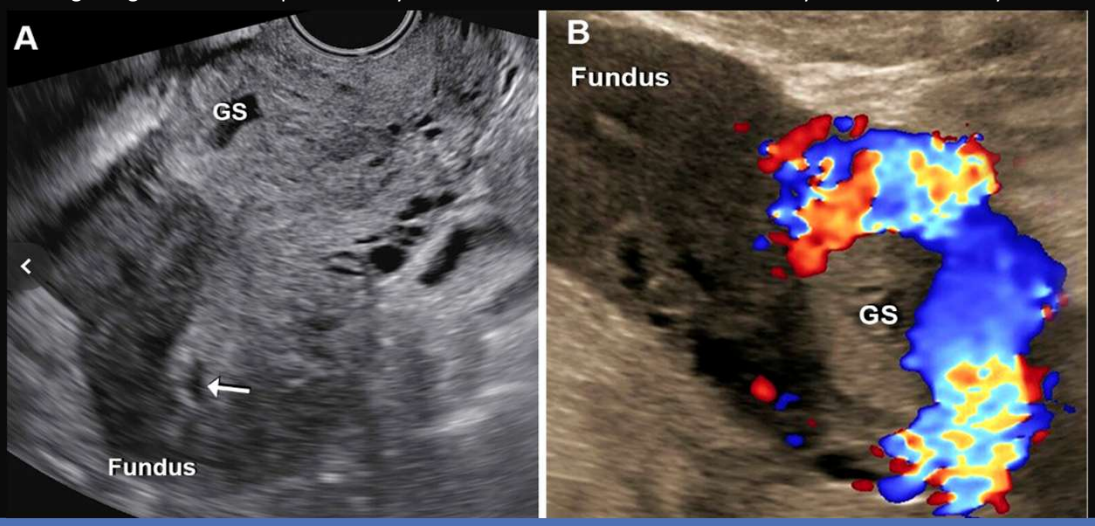

Kennedy AM, et al. Cesarean scar ectopic pregnancy: a do-not-miss diagnosis. RadioGraphics. 2024;44(7). doi:10.1148/rg.230199

73

Translation: Doppler to Gross Specimen to Hemorrhage

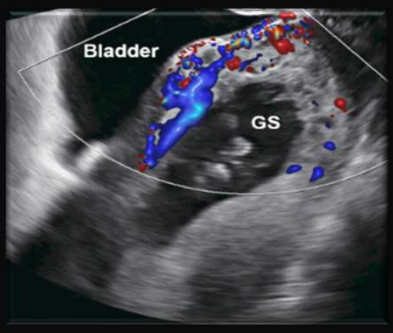

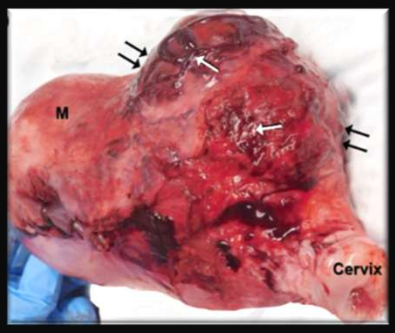

Vessels on the uterine surface contribute to hemorrhage at the time of cesarean hysterectomy.

Kennedy AM, et al. Cesarean scar ectopic pregnancy: a do-not-miss diagnosis. RadioGraphics. 2024;44(7). doi:10.1148/rg.230199

74

© Copyright. Society of Diagnostic Medical Sonography. All Rights Reserved.

Cervical EP Literature Example:

Implanted below the internal cervical os (IO)
Note decidualized endometrium (E)

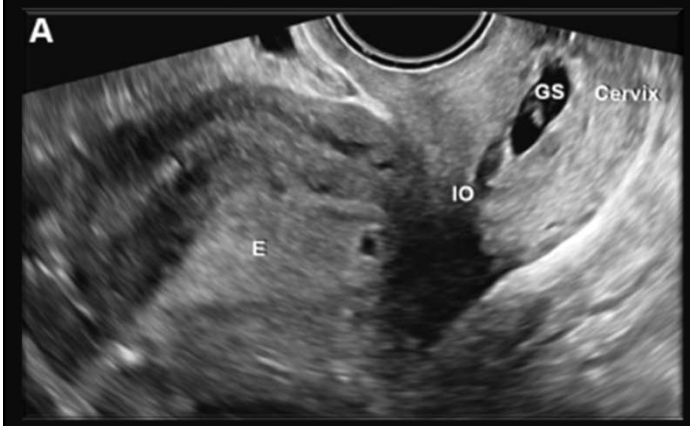

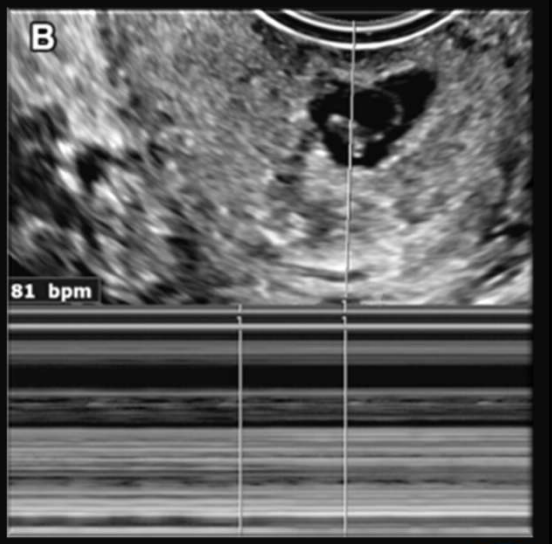

Kennedy AM, et al. Cesarean scar ectopic pregnancy: a do-not-miss diagnosis. RadioGraphics. 2024;44(7). doi:10.1148/rg.230199

75

EPL in Progress:

Flattened low GS in cavity
Collapsed endometrium

TIP: Remember to evaluate with color or power doppler

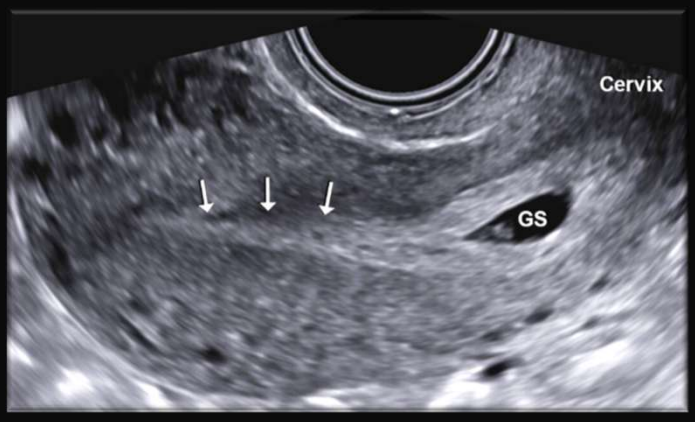

Kennedy AM, et al. Cesarean scar ectopic pregnancy: a do-not-miss diagnosis. RadioGraphics. 2024;44(7). doi:10.1148/rg.230199.

76

© Copyright. Society of Diagnostic Medical Sonography. All Rights Reserved.

EPL in Progress vs CEP/CSEP: Slide Sign

FEATURE	POSITIVE SLIDING SIGN	NEGATIVE SLIDING SIGN
Sac Mobility	Moves/slides with gentle probe pressure	Fixed/immobile sac
Location	Within cervical canal; not implanted	Implanted in cervical tissue possible
Internal os	Usually open	May be closed
Vascular Flow	Minimal/absent	Often increased
Clinical Implication	Suggests inevitable pregnancy loss	Consider cervical ectopic



Radiopaedia. Early pregnancy failure: gestational sac in cervical canal. https://radiopaedia.org/cases/early-pregnancy-failure-gestational-sac-in-cervical-canal .Accessed August 10, 2026.

77

Normal Implantation:

Identify the scar defect TA and/or TV GS will be superior to scar

TIP: Always monitor scar for accreta (PAS) on all exams and follow-ups



Kennedy AM, et al. Cesarean scar ectopic pregnancy: a do-not-miss diagnosis. RadioGraphics. 2024;44(7). doi:10.1148/rg.230199.

78

© Copyright. Society of Diagnostic Medical Sonography. All Rights Reserved.

Other Helpful Hints:

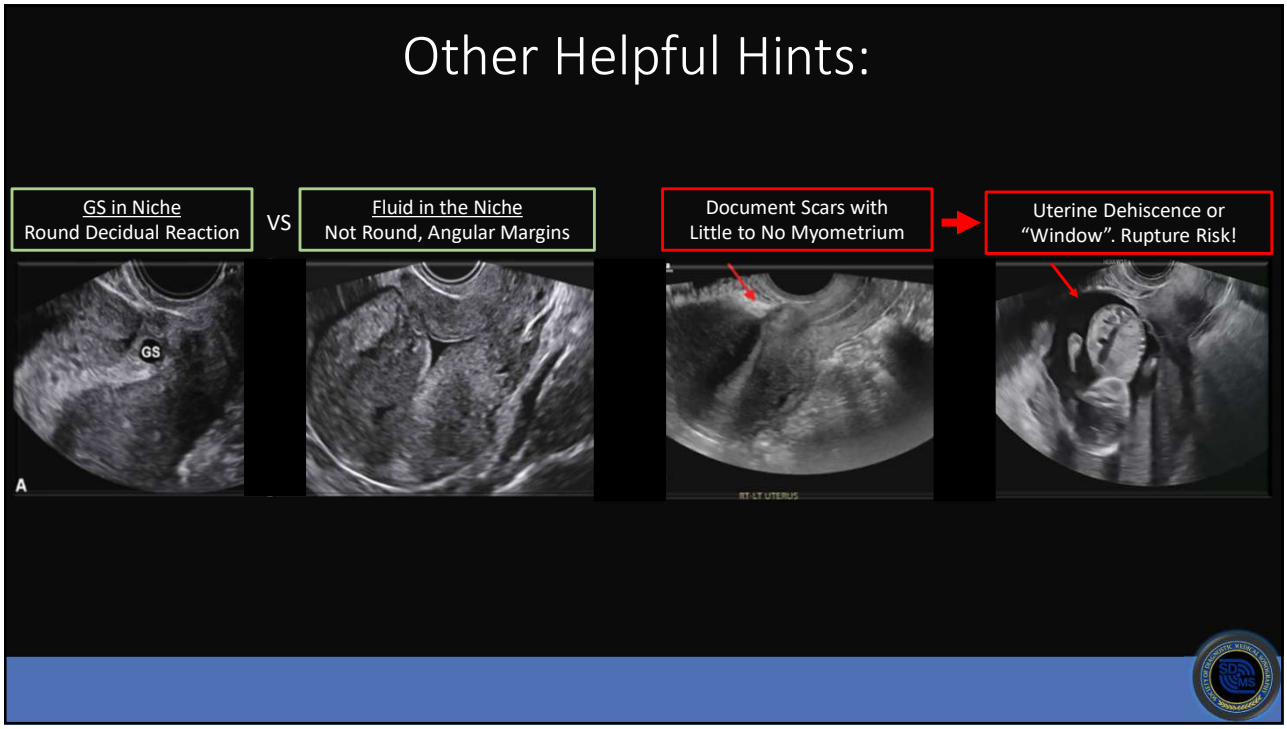

79

Key Takeaways:

USE	IDENTIFY	RECOGNIZE	KNOW
SRU Lexicon	Implantation Location	Ectopic Pregnancy Signs	Pitfalls & Mimics

80

© Copyright. Society of Diagnostic Medical Sonography. All Rights Reserved.

Early Diagnosis Improves Outcomes.

Language Matters. Location Matters.

Patient Outcomes Depend on Both.

81

References

1. Rodgers SK, Horrow MM, Doubilet PM, Frates MC, Kennedy AM, Morgan TA, Kamaya A, Maturen KE, et al. Radiology. 2024;312(2). doi:10.1148/radiol.240122.

2. Bree RL, et al. AJR Am J Roentgenol. 1989;153(1):75-79. doi:10.2214/AJR.153.1.75.

3. Vadakekut ES, Gnugnoli DM. Ectopic Pregnancy. In: StatPearls. Treasure Island (FL): StatPearls Publishing; March 27, 2025.

4. Brincat M, Bryant-Smith A, Holland TK. Gynecol Surg. 2019;16(1):2. doi:10.1186/s10397-018-1054-4.

5. Lewiss RE, Shaukat N, Saul T. J Ultrasound Med. 2014;33(7):1143-1146. doi:10.7863/ultra.33.7.1143.

6. Kennedy AM, et al. RadioGraphics. 2024;44(7). doi:10.1148/rg.230199.

7. Srinivasan D, et al. Eur J Obstet Gynecol Reprod Biol. 2022;270:181-189.

8. Bouab M, et al. Int J Surg Case Rep. 2021;91:106742. doi:10.1016/j.ijscr.2021.106742.

9. Noor N, Firdous N, Bilal S. J Hum Reprod Sci. 2012;5(2):213-214. doi:10.4103/0974-1208.101024.

10. Cleveland Clinic. Ectopic pregnancy. Accessed Aug 10, 2026.

11. The Ectopic Pregnancy Trust. Sites of ectopic pregnancy. Accessed Aug 10, 2026.

12. Gaillard F, et al. Interstitial ectopic pregnancy. Radiopaedia.org. Accessed September 7, 2026. https://radiopaedia.org

13. Radiopaedia. Early pregnancy failure: gestational sac in cervical canal.

14. Hysteronews. Unicornuate uterus. 2019.

Figure acknowledgments: Rodgers et al. Radiology 2024; Kennedy et al. RadioGraphics 2024.

With gratitude to the sonographers, researchers, clinicians, educators, and patients whose contributions have advanced our understanding of ectopic pregnancy and made this educational presentation possible.

82

© Copyright. Society of Diagnostic Medical Sonography. All Rights Reserved.



© Copyright. Society of Diagnostic Medical Sonography. All Rights Reserved.