2026 SDMS Annual Conference

Endometriosis: Crucial Clues You Can't Afford to Miss

Lindsay Akers, RDMS
Advance Practice Sonographer
Michigan Medicine, University of Michigan
Lead, APS & Sonographer Special Interest Group
Society of Radiologists in Ultrasound
Go Blue!

1

No Disclosures

2

© Copyright. Society of Diagnostic Medical Sonography. All Rights Reserved.

SPEAKER PRESENTATION DISCLAIMER

The content and views presented are made available for educational purposes only. The information presented are the opinions of the presenter and do not necessarily represent the views of the Society of Diagnostic Medical Sonography (SDMS) or its affiliated organizations, officers, Boards of Directors, or staff members.

The presenter is responsible for ensuring balance, independence, objectivity, scientific rigor, and avoiding commercial bias in their presentation. Before making the presentation, the presenter is required to disclose to the audience any relevant financial interests or relationships with manufacturers or providers of medical products, services, technologies, and programs.

The SDMS and its affiliated organizations, officers, Board of Directors, and staff members disclaim any and all liability for all claims that may arise out of the use of this educational activity.

3

GENERATIVE AI DISCLAIMER

The presenter utilized the use of large language models (LLMs) and generative artificial intelligence (AI) as a productivity tool to assist in drafting and refining content in this presentation.

While these tools can aid in structuring ideas, summarizing, paraphrasing, and language polishing, they have inherent limitations and cannot replace human creativity, critical thinking, or expert judgment. AI-generated content may contain errors, biases, or gaps in knowledge.

This presentation is intended for informational purposes only and should not be construed as definitive or authoritative guidance. Participants are encouraged to critically evaluate the information presented and consult relevant experts as needed. The SDMS and its affiliated organizations, officers, Board of Directors, and staff members disclaim any and all liability for claims that may arise from the use or interpretation of this educational material.

4

© Copyright. Society of Diagnostic Medical Sonography. All Rights Reserved.

In the USA, there is a delay longer than 7 years between the onset of symptoms and diagnosis of endometriosis.

-SRU consensus on Routine Pelvic US for Endometriosis

1 out of 10 reproductive women have endometriosis.

–Endometriosis Foundation Association

"More attention on endometriosis would accelerate a correct, earlier diagnosis."

-Dr. As-Sanie Director of U of M Endometriosis Pelvic Pain Clinic

5

Endometriosis

6

© Copyright. Society of Diagnostic Medical Sonography. All Rights Reserved.

Learning Objectives:

Recognize Key Clues of Endometriosis

Identify Findings of DIE

Apply Systematic Approach to the Posterior Compartment and Sliding Sign Evaluation

Incorporate Augmented Techniques Into Daily Practice

7

7-Year Diagnosis Delay

- Despite TVUS used worldwide as first-line imaging for pelvic pain and infertility
- Standardized Protocols (2016 International DE Analysis Group), remain underutilized in the U.S.

Why the Gap?

- Limited awareness of DE imaging techniques
- Lack of standardized protocols
- Inconsistent, non-systematic approach

Young SW, Jha P, Chamié L, et al. Society of Radiologists in Ultrasound Consensus on Routine Pelvic US for Endometriosis. Radiology. 2024;311(1):e232191. doi:10.1148/radiol.232191

8

© Copyright. Society of Diagnostic Medical Sonography. All Rights Reserved.

Solution: Society of Radiologists in Ultrasound Consensus on Routine Pelvic US for Endometriosis
Young et al. April 2024

Summary:

- Expert consensus to improve endometriosis detection
- Introduction of Augmented Pelvic Ultrasound
- Standardized observation + reporting system
- Clear imaging and management recommendations

Augmented Pelvic Ultrasound:

- Posterior compartment evaluation
- Position of the uterus and ovaries
- Uterine slide sign maneuver
- Additional technique - 5 minutes or less and decrease the delay of diagnosing endometriosis

Young SW, Jha P, Chamié L, et al. Society of Radiologists in Ultrasound Consensus on Routine Pelvic US for Endometriosis. Radiology. 2024;311(1):e232191. doi:10.1148/radiol.232191

9

Augmented Protocol Michigan Medicine

Table 4: Summary of Panel Consensus Recommendations for Augmented Pelvic US for Detection of Endometriosis

Recommendation Category	Recommendation Summary
Screening population	Perform augmented pelvic US only in premenopausal or early postmenopausal individuals (<5 years since the cessation of menses). Patients should have chronic pelvic pain symptoms, infertility, or clinically or radiographically suspected endometriosis. The panel does not recommend performing augmented maneuvers routinely for all pelvic US.
Augmented pelvic US technique	The panel unanimously agreed that an augmented pelvic US would have the greatest acceptance and impact in general US-based screening for DE. Additional imaging to enhance the detection of DE during augmented pelvic US focuses on the transvaginal evaluation of the posterior compartment, the relative positioning of the uterus and ovaries, and the uterine sliding sign. Transvaginal US is essential for screening detection of DE and transabdominal examination alone is insufficient. When transvaginal imaging is not feasible or technically inadequate, use expert MRI if there is high clinical suspicion for endometriosis. The panel does not recommend bowel preparation for augmented pelvic US.
Augmented pelvic US observations	Assess direct and indirect signs during augmented pelvic US.
Augmented pelvic US reporting and clinical recommendations	Report augmented pelvic US using four categories: incomplete (APU-0), normal (APU-1), equivocal (APU-2), and positive (APU-3). Any single direct imaging observation (category A) of endometriosis should lead to endometriosis diagnosis, recommendation for advanced endometriosis imaging, and referral to a reproductive endocrinologist and/or gynecologic surgeon familiar with DE, as appropriate. In the absence of category A observations, findings are suggestive of endometriosis when two or more indirect observations (category B) or one category B and one endometriosis-associated observation (category C) are noted; referral to gynecology for further evaluation and possible advanced endometriosis imaging is recommended. When only category C observations are present, a gynecology referral is appropriate. Given the nonspecific nature of these findings, advanced endometriosis imaging is not recommended but may be obtained if there is high clinical suspicion of endometriosis. Advanced endometriosis imaging consists of either expert US mapping of endometriosis following a prescribed pattern of search and/or endometriosis-specific MRI with expert interpretation (4,6,13,32,69).

Note.—APU = augmented pelvic US, DE = deep endometriosis.

Key Points:

- Perform on orders where endometriosis is written as an indication
- Do not perform maneuvers on routine pelvic ultrasound exam
- TV used to focus on posterior compartment
- Assess direct and indirect signs for DE

Young SW, Jha P, Chamié L, et al. Society of Radiologists in Ultrasound Consensus on Routine Pelvic US for Endometriosis. Radiology. 2024;311(1):e232191. doi:10.1148/radiol.232191

10

© Copyright. Society of Diagnostic Medical Sonography. All Rights Reserved.

What Are Direct and Indirect Observations?

Table 7: Direct and Indirect US Observations in Deep Endometriosis

Category and Observation
Category A: direct endometriosis observation
Ovarian endometrioma
DE implant of the uterine serosa with an outside-in pattern
Retrocervical DE (torus uterinus and/or USL) implant
Bladder DE implant in posterior location involving the detrusor muscle
DE implant in the uterovesical space
Rectovaginal space or rectovaginal septal DE implant
Rectosigmoid hypoechoic DE implant with tapering ends (other descriptors: Comet tail sign)
Category B: indirect endometriosis observation
Fixed uterine retroflexion
Bowel tethering to posterior uterus without discrete endometriosis implant in the absence of PID symptoms, inflammatory bowel disease, or prior myomectomy
Kissing ovaries without ovarian endometriomas
Unilateral or bilateral posterior ovarian location in proximity to the cervix/retrocervical space without endometrioma
Ovarian immobility if incidentally observed on uterine sliding maneuver without endometrioma
Category C: endometriosis-associated observation
Adenomyosis, typical (nonspecific)
Hydrosalpinx (nonspecific)
Hematosalpinx (infrequently isolated, differentiate clinically from pyosalpinx)

Note.—DE = deep endometriosis, PID = pelvic inflammatory disease, USL = uterosacral ligament.

Key Points:

Know observations.

DON'T GET CAUGHT UP IN CATEGORIES

- Endometriomas
- Uterine Serosa outside-in pattern of heterogeneity
- Retrocervical DE implants (uterine body and USL)
- Retrovaginal DE implant
- Retrosigmoid DE implant
- Fixed uterine retroflexion
- Bowel tethering to posterior uterus
- Kissing ovaries with or without endometriomas
- Ovarian location (near cervix/retrocervical space)
- Ovarian immobility
- Adenomyosis
- Hydro/hemato-salpinx

Young SW, Jha P, Chamié L, et al. Society of Radiologists in Ultrasound Consensus on Routine Pelvic US for Endometriosis. Radiology. 2024;311(1):e232191. doi:10.1148/radiol.232191

11

Augmented DE Protocol

Routine pelvic US with *added maneuvers* when DE is suspected

Indications:
Chr pelvic pain
Infertility
Suspected DE

Key techniques

LG TRV CLIPS
Uterus, Cervix, and Posterior Compartment

Uterine Slide

Adds 2–5 minutes to exam

Add uterine slide clip to routine pelvic ultrasound That's all!

Young SW, Jha P, Chamié L, et al. Society of Radiologists in Ultrasound Consensus on Routine Pelvic US for Endometriosis. Radiology. 2024;311(1):e232191. doi:10.1148/radiol.232191

12

© Copyright. Society of Diagnostic Medical Sonography. All Rights Reserved.

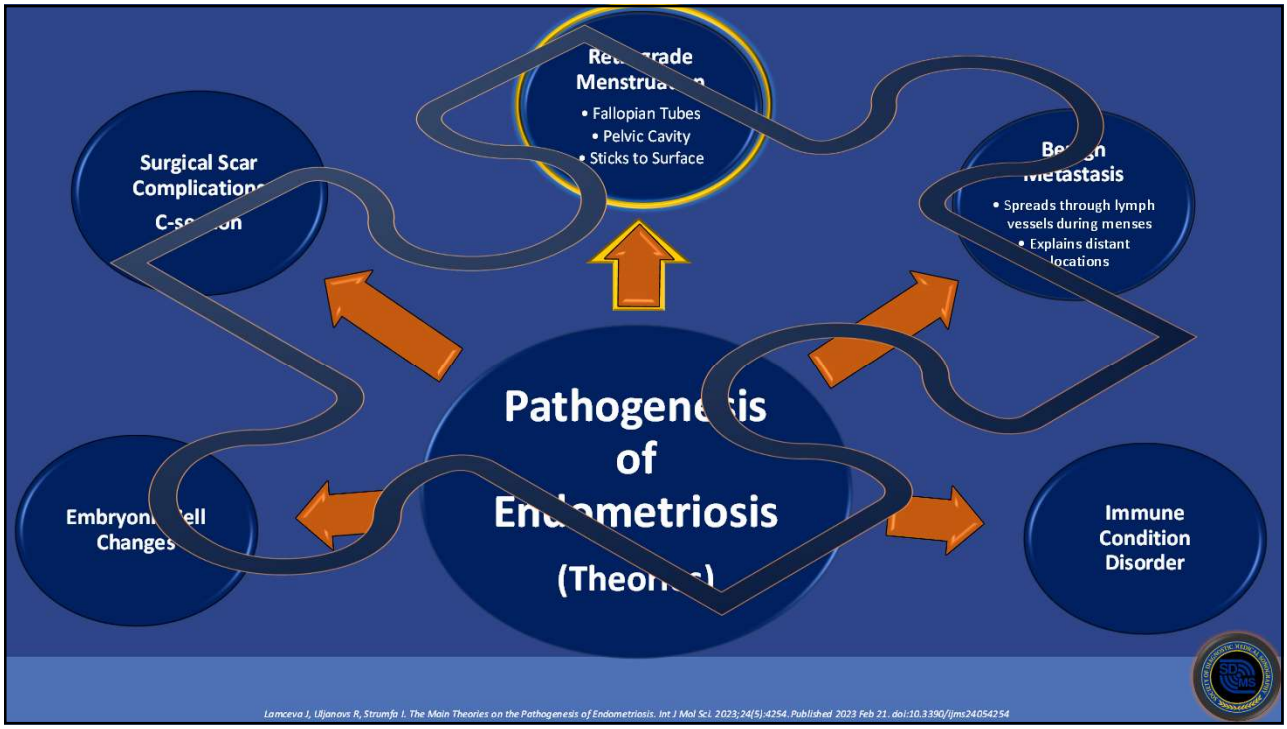

13

Types of Endometriosis

SUPERFICIAL

Shallow lesions on the peritoneum, common (80% of cases)

Better seen on laparoscopy

ENDOMETRIOMAS

Lesions start on surface, invaginate into stroma

Burrow into the ovary like a worm in an apple

Difficult to preserve ovary



DEEP INFILTRATING ENDOMETRIOSIS

Invades bowel, bladder, pelvic organs, uterosacral ligament, pelvic cavity

Slezov.Sergey. Apple Worm.2020. https://www.artstation.com/artwork/W2Nm6Q.8/14/2026

14

© Copyright. Society of Diagnostic Medical Sonography. All Rights Reserved.

Superficial Endometriosis

15

Types of Endometriosis: Superficial

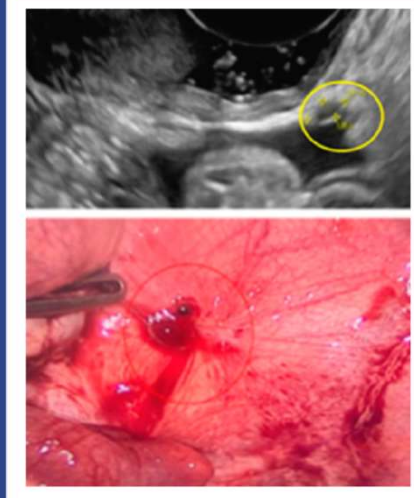

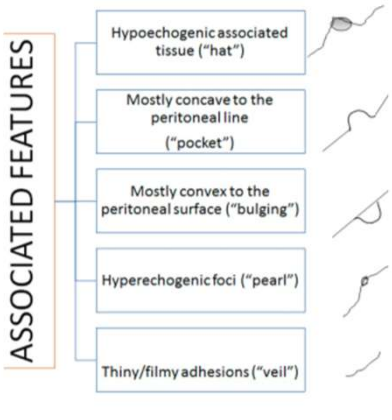

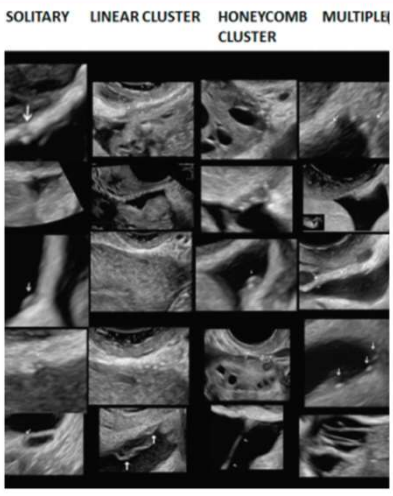

Pedrassani, M, et al. Superficial Endometriosis at Ultrasound Examination.Diagnostics(Basel). 2023Pedrassani M, Guerriero S, Pascual MÁ, et al. Superficial Endometriosis at Ultrasound Examination-A Diagnostic Criteria Proposal. Diagnostics (Basel). 2023;13(11):1876. Published 2023 May 27. doi:10.3390/diagnostics13111876 May 27;13(11):1876

16

© Copyright. Society of Diagnostic Medical Sonography. All Rights Reserved.

Endometriomas

17

Types of Endometriosis: Endometriomas

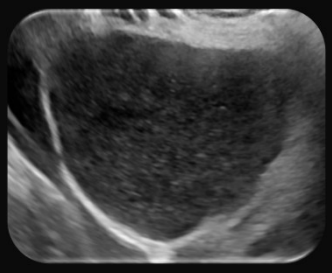

- Typical
- Homogenous
- Ground Glass



- Foci are cholesterol deposits and hemosiderin crystals from prior hemorrhage
- May twinkle

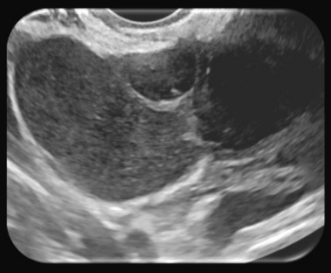

- Multiloculated (<3 locules typical)
- Possible flow in intervening ovarian parenchyma

18

© Copyright. Society of Diagnostic Medical Sonography. All Rights Reserved.

Something to Note:

Postmenopausal Patients (initial discovery):
Appearance Overlaps With Neoplasia

Increase of Endometriosis-Associated Malignancy After Menopause

O-RADS Recommendation

Dave D, Page HE, Carrubba AR. Clinical management of endometriosis in menopause: a narrative review. Medicina (Kaunas). 2024;60(8):1341. doi:10.3390/medicina60081341

19

Atypical Endometriomas : (Power, MVI, Pulse)

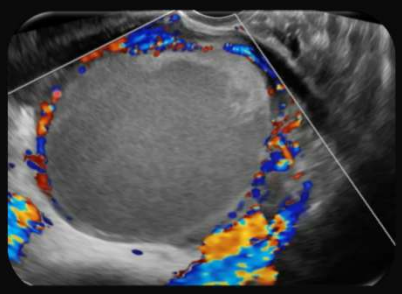



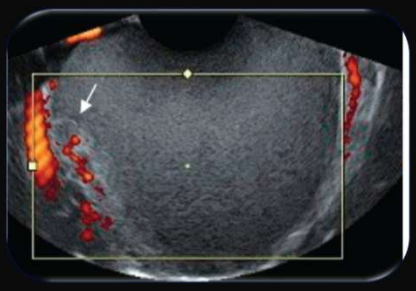

- Atypical with echogenic peripheral nodularity
- Avascular
- Benign fibrin material

- Decidualized (benign)
- Hormonal changes (pregnancy, high progesterone levels) may cause size increase
- Mimics malignancy

- Rarely (1%) undergo malignant transformation
- Most common endometrioid carcinoma and clear cell carcinoma.

For readers: When solid or solid-appearing components present, panel recommends characterizing with O RADS.

Young SW, Jha P, Chamié L, et al. Society of Radiologists in Ultrasound Consensus on Routine Pelvic US for Endometriosis. Radiology. 2024;311(1):e232191. doi:10.1148/radiol.232191

20

© Copyright. Society of Diagnostic Medical Sonography. All Rights Reserved.

Deep Infiltrating Endometriosis (DIE or DE)

21

Types of Endometriosis: Deep Endometriosis

DE manifests in the posterior compartment in 93% of effected patients.

Kondo W, Ribeiro R, Trippia C, Zomer MT. Endometriose profunda infiltrativa: distribuição anatômica e tratamento cirúrgico [Deep infiltrating endometriosis: anatomical distribution and surgical treatment]. Rev Bras Ginecol Obstet. 2012;34(6):278-284

Chapron C, Fauconnier A, Vieira M, et al. Anatomical distribution of deeply infiltrating endometriosis: surgical implications and proposition for a classification. Hum Reprod. 2003;18(1):157-161. doi:10.1093/humrep/deg009

22

© Copyright. Society of Diagnostic Medical Sonography. All Rights Reserved.

Deep Endometriosis Watch

Focus:

- Position of Uterus and Ovaries
- Posterior & Middle Compartments
- Slide Sign

Meaning what exactly…

23

Posterior Compartment: Retrograde Menstruation Theory

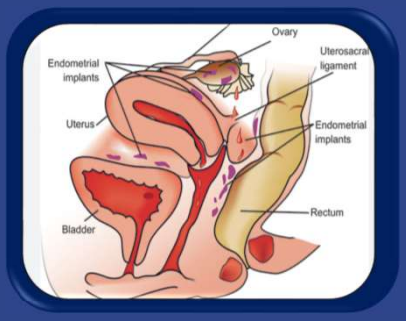





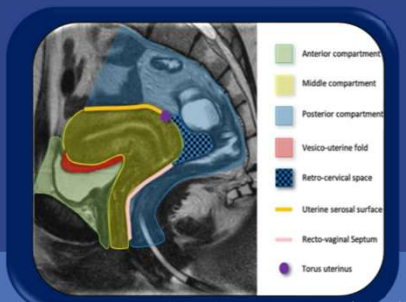

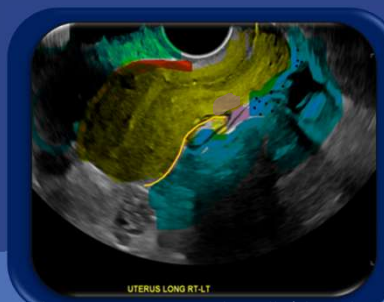

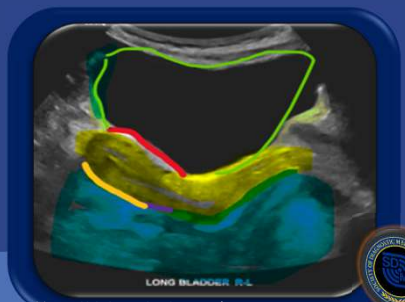

Lorusso F, Scioscia M, Rubini D, et al. Magnetic resonance imaging for deep infiltrating endometriosis: current concepts, imaging technique and key findings. Insights Imaging. 2021;12(1):105. Published 2021 Jul 22. doi:10.1186/s13244-021-01054-x

24

© Copyright. Society of Diagnostic Medical Sonography. All Rights Reserved.

Evaluating Posterior Compartment: Slide Sign Technique

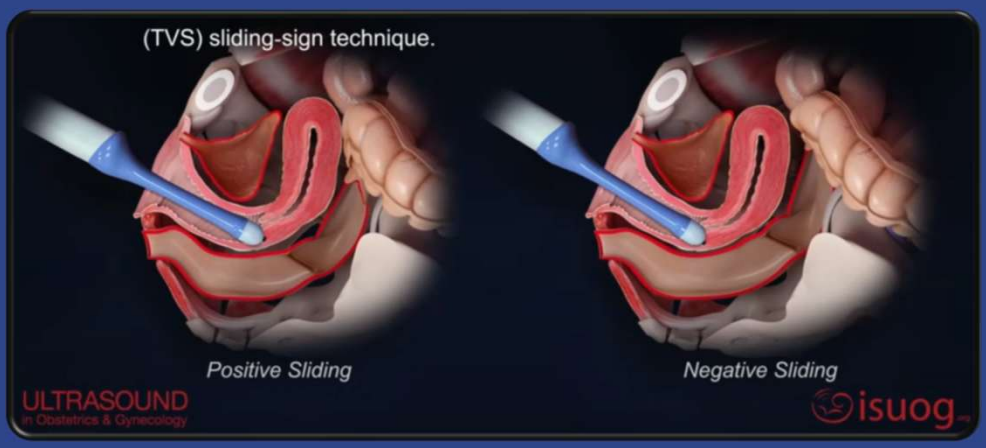

Slide Sign Reported As: Normal, Abnormal, Equivocal, Technically Inadequate, or Not Performed

Reid S, Lu C, Casikar I, et al. Prediction of pouch of Douglas obliteration in women with suspected endometriosis using a new real-time dynamic transvaginal ultrasound technique: the sliding sign. Ultrasound Obstet Gynecol. 2013;41(6):685-691. doi:10.1002/uog.12305
Leonardi M, Martins WP, Espada M, Georgousopoulou E, Condous G. Prevalence of negative sliding sign representing pouch of Douglas obliteration during pelvic transvaginal ultrasound for any indication. *Ultrasound Obstet Gynecol.* 2020;56(6):928-933. doi:10.1002/uog.22023
Young SW, Jha P, Chamié L, et al. Society of Radiologists in Ultrasound Consensus on Routine Pelvic US for Endometriosis. Radiology. 2024;311(1):e232191. doi:10.1148/radiol.232191

25

Evaluation Posterior Compartment: Slide Sign Technique

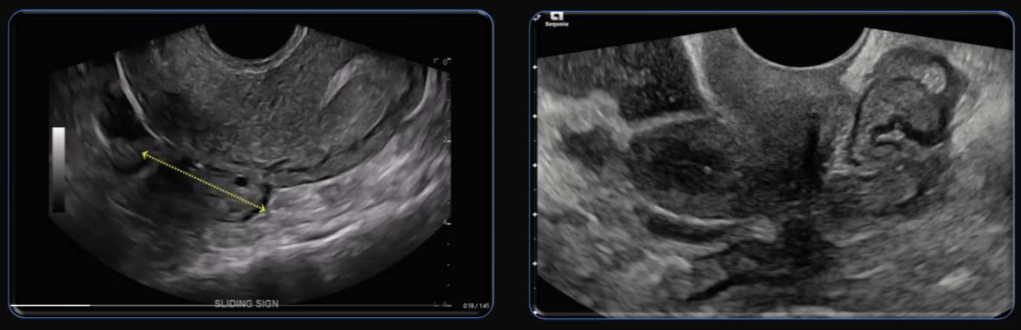

Retroverted

Anteverted

Young SW, Jha P, Chamié L, et al. Society of Radiologists in Ultrasound Consensus on Routine Pelvic US for Endometriosis. Radiology. 2024;311(1):e232191. doi:10.1148/radiol.232191

26

© Copyright. Society of Diagnostic Medical Sonography. All Rights Reserved.

"Slide Sign" Incorrect

Probe in Anterior Fornix



27

How to Identify USL (DE hot spot)



- Uterosacral Ligament

Young SW, Jha P, Chamié L, et al. Society of Radiologists in Ultrasound Consensus on Routine Pelvic US for Endometriosis. Radiology. 2024;311(1):e232191. doi:10.1148/radiol.232191

28

© Copyright. Society of Diagnostic Medical Sonography. All Rights Reserved.

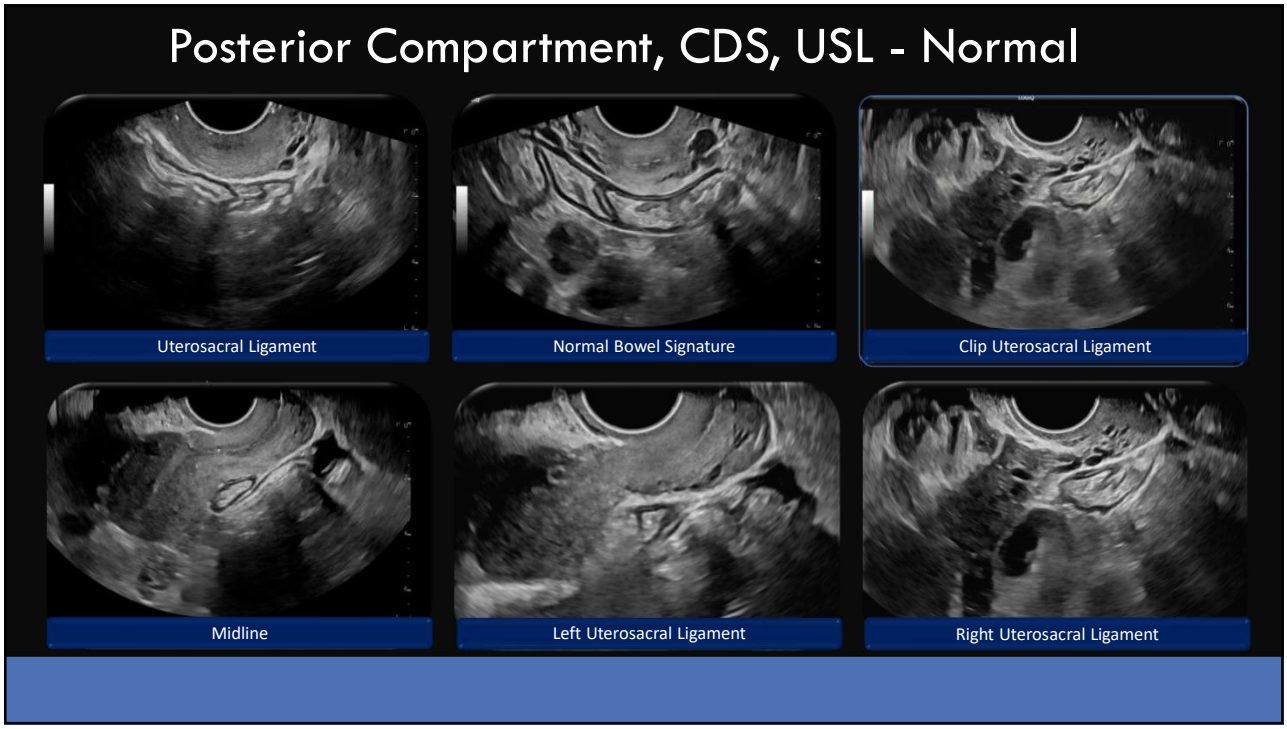

29

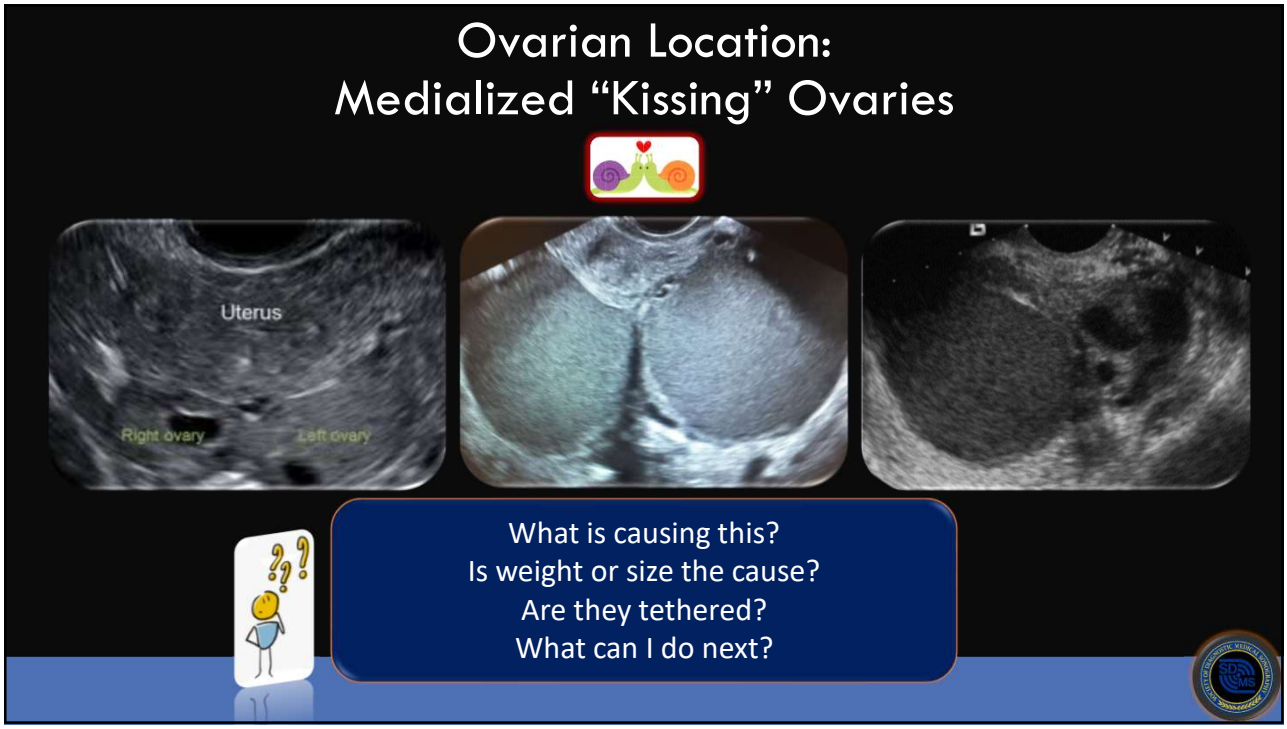

30

© Copyright. Society of Diagnostic Medical Sonography. All Rights Reserved.

Ovarian Sliding Sign (*not in protocol but helpful*)







Does the ovary slide freely from:
- Bowel
- Pelvic sidewall

Does bowel have any areas of thickening or Is there normal mucosal signature?



Yes, everything is sliding.

NORMAL

Does the ovary slide freely from:

- Fallopian tube
- Uterus
- Pelvic sidewall

Young SW, Jha P, Chamié L, et al. Society of Radiologists in Ultrasound Consensus on Routine Pelvic US for Endometriosis. Radiology. 2024;311(1):e232191. doi:10.1148/radiol.232191

31

Ovarian Slide Sign



- Hypoechoic plaque on sigmoid colon
- Bowel isn't sliding from ovary
- Ovary little slide from pelvic sidewall
- Yellow arrows – tubal adhesions



Things are amiss.

Abnormal DE



- Ovary not sliding from fibroid uterus
- Little slide from pelvic sidewall
- Lesion is a confirmed endometrioma
- Small hematosalpinx

Young SW, Jha P, Chamié L, et al. Society of Radiologists in Ultrasound Consensus on Routine Pelvic US for Endometriosis. Radiology. 2024;311(1):e232191. doi:10.1148/radiol.232191

32

© Copyright. Society of Diagnostic Medical Sonography. All Rights Reserved.

Observation: Uterus Position



Retroverted/Plaque Out-In Pattern

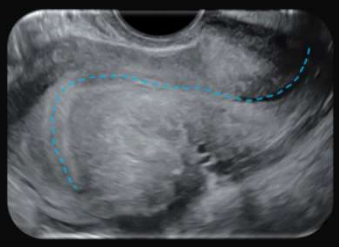

Question Mark Shape (look for plaque)



Fundal Retroflex/Plaque; Out-In Pattern

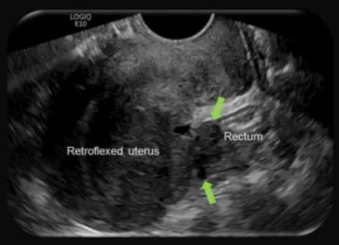

Fundal Retroflexion with Rectal Plaque

DIE plaques can tether the posterior uterine body to posterior cervix

- ✓ Retroflexion?
- ✓ Endometrial axis off?
- ✓ Uterus question mark shape?



Yes!

Look for plaques & in-out patten.

Young SW, Jha P, Chamié L, et al. Society of Radiologists in Ultrasound Consensus on Routine Pelvic US for Endometriosis. Radiology. 2024;311(1):e232191. doi:10.1148/radiol.232191

33

Case 1

34

© Copyright. Society of Diagnostic Medical Sonography. All Rights Reserved.

Deep Endometriosis



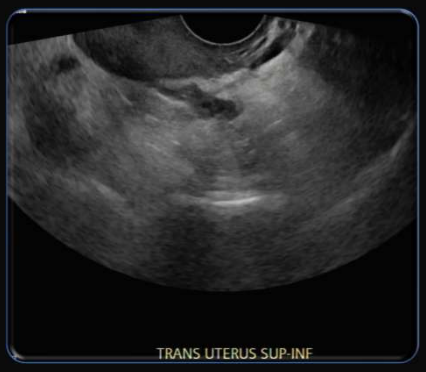

Tethering Plaque Anterior Rectum/Posterior Uterus

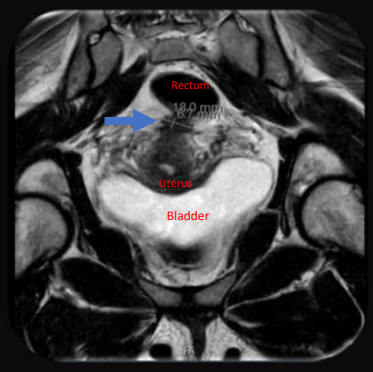

MRI correlate

35

Deep Endometriosis



Tether Left Ovary - Uterus
(abnormal slide clip)

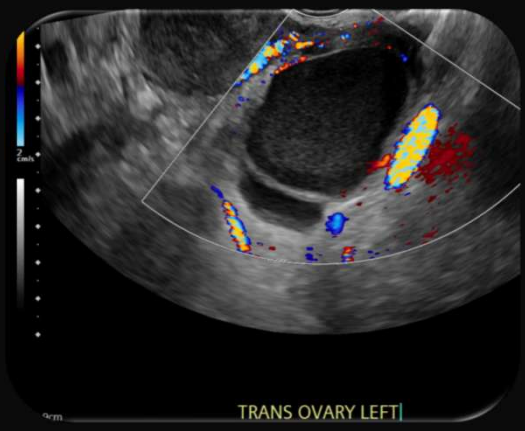

Left Ovarian Endometrioma
(still)

36

© Copyright. Society of Diagnostic Medical Sonography. All Rights Reserved.

Case 2

37

DIE: Ovarian Tethering, Invasion Into Myometrium





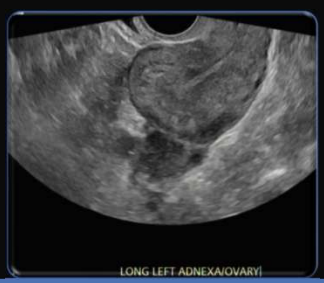



Findings of Deep Infiltrating Endometriosis:

- Ovarian tethering plaques
- Left ovarian endometriomas
- Posterior uterine wall involvement (out-in pattern)

38

© Copyright. Society of Diagnostic Medical Sonography. All Rights Reserved.

Deep Infiltrating Endometriosis, MRI Correlate

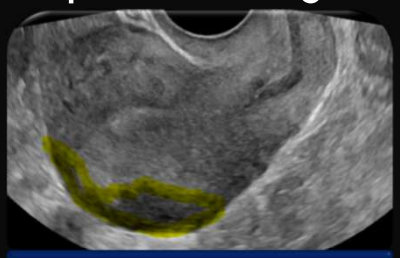

Myometrium Invasion



Right Ovarian Tether

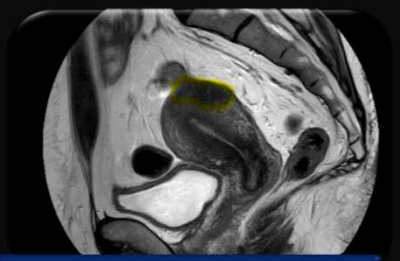

MRI Correlate



MRI Correlate

39

Ultrasound versus MRI Impression

IMPRESSION:

1. Findings of deep infiltrating endometriosis include, several rectouterine plaques, probable ovarian tethering/adhesions, left ovarian endometrioma and probable posterior uterine myometrial involvement. Pelvic MRI may be beneficial for further assessment, as clinically indicated.

IMPRESSION:

1. Multifocal deep infiltrating endometriosis, predominantly along the superior and posterior uterine serosa extending into the myometrium, which medially tethers both ovaries. There are scattered hemorrhagic/glandular components.

2. Small volume deep infiltrating endometriosis suspected along the left aspect of the lower/anterior uterine serosa in the region of the anterior cul-de-sac.

3. Superficial adhesions to the sigmoid colon but no muscle-invasive disease.

4. Left ovarian endometrioma (2.3 cm).

40

© Copyright. Society of Diagnostic Medical Sonography. All Rights Reserved.

Case 3

41

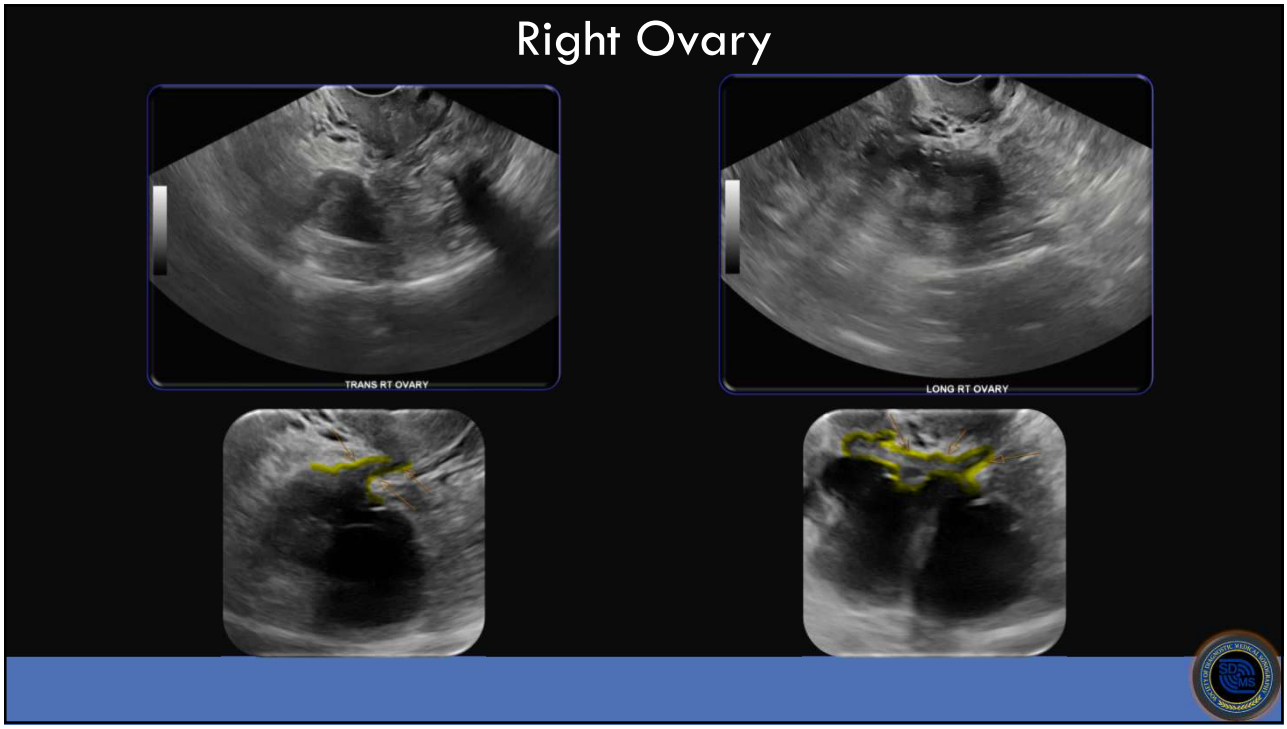

42

© Copyright. Society of Diagnostic Medical Sonography. All Rights Reserved.

Bilateral Endometriomas (previously seen)

12/2024

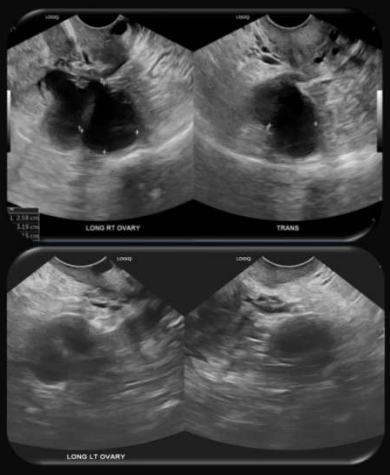

1/2023

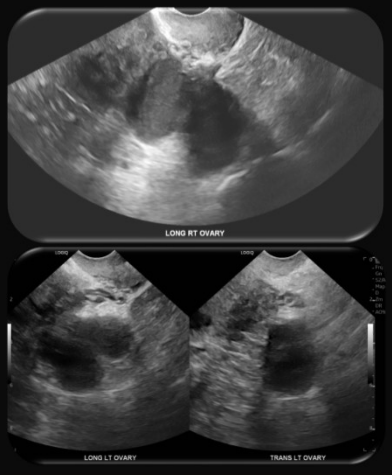

43

Ovarian Findings

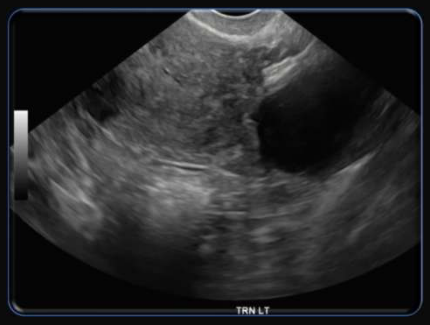

Abnormal Left Ovarian Slide

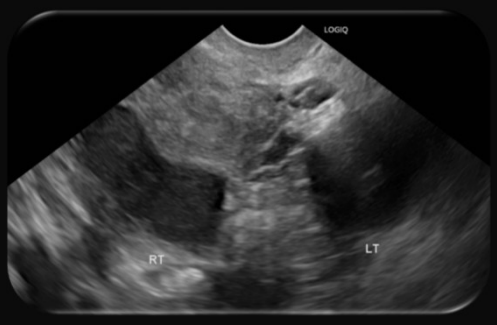

Medialization of Ovaries

Impression:
DE: Bilateral Endometriomas, Medialized Ovaries, and Tethering Plaques.

44

© Copyright. Society of Diagnostic Medical Sonography. All Rights Reserved.

Case 4

(Audience-Focused)

45

Watch for Bait and Switch. Hard Case. Real Life.

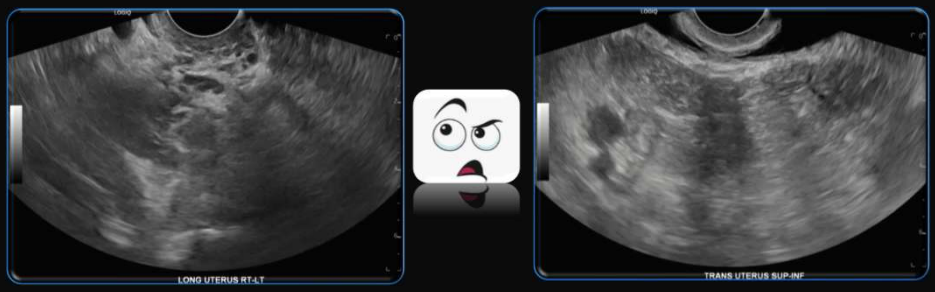

Don't get tunnel vision and overwhelmed. BE SYSTEMATIC!

Step 1: Acknowledge Obvious
- Fibroids or Adenomyosis and move past.

Tip: Revisit heterogeneity cause if you suspect DE. Could the cause be DE invasion, as well?

Step 2: Uterine Position
- Retroflexed-verted, endo axis, question mark shape?

Tip: See past fibroids. Can you see the endo axis? It is vague, like a shadow.

Step 3: Ovarian Position
- Are they normal, by pelvic wall?
- Medialized?
- Low in CDS?

Step 4: Post & Mid Compartments
- Is the uterine serosa smooth?
- Do I see possible plaques and tethers?

46

© Copyright. Society of Diagnostic Medical Sonography. All Rights Reserved.

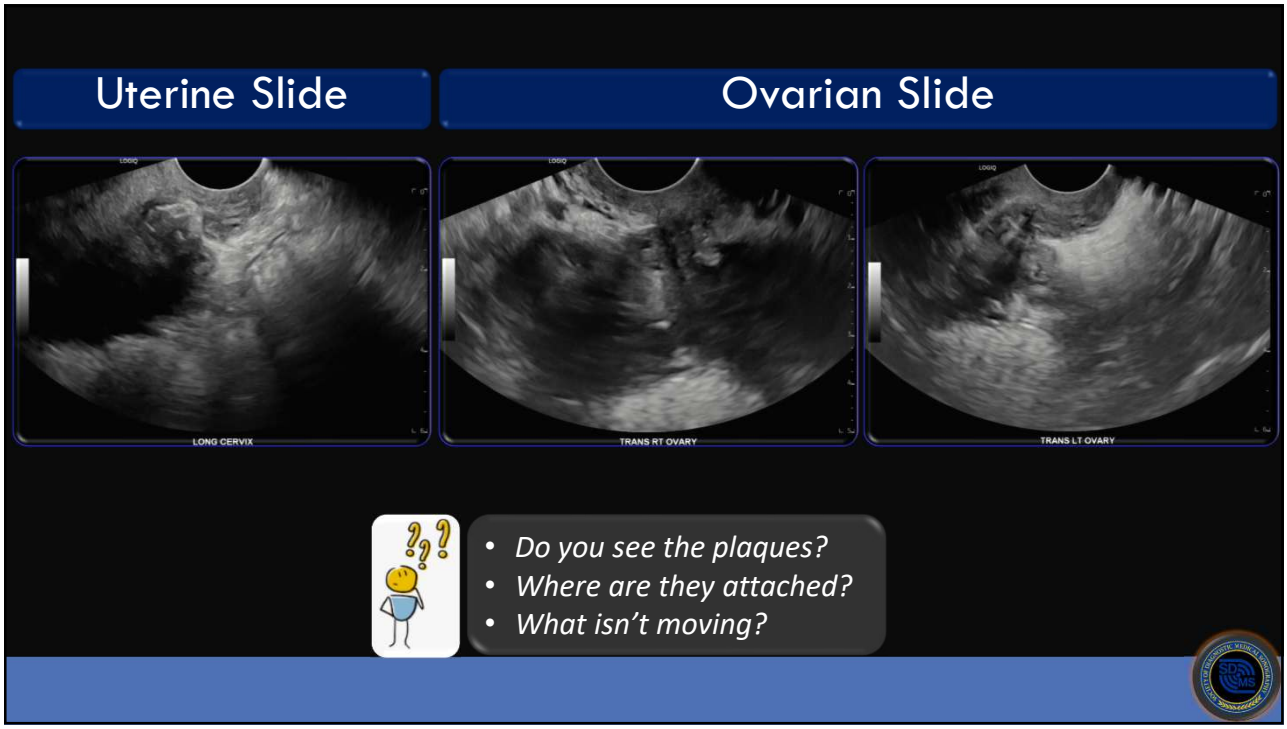

47

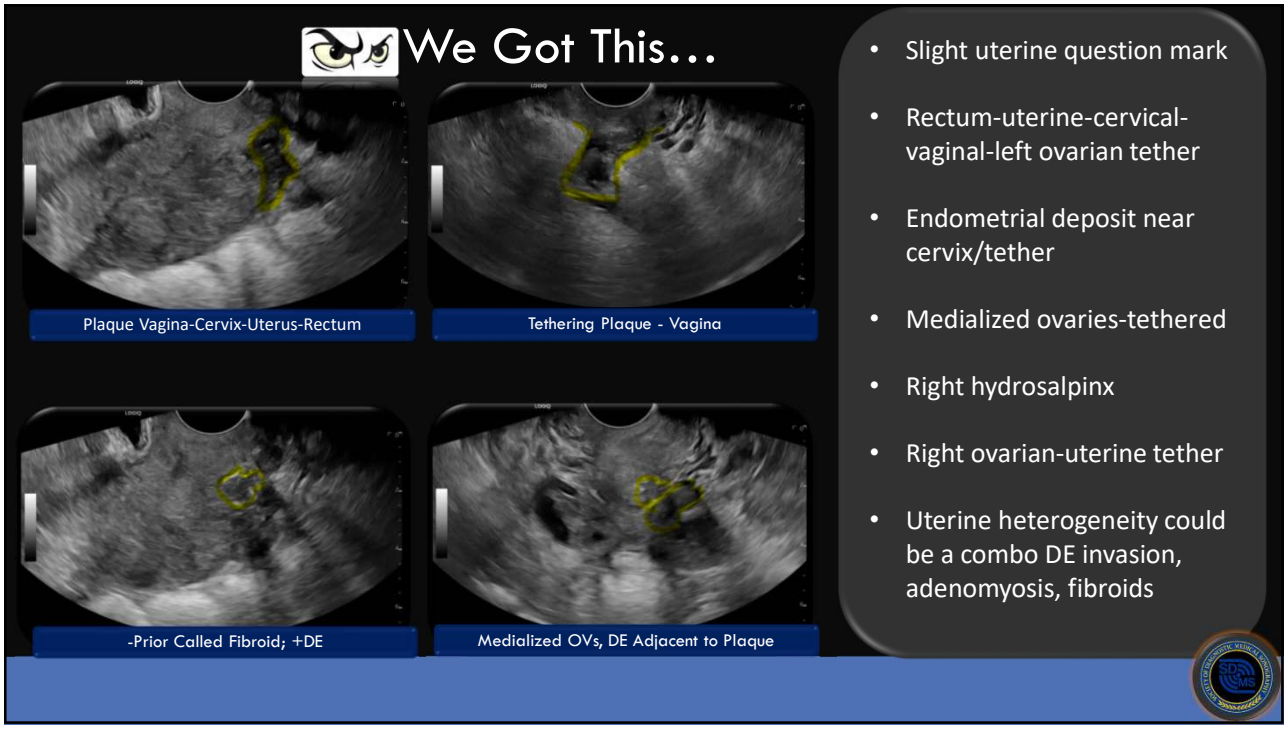

48

© Copyright. Society of Diagnostic Medical Sonography. All Rights Reserved.

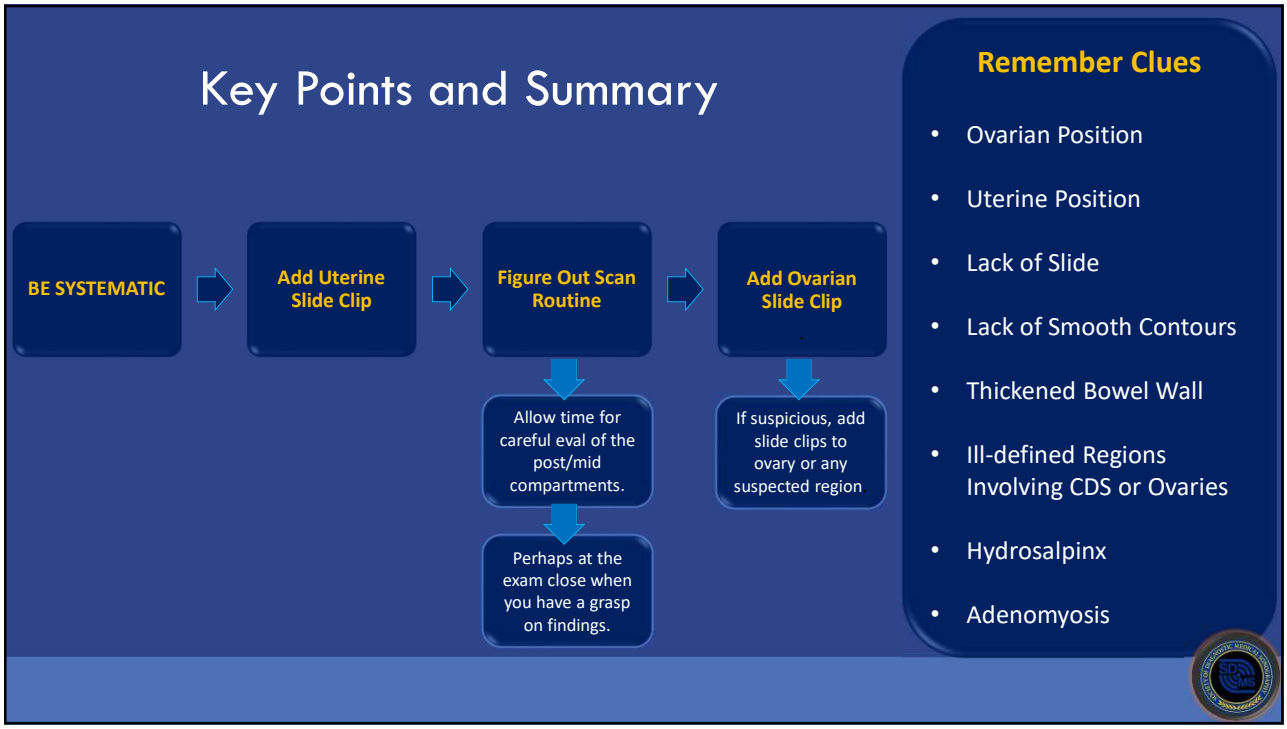

49

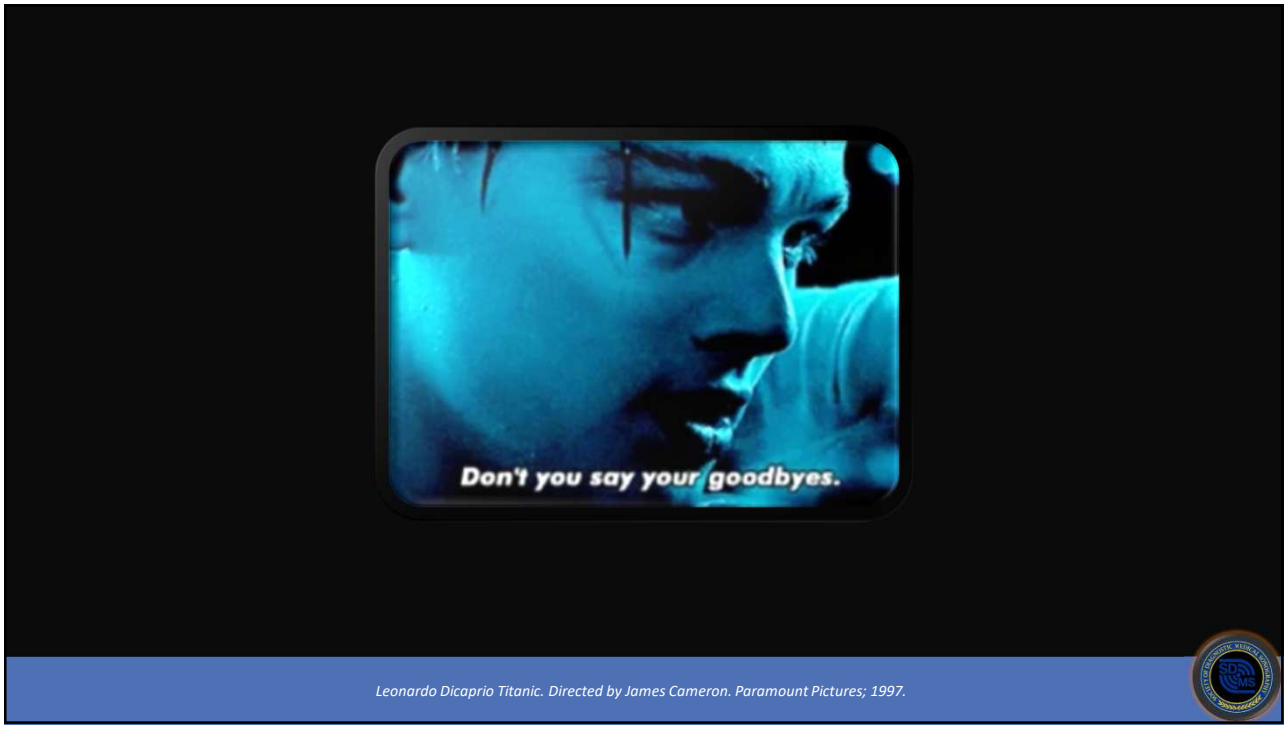

50

© Copyright. Society of Diagnostic Medical Sonography. All Rights Reserved.

🥰 Two Days After U of M Talk…

Erica found this:

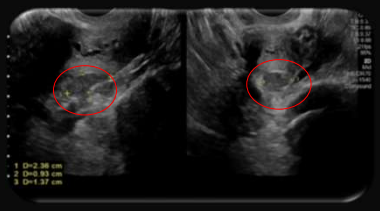

2/17/25

Annica found this plaque
Missed on several priors back to 2022:



2/17/25



2024



2023

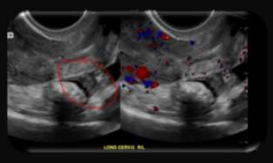

2022

51

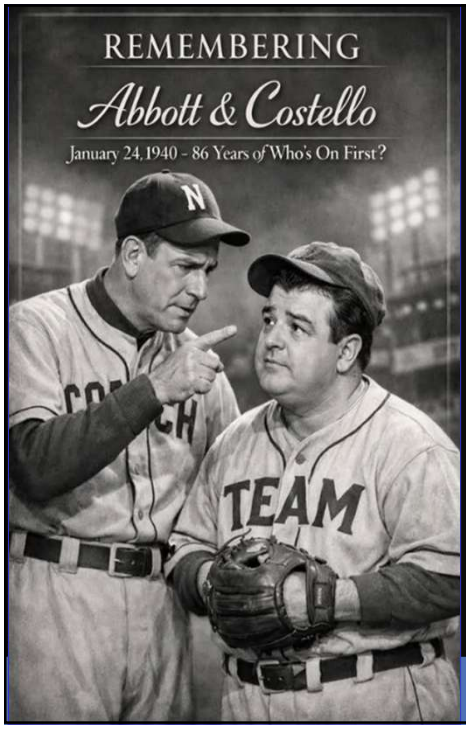

Differential Diagnosis of DE

Don't get confused!

Abbott B, Costello L. Who's on First? Performed on radio beginning in 1938; featured in The Naughty Nineties. Universal Pictures; 1945

52

© Copyright. Society of Diagnostic Medical Sonography. All Rights Reserved.

Differential Diagnosis of DE



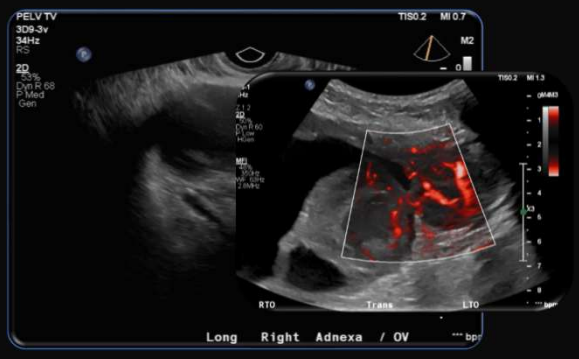

Postmenopausal
Free fluid is not normal
Carcinomatosis!

Premenopausal
Complex findings
PID/TOA!

53

Case 5

54

© Copyright. Society of Diagnostic Medical Sonography. All Rights Reserved.

History

Painful Lump After Cesarean Section
Noticed After 85 lb Weight Loss

55

Images

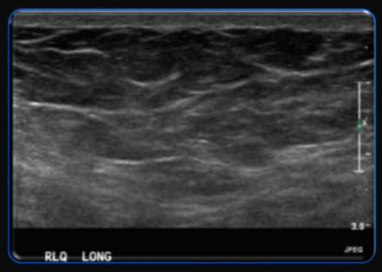

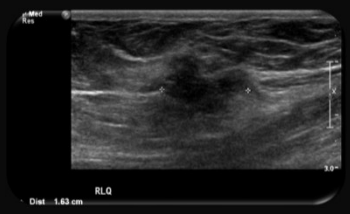





Impression: Nonspecific mass in palpable area. MRI recommended.

56

© Copyright. Society of Diagnostic Medical Sonography. All Rights Reserved.

Diagnosis

Endometrioma in Abdominal Wall Fascia
(pathology proven)

57

TIPS

- Palpable Lump
- Near Scar
- Spiculated Margins
- Hypoechoic
- Fibrotic Change
- Size Fluctuates
- Painful

58

© Copyright. Society of Diagnostic Medical Sonography. All Rights Reserved.

What are we forgetting?

- We've been focusing on the posterior and middle compartments.
- Don't forget, you may come across DE in the anterior compartment.

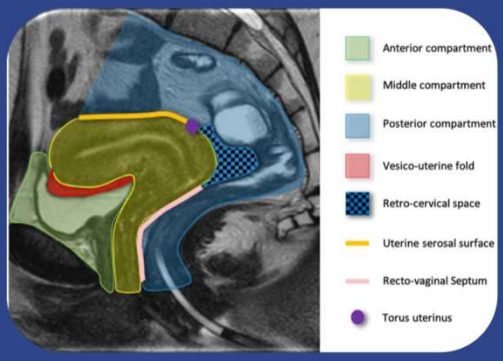

Lorusso F, Scioscia M, Rubini D, et al. Magnetic resonance imaging for deep infiltrating endometriosis: current concepts, imaging technique and key findings. Insights Imaging. 2021;12(1):105. Published 2021 Jul 22. doi:10.1186/s13244-021-01054-x

59

Anterior Compartment DE

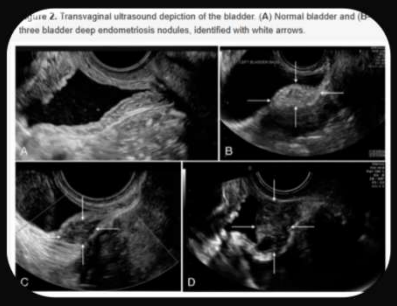

Bladder DE involvement can mimic masses.

May need additional work-up to exclude neoplasm.



01/2025



09/2023

Vaginal DE involvement can mimic a mass or complex cyst.
(Echogenicity changed in this case, likely fibrin.)

Leonardi M, Espada M, Kho RM, et al. Endometriosis and the Urinary Tract: From Diagnosis to Surgical Treatment. Diagnostics (Basel). 2020;10(10):771. Published 2020 Sep 30. doi:10.3390/diagnostics10100771

60

© Copyright. Society of Diagnostic Medical Sonography. All Rights Reserved.

Takeaway: *Remember Your Clues*

- **Evaluation**
  - Uterine Position
  - Ovarian Position
  - Posterior Compartment
  - Slide Sign
  - Look for small clues when sliding

61

Adenomyosis

Bonus Track

62

© Copyright. Society of Diagnostic Medical Sonography. All Rights Reserved.

Pathogenesis of Adenomyosis

Definition:
Ectopic endometrial glands in the myometrium

Risk Factors:
Multiparity
D&C
C-Section

(Cause damage to endo-myometrial junction-allows growth of ectopic glands)

Van den Bosch T, de Bruijn AM, de Leeuw RA, et al. Sonographic classification and reporting system for diagnosing adenomyosis. Ultrasound Obstet Gynecol. 2019;53(5):576-582. doi:10.1002/uog.19096

63

Diffuse Versus Focal Adenomyosis

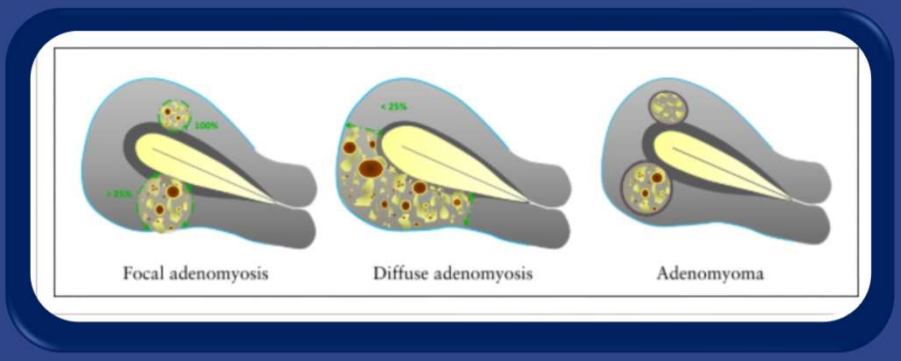

Van den Bosch T, de Bruijn AM, de Leeuw RA, et al. Sonographic classification and reporting system for diagnosing adenomyosis. Ultrasound Obstet Gynecol. 2019;53(5):576-582. doi:10.1002/uog.19096

64

© Copyright. Society of Diagnostic Medical Sonography. All Rights Reserved.

Adenomyosis: Spectrum of Appearance

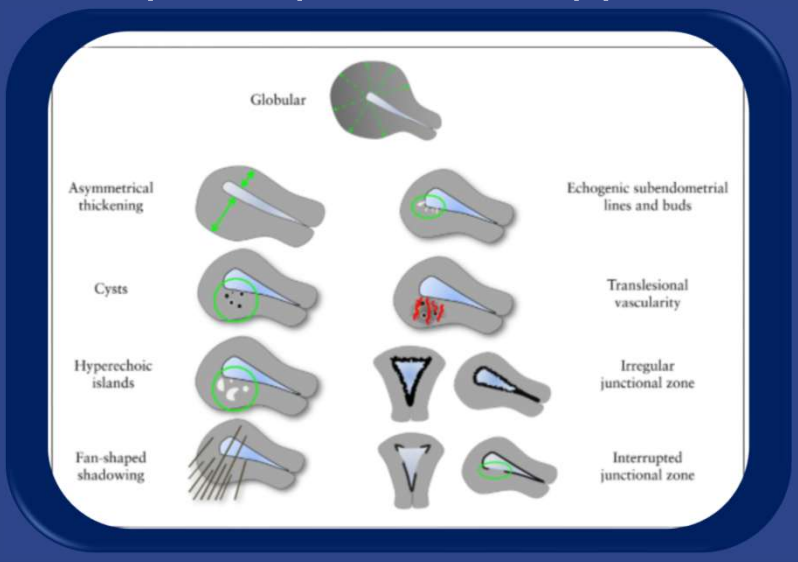

Van den Bosch T, de Bruijn AM, de Leeuw RA, et al. Sonographic classification and reporting system for diagnosing adenomyosis. Ultrasound Obstet Gynecol. 2019;53(5):576-582. doi:10.1002/uog.19096

65

Adenomyosis Versus DE Myometrial Invasion

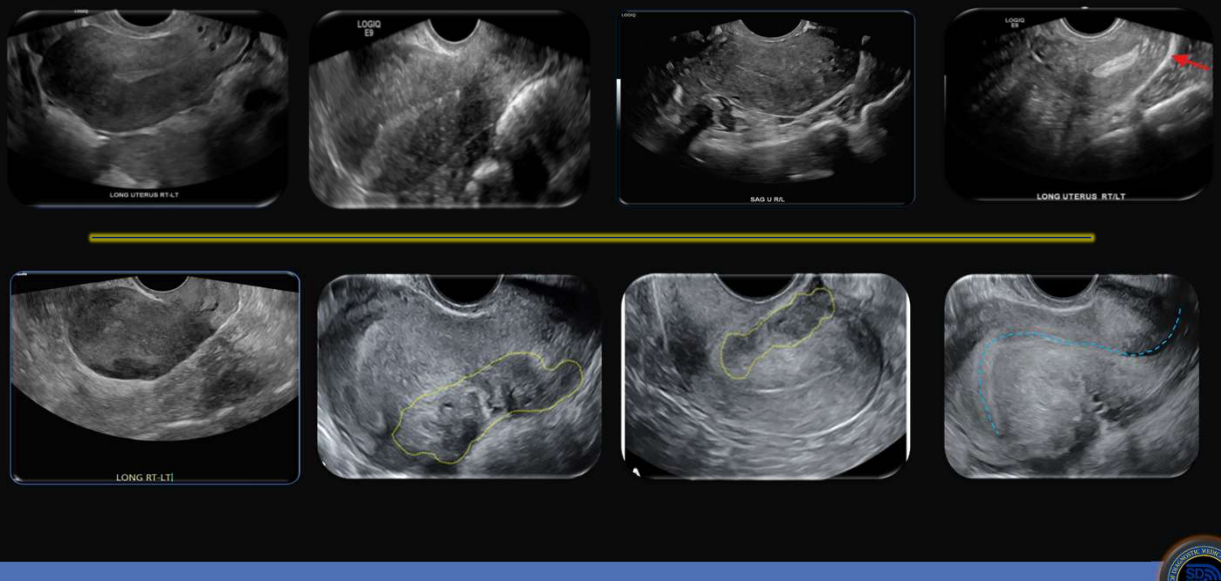

66

© Copyright. Society of Diagnostic Medical Sonography. All Rights Reserved.

A few extra minutes may help shorten the diagnostic delay and improve patient care.

67

References

1. Young SW, Jha P, Chamié L, et al. Society of Radiologists in Ultrasound Consensus on Routine Pelvic US for Endometriosis. Radiology. 2024;311(1):e232191. doi:10.1148/radiol.232191

2. Lamceva J, Uljanovs R, Strumfa I. The Main Theories on the Pathogenesis of Endometriosis. *Int J Mol Sci*. 2023;24(5):4254. Published 2023 Feb 21. doi:10.3390/ijms240542543. Pedrassani M, et al. Superficial Endometriosis at Ultrasound Examination. Diagnostics (Basel). 2023;13(11):1876

3. Pedrassani M, Guerriero S, Pascual MÁ, et al. Superficial Endometriosis at Ultrasound Examination-A Diagnostic Criteria Proposal. *Diagnostics (Basel)*. 2023;13(11):1876. Published 2023 May 27. doi:10.3390/diagnostics13111876

4. Kondo W, Ribeiro R, Trippia C, Zomer MT. Endometriose profunda infiltrativa: distribuição anatômica e tratamento cirúrgico [Deep infiltrating endometriosis: anatomical distribution and surgical treatment]. Rev Bras Ginecol Obstet. 2012;34(6):278-284

5. Chapron C, Fauconnier A, Vieira M, et al. Anatomical distribution of deeply infiltrating endometriosis: surgical implications and proposition for a classification. *Hum Reprod*. 2003;18(1):157-161. doi:10.1093/humrep/deg009

6. Reid S, Lu C, Casikar I, et al. Prediction of pouch of Douglas obliteration in women with suspected endometriosis using a new real-time dynamic transvaginal ultrasound technique: the sliding sign. *Ultrasound Obstet Gynecol*. 2013;41(6):685-691. doi:10.1002/uog.12305

7. Leonardi M, Martins WP, Espada M, Georgousopoulou E, Condous G. Prevalence of negative sliding sign representing pouch of Douglas obliteration during pelvic transvaginal ultrasound for any indication. Ultrasound Obstet Gynecol. 2020;56(6):928-933. doi:10.1002/uog.22023

8. Lorusso F, Scioscia M, Rubini D, et al. Magnetic resonance imaging for deep infiltrating endometriosis: current concepts, imaging technique and key findings. Insights Imaging. 2021;12(1):105. Published 2021 Jul 22. doi:10.1186/s13244-021-01054-x

9. Leonardi M, Espada M, Kho RM, et al. Endometriosis and the Urinary Tract: From Diagnosis to Surgical Treatment. Diagnostics (Basel). 2020;10(10):771. Published 2020 Sep 30. doi:10.3390/diagnostics10100771

10. Van den Bosch T, de Bruijn AM, de Leeuw RA, et al. Sonographic classification and reporting system for diagnosing adenomyosis. Ultrasound Obstet Gynecol. 2019;53(5):576-582. doi:10.1002/uog.19096

11. Jensen KK, Pyle C, Foster BR, Sohaey R, Oh KY. Adenomyosis in Pregnancy: Diagnostic Pearls and Pitfalls. Radiographics. 2021;41(3):929-944. doi:10.1148/rg.2021200120

12. Dave D, Page HE, Carrubba AR. Clinical management of endometriosis in menopause: a narrative review. Medicina (Kaunas). 2024;60(8):1341. doi:10.3390/medicina60081341

With gratitude to the sonographers, researchers, clinicians, educators, and patients whose contributions have advanced our understanding of endometriosis/adenomyosis and made this educational presentation possible.

68

© Copyright. Society of Diagnostic Medical Sonography. All Rights Reserved.

2026 SDMS Annual Conference



69

© Copyright. Society of Diagnostic Medical Sonography. All Rights Reserved.