Title: At the Carotid Fork: A Tumor Hiding in Plain Sight

Lonette Spence, DHSc, RVT

Associate Professor, Nova Southeastern University

1

SPEAKER PRESENTATION DISCLAIMER

The content and views presented are made available for educational purposes only. The information presented are the opinions of the presenter and do not necessarily represent the views of the Society of Diagnostic Medical Sonography (SDMS) or its affiliated organizations, officers, Boards of Directors, or staff members.

The presenter is responsible for ensuring balance, independence, objectivity, scientific rigor, and avoiding commercial bias in their presentation. Before making the presentation, the presenter is required to disclose to the audience any relevant financial interests or relationships with manufacturers or providers of medical products, services, technologies, and programs.

The SDMS and its affiliated organizations, officers, Board of Directors, and staff members disclaim any and all liability for all claims that may arise out of the use of this educational activity.

2

© Copyright. Society of Diagnostic Medical Sonography. All Rights Reserved.

RESEARCH DISCLAIMER

The information presented in this presentation is based on research conducted to the best of the presenters' abilities and knowledge. Research involves uncertainty and is subject to limitations. The findings and conclusions presented herein may be influenced by various factors including but not limited to data quality, methodology, assumptions, and interpretation.

Research outcomes may not always accurately predict real-world scenarios or future events. While the presenter may make efforts to ensure the accuracy and reliability of the information presented, completeness or absolute correctness is not guaranteed. This presentation is intended for informational purposes only and should not be construed as professional advice. Participants are encouraged to independently verify any information provided and consult relevant experts or professionals where appropriate.

The SDMS and its affiliated organizations, officers, Board of Directors, and staff members disclaim any and all liability for all claims that may arise out of the use of this educational activity.

3

GENERATIVE AI DISCLAIMER

The presenter utilized the use of large language models (LLMs) and generative artificial intelligence (AI) as a productivity tool to assist in drafting and refining content in this presentation.

While these tools can aid in structuring ideas, summarizing, paraphrasing, and language polishing, they have inherent limitations and cannot replace human creativity, critical thinking, or expert judgment. AI-generated content may contain errors, biases, or gaps in knowledge.

This presentation is intended for informational purposes only and should not be construed as definitive or authoritative guidance. Participants are encouraged to critically evaluate the information presented and consult relevant experts as needed. The SDMS and its affiliated organizations, officers, Board of Directors, and staff members disclaim any and all liability for claims that may arise from the use or interpretation of this educational material.

4

© Copyright. Society of Diagnostic Medical Sonography. All Rights Reserved.

Learning Objectives

- Identify characteristic sonographic features of carotid body tumors to support accurate recognition.
- Distinguish carotid body tumors from other neck masses using duplex ultrasound findings and clinical context to improve diagnostic accuracy.
- Recognize the correlation between sonographic findings and advanced imaging to support clinical decision-making.

5

Introduction- What is a Carotid Body Tumor?

The carotid body is a small, rounded peripheral chemoreceptor located within the adventitia at the bifurcation of the common carotid artery.

- One carotid body is present on each side of the neck, measuring approximately 2–6 mm and about 20 mm^3 in volume (Forbes et al., 2026).
- The carotid body plays an essential role in respiratory and cardiovascular homeostasis by continuously monitoring:
  - Arterial oxygen (O_2)
  - Carbon dioxide (CO_2)
  - Blood pH (Yu et al., 2026)

6

© Copyright. Society of Diagnostic Medical Sonography. All Rights Reserved.

Carotid Body Anatomy

- Carotid body tumors (CBTs), also known as carotid paragangliomas or chemodectomas, are rare neuroendocrine tumors arising from the carotid body at the carotid bifurcation (Hoang et al., 2019).
- CBTs are the most common paragangliomas of the head and neck (Aru et al., 2021).

Image from https://my.clevelandclinic.org/health/diseases/22394-paraganglioma/ Accessed on Jun3 30th, 2026

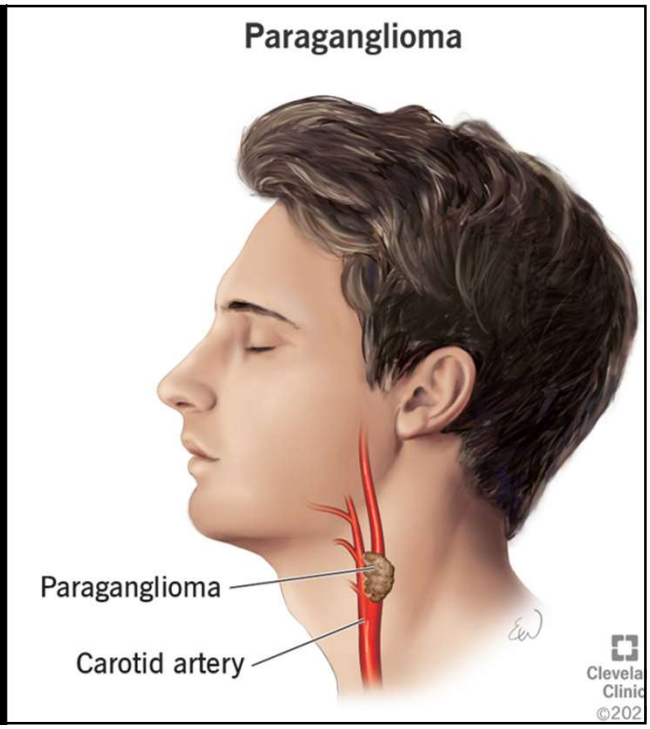

7

Carotid Body Innervation & Clinical Significance

The carotid body is innervated primarily by the glossopharyngeal nerve (cranial nerve IX) through the carotid sinus nerve (Hering's nerve) (Wahba et al., 2026).

- The carotid region also receives sympathetic fibers from the cervical sympathetic chain.

Because the close relationship with surrounding neurovascular structures, larger or more invasive CBTs may compress or involve adjacent cranial nerves (CN):

- CN IX – Glossopharyngeal
- CN X – Vagus
- CN XII – Hypoglossal (Aru et al., 2021)

8

© Copyright. Society of Diagnostic Medical Sonography. All Rights Reserved.

Carotid Body Anatomy

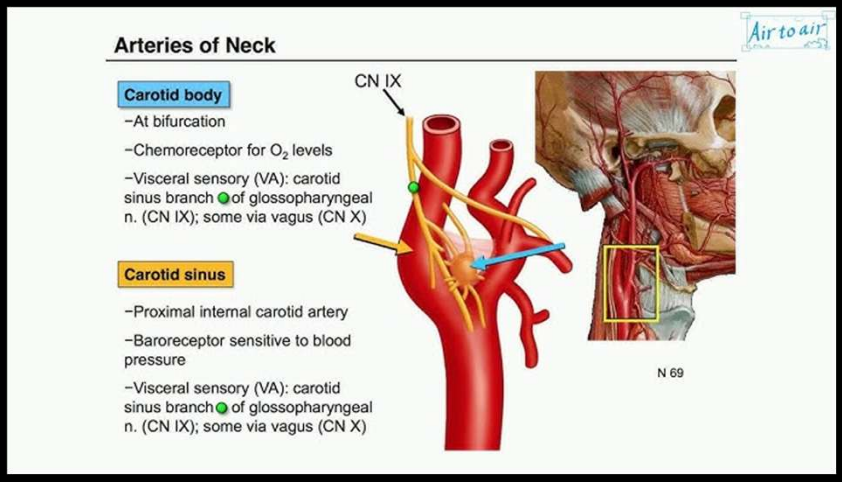

Image from https://share.google/6lj2rD6BvM2GdxJ1j accessed on July 1, 2026

9

Carotid Body Blood Supply

The carotid body is highly vascular, receiving its blood supply predominantly from branches of the external carotid artery (ECA).

- ECA branches (60.5%) the most common source.
- Common carotid artery (23%)
- The ascending pharyngeal artery specifically (10.3%). It is the major contributor (Seyedian, et al. 2025)

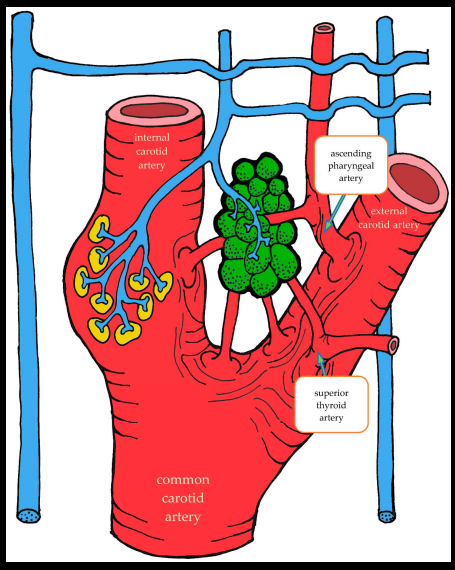

Image- Otlyga. Et al 2025 https://www.mdpi.com/1422-0067/26/22/11129 accessed on July 1, 2026

10

© Copyright. Society of Diagnostic Medical Sonography. All Rights Reserved.

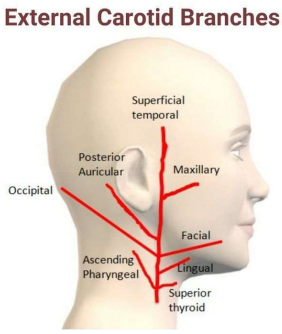

Image from https://www.pinterest.com/pin/68747899867/accessed on July 1, 2026

Carotid Body Blood Supply

Additional/accessory sources that may supply blood can arise from:

- Occipital artery
- Superior thyroid artery
- Other branches of the ECA (Kim, et al. 2025)

11

Carotid Body: Cellular Structure

The carotid body is embryologically derived from neural crest cells that migrate to the carotid bifurcation.

Its structural and functional units consist of clusters of cells called glomeruli.

Two types:

- Type I (chief) cells: Primary oxygen-sensing neuroendocrine cells, produce dopamine, and are the cells from which carotid body tumors arise.
- Type II (sustentacular) cells: Surround and support the chief cells and may promote cell proliferation during chronic hypoxia (insufficient oxygen to organs and tissues).

Additional cellular components include interstitial cells, adipocytes and macrophages.

(Forbes et al, 2023)

12

© Copyright. Society of Diagnostic Medical Sonography. All Rights Reserved.

Clinical Presentation

Typically, benign, slow growing circular neck mass.

Nonfunctional, it does not secrete hormones.

It arises at the carotid bifurcation, anterior to the sternocleidomastoid muscle, near the angle of the mandible. (Ozawa, et al 2024)



Image- Goldemund, D. 2026. https://www.stroke-manual.com/carotid-body-tumor/July 6, 2026

13

Clinical Presentation

As carotid body tumors enlarge, they produce the classic *Lyre sign* by splaying the internal and external carotid arteries.

Progressive tumor growth may compress adjacent cranial nerves, resulting in symptoms such as:

- Painless lateral neck mass (most common symptom)
- Hoarseness (dysphonia)
- Difficulty swallowing (dysphagia)
- Shoulder weakness (advanced cases due to cranial nerve involvement). (Kim, et al, 2025)

Lyre sign

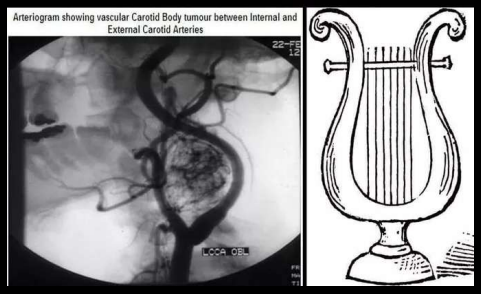

Image from https://medizzy.com/feed/7826218 accessed on July, 1, 2026

14

© Copyright. Society of Diagnostic Medical Sonography. All Rights Reserved.

Etiology & Genetic Factors

The exact cause of carotid body tumors (CBTs) remains unknown.

Approximately 30–40% of CBTs are associated with hereditary factors (Lin et al., 2021).

Most hereditary cases are associated with mutations in the succinate dehydrogenase (SDH) genes.

SDH genes are involved in mitochondrial energy metabolism and cellular oxygen sensing (Lin et al., 2021).

15

Risk Factors

The four major SDH genes include:

- SDHD – Succinate Dehydrogenase Complex Subunit D
  - Most commonly associated with familial head and neck paragangliomas
- SDHB – Succinate Dehydrogenase Complex Subunit B
  - Associated with a higher risk of malignant tumors, metastatic disease, and multifocal tumors
- SDHC – Succinate Dehydrogenase Complex Subunit C
  - Less common; usually associated with benign head and neck paragangliomas
- SDHA – Succinate Dehydrogenase Complex Subunit A
  - Rarely associated with hereditary paragangliomas

(Lin, et al, 2021)

16

© Copyright. Society of Diagnostic Medical Sonography. All Rights Reserved.

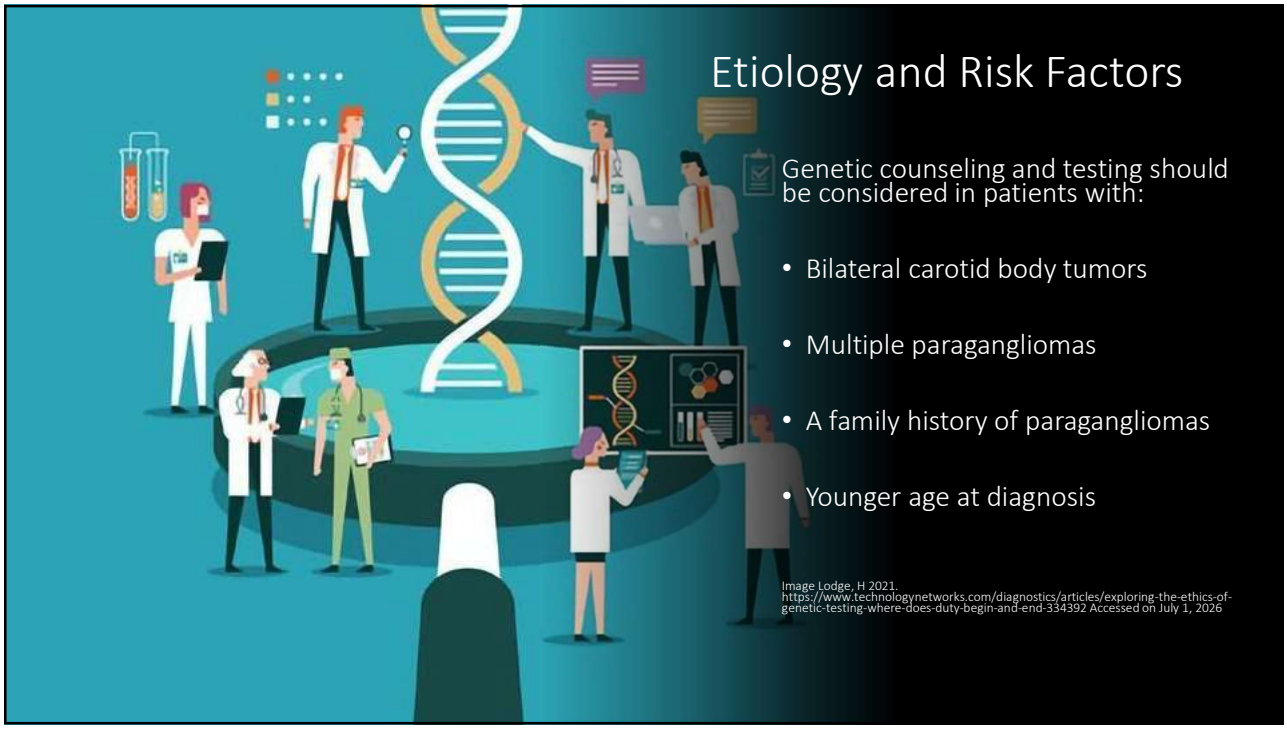

Etiology and Risk Factors

Genetic counseling and testing should be considered in patients with:

- Bilateral carotid body tumors
- Multiple paragangliomas
- A family history of paragangliomas
- Younger age at diagnosis

Image Lodge, H 2021. https://www.technologynetworks.com/diagnostics/articles/exploring-the-ethics-of-genetic-testing-where-does-duty-begin-and-end-334392 Accessed on July 1, 2026

17

Environmental Risk Factors

Chronic or intermittent hypoxemia has been proposed as a non-genetic risk factor for carotid body tumors.

Conditions associated with chronic hypoxemia include:

- High-altitude residence
- Chronic pulmonary disease
- Cyanotic congenital heart disease

Chronic hypoxia may stimulate carotid body hyperplasia, potentially contributing to tumor development.

However, the association between high-altitude exposure and CBTs remains uncertain, suggesting that genetic and other environmental factors may also contribute.

(Yu et al., 2026)

18

© Copyright. Society of Diagnostic Medical Sonography. All Rights Reserved.

Differential Diagnosis

Diagnosis	Ultrasound findings	CT findings	MRI findings	Angiography/DSA findings
Carotid body tumor	Well-defined, hypoechoic mass that splays apart the carotid bifurcation. Prominent hypervascularity and a low-resistance flow pattern on Doppler.	Soft-tissue-density mass at the carotid bifurcation Enhances heterogeneously Strong, rapid uptake in the early arterial phase.	Sits between the internal and external carotid arteries, with signal intensity. Has the classic "salt and pepper" appearance.	Splaying of the carotid vessels, with the ascending pharyngeal artery as the dominant feeding vessel;
Carotid artery aneurysm	Anechoic or complex fluid-filled sac in the arterial lumen. May show "yin-yang" turbulent flow, "to-and-fro" flow at a pseudoaneurysm neck.	Vessel-wall outpouching or diameter change; Wall irregularities or active extravasation if ruptured	Vessel lumen may appear oval, irregular, or slit-like in cross-section rather than round.	Useful for delineating the extent of the dissection and detecting any associated stenosis.
Carotid artery pseudoaneurysm	Shows a hypoechoic, cystic structure next to the true vessel lumen. Color Doppler reveals classic "to-and-fro" flow with a bidirectional waveform in the pseudoaneurysm neck.	Can demonstrate vessel wall irregularity and an irregular outpouching, findings consistent with rupture and active bleeding.	T1-weighted fat-suppressed sequences help evaluate intraluminal thrombus and measure the size of the pseudoaneurysm sac.	The gold standard for definitively evaluating a pseudoaneurysm.

Hoang, et al, 2019.

19

Differential Diagnosis

Diagnosis	Ultrasound findings	CT findings	MRI findings	Angiography/DSA findings
Neck hematoma/ thrombus	Shows a dilated, incompressible arterial segment with intraluminal clot, and no response to arterial compression maneuvers.	Hematoma appears as a high-density mass on non-contrast CT and shows no enhancement on contrast-enhanced CT.	Sits between the internal and external carotid arteries, with signal intensity close to muscle on T1-weighted images and hyperintense signal on T2-weighted images; the classic "salt and pepper" appearance reflects mixed flow voids and areas of hemorrhage/slow flow.	Can help localize the active arterial bleed or source of hemorrhage.
Glomus vagale tumor	Appears as a solid, heterogeneously hypoechoic lesion containing small vascular structures.	Shows a soft-tissue-density mass with heterogeneous enhancement.	Typically, low signal on T1-weighted images, high signal with multiple flow voids on T2-weighted images, and intense enhancement on T1 post-gadolinium sequences.	Similar vascular pattern to a carotid body tumor, but this lesion tends to displace the carotid artery anteriorly rather than splaying it.
Schwannoma	Allows direct visualization of the vagus nerve, so its relationship to the mass can be assessed; often causes increased separation between the carotid artery and jugular vein.	Appears as a soft-tissue-density mass that does not enhance with contrast.	Well-encapsulated tumors present as a round or oval mass, isointense to muscle on T1-weighted images and hyperintense on T2-weighted images; as nerve sheath tumors, they may or may not enhance.	Displaces the carotid artery and jugular vein together as a unit, rather than splaying them apart.

Hoang, et al, 2019.

20

© Copyright. Society of Diagnostic Medical Sonography. All Rights Reserved.

Differential Diagnosis

Diagnosis	Location	Vascularity	Lyre Sign	Key Differentiator
Carotid Body Tumor	Carotid bifurcation (posterior)	High	Yes (pathognomonic)	Splays ICA & ECA; highly vascular
Schwannoma	Along nerve course; may be parapharyngeal	Low	No	Avascular/hypovascular; 'target sign' on MRI
Cervical Lymphadenopathy	Variable; regional nodes	Variable	No	Fatty hilum; cortical thickening; often multiple
Thyroid Nodule (ectopic)	Anterior/medial	Variable	No	Moves with swallowing; isoechoic to thyroid
Carotid Aneurysm	Within carotid lumen	Very high (turbulent)	No	Pulsatile; direct arterial communication
Branchial Cleft Cyst	Lateral neck; anterior SCM	None	No	Anechoic; thin walls; no internal flow
Vagal Paraganglioma	ICA & ECA (more superior/rostral)	High	Sometimes	Displaces ICA anteriorly; no splaying

Jerosha, et al. 2024

21

Differential Diagnosis of Carotid Space Masses

Lesion Type	Displacement of Vessels	Common Features
Paraganglioma (Carotid Body Tumor)	Splaying of the carotid bifurcation (Lyre sign)	Highly vascular, enhancing imaging
Schwannoma	Anteromedial displacement of carotid artery	Homogeneous, slow-growing, well-defined, may cause nerve symptoms
Neurofibroma	Anteromedial displacement of carotid artery	Associated with neurofibromatosis, variable enhancement
Metastatic Lymphadenopathy	Variable displacement depending on size and location	Often multiple, irregular enhancement
Abscess	Anteromedial displacement of carotid artery	Rim-enhancing lesion, signs of infection
Carotid Artery Aneurysm	Displacement variable may be minimal	Fusiform or saccular dilatation of the artery
Glomus Vagale	Posterolateral displacement of carotid artery	Vascular mass at the skull base, similar to paraganglioma
Lymphoma	Variable displacement depending on size and location	Homogeneous, often encasing vessels
Meningioma	May encase and displace carotid artery	Dural attachment, enhancing with possible calcifications
Salivary Gland Tumors (e.g., Pleomorphic Adenoma)	Anteromedial displacement of vessels	Well-circumscribed, arising from the deep lobe of parotid
Branchial Cleft Cyst	Lateral displacement of the carotid artery	Cystic mass with possible infection or fistula

Image from https://www.cureus.com/articles/250460-the-radiological-assessment-of-carotid-space-lesions-a-case-series#!/Accessed on July 1, 2026

22

© Copyright. Society of Diagnostic Medical Sonography. All Rights Reserved.

Incidence of Carotid Body Tumors

- Rare with an incidence of 1-2 cases per 100,000 people.
- Accounts for approximately 0.5% of all head and neck tumors.
- Typically diagnosed between 30-50 years of age.
- Occurs more frequently in women. (Yu J, et al, 2026)

23

Diagnosing Carotid Body Tumors

Diagnosis relies on advanced vascular imaging to evaluate:

- Tumor size
- Vascular supply
- Degree of carotid artery encasement
- Relationship to adjacent neurovascular structures

Biopsies should be avoided because carotid body tumors are highly vascular, which places patients at risk for severe bleeding. (Ma, at al 2024)

24

© Copyright. Society of Diagnostic Medical Sonography. All Rights Reserved.

Imaging Methods used in Diagnosing Carotid Body Tumors

Duplex Ultrasound- First-line imaging modality.

- Portrays a hypervascular, solid mass at the carotid bifurcation.
- Characteristic "lyre sign" with splaying of the internal and external carotid arteries.
- Color and spectral Doppler assess vascularity and carotid blood flow. (Gaillard, et al 2026)

Magnetic Resonance Imaging (MRI)/MR Angiography (MRA)- Preferred modality for an overall evaluation

- Defines tumor size, margins, and skull base or cranial nerve involvement.
- Classic "salt-and-pepper" appearance on T1- and T2-weighted images due to flow voids and hemorrhage.
- Excellent for preoperative planning. (Gaillard, et al 2026)

25

Imaging Methods used in Diagnosing Carotid Body Tumors

Computed Tomography (CT) / CT Angiography (CTA)- Accurately evaluates tumor size and carotid artery involvement.

- Detects skull base and osseous involvement.
- Assists in Shamblin classification and assessment of surgical complexity. (Gaillard, et al 2026)

Digital Subtraction Angiography (DSA)- the gold standard.

- Defines vascular anatomy
- Identifies feeding vessels
- Used for planning preoperative embolization to reduce intraoperative blood loss. (Gaillard, et al 2026)

Functional Imaging (PET/CT)[68]

- Ga-DOTATATE PET/CT is highly sensitive for detecting somatostatin receptor–expressing paragangliomas.
- Identifies multifocal, recurrent, and metastatic disease.
- Particularly useful in patients with hereditary syndromes or SDHx gene mutations. (Gaillard, et al 2026)

26

© Copyright. Society of Diagnostic Medical Sonography. All Rights Reserved.

Classification of Carotid Body Tumors

Sporadic

- Most common type (85% of cases)
- Usually unilateral
- No known family history

Familial

- Approximately 10% of cases
- Often occurs at a younger age
- Typically, about 30% are bilateral
- Frequently associated with autosomal dominant inherited mutations (SDH gene mutations). (Yu, et al. 2026)

Hyperplastic

- Less common
- Depends on environmental factors
  - Hypoxia
  - High altitudes (Bobadilla-Rosado et al, 2024)

27

Treatment

The type of treatment depends on various factors such as:

- Patients' comorbidities (hypertension, diabetes, obesity, ESRD etc.)
- Overall Surgical risk- A comprehensive preoperative exam is important in assessing the risk of surgery.
- Tumor
  - Size
  - Location
  - Extent of carotid vessel involvement

CBTs were previously thought as highly aggressive with high malignancy rates; Current research as shown that there is a low metastasis incidence in fewer than 5% of cases. (Gonzalez, et al. 2023)

28

© Copyright. Society of Diagnostic Medical Sonography. All Rights Reserved.

Shamblin classification of Carotid Body Tumors

In the 1970's the Shamblin classification was first introduced categorize CBTs according to their relationship with the carotid arteries.

- It is the most widely used system for preoperative risk assessment and surgical planning.

Tumors with minimal, partial, or complete encasement of the carotid vessels are classified as:

Type I: Small

- Minimal attachment.
- No attachment to the carotid arteries.

Type II: Tumors that partially surround or adhere to the carotid vessels.

Type III: Large tumors that completely encase the carotid arteries. (Kim, et al, 2025)

29

Shamblin classification of Carotid Body Tumors

The traditional Shamblin primarily focuses on the size and relationship between the tumor and carotid vessels.

It excludes the arterial morphology or extent of tumor invasion into the parapharyngeal space (PPS) which is apparent in the Shamblin type III CBTs.

Several modified classification systems have been proposed to address these limitations. (Ma, at al 2024)

A visual representation is used to estimate the surgical complexity of carotid body tumor resection based on the tumor's relationship to the carotid vessels.

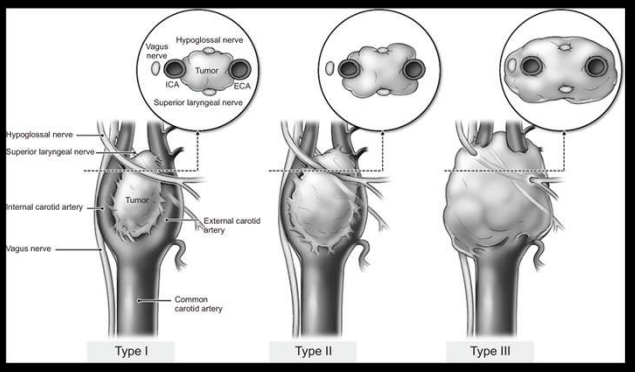

Image Kim, et al, 2025
https://www.vsijournal.org/journal/view.html?doi=10.5758/vsi.250063Accessed on July 1, 2026

30

© Copyright. Society of Diagnostic Medical Sonography. All Rights Reserved.

Figure Figure



Shamblin III Carotid Body Tumor

Image Ma, et al,2024 https://link.springer.com/article/10.1007/s10143-024-02389-x assessed on July 7, 2026

31

Treatment Options for Carotid Body Tumors

Treatment is individualized based on patient age, symptoms, tumor size, Shamblin classification, comorbidities, and vascular involvement.

Observation

- Appropriate for selected elderly, asymptomatic, or high-risk patients

Radiation therapy

- Considered for recurrent, unresectable, or high-surgical-risk tumors

Surgical resection

- Definitive treatment for appropriate surgical candidates

Surgical adjuncts may include:

- Preoperative embolization
- ICA reconstruction

(Gonzalez-Urquijo et al., 2023)

32

© Copyright. Society of Diagnostic Medical Sonography. All Rights Reserved.

Radiation Therapy

Radiation therapy is typically considered for inoperable or recurrent tumors and for elderly or high-risk patients.

- Primarily provides long-term tumor control rather than tumor removal.
- May limit continued tumor growth.
- Avoids some of the cranial nerve and vascular risks associated with surgical resection.

Techniques:

- External Beam Radiation Therapy (EBRT/IMRT): Fractionated radiation delivered while limiting exposure to surrounding structures.
- Stereotactic Radiosurgery (SRS): Highly focused radiation, such as Gamma Knife or CyberKnife, for selected small, well-defined tumors.

(Hernández et al., 2025)

33

Preoperative Embolization

Preoperative embolization may be performed before surgical resection to reduce the vascularity of the tumor.

Potential benefits:

- Reduces intraoperative blood loss
- Improves visualization of the operative field
- May facilitate tumor dissection
- Can decrease operative time

Technique:

- Selective catheterization and embolization of tumor-feeding arteries.
- Care is required to prevent non-target embolization and neurologic complications.

(Osofsky et al., 2021)

34

© Copyright. Society of Diagnostic Medical Sonography. All Rights Reserved.

Surgical Resection & ICA Reconstruction

Surgical resection provides definitive tumor removal and is generally considered for appropriate surgical candidates with symptomatic or progressive disease.

Surgical approach:

- Obtain vascular control of the CCA, ICA, and ECA
- Carefully dissect the tumor from the carotid vessels
- Control or ligate tumor-feeding vessels
- Preserve adjacent cranial nerves when possible

For advanced Shamblin III tumors involving or encasing the ICA, vascular reconstruction may be required.

35

Treatment Option- Surgical Resection

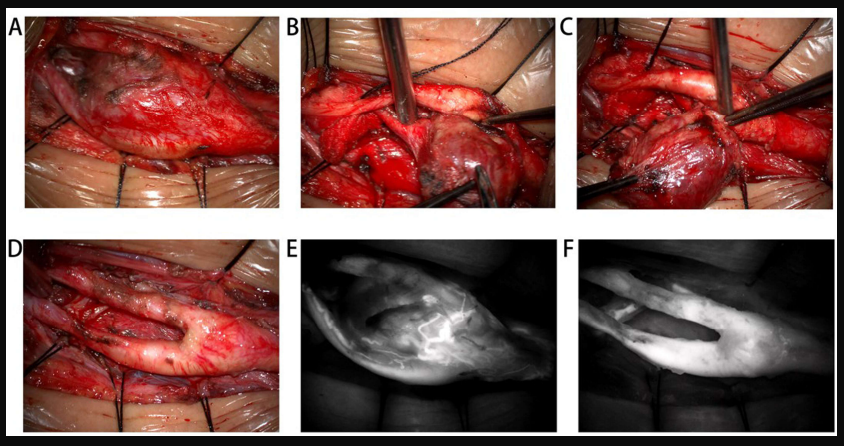

Images from Yu J, et al., 2025 https://pubmed.ncbi.nlm.nih.gov/41127900/ Accessed on June 30, 2026

36

© Copyright. Society of Diagnostic Medical Sonography. All Rights Reserved.

Surgical Resection & ICA Reconstruction con't

ICA reconstruction options include:

- Primary end-to-end anastomosis
- Interposition vein graft
- Prosthetic graft
- Selected endovascular or hybrid approaches

The goal is to maintain cerebral perfusion while allowing adequate tumor resection. (Ma et al., 2024)

37

Treatment Options- | Intraoperative ICA reconstruction

Figure 1



Figure 2



Figure 3



Images from Alqaim, et al, 2019. https://pmc.ncbi.nlm.nih.gov/articles/PMC6859284/Assessed on July 7, 2026

38

© Copyright. Society of Diagnostic Medical Sonography. All Rights Reserved.

Surgical Complications

Although the Shamblin classification helps estimate surgical complexity, postoperative outcomes also depend on tumor size, vascular involvement, prior treatment, and patient factors.

Cranial nerve injury

- Particularly involving the vagus (CN X) and hypoglossal (CN XII) nerves
- May result in:
  - Hoarseness
  - Dysphagia
  - Tongue weakness/paralysis
  - Other neurologic deficits

39

Surgical Complications

Vascular complications

- ICA injury
- Hemorrhage
- Thrombosis
- Stroke
- Need for vascular reconstruction

Vascular complications involving the ICA have been reported in approximately 2–13% of cases.

Preoperative embolization may decrease blood loss and operative time, but it does not necessarily reduce the incidence of cranial nerve injury. (Ma et al., 2024)

40

© Copyright. Society of Diagnostic Medical Sonography. All Rights Reserved.

Case Studies



41

Case 1- Introduction

A 42-year-old woman presented with a one-year history of a gradually enlarging left-sided neck mass. She was otherwise asymptomatic, with no evidence of dysphagia, hoarseness, dyspnea, or other compressive symptoms.

Physical examination of the left jugulocarotid region near the angle of the mandible revealed:

- A Firm 4 × 3 cm mass
  - Painless
  - Mildly pulsatile
  - Mobile in a transverse plane
  - Displayed a faint bruit on auscultation

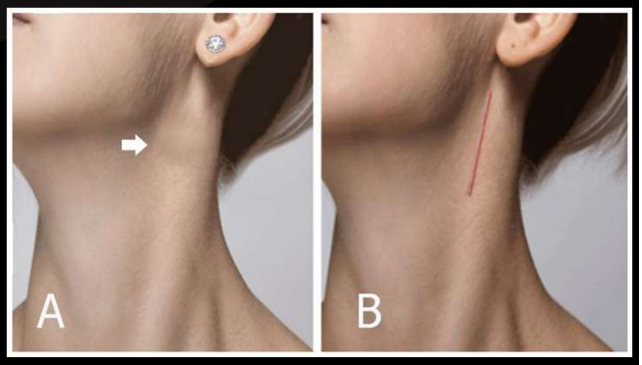

Image- Hoang, et al, 2019. https://www.researchgate.net/publication/335562951_Carotid_body_tumor_a_case_report_and_literature_review/citation/download Accessed July 6, 2026

42

© Copyright. Society of Diagnostic Medical Sonography. All Rights Reserved.

Case 1- Carotid artery duplex ultrasound

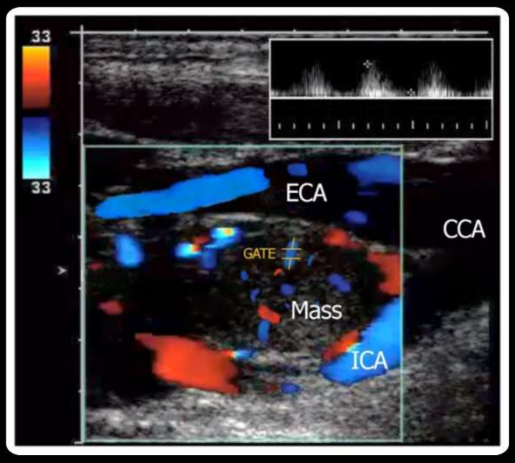

Image- Hoang, et al, 2019. https://www.researchgate.net/publication/335562951_Carotid_body_tumor_a_case_report_and_literature_review/citation/download Accessed July 6, 2026

A carotid artery duplex ultrasound was performed, the results revealed:

- Gray-scale imaging
  - Demonstrated a well-defined, hypoechoic mass.
  - At the carotid bifurcation between the internal carotid artery (ICA) and external carotid artery (ECA).
- Color Doppler imaging
  - Demonstrated marked internal vascularity, a hallmark feature of carotid body paragangliomas.
- Spectral Doppler waveform analysis
  - Resulted in a low-resistance arterial flow within the lesion.

The mass produces the characteristic splaying of the ICA and ECA (Lyre sign) without evidence of luminal narrowing or vascular compromise.

43

Case 1- Computed tomography (CT) images

FINDINGS:

- A- CT without contrast illustrates a mass at the left carotid bifurcation.
- Images B–D shows CT images with contrast obtained during the early arterial phase shows a heterogeneously and hypervascular mass at the carotid bifurcation.
  - Produces characteristic splaying of the internal carotid artery and external carotid artery (Lyre sign).
- E. A CT angiography reconstruction illustrates the carotid body tumor and its relationship to the carotid bifurcation.

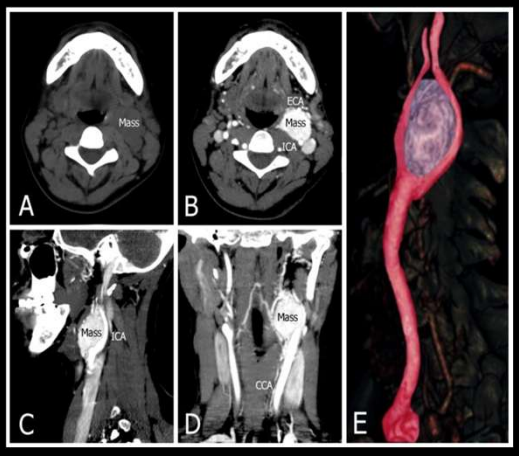

Image- Hoang, et al, 2019. https://www.researchgate.net/publication/335562951_Carotid_body_tumor_a_case_report_and_literature_review/citation/download Accessed July 6, 2026

44

© Copyright. Society of Diagnostic Medical Sonography. All Rights Reserved.

Case 1- Discussion

- The patient had a Shamblin II CBT, it was successfully resected without incident.
- Her CCA, ICA and ECA were preserved, small branches from her bifurcation were ligated.
- It was confirmed that her carotid body tumor had the characteristic of nests of uniform epithelioid cells with granular cytoplasm, a round nuclei, surrounded by a vascular stroma.

45

Case 2- Introduction

An 87-year-old male with a history of left carotid body tumor resection 17 years earlier and thyroidectomy for thyroid cancer 5 years earlier presented with:

- Sudden onset of left-sided facial pain localized around his left eye and radiating to his left neck and chest.
  - The episode lasted approximately five minutes.
- Chronic hoarseness
  - More than 1 year, which had progressively worsened over the previous weeks
  - Intermittent dysphagia that had been present for approximately two weeks.

46

© Copyright. Society of Diagnostic Medical Sonography. All Rights Reserved.

Case 2- Physical Examination

Examination of the neck revealed

- Left-sided palpable neck mass
- Located anterior to the sternocleidomastoid muscle
- Mildly pulsatile
- Previous surgical scars

Symptoms

- Hoarseness
- Dysphagia

47

Case 2- Ultrasound Results

A Carotid duplex ultrasound demonstrated a well-defined, oval, solid hypoechoic mass at the left carotid artery bifurcation, measuring approximately 28 × 15 × 23 mm.

The lesion was homogeneous and produced splaying of the internal and external carotid arteries (Lyre sign), with partial involvement of the adjacent vessel walls.

Color and power Doppler imaging revealed marked internal vascularity, with the tumor supplied primarily by branches of the left external carotid artery (ECA).

48

© Copyright. Society of Diagnostic Medical Sonography. All Rights Reserved.

Case 2- Images

The two images represent the Lt left lateral side of the neck.

There is a slow-growing, non-tender, and rubbery mass in between the ICA and ECA.

Figure 1



Figure 2

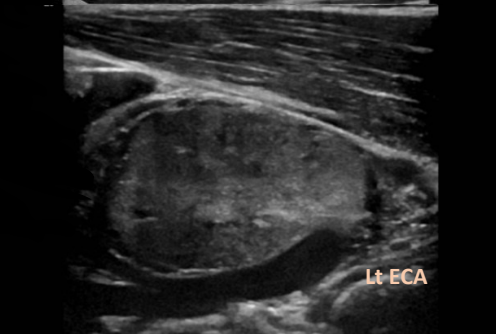

Images- Tarawneh, M. 2023 https://radiopaedia.org/cases/carotid-body-tumour-31 assessed on July 7, 2026

49

Case 2- Ultrasound Results Lt side

Figure 3

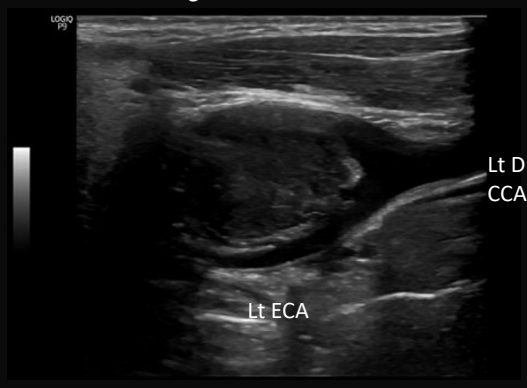

Figure 4

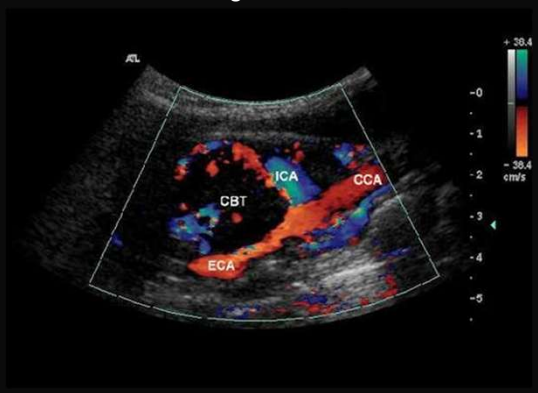

Images- Tarawneh, M. 2023 https://radiopaedia.org/cases/carotid-body-tumour-31 assessed on July 7, 2026

50

© Copyright. Society of Diagnostic Medical Sonography. All Rights Reserved.

Case 2- CT Images

Figure 5



Figure 6

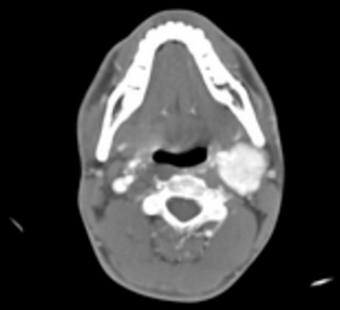

Images- Tarawneh, M. 2023 https://radiopaedia.org/cases/carotid-body-tumour-31 assessed on July 7, 2026

51

Case 2- Discussion

Due to the patient's advanced age, biopsy and surgical resection were not recommended, but conservative management with observation was chosen.

This case highlights the value of duplex ultrasound as a noninvasive, cost-effective, and readily available modality for the diagnosis and follow-up of carotid body tumors.

Although CT, MRI, and angiography provide additional anatomic detail for diagnosis and surgical planning, observation was considered the most appropriate management strategy for this 87-year-old patient.

52

© Copyright. Society of Diagnostic Medical Sonography. All Rights Reserved.

Case 3- Introduction

A 65-year-old man presented with a gradually enlarging, painless right-sided neck mass of six months' duration. Physical examination revealed a firm, non-tender swelling on the right side of the neck. Ultrasound demonstrated a well-defined, homogeneous lesion measuring 1.3 × 0.98 cm at the right carotid bifurcation, consistent with a small carotid body tumor (CBT).

53

Case 3- Images

Figure 1- Rt CBT



Figure 2- Rt ICA & ECA



Figure 3- Rt ICA & ECA

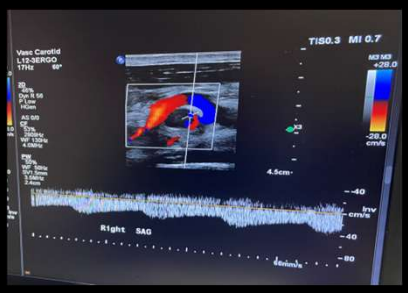

Images are from the personal files of Moree, S

54

© Copyright. Society of Diagnostic Medical Sonography. All Rights Reserved.

Case 3- Images

Figure 4- Rt CBT



Figure 5- Rt CBT

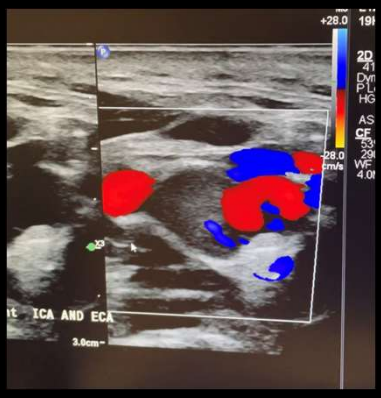

Images are from the personal files of Moree, S

55

Case 3- Discussion

Treatment: Active Surveillance

Active surveillance with periodic imaging may be appropriate for selected patients with small, asymptomatic, or slow-growing carotid body tumors.

Particularly appropriate for:

- Older patients
- Patients with significant comorbidities
- Patients in whom the risks of intervention outweigh the benefits

Follow-up may include duplex ultrasound and/or MRI at regular intervals to evaluate:

- Tumor size and growth
- Vascular involvement
- Development of new symptoms

56

© Copyright. Society of Diagnostic Medical Sonography. All Rights Reserved.

Case 4- Introduction

A 25-year-old man presented with hypertension, intermittent palpitations, headache, vomiting, and a tender right submandibular mass.

Duplex ultrasound demonstrated a 5.3 cm heterogeneous, hypervascular mass at the right carotid bifurcation. The mass caused marked splaying and compression of the internal carotid artery (ICA) and external carotid artery (ECA), producing the characteristic lyre sign and supporting the diagnosis of a carotid body tumor (CBT).

Laboratory testing demonstrated elevated catecholamine levels, raising concern for a functioning (secretory) paraganglioma.

57

Case 4- Ultrasound Images

Figure A- Rt CCA, ICA and ECA

Figure B- Rt CCA, ICA and ECA

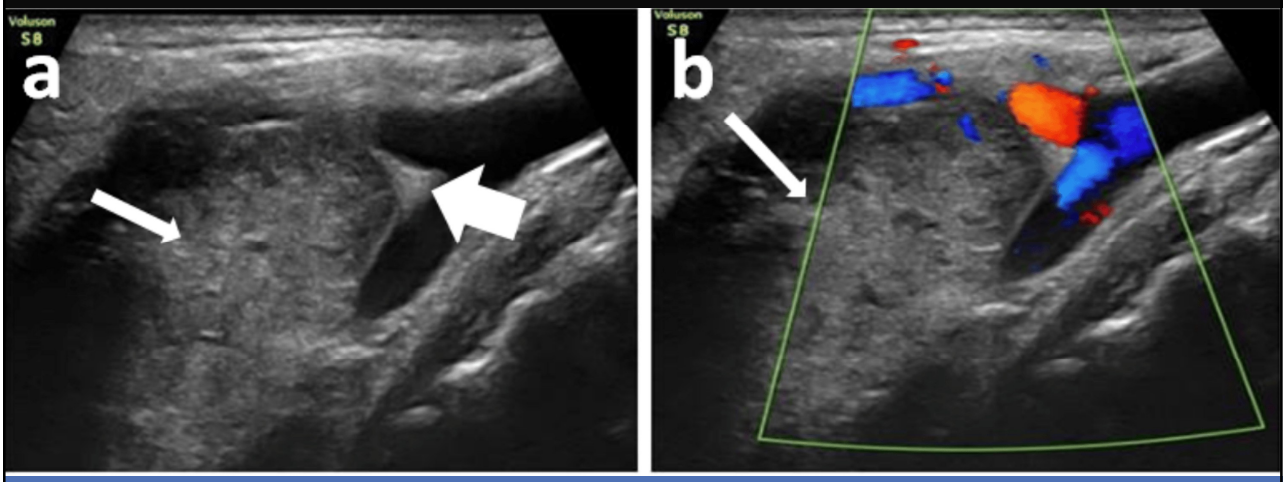

Image from https://www.cureus.com/articles/250460-the-radiological-assessment-of-carotid-space-lesions-a-case-series#!/Accessed on July 1, 2026

58

© Copyright. Society of Diagnostic Medical Sonography. All Rights Reserved.

Case 4-Contrast-Enhanced Computed Tomography

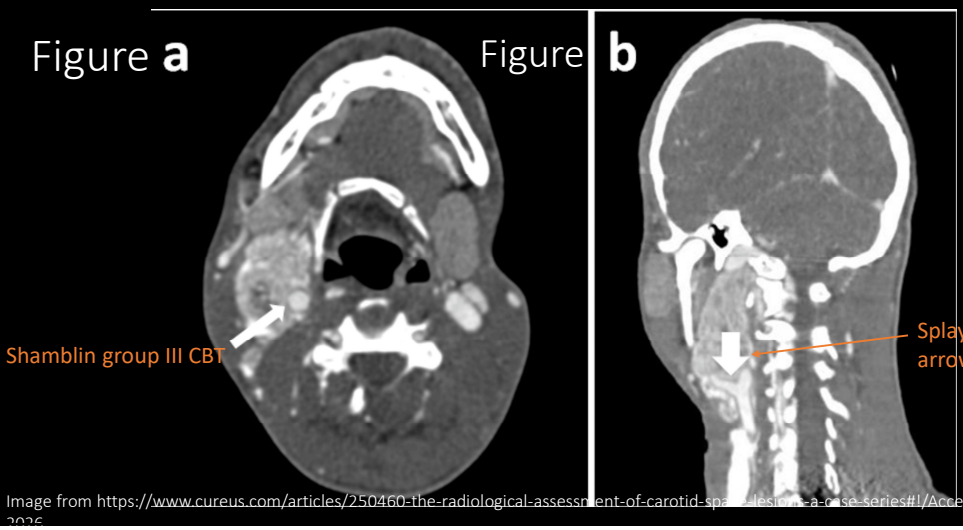

Image from https://www.cureus.com/articles/250460-the-radiological-assessment-of-carotid-space-lesions-a-case-series#!/Accessed on July 1, 2026

59

Case 4-Contrast-Enhanced Computed Tomography

The lesion was classified as Shamblin III, with greater than 270° encasement of the carotid vessels.

A three-dimensional volume-rendered CT reconstruction demonstrates splaying of the internal and external carotid arteries.



Image from https://www.cureus.com/articles/250460-the-radiological-assessment-of-carotid-space-lesions-a-case-series#!/Accessed on July 1, 2026

60

© Copyright. Society of Diagnostic Medical Sonography. All Rights Reserved.

Case 4- Discussion

The lesion was surgically excised, and a histopathological examination of the specimen confirmed the diagnosis of paraganglioma.

61

Case 5-BILATERAL CAROTID BODY TUMORS

A 62-year-old man with known bilateral carotid body tumors (CBTs) underwent follow-up carotid duplex ultrasound with 3D ultrasound reconstruction to assess interval progression and further characterize both tumors.

Previous MRI – December 7, 2020:

- Left CBT: 0.8 × 0.5 cm
- Right CBT: 3.3 × 2.9 × 2.3 cm

Current Presentation:

- Progressive enlargement of the left-sided neck mass
- Mild left-sided neck pain while shaving

The follow-up duplex examination was performed to evaluate interval tumor growth, vascularity, and the relationship of the tumors to the carotid vessels.

62

© Copyright. Society of Diagnostic Medical Sonography. All Rights Reserved.

Case 5- Rt CCA

Figure 1 Figure 2 Figure 3



Images are from the personal files of Eisenhart, T & Nofzinger, M.

63

Case 5- Rt Bifurcation

Figure 3 Figure 4 Figure 5

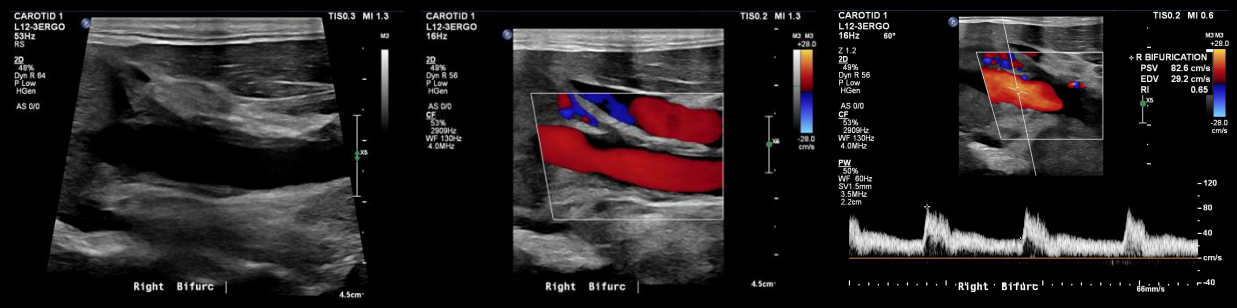

Images are from the personal files of Eisenhart, T & Nofzinger, M.

64

© Copyright. Society of Diagnostic Medical Sonography. All Rights Reserved.

Case 5-Rt ECA

Figure 6

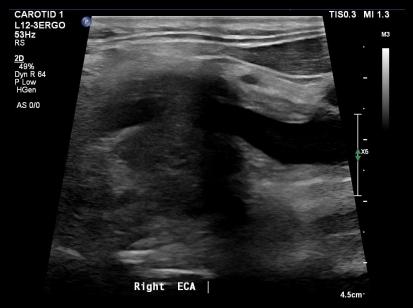

Figure 7

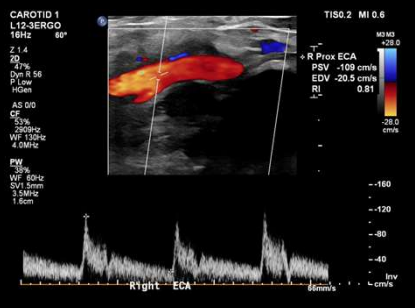

Figure 8

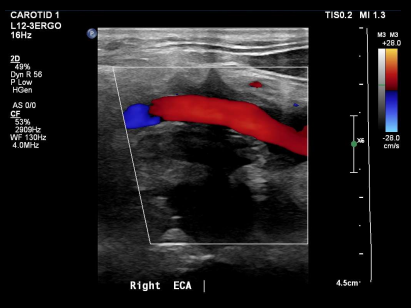

Images are from the personal files of Eisenhart, T & Nofzinger, M.

65

Case 6-Rt ICA

Figure 9

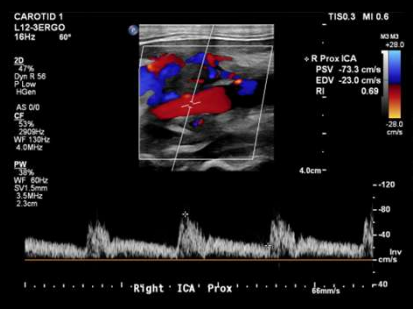

Figure 10

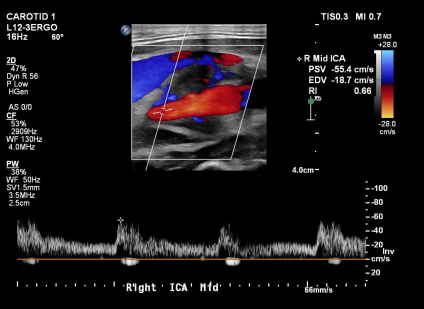

Figure 11



Images are from the personal files of Eisenhart, T & Nofzinger, M.

66

© Copyright. Society of Diagnostic Medical Sonography. All Rights Reserved.

Case 5- Rt CCA CBT Trans

Figure 12



Figure 13

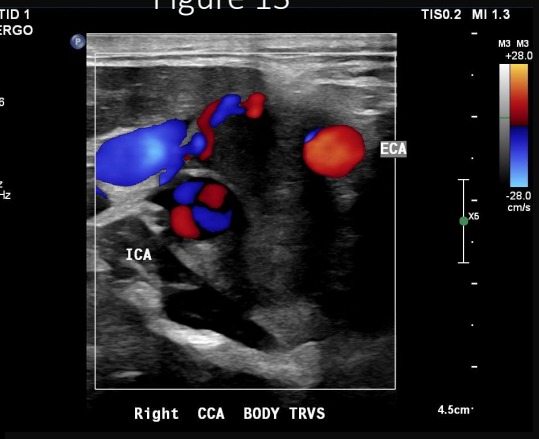

Images are from the personal files of Eisenhart, T & Nofzinger, M.

67

Case 5-Rt CCA CBT Sag

Figure 14



Figure 15



Images are from the personal files of Eisenhart, T & Nofzinger, M.

68

© Copyright. Society of Diagnostic Medical Sonography. All Rights Reserved.

Case 5-Rt CCA CBT Sag

Figure 16



Figure 17

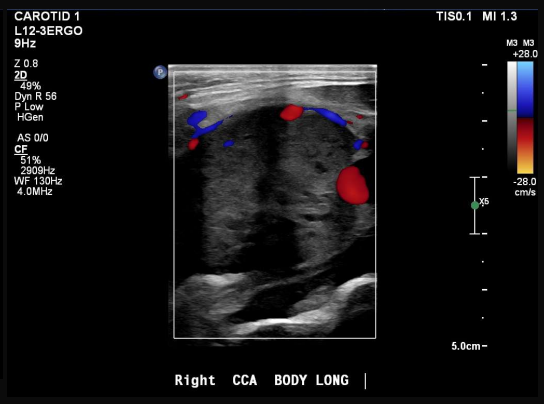

Images are from the personal files of Eisenhart, T & Nofzinger, M.

69

Case 5- Rt ICA CBT Sag

Figure 18

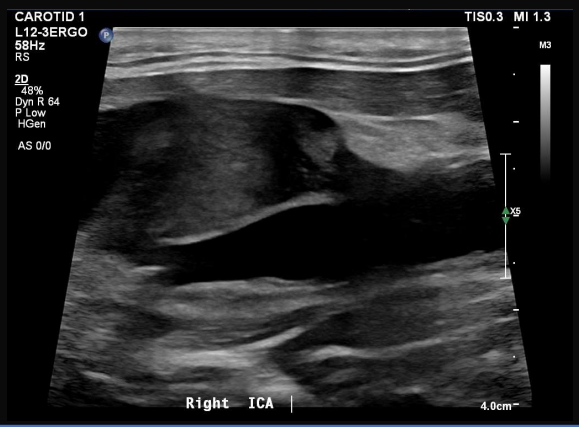

Figure 19

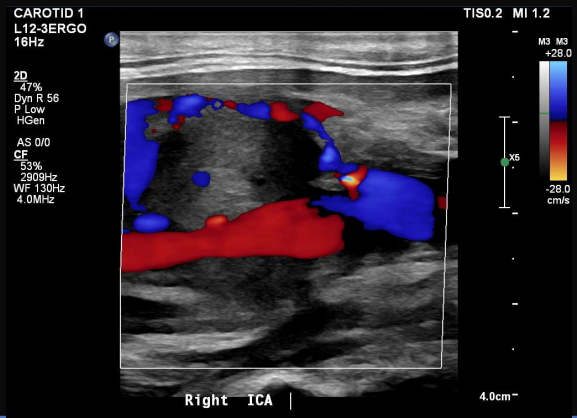

Images are from the personal files of Eisenhart, T & Nofzinger, M.

70

© Copyright. Society of Diagnostic Medical Sonography. All Rights Reserved.

Case 5- Left CCA

Figure 20

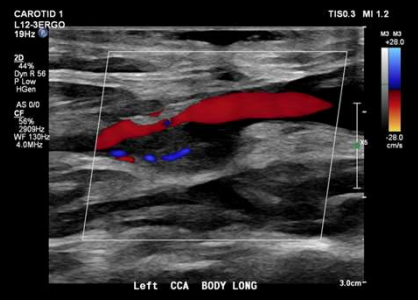

Figure 21



Figure 22



Images are from the personal files of Eisenhart, T & Nofzinger, M.

71

Case 5- Left CCA

Figure 23



Figure 24



Images are from the personal files of Eisenhart, T & Nofzinger, M.

72

© Copyright. Society of Diagnostic Medical Sonography. All Rights Reserved.

Case 5- Left CCA

Figure 24



Figure 25

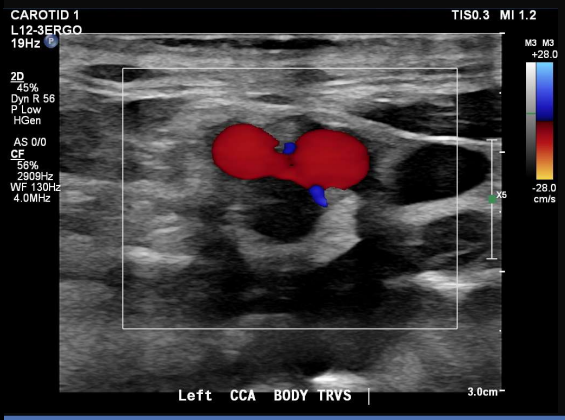

Images are from the personal files of Eisenhart, T & Nofzinger, M.

73

Case 5- RT CCA

- 3D reconstructions were obtained for both carotid body tumors.
- The images demonstrated asymmetric tumor size and displacement of the carotid vessels.
- 3D imaging provided enhanced visualization of the spatial relationship between the tumors and adjacent carotid arteries.
- This additional anatomic information may assist with clinical assessment and treatment planning.

Figure 26



Figure 27



Images are from the personal files of Eisenhart, T & Nofzinger, M.

74

© Copyright. Society of Diagnostic Medical Sonography. All Rights Reserved.

Case 5-RT CCA

Figure 28

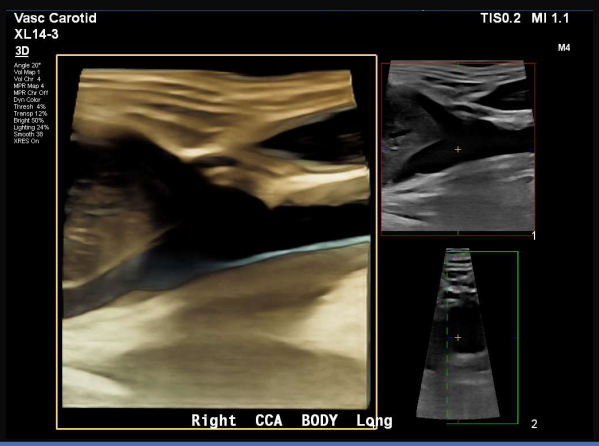

Figure 29



Images are from the personal files of Eisenhart, T & Nofzinger, M.

75

Case 5-LT CCA

Figure 30



Figure 31

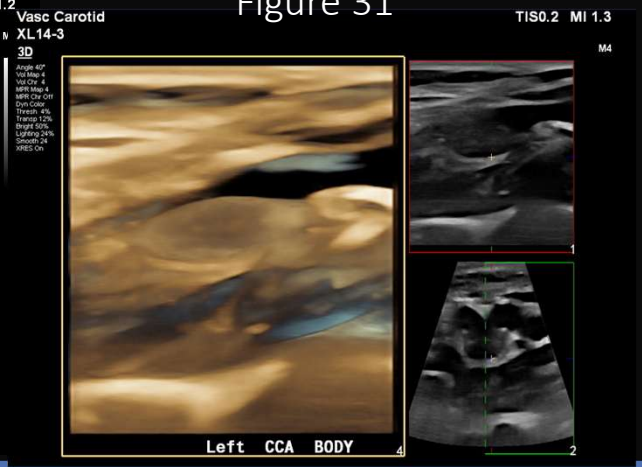

Images are from the personal files of Eisenhart, T & Nofzinger, M.

76

© Copyright. Society of Diagnostic Medical Sonography. All Rights Reserved.

Case 5- Results

Previous Imaging

- Right CBT: 3.3 × 2.9 × 2.3 cm
- Left CBT: 0.8 × 0.5 cm

Current Examination

Right Carotid Body Tumor

- Increased in size to 4.3 × 3.5 × 3.5 cm
- Demonstrated increased internal vascularity with color Doppler
- Mild mass on the internal carotid artery (ICA)

Left Carotid Body Tumor

- Measured 0.8 × 1.6 × 0.7 cm, demonstrating some growth
- Well-defined and appears hypervascular with color Doppler
- No evidence of carotid wall invasion or significant mass effect

77

Case 5- Discussion

Management and Follow-Up

- Minimal tumor growth compared with previous imaging.
- No evidence of significant neurovascular compromise.
- Conservative management was selected due to the absence of significant symptoms.
- Periodic ultrasound surveillance will monitor for:
  - Tumor growth
  - Vascular involvement
  - New or worsening symptoms

78

© Copyright. Society of Diagnostic Medical Sonography. All Rights Reserved.

Conclusion

As demonstrated through the five case studies and supporting literature, advances in diagnostic imaging and treatment have improved the detection, characterization, and management of carotid body tumors.

Duplex ultrasound remains a valuable first-line imaging modality, allowing sonographers to recognize the characteristic location, hypervascularity, and relationship of CBTs to the carotid arteries.

Treatment should be individualized based on:

- Tumor characteristics
- Patient age, symptoms, and comorbidities
- Genetic risk
- Imaging findings
- Potential complications

Early recognition of the characteristic sonographic features of CBTs is essential for prompt diagnosis, appropriate multidisciplinary management, and long-term surveillance.

79

References

- Hoang VT, Trinh CT, Lai TAK, Doan DT, Tran TTT. Carotid body tumor: a case report and literature review. J Radiol Case Rep. 2019 Aug 31;13(8):19-30. doi: 10.3941/jrcr.v13i8.3681. PMID: 31558967; PMCID: PMC6738487.
- Aru RG, Aouad RK, Fraser JF, Romesberg AM, Hatton KW, Tyagi SC. Operative management of symptomatic, metachronous carotid body tumors involving the skull base and its neurological sequelae. J Vasc Surg Cases Innov Tech. 2021 May 20;7(3):378-381. doi: 10.1016/j.jvscit.2021.04.018. PMID: 34278062; PMCID: PMC8261542.
- Forbes Kaprive J, Menezes RG. Anatomy, Head and Neck: Carotid Bodies. [Updated 2023 Jul 25]. In: StatPearls [Internet]. Treasure Island (FL): StatPearls Publishing; 2026 Jan-. Available from: https://www.ncbi.nlm.nih.gov/books/NBK562237/
- Yu J, Yuan W, Cao K, et al. Carotid Body Tumors: From Basic to Clinical Practice. Vascular and Endovascular Surgery. 2026;60(3):244-254. doi:10.1177/15385744251387662
- Wahba M, Willox G, Hacking C, et al. Glossopharyngeal nerve. Reference article, Radiopaedia.org (Accessed on 01 Jul 2026) https://doi.org/10.53347/rID-7173

80

© Copyright. Society of Diagnostic Medical Sonography. All Rights Reserved.

References

- Seyedian Moghaddam A, Geyer SH, Dogan B, Pruidze P, Weninger JT, Schwendt KM, Weninger WJ. Blood supply of the human carotid body. Sci Rep. 2025 Jul 1;15(1):22043. doi: 10.1038/s41598-025-05974-2. PMID: 40592941; PMCID: PMC12214507.
- Otlyga, D., Otlyga, E., Junemann, O., Krivova, Y., & Saveliev, S. (2025). The Carotid Body as Part of a Unified Sympathoadrenal System of Neural Crest Derivatives: Insights from Two Centuries of Research. International Journal of Molecular Sciences, 26(22), 11129. https://doi.org/10.3390/ijms262211129
- Kim YW. Current Understanding of Carotid Body Paraganglioma Management. Vasc Specialist Int 2025. https://doi.org/10.5758/vsi.250063
- Forbes Kaprive J, Menezes RG. Anatomy, Head and Neck: Carotid Bodies. [Updated 2023 Jul 25]. In: StatPearls [Internet]. Treasure Island (FL): StatPearls Publishing; 2026 Jan-. Available from: https://www.ncbi.nlm.nih.gov/books/NBK562237/
- Ozawa, H. (2024). Current Management of Carotid Body Tumors. Auris Nasus Larynx, 51(3), 501–506. https://doi.org/10.1016/j.anl.2024.01.007

81

References

- Lin, E. P., Chin, B. B., Fishbein, L., Moritani, T., Montoya, S. P., Ellika, S., & Newlands, S. (2022). Head and neck paragangliomas: An update on the molecular classification, state-of-the-art imaging, and management recommendations. Radiology: Imaging Cancer, 4(3), Article e210088. https://doi.org/10.1148/rycan.210088
- Jerosha S, Subramonian S, Ramakrishnan K (June 11, 2024) The Radiological Assessment of Carotid Space Lesions: A Case Series. Cureus 16(6): e62202. doi:10.7759/cureus.62202
- Ma, Q., Si, Y., Sun, M. et al. Novel insights into the classification of Shamblin III carotid body tumors from a neurosurgical perspective. Neurosurg Rev 47, 141 (2024). https://doi.org/10.1007/s10143-024-02389-x
- Gaillard F, Kumar K, Walizai T, et al. Carotid body tumor. Reference article, Radiopaedia.org (Accessed on 07 Jul 2026) https://doi.org/10.53347/rID-4629
- Bobadilla-Rosado LO, Anaya-Ayala JE, Santos-Chavez E, et al. Retrocarotid dissection technique compared to the caudocranial approach for the surgical treatment of carotid body tumors: A 15-year experience. Vascular Medicine. 2024;29(3):302-308. doi:10.1177/1358863X241242740

82

© Copyright. Society of Diagnostic Medical Sonography. All Rights Reserved.

References

- Gonzalez-Urquijo M, Hinojosa-Gonzalez DE, Fabiani MA, et al. High Altitude Carotid Body Tumors Growth During active Surveillance. Vascular and Endovascular Surgery. 2023;57(5):451-455. doi:10.1177/15385744231154089
- Hernández YB, Herrera VV, Gómez KV, Martinez ALL. Treatment with radiotherapy in carotidal paraganglioma: experience of the General Hospital of Mexico. Rep Pract Oncol Radiother. 2025 Aug 7;30(3):345-351. doi: 10.5603/rpor.106150. PMID: 40919246; PMCID: PMC12413236.
- Alqaim M, Puri AS, Vaezi AE, Schanzer A. Carotid body tumor resection utilizing a covered stent graft to enable resection of the tumor en bloc with the internal carotid artery. J Vasc Surg Cases Innov Tech. 2019 Nov 13;5(4):481-484. doi: 10.1016/j.jvscit.2019.07.012. PMID: 31763503; PMCID: PMC6859284.
- Osofsky R, Clark R, Das Gupta J, Boyd N, Olson G, Chavez L, Guliani S, Langsfeld M, Marek J, Rana MA. The effect of preoperative embolization on surgical outcomes for carotid body tumor resection. SAGE Open Med. 2021 Mar 30;9:20503121211005229. doi: 10.1177/20503121211005229. PMID: 33854776; PMCID: PMC8013905.

83



84

© Copyright. Society of Diagnostic Medical Sonography. All Rights Reserved.