Imaging the Left Atrial Appendage Pre and Post Left Atrial Appendage Device Implantation

Margaret M. Park, BS, ACS, RDCS, RVT, FASE, FSDMS
Lead HVTI Research Imaging Specialist
C5Research, Cleveland Clinic
Cleveland, Ohio
SDMS 2026 Annual Meeting Atlanta, Georgia

1

SPEAKER PRESENTATION DISCLAIMER

The content and views presented are made available for educational purposes only. The information presented are the opinions of the presenter and do not necessarily represent the views of the Society of Diagnostic Medical Sonography (SDMS) or its affiliated organizations, officers, Boards of Directors, or staff members.

The presenter is responsible for ensuring balance, independence, objectivity, scientific rigor, and avoiding commercial bias in their presentation. Before making the presentation, the presenter is required to disclose to the audience any relevant financial interests or relationships with manufacturers or providers of medical products, services, technologies, and programs.

The SDMS and its affiliated organizations, officers, Board of Directors, and staff members disclaim any and all liability for all claims that may arise out of the use of this educational activity.

2

© Copyright. Society of Diagnostic Medical Sonography. All Rights Reserved.

RESEARCH DISCLAIMER

The information presented in this presentation is based on research conducted to the best of the presenters' abilities and knowledge. Research involves uncertainty and is subject to limitations. The findings and conclusions presented herein may be influenced by various factors including but not limited to data quality, methodology, assumptions, and interpretation.

Research outcomes may not always accurately predict real-world scenarios or future events. While the presenter may make efforts to ensure the accuracy and reliability of the information presented, completeness or absolute correctness is not guaranteed. This presentation is intended for informational purposes only and should not be construed as professional advice. Participants are encouraged to independently verify any information provided and consult relevant experts or professionals where appropriate.

The SDMS and its affiliated organizations, officers, Board of Directors, and staff members disclaim any and all liability for all claims that may arise out of the use of this educational activity.

3

Conflicts of Interest

- Speaker Lantheus Medical Imaging
- Consultant with Siemens Healthineers

4

© Copyright. Society of Diagnostic Medical Sonography. All Rights Reserved.

Learning Objectives

1. By the end of this talk, attendees will be able to:
2. Identify goals of pre and post Left Atrial Appendage Occlusion (LAAO) imaging.
3. Compare TEE vs Cardiac CT for follow up.
4. Recognize normal vs abnormal post implant findings.
5. Apply imaging findings to clinical decision making.
6. Gain insight, understanding and appreciation for the role of multimodality imaging in Left Atrial Appendage Occlusion.

5



Atrial Fibrillation (AF)

- Most common arrhythmia worldwide
- Systemic thromboembolism is a major complication of valvular and nonvalvular AF
- Left atrial appendage (LAA) most common site of thrombus formation 91% of left heart thrombi in patients with nonrheumatic AF and 57% with rheumatic AF

Cleveland Clinic

C5Research

6

© Copyright. Society of Diagnostic Medical Sonography. All Rights Reserved.

TTE Anatomic Relationship LAA

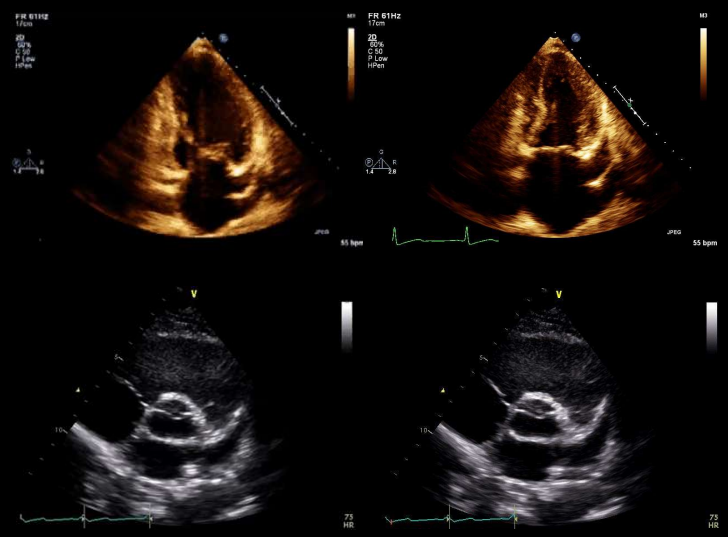

Cleveland Clinic

C5Research

7

Anatomic Relationship LAA

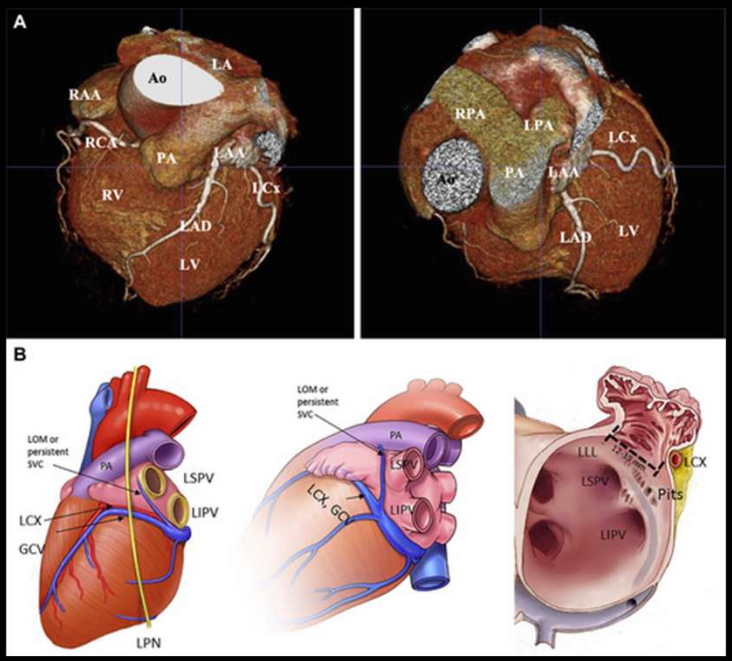

Cleveland Clinic

8

© Copyright. Society of Diagnostic Medical Sonography. All Rights Reserved.

LAA Anatomy

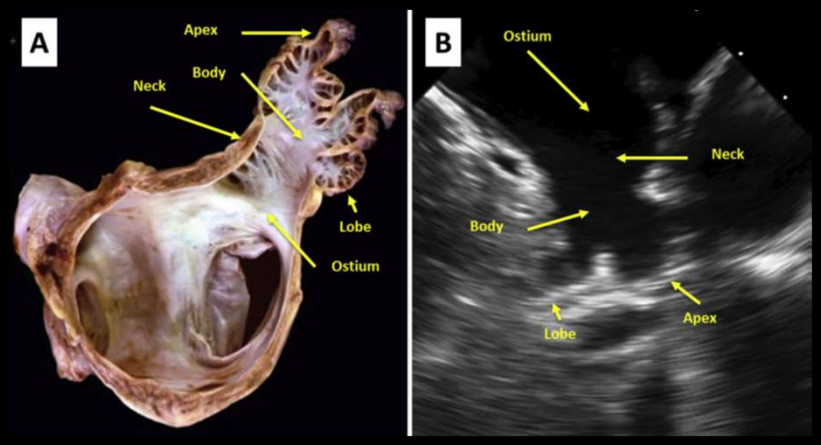

J Am Soc Echocardiogr 2018;31:454-74

Cleveland Clinic

C5Research

9

LAA Contractility PW Doppler

- Sample volume(SV) placed within proximal 1/3 of the LAA toward LA
- Careful to avoid artifact from the LAA wall
- Keep gain low, SV parallel to flow

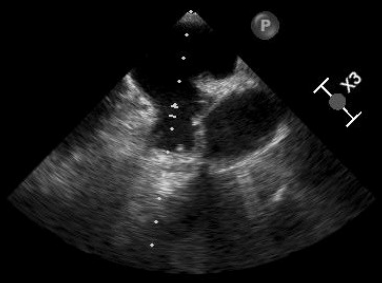

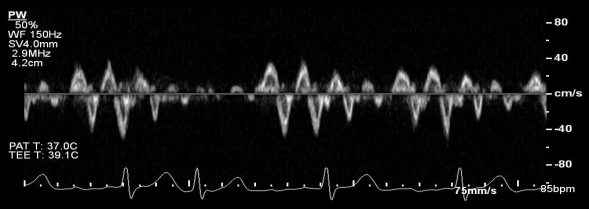

Cleveland Clinic

C5Research

10

© Copyright. Society of Diagnostic Medical Sonography. All Rights Reserved.

LAA Pulsed Doppler

1. LAA contraction (emptying), positive deflection shortly following the onset of the ECG P wave
2. LAA filling, nearly systolic, negative deflection following LA contraction
3. Systolic reflection waves, positive & negative, following LAA contraction and filling
4. Early diastolic LAA flow, a low velocity outflow signal (mitral E wave)

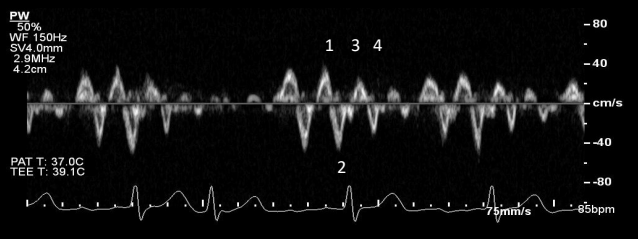

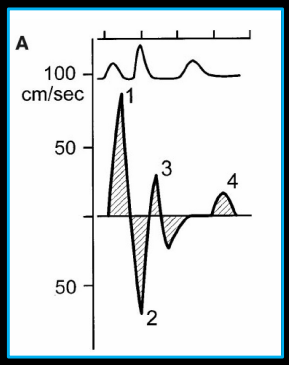

Cleveland Clinic

Agmon et al; JACC Vol.34, No. 7, 1999, 1867-77

11

LAA Anatomic Variants

- LAA orifice separated from the left-sided pulmonary veins by the ligament of Marshall also referred to as the Coumadin ridge
- May contain one or more lobes, defined as protrusions from its main body

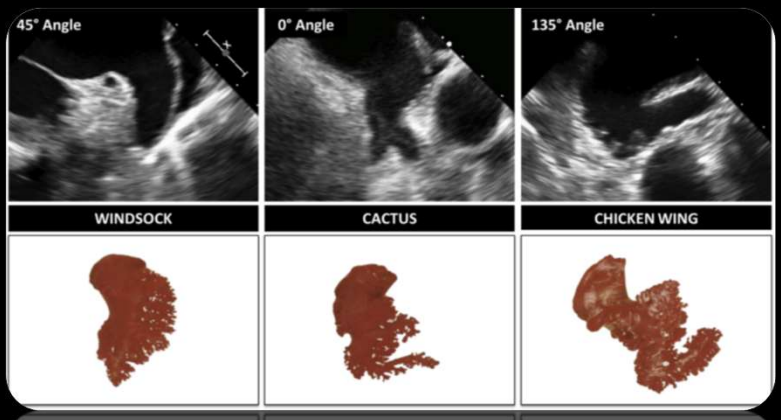

J Am Soc Echocardiogr 2018;31:454-74

Cleveland Clinic

C5Research

12

© Copyright. Society of Diagnostic Medical Sonography. All Rights Reserved.

LAA Anatomic Variants

Morphologic types of Left atrial appendage	Clinical Relevance
Windsock	• Prevalence 19% • It has long dominant lobe, and may have secondary or tertiary lobes arising from primary lobe
Chicken-Wing	• Most common. Prevalence 48% • It has a central lobe with a bend in the proximal/middle aspect of LAA and may also have secondary lobes. • Higher LAA flow velocities as compared to cactus and cauliflower subtypes.
Cauliflower or Broccoli	• Least common. Prevalence 3% • It has irregularly shaped ostium and complex internal characteristics with varying number of lobes. • The highest risk of thromboembolism independent of the CHA_2DS_2-VASc score.
Cactus	• Second most common. Prevalence 30% • It has dominant central lobe with secondary lobe extending from the main body in superior and inferior directions

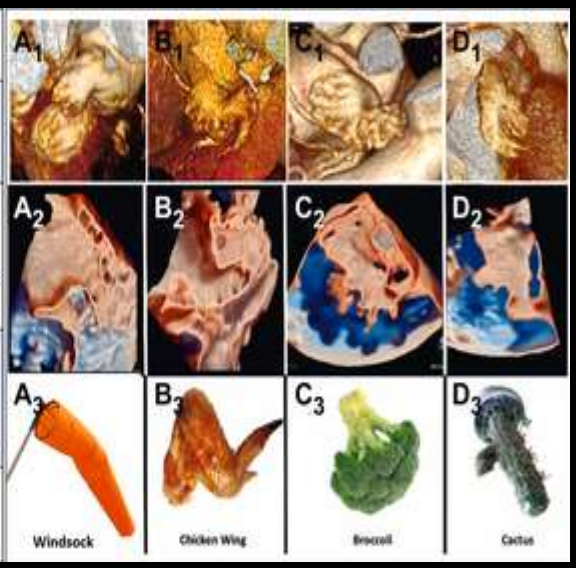

Cleveland Clinic Jalaj Garg et al. *J Am Coll* Jalaj Garg et al. *J Am Coll* 2025; 11:602-641. C5Research

13

Grading the Severity of SEC

Description	*Grade*
Absence of echogenicity	0
Mild (minimal echogenicity, only transiently detectable with optimal gain settings)	1+
Mild to moderate (transient spontaneous echo contrast without increased gain setting)	2+
Moderate (dense swirling pattern throughout the cardiac cycle)	3+
Severe (intense echo density and very slow swirling patterns in the LAA and LA body)	4+

Modified from Manish Bansal, Ravi Kasliwal; Indian heart journal 64 (2012) 469-475

Cleveland Clinic C5Research

14

© Copyright. Society of Diagnostic Medical Sonography. All Rights Reserved.

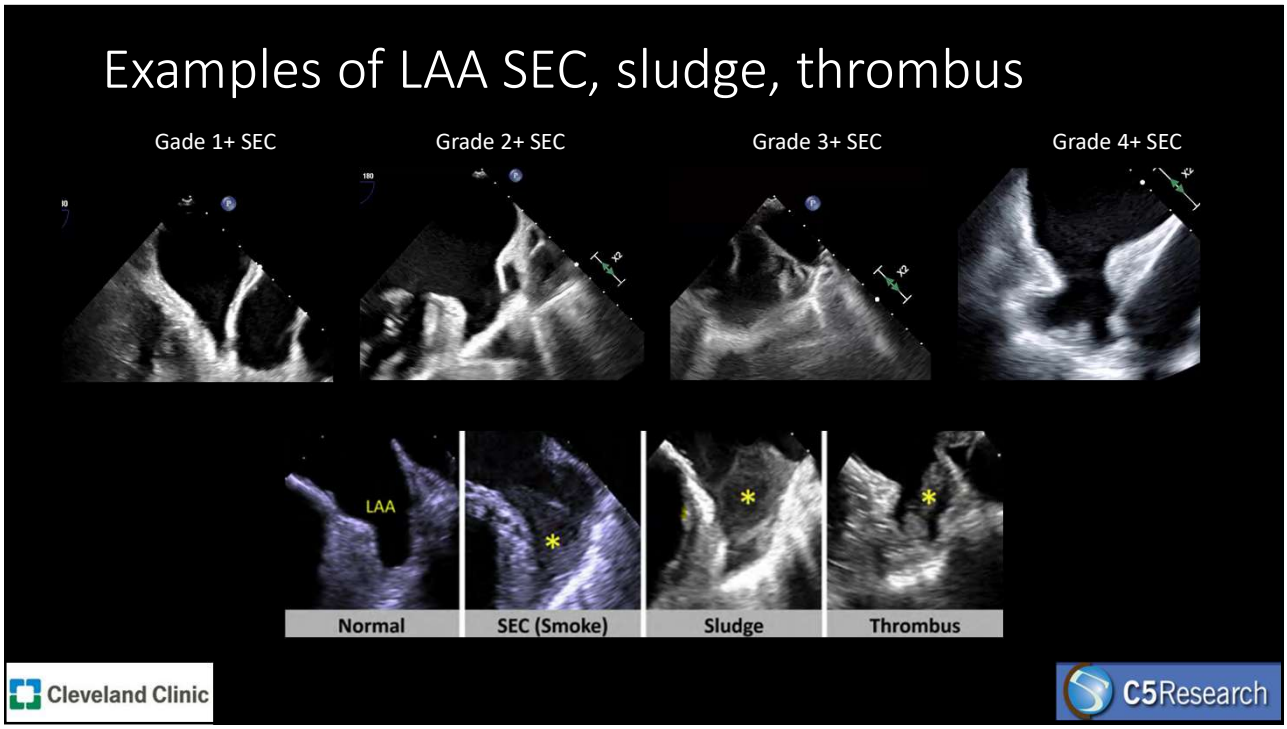

15

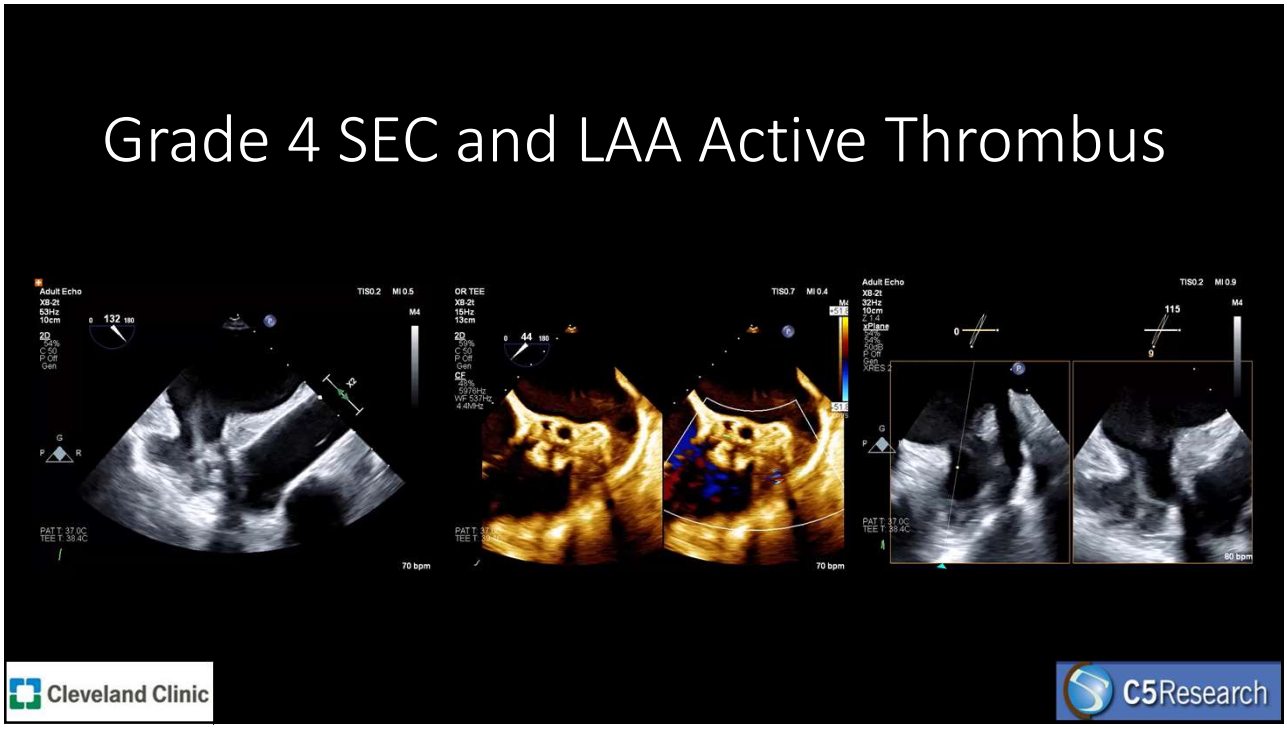

16

© Copyright. Society of Diagnostic Medical Sonography. All Rights Reserved.

TEE/RAO Caudal Fluoroscopic view

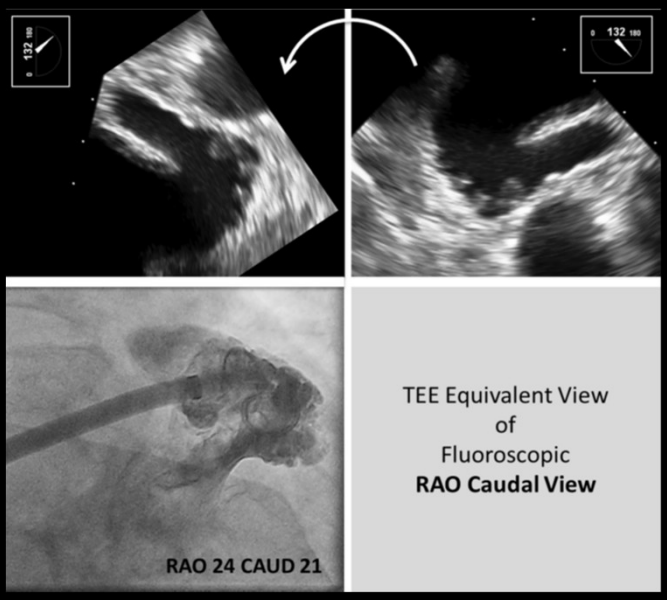

J Am Soc Echocardiogr 2018;31:454-74

Cleveland Clinic

C5Research

17

TEE/RAO Cranial Fluoroscopic view

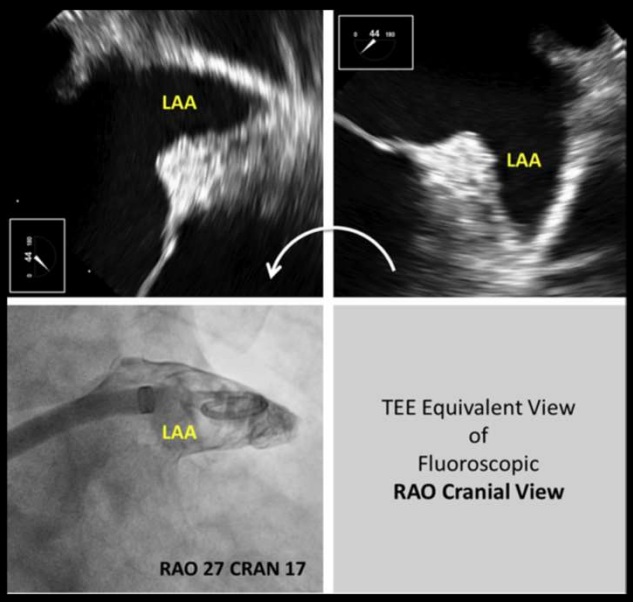

J Am Soc Echocardiogr 2018;31:454-74

Cleveland Clinic

C5Research

18

© Copyright. Society of Diagnostic Medical Sonography. All Rights Reserved.

Key points LAA

- Common source of cardiac thrombus formation
- Single or multilobed, shape and sizes vary
- Trabeculated comb like structure (pectinate muscles)
- SEC precedes thrombus formation
- TEE - multiple imaging planes to exclude thrombus
- PW Doppler preferred method for establishing LAA function
- Contrast can help define thrombus

19

Non valvular A-Fib Current Treatments

Systemic anticoagulation

Surgical LAA exclusion

Percutaneous devices for LAA exclusion





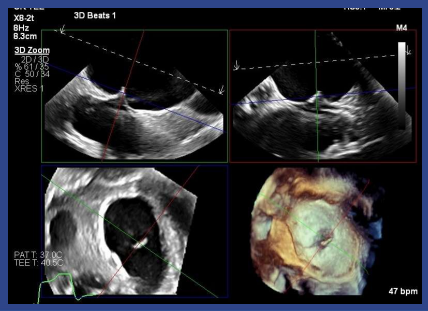

Cleveland Clinic

C5Research

20

© Copyright. Society of Diagnostic Medical Sonography. All Rights Reserved.

Types of Closure Devices

- Devices that block the left atrial appendage's opening: WATCHMAN™, Amulet™, WaveCrest™
- Devices that clamp the base of the LAA to close it off: AtriClip™ (disclosure: Cleveland Clinic proprietary)
- Devices that use a band or suture loop to close off your LAA: Lariat™ and Sierra™

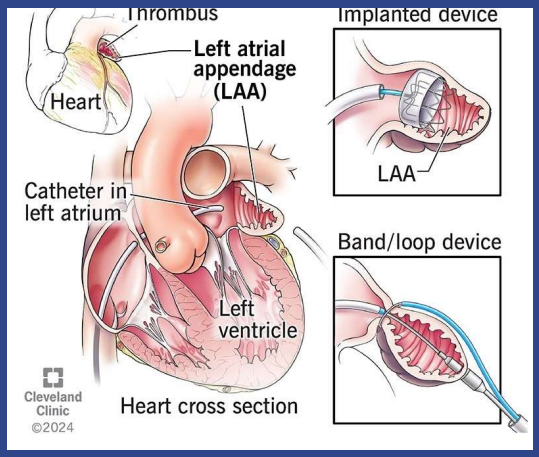

Cleveland Clinic

Image modified form :https://my.clevelandclinic.org/health/treatments/17167-left-atrial-appendage--closure

C5Research

21

LAA Closure Devices





Amplatzer Amulet



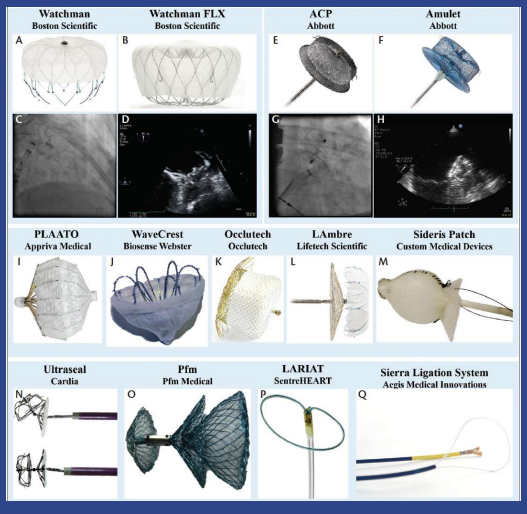



Watchman

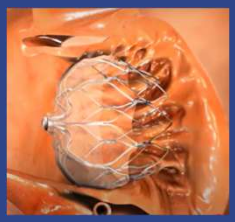

Cleveland Clinic

C5Research

22

© Copyright. Society of Diagnostic Medical Sonography. All Rights Reserved.

Indications for Percutaneous LAAO US

Indicated to reduce risk of thromboembolism (LAA)in patients with NVAF who:

- ✓Are at increased risk for stroke and systemic embolization
- ✓Are deemed suitable for at least short-term antithrombotic therapy post-LAAO
- ✓Require a nonpharmacologic alternative to oral anticoagulant
- ✓No other indication for OAC than AF (e.g., prior VTE, mechanical valve, presence or predisposition to left atrial or left ventricular thrombus.
- ✓Anatomy appropriate for LAAO

Cleveland Clinic C5Research

23

Contraindications to LAAO

X Inability to take short-term OAC or antiplatelet therapy post-LAAO.

Presence of another indication for OAC than AF. Examples:

- Prior VTE
- Mechanical valve
- Hypercoagulable state
- Presence or predisposition to LA or LV thrombus

X Anatomy inappropriate for LAAO based on CT or TEE imaging.

X Prior surgical excision or clipping of LAA.

X Valvular AF (i.e., rheumatic heart disease)*

Cleveland Clinic C5Research

24

© Copyright. Society of Diagnostic Medical Sonography. All Rights Reserved.

Watchman Device

	Key Design Features	LAA Anatomy Treated
WATCHMAN 2.5 	Only partially recapturable 10 strut frames Anchors in single row Sharp tip on advancement Open tip on deployment	16.8 - 30.5 mm
WATCHMAN-FLX PRO 	Fully recapturable 18 strut frames 2 rows of anchors (9 each row) FLX ball – soft tip when advancing Closed tip on deployment Fabric covers more of device	14.0 – 36 mm Easier to maneuver for difficult anatomies

Cleveland Clinic

C5Research

25

Watchman FLX Device

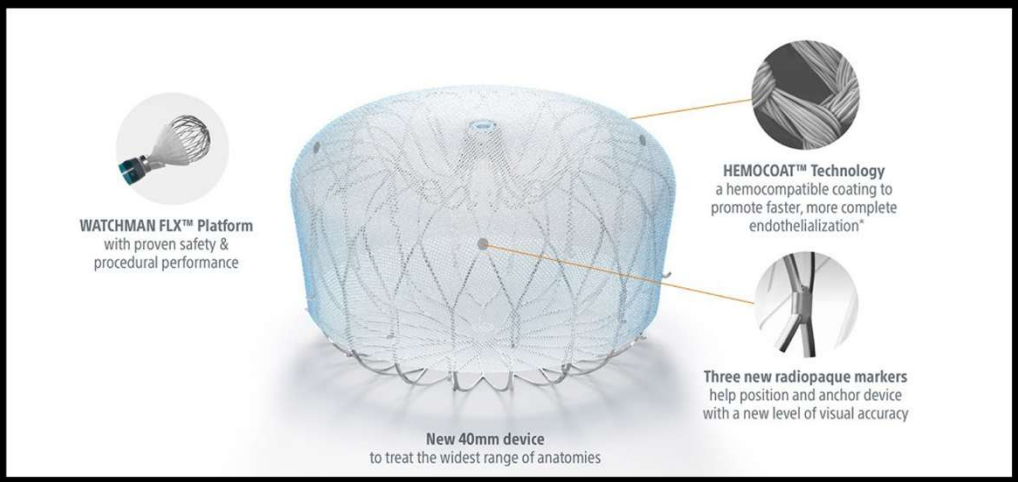

Cleveland Clinic

C5Research

26

© Copyright. Society of Diagnostic Medical Sonography. All Rights Reserved.

Device Sizing

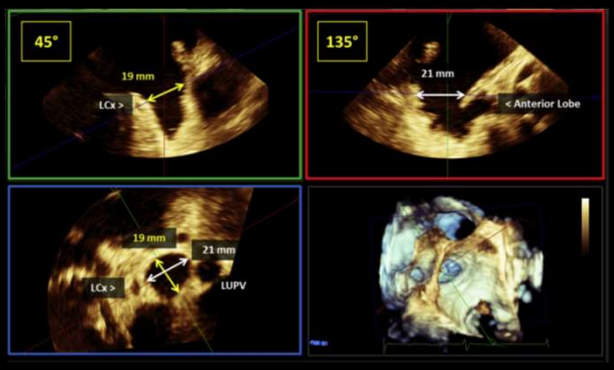

WATCHMAN DEVICE SIZES					
Device Diameter (mm)	21	24	27	30	33
Max LAA Orifice Range (mm)	17-19	20-22	23-25	26-28	29-31
Compressed Diameter (mm)	16.8-19.3	19.2-22.1	21.6-24.8	24-27.6	26.4-30.4

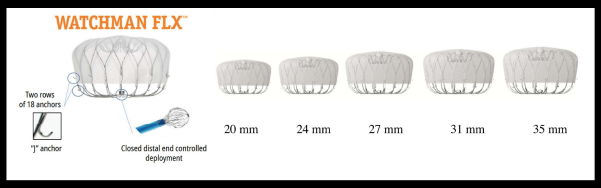

Cleveland Clinic

C5Research

27

Baseline Implantation Observations

- LV and LA function
- Amount of Spontaneous Echo Contrast (SEC)
- LA/LAA free of thrombus /clot
- LAA morphology (lobes, trabeculations, shape)
- LAA sizing (depth and width)
- Valvular disease presence
- Pericardial Effusion (size/location)

Cleveland Clinic

C5Research

28

© Copyright. Society of Diagnostic Medical Sonography. All Rights Reserved.

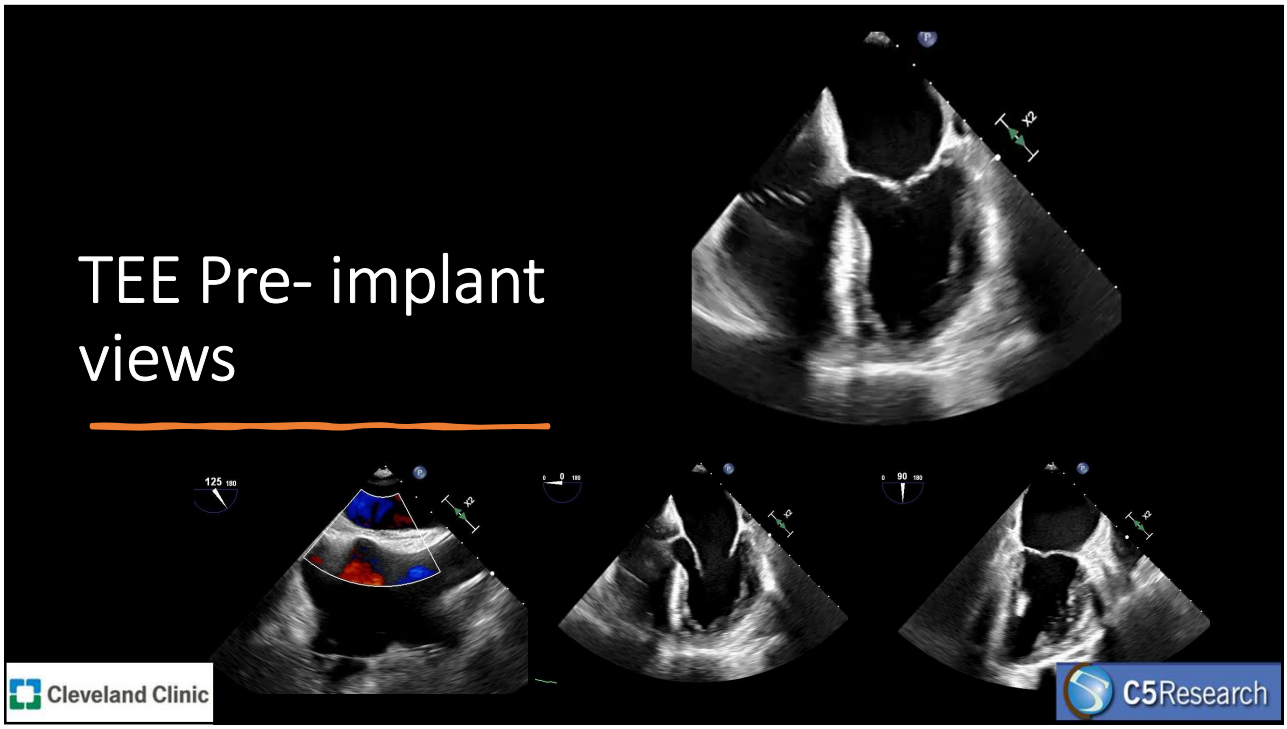

29

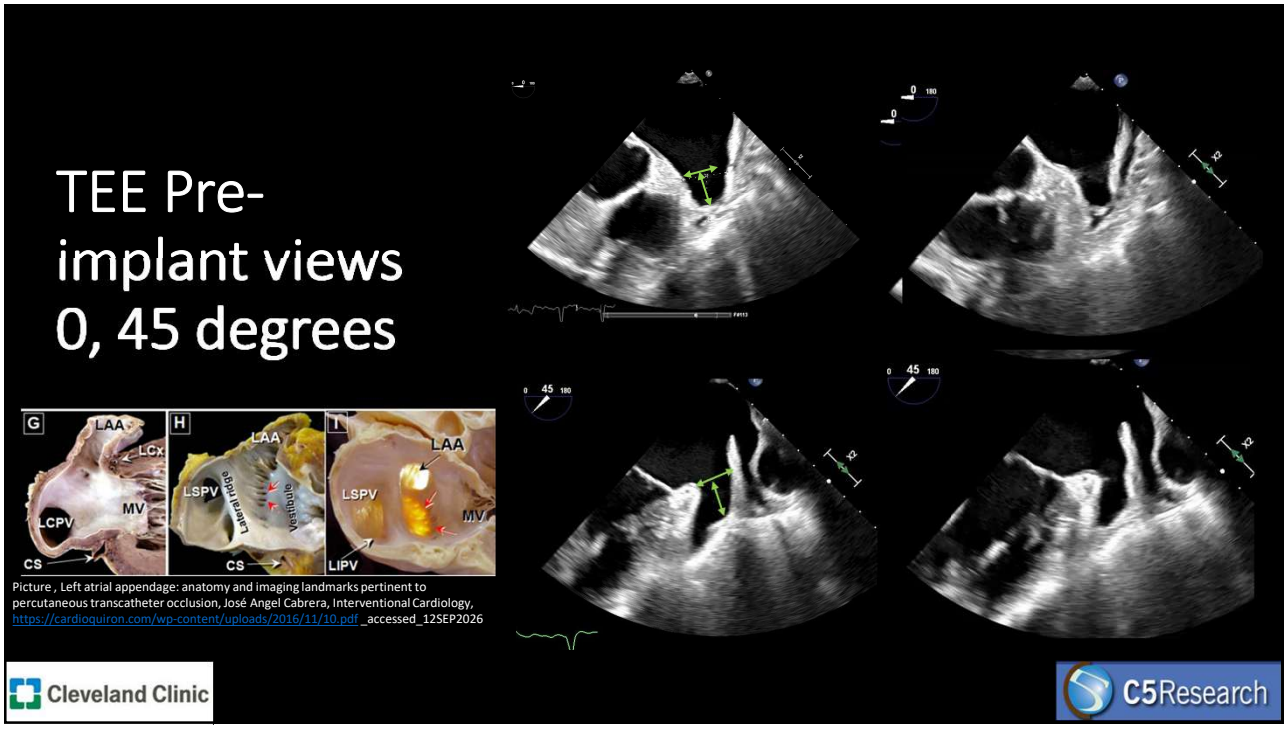

30

© Copyright. Society of Diagnostic Medical Sonography. All Rights Reserved.

TEE Pre-implant views 90, 135 degrees

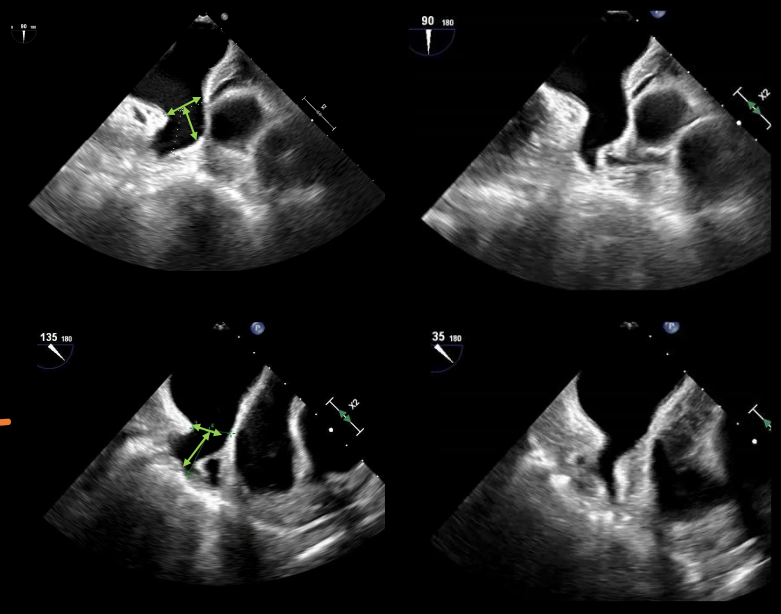

Cleveland Clinic

C5Research

31

LAA Terminology

Degree	Left of Sector	Right of sector
0	Anterior	Posterior
45	Anterior	Posterior
90	Inferior (mitral side)	Superior (limbus)
135	Posterior	Anterior

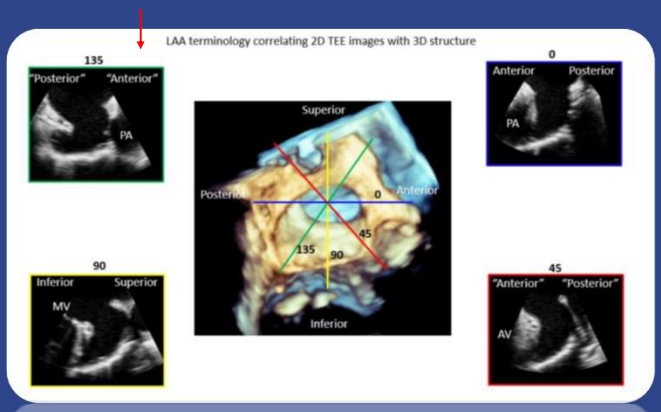

Cleveland Clinic

C5Research

32

© Copyright. Society of Diagnostic Medical Sonography. All Rights Reserved.

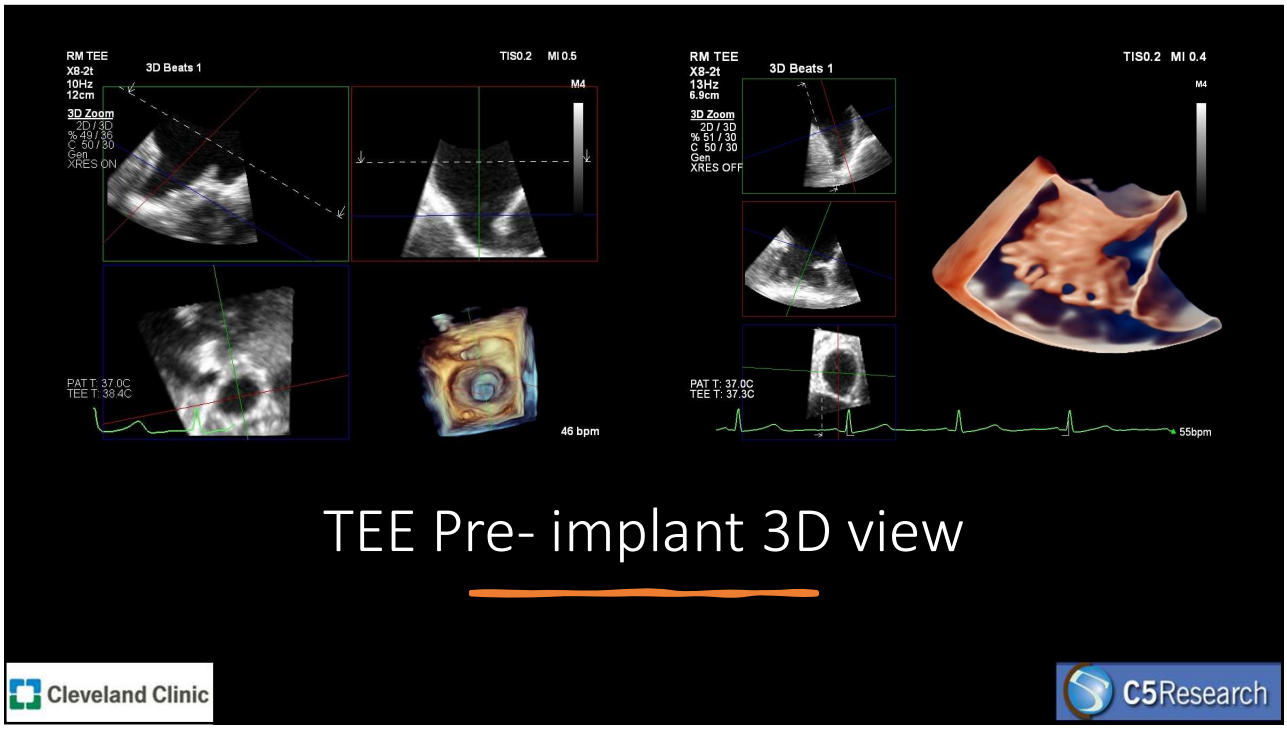

33

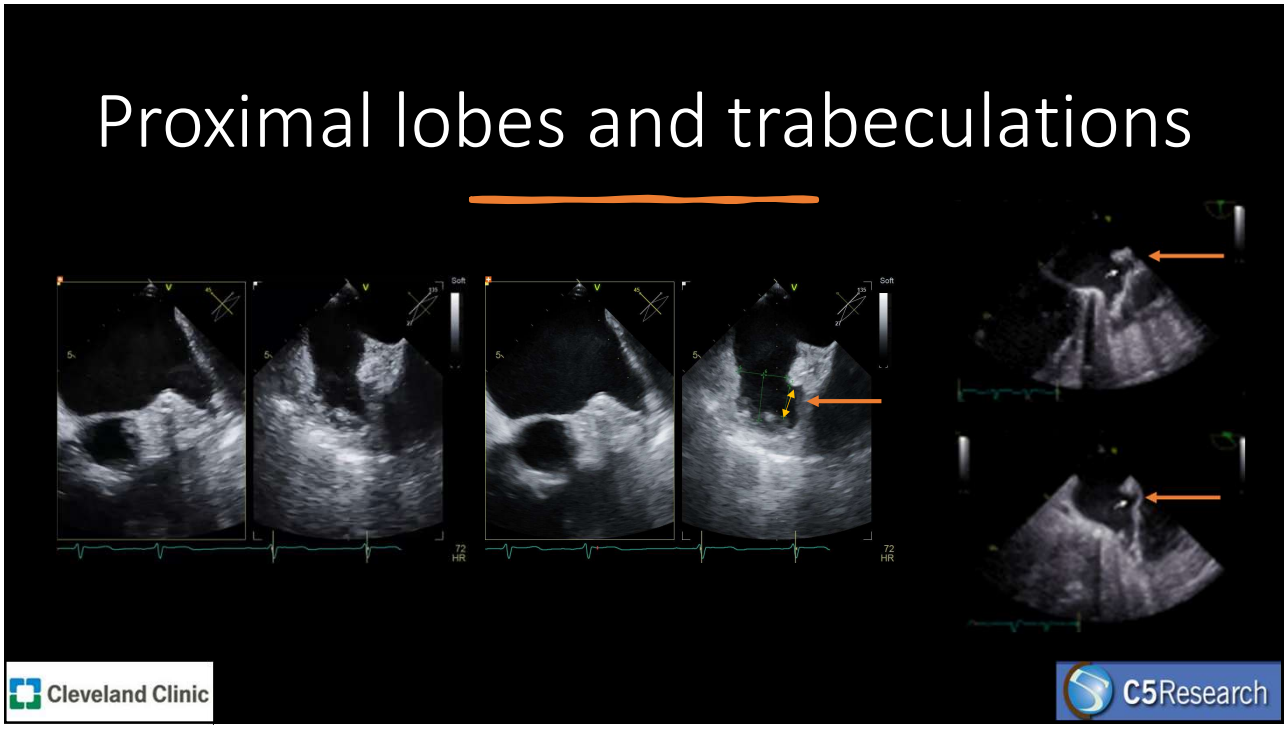

34

© Copyright. Society of Diagnostic Medical Sonography. All Rights Reserved.

ICE Imaging LAAO

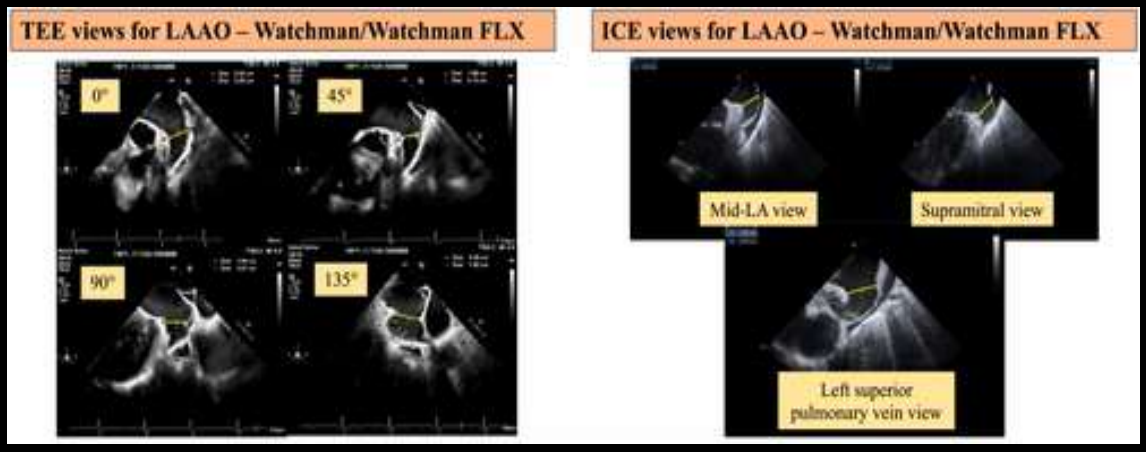

Cleveland Clinic

Jalaj Garg et al. *J Am Coll Cardiol EP* 2025; 11:602-641.

C5Research

35

IntraCardiac Echo (ICE)

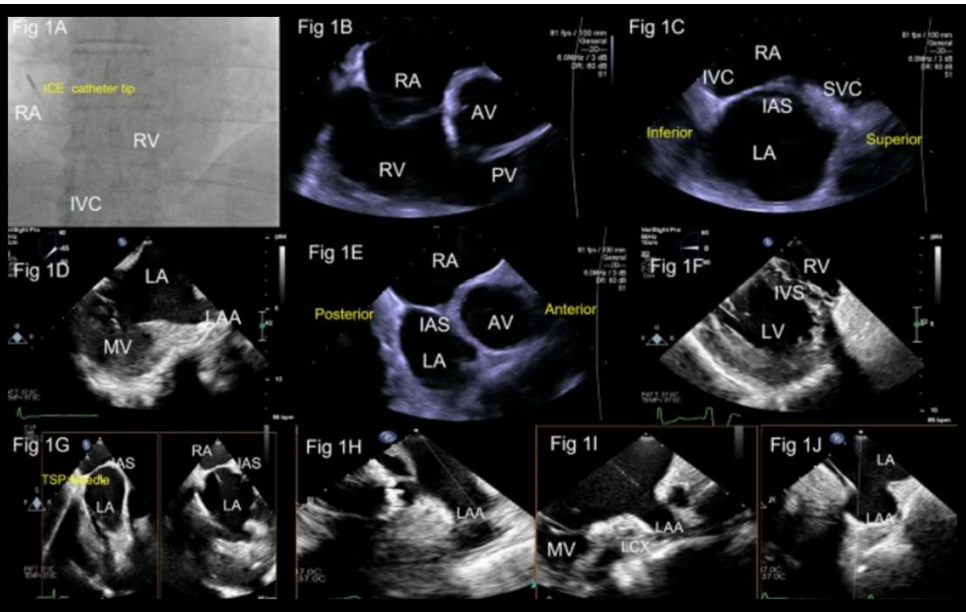

Jhand, A., Goldsweig, A.M. The Emerging Role of Intracardiac Echocardiography (ICE) in Left Atrial Appendage Closure (LAAC). *Curr Cardiol Rep* **25**, 1223–1232 (2023). https://doi.org/10.1007/s11886-023-01940-4

Cleveland Clinic

C5Research

36

© Copyright. Society of Diagnostic Medical Sonography. All Rights Reserved.

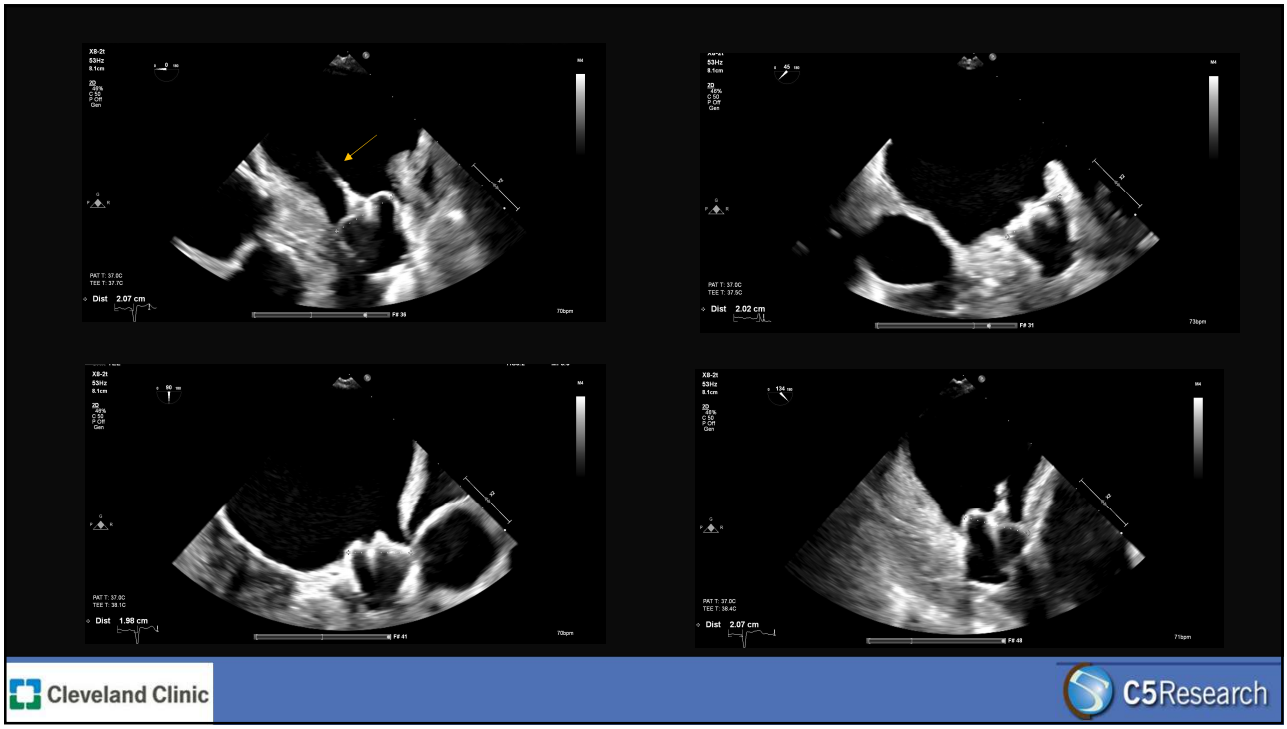

37

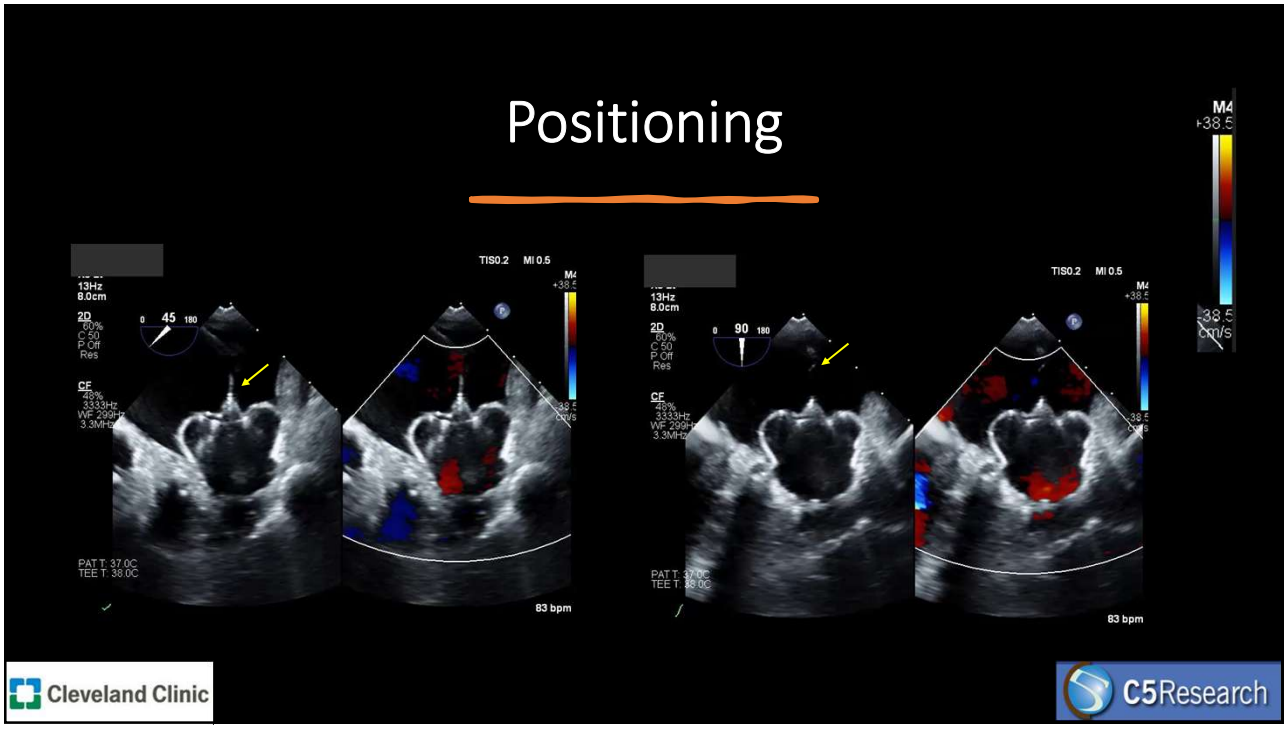

38

© Copyright. Society of Diagnostic Medical Sonography. All Rights Reserved.

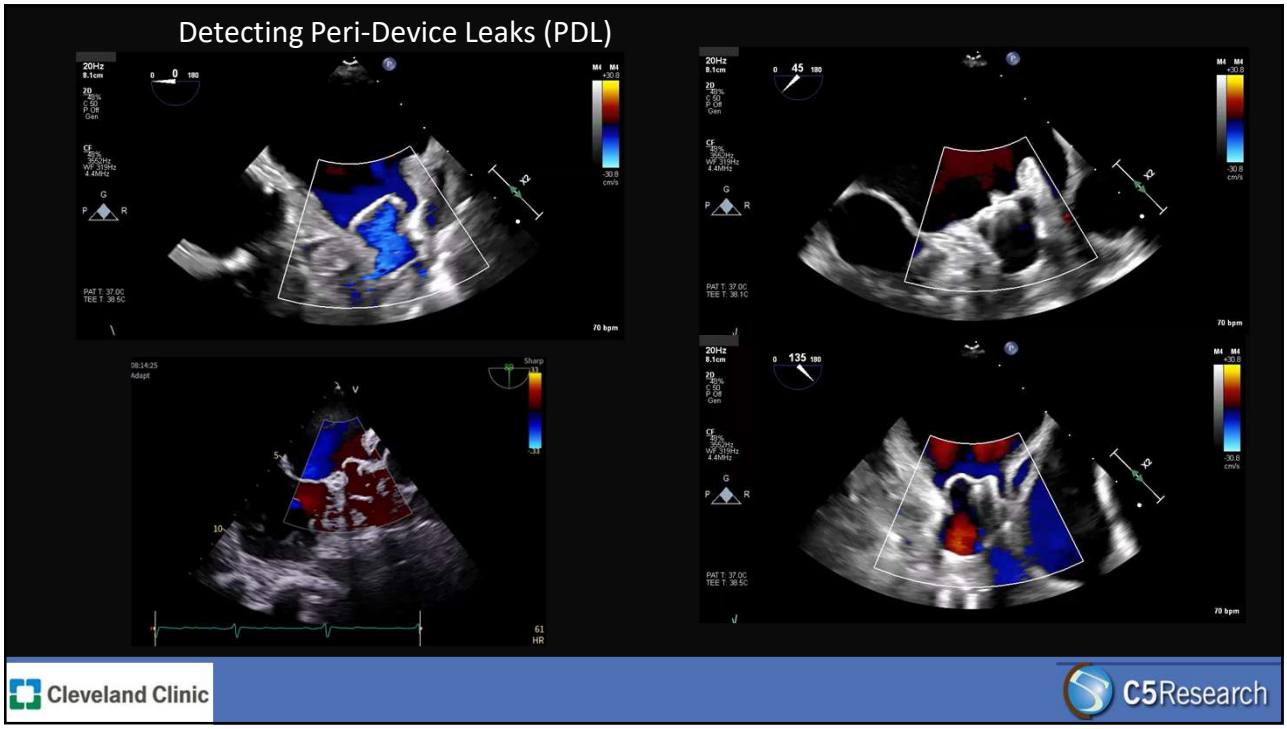

39

Device Measurements & Observations

- Device Size
- Position / Tilt
- Implant Shoulder
- Uncovered Proximal Lobe
- Uncovered Tissue
- Peri-device Leaks
- Device Related Thrombus (DRT)
- Position shift from previous

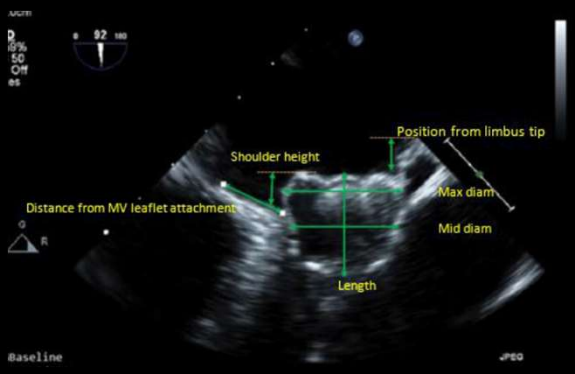

Cleveland Clinic
C5Research

40

© Copyright. Society of Diagnostic Medical Sonography. All Rights Reserved.

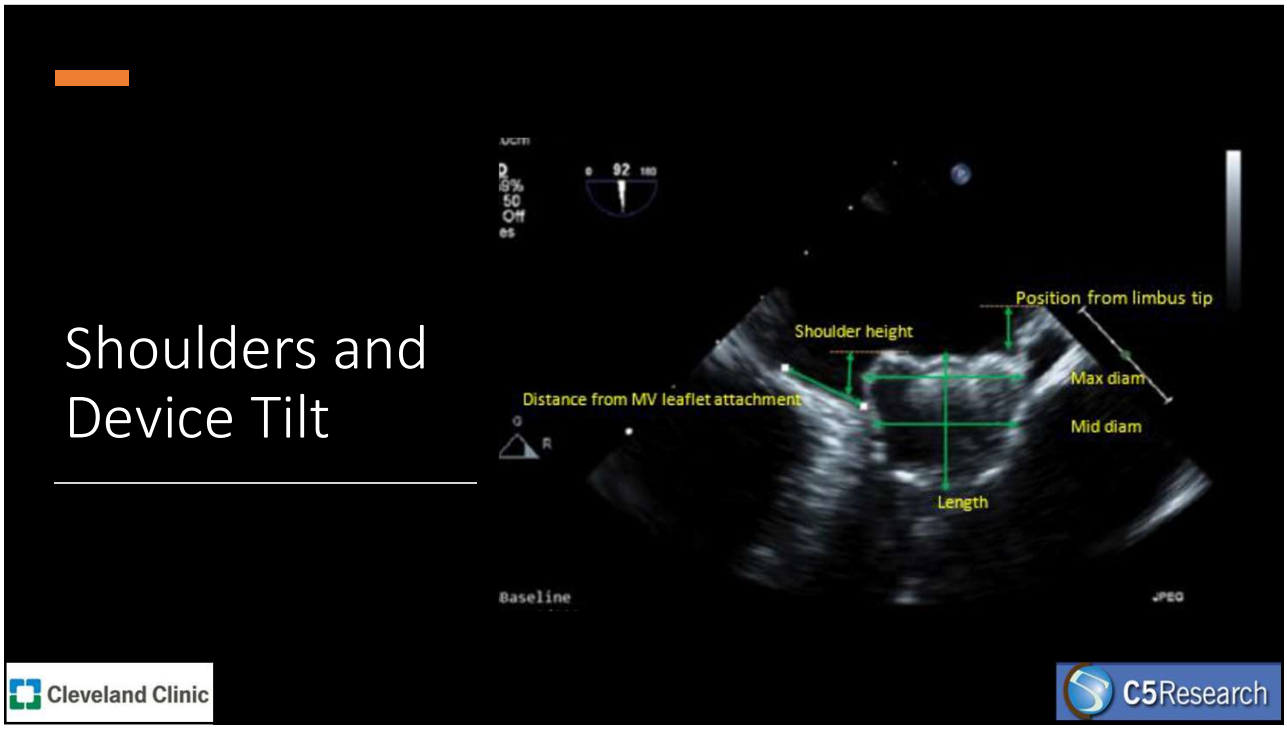

41

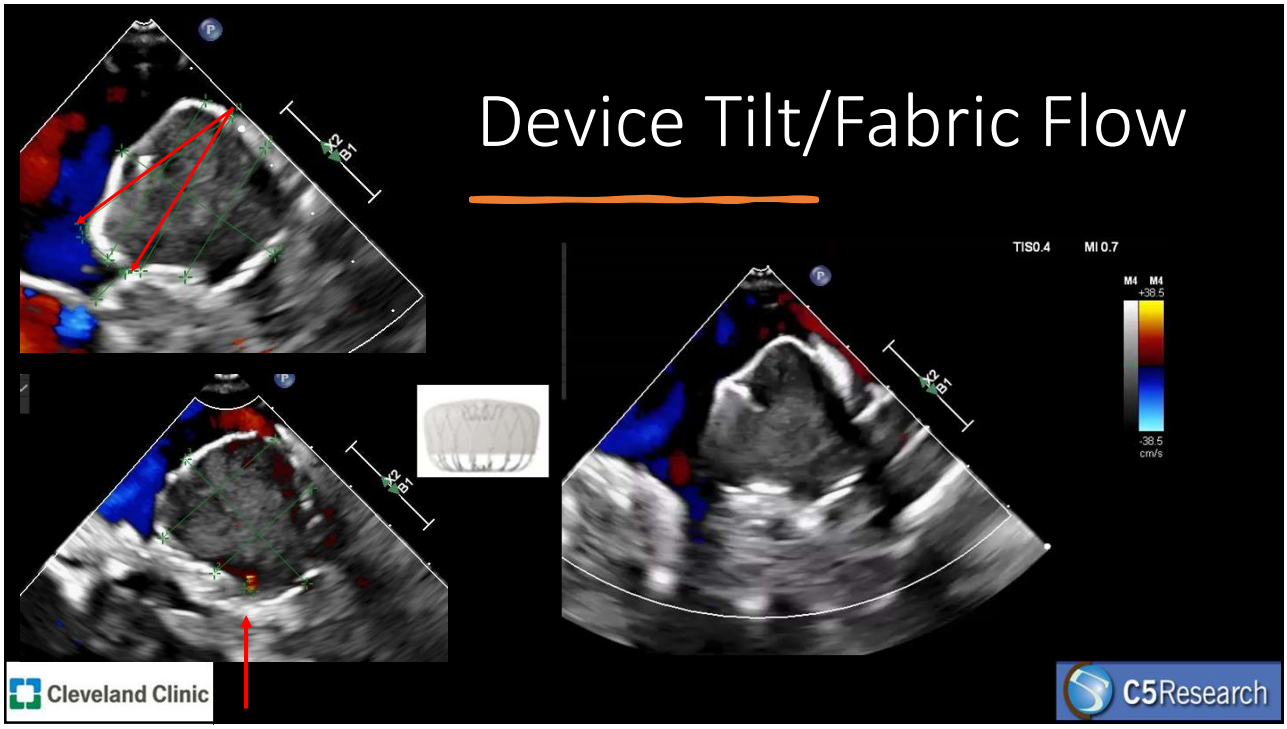

42

© Copyright. Society of Diagnostic Medical Sonography. All Rights Reserved.

2026 SDMS Annual Conference

Device Shift

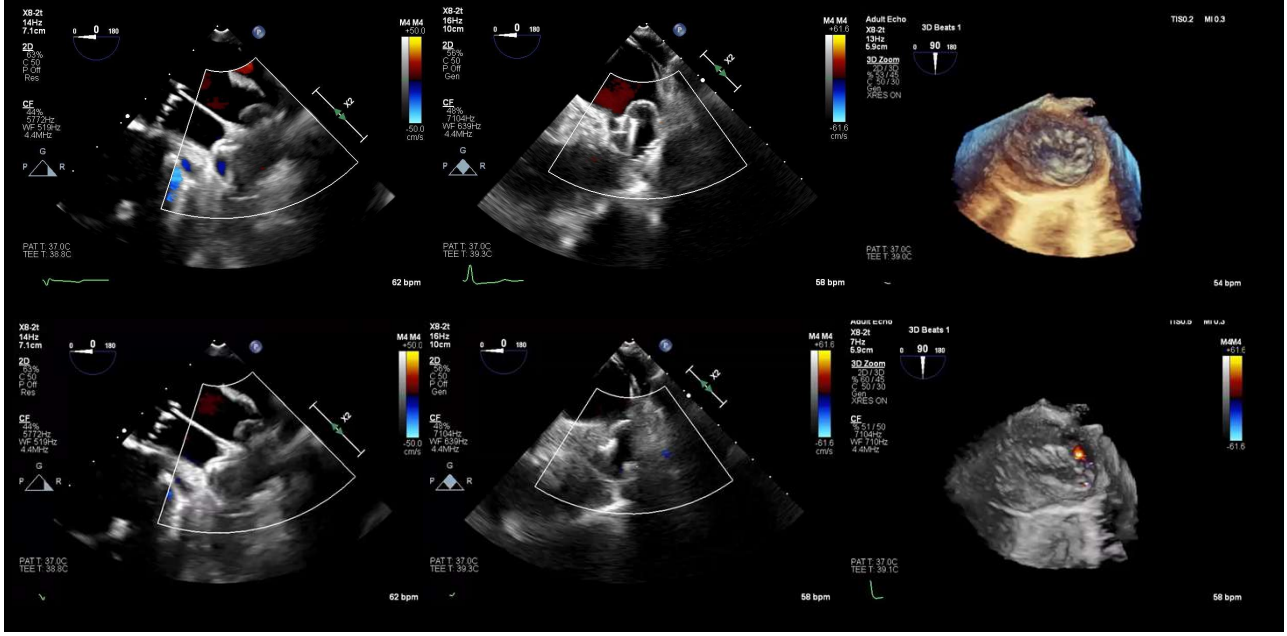

43

Peri –Device Leaks

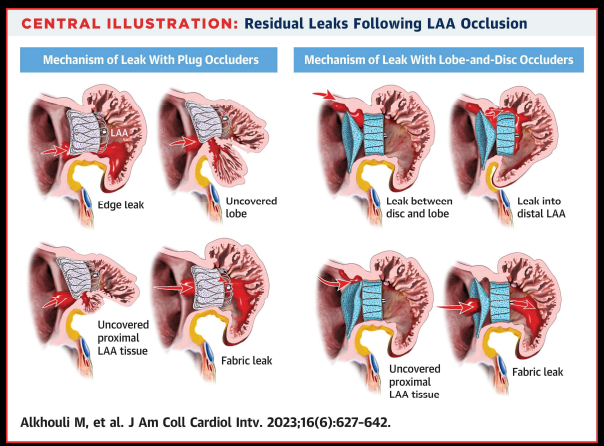

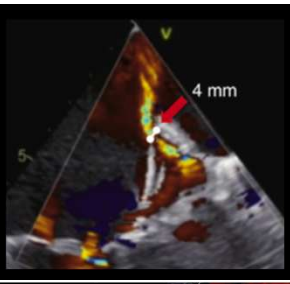

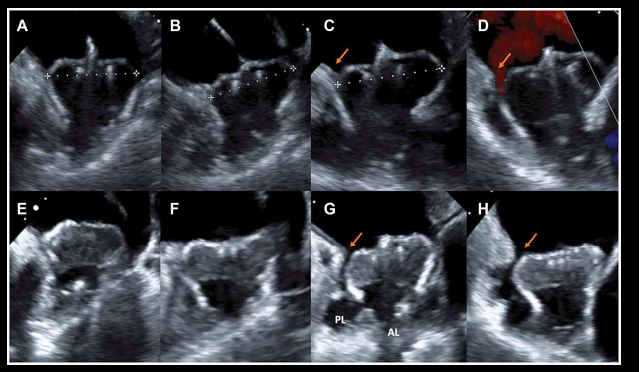

J Am Coll Cardiol Intv. 2023 Mar, 16 (6) 627–642

44

© Copyright. Society of Diagnostic Medical Sonography. All Rights Reserved.

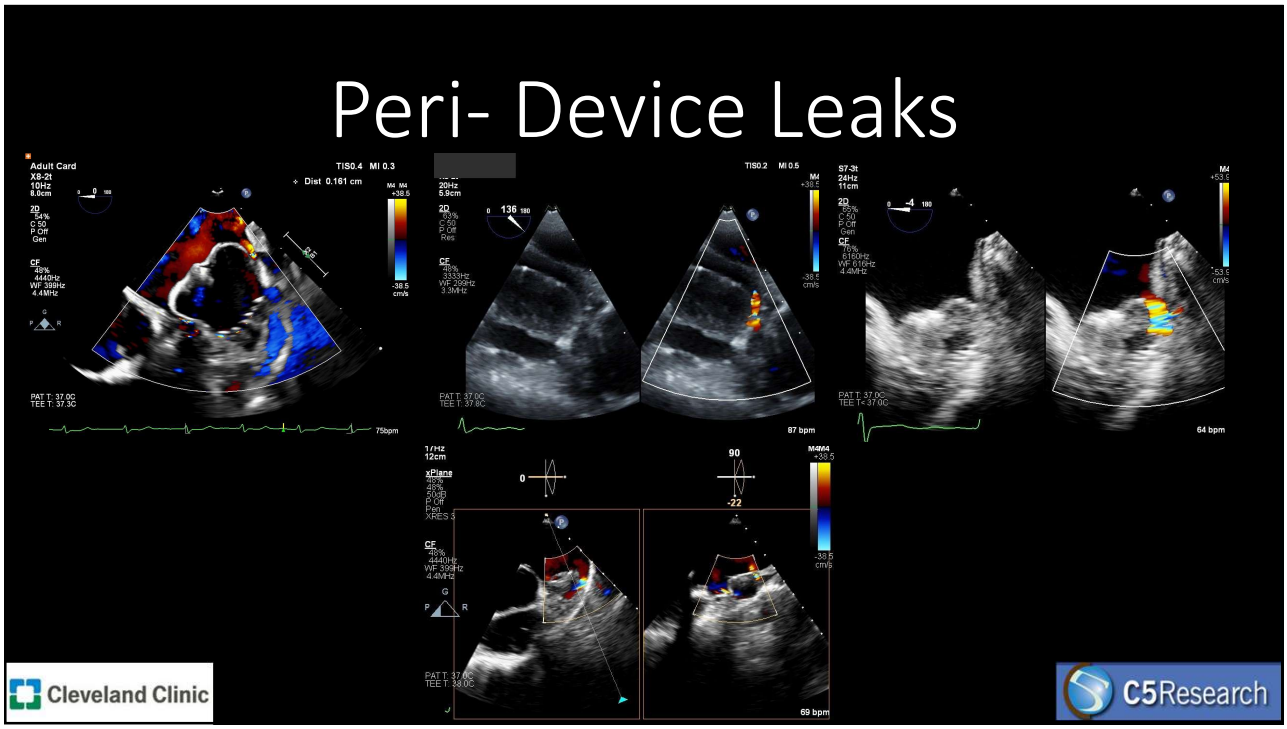

45

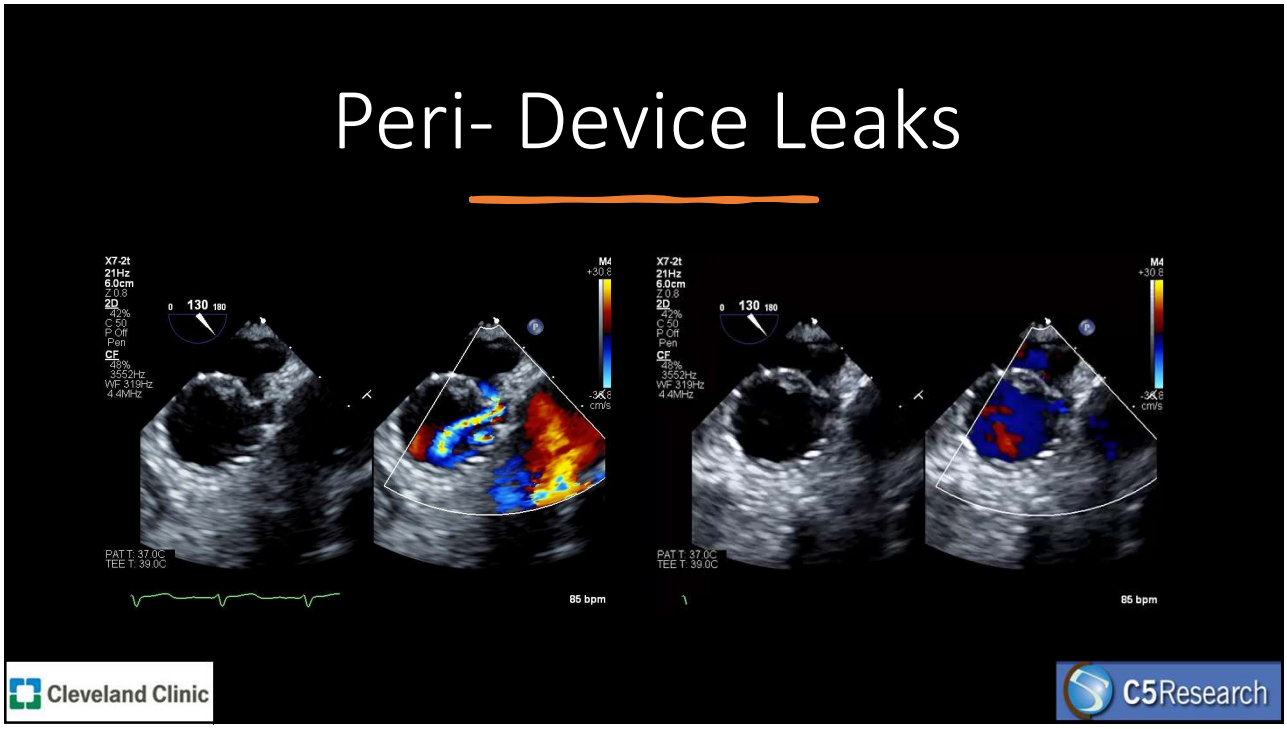

46

© Copyright. Society of Diagnostic Medical Sonography. All Rights Reserved.

PDL through device face

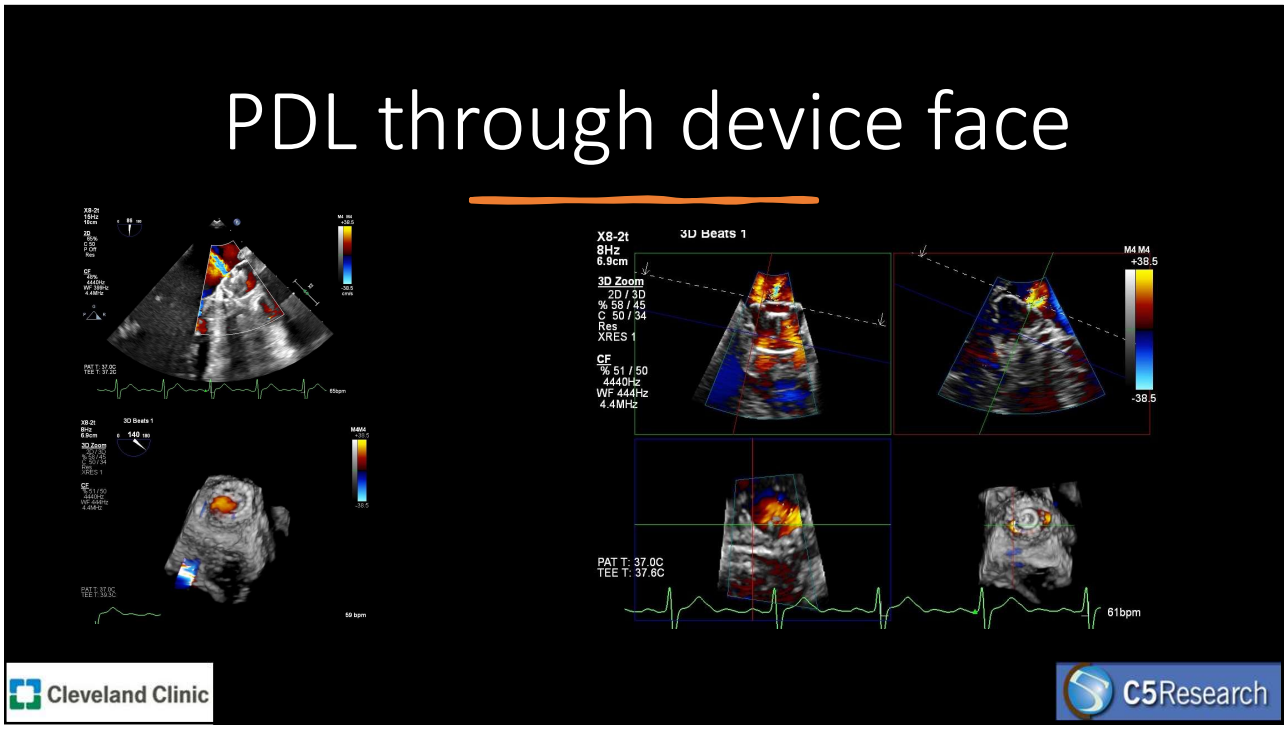

47

Probable Fabric Flow/ Fabric Edge Leak

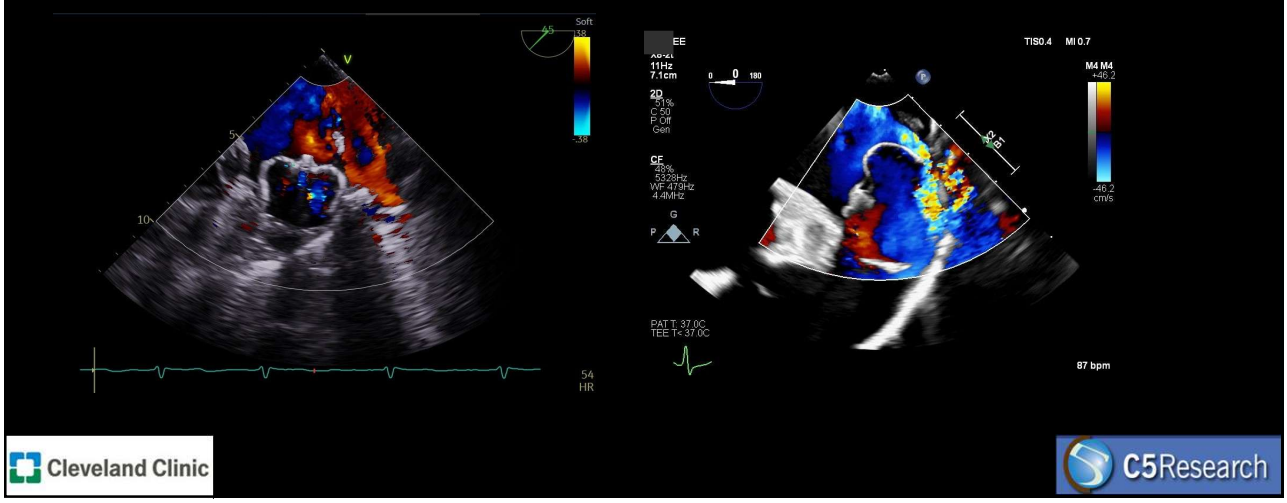

48

© Copyright. Society of Diagnostic Medical Sonography. All Rights Reserved.

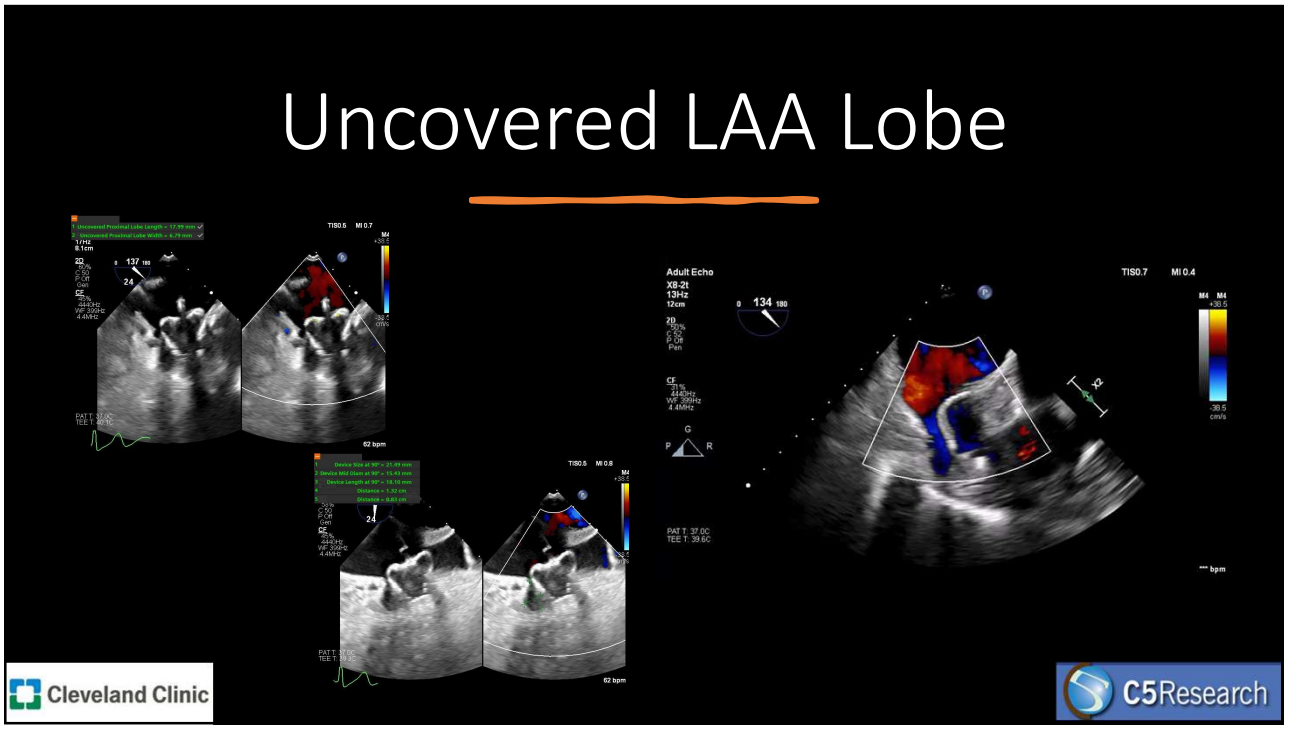

49

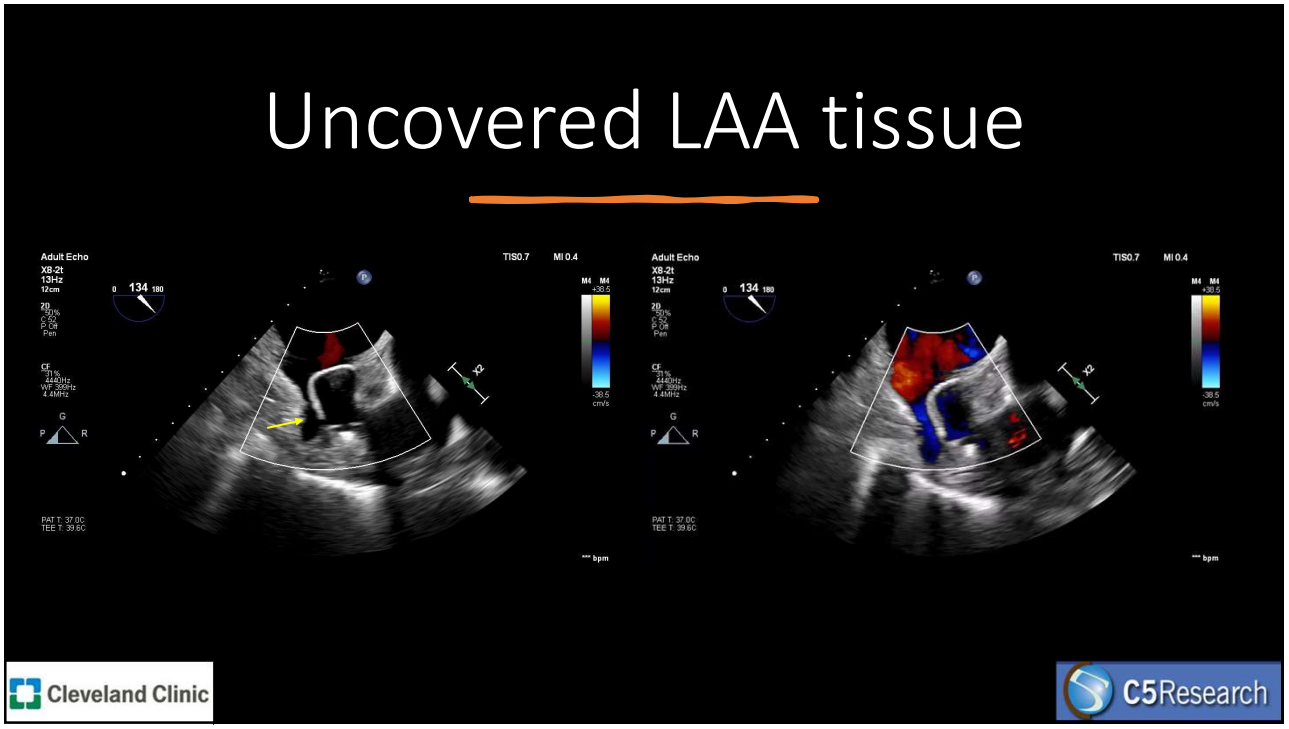

50

© Copyright. Society of Diagnostic Medical Sonography. All Rights Reserved.

Uncovered lobe / tissue

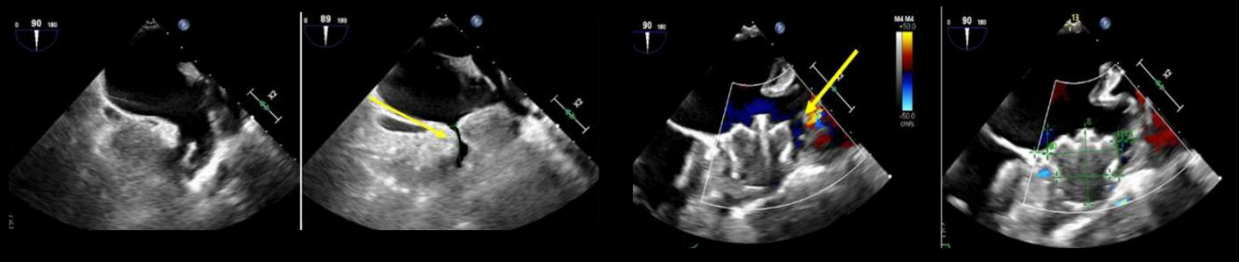

Cleveland Clinic

C5Research

51

Device Related Thrombus (DRT)

Grade 0 = isolated sub fabric hypoattenuating thickening (HAT)
Grade 1 = device surface with thickness ≤3 mm or above 3 mm but with a smooth surface and continuity of the left atrial wall
Grade 2 = thickness above 3 mm and irregular surface and/or without LA wall continuity
Grade 3 =pedunculated HAT of any size

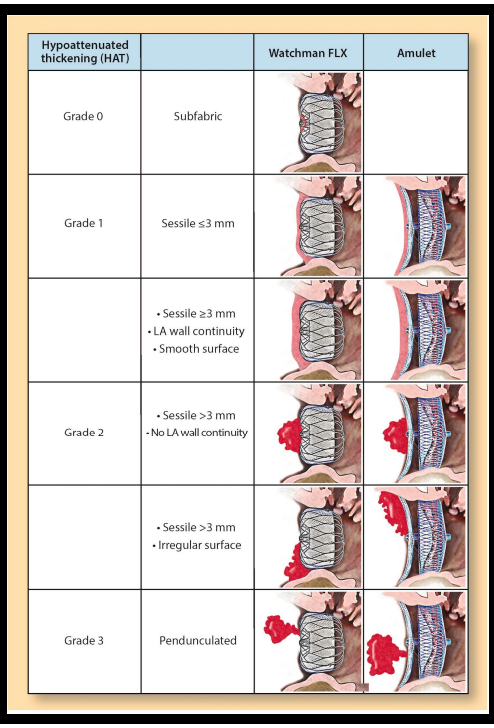

Cleveland Clinic

52

© Copyright. Society of Diagnostic Medical Sonography. All Rights Reserved.

Risk Factors

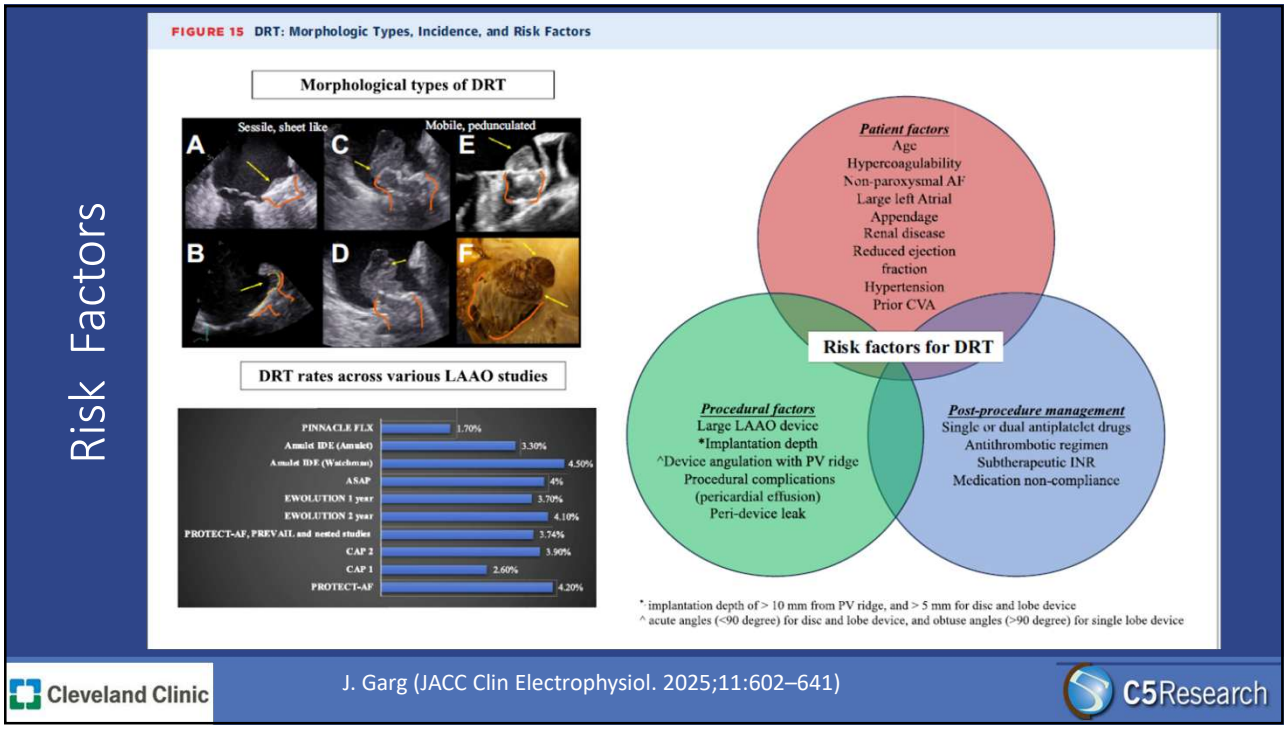

Cleveland Clinic

J. Garg (JACC Clin Electrophysiol. 2025;11:602–641)

C5Research

53

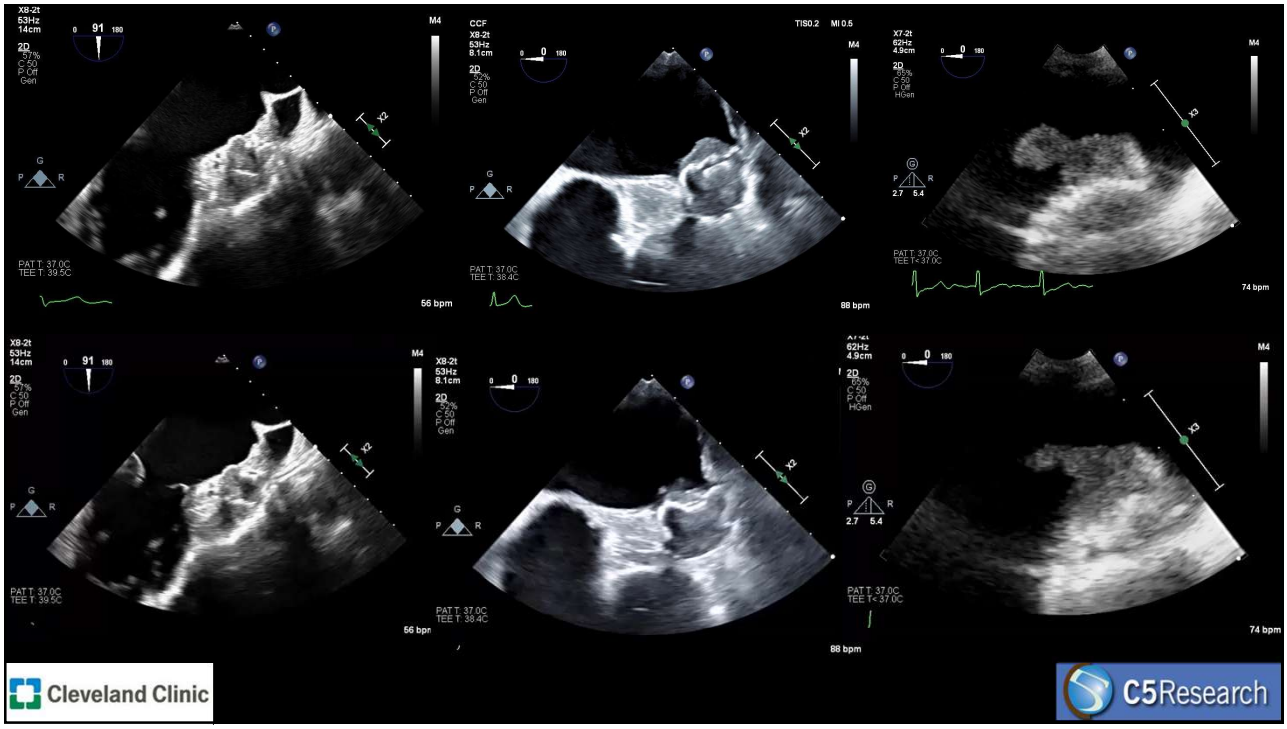

54

© Copyright. Society of Diagnostic Medical Sonography. All Rights Reserved.

Pedunculated (Grade 3)

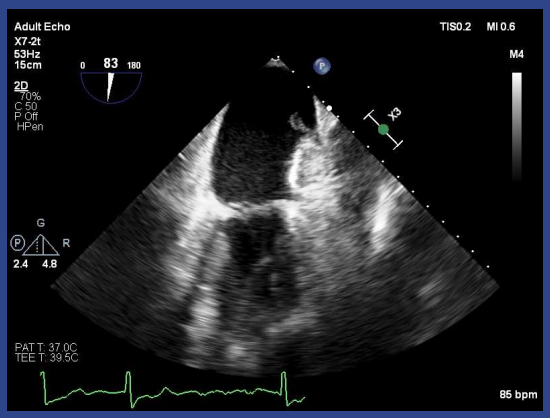

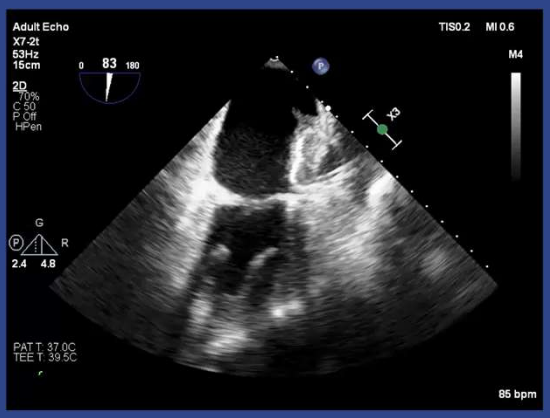

Cleveland Clinic

55

Cardiac Computed Tomography (CCT)

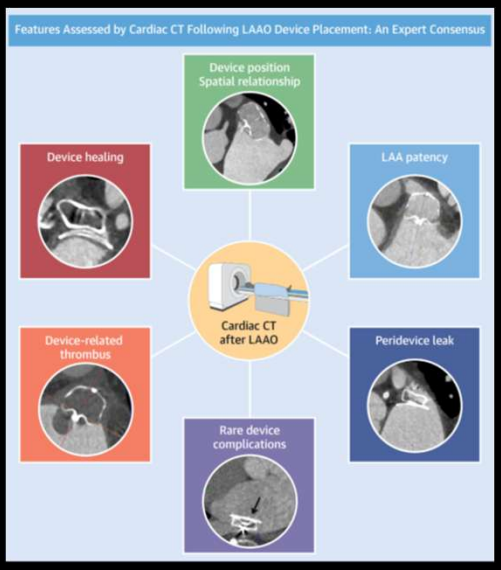



Cleveland Clinic

Korsholm K, et al. JACC Cardiovasc Interv. 2024;17(15):1747–1764.

C5Research

56

© Copyright. Society of Diagnostic Medical Sonography. All Rights Reserved.

LLA reconstruction from CT MPR Images

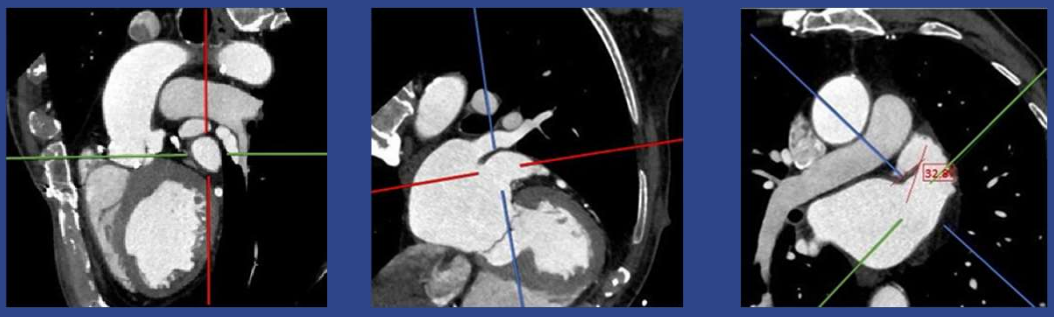

Cleveland Clinic C5Research

57

- **Device max diameter (mm)** measure at the device shoulders, outer edge to outer edge
- **Device mid diameter (mm)** measure where the shoulder tapers in to meet the device body, outer edge to outer edge
- **Device Length (mm**) measure from the center hub to distal hub, outer edge to outer edge
- **Device max and min diameter in cross section (mm)** at the level of max device width
- **Distance to limbus tip (mm)** – rotate cross-section image to open the LUPV and limbus, measure distance from device face to limbus tip
- **Distance to MV attachment (mm)-** rotate cross-section image to open the full extent of the MV annulus, measure from device edge to MV leaflet attachment
- **Max Shoulder Height (mm)** – distance from tissue apposition to the device face
- **Location of the MAX shoulder – once the max shoulder is identified, identify the clock position location of the shoulder in SAX, AO should be aligned in the 3 o'clock position

Cleveland Clinic

58

© Copyright. Society of Diagnostic Medical Sonography. All Rights Reserved.

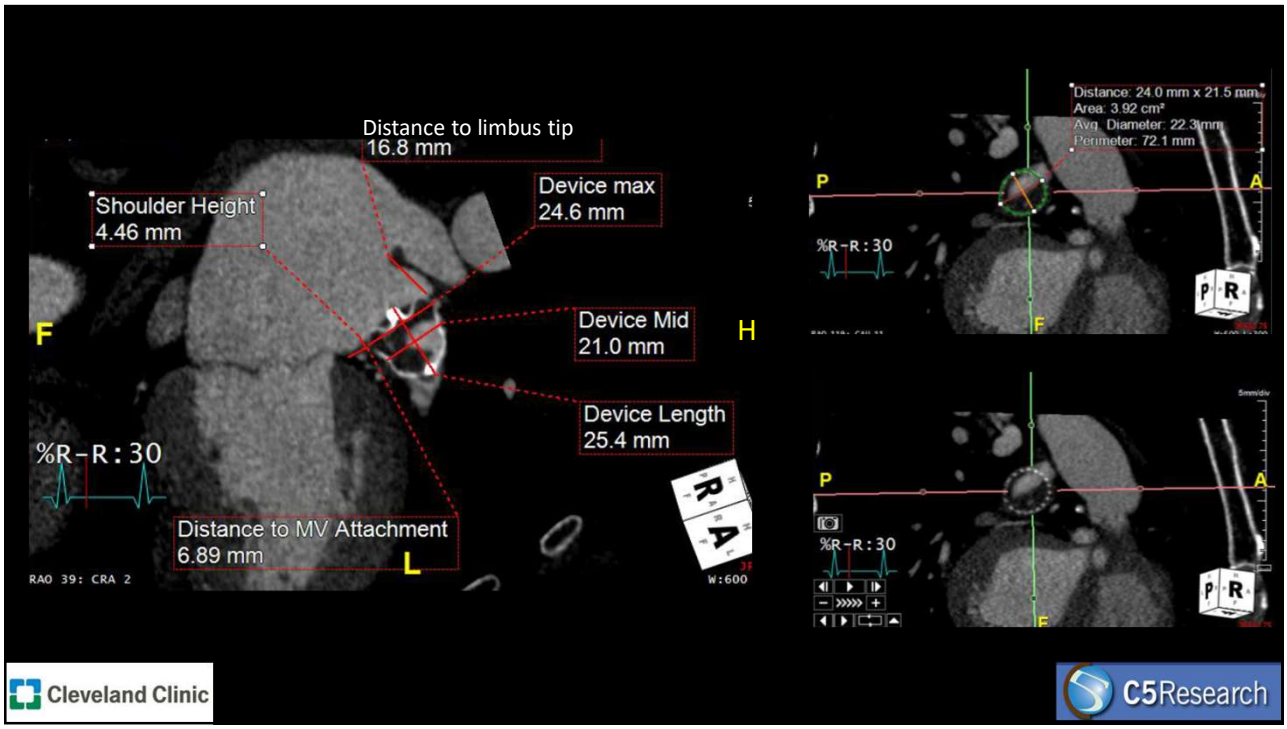

59

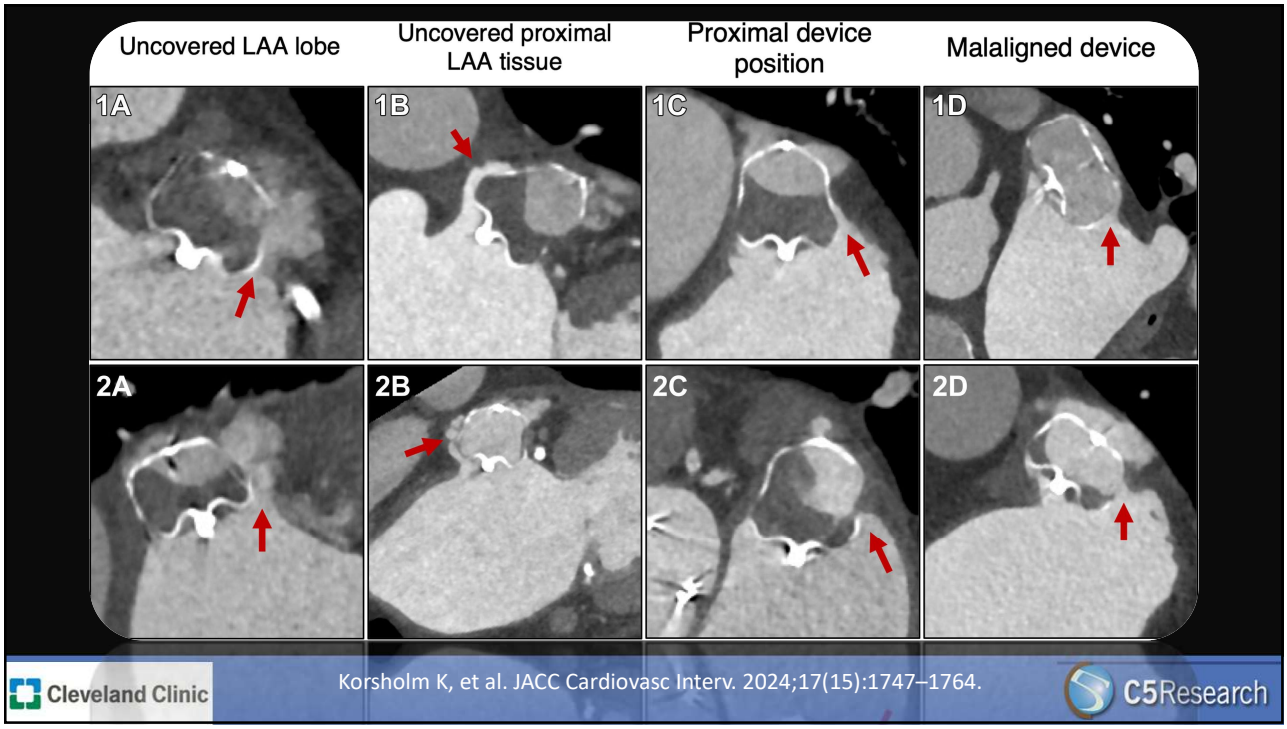

60

© Copyright. Society of Diagnostic Medical Sonography. All Rights Reserved.

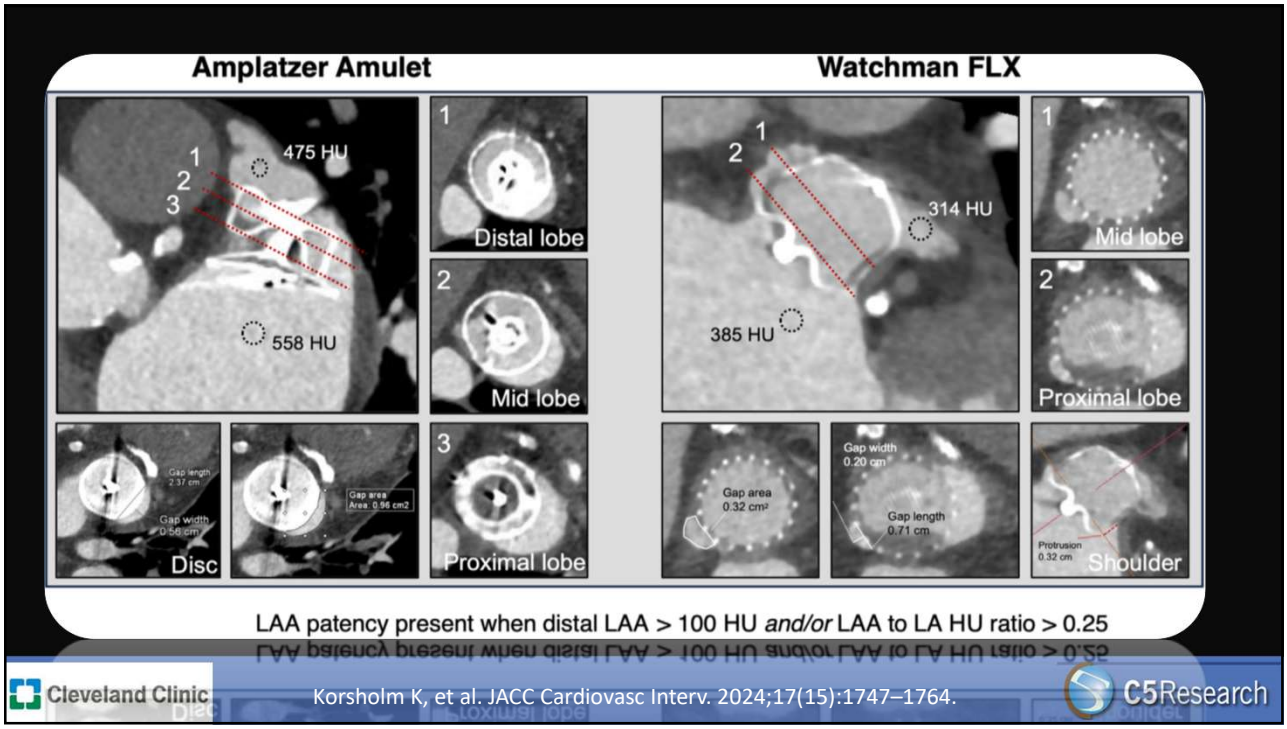

61

CT Classification of Hypoattenuated Thickening (HAT)

Grade 0 HAT (sub-fabric hypoattenuation (1A-!D)

Grade 1 HAT (flat sessile HAT with smooth surface and left atrial wall continuity (2A-2D)

Grade 2 HAT (protruding sessile HAT) identified by the yellow arrows (3A-AD)

Grade 3 HAT (pedunculated HAT) identified by a thick red line

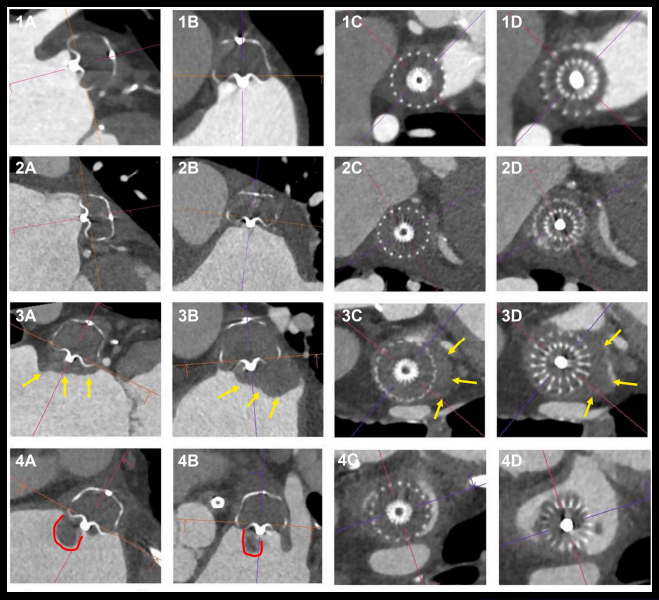

Cleveland Clinic

JACC: CARDIOVASCULAR INTERVENTIONS VOL. 16, NO. 22, 2023
DRT After LAAO NO V EMB E R 27, 2023: 2695–2707, Alkhouli et al

C5Research

62

© Copyright. Society of Diagnostic Medical Sonography. All Rights Reserved.

THREE-DIMENSIONAL TRANSESOPHAGEAL ECHOCARDIOGRAPHY

Accuracy and Reliability of Left Atrial Appendage Morphology Assessment by Three-Dimensional Transesophageal Echocardiographic Glass Rendering Modality: A Comparative Study With Computed Tomography

Giorgio Fiore, MD, Carlo Gaspardone, MD, Giacomo Ingallina, MD, Vincenzo Rizza, MD, Francesco Melillo, MD, Stefano Stella, MD, Francesco Ancona, MD, Federico Biondi, MD, Davide Margonato, MD, Anna Palmisano, MD, Antonio Esposito, MD, and Eustachio Agricola, MD, *Milan, Ita*

(J Am Soc Echocardiogr 2023;36:1083-91.)

63

Comparative Imaging Methods CT and TEE

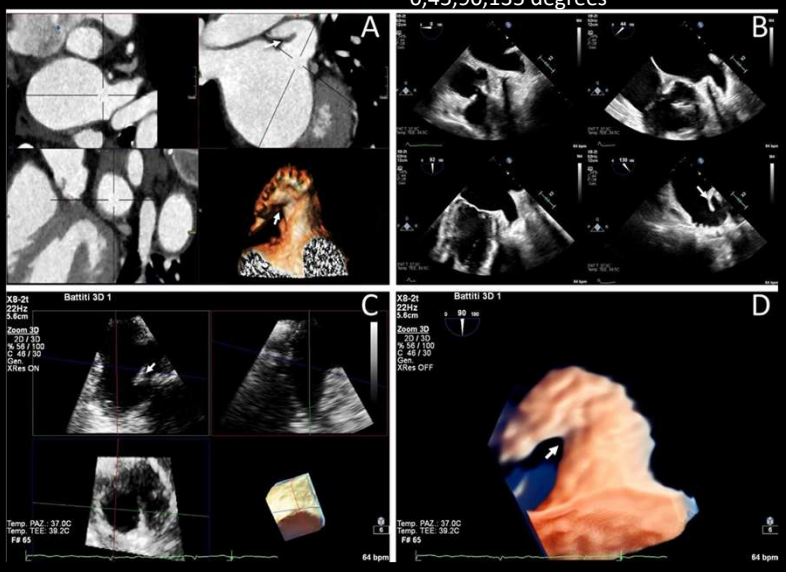

Fiore et al, J Am Soc Echocardiogr 2023;36:1083-91

64

© Copyright. Society of Diagnostic Medical Sonography. All Rights Reserved.

Classification systems for LAA morphology and their reliability

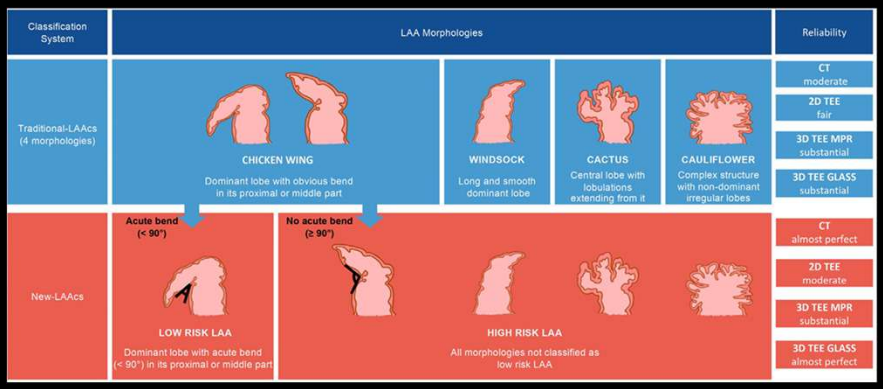

Cleveland Clinic

C5Research

65

Thank you for your attention!





parkm@ccf.org

Sydell and Arnold Miller Family Heart, Vascular and Thoracic Institute
Cleveland Clinic Foundation, Cleveland Ohio

66

© Copyright. Society of Diagnostic Medical Sonography. All Rights Reserved.