Hemodialysis Ultrasound

Preoperative Mapping and Postoperative Evaluation

Mark E. Lockhart, MD, MPH
University of Alabama at Birmingham
September 25, 2026

1

SPEAKER PRESENTATION DISCLAIMER

The content and views presented are made available for educational purposes only. The information presented are the opinions of the presenter and do not necessarily represent the views of the Society of Diagnostic Medical Sonography (SDMS) or its affiliated organizations, officers, Boards of Directors, or staff members.

The presenter is responsible for ensuring balance, independence, objectivity, scientific rigor, and avoiding commercial bias in their presentation. Before making the presentation, the presenter is required to disclose to the audience any relevant financial interests or relationships with manufacturers or providers of medical products, services, technologies, and programs.

The SDMS and its affiliated organizations, officers, Board of Directors, and staff members disclaim any and all liability for all claims that may arise out of the use of this educational activity.

2

© Copyright. Society of Diagnostic Medical Sonography. All Rights Reserved.

Disclosures

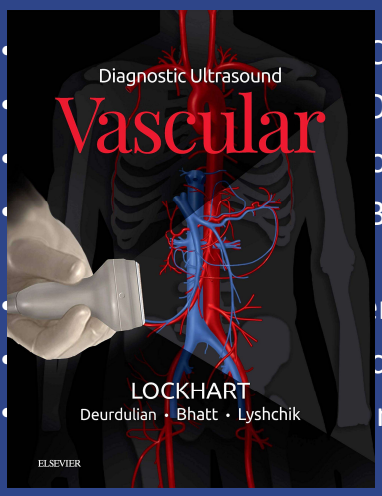

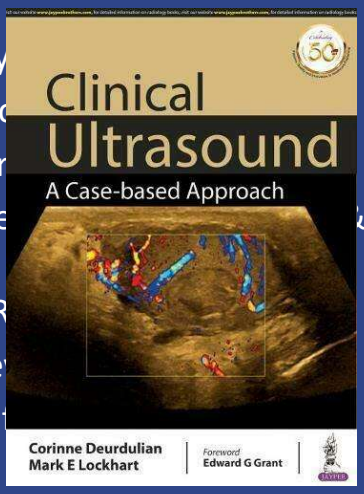

Thank you to Michelle Robbin, MD

3

Educational Objectives

- To review the basics of hemodialysis access ultrasound
- To discuss diagnostic criteria applied in hemodialysis Doppler preoperatively and after creation
- To show the sonographic appearance of common hemodialysis access complications

4

© Copyright. Society of Diagnostic Medical Sonography. All Rights Reserved.

Background

- Large demand for hemodialysis
- Current guidelines encourage fistula over graft but to a lesser degree than “fistula first”
- Earlier and more frequent hemodialysis has led to 68% increase in access repair interventions
- Vascular mapping can increase the proportion of patients who dialyze by fistula and decrease early failure

Allon Kidney Int 2001; Tordoir Neph Dial Trans 2007; Lok 2020

5

Permanent HD Access

- Arteriovenous fistulas (AVF)
  - Increased access longevity
  - Lower total cost in first two years
  - Fewer interventions to maintain patency
- Arteriovenous grafts (graft)
  - Nearly immediate use and lower primary failure rate (15% vs 50%)
  - Graft longevity less than fistula

Allon Neph Dial Trans 2005; Patel Am J Inf Cont 2016

6

© Copyright. Society of Diagnostic Medical Sonography. All Rights Reserved.

Permanent HD Access

- Arteriovenous fistulas (AVF)
  - Increased access longevity
  - Lower total cost in first two years
  - Fewer interventions to maintain patency
- Arteriovenous grafts (graft)
  - Nearly immediate use and lower primary failure rate (15% vs 50%)
  - Graft longevity less than fistula
- Catheter-based associated with 2 infections/year
  - If infection, 43.8% ICU, hospitalized > 7 days, or died
  - 67% of HD infections from 2007-2011

Allon Neph Dial Trans 2005; Patel Am J Inf Cont 2016; Sharbidre 2023

7

Background

Risk Factors of Primary Fistula Failure:

- Female
- Black
- Older
- Obese
- Vascular comorbidities
- Diabetes mellitus
- Smoking history
- Forearm fistula
- Low initial flow < 500 ml/min

Lok JASN 2006; Monroy-Cuadros CJASN 2010

8

© Copyright. Society of Diagnostic Medical Sonography. All Rights Reserved.

Routine Preoperative Ultrasound Mapping

- Meta-analysis of 18 studies (3655 subjects)
- Mapping reduced primary fistula failure rates
  - Risk ratio 0.56
- Mapping improved 1-year primary patency rates
  - Risk ratio 1.33
- Result significance persisted when restricted to RCT's

Chlorogiannis 2024

9

Revised 2021 (Resolution 35)*

ACR–AIUM–SRU PRACTICE PARAMETER FOR THE PERFORMANCE OF ULTRASOUND VESSEL MAPPING PRIOR TO DIALYSIS ACCESS CREATION

ACR
Michelle L. Robbin, MD, MS, FACR, FAIUM, FSRU, Chair
Christopher Fung, MD
Sheila Sheth, MD, FACR

AIUM
George Berdejo, BA, RVT, FSVU
Margarita V. Revzin, MD, MS, FSRU, FAIUM

SRU
Wui Kheong Chong, MD

10

© Copyright. Society of Diagnostic Medical Sonography. All Rights Reserved.

Choice of Access

- Systematic – detailed protocol in Radiographics 2023
  - Forearms (non-dominant first)
  - Upper arms (non-dominant first)
  - Dominant upper arm fistula preferred over non-dominant graft
  - Groin if arms not possible

Thigh graft still nearly 4x longevity of catheter

Ong CJASN 2013; Sharbidre 2023

11

Terminology

- Longitudinal versus transverse/short axis
- Cranial versus caudal (avoid proximal or distal)
- Upstream/inflow versus downstream
- Draining vein versus central veins

12

© Copyright. Society of Diagnostic Medical Sonography. All Rights Reserved.

Radiocephalic

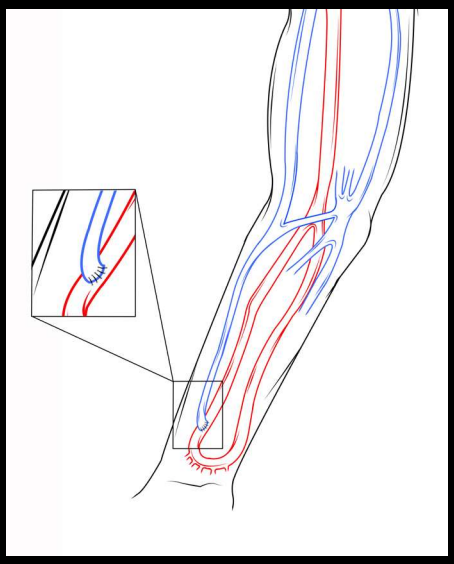

Brachiocephalic

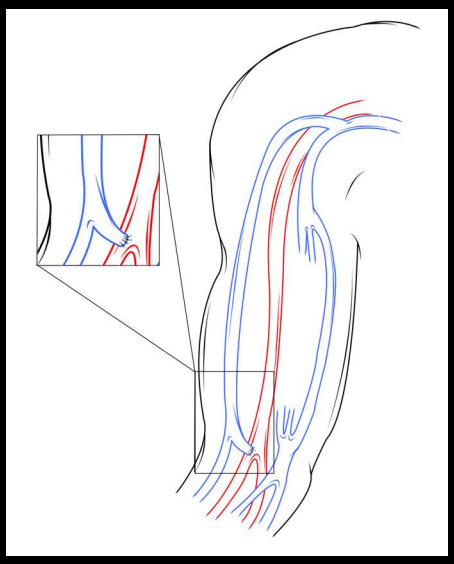

13

Radiocephalic

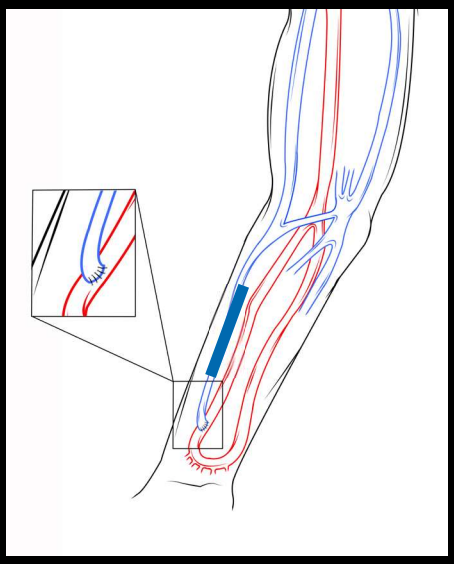

Transposition

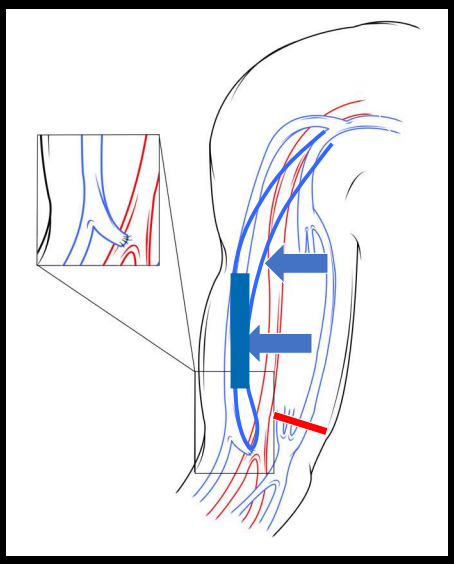

14

© Copyright. Society of Diagnostic Medical Sonography. All Rights Reserved.

Forearm Loop Graft

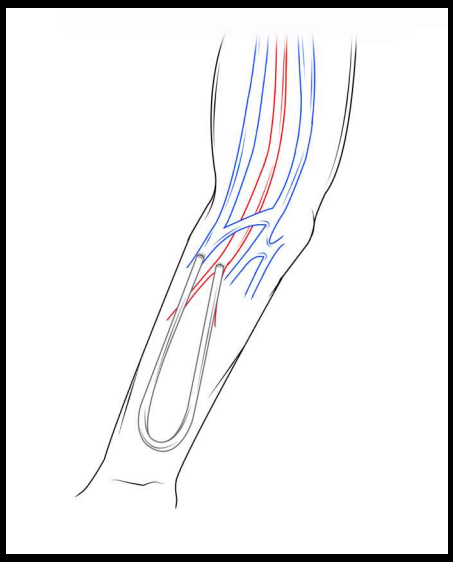

15

UA Straight Graft Upper Arm Axillary Loop graft

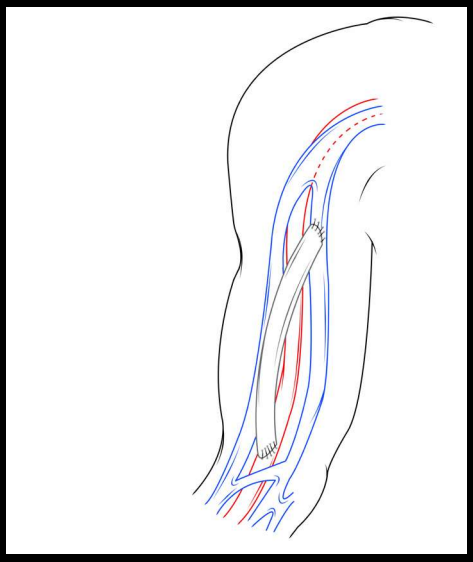

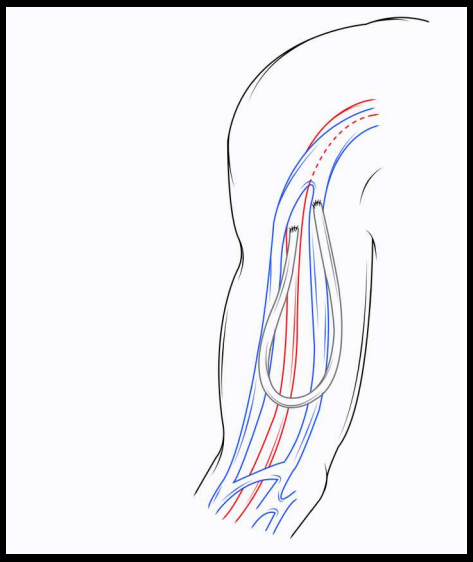

16

© Copyright. Society of Diagnostic Medical Sonography. All Rights Reserved.

Performing the Exam

- Comfortably position arm palm up on Mayo stand
- Copious gel - no pressure
- Systematic approach and standardization
  - Central veins
  - Routine goes quicker
  - Hope for perfect veins
- Patient comfort (long exam)

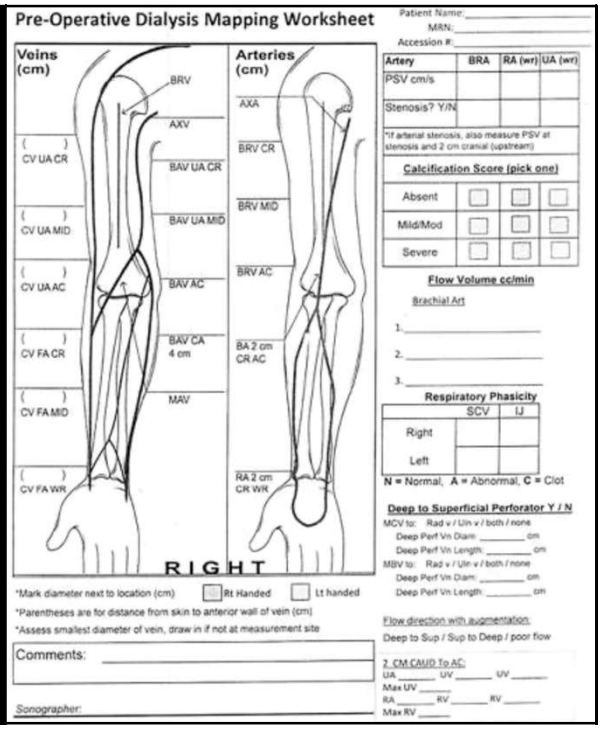

17

Preoperative Mapping

- Grayscale Criteria (inner wall-inner wall)
  - Diameters for fistula
    - Artery > 2.0 mm
    - Vein > 2.5 mm
  - Diameters for graft
    - Artery > 2.0 mm
    - Vein > 4.0 mm

Note any intimal hyperplasia or plaques in feeding artery

Silva J Vasc Surg 1998

18

© Copyright. Society of Diagnostic Medical Sonography. All Rights Reserved.

Preoperative Mapping

- Use of tourniquet to dilate vein to reach diameter > 2.5 mm
  - If less than 2.5 mm without tourniquet but > 2.5 mm with tourniquet, they have same success rate (15/45) as those initially > 2.5 mm (11/28)
  - Doubled number of successful forearm fistulas recommended by mapping

Lockhart JUM 2007

19

Tourniquet



Without Tourniquet
Diameter 0.174 cm



With Tourniquet
Diameter 0.266 cm

Resulted in usable fistula

20

© Copyright. Society of Diagnostic Medical Sonography. All Rights Reserved.

Size is not enough

- No difference in preoperative size (mm) once threshold is met

	Mature	Immature
FA artery	2.7	2.7
FA vein	3.0	2.9
UA artery	4.8	4.7
UA vein	4.2	4.0

Miller CD Kid Int 2003

21

Early Thrombosis

- HFMA study – 5.2% of 602 subjects within 18 days
- Associated with:
  - Female gender
  - Forearm location and radial artery
  - Small artery diameter
  - Intraoperative protamine
  - Clinical concern or frustration during surgery
  - Absent or reduced thrill at surgery

Farber J Vasc Surg 2016

22

© Copyright. Society of Diagnostic Medical Sonography. All Rights Reserved.

Revised 2024 (Resolution 23)

ACR–AIUM–SRU PRACTICE PARAMETER FOR THE PERFORMANCE OF VASCULAR ULTRASOUND FOR POSTOPERATIVE ASSESSMENT OF HEMODIALYSIS ACCESS

- Hemodialysis access blood flow inadequate for dialysis (500-600 ml/min or 25% decrease)
- Persistent ipsilateral arm edema or pain after access placement or during hemodialysis
- Delayed maturity of surgically created fistula > 6 weeks
- Suspected pseudoaneurysm, fistula, graft stenosis, perigraft infection or fluid collection
- Decreased or absent thrill or abnormal bruit over hemodialysis site
- Follow-up after intervention
- Clinical signs or symptoms of hand/digit ischemia, typically during or after hemodialysis
- Access collapse during hemodialysis
- Prolonged site bleeding > 20 min from access needle sites
- Unexplained decrease in dialysis dose delivery (Kt/V), which is dialyzer clearance x time / H_20 volume
- Repeated difficult cannulation
- Thrombus aspiration during hemodialysis
- Elevated venous pressure 200 mmHg on 300 ml/min pump
- Recirculation time elevation> 15%

23

Post-op US Technique

- Grayscale – trans, long
- Color Doppler – Aliasing
- Spectral Doppler
  - PSV, EDV, Ratio
  - Doppler ≤ 60 degrees
- Wall filter
- Volume flow
  - Straight non-tapering
  - Gate perpendicular to vein
  - Measure 3-4 cycles

- Linear when possible
- Transducer at least 7 MHz
- Use 9-15 MHz for volume flow rates for resolution and near-field
- Above 2.5 MHz for Doppler for better Doppler shift and SNR

24

© Copyright. Society of Diagnostic Medical Sonography. All Rights Reserved.

Post-op US Technique

- Arterial
  - Feeding artery for stenosis
  - Artery diameter
  - Feeding artery color and spectral
  - PSV/EDV inflow and anast
  - Parallel to jet
  - Flow volume in artery

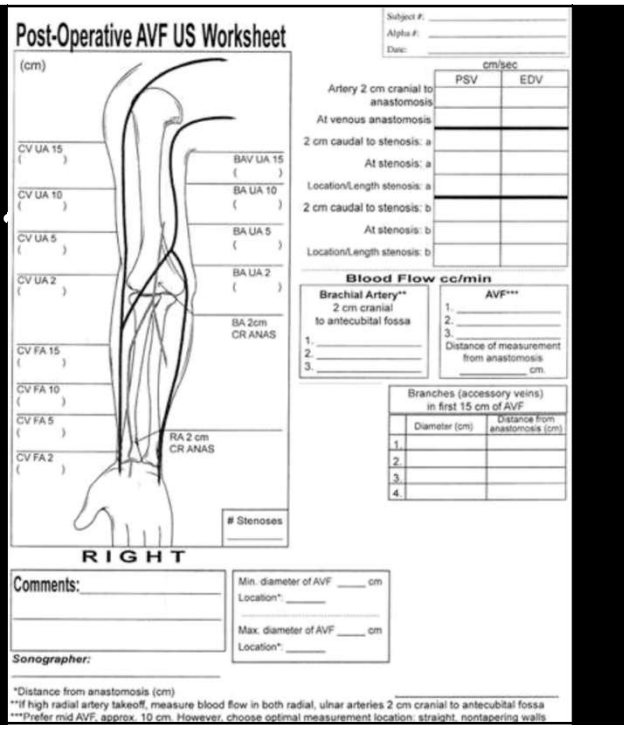

25

Two Broad Concepts of Fistula Evaluation

- Delayed fistula maturity (failure if > 3 months)
  - 28-60% do not mature in typical time frame
  - Physical exam struggles
  - Ultrasound can predict dialysis access success at first usage
- Dysfunction of previously functional fistula
  - Characterization to guide optimal management

26

© Copyright. Society of Diagnostic Medical Sonography. All Rights Reserved.

>50% of fistulas fail to mature

- Multicenter trial of 877 patients showed non-maturation in 60%
- Etiologies:
  - Stenosis due to neo-intimal hyperplasia
  - Branches
  - Artery unable to deliver adequate blood flow
  - Vein unable to dilate

Dember JAMA 2008

27

Failure to Mature

- Vein diameter, depth, and flow volume are the key parameters
- If abnormal, then search for the underlying cause
- Often due to stenosis

28

© Copyright. Society of Diagnostic Medical Sonography. All Rights Reserved.

Minimum Vein Diameter

- ≥ 0.4 cm
  - Adequate for dialysis 89% (24/27)
- < 0.4 cm
  - Adequate for dialysis 44% (12/27)

Robbin Radiology 2002

29

Minimum Blood Flow

- ≥ 500 ml/min
  - Adequate fistula in 84% (26/31)
- < 500 ml/min
  - Adequate fistula in 43% (9/21)

If low flow, look harder for stenosis

Don't forget central causes of low flow

Robbin Radiology 2002

30

© Copyright. Society of Diagnostic Medical Sonography. All Rights Reserved.

Diameter and Blood Flow

- Both criteria
  - 95% adequate for dialysis (19/20)
- Neither criteria
  - 33% adequate for dialysis (5/15)

Robbin Radiology 2002

31

K-DOQI

- 0.6 cm diameter
- 0.6 cm depth
- 600 ml/min

Nearly 1/3 of our successful fistulas would not have qualified

KDOQI Am J Kid Dis 2006

32

© Copyright. Society of Diagnostic Medical Sonography. All Rights Reserved.

Summary of Current Criteria for Maturation

- Diameter ≥ 0.4-0.6 cm
- Depth ≤ 0.5-0.6 cm
- Volume flow ≥ 500-600 ml/min

Robbin 2002; Singh 2008; Ferring 2014

33

Normal Mature Fistula

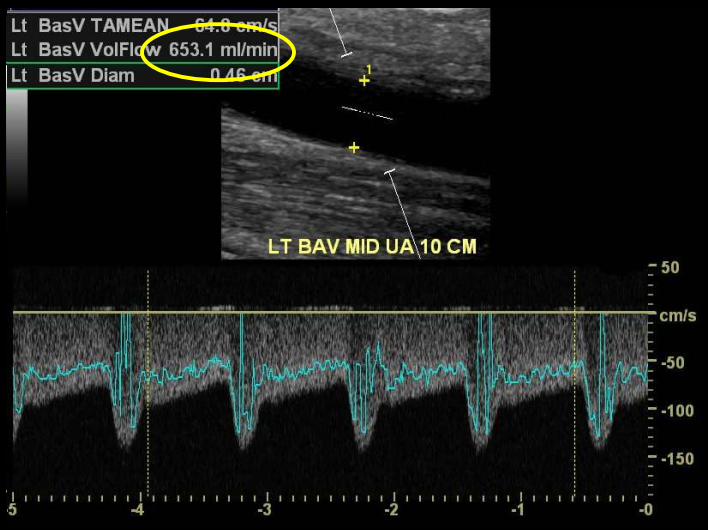

34

© Copyright. Society of Diagnostic Medical Sonography. All Rights Reserved.

Immature Fistula

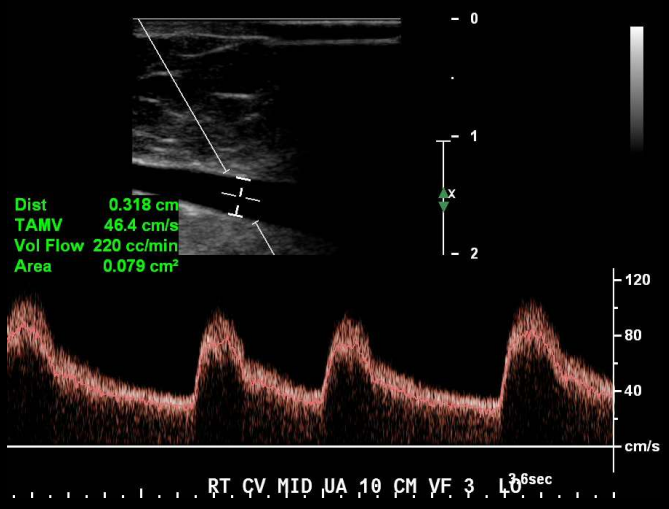

35

Clinical versus Sonographic Immature Fistula

- Sonographic evaluation of 95 *clinically immature* fistulas
  - 29% sono mature — 91% usable
  - 71% sono immature — 31% without salvage; 78% with salvage

Singh Radiology 2008

36

© Copyright. Society of Diagnostic Medical Sonography. All Rights Reserved.

Etiologies for Sonographic Immature Fistula

- Detected lesions in sonographically immature fistulas
  - Vein branch 51%
  - Stenosis 34%
  - Too deep 28%
  - Multiple abnormalities 19%
- Can direct patient to proper therapy

Singh Radiology 2008; Forsythe Card Int Rad 2015

37

Fistula Stenosis > 50%

- Same criteria whether associated with failure to mature or dysfunction of a previously usable fistula
- Anastomosis is most common site of stenosis but up to 50% will also have venous abnormalities
- PSV Ratio at Anastomosis > 3.0 suggests 50% stenosis
- Correlate with grayscale

Pay close attention near anastomosis

Do not panic if stenosis present

Beathard 2003; Rajan 2004; Lockhart 2004; Chao 2001; Asif 2005

38

© Copyright. Society of Diagnostic Medical Sonography. All Rights Reserved.

Fistula Stenosis > 50%

- PSV > 375 cm/sec
  - Sensitivity 96%
  - Specificity 76%
- May be associated with higher resistance of the inflow
- If parvus-tardus, an inflow stenosis may prevent adequate velocity elevation for diagnosis

Doelmam 2004; Moreno 2014

39

Fistula Anastomotic Stenosis

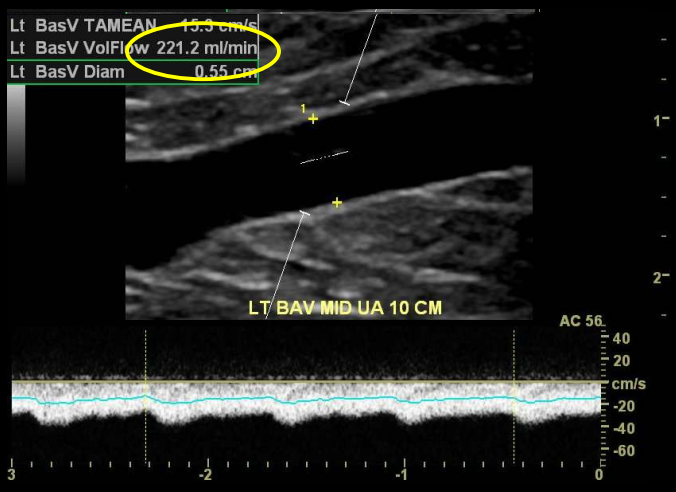

PSV Ratio at Anastomosis > 3.0

40

© Copyright. Society of Diagnostic Medical Sonography. All Rights Reserved.

Draining Vein Stenosis

- PSV ratio ≥ 2.0 suggests 50 – 74%
- PSV ratio ≥ 3.0 suggests ≥ 75%

High pressure collaterals may confuse

41

DV Stenosis



42

© Copyright. Society of Diagnostic Medical Sonography. All Rights Reserved.

DV Occlusion

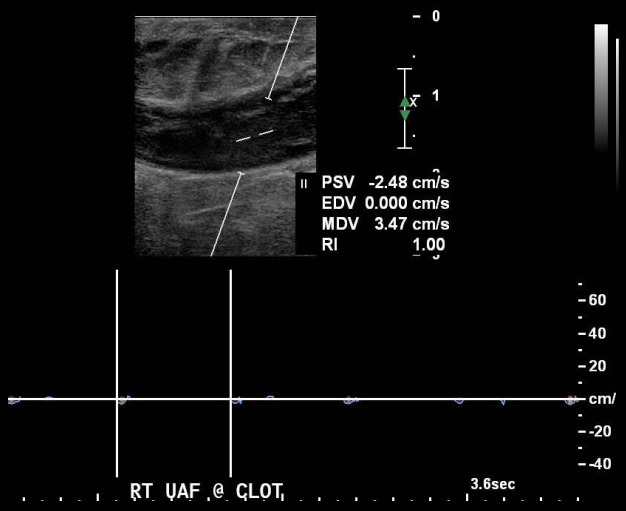

Use low scale

43

Monophasic Central Venous Flow

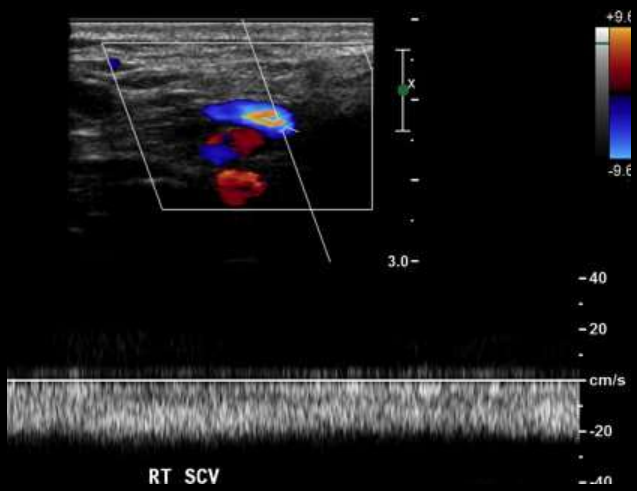

Predictive of central stenosis

Patel MC Rad 1999

44

© Copyright. Society of Diagnostic Medical Sonography. All Rights Reserved.

Monophasic Central Venous Flow



45

Treatment of Central Stenosis

- Stenting versus angioplasty
- Both groups required multiple subsequent interventions
- No difference in primary or secondary fistula patency rates

Bakken AM J Vasc Surg 2007

46

© Copyright. Society of Diagnostic Medical Sonography. All Rights Reserved.

Large Competing Vein



47

Large Competing Vein

- Most important in first 10 cm
- May prevent adequate wall stress on main draining vein

Check volume flows upstream and downstream from large branch

48

© Copyright. Society of Diagnostic Medical Sonography. All Rights Reserved.

Vein Too Deep

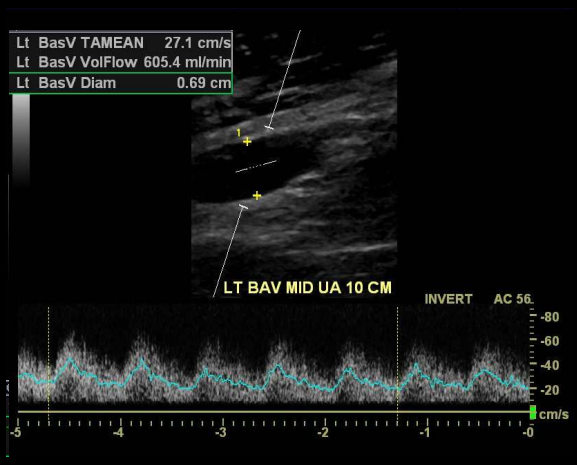

Matters mostly in "stick zone"

49

Arterial Steal

- 5-7% of accesses; most are asymptomatic
- More commonly symptomatic in brachial access (87%)
- Severe cases (4%) may require ligation or distal revascularization with interval ligation (female, DM, CAD, large outflow veins)

If symptoms, check palmar arch for collateral supply to thumb

If incomplete arch, may require sacrifice of the fistula

Sivanesan NDT 1998; Leake J Vasc Surg 2015; Huber 2016

50

© Copyright. Society of Diagnostic Medical Sonography. All Rights Reserved.

Arterial Steal

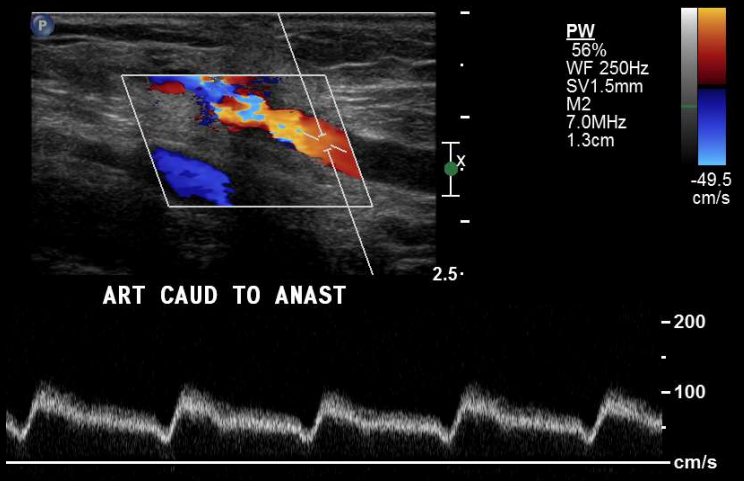

51

Arterial Steal

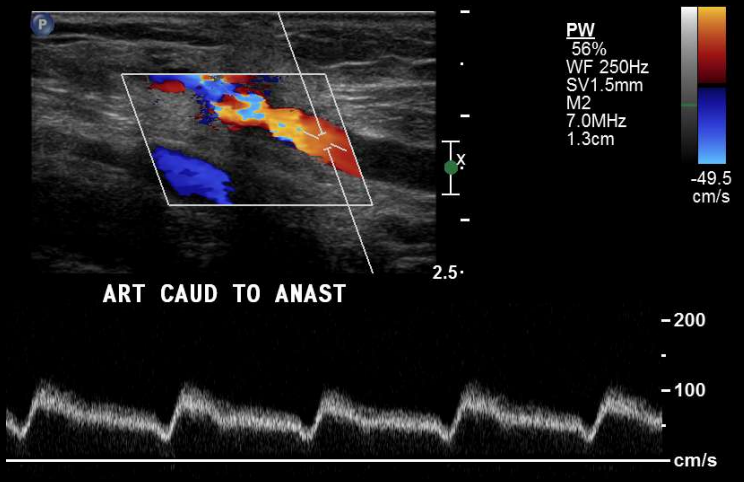

52

© Copyright. Society of Diagnostic Medical Sonography. All Rights Reserved.

High Outflow Cardiac Failure

- Treatable form of cardiac failure after transplant
  - Present in up to 24%
- Risk factors – wide anastomosis, upper arm, male, volume expansion
- High access flow rate > 2000 ml/min or flow-to-cardiac output ratio > 30-35%
- Symptoms resolve after access closure

Zahra 2021; Saleh 2018

53

Salvage of Immature AVF

- AVF adequacy lower in women than men
  (31% vs. 51%)
- Worse in forearms (18% vs. 43%)
- Maturation after salvage procedure better for women (50% vs. 37%)

Allon M Kid Int 2003

54

© Copyright. Society of Diagnostic Medical Sonography. All Rights Reserved.

Salvage of Immature AVF

- Salvage success depends on underlying lesion

Likelihood of Fistula Maturation

	Rx	No Rx
Stenosis	70%	0%
Vein Branch	83%	33%
Too Deep	71%	28%

Singh P Rad 2008

55

Successful Salvage

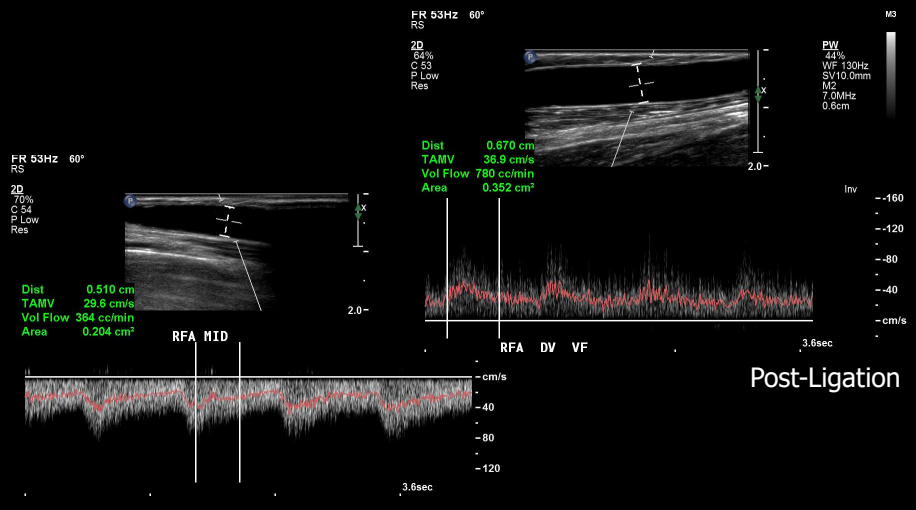

56

© Copyright. Society of Diagnostic Medical Sonography. All Rights Reserved.

Grafts

57

Arteriovenous Graft

- Primary failure rate 5-15%
- 70% patent at 1-year
  Compared with tunneled catheter 30-65% at 1-year
- Related to neo-intimal hyperplasia which is not present preoperatively

KDOQI 2006; Mehta S 1991; Roy-Chaudhury 2001

58

© Copyright. Society of Diagnostic Medical Sonography. All Rights Reserved.

Graft Thrombosis



Results in graft abandonment in over two-thirds

59

Graft Stenosis

- Venous anastomosis
  - PSV ratio ≥ 2.0 suggests ≥ 50%
  - PSV ratio ≥ 3.0 suggests ≥ 75%
  - If borderline ratio, PSV > 310 - 400 cm/s or visible narrowing greater than 50% can help diagnosis
- Arterial anastomosis
  - PSV ratio ≥ 3.0 suggests ≥ 50%
  - PSV > 310 cm/s is 93% specific but only 50% sensitive

Older RA Rad 1998; Robbin ML Rad 1998; Doelman 2005

60

© Copyright. Society of Diagnostic Medical Sonography. All Rights Reserved.

Venous Anastomosis Stenosis

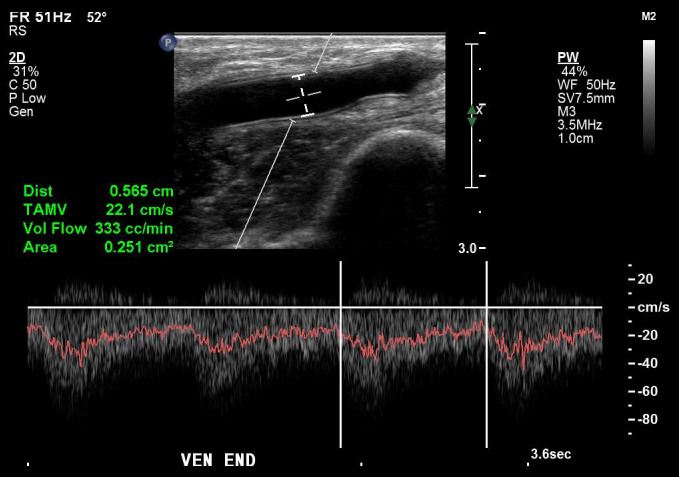

Most common site of stenosis

61

Draining Vein Stenosis in Graft

- 2nd most common site of stenosis
- Similar appearance to draining vein stenosis in fistula
- Draining Vein Stenosis
  - PSV ratio across stenosis ≥ 2.0

62

© Copyright. Society of Diagnostic Medical Sonography. All Rights Reserved.

Volume Flow in Graft

- Normal flow volumes are typically higher in grafts than fistulas
- Routinely may reach 1300 ml/min
- May be above 500 ml/min in setting of stenosis

Flow volume less than 500 ml/min should prompt fistulogram even if no stenosis identified

63

Brachiocephalic Vein Occlusion



64

© Copyright. Society of Diagnostic Medical Sonography. All Rights Reserved.

Brachiocephalic Vein Occlusion

- One of the few causes of reversal of internal jugular flow
- Could also consider carotid-jugular fistula
- Look for clot with small footprint transducer

65

Graft Degeneration

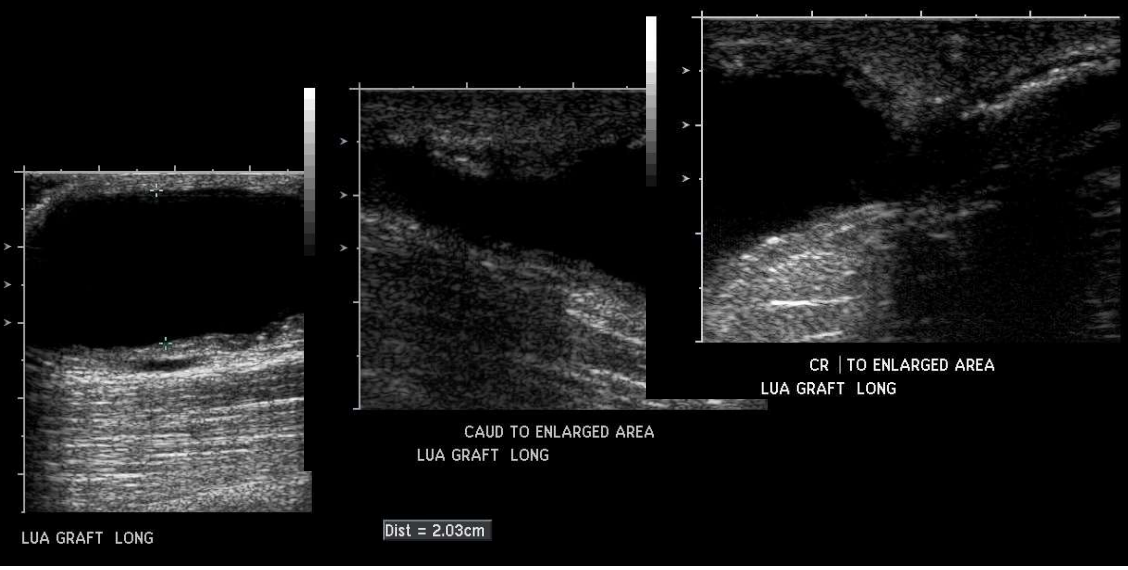

66

© Copyright. Society of Diagnostic Medical Sonography. All Rights Reserved.

Graft Pseudoaneurysm



67

Percutaneous Interventions

- Study of 40,132 CMS beneficiaries
  - Limited overall benefits to access survival
  - Greatest benefits appear to be in patients with:
    - New access
    - Low access flow rates

Chan CJASN 2011

68

© Copyright. Society of Diagnostic Medical Sonography. All Rights Reserved.

Routine Fistula Screening

- Meta-analysis of 14 studies (active surveillance and preemptive correction versus routine clinical screening or deferred salvage
  - Preemptive screening had significant effect on thrombosis [RR 0.79], but a nonsignificant effect on access loss [RR 0.81]
  - Treatment effects were larger in fistulas than grafts

ACC 2013 suggests routine surveillance is rarely appropriate for asymptomatic functioning hemodialysis AVG or AVF

KDOQI 2019 recommends against preemptive treatment of stenosis in absence of clinical signs

Tonelli Am J Kid Dis 2008; Paulson Sem Dial 2013; Gornik 2013; Ravani 2016; Lok 2020

69

Recent Developments/Future Directions

- Dynamic flow modeling
  - Flow volumes (< 500 ml/min) and rapid flow volume decline (> 25%) as better predictors
- Automated surveillance
  - Artificial intelligence-assisted stenosis segmentation
- Functional failure prediction with machine learning

70

© Copyright. Society of Diagnostic Medical Sonography. All Rights Reserved.

Summary

- Ultrasound is useful preoperatively to select the best site and postoperatively to evaluate an immature or dysfunctional hemodialysis access
- Important to understand threshold values, potential complications, and salvage options
- Role of routine screening is still in doubt

Selected References

- Lok CE, Huber TS, Lee T, Shenoy S, Yevzlin AS, Abreo K, Allon M, Asif A, Astor BC, Glickman MH, Graham J, Moist LM, Rajan DK, Roberts C, Vachharajani TJ, Valentini RP; National Kidney Foundation. KDOQI Clinical Practice Guideline for Vascular Access: 2019 Update. Am J Kidney Dis. 2020 Apr;75(4 Suppl 2):S1-S164. doi: 10.1053/j.ajkd.2019.12.001. Epub 2020 Mar 12. Erratum in: Am J Kidney Dis. 2021 Apr;77(4):551. doi: 10.1053/j.ajkd.2021.02.002. PMID: 32778223.
- Tordoir J, Canaud B, Haage P, Konner K, Basci A, Fouque D, Kooman J, Martin-Malo A, Pedrini L, Pizzarelli F, Tattersall J, Vennegoor M, Wanner C, ter Wee P, Vanholder R. EBPG on Vascular Access. Nephrol Dial Transplant. 2007 May;22 Suppl 2:ii88-117. doi: 10.1093/ndt/gfm021. PMID: 17507428.
- Allon M, Lockhart ME, Lilly RZ, Gallichio MH, Young CJ, Barker J, Deierhoi MH, Robbin ML. Effect of preoperative sonographic mapping on vascular access outcomes in hemodialysis patients. Kidney Int. 2001 Nov;60(5):2013-20. doi: 10.1046/j.1523-1755.2001.00031.x. PMID: 11703621.
- Patel PR, Shugart A, Mbaeyi C, Goding Sauer A, Melville A, Nguyen DB, Kallen AJ; NHSN Outpatient Hemodialysis Center Participants. Dialysis Event Surveillance Report: National Healthcare Safety Network data summary, January 2007 through April 2011. Am J Infect Control. 2016 Aug 1;44(8):944-7. doi: 10.1016/j.ajic.2016.02.009. Epub 2016 Mar 31. PMID: 27040568.
- Sharbidre KG, Alexander LF, Al-Balas A, Robbin ML. Percutaneous Creation of Dialysis Arteriovenous Fistula: Patient Selection and Ultrasound Mapping. Semin Intervent Radiol. 2023 May 4;40(1):87-99. doi: 10.1055/s-0043-1764430. PMID: 37152789; PMCID: PMC10159719.
- Allon M, Radeva M, Bailey J, Beddhu S, Butterly D, Coyne DW, Depner TA, Gassman JJ, Kaufman AM, Kaysen GA, Lewis JA, Schwab SJ; HEMO Study Group. The spectrum of infection-related morbidity in hospitalized haemodialysis patients. Nephrol Dial Transplant. 2005 Jun;20(6):1180-6. doi: 10.1093/ndt/gfh729. Epub 2005 Mar 15. PMID: 15769823.
- Chlorogiannis DD, Bousi SE, Zachiotis M, Chlorogiannis A, Kyriakoulis I, Bellos I. Pre-operative ultrasound mapping before arteriovenous fistula formation: an updated systematic review and meta-analysis. J Nephrol. 2024 Mar;37(2):281-292. doi: 10.1007/s40620-023-01814-6. Epub 2023 Dec 22. PMID: 38133741; PMCID: PMC11043143.
- Ong S, Barker-Finkel J, Allon M. Long-term outcomes of arteriovenous thigh grafts in hemodialysis patients: a comparison with tunneled dialysis catheters. Clin J Am Soc Nephrol. 2013 May;8(5):804-9. doi: 10.2215/CJN.09240912. Epub 2013 Jan 31. PMID: 23371958; PMCID: PMC3641621.
- Silva MB Jr, Hobson RW 2nd, Pappas PJ, Jamil Z, Araki CT, Goldberg MC, Gwertzman G, Padberg FT Jr. A strategy for increasing use of autogenous hemodialysis access procedures: impact of preoperative noninvasive evaluation. J Vasc Surg. 1998 Feb;27(2):302-7; discussion 307-8. doi: 10.1016/s0741-5214(98)70360-x. PMID: 9510284.
- Miller CD, Robbin ML, Allon M. Gender differences in outcomes of arteriovenous fistulas in hemodialysis patients. Kidney Int. 2003 Jan;63(1):346-52. doi: 10.1046/j.1523-1755.2003.00740.x. PMID: 12472802.
- Farber A, Imrey PB, Huber TS, Kaufman JM, Kraiss LW, Larive B, Li L, Feldman HI; HFM Study Group. Multiple preoperative and intraoperative factors predict early fistula thrombosis in the Hemodialysis Fistula Maturation Study. J Vasc Surg. 2016 Jan;63(1):163-70.e6. doi: 10.1016/j.jvs.2015.07.086. PMID: 26718822; PMCID: PMC4698902.
- Zahra SA, Choudhury RY, Basharat K, Tran T, Begum M, Abotabekh A, Hedayat F, Rimmer L, Harky A, Bashir M. Translational Sciences in Cardiac Failure Secondary to Arteriovenous Fistula in Hemodialysis Patients. Ann Vasc Surg. 2021 Jul;74:431-449. doi: 10.1016/j.avsg.2021.01.071. Epub 2021 Feb 6. PMID: 33556504.
- Huber TS, Larive B, Imrey PB, Radeva MK, Kaufman JM, Kraiss LW, Farber AM, Berceli SA; HFM Study Group. Access-related hand ischemia and the Hemodialysis Fistula Maturation Study. J Vasc Surg. 2016 Oct;64(4):1050-1058.e1. doi: 10.1016/j.jvs.2016.03.449. Epub 2016 Jul 29. PMID: 27478007; PMCID: PMC5036979.

© Copyright. Society of Diagnostic Medical Sonography. All Rights Reserved.



© Copyright. Society of Diagnostic Medical Sonography. All Rights Reserved.