Ultrasound of Renal, Hepatic, and Pancreas Transplants

Mark E. Lockhart, M.D, M.P.H.
University of Alabama at Birmingham
September 25, 2026

1

SPEAKER PRESENTATION DISCLAIMER

The content and views presented are made available for educational purposes only. The information presented are the opinions of the presenter and do not necessarily represent the views of the Society of Diagnostic Medical Sonography (SDMS) or its affiliated organizations, officers, Boards of Directors, or staff members.

The presenter is responsible for ensuring balance, independence, objectivity, scientific rigor, and avoiding commercial bias in their presentation. Before making the presentation, the presenter is required to disclose to the audience any relevant financial interests or relationships with manufacturers or providers of medical products, services, technologies, and programs.

The SDMS and its affiliated organizations, officers, Board of Directors, and staff members disclaim any and all liability for all claims that may arise out of the use of this educational activity.

2

© Copyright. Society of Diagnostic Medical Sonography. All Rights Reserved.

Disclosures

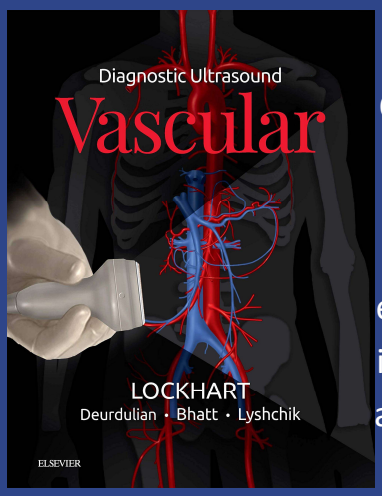

Cer
Ora
of U
Bro
rs &
er, A
ical
and

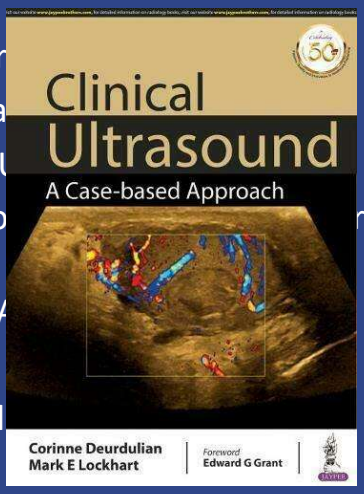

3

Objectives

- To provide examples of complications of hepatic, renal, and pancreas transplants as unknown cases

4

© Copyright. Society of Diagnostic Medical Sonography. All Rights Reserved.

Renal

5

US is Modality to Evaluate Renal Transplant Dysfunction

American College of Radiology
ACR Appropriateness Criteria®

- Ultrasound highest rating for any imaging modality
- Scored 9
- (MAG-3 next highest rated 6)

6

© Copyright. Society of Diagnostic Medical Sonography. All Rights Reserved.

Technique

- Ask the patient and look for the scar
- More superficial – allows higher frequency transducer
- Start with overview of kidney (grayscale)
- Trace along artery toward the origin
- Optimize Doppler settings on iliac artery if difficult to detect flow

7

US Post-transplant Technique

- High frequency curved transducer
- Visualize entire artery and vein using color Doppler
- Spectral Doppler of anastomoses, inflow artery, and renal vein
- Segmental artery Dopplers
- Power Doppler of parenchymal perfusion if questionable flow

8

© Copyright. Society of Diagnostic Medical Sonography. All Rights Reserved.

Elevated Intra-renal RI's

- Abnormal if RI > 0.75 - 0.80
- Spectral Doppler for rejection:
  - Sensitivity 54-75%
  - Specificity 33-90%
- Similar wide variation for Power Doppler

Datta 2005; Rigsby 1987

9

Elevated Intra-renal RI's

- Combination of factors such as compliance, heart rate, Valsalva
- Superficial location of transplant allograft
  - Susceptible to compression by transducer
  - May artifactually increase RI

Krumme 2006

10

© Copyright. Society of Diagnostic Medical Sonography. All Rights Reserved.

Renal Allograft Dysfunction

- Gray-scale findings
  - Renal enlargement
  - Abnormal echogenicity of parenchyma
  - Loss of corticomedullary differentiation
  - Prominent pyramids
  - Collecting system thickening

11

Renal Allograft Dysfunction

- Gray-scale findings
  - Renal enlargement
  - Abnormal echogenicity of parenchyma
  - Loss of corticomedullary differentiation
  - Prominent pyramids
  - Collecting system thickening

Rejection > ATN

12

© Copyright. Society of Diagnostic Medical Sonography. All Rights Reserved.

Acute Tubular Necrosis

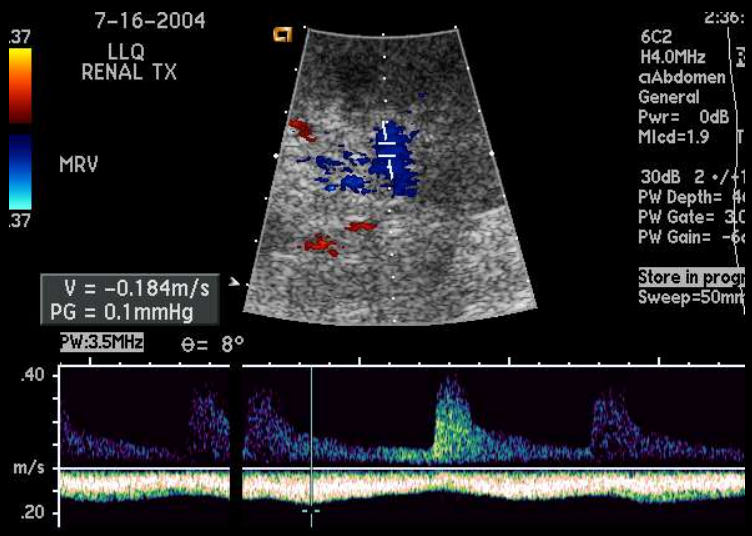

13

Acute Rejection

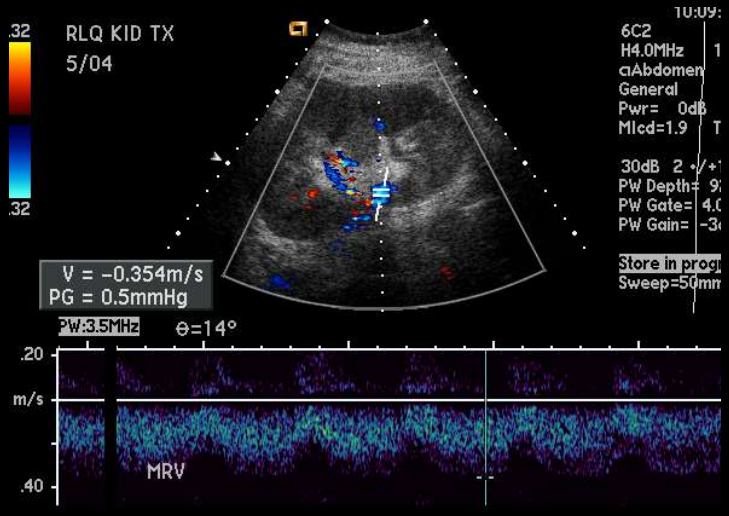

14

© Copyright. Society of Diagnostic Medical Sonography. All Rights Reserved.

Acute Rejection

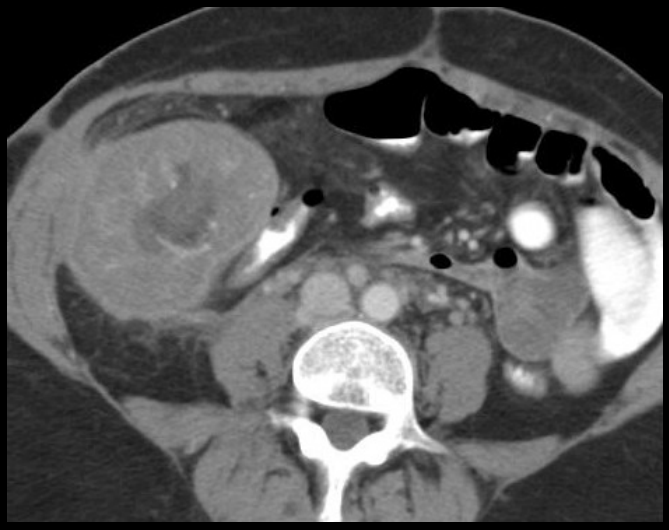

15

Elevated Intra-renal RI's

- Prospective study
- Independent marker of future graft loss
- Not specific for a given etiology

- Contradicted in subsequent study

Radermacher 2003; Heine 2005

16

© Copyright. Society of Diagnostic Medical Sonography. All Rights Reserved.

Vascular Complications

- 1500 transplants from 1988-2006
  - Hemorrhage 6.1%
  - Renal artery stenosis 1.7%
  - Renal artery thrombosis 0.6%
  - Renal vein thrombosis 0.5%

Salehipour Saudi J Kid Dis Transpl

17

Peritransplant Collection

- Hematoma
- Urinoma
- Lymphocele
- Abscess

Collections may be present on ultrasound in as many as 51% of recent transplants

Silver TM, Rad 1981

18

© Copyright. Society of Diagnostic Medical Sonography. All Rights Reserved.

Case

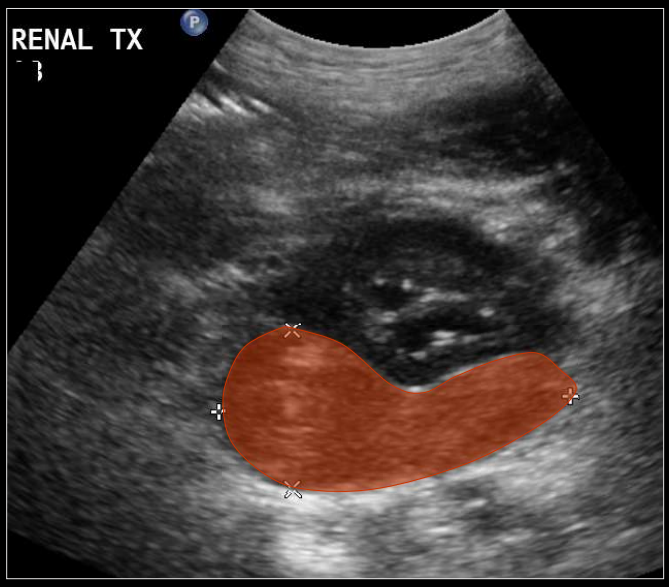

19

Peritransplant Collection

- Hematoma
- Urinoma
- Lymphocele
- Abscess

Collections may be present on ultrasound in as many as 51% of recent transplants

Silver TM, Rad 1981

20

© Copyright. Society of Diagnostic Medical Sonography. All Rights Reserved.

Hematoma

- Common in the early postoperative period
- Usually small and resolve
- Cresent of echogenic fluid that becomes anechoic over time

21

Hematoma

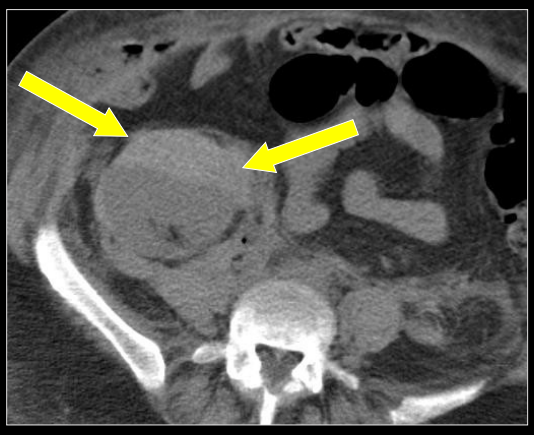

Compression of kidney is rare cause of reversed diastolic flow

Lockhart AJR 2007

22

© Copyright. Society of Diagnostic Medical Sonography. All Rights Reserved.

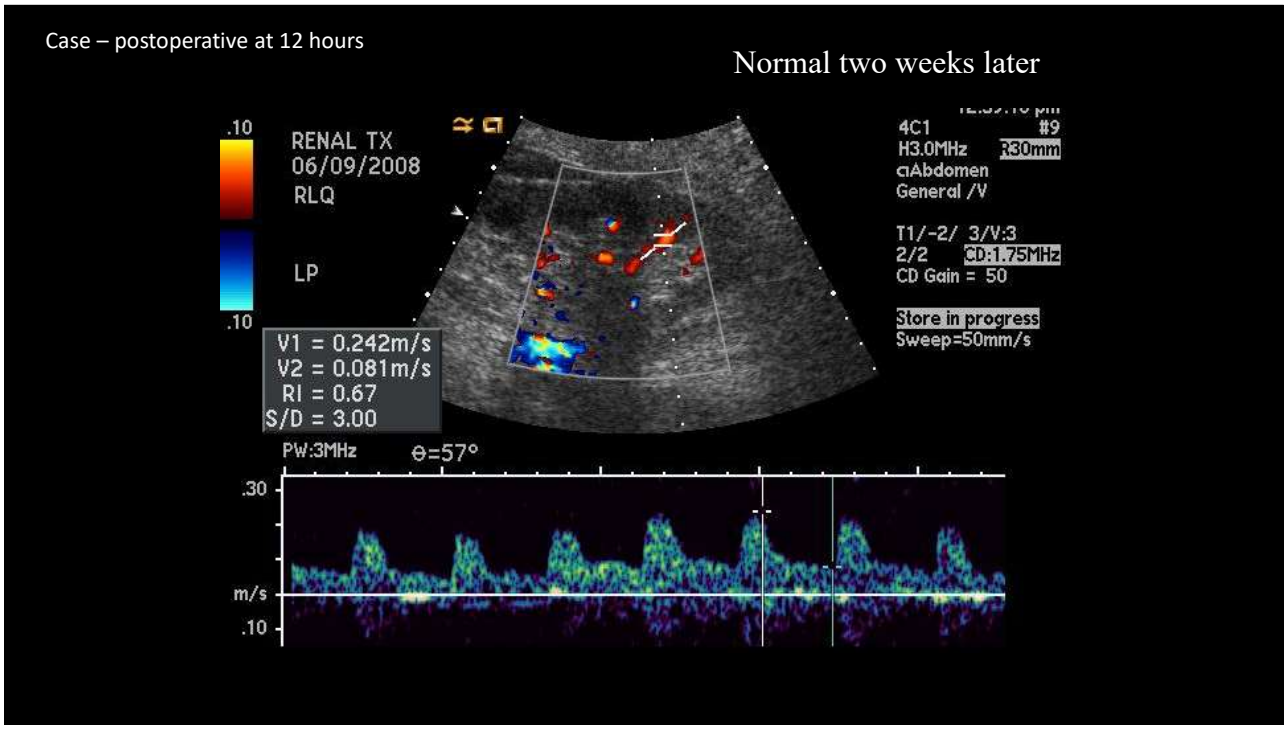

23

Perioperative Edema

- Higher PSV may occur at anastomosis in perioperative period without stenosis
  - 22 recipients without complication
    - Perioperative mean PSV 271 cm/sec
    - At 3 months PSV 187 cm/sec

Thalhammer Utraschall Med 2006

24

© Copyright. Society of Diagnostic Medical Sonography. All Rights Reserved.

New case

Transplant RAS

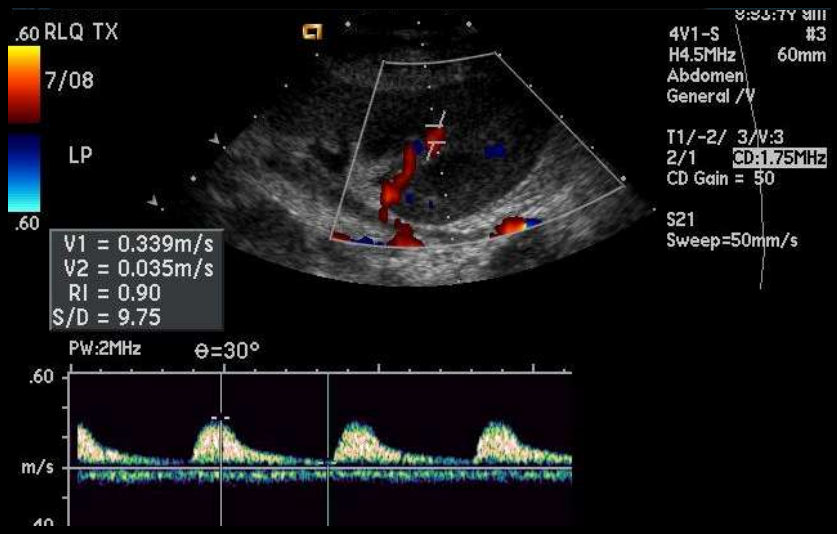

25

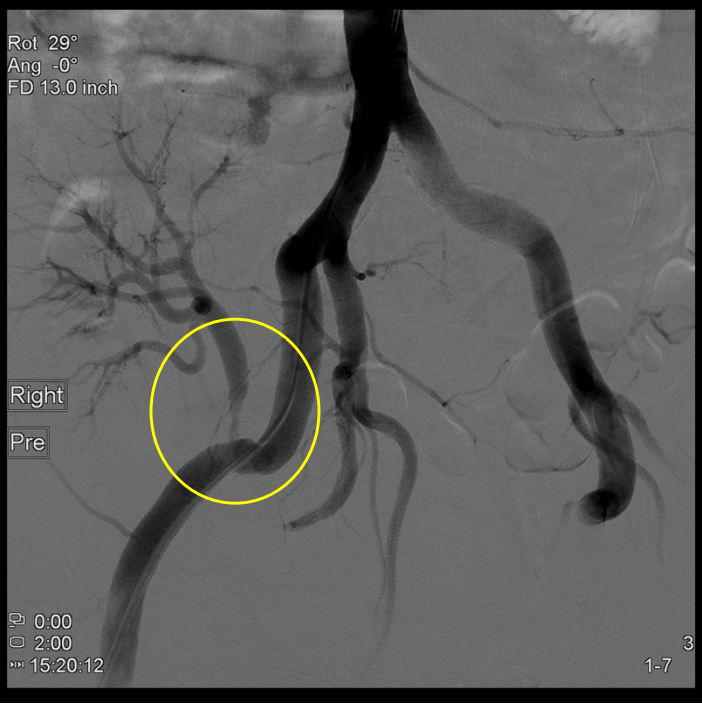

26

© Copyright. Society of Diagnostic Medical Sonography. All Rights Reserved.

Tx Renal Artery Stenosis

- Etiology of transplant hypertension in less than 5% of patients
- Usually occurs from 3-24 months after transplantation surgery
- Prevalence 1-23% in literature but 1-3% in later studies of 793 and 831 patients

Bruno JASN 2004; Patel Rad 2001; Polak Trans Proc 2006

27

Tx Renal Artery Stenosis

- Associated with vascular injury
  - Higher in cadaveric with prolonged cold ischemia
- Early stenosis likely related to surgical trauma
- Late stenosis may represent atherosclerotic disease progression

Bruno JASN 2004; Becker Clin Transplant 1999

28

© Copyright. Society of Diagnostic Medical Sonography. All Rights Reserved.

Tx RAS – Indirect Criteria

- Abnormal Resistive Indices
  - Downstream may have high or low RI
- Loss of Early Systolic Peak less useful than in native kidneys
- Delayed systolic acceleration
  - Acceleration Time > 0.1 sec (unlike 0.07 in native)
- Parvus-tardus

29

Tx Renal Artery Stenosis

- 200 cm/sec is too low (11% PPV)
- Patel suggests 300 cm/sec in a surveillance population
  - 5 (4.2%) had stenosis
  - All had PSV > 250 cm/sec
  - Using 300 cm/sec – sens 80%, spec 93%

Patel Clin Rad 2003

30

© Copyright. Society of Diagnostic Medical Sonography. All Rights Reserved.

Tx Renal Artery Stenosis

- If clinical suspicion, screening should use 250 cm/sec or ratio >1.8, and consider intrarenal waveforms
- Using a PSV > 300 cm/sec or ratio >2.5 reduces false positives in a low-risk population

Patel Clin Rad 2003

31

Case

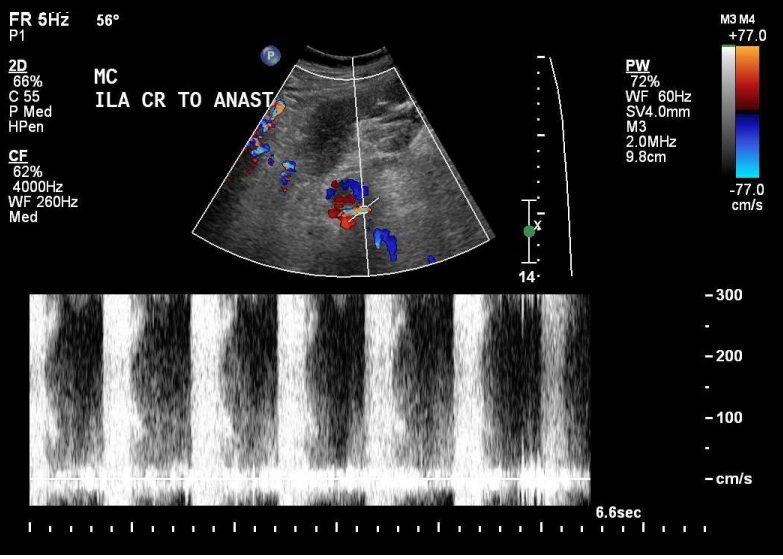

32

© Copyright. Society of Diagnostic Medical Sonography. All Rights Reserved.

Different Patient



33

Iliac Artery Stenosis

- 819 transplant patients
- 44 with stenosis (mean age 47 years)
  - 55% TRAS
  - 45% Iliac stenosis (pseudo-TRAS)
    - DM, age, weight, panel reactive Ab
- Both had similarly worse graft survival

Becker Clin Transplantation 1999

34

© Copyright. Society of Diagnostic Medical Sonography. All Rights Reserved.

Accessory Artery Stenosis



35

Multiple Renal Arteries

- 350 renal transplants from 2000-2007
- Over 90% of transplanted kidneys have single artery
- Approximately 6% have two arteries
- 1-3% have 3 or more arteries

Surgical note can be very useful

Saidi R, Arch Surg 2009

36

© Copyright. Society of Diagnostic Medical Sonography. All Rights Reserved.

Multiple Renal Arteries

- No difference in complications
  - RAS rate (2.8% vs 3.2%)
- No difference in allograft survival
- Last 100 cases had 16% with multiple arteries

Saidi R, Arch Surg 2009

37

Multiple Renal Arteries

- 718 renal transplants from 1998-2007
- Slightly higher RAS rate (8% vs 6%)
- Delayed graft function in multiple
- No difference in other complications
- No difference in one year survival

Kamali K, Saudi J Kid Dis Transpl

38

© Copyright. Society of Diagnostic Medical Sonography. All Rights Reserved.

Case

When Things Go *Really* Bad

Arterial Occlusion

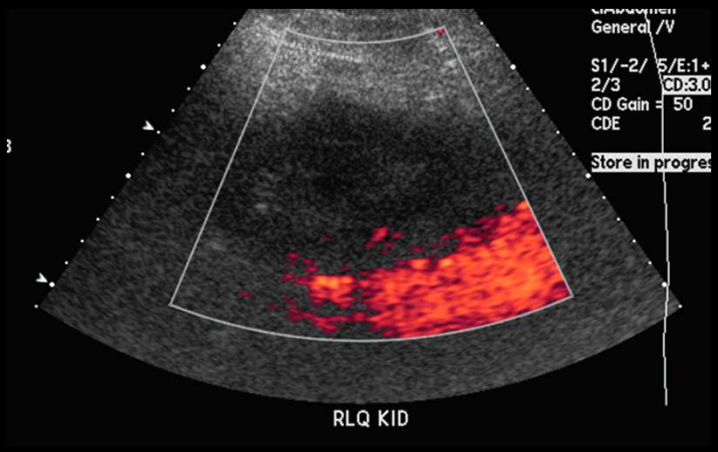

39

Renal Artery Thrombosis

- Rare complication <1%
- Occurs early after surgery
- Leads almost invariably to graft loss

Hyperacute/acute rejection
Surgical technique
Stenosis or vascular kink
Hypotension
Hypercoagulable states / emboli
Cyclosporine toxicity

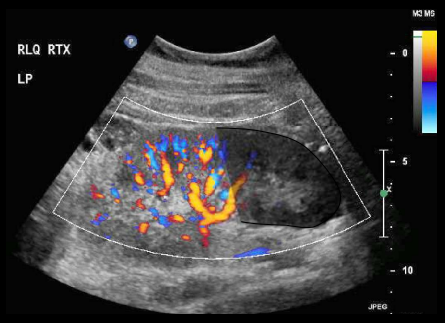

40

© Copyright. Society of Diagnostic Medical Sonography. All Rights Reserved.

Case

Renal Vein Thrombosis

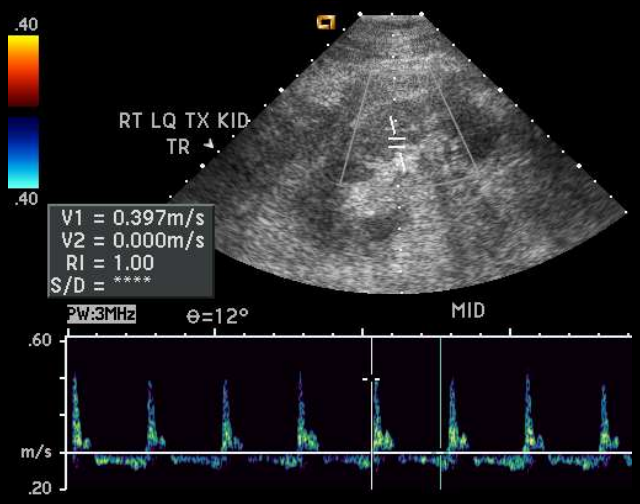

41



42

© Copyright. Society of Diagnostic Medical Sonography. All Rights Reserved.

Etiology of RDF (n=59)

• Rejection	30
• ATN	16
• RVT	5
• Hematoma	3
• Glomerulosclerosis	3
• Cardiac Output Abn	1
• Vascular kink	1

Lockhart AJR 2007

43

Failure Rate in RDF

• Long-term Rejection	73%
• Acute Rejection	27%
• RVT	80%
• Glomerulosclerosis	67%
• ATN	0%
• Hematoma/Kink	0%

Lockhart AJR 2007

44

© Copyright. Society of Diagnostic Medical Sonography. All Rights Reserved.

Case

Hydronephrosis

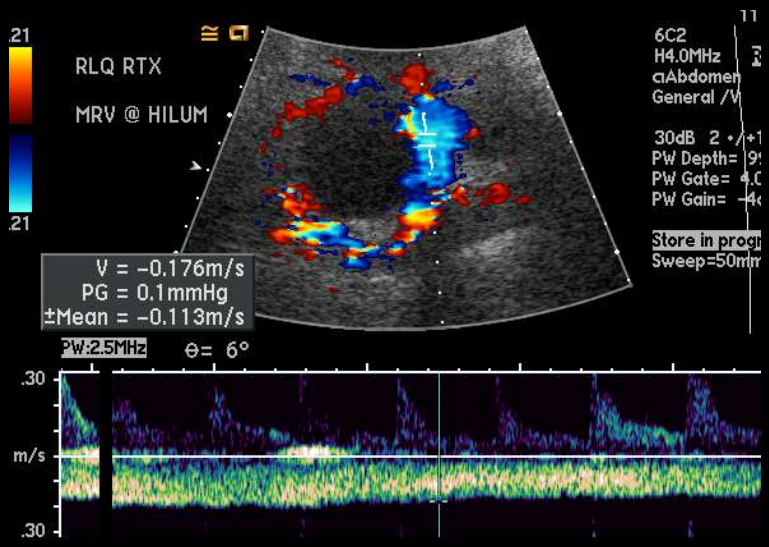

45

Transplant Ureter Stone

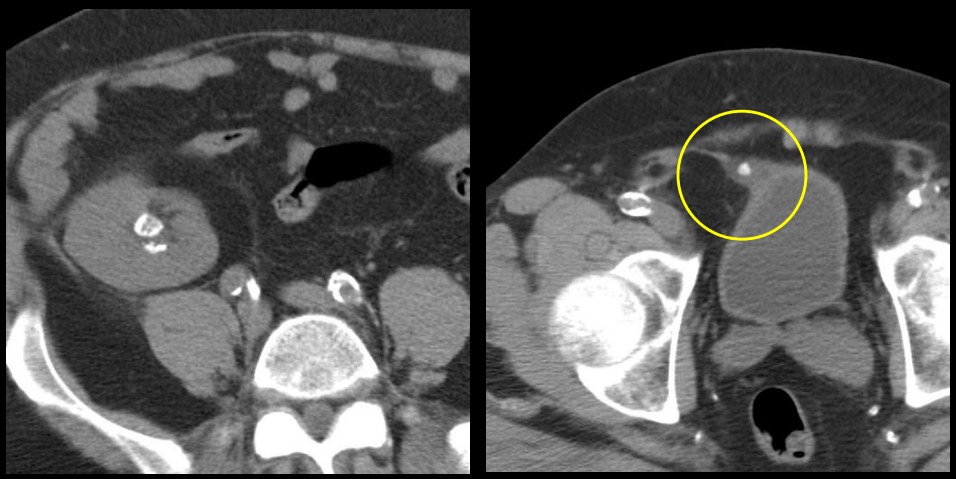

Denervated kidney may not have classic renal colic

46

© Copyright. Society of Diagnostic Medical Sonography. All Rights Reserved.

Different patient

Ureter Insertion on Ultrasound

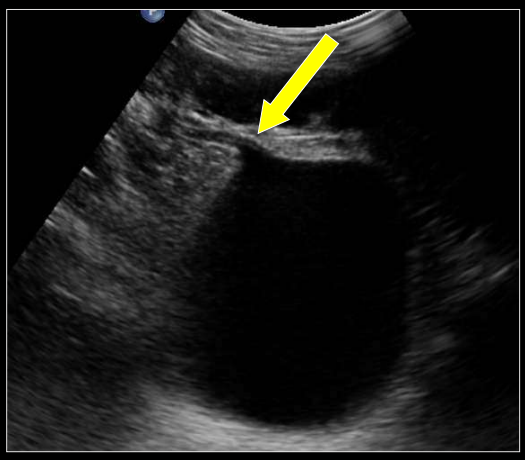

47

Risk of Gifted Stones

- 44 of 710 donated kidneys contained stones
- 86% were 1-2 mm; 14% were 3-6 mm
- Mean follow-up of 21 months
  - None developed obstruction
  - Of 13 with CT, stones larger in 4 patients
  - One stone grew from 1 mm to 8 mm

48

© Copyright. Society of Diagnostic Medical Sonography. All Rights Reserved.

Case

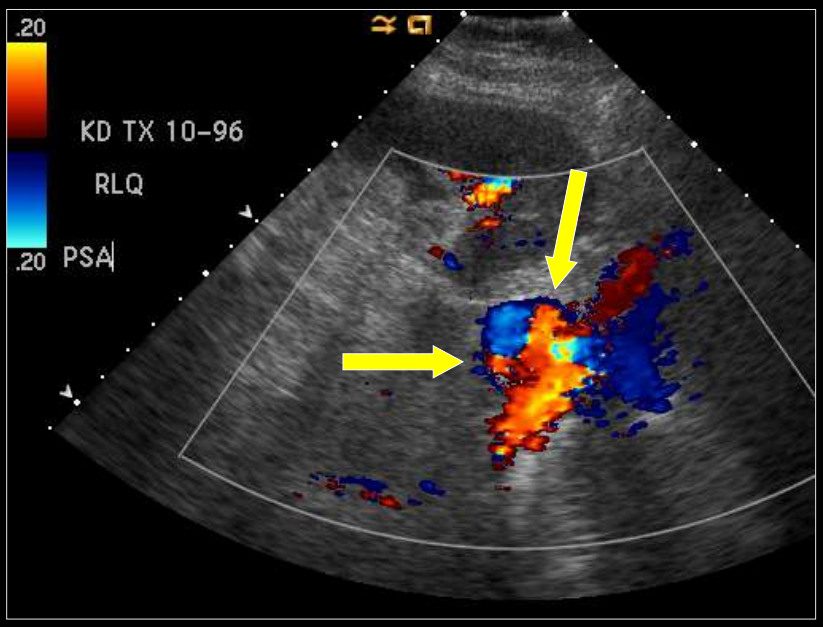

49

Renal Pseudoaneurysm

- Most common at anastomosis
- May be related to surgical technique
- Associated with infection

50

© Copyright. Society of Diagnostic Medical Sonography. All Rights Reserved.

Case

Renal Vein Stenosis

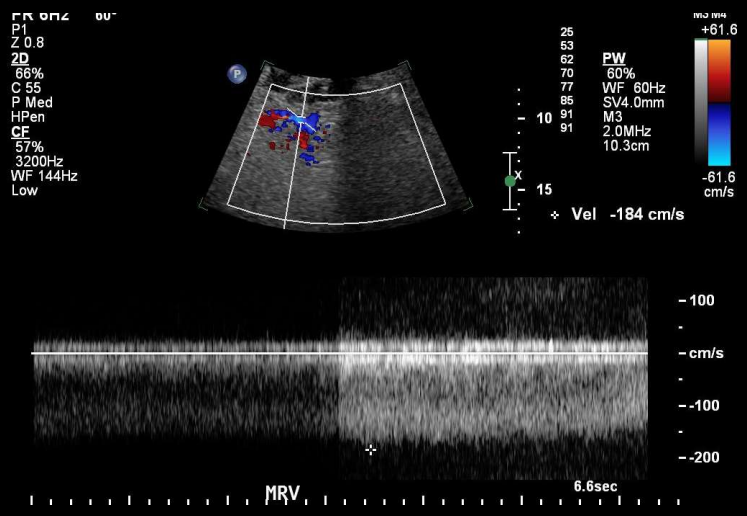

51

Renal Vein Stenosis

- Secondary to perivascular fibrosis or mass effect
- High velocities are seen as areas of color aliasing on color Doppler
  - Lower limits of 3 to 4 fold increase in velocity relative to upstream flow

Tublin 1995

52

© Copyright. Society of Diagnostic Medical Sonography. All Rights Reserved.

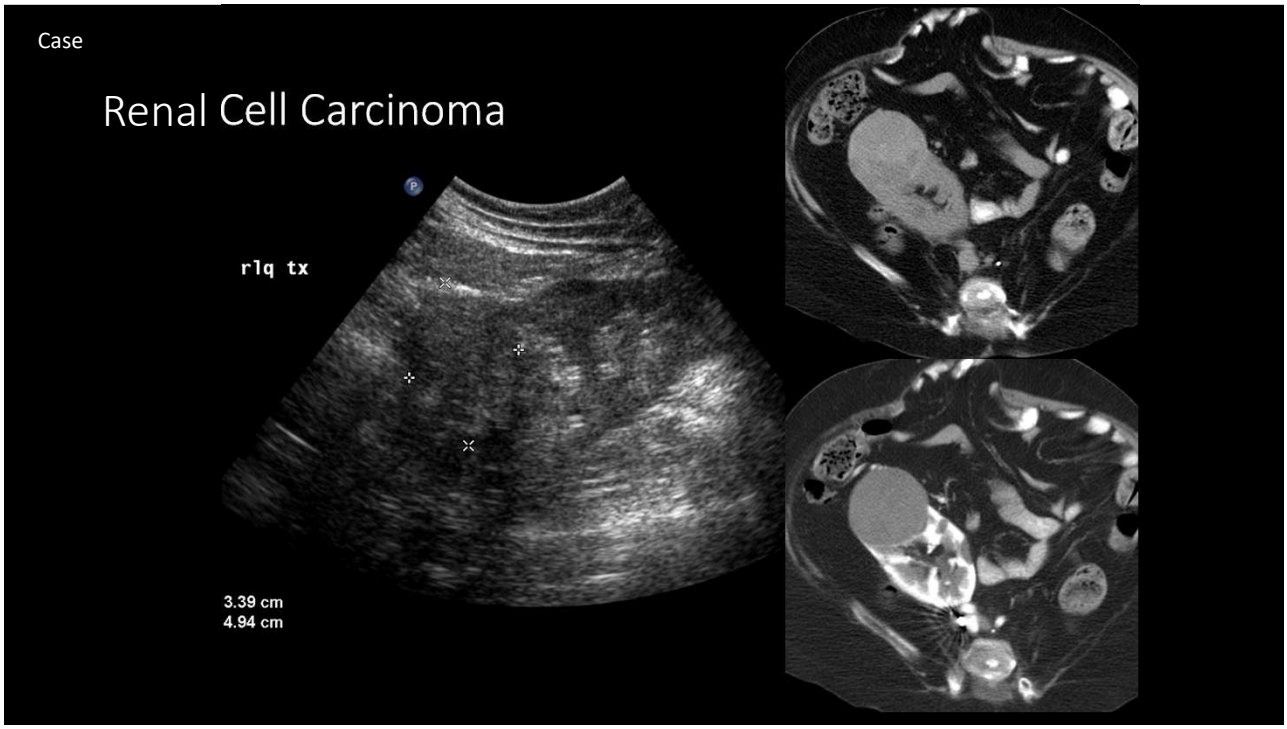

53

Neoplasms

- 175,732 Transplant patients 1987-2008
  - At least some increase in 32 cancer types
  - Highest for kaposi, skin, and lip cancer
- Renal Transplant in 58%
  - 6.66 fold risk of renal cancer
    - Bimodal at 1 year and years 4-15
  - 6.05 fold risk of non-Hodgkins lymphoma
  - 1.46 fold risk of lung cancer

Engels JAMA 2011

54

© Copyright. Society of Diagnostic Medical Sonography. All Rights Reserved.

Hepatic

55

Case

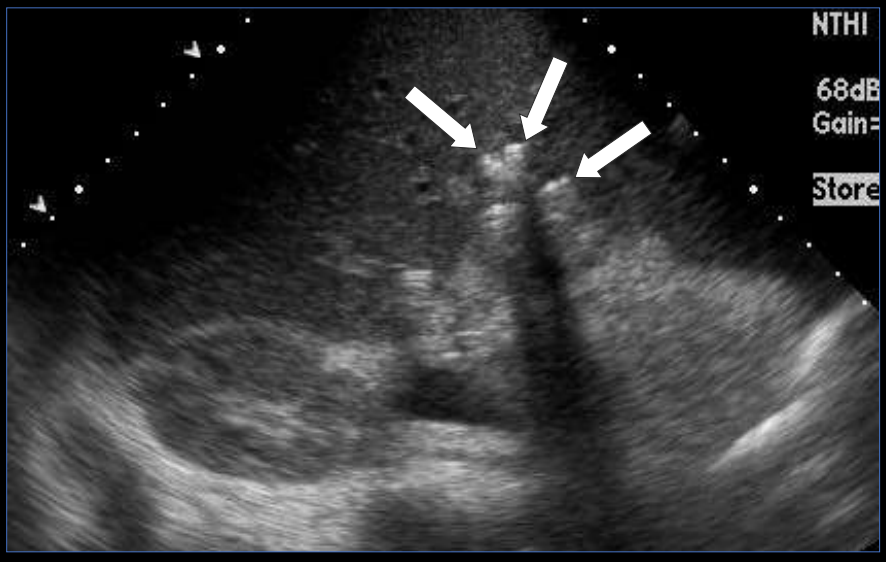

Bile ducts solely supplied by hepatic artery

56

© Copyright. Society of Diagnostic Medical Sonography. All Rights Reserved.

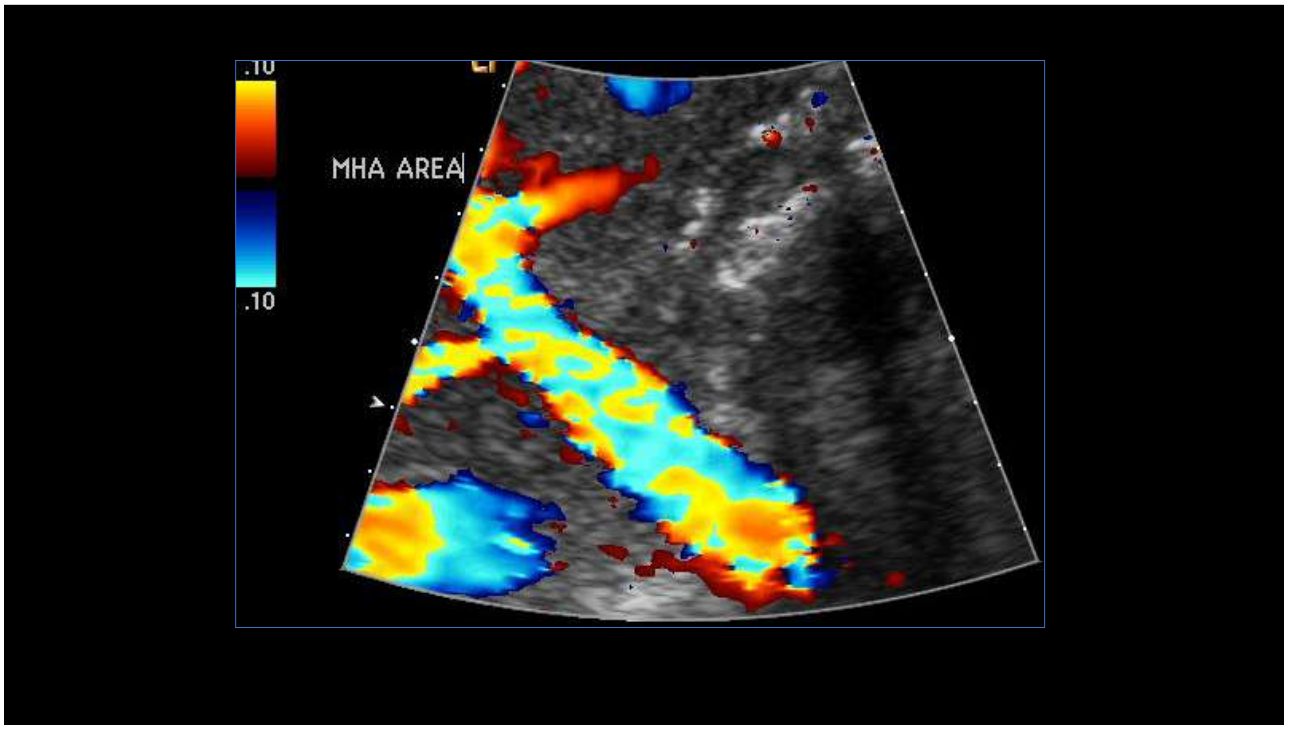

57

Hepatic Artery Thrombosis

- Most common vascular complication
  4-12% adults; 42% peds
- Risk factors
  - Increased cold ischemic time
  - ABO blood type incompatability
  - Small sized vessels in peds
  - Rejection

Wozney AJR 1986; Langas AmJSurg 1991

58

© Copyright. Society of Diagnostic Medical Sonography. All Rights Reserved.

Hepatic Artery Thrombosis

- Doppler correct 92%
  - Absence of proper hepatic and intrahepatic arterial flow
  - Absent arterial flow at porta with intrahepatic parvus tardus

Collaterals form within 6 months from Roux loop or diaphragm

Flint AJR 1988

59

Hepatic Artery Thrombosis

Associated with:

- Bilomas
- Hepatic infarcts
- Abscesses

Flint AJR 1988

60

© Copyright. Society of Diagnostic Medical Sonography. All Rights Reserved.

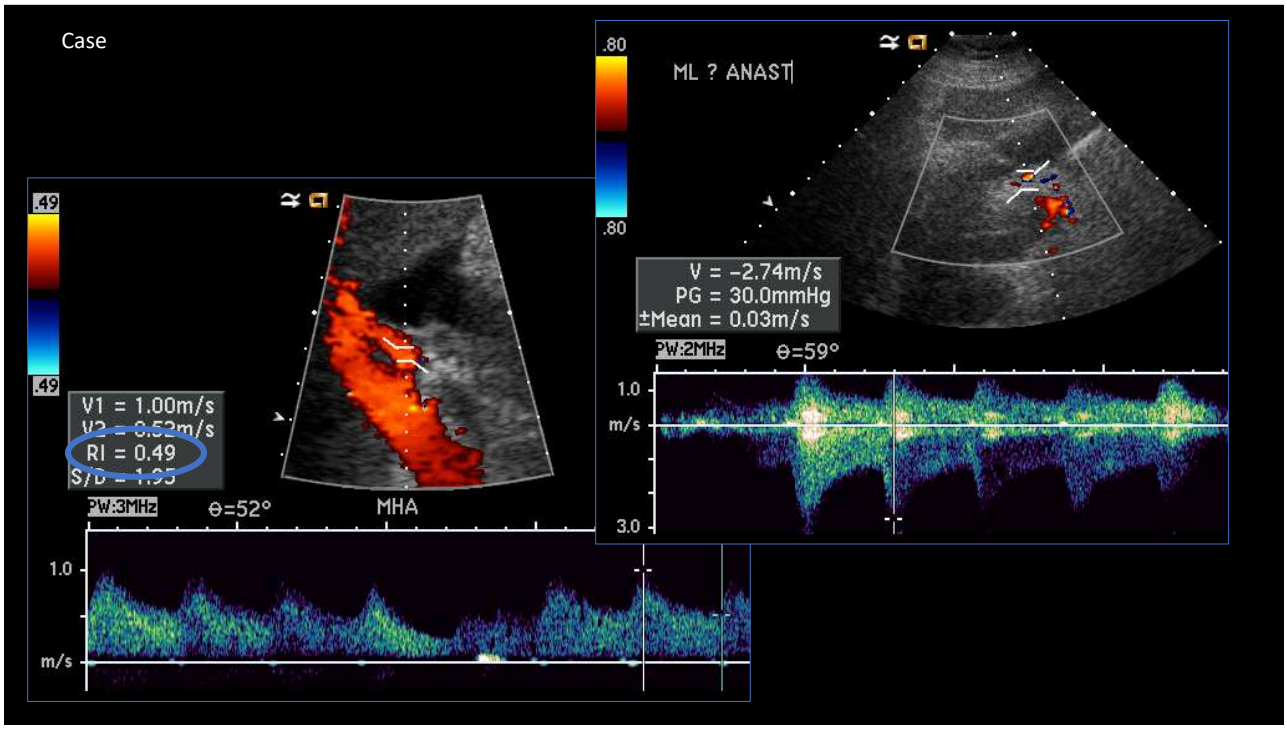

61

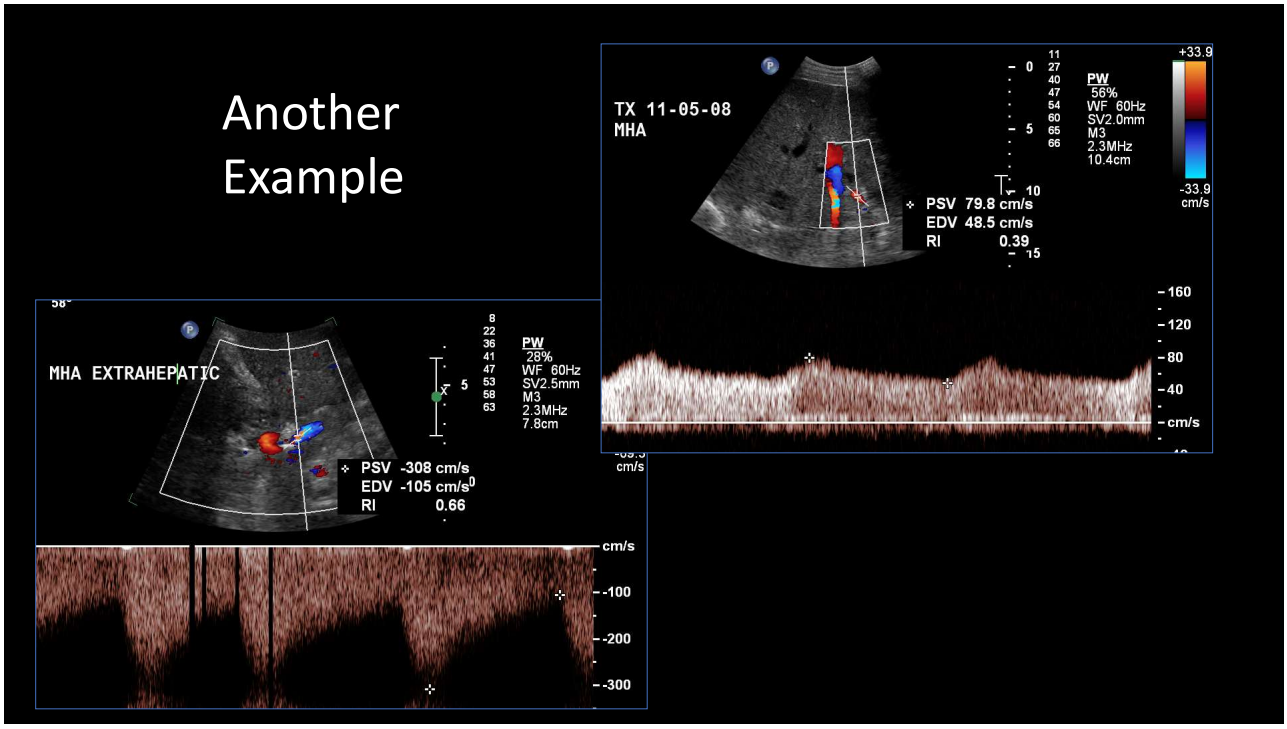

62

© Copyright. Society of Diagnostic Medical Sonography. All Rights Reserved.

Hepatic Artery Stenosis

- Doppler findings
  - Focal accelerated velocity
  - Aliasing
  - Post stenotic turbulence
  - Parvus tardus waveform

Dodd Radiol 1994

63

Hepatic Artery Stenosis

- Occur in 11% of liver transplant
- Etiologies
  - Surgical technique
  - Clamp injury
  - Intimal trauma from perfusion cannulas
  - Disrupted vasa vasorum
  - Rejection

Dodd Radiol 1994

64

© Copyright. Society of Diagnostic Medical Sonography. All Rights Reserved.

Case

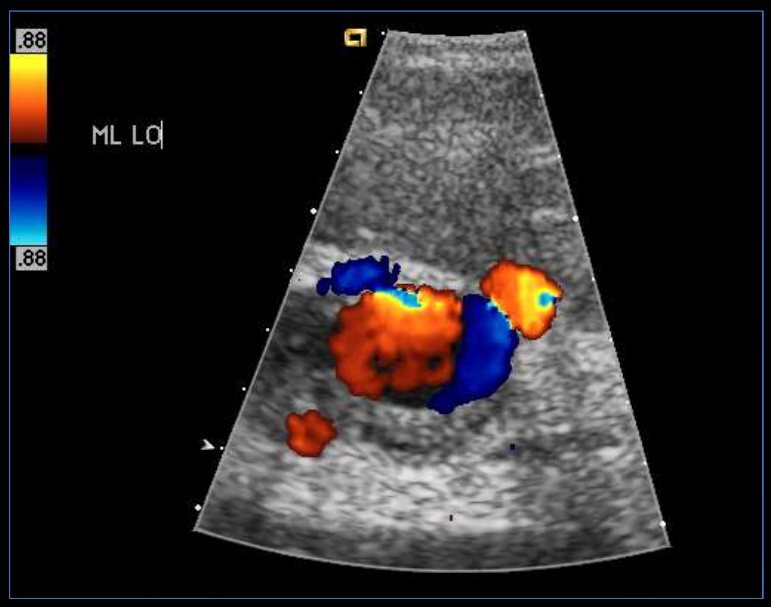

65

Hepatic Artery Pseudoaneurysm

- 0.9-2.6% post transplant
- Rare but potentially fatal hemorrhage
- Most occur at anastomotic site
- May be complication of:
  - Biopsy
  - Biliary intervention
  - Infection

Fistouris Trans Proc 2006; Zajko Trans Proc 1989

66

© Copyright. Society of Diagnostic Medical Sonography. All Rights Reserved.

Case

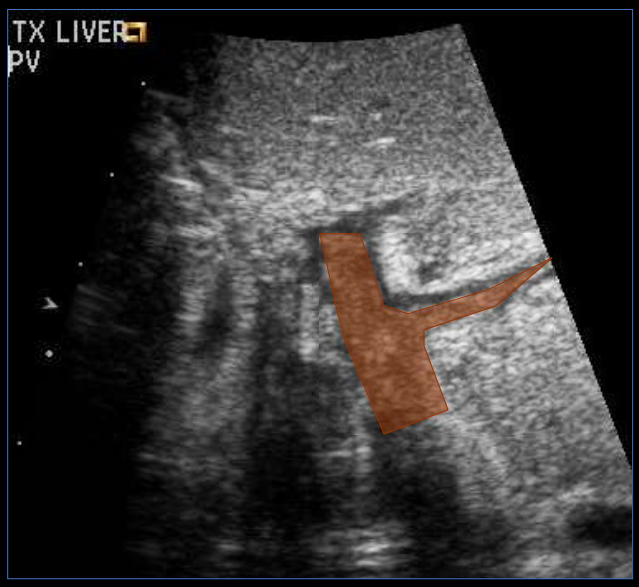

67

Portal Vein Complications

- 1-6% liver transplant patients
- Etiologies
  - Surgical technique
  - Vessel misalignment
  - Excessive vessel length
  - Hypercoagulable state
  - Portal venous bypass cannula
  - Previous portal venous surgery

Langnas Am J Surg 1991; Wozney AJR 1986

68

© Copyright. Society of Diagnostic Medical Sonography. All Rights Reserved.

Portal Vein Complications

- Clinical presentation
  - Portal hypertension
  - Hepatic failure
  - Massive ascites
  - Edema
- Gray-scale US
  - Echogenic luminal thrombus
  - Portal vein narrowing

69

Portal Vein Complications

- Doppler US
  - No detectable flow in thrombosis
  - Focal color aliasing with increased flow velocity at site of narrowing relative to pre-stenotic segment

70

© Copyright. Society of Diagnostic Medical Sonography. All Rights Reserved.

Case

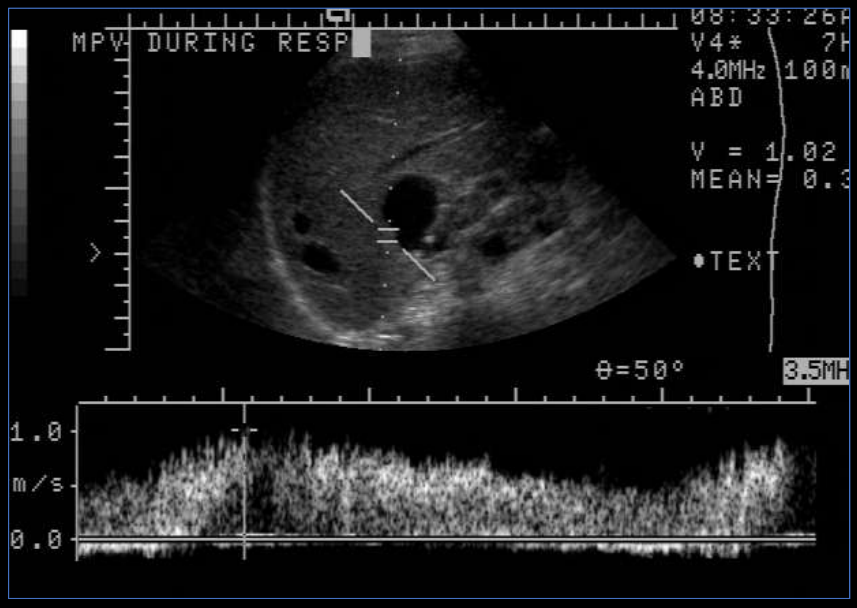

71

Portal Vein Stenosis

- Visualized diameter < 2.5 mm
- Portal hypertension
- PSV > 150 cm/sec
- Ratio > 4:1 compared to upstream
- Post-stenotic dilatation

Chardot Liver Tx Surg 2007; Zajko Trans Proc 2003

72

© Copyright. Society of Diagnostic Medical Sonography. All Rights Reserved.

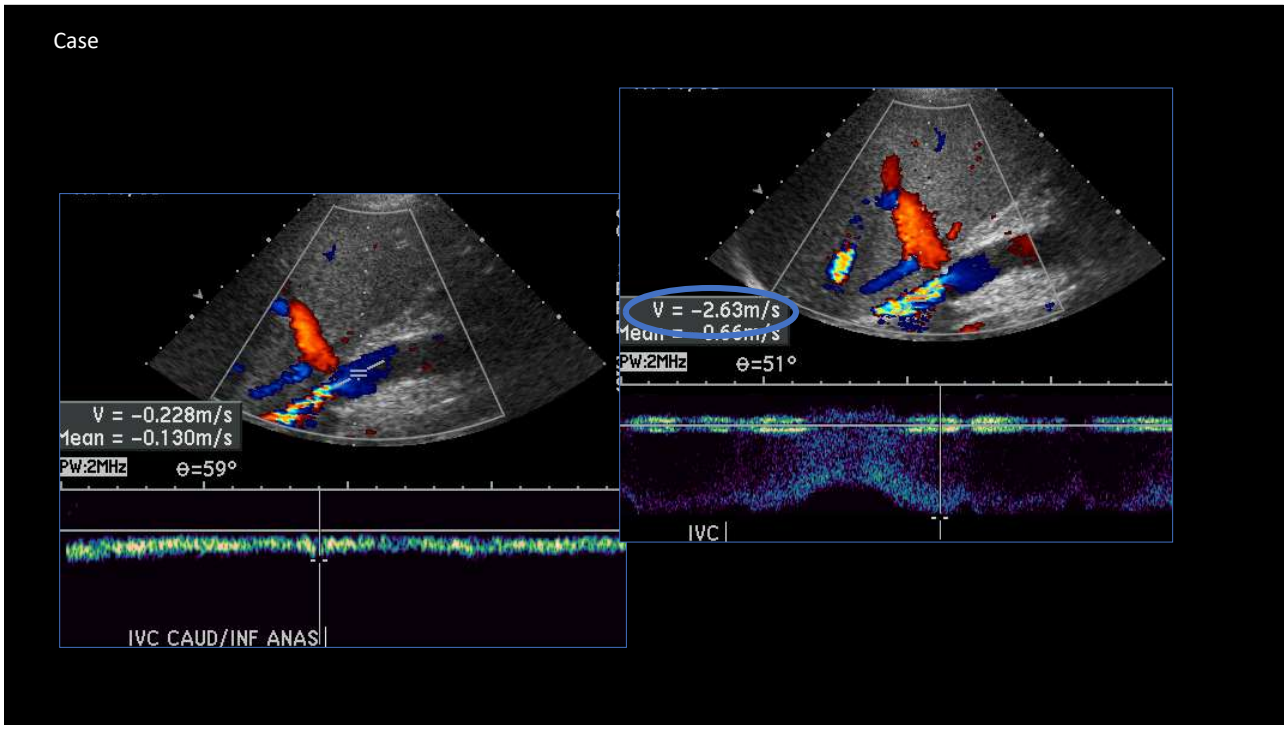

73

IVC Complications

- Spectral Doppler
  - Increased velocity (3-4:1) through stenosis relative to pre-stenotic segment
  - Loss of normal caval phasicity
  - Reversal of flow in hepatic veins
  - Absence of phasicity in hepatic venous waveform

Pfammatter AJR 1997; Rossi Radiol 1993

74

© Copyright. Society of Diagnostic Medical Sonography. All Rights Reserved.

Pancreas

75

Allograft Dysfunction

- Pancreatitis
  - 10%
  - US hypoechogenicity+/- fluid collections
- Necrosis
  - Lack of venous and arterial flow with echogenicity suggestive of gas
- Rejection
- Fistula

76

© Copyright. Society of Diagnostic Medical Sonography. All Rights Reserved.

Bowel Complications

- Small bowel obstruction
  - Adhesive disease 5%
  - Internal hernia 3%
- Anastomotic leak

77

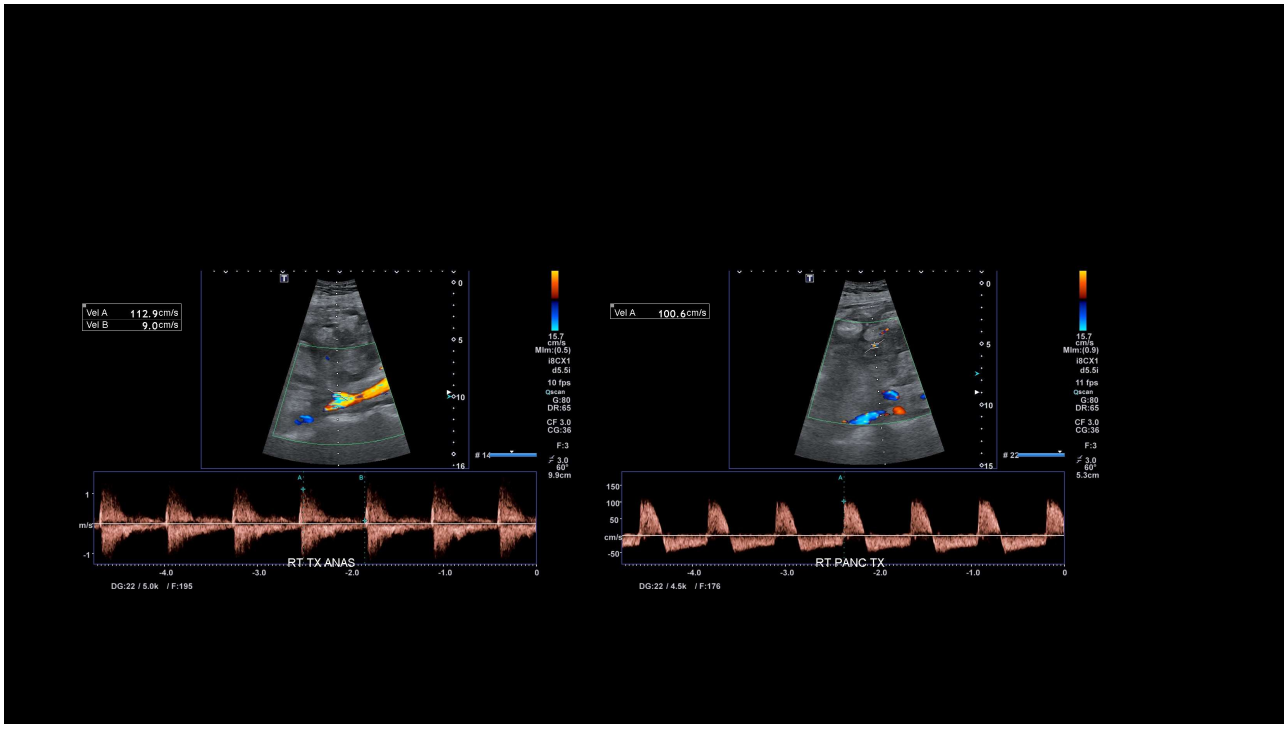

78

© Copyright. Society of Diagnostic Medical Sonography. All Rights Reserved.

Case

Venous Thrombosis

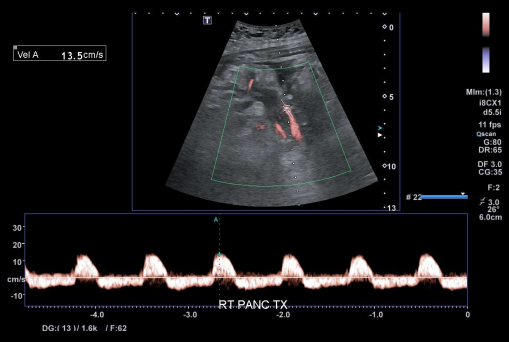



79

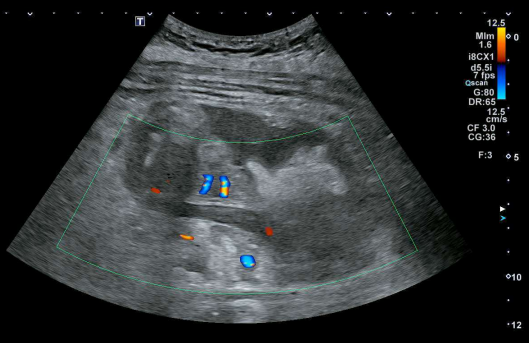

80

© Copyright. Society of Diagnostic Medical Sonography. All Rights Reserved.

Vascular Complications

- Venous thrombosis 4.8%
  - US
    - Lack of arterial or venous flow within the graft
    - Echogenic thrombus within a vessel
    - Reversal of diastolic flow in pancreas artery

81

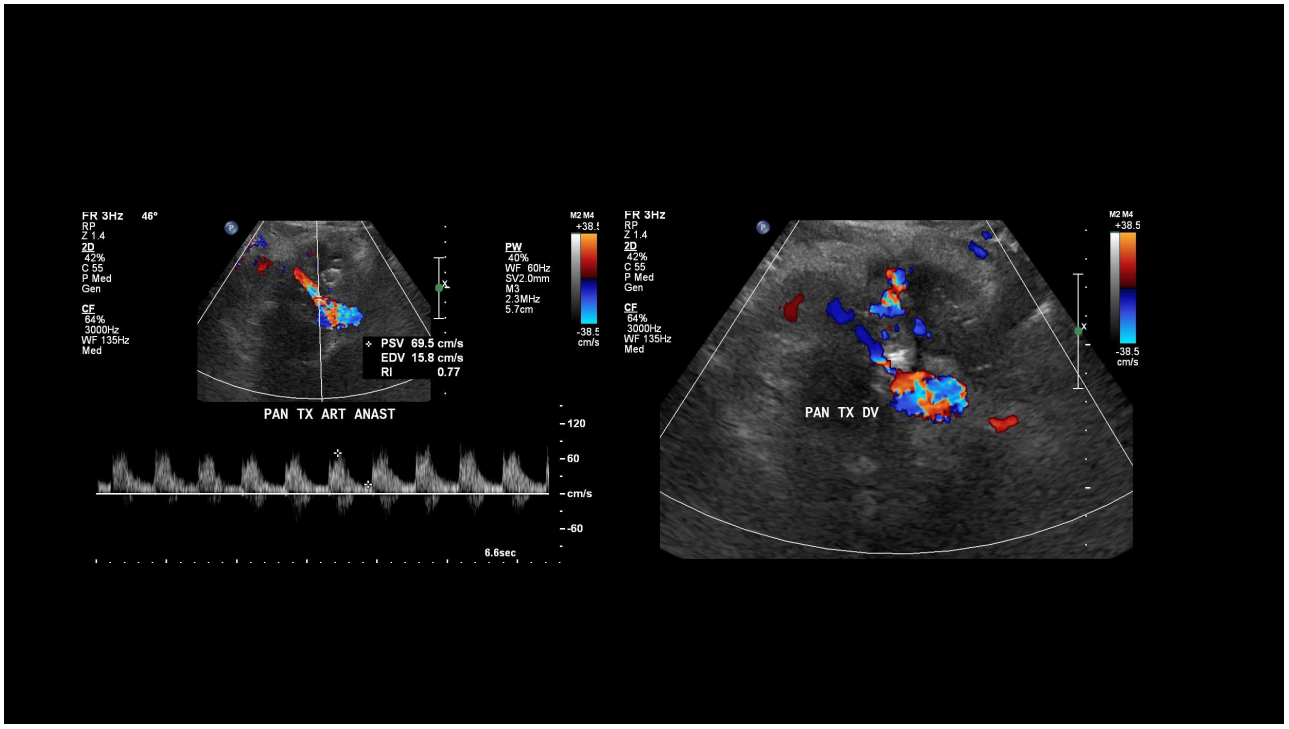

82

© Copyright. Society of Diagnostic Medical Sonography. All Rights Reserved.

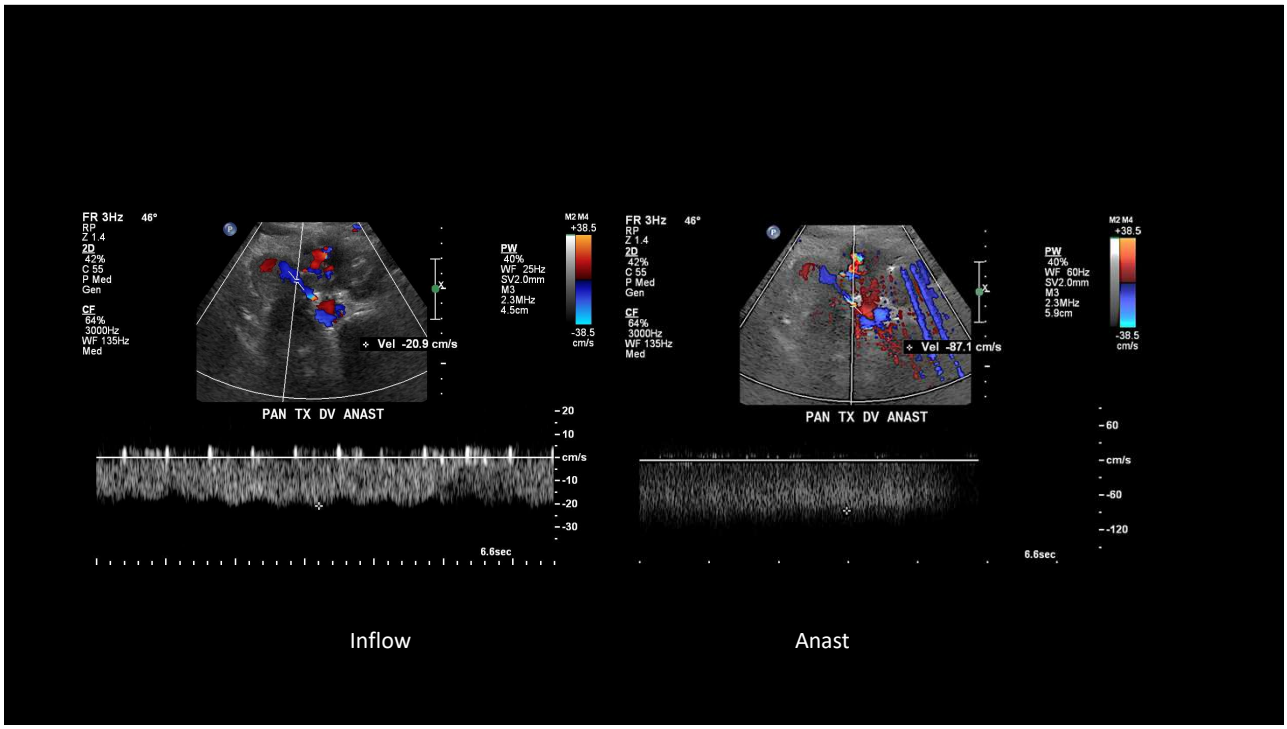

83

Draining Vein Stenosis

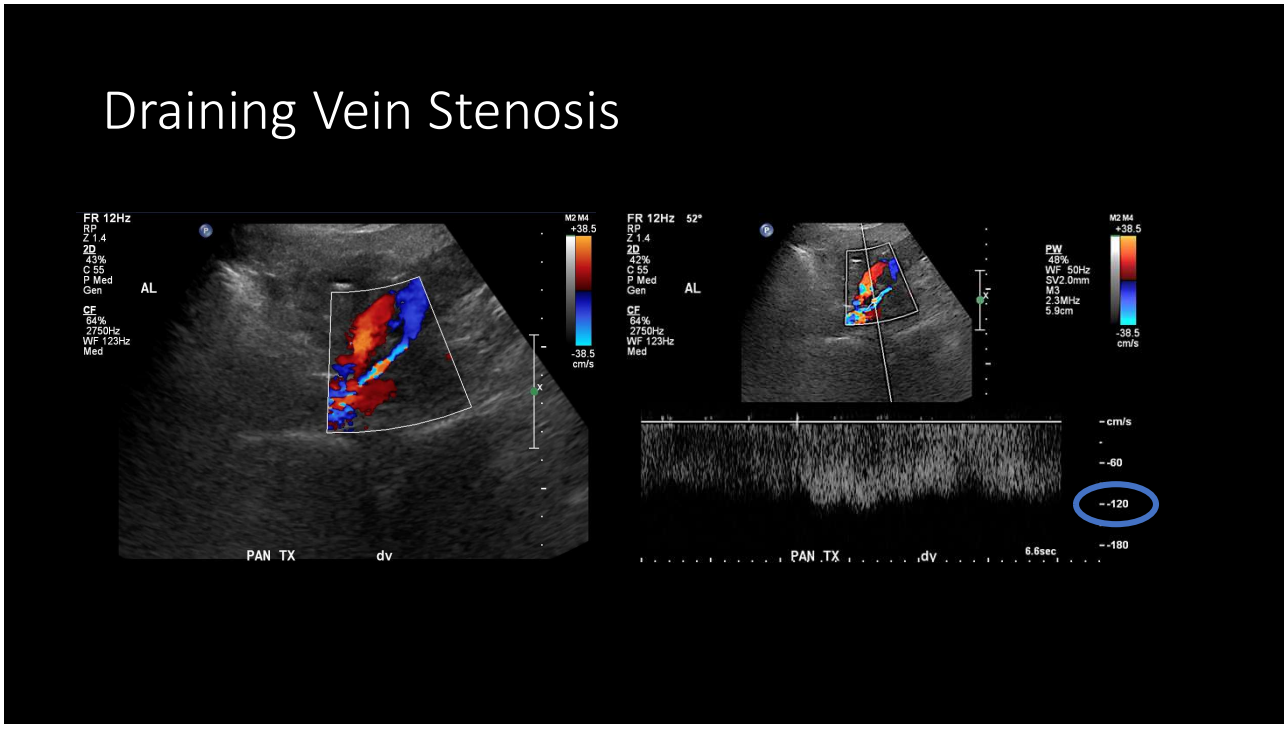

84

© Copyright. Society of Diagnostic Medical Sonography. All Rights Reserved.

Summary

- There are a wide range of abnormalities in transplant allografts
- Knowledge of the Doppler findings and criteria is crucial

85

Selected References

- Datta R, Sandhu M, Saxena AK, Sud K, Minz M, Suri S. Role of duplex Doppler and power Doppler sonography in transplanted kidneys with acute renal parenchymal dysfunction. Australas Radiol. 2005 Feb;49(1):15-20. doi: 10.1111/j.1440-1673.2005.01350.x. PMID: 15727604.
- Krumme B. Renal Doppler sonography--update in clinical nephrology. Nephron Clin Pract. 2006;103(2):c24-8. doi: 10.1159/000090605. Epub 2006 Mar 10. PMID: 16543752.
- Heine GH, Gerhart MK, Ulrich C, Köhler H, Girndt M. Renal Doppler resistance indices are associated with systemic atherosclerosis in kidney transplant recipients. Kidney Int. 2005 Aug;68(2):878-85. doi: 10.1111/j.1523-1755.2005.00470.x. PMID: 16014069.
- Radermacher J, Mengel M, Ellis S, Stuht S, Hiss M, Schwarz A, Eisenberger U, Burg M, Luft FC, Gwinner W, Haller H. The renal arterial resistance index and renal allograft survival. N Engl J Med. 2003 Jul 10;349(2):115-24. doi: 10.1056/NEJMoa022602. PMID: 12853584.
- Lockhart ME, Robbin ML. Renal vascular imaging: ultrasound and other modalities. Ultrasound Q. 2007 Dec;23(4):279-92. doi: 10.1097/ruq.0b013e31815adf4c. PMID: 18090838.
- Thalhammer C, Aschwanden M, Mayr M, Koller M, Steiger J, Jaeger KA. Duplex sonography after living donor kidney transplantation: new insights in the early postoperative phase. Ultraschall Med. 2006 Apr;27(2):141-5. doi: 10.1055/s-2006-926560. PMID: 16612723.
- Polak WG, Jezior D, Garcarek J, Chudoba P, Patrzałek D, Boratyńska M, Szyber P, Klinger M. Incidence and outcome of transplant renal artery stenosis: single center experience. Transplant Proc. 2006 Jan-Feb;38(1):131-2. doi: 10.1016/j.transproceed.2005.11.097. PMID: 16504683.
- Bruno S, Remuzzi G, Ruggenenti P. Transplant renal artery stenosis. J Am Soc Nephrol. 2004 Jan;15(1):134-41. doi: 10.1097/01.asn.0000099379.61001.f8.
- PMID: 14694165.
- Patel U, Khaw KK, Hughes NC. Doppler ultrasound for detection of renal transplant artery stenosis-threshold peak systolic velocity needs to be higher in a low-risk or surveillance population. Clin Radiol. 2003 Oct;58(10):772-7. doi: 10.1016/s0009-9260(03)00211-3. PMID: 14521886.
- Saidi R, Kawai T, Kennealey P, Tsouflas G, Elias N, Hertl M, Cosimi AB, Ko DS. Living donor kidney transplantation with multiple arteries: recent increase in modern era of laparoscopic donor nephrectomy. Arch Surg. 2009 May;144(5):472-5. doi: 10.1001/archsurg.2009.49. PMID: 19451491.
- Engels EA, Pfeiffer RM, Fraumeni JF Jr, Kasiske BL, Israni AK, Snyder JJ, Wolfe RA, Goodrich NP, Bayakly AR, Clarke CA, Copeland G, Finch JL, Fleissner ML, Goodman MT, Kahn A, Koch L, Lynch CF, Madeleine MM, Pawlish K, Rao C, Williams MA, Castenson D, Curry M, Parsons R, Fant G, Lin M. Spectrum of cancer risk among US solid organ transplant recipients. JAMA. 2011 Nov 2;306(17):1891-901. doi: 10.1001/jama.2011.1592. PMID: 22045767; PMCID: PMC3310893.
- Fistouris J, Herlenius G, Bäckman L, Olausson M, Rizell M, Mjörnstedt L, Friman S. Pseudoaneurysm of the hepatic artery following liver transplantation. Transplant Proc. 2006 Oct;38(8):2679-82. doi: 10.1016/j.transproceed.2006.07.028. PMID: 17098038.

86

© Copyright. Society of Diagnostic Medical Sonography. All Rights Reserved.



87

© Copyright. Society of Diagnostic Medical Sonography. All Rights Reserved.