3D Quantification of Mitral Regurgitation: Accurate Vena Contracta Area (VCA) Measurement

Meredith Ott, MBA, ACS, RCCS, RDCS (AE, PE)
Cardiac Sonographer III
Orlando Regional Medical Center
Orlando, Florida

1

SPEAKER PRESENTATION DISCLAIMER

The content and views presented are made available for educational purposes only. The information presented are the opinions of the presenter and do not necessarily represent the views of the Society of Diagnostic Medical Sonography (SDMS) or its affiliated organizations, officers, Boards of Directors, or staff members.

The presenter is responsible for ensuring balance, independence, objectivity, scientific rigor, and avoiding commercial bias in their presentation. Before making the presentation, the presenter is required to disclose to the audience any relevant financial interests or relationships with manufacturers or providers of medical products, services, technologies, and programs.

The SDMS and its affiliated organizations, officers, Board of Directors, and staff members disclaim any and all liability for all claims that may arise out of the use of this educational activity.

2

© Copyright. Society of Diagnostic Medical Sonography. All Rights Reserved.

RESEARCH DISCLAIMER

The information presented in this presentation is based on research conducted to the best of the presenters' abilities and knowledge. Research involves uncertainty and is subject to limitations. The findings and conclusions presented herein may be influenced by various factors including but not limited to data quality, methodology, assumptions, and interpretation.

Research outcomes may not always accurately predict real-world scenarios or future events. While the presenter may make efforts to ensure the accuracy and reliability of the information presented, completeness or absolute correctness is not guaranteed. This presentation is intended for informational purposes only and should not be construed as professional advice. Participants are encouraged to independently verify any information provided and consult relevant experts or professionals where appropriate.

The SDMS and its affiliated organizations, officers, Board of Directors, and staff members disclaim any and all liability for all claims that may arise out of the use of this educational activity.

3

GENERATIVE AI DISCLAIMER

The presenter utilized the use of large language models (LLMs) and generative artificial intelligence (AI) as a productivity tool to assist in drafting and refining content in this presentation.

While these tools can aid in structuring ideas, summarizing, paraphrasing, and language polishing, they have inherent limitations and cannot replace human creativity, critical thinking, or expert judgment. AI-generated content may contain errors, biases, or gaps in knowledge.

This presentation is intended for informational purposes only and should not be construed as definitive or authoritative guidance. Participants are encouraged to critically evaluate the information presented and consult relevant experts as needed. The SDMS and its affiliated organizations, officers, Board of Directors, and staff members disclaim any and all liability for claims that may arise from the use or interpretation of this educational material.

4

© Copyright. Society of Diagnostic Medical Sonography. All Rights Reserved.

Agenda

- 1. The 2D Toolkit — why standard methods break down in real-world MR
- 2. Enter the Third Dimension — vena contracta physics and the case for area over width
- 3. The Evidence Base — validation against PISA, CMR, prognosis, and reproducibility
- 4. Acquisition — getting a measurable 3D color dataset the first time
- 5. The Measurement Workflow — a reproducible, step-by-step protocol for 3D VCA
- 6. Pitfalls & Troubleshooting — recognizing and avoiding the errors that undermine accuracy
- 7. Putting It Into Practice — etiology pearls, a case vignette, and where this is headed

5

Learning Objectives

Explain the Rationale

Articulate why area-based 3D VCA outperforms 2D width and PISA in non-circular, eccentric, and multi-jet MR.

Optimize Acquisition

Tune modality, beat mode, frame rate, and color Doppler settings to capture a measurable dataset.

Perform the Measurement

Execute the MPR workflow to isolate the en-face plane and planimeter the vena contracta.

Avoid the Pitfalls

Recognize stitching artifacts, blooming, and timing errors before they compromise a result.

6

© Copyright. Society of Diagnostic Medical Sonography. All Rights Reserved.

Why This Matters

2–3%

of the general population

has at least moderate-to-severe mitral regurgitation — the most common significant valve lesion seen in echo labs.

#1

imaging-dependent decision

Surgical and transcatheter referral hinges directly on the severity grade your lab reports.

↓

intervention thresholds

Durable transcatheter options have lowered the bar for treatment — small grading errors now carry larger consequences.

7

The Clinical Stakes

Primary (degenerative) MR: driven by structural leaflet or chordal pathology — prolapse, flail, chordal rupture — with severity grading that directly informs surgical timing.

Secondary (functional) MR: driven by LV or annular remodeling with structurally normal leaflets — grading is harder, and the coaptation defect is rarely circular.

Transcatheter edge-to-edge repair now benefits high-risk primary MR patients and a select group of severely symptomatic secondary MR patients on optimal heart failure therapy.

Every one of these referral decisions rests on a quantitative severity grade — measurement accuracy is a direct patient-outcome variable, not an academic exercise.



8

© Copyright. Society of Diagnostic Medical Sonography. All Rights Reserved.

The Guideline Framework

ASE and EACVI both recommend an integrative, multiparametric approach to grading native valvular regurgitation — no single measurement is sufficient on its own.

Qualitative and semi-quantitative signs (jet area, vena contracta width, valve morphology, PW/CW Doppler patterns) are combined with quantitative parameters.

Quantitative parameters — effective regurgitant orifice area (EROA), regurgitant volume, and regurgitant fraction — carry the most weight when feasible.

3D echocardiography and cardiac MRI were added as supplemental tools precisely because 2D methods have well-documented blind spots — the subject of this section.



9

The 2D Toolkit — and Where It Breaks Down

A quick recap of the standard quantitative arsenal, and the specific clinical scenarios where its underlying assumptions start to fail.

10

© Copyright. Society of Diagnostic Medical Sonography. All Rights Reserved.

The Standard 2D Arsenal

Parameter	What It Measures	Key Assumption
Vena contracta width	Narrowest diameter of the jet in one 2D plane	The orifice is symmetric enough that one diameter represents it
PISA / EROA	Effective regurgitant orifice area from flow convergence	The proximal isovelocity surface is a perfect hemisphere; the orifice is circular
Volumetric method	Regurgitant volume from stroke volume differences	Accurate, non-overlapping annular and outflow tract measurements
Jet area (color Doppler)	Spatial extent of the jet in the receiving chamber	Jet area scales predictably with regurgitant severity

Every method above compresses a three-dimensional flow problem into a 2D measurement — which is exactly where the trouble starts.

11

Where 2D Fails

Non-Circular Orifices

Functional MR coaptation defects are frequently elliptical or crescentic — a method built on a circular assumption systematically misjudges the area.

Eccentric Jets

Jets that hug the atrial wall (Coanda effect) distort jet-area assessment and make an on-axis 2D cut plane difficult to guarantee.

Multiple Jets

Bileaflet prolapse or multiple functional regurgitant orifices mean a single 2D measurement plane cannot capture total regurgitant burden.

12

© Copyright. Society of Diagnostic Medical Sonography. All Rights Reserved.

PISA's Built-In Assumption

What PISA Assumes



A single radius (r) defines a perfect circle

What the Orifice Often Looks Like

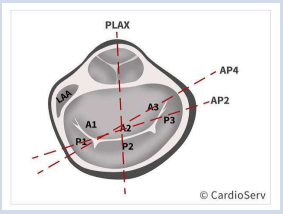

Elliptical, crescentic, or multiple orifices — a single radius under- or overestimates true area

13

Enter the Third Dimension

The physical basis of the vena contracta, and why measuring its true cross-sectional area — not a single diameter — changes the accuracy equation.

14

© Copyright. Society of Diagnostic Medical Sonography. All Rights Reserved.

The Vena Contracta, Defined

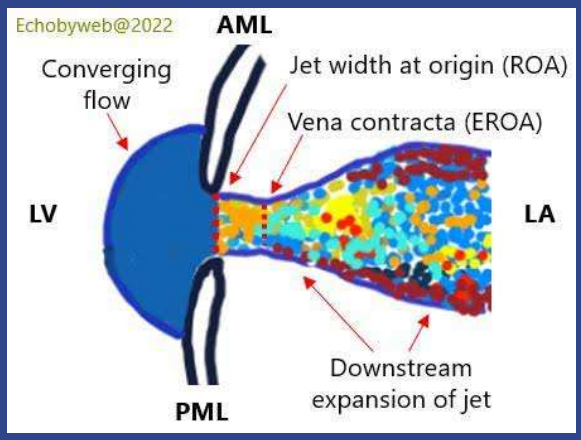

Governed by free-jet theory — only slightly smaller than the true anatomic orifice, and unlike PISA, it requires no geometric assumption about flow convergence.

15

Introducing 3D Vena Contracta Area

Three-dimensional VCA is the direct planimetry of the jet's narrowest cross-section, captured en face from a 3D color Doppler dataset — an area measurement, not an inferred one.

Because it is measured directly rather than derived from a geometric formula, 3D VCA makes no assumption about the shape of the regurgitant orifice.

It has been shown to remain accurate in exactly the scenarios that defeat 2D PISA: eccentric jets, multiple jets, and non-circular coaptation defects.

The trade-off is acquisition and analysis time, image-quality dependency, and a workflow that takes deliberate practice to execute reproducibly — the focus of the

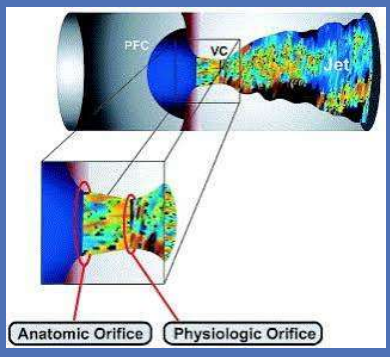

16

© Copyright. Society of Diagnostic Medical Sonography. All Rights Reserved.

The Evidence Base

How 3D VCA holds up against the existing quantitative reference standards — and what it adds in prognostic and reproducibility terms.

17

Validation Against 2D PISA and Anatomic Orifice Area

r = 0.93

correlation with 2D PISA EROA

Across 105 patients with functional MR undergoing TEE (Dresden Mitral Valve Registry).

r = 0.94

correlation with anatomic orifice area

Measured without color Doppler, confirming 3D VCA tracks true anatomy, not just flow signal.

No Δ

with eccentric or multiple jets

Unlike 2D PISA, correlation did not degrade in the jet geometries that typically cause the most error.

Source: Utz et al., "Benefit of 3D Vena Contracta Area Over 2D-Based Echocardiographic Methods in Quantification of Functional Mitral Valve Regurgitation," Diagnostics 2023.

18

© Copyright. Society of Diagnostic Medical Sonography. All Rights Reserved.

Validation Against Cardiac MRI

<1 mL	No Sig. Δ	High
mean difference per beat	**between techniques**	**agreement, low bias**
Between VCA-derived regurgitant volume (VCA × jet time-velocity integral) and CMR-measured regurgitant volume.	Marsan et al. found no statistically significant volume difference across the two independent modalities.	CMR remains a reference standard for regurgitant volume — 3D VCA tracked it closely without a systematic offset.

Source: Marsan NA et al., JACC Cardiovasc Imaging 2009; discussed in Little SH, JACC Cardiovasc Imaging 2012.

19

Prognostic Value

>0.2 cm²	0.99 → 0.22	↑ 6MWD
EROA — excess mortality begins	**cm² VCA reduction post-PMVR**	**functional capacity gained**
Risk climbs steadily above this threshold, with a marked increase beyond 0.4 cm² in functional MR.	Direct 3D VCA planimetry tracked procedural success after percutaneous mitral valve repair.	Greater residual-VCA reduction after repair tracked with improved six-minute walk distance at follow-up.

Sources: Grayburn PA et al. on EROA and mortality; Utz D et al., "3D Vena Contracta Area After MitraClip," Clin Res Cardiol 2018.

20

© Copyright. Society of Diagnostic Medical Sonography. All Rights Reserved.

Guideline-Supported Severity Thresholds

Clinical Context	Severe MR Threshold	Notes
General EROA (ASE/EACVI, 2D PISA)	≥ 0.40 cm^2	The long-standing reference cutoff cited across current guideline documents
3D VCA in functional MR	≥ 0.43 cm^2	Derived cutoff (AUC 0.98) discriminating moderate from severe FMR, Dresden registry
3D VCA in mitral valve prolapse	Etiology-specific cutoff	Distinct validated cutoffs proposed for degenerative MR/MVP populations
Intermediate vena contracta width	3–7 mm	Guidelines flag this range as needing confirmation with a quantitative method

Always interpret any single cutoff within the full multiparametric picture — no one number should grade MR in isolation.

21

Reproducibility Across Observers

0.94

ICC for 3D VCA

Interclass correlation coefficient for interobserver agreement in the Dresden functional MR cohort.

0.81

ICC for 2D PISA EROA

The comparison figure for the conventional method in the same patient cohort.

A tighter spread between observers means more consistent grading and more defensible serial comparisons over time. Source: Utz et al., Diagnostics 2023.

22

© Copyright. Society of Diagnostic Medical Sonography. All Rights Reserved.

Acquisition — Getting the Data Right

No post-processing technique can rescue a poorly acquired 3D color dataset. This is where measurement accuracy is actually won or lost.

23

Choosing Your Approach

Modality: TTE vs. TEE

- TTE is a reasonable first-line approach and has shown VCA values consistent with TEE in cross-platform comparisons.
- TEE offers higher near-field resolution for the mitral apparatus and is often preferred when TTE image quality is limited.
- Choose based on acoustic windows and the clinical question — pre-procedural planning frequently defaults to TEE.

Beat Mode: Single vs. Multi

- Multi-beat (full-volume) stitching improves temporal and spatial resolution but is vulnerable to stitching artifacts from ECG or respiratory motion.
- Single-beat acquisition avoids stitching artifacts entirely and is increasingly preferred, at some cost to volume rate.
- Whichever mode is used, confirm the dataset is free of visible seams before proceeding to measurement.

24

© Copyright. Society of Diagnostic Medical Sonography. All Rights Reserved.

Frame Rate Matters

A median 3D volume rate of approximately 18 Hz has been reported as adequate for reliable VCA measurement in validated protocols.

Volume rate trades directly against spatial resolution and sector size — a wider, deeper color box lowers your frame rate.

Narrow the color sector to the smallest box that still fully contains the jet, and reduce depth to the minimum needed to visualize the vena contracta.

If achievable volume rate falls too low, consider zoom-mode or single-beat acquisition rather than accepting a blurred, temporally averaged jet.

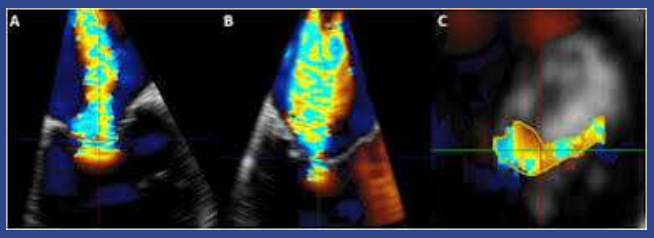

25

Optimizing Color Doppler Settings

Aliasing Velocity

Set the Nyquist limit mid-range so it clearly delineates flow convergence without an over/under-sized color map.

Gain

Reduce gain just until color blooming disappears — excess gain artificially enlarges the apparent orifice.

Sector & Depth

Minimize both to the smallest region that fully contains the jet, protecting your achievable volume rate.

Gating & Breath-Hold

Use ECG gating with an end-expiratory breath-hold for multi-beat capture, or zoom/single-beat mode to sidestep motion.

26

© Copyright. Society of Diagnostic Medical Sonography. All Rights Reserved.

The Measurement Workflow

A reproducible, four-step protocol for turning a well-acquired 3D color dataset into a defensible vena contracta area measurement.

27

From Dataset to Measurement

01

Acquire

Capture the 3D color full-volume dataset per your optimized settings; verify no stitching artifact.

02

Align MPR Planes

Fit two orthogonal long-axis planes along the visible course of the jet, origin to receiving chamber.

03

Find the En-Face Cut

Tilt and translate the third plane until perpendicular to the jet at its narrowest neck.

04

Planimeter

Trace the jet cross-section at early-to-mid systole on the isolated en-face plane; record area in cm^2.

Repeat across two to three cardiac cycles when feasible and average — consistent with the reproducibility gains documented for this method.

28

© Copyright. Society of Diagnostic Medical Sonography. All Rights Reserved.

Aligning the Multiplanar Reconstruction

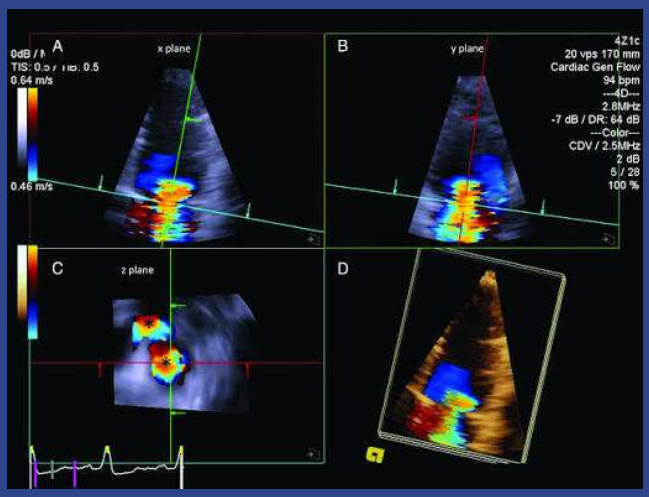

- **Plane 1 & 2**

  Two orthogonal long-axis planes are fitted along the visible course of the color Doppler jet, from origin to receiving chamber.

- **Plane 3**

  A third plane is tilted and translated until it sits perpendicular to the jet at its narrowest point — the en-face cutting plane.

- **Result**

  Plane 3 becomes the short-axis view used for direct planimetry of the vena contracta area.

29

The En-Face View & Planimetry

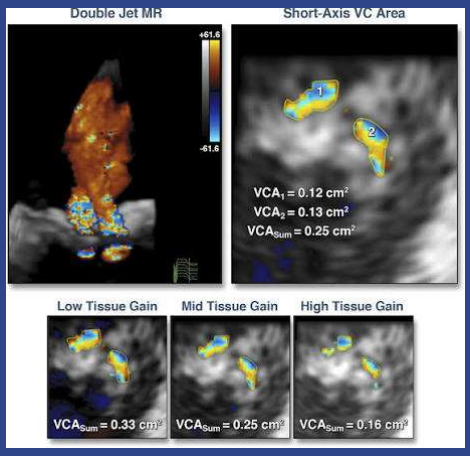

- View the short-axis (en-face) plane with 2D grayscale turned off to isolate the color Doppler jet cross-section.
- Identify the narrowest, most laminar neck of the jet — the true vena contracta, not the widest color splay.
- Trace the jet cross-section directly with planimetry; the software reports the enclosed area in cm^2.
- Re-confirm the cut plane is truly perpendicular to jet flow at that frame — an oblique cut inflates the measured area.

30

© Copyright. Society of Diagnostic Medical Sonography. All Rights Reserved.

Direct Planimetry vs. MPR-Derived VCA

Direct planimetry (DP) traces the jet cross-section on a manually cropped en-face view; MPR-derived VCA reconstructs the same plane through the three-plane alignment just described.

The two approaches correlate strongly (r = 0.97) — either is defensible when performed carefully, and familiarity with both builds workflow flexibility across vendor platforms.

MPR is generally the more systematic, teachable approach for less-experienced operators; direct planimetry via zoom-mode acquisition can be faster once the jet is reliably captured en face.

Whichever approach you standardize on, apply it consistently within your lab — reproducibility depends as much on protocol discipline as on technique.

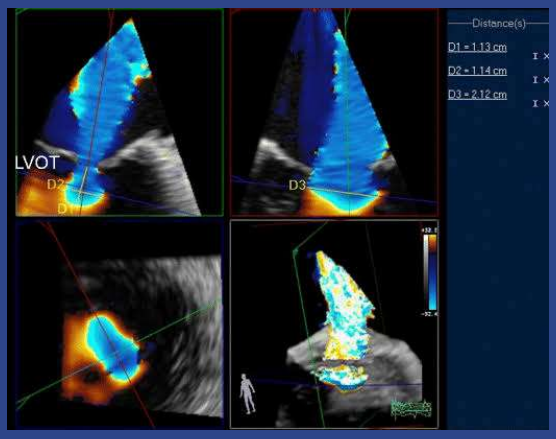

31

Pitfalls & Troubleshooting

The measurement errors that most often undermine an otherwise well-executed 3D VCA study — and how to catch them before they reach the report.

32

© Copyright. Society of Diagnostic Medical Sonography. All Rights Reserved.

Common Measurement Errors

Blooming

Excess color gain renders the Doppler signal larger than the true laminar jet core, inflating the measured area.

Coanda Effect

Wall-hugging eccentric jets can appear deceptively small on standard views, biasing severity toward underestimation.

Resolution Anisotropy

Lateral resolution is inherently coarser than axial — orient your en-face cut to minimize this asymmetry's effect on the traced outline.

33

Stitching Artifacts

Multi-beat full-volume acquisition stitches together sub-volumes from several cardiac cycles — any inconsistency between beats leaves a visible seam.

In validated cohorts, stitching artifacts were the single largest cause of excluded or unusable datasets — this is not a rare, edge-case problem.

Before measuring, scroll through the volume perpendicular to the acquisition sweep plane and confirm no discontinuity crosses the vena contracta region.

When stitching is a recurring problem, single-beat or zoom-mode acquisition removes the artifact source entirely, at some cost to volume rate.

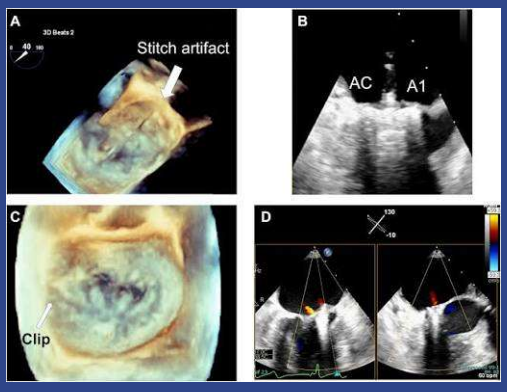

34

© Copyright. Society of Diagnostic Medical Sonography. All Rights Reserved.

Multiple Jets

Bileaflet prolapse and some functional MR mechanisms produce more than one distinct regurgitant orifice — a scenario 2D methods are particularly poor at capturing.

Measure each jet individually at its own optimally oriented en-face plane; do not force a single cut plane across multiple orifices.

Vena contracta values from separate jets are not simply additive — apply the same caution guidelines already give for 2D vena contracta width in multi-jet MR.

Report each jet's contribution and let the multiparametric, integrative severity assessment combine them.

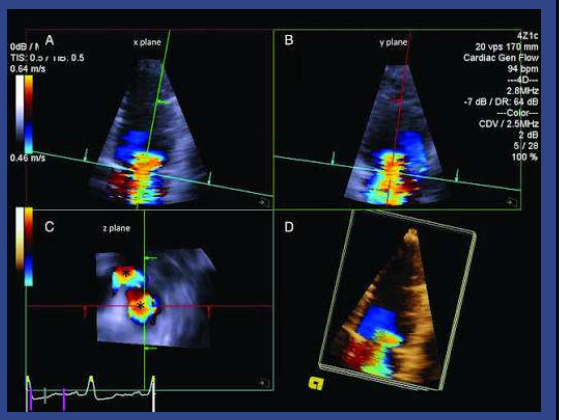

35

Putting It Into Practice

Etiology-specific pearls, a real-world procedural case, and where automated 3D quantification is headed next.

36

© Copyright. Society of Diagnostic Medical Sonography. All Rights Reserved.

Etiology-Specific Pearls

Secondary (Functional) MR

- Coaptation defects are frequently elongated or crescentic — exactly where 3D VCA's advantage over PISA is best documented.
- Jet direction can shift with loading conditions; re-confirm en-face orientation if hemodynamics change mid-study.
- The validated 0.43 cm² cutoff comes from this population specifically — apply etiology-matched thresholds where available.

Primary (Degenerative) MR

- Flail segments and bileaflet prolapse often generate eccentric or multiple jets — measure each orifice separately.
- Jets can be highly dynamic across systole; timing the planimetry frame to early-to-mid systole is especially important here.
- Etiology-specific 3D VCA cutoffs have been separately derived and validated for mitral valve prolapse populations.

37

Case Vignette — Monitoring Percutaneous Repair

0.99 cm²

baseline 3D VCA

Severe functional MR prior to transcatheter edge-to-edge repair (mean, PMVR registry cohort).

0.22 cm²

post-procedure 3D VCA

Residual MR quantified by direct planimetry — far more granular than a I–IV ordinal grade.

Consistent

across platforms

Cross-platform case data show 3D VCA values agree closely between TTE and TEE, and across vendor systems.

Sources: Utz D et al., Clin Res Cardiol 2018; cross-platform case comparison, CASE (JASE) 2022.

38

© Copyright. Society of Diagnostic Medical Sonography. All Rights Reserved.

The Horizon

Semi-automated and AI-assisted 3D color quantification tools are emerging to speed MPR alignment and reduce operator-dependent variability.

Faster single-beat, high-volume-rate 3D color acquisition continues to narrow the temporal-resolution gap with 2D imaging.

None of these tools remove the need for sonographer judgment — recognizing artifact, confirming true en-face orientation, and timing the cardiac cycle correctly remain fundamentally human skills.

Expect 3D VCA to move from a supplemental, research-adjacent tool toward a routine component of the quantitative MR work-up as platforms mature.

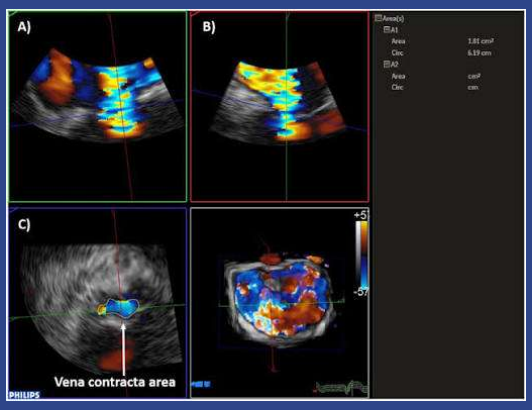

39

Your Workflow Checklist

- Optimize the color box: smallest sector and depth that fully contains the jet, gain reduced until blooming resolves.
- Prefer single-beat or zoom-mode acquisition when volume rate allows; if multi-beat is needed, gate and breath-hold carefully.
- Before measuring, scroll the dataset to confirm it is free of stitching artifact end to end.
- Align MPR planes along the jet, isolate the true en-face cut, and planimeter at early-to-mid systole — averaging across beats when feasible.
- For multiple jets, measure each individually and report each contribution within the full multiparametric picture.

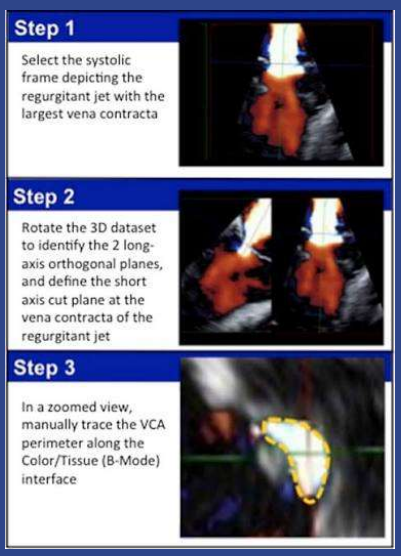

40

© Copyright. Society of Diagnostic Medical Sonography. All Rights Reserved.

5 Headline Points to Carry Into Your Next Study

1. 2D methods systematically misjudge non-circular, eccentric, and multi-jet mitral regurgitation — precisely the cases you see most often.
2. 3D VCA measures the jet's true cross-sectional area directly, with strong validation against 2D PISA, anatomic orifice area, and cardiac MRI.
3. Accurate acquisition — sector size, gain, beat mode, and frame rate — determines measurement quality more than any post-processing step.
4. The four-step MPR workflow (acquire, align, isolate en-face, planimeter) is teachable, reproducible, and correlates strongly with direct planimetry.
5. Watch for stitching artifacts, blooming, and mistimed frames — and measure every distinct jet on its own merits.

41

References

Zoghbi WA, Adams D, Bonow RO, et al. Recommendations for Noninvasive Evaluation of Native Valvular Regurgitation: A Report from the American Society of Echocardiography. J Am Soc Echocardiogr. 2017.

Lancellotti P, Tribouilloy C, Hagendorff A, et al. Recommendations for the Echocardiographic Assessment of Native Valvular Regurgitation: An Executive Summary from EACVI. Eur Heart J Cardiovasc Imaging. 2013.

Utz D, Boehm M, et al. Benefit of 3D Vena Contracta Area Over 2D-Based Echocardiographic Methods in Quantification of Functional Mitral Valve Regurgitation. Diagnostics. 2023.

Utz D, et al. 3D Vena Contracta Area After MitraClip: Precise Quantification of Residual Mitral Regurgitation and Identification of Prognostic Information. Clin Res Cardiol. 2018.

Marsan NA, Delgado V, et al. Quantification of Functional Mitral Regurgitation by Real-Time 3D Echocardiography: Comparison with 2D and Cardiac Magnetic Resonance. JACC Cardiovasc Imaging. 2009.

Little SH. The Vena Contracta Area: Conquering Quantification With a 3D Cut? JACC Cardiovasc Imaging. 2012.

Grewal J, et al. Multiplanar Reformat and Direct Planimetry: Quantitative Assessment of Mitral Regurgitation — How Best to Do It. JACC Cardiovasc Imaging. 2012.

Vena Contracta Area Measurement by 3D Echocardiography for Assessing Mitral Regurgitation Severity Using a Novel, Fast, and Reliable Method. BMC Cardiovasc Disord. 2025.

3D Vena Contracta Area in Degenerative Mitral Regurgitation: Cross-Platform Comparison in a Single Patient. CASE (JASE). 2022.

Quantification of Mitral Regurgitation in Mitral Valve Prolapse by 3D Vena Contracta Area: Derived Cutoff Values and Comparison With 2D Multiparametric Approach. J Am Soc Echocardiogr. 2024.

42

© Copyright. Society of Diagnostic Medical Sonography. All Rights Reserved.

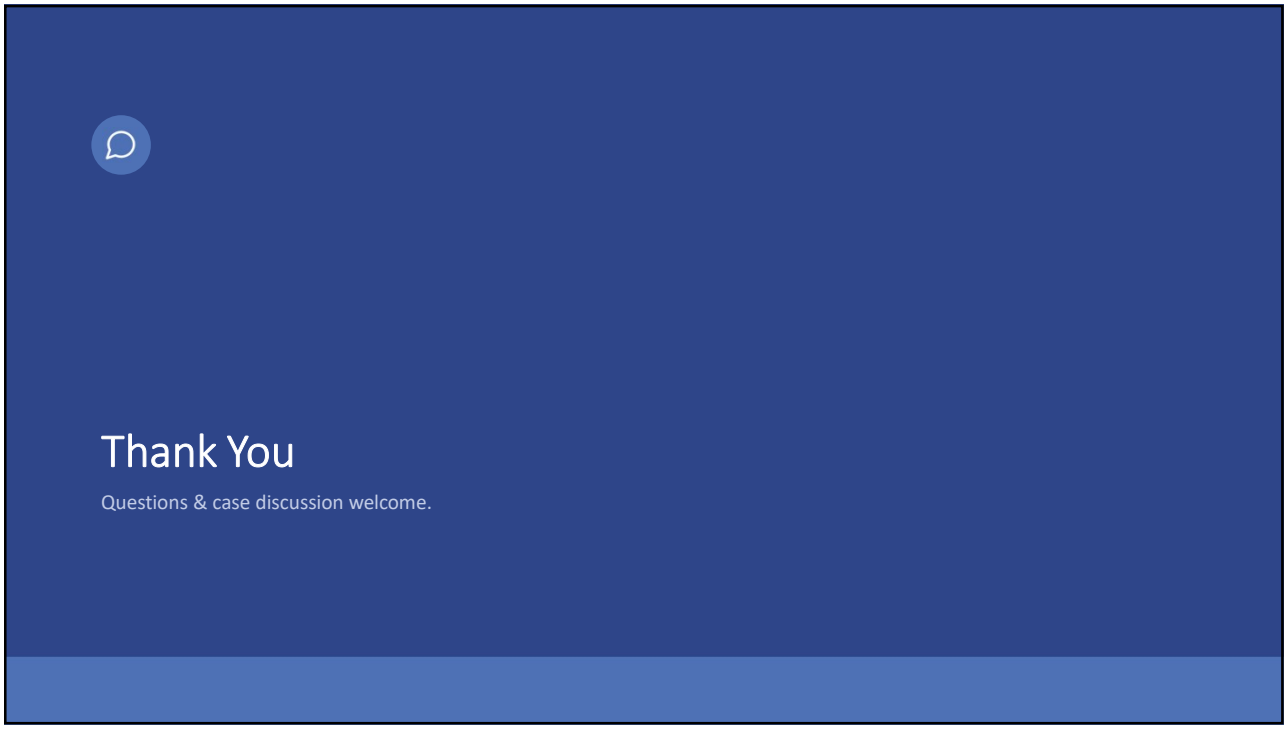

43

© Copyright. Society of Diagnostic Medical Sonography. All Rights Reserved.