High-Output Hemodynamics in Acute Anemia: Echocardiographic Insights and Clinical Implications

Meredith Ott, MBA, ACS, RCCS, RDCS (AE, PE)
Cardiac Sonographer III
Orlando Regional Medical Center
Orlando, Florida

1

SPEAKER PRESENTATION DISCLAIMER

The content and views presented are made available for educational purposes only. The information presented are the opinions of the presenter and do not necessarily represent the views of the Society of Diagnostic Medical Sonography (SDMS) or its affiliated organizations, officers, Boards of Directors, or staff members.

The presenter is responsible for ensuring balance, independence, objectivity, scientific rigor, and avoiding commercial bias in their presentation. Before making the presentation, the presenter is required to disclose to the audience any relevant financial interests or relationships with manufacturers or providers of medical products, services, technologies, and programs.

The SDMS and its affiliated organizations, officers, Board of Directors, and staff members disclaim any and all liability for all claims that may arise out of the use of this educational activity.

2

© Copyright. Society of Diagnostic Medical Sonography. All Rights Reserved.

RESEARCH DISCLAIMER

The information presented in this presentation is based on research conducted to the best of the presenters' abilities and knowledge. Research involves uncertainty and is subject to limitations. The findings and conclusions presented herein may be influenced by various factors including but not limited to data quality, methodology, assumptions, and interpretation.

Research outcomes may not always accurately predict real-world scenarios or future events. While the presenter may make efforts to ensure the accuracy and reliability of the information presented, completeness or absolute correctness is not guaranteed. This presentation is intended for informational purposes only and should not be construed as professional advice. Participants are encouraged to independently verify any information provided and consult relevant experts or professionals where appropriate.

The SDMS and its affiliated organizations, officers, Board of Directors, and staff members disclaim any and all liability for all claims that may arise out of the use of this educational activity.

3

GENERATIVE AI DISCLAIMER

The presenter utilized the use of large language models (LLMs) and generative artificial intelligence (AI) as a productivity tool to assist in drafting and refining content in this presentation.

While these tools can aid in structuring ideas, summarizing, paraphrasing, and language polishing, they have inherent limitations and cannot replace human creativity, critical thinking, or expert judgment. AI-generated content may contain errors, biases, or gaps in knowledge.

This presentation is intended for informational purposes only and should not be construed as definitive or authoritative guidance. Participants are encouraged to critically evaluate the information presented and consult relevant experts as needed. The SDMS and its affiliated organizations, officers, Board of Directors, and staff members disclaim any and all liability for claims that may arise from the use or interpretation of this educational material.

4

© Copyright. Society of Diagnostic Medical Sonography. All Rights Reserved.

Learning Objectives (1)

- Build the red blood cell from membrane → hemoglobin → heme iron → oxygen carriage.
- Predict how hemoglobin and hematocrit alter viscosity, cardiac output, Reynolds number, and Doppler velocity.
- Recognize flow-dependent valve measurements that can overstate stenosis in acute anemia.

5

Learning Objectives (2)

- Use a safeguard hierarchy: technique → flow quantification → flow-independent corroboration → re-study after optimization.
- Explain why iron deficiency, hemoglobin concentration, and hematocrit are related—but not interchangeable Doppler variables.

6

© Copyright. Society of Diagnostic Medical Sonography. All Rights Reserved.

The Red Blood Cell: A Deformable Oxygen-Delivery Vehicle (1)

- **MEMBRANE/CYTOSKELETON:** BICONCAVE, FLEXIBLE, ANUCLEATE. DEFORMABILITY MATTERS FOR MICROVASCULAR FLOW.
- **HEMOGLOBIN:** TETRAMERIC PROTEIN FILLING THE RBC; THE DOMINANT CARRIER OF BLOOD OXYGEN.
- **HEME IRON:** EACH HEME CONTAINS FE^{2+} THAT REVERSIBLY BINDS OXYGEN. IRON DEFICIENCY LIMITS HEMOGLOBIN SYNTHESIS.

7

The Red Blood Cell: A Deformable Oxygen-Delivery Vehicle (2)

- **HEMOCRIT:** FRACTION OF BLOOD VOLUME OCCUPIED BY RBCS. A MAJOR DETERMINANT OF WHOLE-BLOOD VISCOSITY.
- **LIFESPAN AND PRODUCTION:** RBC LIFESPAN ≈120 DAYS. ERYTHROPOIESIS REQUIRES IRON, B12, FOLATE, HEME, AND EPO SIGNALING.

**EPO= Erythropoietin, a natural hormone made by the kidneys that tells bone marrow to produce red blood cells.*

8

© Copyright. Society of Diagnostic Medical Sonography. All Rights Reserved.

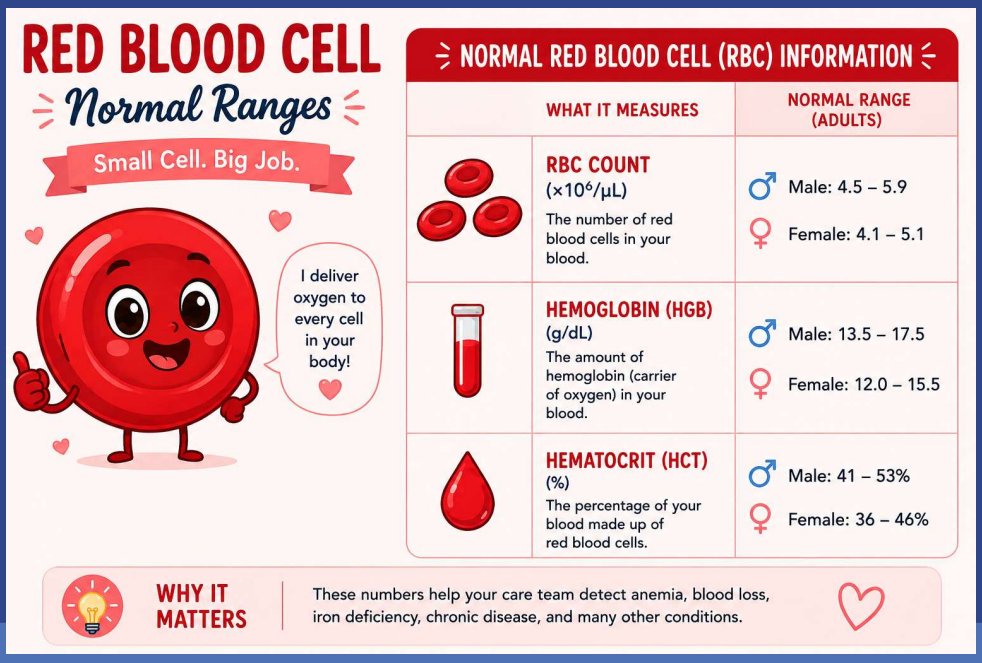

9

Oxygen Delivery Forces the Circulation to Compensate

DO_2 = Cardiac Output × CaO_2 × 10

**DO2 represents oxygen delivery*

**CaO2 (Arterial Oxygen Content): The amount of oxygen bound to hemoglobin plus the small amount dissolved in the blood plasma.*

**Multiplying CaO2 (mL/dL) by 10 adjusts to mL/L.*

10

© Copyright. Society of Diagnostic Medical Sonography. All Rights Reserved.

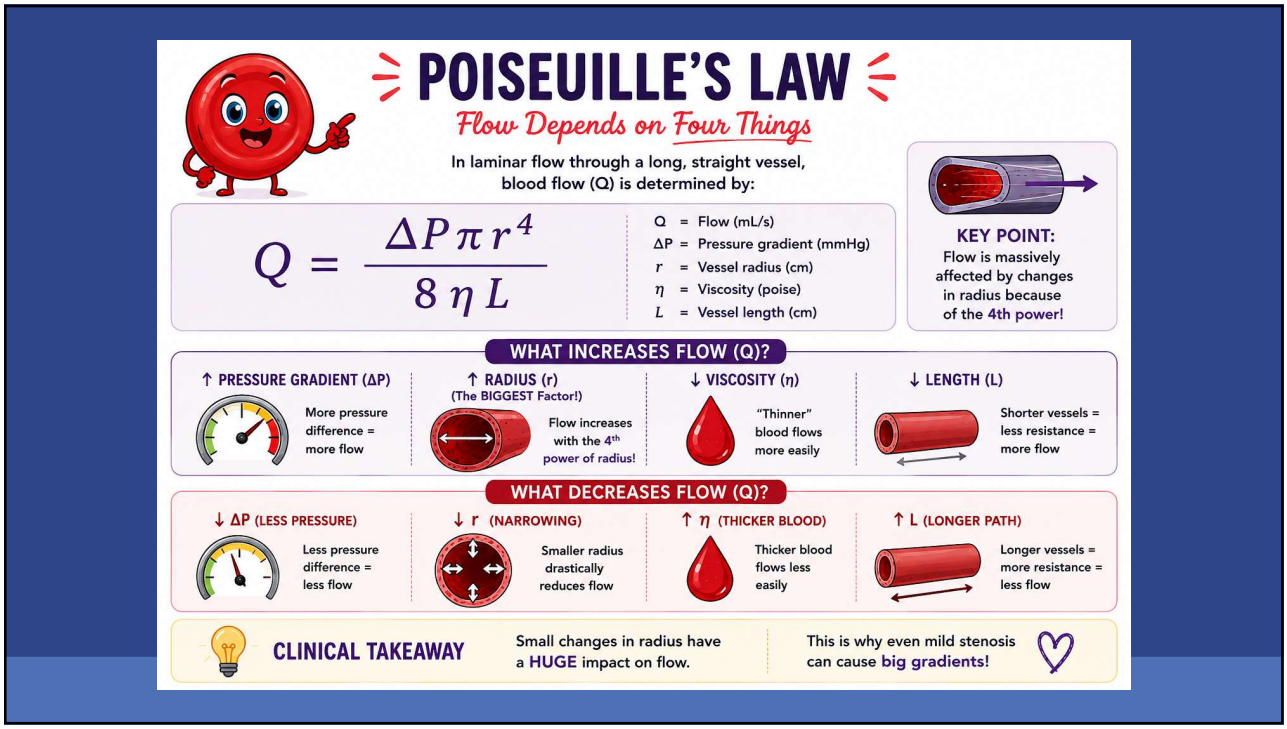

11

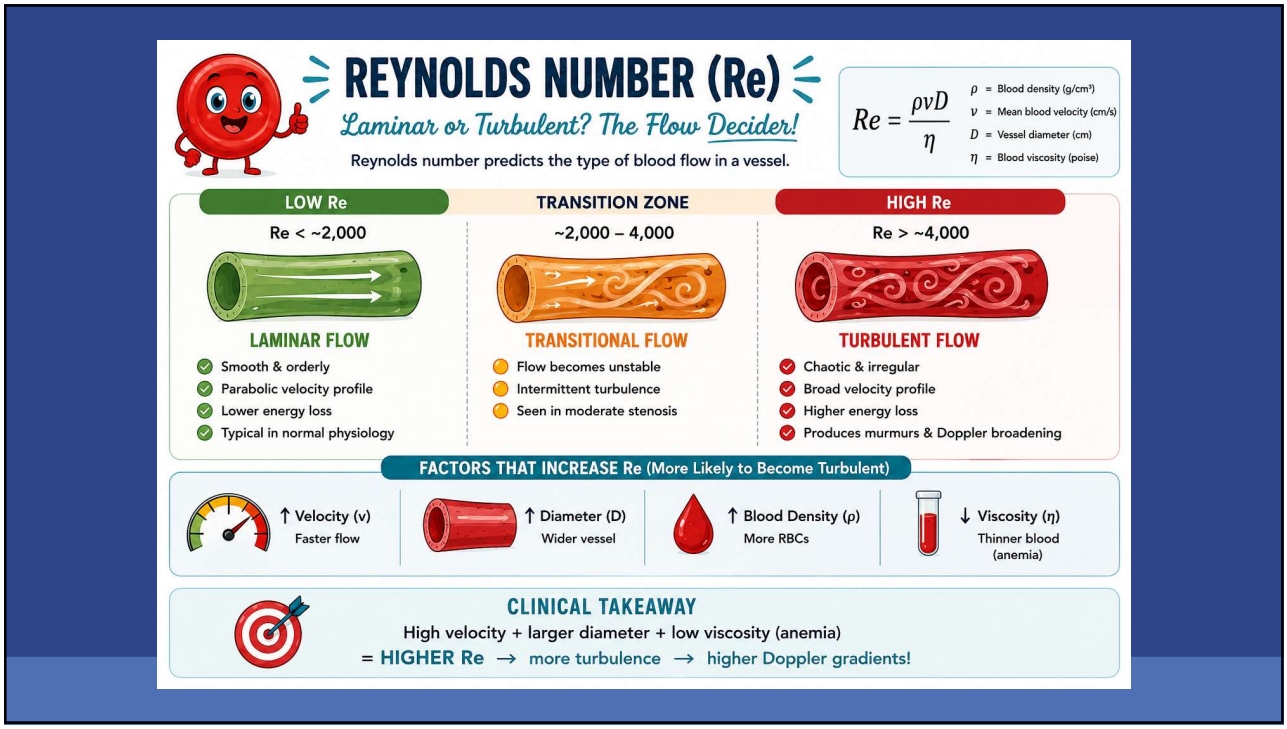

12

© Copyright. Society of Diagnostic Medical Sonography. All Rights Reserved.

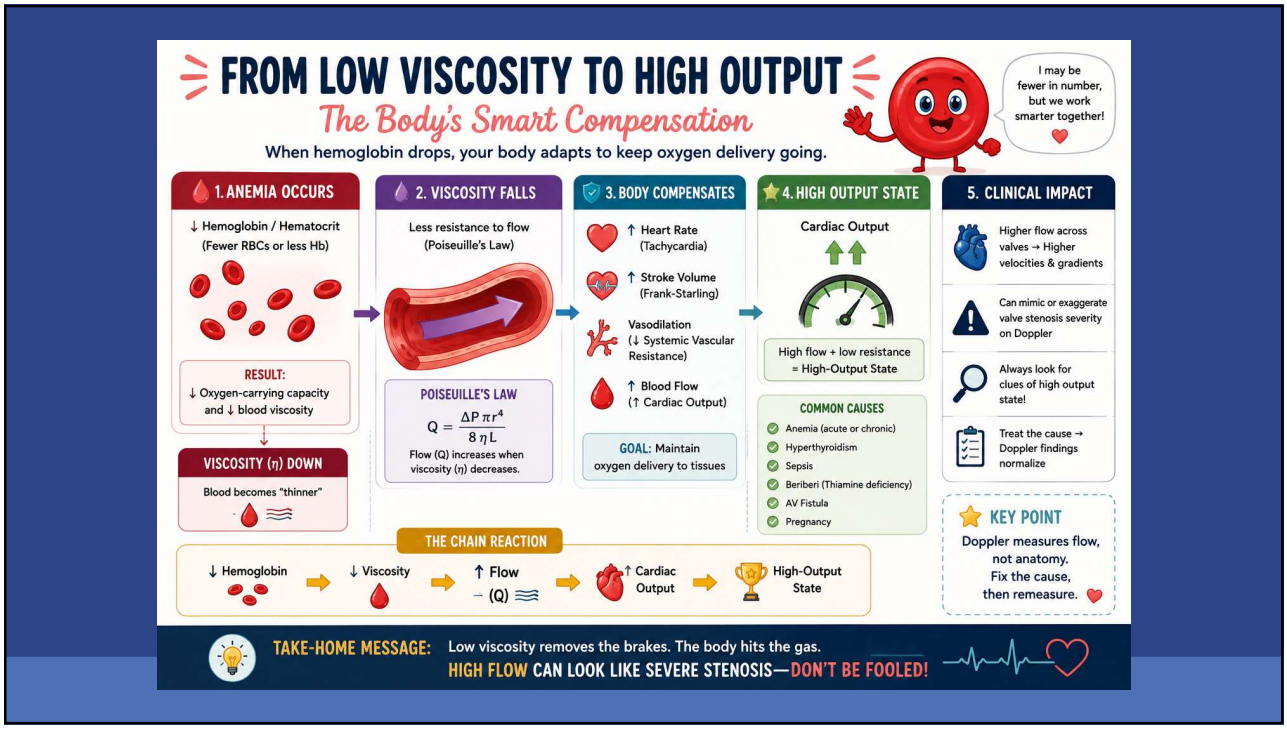

13

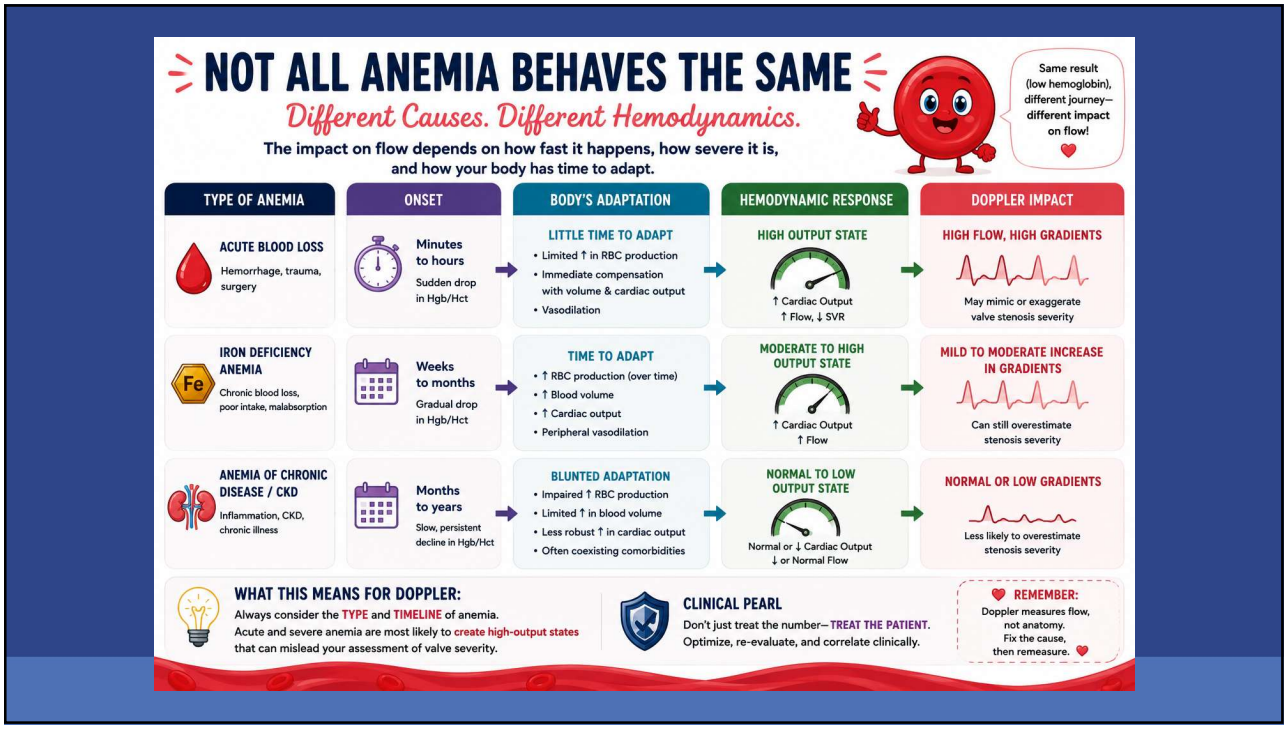

14

© Copyright. Society of Diagnostic Medical Sonography. All Rights Reserved.

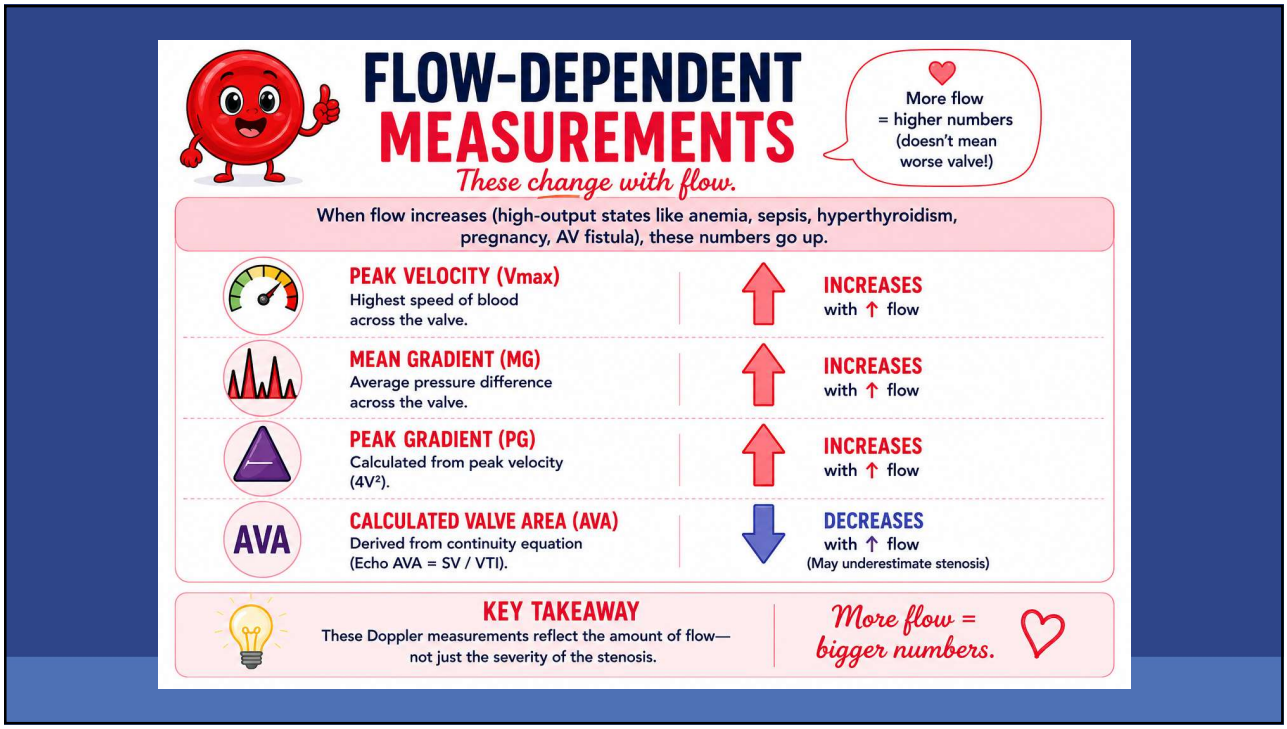

15

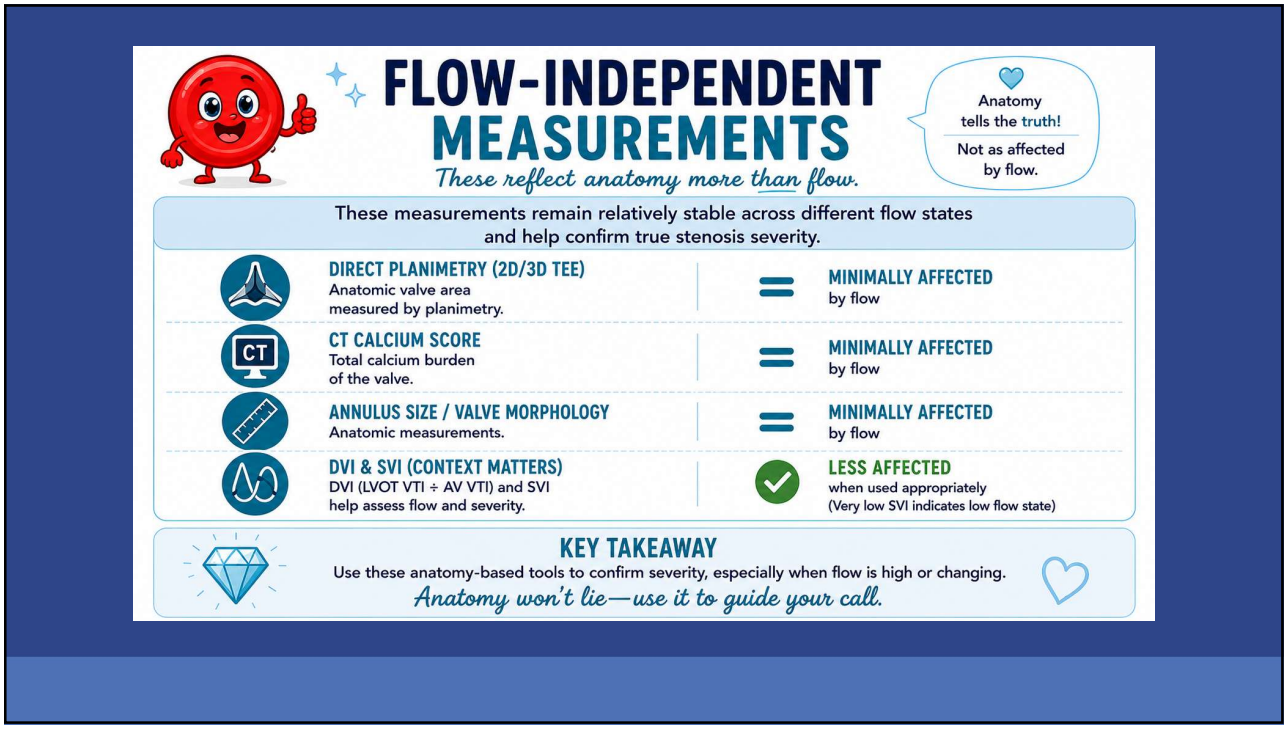

16

© Copyright. Society of Diagnostic Medical Sonography. All Rights Reserved.

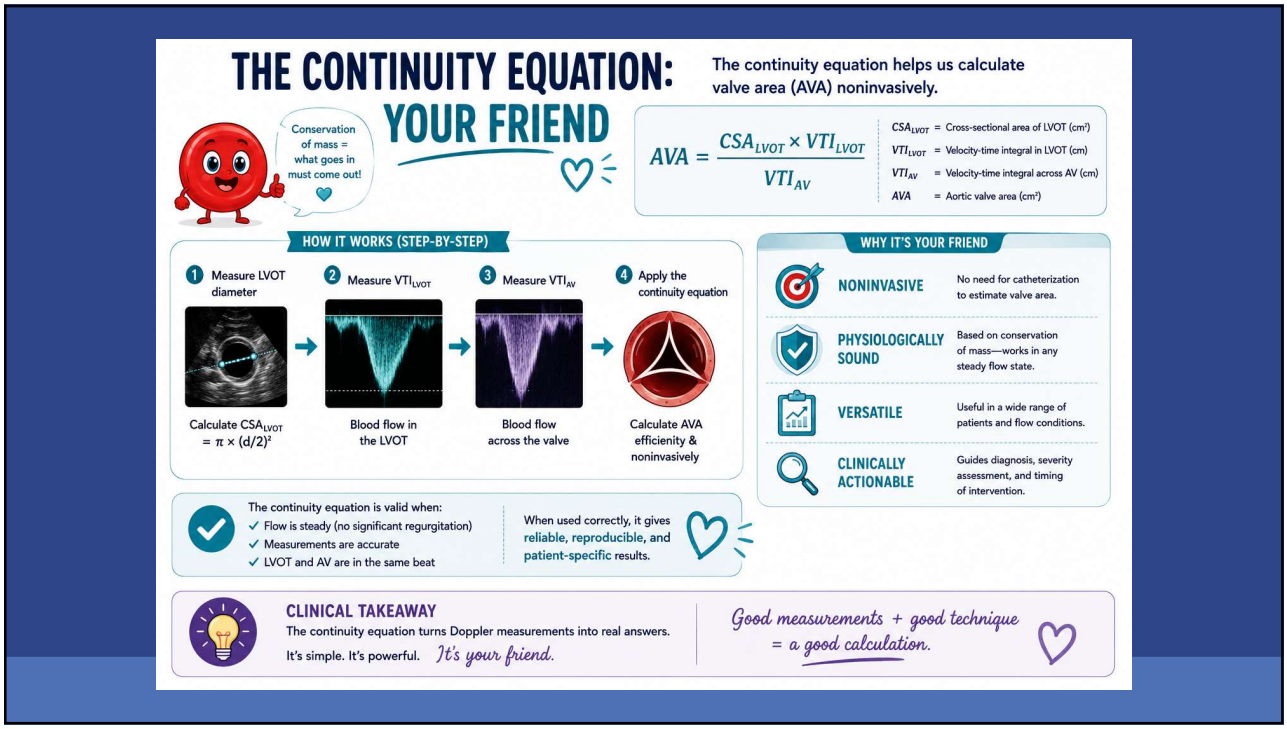

17

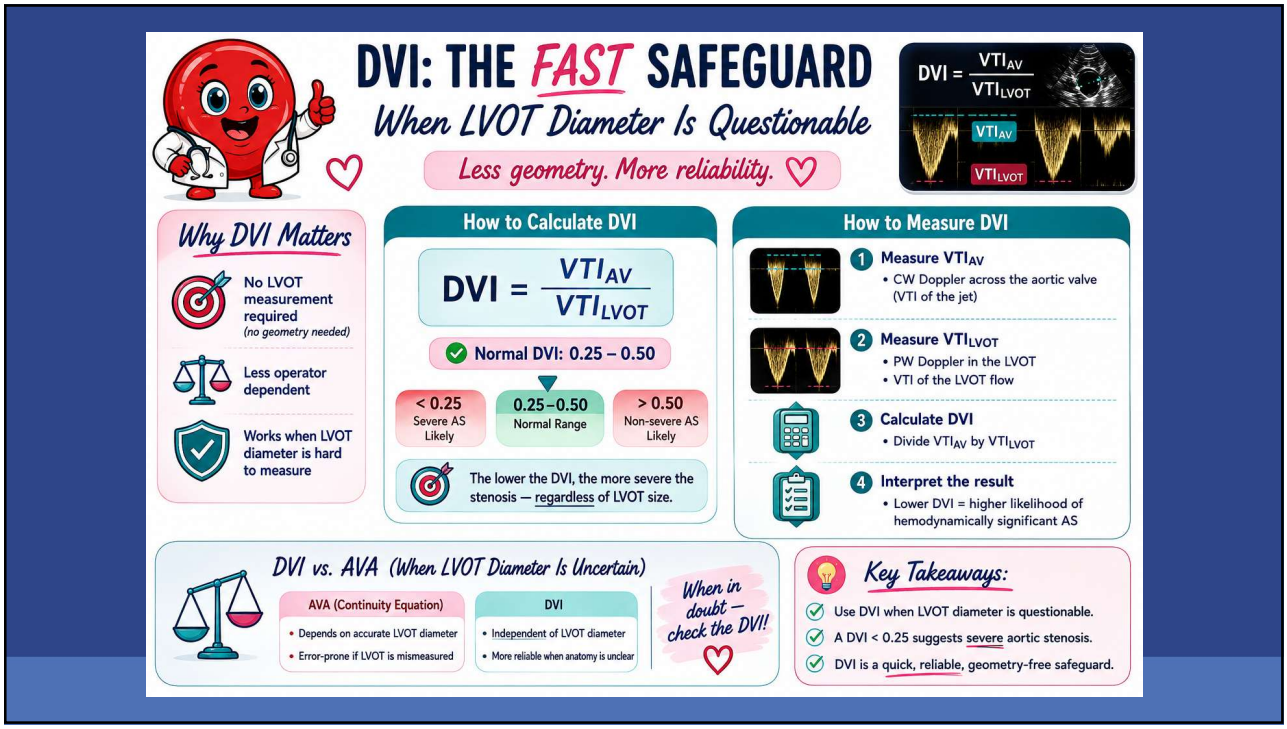

18

© Copyright. Society of Diagnostic Medical Sonography. All Rights Reserved.

Acceleration Time and Contour: Supportive, Not Standalone

Use waveform shape + acceleration time as corroborating physiology. Do not let one secondary sign overrule a technically sound



19

Mitral Stenosis: Mean Gradient is Flow AND Heart-Rate Dependent

Transmitral mean gradient rises with more flow and shorter diastolic filling time.

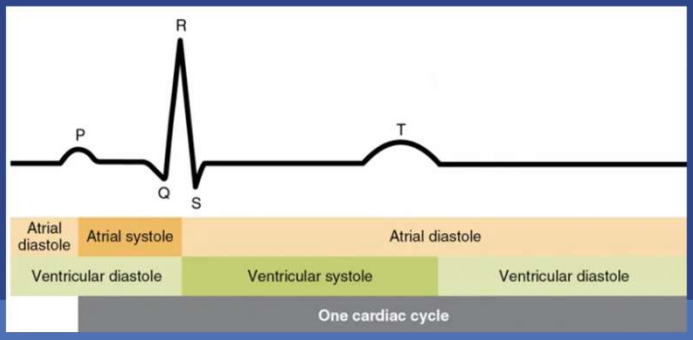

20

© Copyright. Society of Diagnostic Medical Sonography. All Rights Reserved.

Prosthetic valves: anemia can mimic obstruction (1)

- High flow can elevate transprosthetic velocities and gradients without structural valve obstruction. (not valid in the setting of hocm or subvalvular membranes)
- Compare with the patient's baseline study and the expected normal values for that prosthesis type/size. look at previous studies.
- All valve information e.g. EROA and peak/mean pressure gradient are readily available online.

21

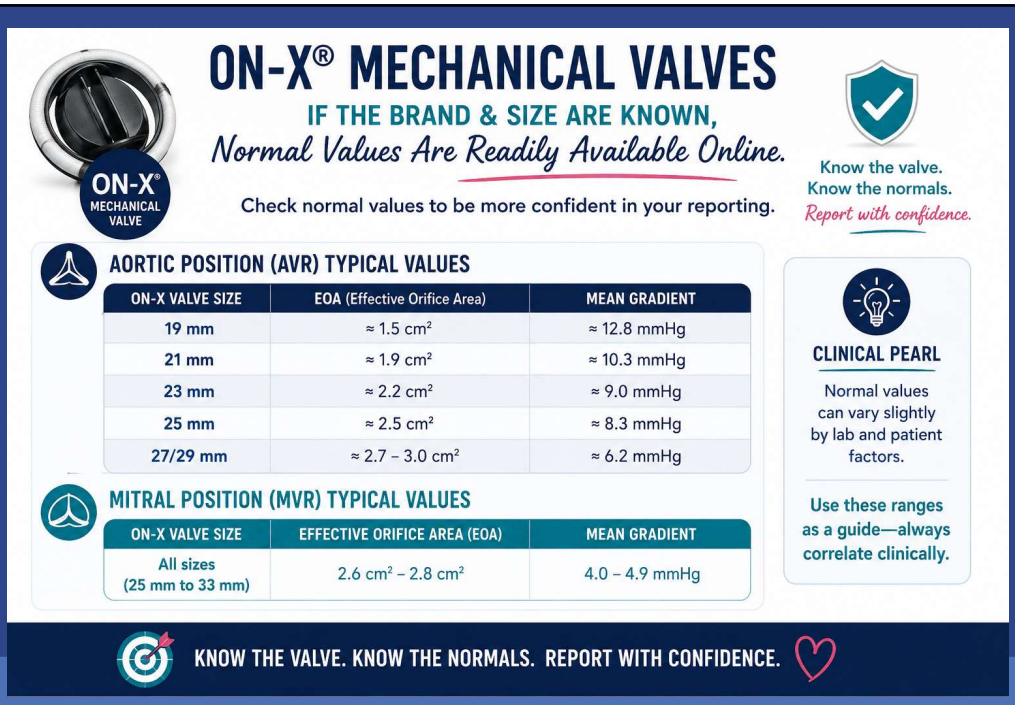

22

© Copyright. Society of Diagnostic Medical Sonography. All Rights Reserved.

Prosthetic valves: anemia can mimic obstruction (2)

- USE DVI, ACCELERATION TIME, JET CONTOUR, EFFECTIVE ORIFICE AREA, AND LEAFLET/DISC MOTION—NOT GRADIENT ALONE.
- SEARCH FOR REVERSIBLE CAUSES OF HIGH FLOW: ANEMIA, FEVER/SEPSIS, HYPERTHYROIDISM, AV FISTULA, SIGNIFICANT REGURGITATION.
- IF THE PROSTHESIS LOOKS NORMAL BUT THE GRADIENT SUDDENLY RISES, PHYSIOLOGY BELONGS HIGH ON THE DIFFERENTIAL.

23

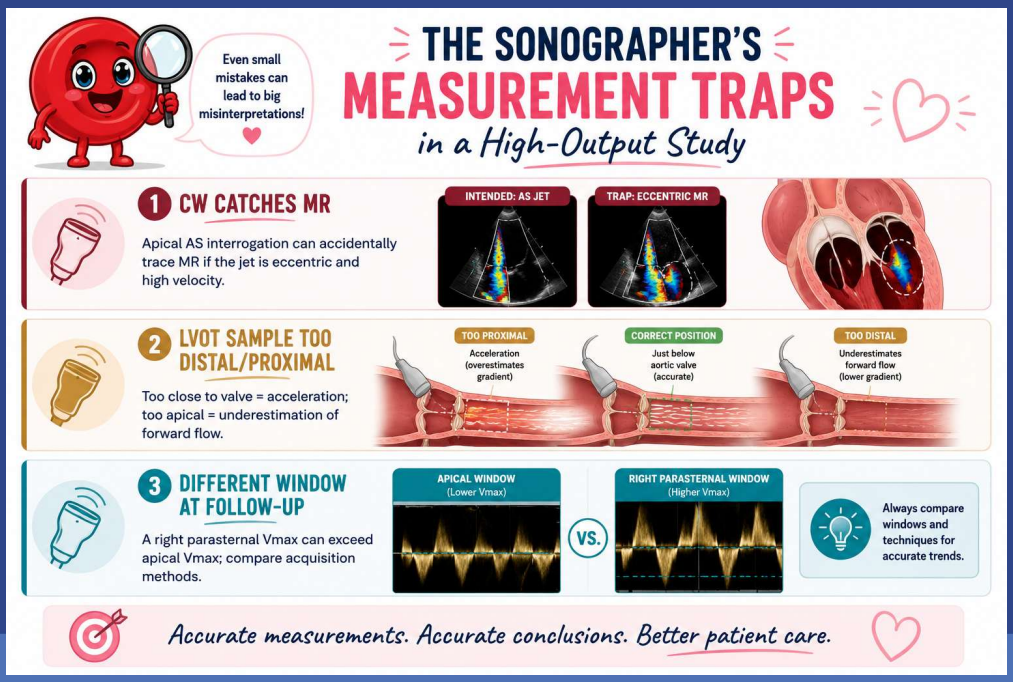

24

© Copyright. Society of Diagnostic Medical Sonography. All Rights Reserved.

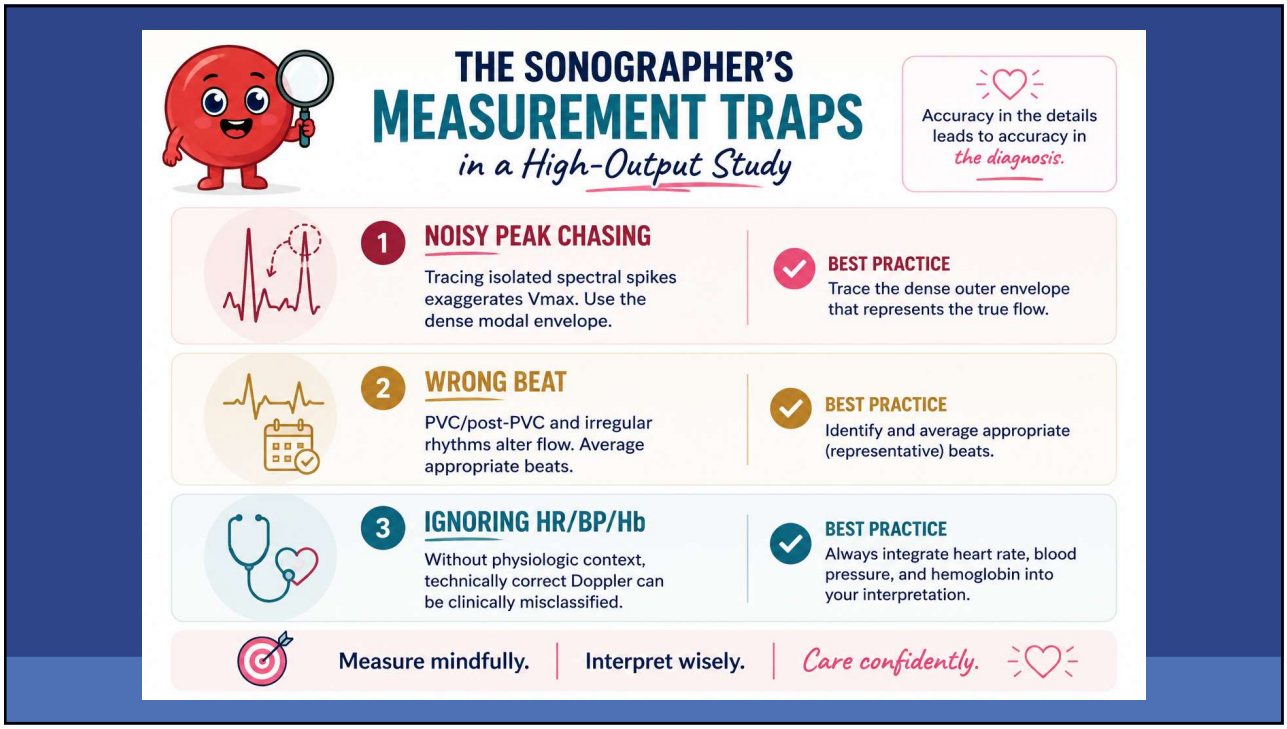

25

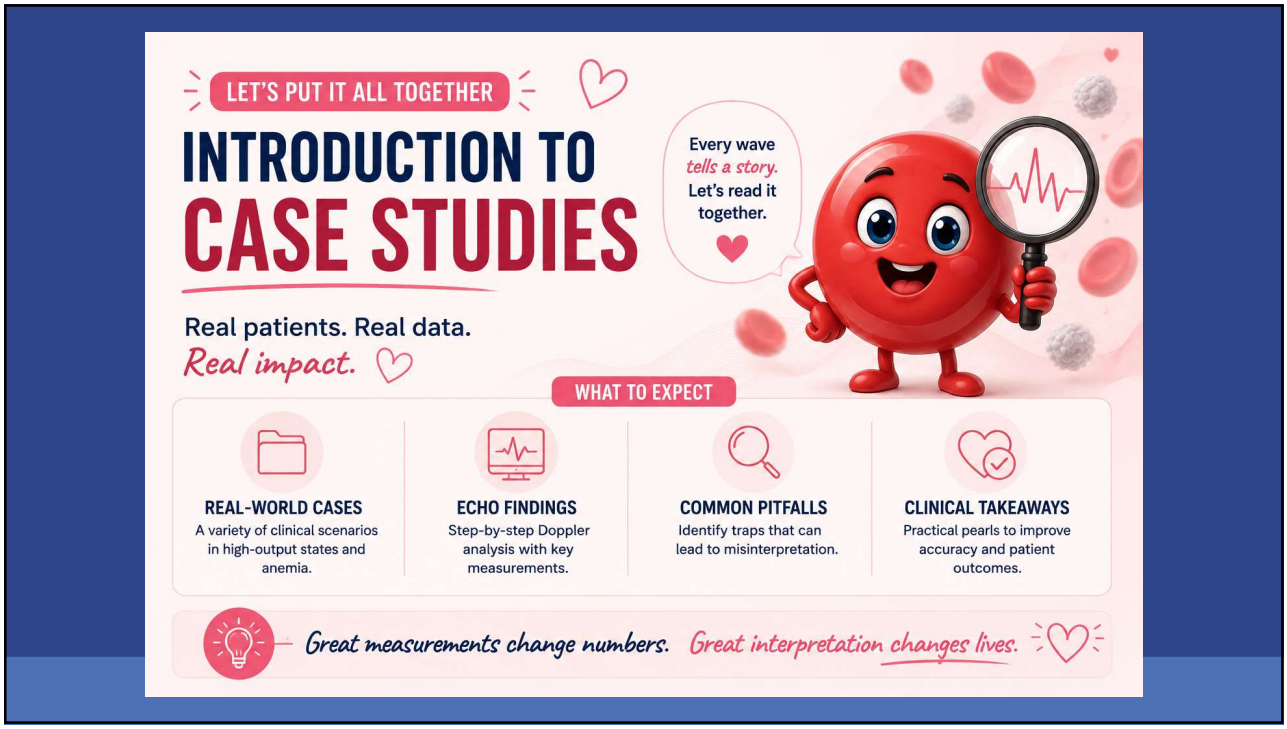

26

© Copyright. Society of Diagnostic Medical Sonography. All Rights Reserved.

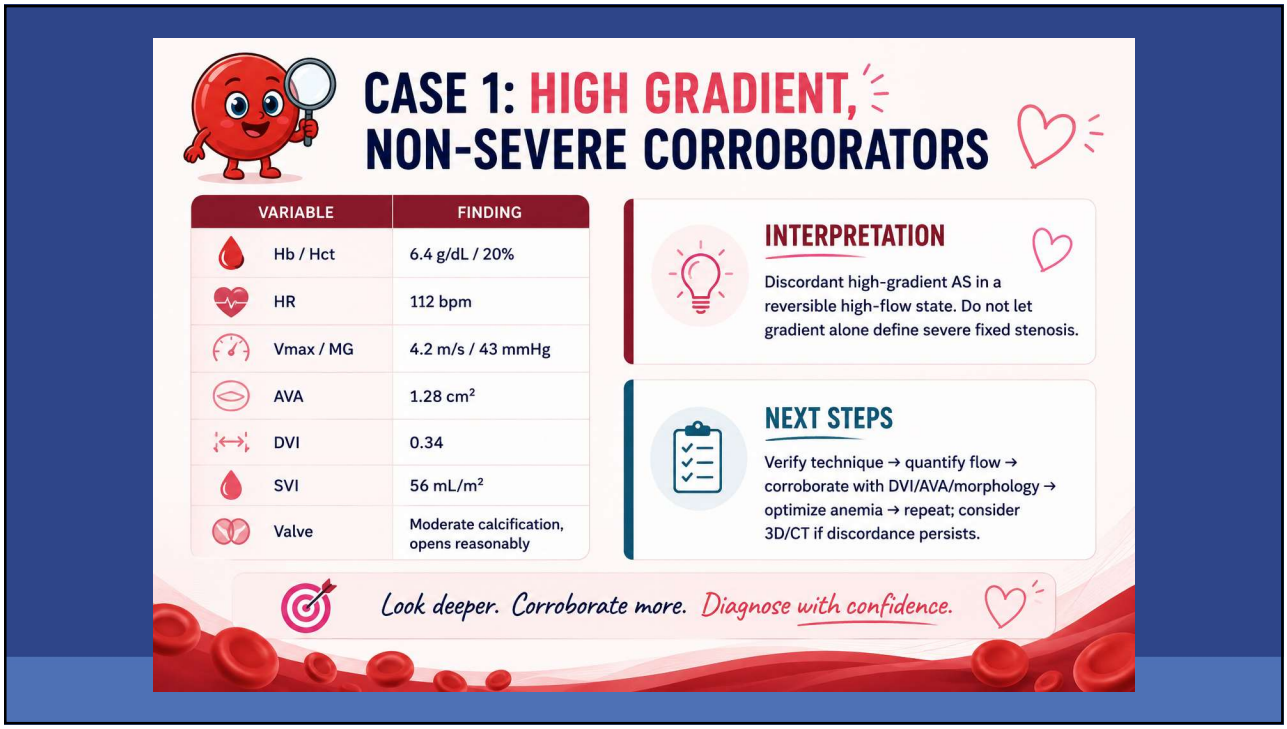

27

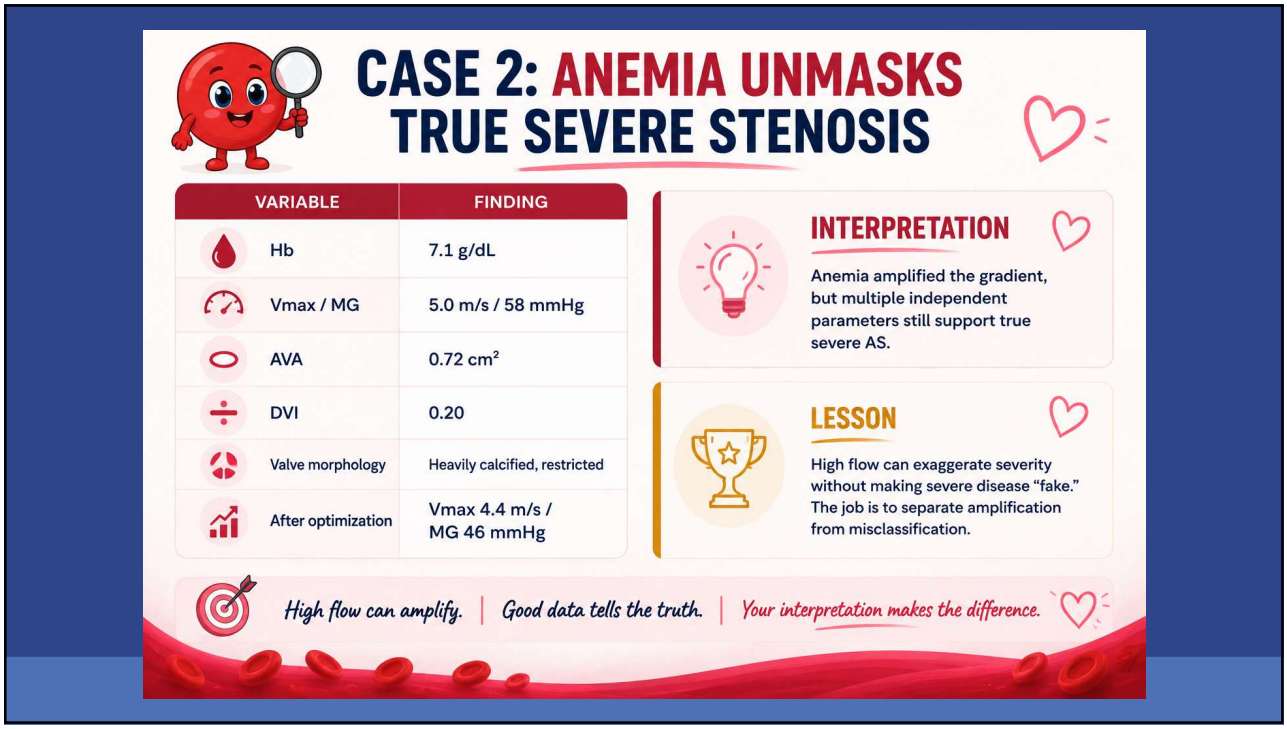

28

© Copyright. Society of Diagnostic Medical Sonography. All Rights Reserved.

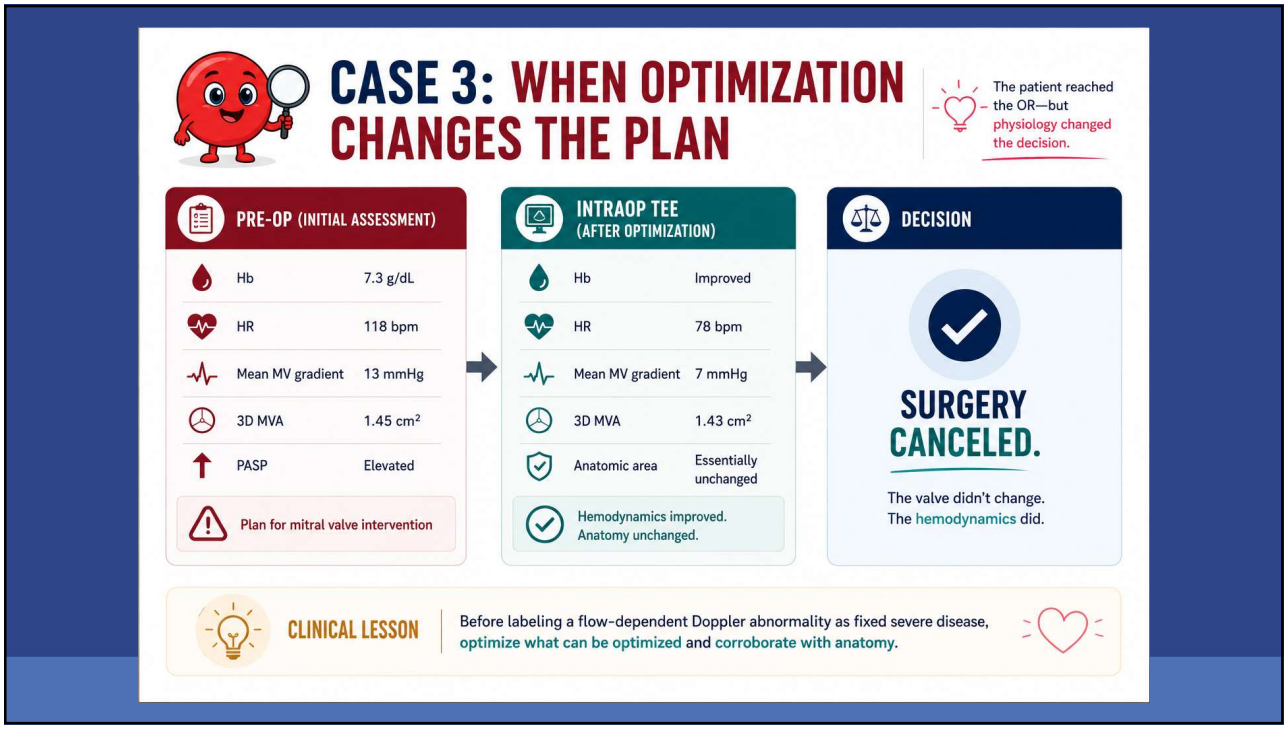

29

References

Baumgartner H, Hung J, Bermejo J, et al. Recommendations on the echocardiographic assessment of aortic valve stenosis: a focused update from the European Association of Cardiovascular Imaging and the American Society of Echocardiography. J Am Soc Echocardiogr. 2017;30(4):372-392.

Baumgartner H, Hung J, Bermejo J, et al. Echocardiographic assessment of valve stenosis: EAE/ASE recommendations for clinical practice. Eur J Echocardiogr. 2009;10(1):1-25.

Zoghbi WA, Jone PN, Chamsi-Pasha MA, et al. Guidelines for the evaluation of prosthetic valve function with cardiovascular imaging: a report from the American Society of Echocardiography. J Am Soc Echocardiogr. 2024;37(1):2-63.

Zoghbi WA, Chambers JB, Dumesnil JG, et al. Recommendations for evaluation of prosthetic valves with echocardiography and Doppler ultrasound. J Am Soc Echocardiogr. 2009;22(9):975-1014.

Mitchell C, Rahko PS, Blauwet LA, et al. Guidelines for performing a comprehensive transthoracic echocardiographic examination in adults: recommendations from the American Society of Echocardiography. J Am Soc Echocardiogr. 2019;32(1):1-64.

Lang RM, Badano LP, Mor-Avi V, et al. Recommendations for cardiac chamber quantification by echocardiography in adults. J Am Soc Echocardiogr. 2015;28(1):1-39.

Nagueh SF, Smiseth OA, Appleton CP, et al. Recommendations for the evaluation of left ventricular diastolic function by echocardiography. J Am Soc Echocardiogr. 2016;29(4):277-314.

Otto CM, Nishimura RA, Bonow RO, et al. 2020 ACC/AHA guideline for the management of patients with valvular heart disease. Circulation. 2021;143(5):e72-e227.

30

© Copyright. Society of Diagnostic Medical Sonography. All Rights Reserved.

References

Clavel MA, Magne J, Pibarot P. Low-gradient aortic stenosis. Eur Heart J. 2016;37(34):2645-2657.

Pibarot P, Dumesnil JG. Low-flow, low-gradient aortic stenosis with normal and depressed left ventricular ejection fraction. J Am Coll Cardiol. 2012;60(19):1845-1853.

Duke M, Abelmann WH. The hemodynamic response to chronic anemia. Circulation. 1969;39(4):503-515.

Murray JF, Escobar E, Rapaport E. Effects of blood viscosity on hemodynamic responses in acute normovolemic anemia. Am J Physiol. 1969;216:638-642.

Weiskopf RB, Viele MK, Feiner J, et al. Human cardiovascular and metabolic response to acute, severe isovolemic anemia. JAMA. 1998;279(3):217-221.

Anand IS. Anemia and chronic heart failure: implications and treatment options. J Am Coll Cardiol. 2008;52(7):501-511.

Camaschella C. Iron-deficiency anemia. N Engl J Med. 2015;372(19):1832-1843.

31

Thank You!



32

© Copyright. Society of Diagnostic Medical Sonography. All Rights Reserved.