The Sonographer's Visual Dictionary: A Practical Guide to Common Abdominal Ultrasound Signs

Nicole Y. García Santiago MHS, RDMS, RVT, RDCS

1

SPEAKER PRESENTATION DISCLAIMER

The content and views presented are made available for educational purposes only. The information presented are the opinions of the presenter and do not necessarily represent the views of the Society of Diagnostic Medical Sonography (SDMS) or its affiliated organizations, officers, Boards of Directors, or staff members.

The presenter is responsible for ensuring balance, independence, objectivity, scientific rigor, and avoiding commercial bias in their presentation. Before making the presentation, the presenter is required to disclose to the audience any relevant financial interests or relationships with manufacturers or providers of medical products, services, technologies, and programs.

The SDMS and its affiliated organizations, officers, Board of Directors, and staff members disclaim any and all liability for all claims that may arise out of the use of this educational activity.

2

© Copyright. Society of Diagnostic Medical Sonography. All Rights Reserved.

GENERATIVE AI DISCLAIMER

The presenter utilized the use of large language models (LLMs) and generative artificial intelligence (AI) as a productivity tool to assist in drafting and refining content in this presentation.

While these tools can aid in structuring ideas, summarizing, paraphrasing, and language polishing, they have inherent limitations and cannot replace human creativity, critical thinking, or expert judgment. AI-generated content may contain errors, biases, or gaps in knowledge.

This presentation is intended for informational purposes only and should not be construed as definitive or authoritative guidance. Participants are encouraged to critically evaluate the information presented and consult relevant experts as needed. The SDMS and its affiliated organizations, officers, Board of Directors, and staff members disclaim any and all liability for claims that may arise from the use or interpretation of this educational material.

3

Objectives

- Recognize common abdominal ultrasound signs associated with specific pathological findings.
- Identify sonographic patterns that distinguish various abdominal conditions.
- Summarize the clinical significance of key ultrasound signs in abdominal imaging.

4

© Copyright. Society of Diagnostic Medical Sonography. All Rights Reserved.

The Power of Pattern Recognition

Accurate diagnosis requires integrating your images with patient history and laboratory data.

5

The Diagnostic Framework

Pattern recognition acts as the most efficient diagnostic tool in your daily practice.

6

© Copyright. Society of Diagnostic Medical Sonography. All Rights Reserved.

The Diagnostic Framework

A classic ultrasound sign is a reliable clue to pathology, not a definitive final diagnosis

7

The Mickey Mouse Sign

The portal vein, hepatic artery, and bile duct form your essential RUQ map.



Image 1

8

© Copyright. Society of Diagnostic Medical Sonography. All Rights Reserved.

The Reindeer/Bunny Sign

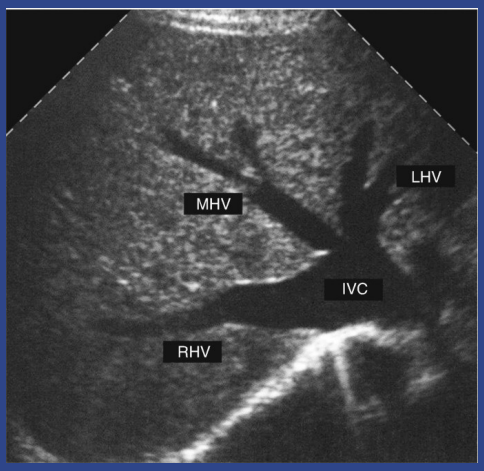

Image 2

The hepatic veins draining into the IVC create the classic "bunny" appearance.

9

Renal Cortex Comparison

The normal cortex should appear slightly hypoechoic to the adjacent liver parenchyma.



Image 3

10

© Copyright. Society of Diagnostic Medical Sonography. All Rights Reserved.

Aorta and IVC Relationship

Midline vascular relationships provide the key to your sagittal scanning plane.

11

Aorta and IVC Relationship



Image 4



Image 5

12

© Copyright. Society of Diagnostic Medical Sonography. All Rights Reserved.

Pancreatic Body Landmark

The splenic vein serves as the primary posterior landmark for the pancreatic body.



Image 6

13

Gallbladder Fossa Landmark

The main lobar fissure connects the gallbladder neck to the portal vein.

14

© Copyright. Society of Diagnostic Medical Sonography. All Rights Reserved.

The Appendix Target

Identify the blind-ended, non-compressible structure in the right lower quadrant.

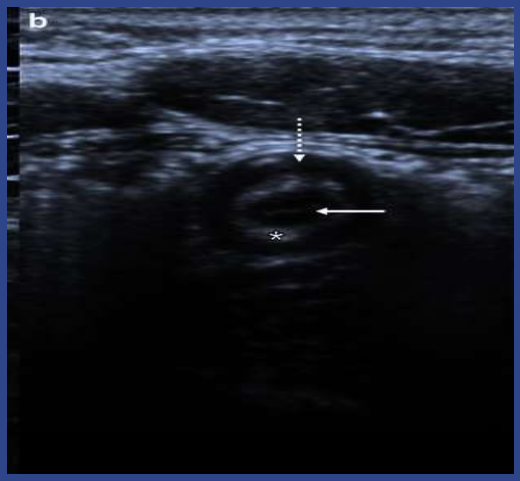

Image 7

15

Appendicitis Correlation

A diameter over 6mm with surrounding hyperechoic fat confirms acute appendicitis.

16

© Copyright. Society of Diagnostic Medical Sonography. All Rights Reserved.

Intussusception

Look for the concentric rings of the "pseudokidney" sign in pediatric patients.

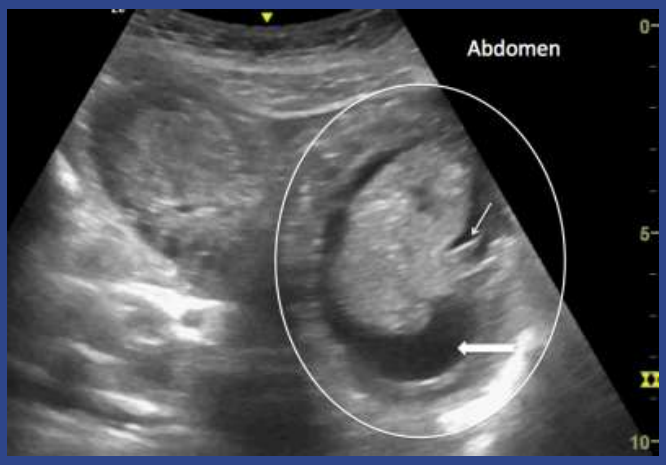

Image 8

17

Intussusception Clinical Significance

This pattern indicates bowel telescoping and necessitates an urgent surgical consultation.

18

© Copyright. Society of Diagnostic Medical Sonography. All Rights Reserved.

The WES Sign

Recognize the Wall-Echo-Shadow complex within the gallbladder lumen.



Image 9

19

Chronic Cholelithiasis Significance

This sign confirms chronic stones and a contracted, stone-filled gallbladder.

20

© Copyright. Society of Diagnostic Medical Sonography. All Rights Reserved.

The Starry Sky Sign

Acute hepatitis causes the portal vein walls to appear abnormally hyperechoic.

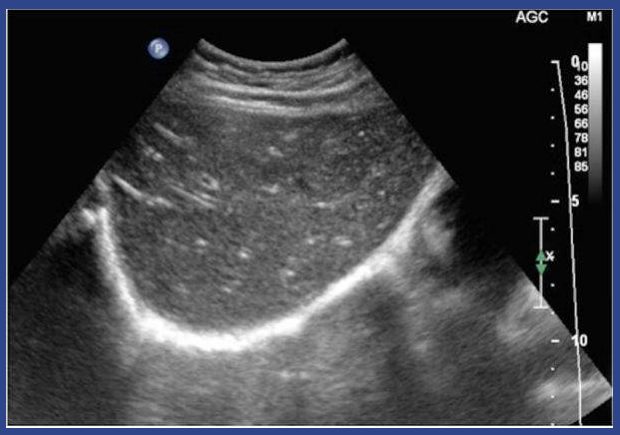

Image 10

21

Hepatitis Significance

This appearance helps differentiate acute inflammatory liver disease from chronic cirrhosis.

22

© Copyright. Society of Diagnostic Medical Sonography. All Rights Reserved.

The Water Lily Sign

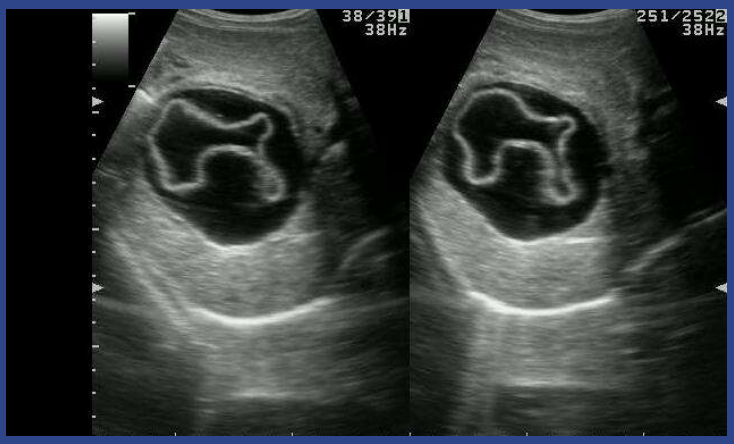

Image 11

A detached membrane floating within a cyst indicates a ruptured hydatid infection.

23

Normal Gut Signature

Normal bowel walls display a distinct and predictable five-layer echogenic architecture.

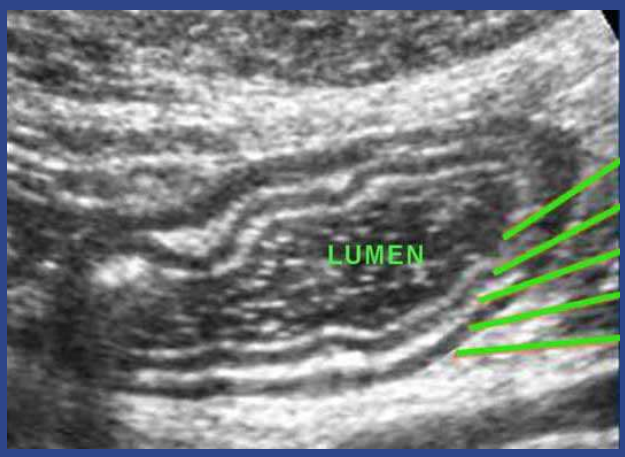

Image 12

24

© Copyright. Society of Diagnostic Medical Sonography. All Rights Reserved.

Bowel Wall Significance

Loss of this layer pattern suggests advanced inflammation or neoplastic infiltration.

25

The Sandwich Sign

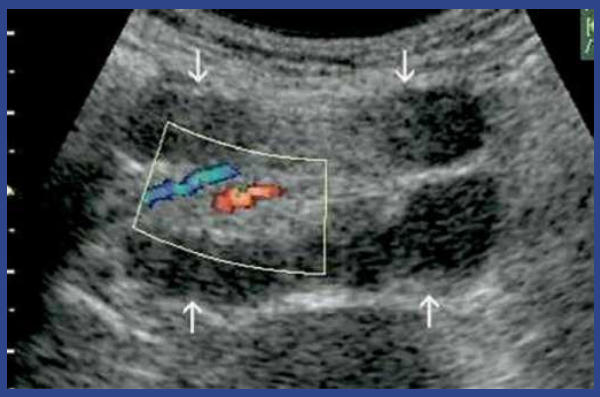

Image 13

Mesenteric lymphadenopathy creates a "sandwich" effect around the aorta and SMA.

26

© Copyright. Society of Diagnostic Medical Sonography. All Rights Reserved.

Lymphoma Significance

This visual pattern is a hallmark finding in cases of abdominal lymphoma.

27

The Twinkling Sign

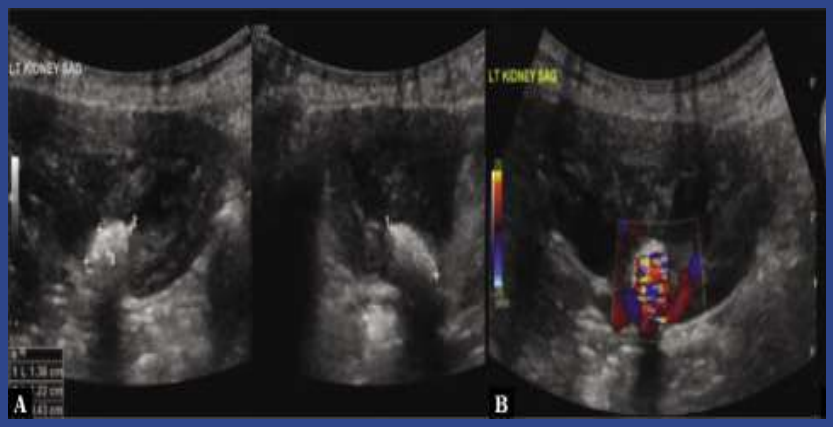

Image 14

This color artifact confirms the presence of calcification behind a suspected stone.

28

© Copyright. Society of Diagnostic Medical Sonography. All Rights Reserved.

Stone Identification

Use this tool to improve the sensitivity of your scan for small calculi.

29

The Gliding Sign

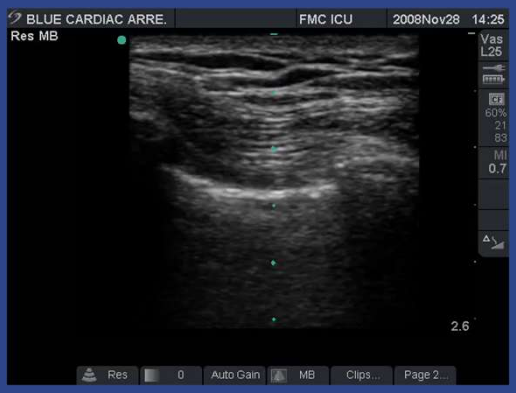

Video 1

The visceral and parietal pleura should slide smoothly against each other during respiration.

30

© Copyright. Society of Diagnostic Medical Sonography. All Rights Reserved.

Pneumothorax Significance

Absence of this sign is a reliable indicator of a possible pneumothorax.

31

The Keyboard Sign

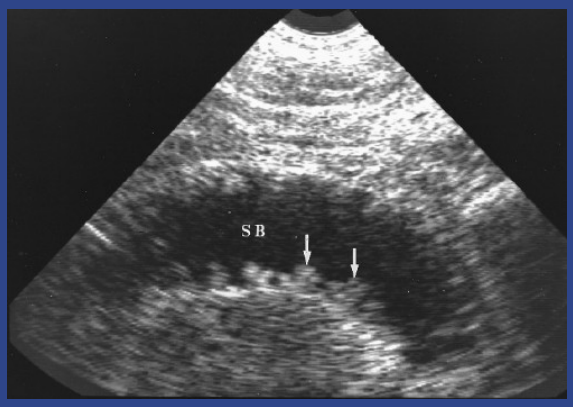

Image 15

Dilated small bowel loops display prominent, regular valvulae conniventes.

32

© Copyright. Society of Diagnostic Medical Sonography. All Rights Reserved.

Inflammatory Bowel Significance

This pattern is a key visual indicator for an acute inflammatory bowel process.

33

Obstruction Significance

This visual marker is essential for accurately identifying small bowel obstruction.

34

© Copyright. Society of Diagnostic Medical Sonography. All Rights Reserved.

Case Challenges

35

What ultrasound sign is demonstrated in this image?



36

© Copyright. Society of Diagnostic Medical Sonography. All Rights Reserved.

This is the WES Sign, indicating contracted gallbladder packed full of gallstones.

37

What ultrasound sign is demonstrated in this image?

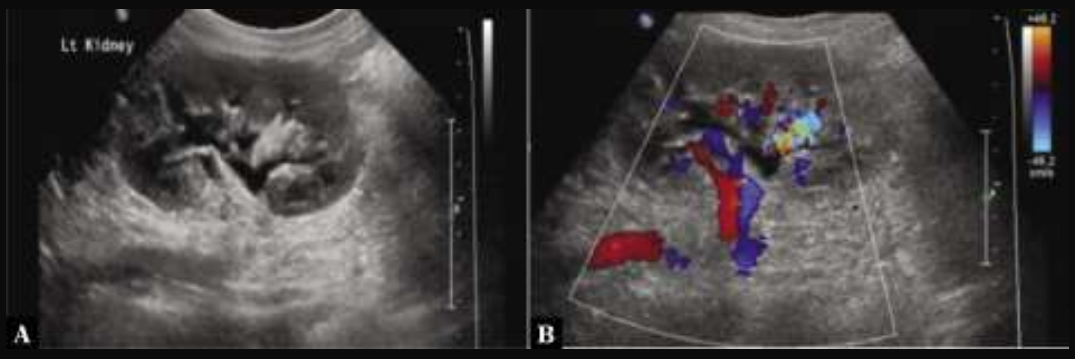

Image 17

38

© Copyright. Society of Diagnostic Medical Sonography. All Rights Reserved.

This is the twinkle sign, indicating kidney stone.

39

What ultrasound sign is demonstrated in this image?



Image 18

40

© Copyright. Society of Diagnostic Medical Sonography. All Rights Reserved.

This is the sandwich sign, indicating enlarged lymph nodes in the mesentery of the abdomen.

41

What ultrasound sign is demonstrated in this image?

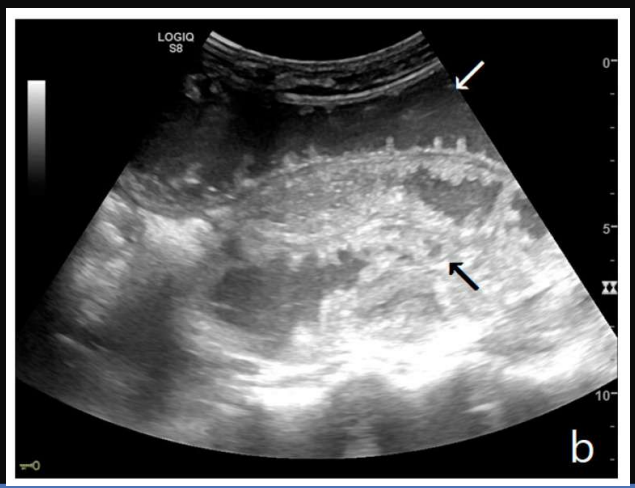

Image 19

42

© Copyright. Society of Diagnostic Medical Sonography. All Rights Reserved.

This is the keyboard sign, indicating small bowel obstruction.

43

Final Takeaways

- Ultrasound signs help us recognize pathology faster, but they should never replace clinical judgment.
- Pattern recognition becomes more powerful when it is combined with patient history, symptoms, and laboratory findings.
- A classic sonographic sign is a clue, not a diagnosis.
- Understanding the clinical significance behind a sign helps improve diagnostic confidence and efficiency.
- The more patterns you recognize, the more effective and confident you become as a sonographer.

.

44

© Copyright. Society of Diagnostic Medical Sonography. All Rights Reserved.

References Images

Image 1. Emory School of Medicine. Mickey Mouse View of Portal Triad. 2026.

Image 2. Lim AKP, ed. *Abdominal Ultrasound: Step by Step.* Singapore: Springer Nature; 2021. Chapter 10, Ultrasonography of the Liver.

Image 3. Kuo J. Ultrasound Liver Right Lobe and Right Kidney. 2011.

Image 4. From personal files of García Santiago NY. (on file with author).

Image 5. From personal files of García Santiago NY. (on file with author).

45

References Images

Image 6. Cylindric. Ultrasound Image of Pancreas. 2011.

Image 7. Mostbeck G. *How to Diagnose Acute Appendicitis: Ultrasound First.* 2016.

Image 8. Academic Life in Emergency Medicine. Pseudokidney Sign (Intussusception). 2019.

Image 9, Image 16. Ehsani-Nia H, Toohey S. Cholelithiasis: WES Sign. *JETem.* 2017;2(1):V1-4.

Image 10. Di Serafino M, Severino R, Gioioso M, Rossi E, Vezzali N, Pelliccia P, Caprio MG, Acampora C, Iorio R, Vallone G. *Paediatric liver ultrasound: a pictorial essay. J Ultrasound.* 2020;23(1):87-103

46

© Copyright. Society of Diagnostic Medical Sonography. All Rights Reserved.

References Images

Video 1. Gillman L, Ball C, Panebianco N, Al-Kadi A, Kirkpatrick A. Clinician performed resuscitative ultrasonography for the initial evaluation and resuscitation of trauma. *Scand J Trauma Resusc Emerg Med.* 2009;17:34

Image 11. ElBeialy MA. Hepatic Hydatid Cyst: Water Lily Sign. Radiopaedia. 2015.

Image 12. The Radiology Assistant. *US of the GI Tract: Normal Anatomy.*

Image 13, Image 18. Patel M. Hamburger Sign (Lymphoma). Radiopaedia. 2021.

Image 14, Image 17. El-Shabrawi M. Twinkle Artifact in Renal Ultrasound. 2021.

Image 15, Image 19. Alobaidi M. *Ultrasound of Small Bowel Obstruction: A Pictorial Review.* 2021.

References

Rumack CM, Wilson SR, Charboneau JW, Levine D, eds. *Diagnostic Ultrasound*. 5th ed. Elsevier; 2018.

Hagen-Ansert SL. *Textbook of Diagnostic Sonography*. 9th ed. Elsevier; 2018.

American Institute of Ultrasound in Medicine. *Practice Parameters and Clinical Standards*. AIUM.

The Radiology Assistant. *US of the GI Tract: Normal Anatomy.*

Di Serafino M, Severino R, Gioioso M, Rossi E, Vezzali N, Pelliccia P, Caprio MG, Acampora C, Iorio R, Vallone G. Paediatric liver ultrasound: a pictorial essay. *J Ultrasound*. 2020;23(1):87-103.

© Copyright. Society of Diagnostic Medical Sonography. All Rights Reserved.

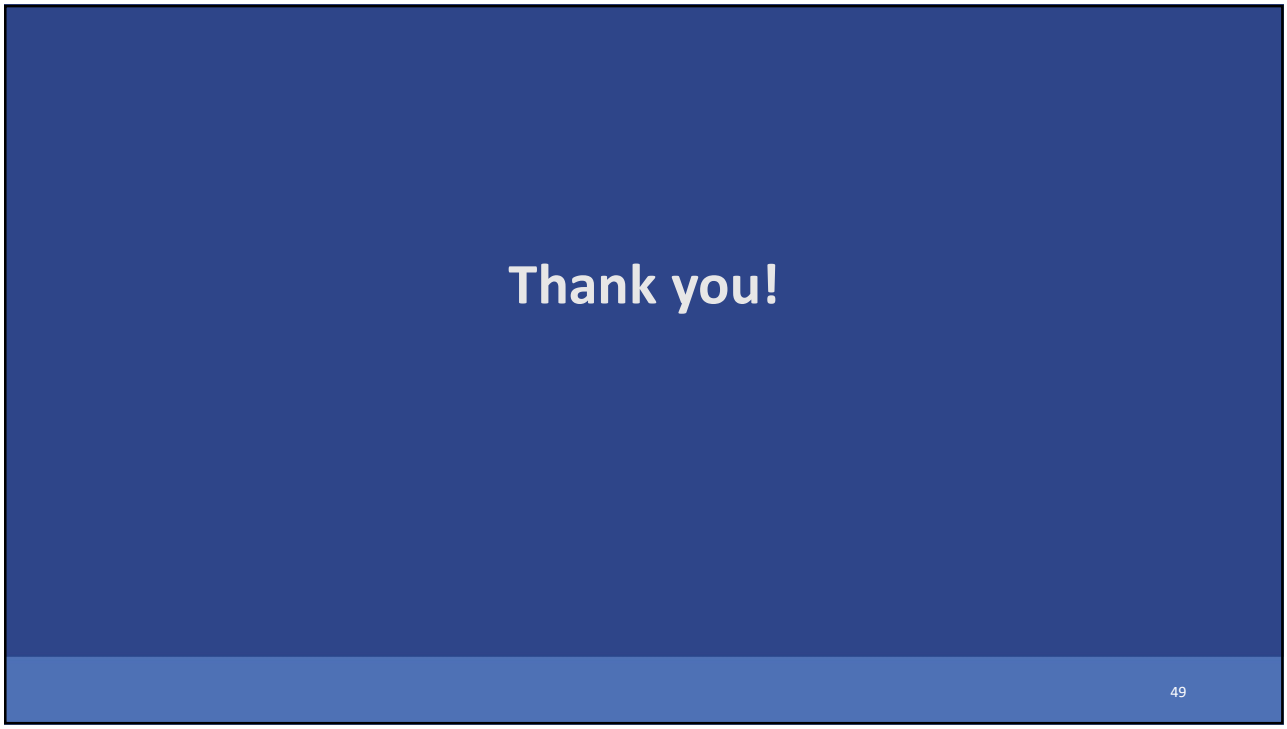

49

© Copyright. Society of Diagnostic Medical Sonography. All Rights Reserved.