Echo Assessment of the Aorta: From Root to Bifurcation

Pamela Burgess, BS, ACS, RDCS, RDMS, RVT, FASE
Atrium Health – Wake Forest Baptist
Winston Salem, NC

1

SPEAKER PRESENTATION DISCLAIMER

The content and views presented are made available for educational purposes only. The information presented are the opinions of the presenter and do not necessarily represent the views of the Society of Diagnostic Medical Sonography (SDMS) or its affiliated organizations, officers, Boards of Directors, or staff members.

The presenter is responsible for ensuring balance, independence, objectivity, scientific rigor, and avoiding commercial bias in their presentation. Before making the presentation, the presenter is required to disclose to the audience any relevant financial interests or relationships with manufacturers or providers of medical products, services, technologies, and programs.

The SDMS and its affiliated organizations, officers, Board of Directors, and staff members disclaim any and all liability for all claims that may arise out of the use of this educational activity.

2

© Copyright. Society of Diagnostic Medical Sonography. All Rights Reserved.

Objectives

- Trace the anatomical segments of the aorta
- Review standard Transthoracic (TTE) and Transesophageal (TEE) echo windows.
- Understand normative dimensions and measurement techniques.
- Identify key pathologies (aneurysm, dissection, coarctation).

3

Ascending Aorta to bifurcation

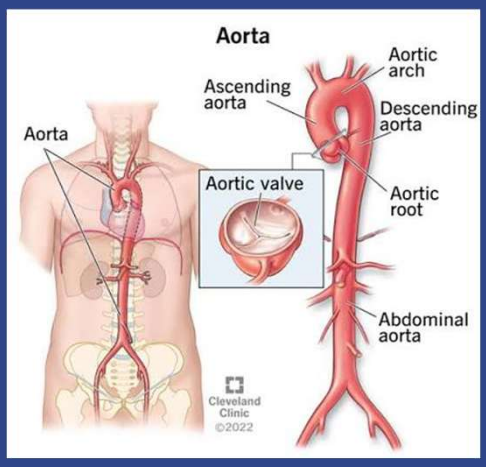

- **Ascending Aorta:** Courses superiorly and rightwards
- **Aortic Arch:** Forms an arch at the SSN
- **Descending Thoracic Aorta:** Runs posterior to the heart and diaphragm.
- **Abdominal Aorta & Bifurcation:** The division into the right and left common iliac arteries.

4

© Copyright. Society of Diagnostic Medical Sonography. All Rights Reserved.

Aortic Root

- **Ventriculo-aortic junction (Annulus):** The basal attachment point.
- **Aortic valve:** Trileaflet structure and leaflets.
- **Sinuses of Valsalva:** Bulges behind the cusps housing the coronary ostia.
- **Sinotubular junction (STJ):** The transition from the root to the tubular aorta.

5

Aortic root

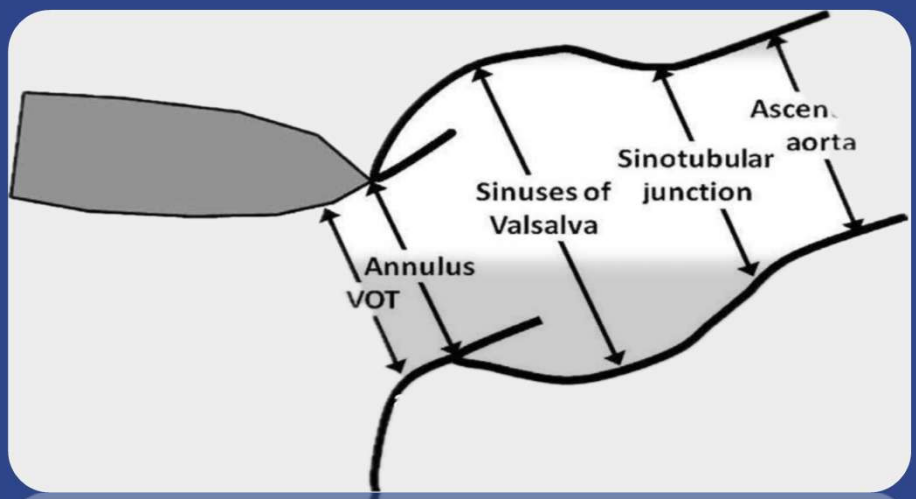

6

© Copyright. Society of Diagnostic Medical Sonography. All Rights Reserved.

TTE vs TEE

- **Transthoracic Echocardiography (TTE):**
  - Ideal for root, ascending aorta, and proximal arch
- **Transesophageal Echocardiography (TEE):**
  - Provides superior near-field resolution.
  - Excellent for comprehensive assessment of the thoracic aorta (aortic root to the proximal descending aorta)

7

Aorta TTE vs TEE

TTE Image

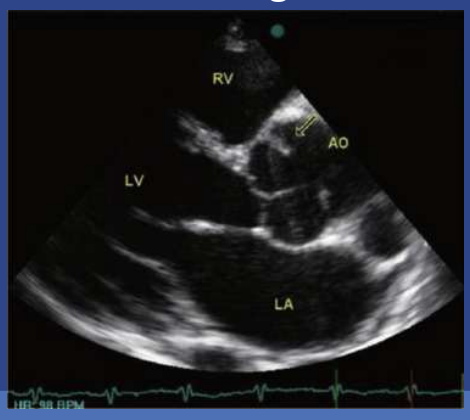

TEE Image

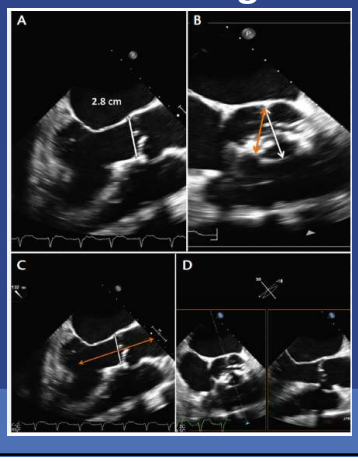

8

© Copyright. Society of Diagnostic Medical Sonography. All Rights Reserved.

Standard TTE views

- **Parasternal Long Axis (PLAX):** Best for evaluating the Normal aortic valve, annulus, sinuses of Valsalva, and STJ.
- **Parasternal Short Axis (PSAX):** Visualizes trileaflet/bicuspid aortic valve anatomy
- **Suprasternal Notch:** Visualizes the aortic arch and its branching vessels.
- **Subcostal View:** Assesses the abdominal aorta

9

TTE Image PLAX

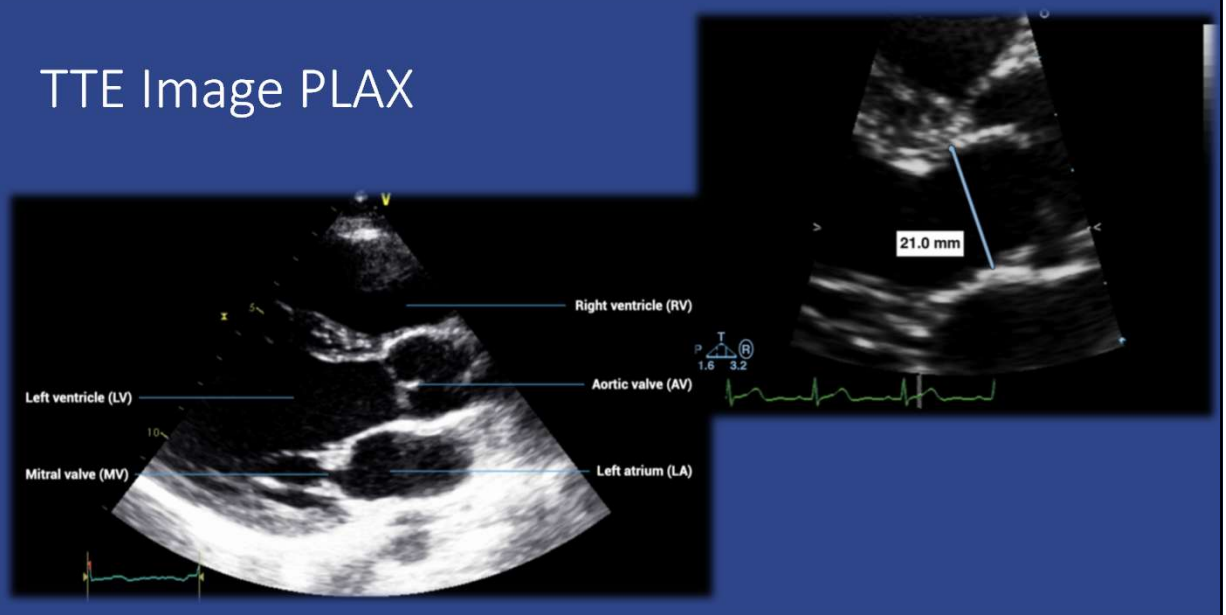

10

© Copyright. Society of Diagnostic Medical Sonography. All Rights Reserved.

Guidelines for aortic measurements

- **Timing of measurement:** End-diastole - Adults (when the root moves the least) or End-systole Pediatrics
- **Measurement method:** Inner edge to inner edge (for annulus) and leading edge to leading edge (for aortic walls).
- **Measurement level:** Annulus, Sinuses of Valsalva, Sinotubular Junction, Tubular Ascending Aorta

11

Aortic root measurements
Leading edge to leading edge

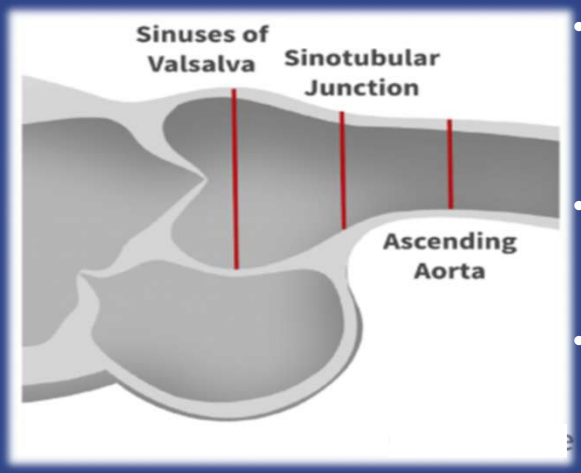

- **Sinuses of Valsalva**: Measured at the widest or middle, maximum diameter of the three sinuses, typically perpendicular to the aortic root.
- **Sinotubular Junction (STJ)**: The point where the sinuses transition into the tubular ascending aorta.
- **Ascending Aorta**: Measured in the tubular portion, typically 1–2 cm above the STJ.

12

© Copyright. Society of Diagnostic Medical Sonography. All Rights Reserved.

TTE aortic root measurement

- Parasternal Long Axis
- Leading edge to leading edge
- End diastole
- Measured at the maximum curvature of the right and non coronary aortic sinuses

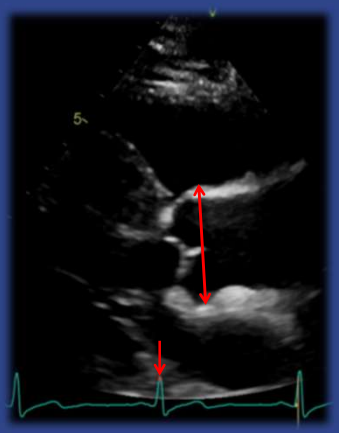

13

IAC TTE standards – Aortic measurements

1. Aorta at the level of the sinuses of Valsalva;
2. measurements of sinotubular junction and
3. mid-ascending, <u>as clinically indicated</u>

Clinically indicated:

*Dilated ascending aorta

*Bicuspid aortic valve

*Any aortic abnormality

IAC Standards and Guidelines for Adult Echocardiography Accreditation; intersocietal.org/programs/echocardiography/. Apri 2025

14

© Copyright. Society of Diagnostic Medical Sonography. All Rights Reserved.

LVOT MEASUREMENT

- PLAX View
- Zoomed image
- Mid-Systole
- Inner edge to Inner edge
- Septal endocardium to Anterior MVL
- Within 0.5-1.0 cm of the aortic valve orifice



15

TTE image ascending aorta

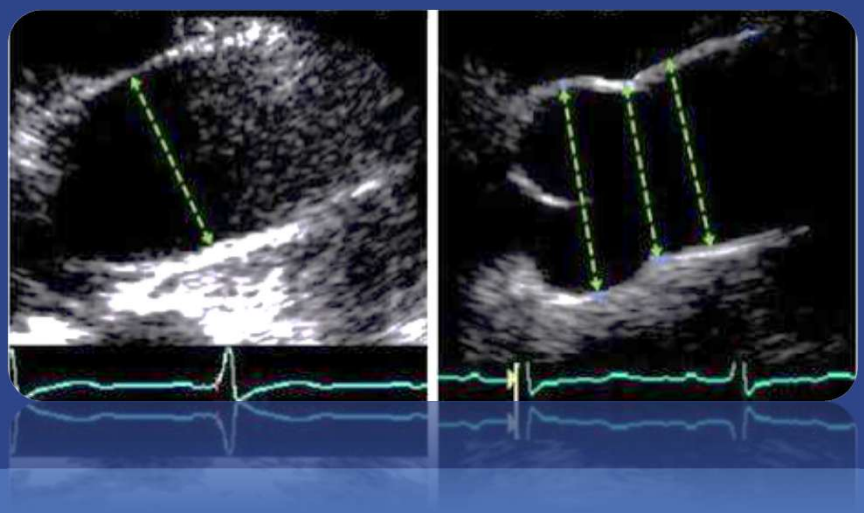

16

© Copyright. Society of Diagnostic Medical Sonography. All Rights Reserved.

AORTIC ROOT NORMAL VALUES

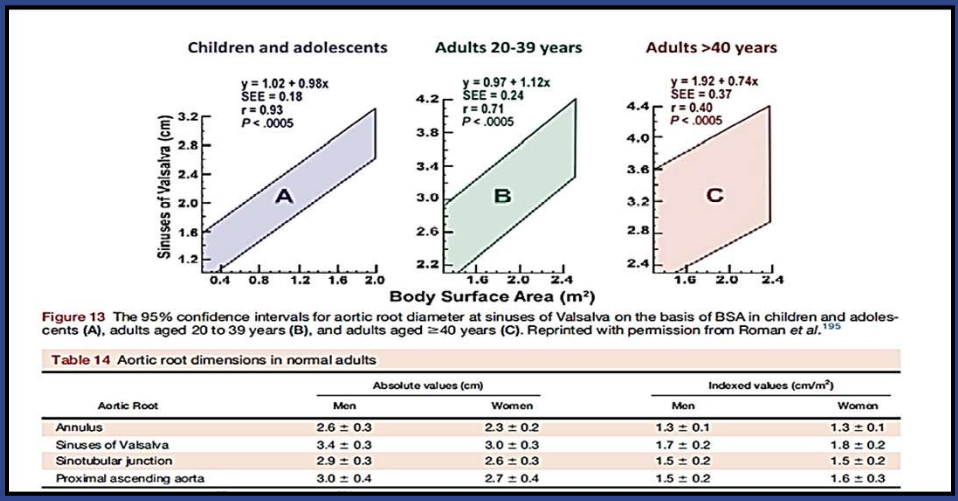

Figure 13 The 95% confidence intervals for aortic root diameter at sinuses of Valsalva on the basis of BSA in children and adolescents (A), adults aged 20 to 39 years (B), and adults aged ≥40 years (C). Reprinted with permission from Roman *et al.*[195]

Table 14 Aortic root dimensions in normal adults

	Absolute values (cm)		Indexed values (cm/m²)	
Aortic Root	Men	Women	Men	Women
Annulus	2.6 ± 0.3	2.3 ± 0.2	1.3 ± 0.1	1.3 ± 0.1
Sinuses of Valsalva	3.4 ± 0.3	3.0 ± 0.3	1.7 ± 0.2	1.8 ± 0.2
Sinotubular junction	2.9 ± 0.3	2.6 ± 0.3	1.5 ± 0.2	1.5 ± 0.2
Proximal ascending aorta	3.0 ± 0.4	2.7 ± 0.4	1.5 ± 0.2	1.6 ± 0.3

Roman MJ, et al. Two-dimensional Echocardiographic Aortic Root Dimensions in Normal Children and Adults, Am J Cardiol 1989;64:507-512

17

MEASUREMENT ISSUES WE ENCOUNTER

Image Quality

Calcifications

- Attenuation
  - Shadow that blocks the structures below the calcification
- Acoustic Blooming
  - A structure (calcification) outshines adjacent weaker signal

18

© Copyright. Society of Diagnostic Medical Sonography. All Rights Reserved.

TTE Image SSN

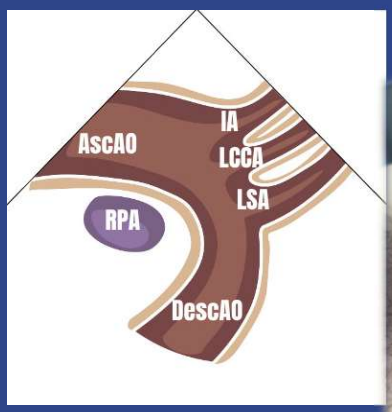





19

IAC Required views - SSN view & Doppler

- 1.6.1.1B Complete examination – aortic arch
  - 1.6.1.2B Complete Doppler Study: Includes spectral Doppler and/or color flow interrogation of all normal and abnormal flows within the heart including the valves, the great vessels and the atrial and ventricular septa.
- 1.6.2.1B, xiii Suprasternal notch view.

IAC Standards and Guidelines for Adult Echocardiography Accreditation; intersocietal.org/programs/echocardiography/. Apri 2025

20

© Copyright. Society of Diagnostic Medical Sonography. All Rights Reserved.

SSN Views

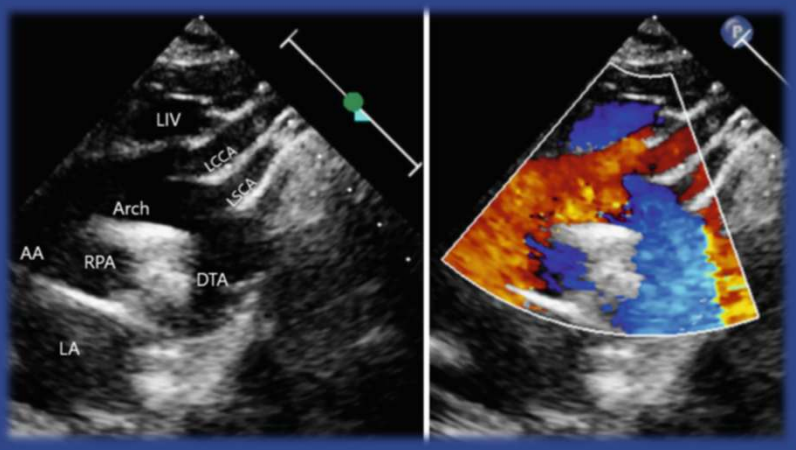

21

SSN Doppler Descending Aorta

Pulsed Wave Doppler

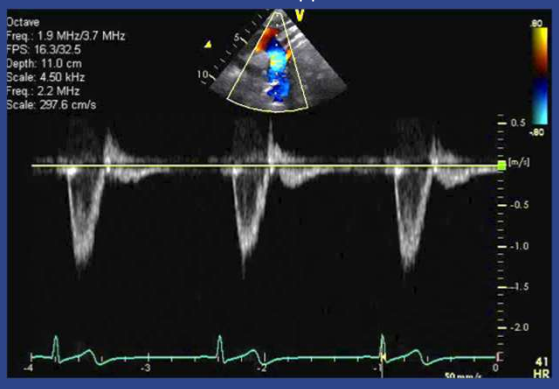

Continuous Wave Doppler

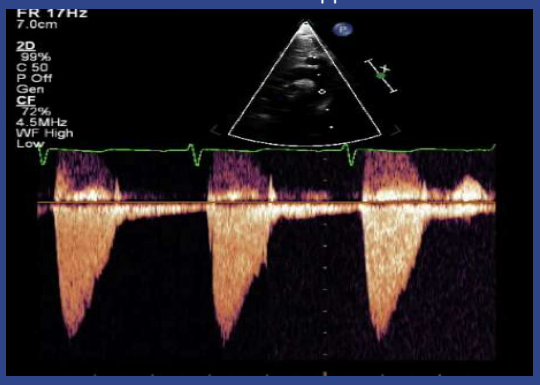

22

© Copyright. Society of Diagnostic Medical Sonography. All Rights Reserved.

TTE image Descending Aorta from Apical View

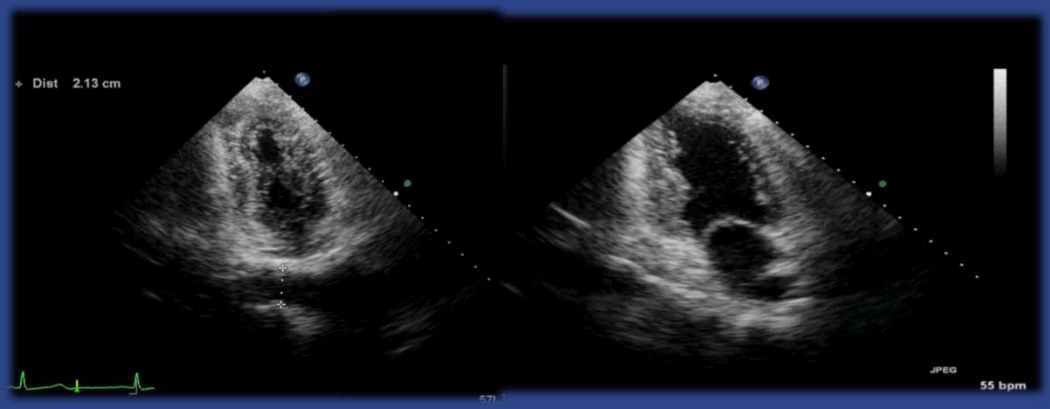

23

TTE Abdominal Aorta



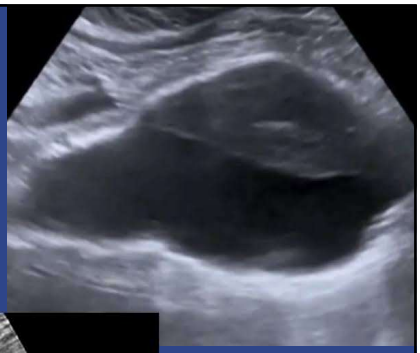

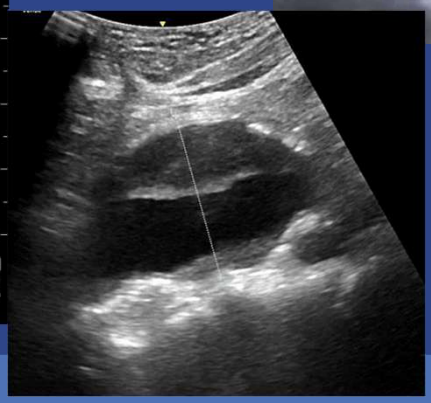

24

© Copyright. Society of Diagnostic Medical Sonography. All Rights Reserved.

Standard TEE views for aorta

- **Aortic Valve Long-Axis:** Equivalent to TTE PLAX.
- **Ascending Aorta Long & Short- Axis:** Sweeps the ascending aorta.
- **Desc Aorta Long & Short-Axis:** Visualizes the descending thoracic aorta down to the diaphragm

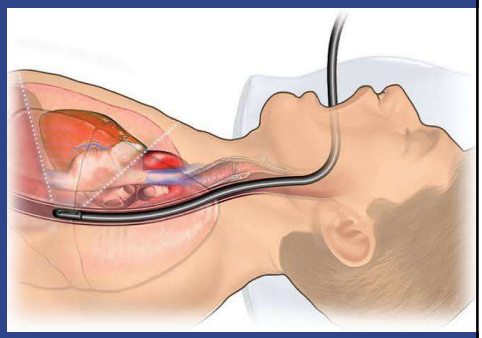

25

TEE aortic root measurement

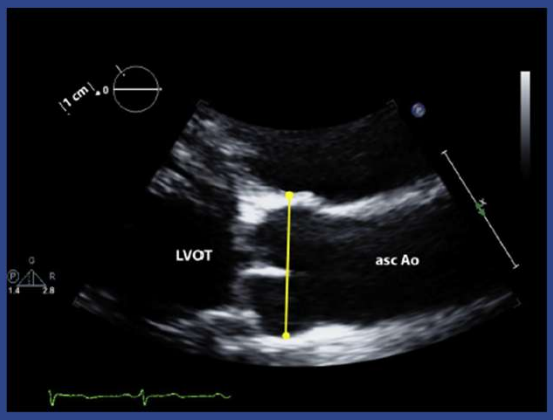

26

© Copyright. Society of Diagnostic Medical Sonography. All Rights Reserved.

Echo Imaging of the Coronary Arteries

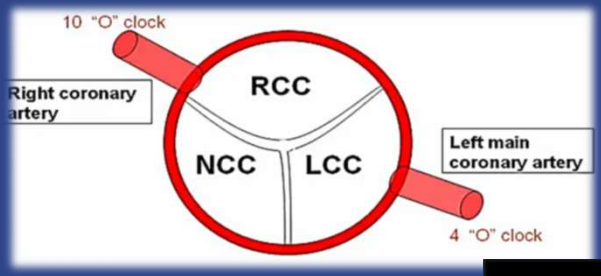

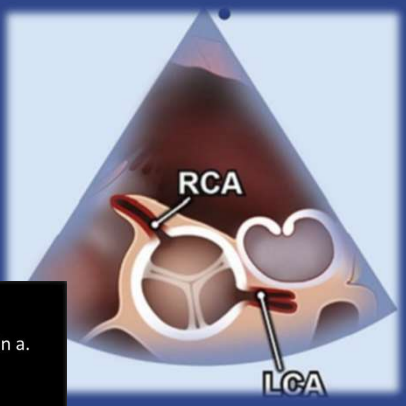

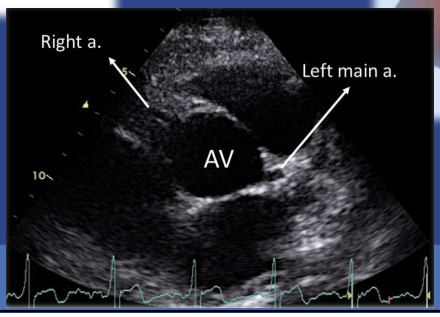

27

Tips on Imaging the Coronaries

- Utilize the **PSAX view** for the left main and Prox LAD and RCA
- **Modified Views-Slide** into a higher intercostal space (2nd & 3rd)
- **3D or X-Plane** – Utilize X-plane features to view SAX and LAX simultaneously
- **Lower Dynamic Range** will enhance between the vessel wall & blood pool
- **Decrease Nyquist Limit** to ~20 cm/s to see slow, diastolic coronary flow
- **Minimize the Color Box** over the target area
- **Manage Color gain** – up until it sparkles and then down until the sparkles go away

28

© Copyright. Society of Diagnostic Medical Sonography. All Rights Reserved.

Pathology of the Aortic Root & Valve

- **Dilatation / Aneurysm:** Root dilation > 4.0 cm (e.g., Marfan syndrome).
- **Aortic Stenosis (AS):** Leaflet calcification, bicuspid morphology.
- **Aortic Regurgitation (AR):** Dilated root leading to coaptation failure

29

Uni, Bi, Or Quad??

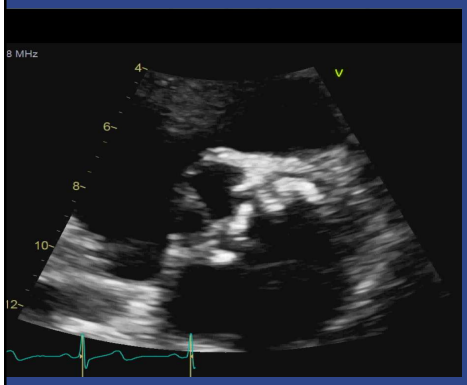

Unicuspid

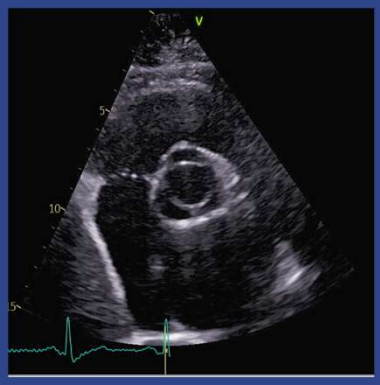

Bicuspid

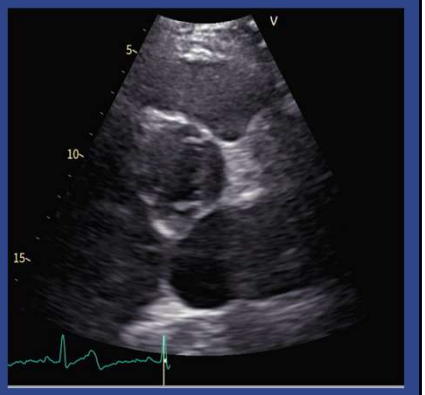

Quadracuspid

30

© Copyright. Society of Diagnostic Medical Sonography. All Rights Reserved.

Dilatation of the Aorta

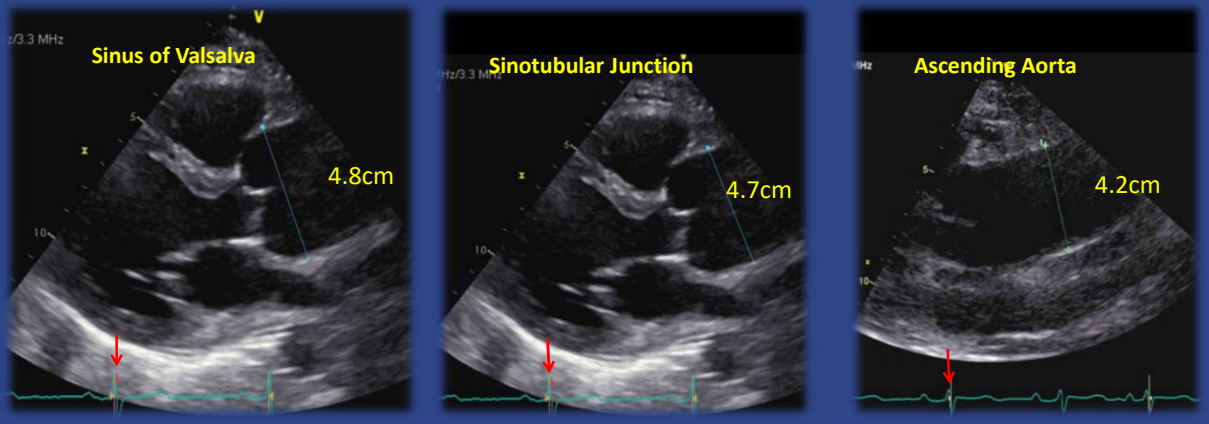

31

Aortic Aneurysm

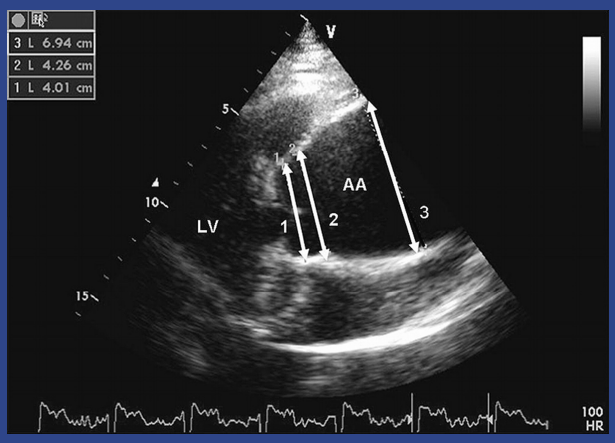

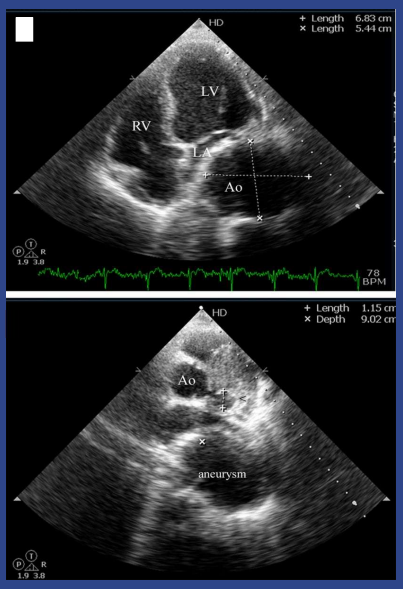

32

© Copyright. Society of Diagnostic Medical Sonography. All Rights Reserved.

Aortic Stenosis



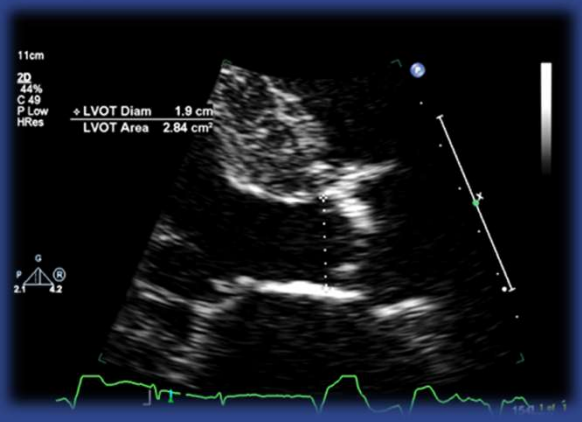

33

PedOff Doppler Views for Aortic Stenosis

- Apical 5 chamber
- Right Sternal Border
- Supra Sternal Notch
- Subcostal
- Right Supra Clavicular

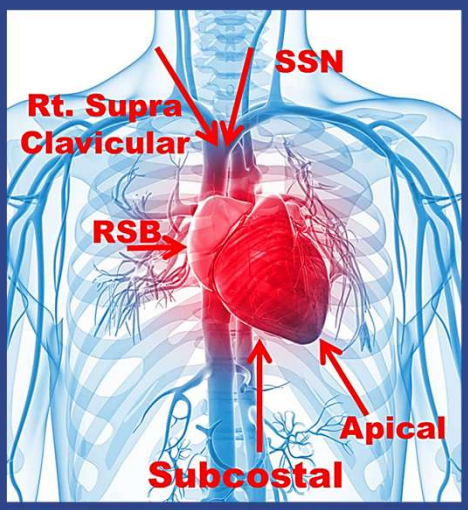

34

© Copyright. Society of Diagnostic Medical Sonography. All Rights Reserved.

Pedof views

No imaging capabilities
- Blind Doppler assessment
- Difficult to find aortic gradient at times
- Can be confusing with other Doppler signals

Big learning curve
- Sonographers are visual

Most important reason…
- Correctly identify the highest aortic gradient

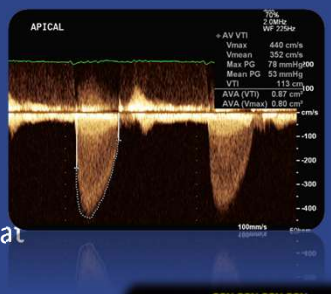



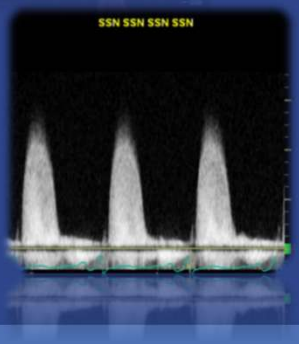

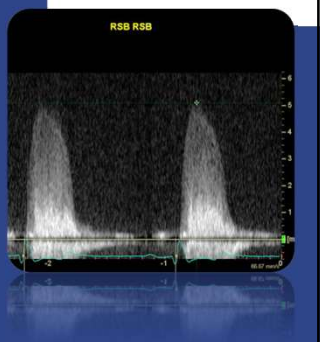

35

Assessment of Max Velocity & Mean Gradient

- Use of multiple windows is required to avoid underestimation of gradient
- Use of non-imaging probe useful in optimizing alignment
- Max velocity was obtained from outside apical window in 61% of patients
- Avoiding the non-apical windows can result in underestimation of AS severity in 23% of patients

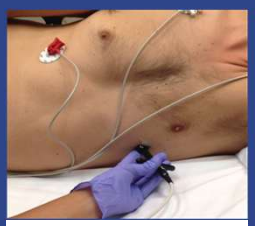
Apical

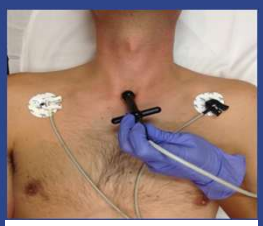
Supra Sternal Notch


Right Sternal Border


Right Supra Clavicular

Thaden JJ, et al. *J AM Soc Echocardiogr.* 2015; 28: 780-785

36

© Copyright. Society of Diagnostic Medical Sonography. All Rights Reserved.

Pedof Assessment of Aortic Valve

- "Blind CW" may need differentiate between MR and AS gradients
- Differentiate with timing of these signals
  - Pre-ejection period prior to the Aortic Velocity begins in contrast to MR
- Remember apical imaging probe velocities
- Remember appearance of waveform
- Make sure your Doppler makes sense!

37

Aortic Regurgitation

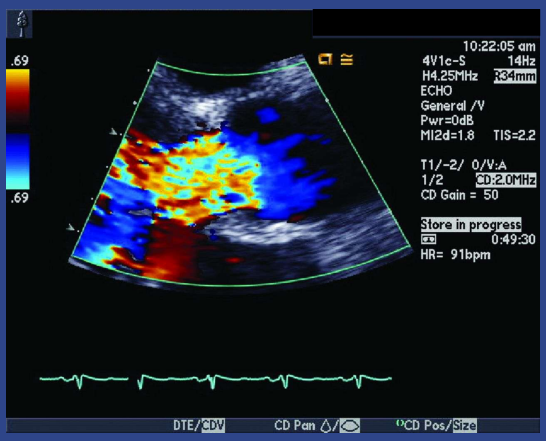

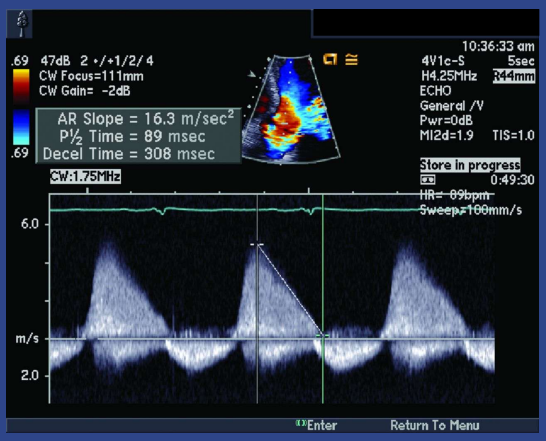

38

© Copyright. Society of Diagnostic Medical Sonography. All Rights Reserved.

Holodyastolic Flow reversal in descending aorta

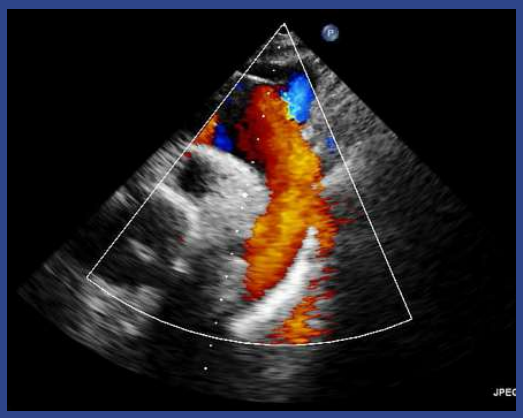

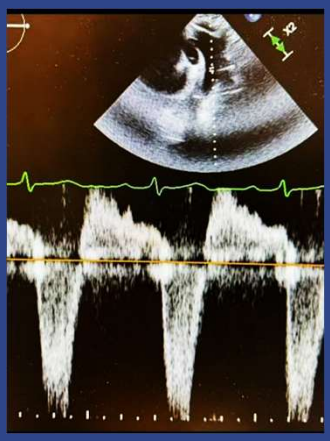

39

Aorta Pathology: Ascending to Bifurcation

- **Aortic Dissection:** Intimal flap separating the true and false lumens
- **Atherosclerotic Plaques:** Evaluation of thickness and ulceration
- **Coarctation:** Narrowing typically near the aortic isthmus

40

© Copyright. Society of Diagnostic Medical Sonography. All Rights Reserved.

Aortic Dissection

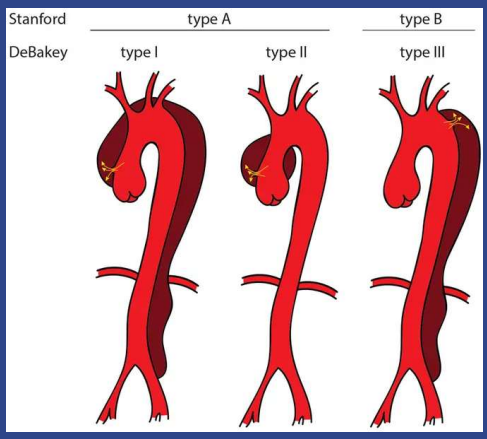

- Occurs due to an injury to the innermost layer of the aorta allows blood to flow between the layers of the aortic wall, forcing the layers apart
- Sudden onset of severe chest or back pain
- Other symptoms-stroke, lower extremity ischemia or mesenteric ischemia

https://aorticdissectionawareness.org/healthcare-professionals/aortic-dissection

41

Abdominal Aortic Dissection

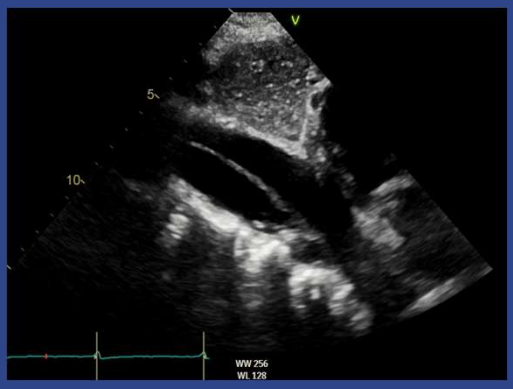



42

© Copyright. Society of Diagnostic Medical Sonography. All Rights Reserved.

Abdominal Aortic Dissection





43

Thoracic Aortic Dissection

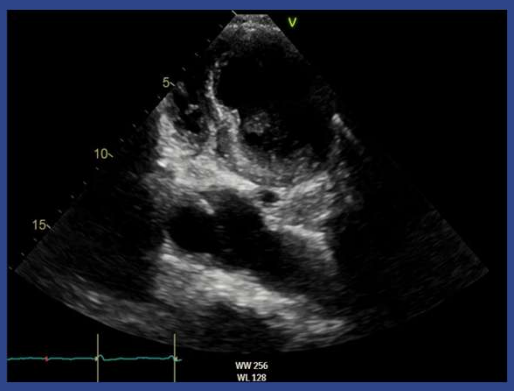



44

© Copyright. Society of Diagnostic Medical Sonography. All Rights Reserved.

Aortic Dissection TTE

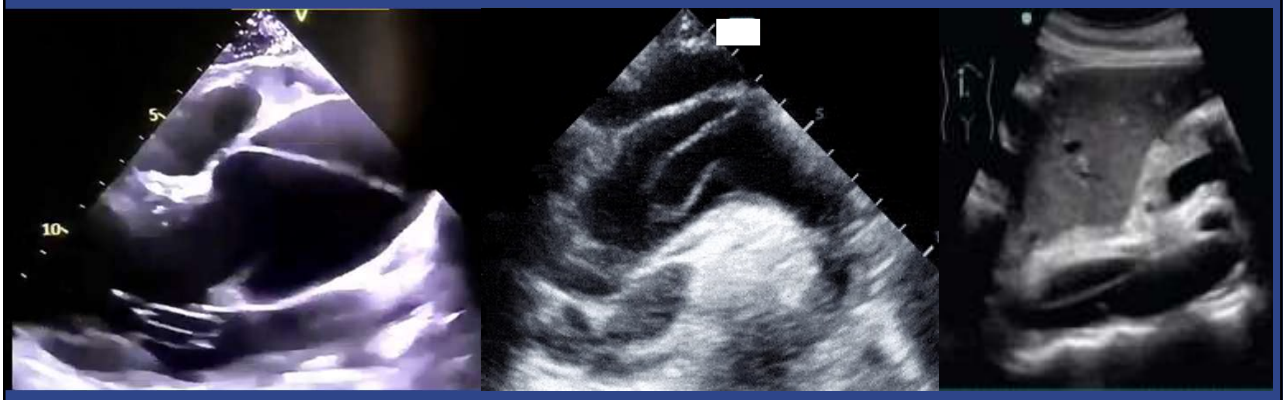

45

Subcostal Imaging



46

© Copyright. Society of Diagnostic Medical Sonography. All Rights Reserved.

R/O Aortic Dissection

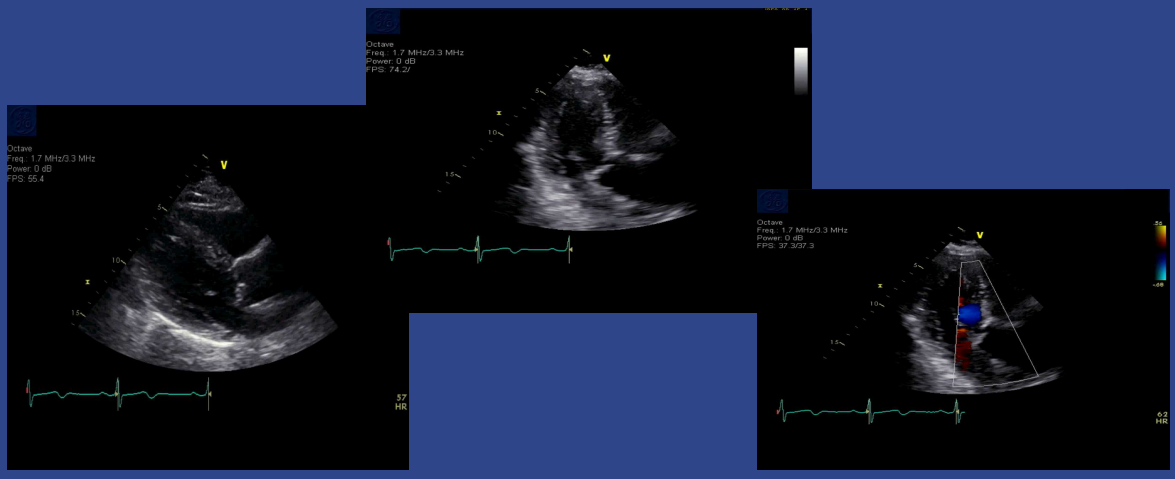

47

Aortic dissection RSB view

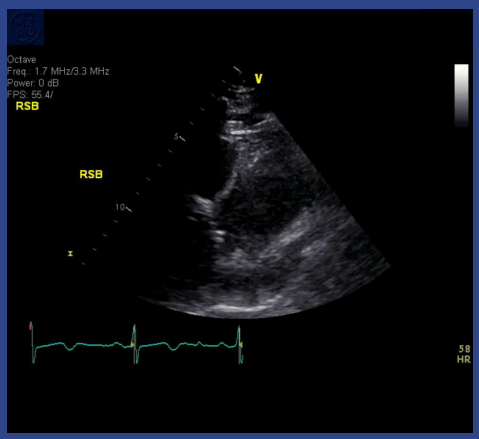

- Position patient in the right lateral decubitus position
- Place the transducer on the 2nd or 3rd intercostal space to the right of sternum
- Marker towards the patient's shoulder or clavicle
- Angle beam toward the long axis of the proximal ascending aorta
- Very small "fans" or "tilts" to find best window and image aorta

48

© Copyright. Society of Diagnostic Medical Sonography. All Rights Reserved.

Atherosclerotic Plaques

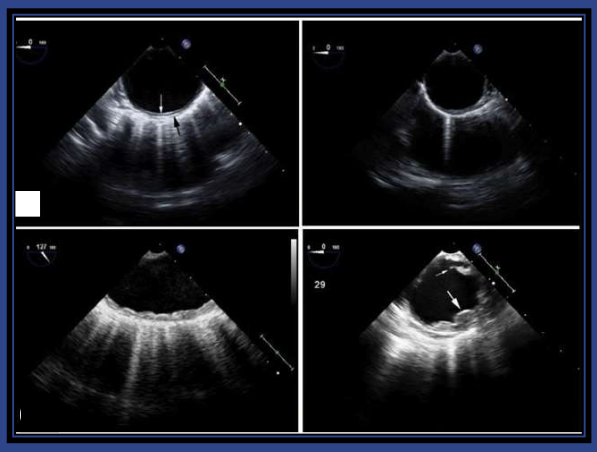

49

Coarctation

- Narrowing of the proximal descending aorta, most commonly just distal to the left subclavian artery
- Elevated Doppler velocities across the coarctation site
- Continuous diastolic flow (Tailing)
- Upper extremity hypertension
- LV hypertrophy from chronic pressure overload
- Associated with:
  - Bicuspid aortic valve
  - VSD
  - PDA
  - Turner syndrome

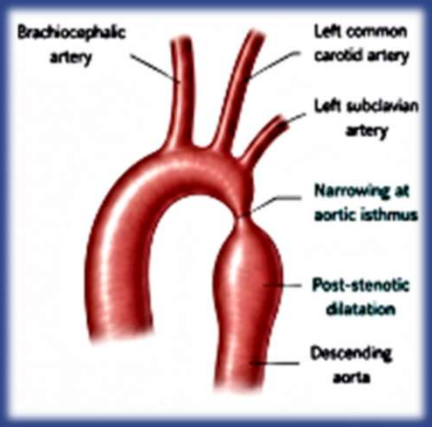

50

© Copyright. Society of Diagnostic Medical Sonography. All Rights Reserved.

Coarctation

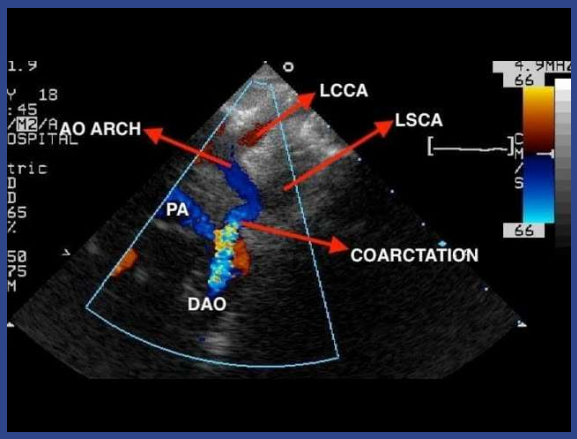

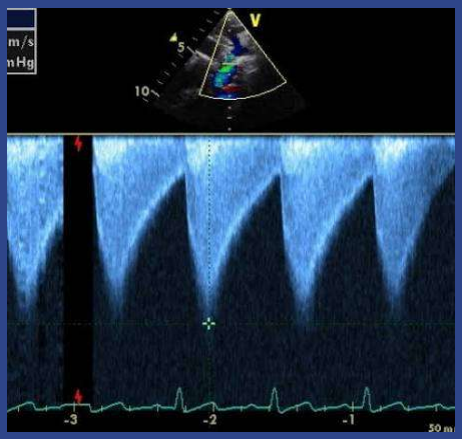

51

Summary

- Multimodality imaging is critical for complete assessment.
- Standardized views (TTE and TEE) provide crucial structural and hemodynamic data
- Attempt off axis and non-standard views to evaluate for pathology
- Accurate, reproducible measurements are vital for tracking disease progression

52

© Copyright. Society of Diagnostic Medical Sonography. All Rights Reserved.