Echo Evaluation of Infiltrative Cardiomyopathies

Pamela Burgess, BS, ACS, RDCS, RVT, RDMS, FASE
Atrium Health Wake Forest Baptist

1

SPEAKER PRESENTATION DISCLAIMER

The content and views presented are made available for educational purposes only. The information presented are the opinions of the presenter and do not necessarily represent the views of the Society of Diagnostic Medical Sonography (SDMS) or its affiliated organizations, officers, Boards of Directors, or staff members.

The presenter is responsible for ensuring balance, independence, objectivity, scientific rigor, and avoiding commercial bias in their presentation. Before making the presentation, the presenter is required to disclose to the audience any relevant financial interests or relationships with manufacturers or providers of medical products, services, technologies, and programs.

The SDMS and its affiliated organizations, officers, Board of Directors, and staff members disclaim any and all liability for all claims that may arise out of the use of this educational activity.

2

© Copyright. Society of Diagnostic Medical Sonography. All Rights Reserved.

Disclosure

- No disclosures relevant to this presentation.

3

Objectives

- Discuss and provide information on the different types of infiltrative cardiomyopathies.
- Review echo findings and needed protocol extensions for infiltrative cardiomyopathies
- Present case examples of each type of infiltrative cardiomyopathy

4

© Copyright. Society of Diagnostic Medical Sonography. All Rights Reserved.

Overview

- **Definition:**
  - Myocardial diseases caused by the extracellular deposition (infiltrative) or intracellular accumulation (storage) of abnormal substances
- **Primary Consequence:**
  - Increased myocardial mass, leading to restrictive physiology and eventual heart failure
  - **Remember:** There are varying stages of each of these cardiomyopathies!

5

Primary Focus

- Amyloidosis (most common)
- Sarcoidosis
- Fabry Disease
- Hemochromatosis
- Carcinoid

6

© Copyright. Society of Diagnostic Medical Sonography. All Rights Reserved.

Amyloidosis

7

Amyloidosis

- Presence of abnormal amyloid proteins deposited in various organs
- Misfolded protein-flat shape pushing the hydrophobic part to the outside and becomes sticky and clumps
- In the heart, deposits are diffuse, involving the valves, myocardium, interatrial septum, and pericardium.
- Amyloid deposits make the myocardium sparkle
- Usually have low voltage QRS or a pseudo-infarct pattern on ECG

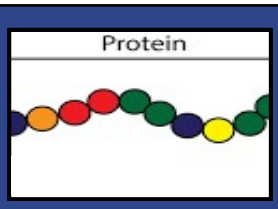

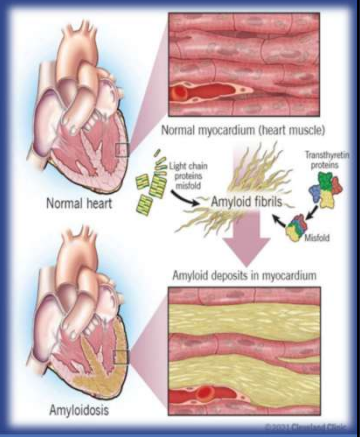

Cleveland Clinic

8

© Copyright. Society of Diagnostic Medical Sonography. All Rights Reserved.

Types of Amyloidosis

AL (Light Chain)	Wild Type (wtATTR)
• Produced by abnormal plasma cells in the bone marrow • Common targets – heart, kidneys, liver, and nerves • Worst prognosis especially when it involves the heart • Progresses much faster with cardiac damage	• More common • Not inherited • Normal TTR proteins misfolding over time due to aging • Over time this builds up of amyloid deposits in various organs • Referred to as “age-related” or “senile” • Tends to affect only the heart

9

Types of Amyloidosis

Hereditary (hATTR)	AA (Secondary)
• Caused by a genetic mutation • Passed down from parent to child • Can present earlier in life (20’s) • Autosomal dominant-means from only one parent • The TTR protein becomes unstable and can misfold from the time it is made-no matter person’s age	• Protein called Serum Amyloid • Linked to long term inflammatory or infectious diseases (rheumatoid arthritis) • Commonly affects the kidneys, liver, and spleen • Most common form of amyloiosis in children

10

© Copyright. Society of Diagnostic Medical Sonography. All Rights Reserved.

Amyloid Type	Systemic Amyloidosis		Transthyretin (TTR) Amyloidosis	
Subtype	AL	AA	ATTRm	ATTRwt
Protein Deposited	Light chain	Amyloid A	Mutated TTR protein	wt TTR monomers
Disease Etiology	Plasma cell dyscrasia with ↑ light chains	Systemic autoimmune or infections	Familial mutation of TTR	Common in elderly aged > 75 years
Specific Features	Kidney, heart and liver affected	Renal dysfunction	V122I common in African Americans	Carpal tunnel; Male dominance
Median Survival	1-3 years	11 years	2 years	4-6 years
Prognostic Factors	Cardiac function, BNP, troponin	Serum AA levels, renal function	Duration, HR>70/min, ↓LVEF	BNP, uric acid, ↓LVEF, ↑ Wall Thickness
Therapy	Chemotherapy ± Stem cell transplant	Treat underlying conditions	Liver ± heart Tx ?siRNA or ASO ?Tafamidis or Diflunisal	?siRNA or ASO ?Tafamidis or Diflunisal

11

When to think Amyloid…

- Males, African descent, older population
- Carpal Tunnel – Especially bilateral (20% associated)
- Aortic Stenosis – 16% correlation; TAVR 20% correlation
- >60 years, but >85 y/o is associated with 20% correlation
- HFpEF – 17% correlation
- Multiple Myeloma
- Sudden cardiac death of family member(s)
- Other signs include:
  - Bicep tendon tear
  - Lumbar stenosis
  - Polyneuropathy

12

© Copyright. Society of Diagnostic Medical Sonography. All Rights Reserved.

Common Symptoms



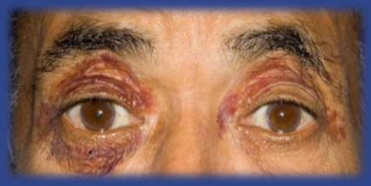

- Serious fatigue and weakness
- Shortness of breath
- Numbness, tingling, or pain in the hands or feet
- Swelling of the ankles and legs
- Additional Symptoms
  - Dizziness & Low BP
  - Diarrhea & Constipation
  - Nausea & loss of appetite with weight loss
  - Enlarged tongue-ripple around edge
  - Skin thickening or easy bruising, and dark or purple patches around eyes

13

Treatment

- Reduce amyloid build up & managing symptoms
- FDA approved meds – some approved for just one type of ATTR
- Works in 2 ways:
  - Keeps the protein from breaking apart and misfolding
  - Gene silencers – reduces how much TTR is made in the liver
- Other treatments for hATTR may include:
  - Treating nerve pain
  - Control heart rate
  - Blood pressure
  - Digestive issues

14

© Copyright. Society of Diagnostic Medical Sonography. All Rights Reserved.

Cardiac amyloidosis

- **Ventricular Changes:** Symmetrical, concentric increase in left ventricular (LV) wall thickness.
- Right ventricular (RV) free wall thickening is a common, highly suggestive "red flag."
- Normal or small LV cavity size

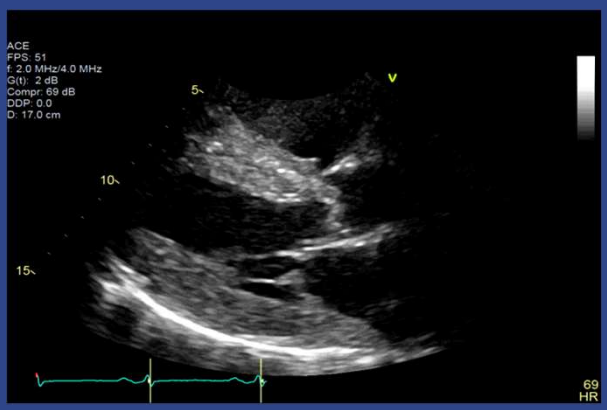

15

Amyloidosis – Myocardial texture

- Often described as **granular, sparkling, or speckled** due to amyloid fibril infiltration
- Myocardial thickening without dilatation of the LV cavity
- Systolic Fx maybe normal until advanced stages



16

© Copyright. Society of Diagnostic Medical Sonography. All Rights Reserved.

Amyloidosis – Valves & Atria

- Biatrial enlargement (due to chronic elevated filling pressures)
- Thickening of the interatrial septum, atrioventricular (AV) valve leaflets, and papillary muscles
- Multivalvular regurgitation
- Small pericardial effusion

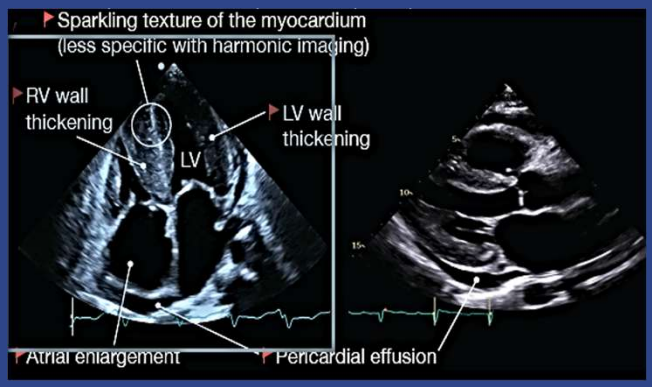

17

Amyloidosis – Doppler findings

- **Early Stages:** Impaired myocardial relaxation; abnormal E/A ratio
- **Advanced Stages: Restrictive filling pattern**:
  - Markedly elevated E/E' ratio.
  - Very short deceleration time (DT ≤ 150 ms).
  - Pulmonary venous flow shows an S/D ratio < 1 (systolic blunting/reversal).
- **Systolic Function:** Ejection Fraction (EF) is characteristically **preserved** until very late stages of the disease

18

© Copyright. Society of Diagnostic Medical Sonography. All Rights Reserved.

Amyloidosis – Doppler

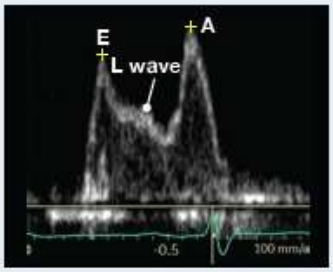

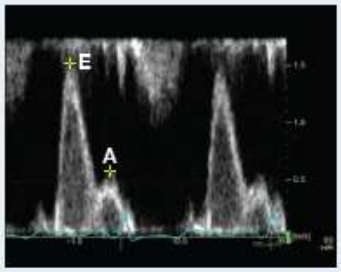

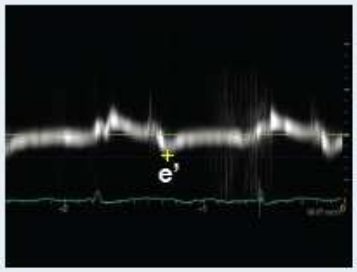

L wave = High Filling Pressure

Restrictive Hemodynamics

Rule of 5
(5-5-5)
All e', a', s' < 5cm/s
Clue to diagnosis of CA

19

Amyloidosis – Strain Imaging

- A crucial tool for differentiating amyloidosis from hypertensive heart disease or hypertrophic cardiomyopathy.

"Apical Sparing" Pattern:

- Hallmark feature of cardiac amyloidosis.
- Markedly reduced **Global Longitudinal Strain (GLS)** in the basal and mid-ventricular segments, with relative preservation (or normal) strain at the apex

20

© Copyright. Society of Diagnostic Medical Sonography. All Rights Reserved.

74 y/o male with longstanding HTN & CHF

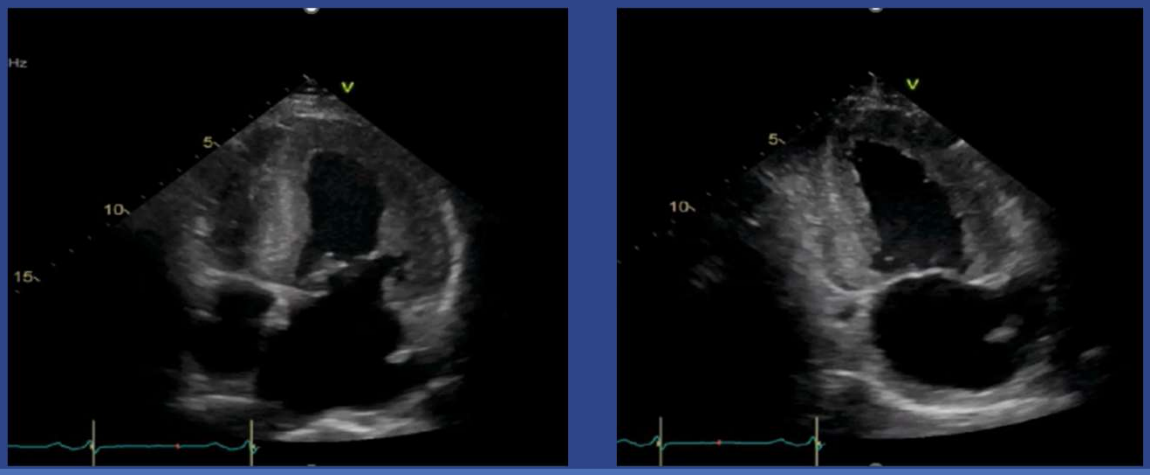

21

Amyloidosis – Strain pattern GLS 8.6%



22

© Copyright. Society of Diagnostic Medical Sonography. All Rights Reserved.

Echo findings

- LVH - >1.2
- Enlarged LA/RA
- Thick valves and Aortic Stenosis
- Diastolic dysfunction (lateral e' <5 and especially 5-5-5 sign for late diagnosis)
- Interatrial septal thickness
- LV with apical sparing
- Cherry on top strain pattern
- Reduced EF
- Elevated PSSP/RVSP
- Atrial Fib
- Pericardial Effusion

23

Key takeaways and red flags

- "Hypertrophy" out of proportion to a history of hypertension.
- Heart failure with preserved ejection fraction (HFpEF) accompanied by thick walls.
- Discordance between low ECG voltages and thick ventricular walls on Echo (highly specific for Amyloidosis).

24

© Copyright. Society of Diagnostic Medical Sonography. All Rights Reserved.

Sarcoidosis

25

Sarcoidosis

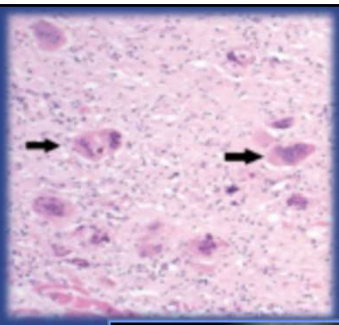

Pathology:
- Characterized by non-caseating granulomas

Echo Phenotype:
- Highly variable; can mimic dilated, restrictive, or ischemic cardiomyopathies



26

© Copyright. Society of Diagnostic Medical Sonography. All Rights Reserved.

Sarcoidosis

- **Regional wall motion abnormalities** that do not correspond to a single coronary artery distribution.
- Thinning or aneurysmal changes, particularly in the basal septum.
- Ventricular arrhythmias (e.g., heart block) are highly prevalent.

27

Cardiac sarcoidosis

- Non-caseating granuloma
- Regional wall motion abnormalities in unusual distribution
- Heart block
- Sudden death



Photo courtesy William Edwards, MD

28

© Copyright. Society of Diagnostic Medical Sonography. All Rights Reserved.

ECHO FEATURES OF CARDIAC SARCOIDOSIS

Echo abnormalities are rare!

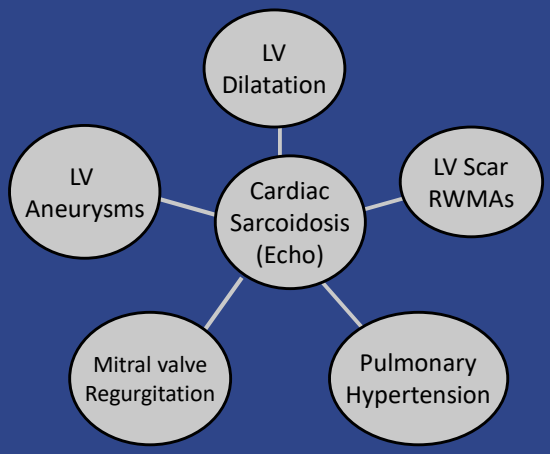

Sekhri V et al. Arch Med Sci 2011

29

SARCOIDOSIS – GRANULOMAS

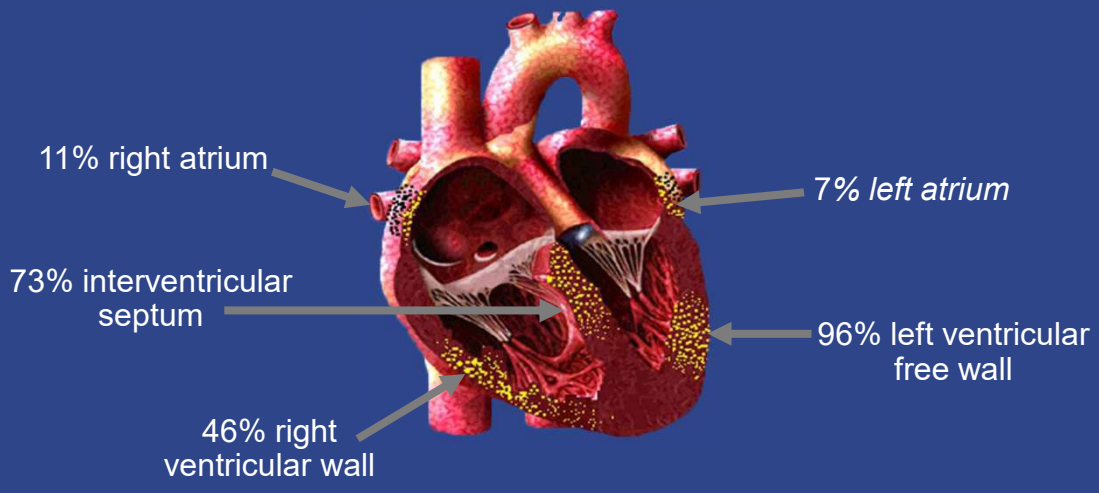

Adapted from Bargout R: Int J Cardio, 2004

30

© Copyright. Society of Diagnostic Medical Sonography. All Rights Reserved.

Echo sarcoidosis: Regional wall motion

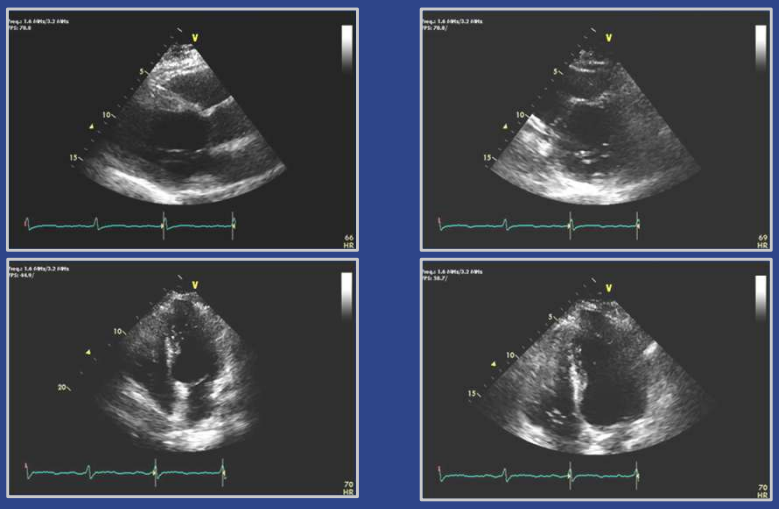

31

Myocardial thinning & aneurysmal walls

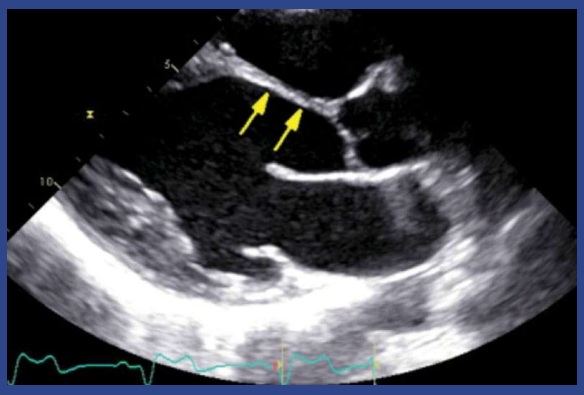

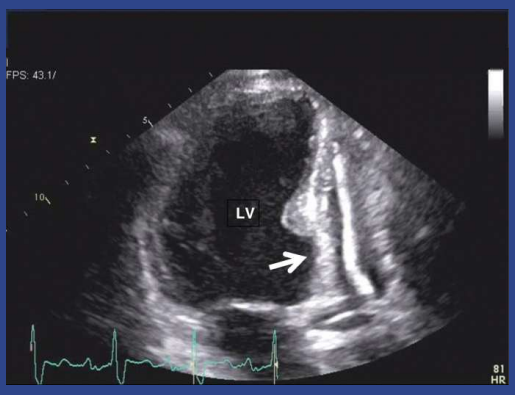

32

© Copyright. Society of Diagnostic Medical Sonography. All Rights Reserved.

Fabry Disease

33

Fabry Cardiomyopathy

- **Genetic disorder**
- **Build up of a certain type of fat in the heart cells (Glycogen Storage)Leading to:**
  - Concentric LV hypertrophy (mimics HCM), often with a unique **papillary muscle hypertrophy**.
  - Reduced strain in the lateral and posterior walls
  - Diastolic dysfunction
  - Arrhythmias
  - Aortic dilatation
  - Valvular disease – Thickening and regurgitation

34

© Copyright. Society of Diagnostic Medical Sonography. All Rights Reserved.

Fabry Cardiomyopathy Echo Findings

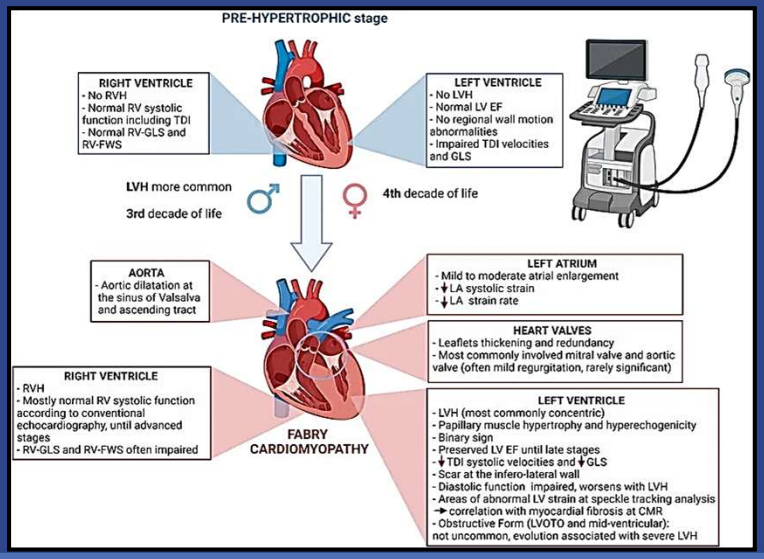

Lillo, R; Pieroni, Pieroni, M; et al 2022 Echocardiography in Anderson-Fabry Disease. Reviews in Cardiovascular Medicine. 23. 201. 10.31083/j.rcm2306201.

35

Concentric hypertrophy – 55 y/o Male
BP 115/63 Moderate LVH

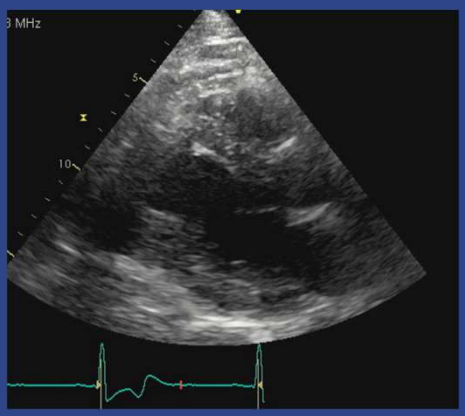

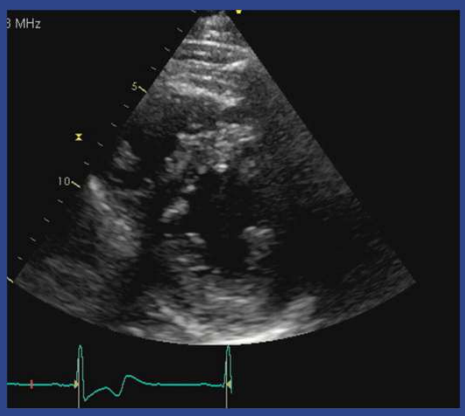

36

© Copyright. Society of Diagnostic Medical Sonography. All Rights Reserved.

Fabry apical 4 & 2

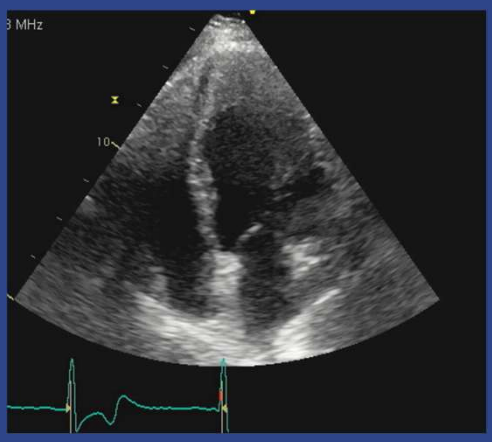

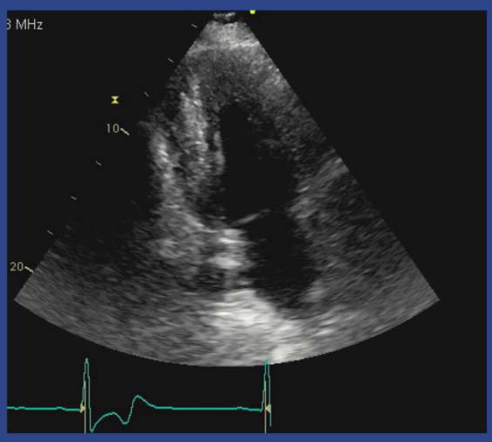

37

Fabry with UEA

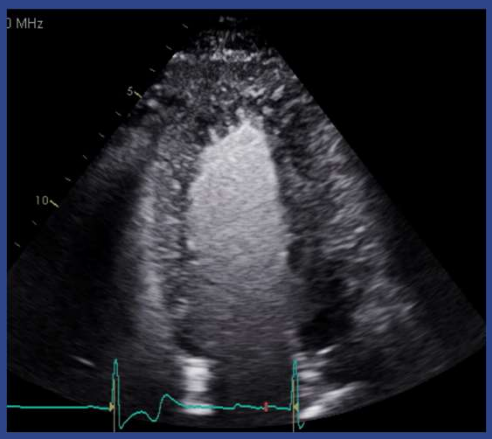

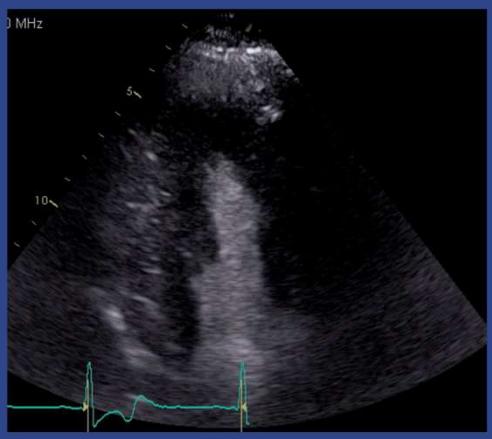

38

© Copyright. Society of Diagnostic Medical Sonography. All Rights Reserved.

Thickened IVS & Papillary muscle

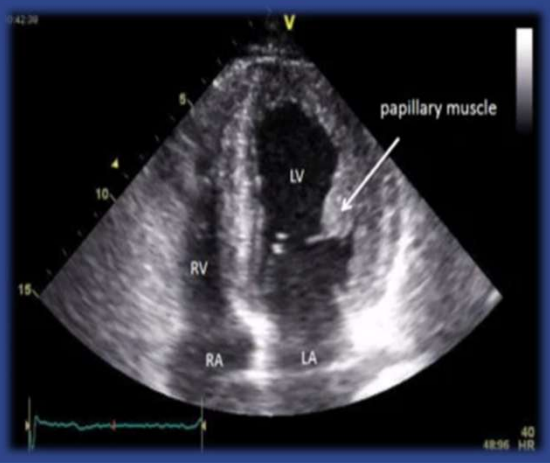

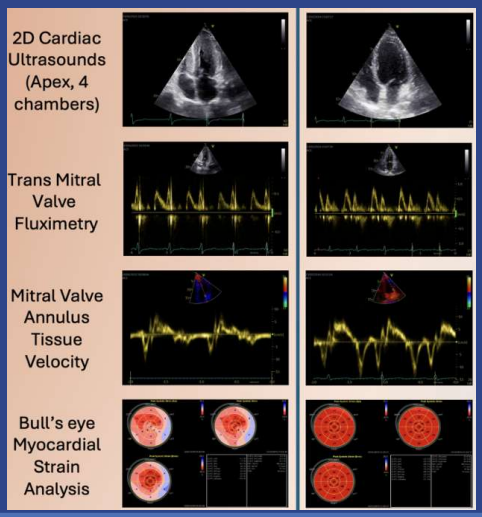

Pande,S; Varzideh,F; et al. Fabry Disease in Cardiomyopathy: A state-of-the-art review. Progress in Cardiovascular Disease 92 (2025) 43-56.

39

Reduced Longitudinal Strain – Basal inferolateral Segment – Characteristic of Fabry CM

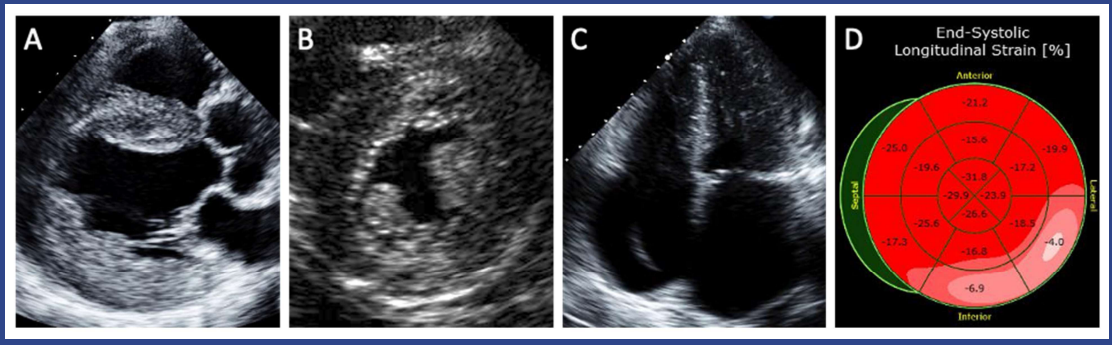

Yim, J; Yau O; et al Fabry Cardiomyopathy: Current Practice and Future Directions. Cells 2021, 10, 1532 https://doi.org/10.3390/cells 1061532

40

© Copyright. Society of Diagnostic Medical Sonography. All Rights Reserved.

Hemochromatosis
Iron Overload

41

What is hemochromatosis?

- The body absorbs and stores too much iron from your diet
- Builds up in major organs
  - Liver
  - Heart
  - Pancreas
- Common Symptoms
  - Tiredness
  - Joint pain, especially in the hands & fingers
  - Abdominal pain
  - Skin color changes (bronze or gray)
  - Weight loss

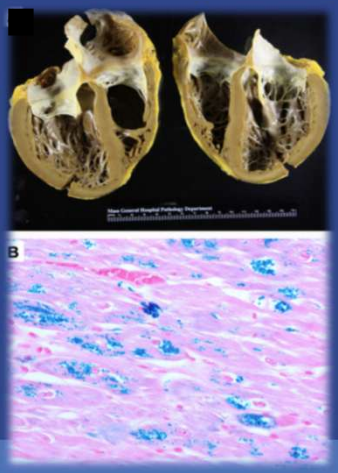

42

© Copyright. Society of Diagnostic Medical Sonography. All Rights Reserved.

Causes of Hemochromatosis

- Hereditary – more common in Northern European descent
- Secondary – Caused by other health issues
  - Anemia
  - Chronic liver disease
  - Frequent blood transfusions
  - Heavy alcohol use
- Symptoms develop in most around 40s - 50s
- Takes a long time for iron to build up in organs
- Milder forms may not be noticed

43

Treatment

- Blood removal that will lower the iron level
- Diet and lifestyle changes
  - Avoid iron & Vitamin C supplements
  - Limiting alcohol
- Monitoring Iron and Ferritin levels

44

© Copyright. Society of Diagnostic Medical Sonography. All Rights Reserved.

Hemochromatosis – Echo Findings

Iron Deposition:

- Early signs of LV diastolic dysfunction that often progressing to a restrictive filling pattern
  - Typically presents as a **dilated cardiomyopathy**
  - Symmetrical wall thinning with severe global systolic dysfunction

45

Hemochromatosis echo findings

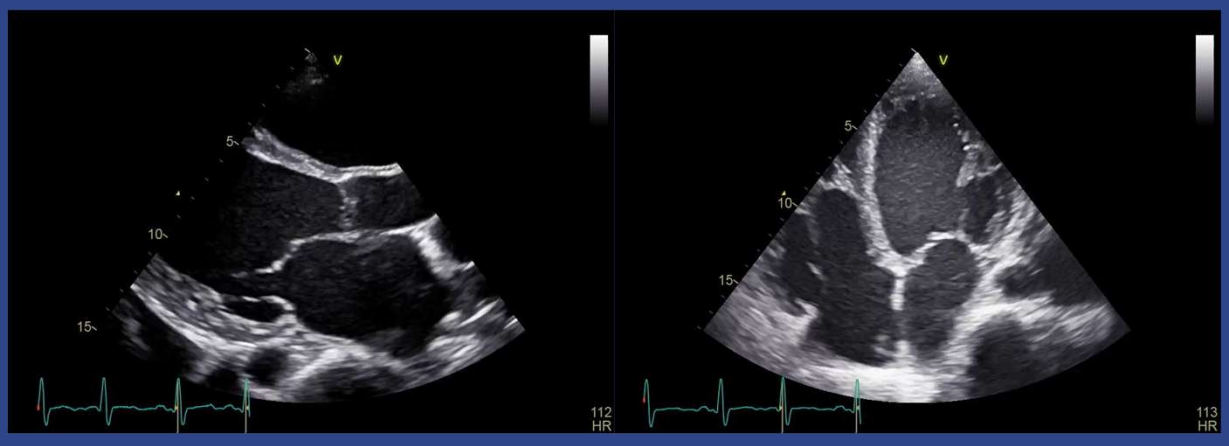

46

© Copyright. Society of Diagnostic Medical Sonography. All Rights Reserved.

Diastology: Restrictive Pattern

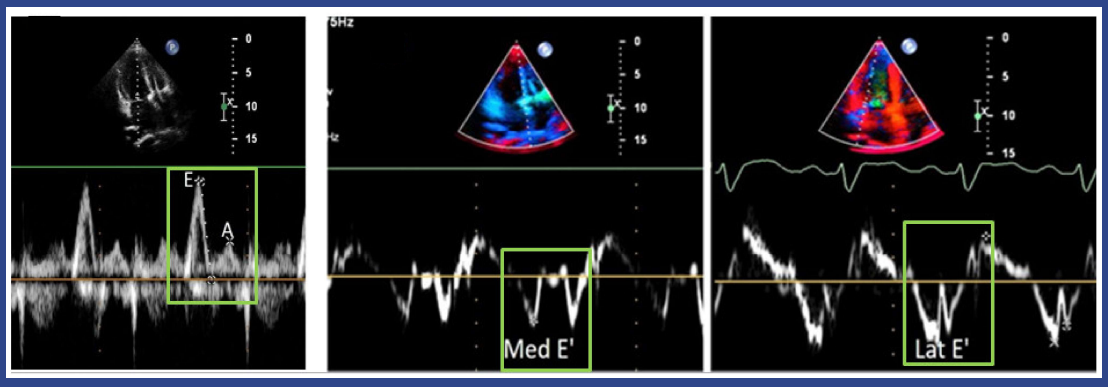

47

Carcinoid

48

© Copyright. Society of Diagnostic Medical Sonography. All Rights Reserved.

Carcinoid Tumors

- Rare slow growing neuroendocrine tumor in small intestines or lungs & liver mets.
- Tumor releases excess hormones in bloodstream – serotonin
- Serotonin get deactivated in the lungs by an enzyme monoamine oxidase, located in the endothelial cells of the pulmonary blood vessels
- Mainly a right heart issue unless there is a communication between R & L heart
- Long term hormone exposure results in fibrous tissue build up on right sided heart valves (Tricuspid / Pulmonic)

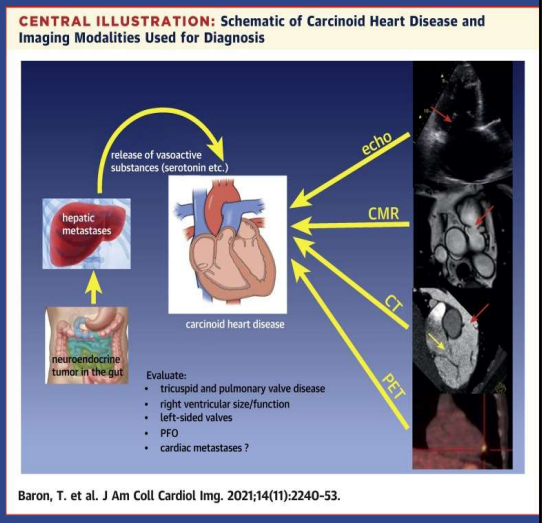

49

Carcinoid Echo Findings

- Tricuspid Valve – Heavily thickened, retracted, Typically fixed in an opened position resulting in torrential TR or stenosis
- Pulmonic Valve – Similar findings as TV, with a mix of pulmonic regurgitation and stenosis
- Left-sided Valves – Mitral and aortic valves are rarely involved unless a right to left shunt is present
- Right heart enlargement – Severe RV & RA enlargement due to chronic volume overload from TR & PR
- Right Ventricular Dysfunction - Reduced RVF & Flattening or paradoxical motion of the IVS. RVFW strain should be performed

50

© Copyright. Society of Diagnostic Medical Sonography. All Rights Reserved.

PLAX RVIF & Apical 4 TR

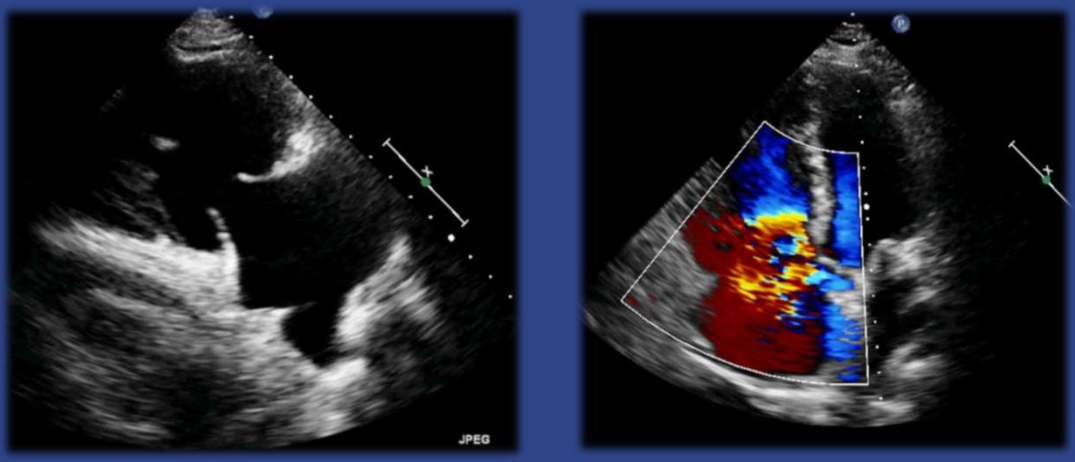

51

Carcinoid Syndrome Echo Findings

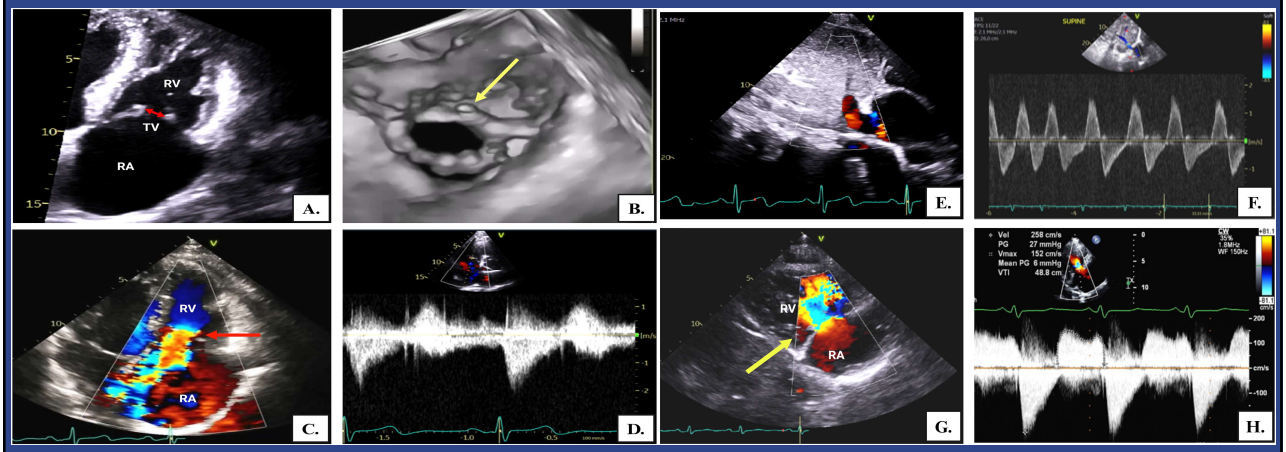

Ayoub,C; Scalia,I; et al. Echocardiographic Evaluation of Carcinoid Heart Disease. J Am Soc of Echocardiogr 2025; 38:775-93

52

© Copyright. Society of Diagnostic Medical Sonography. All Rights Reserved.

Next steps…

- When infiltrative cardiomyopathy is suspected on an echocardiogram, subsequent imaging often includes:
  - **Cardiac Magnetic Resonance (CMR)** for tissue characterization and
  - **Nuclear Imaging** (e.g., Pyrophosphate scans for ATTR amyloidosis)
- Echo findings often mimic other disease states
- Biopsies or genetic testing are frequently needed to nail the diagnosis

53

Thanks for your attention!!



Pamela.R.Burgess@advocatehealth.org

54

© Copyright. Society of Diagnostic Medical Sonography. All Rights Reserved.