Transforming Cerebrovascular Diagnosis with Transcranial Doppler



Patricia Vargas-Ikits, DHSc, RVT
Professor & Founding Program Director
Diagnostic Medical Sonography Program
Touro University California

1

SPEAKER PRESENTATION DISCLAIMER

The content and views presented are made available for educational purposes only. The information presented are the opinions of the presenter and do not necessarily represent the views of the Society of Diagnostic Medical Sonography (SDMS) or its affiliated organizations, officers, Boards of Directors, or staff members.

The presenter is responsible for ensuring balance, independence, objectivity, scientific rigor, and avoiding commercial bias in their presentation. Before making the presentation, the presenter is required to disclose to the audience any relevant financial interests or relationships with manufacturers or providers of medical products, services, technologies, and programs.

The SDMS and its affiliated organizations, officers, Board of Directors, and staff members disclaim any and all liability for all claims that may arise out of the use of this educational activity.

2

© Copyright. Society of Diagnostic Medical Sonography. All Rights Reserved.

RESEARCH DISCLAIMER

The information presented in this presentation is based on research conducted to the best of the presenters' abilities and knowledge. Research involves uncertainty and is subject to limitations. The findings and conclusions presented herein may be influenced by various factors including but not limited to data quality, methodology, assumptions, and interpretation.

Research outcomes may not always accurately predict real-world scenarios or future events. While the presenter may make efforts to ensure the accuracy and reliability of the information presented, completeness or absolute correctness is not guaranteed. This presentation is intended for informational purposes only and should not be construed as professional advice. Participants are encouraged to independently verify any information provided and consult relevant experts or professionals where appropriate.

The SDMS and its affiliated organizations, officers, Board of Directors, and staff members disclaim any and all liability for all claims that may arise out of the use of this educational activity.

3

GENERATIVE AI DISCLAIMER

The presenter utilized the use of large language models (LLMs) and generative artificial intelligence (AI) as a productivity tool to assist in drafting and refining content in this presentation.

While these tools can aid in structuring ideas, summarizing, paraphrasing, and language polishing, they have inherent limitations and cannot replace human creativity, critical thinking, or expert judgment. AI-generated content may contain errors, biases, or gaps in knowledge.

This presentation is intended for informational purposes only and should not be construed as definitive or authoritative guidance. Participants are encouraged to critically evaluate the information presented and consult relevant experts as needed. The SDMS and its affiliated organizations, officers, Board of Directors, and staff members disclaim any and all liability for claims that may arise from the use or interpretation of this educational material.

4

© Copyright. Society of Diagnostic Medical Sonography. All Rights Reserved.

Objectives

1. Describe the role of transcranial Doppler in the detection of cerebrovascular disease.
2. Explain common applications and technical considerations of TCD and TCDI examinations.
3. Identify the importance of cerebral blood flow velocity assessment in supporting clinical evaluation and diagnosis.

5

Introduction

This presentation will discuss the value of transcranial Doppler in the detection of cerebrovascular disease and its role in monitoring intracranial conditions. We will learn the different applications, limitations, and possibilities of transcranial Doppler ultrasound. The equipment, techniques, limitations, and protocols for Transcranial Doppler (TCD) and Transcranial Color Duplex Imaging (TCDI) will be discussed.

The session will provide guidelines and recommendations for best professional practices and best approaches when performing a TCD or TCDI examination, and it will allow students to analyze cases studies.

6

© Copyright. Society of Diagnostic Medical Sonography. All Rights Reserved.

Transcranial Doppler

Transcranial Doppler (TCD) and Transcranial Color Duplex Imaging (TCDI) are diagnostic techniques used to measure blood flow velocities in the basal arteries and the circle of Willis. Diagnostic information is obtained from waveform interpretation and measurements of flow parameters in the spectral display.

TCD is a non-imaging technique and relies on information from the spectral waveform. Non-imaging TCD systems may be equipped with M-mode capabilities. [1]

7

Transcranial Doppler Imaging

TCDI provides faster and more reliable vessel identification, allowing exact localization of the Doppler sample volume, and shortening the examination time. It also allows the visualization of anatomic landmarks and spatial course of the arteries, which are helpful for vessel identification. [1]

TCDI can provide images highly suggestive of certain pathologies. However, the definitive confirmation of flow findings is still derived from the spectral analysis.

8

© Copyright. Society of Diagnostic Medical Sonography. All Rights Reserved.

Functions of the Brain

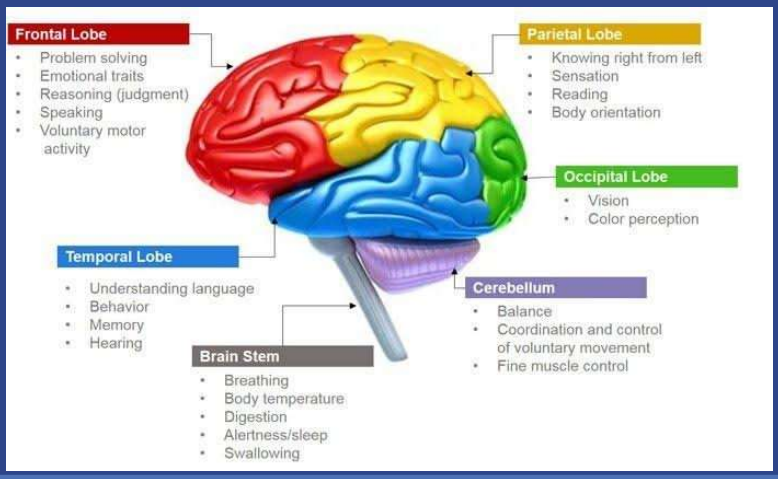

Parts of the Brain & Function. 2021. https://anatomyinfo.com/parts-of-the-brain/. Accessed May 23, 2022.

9

Circle of Willis

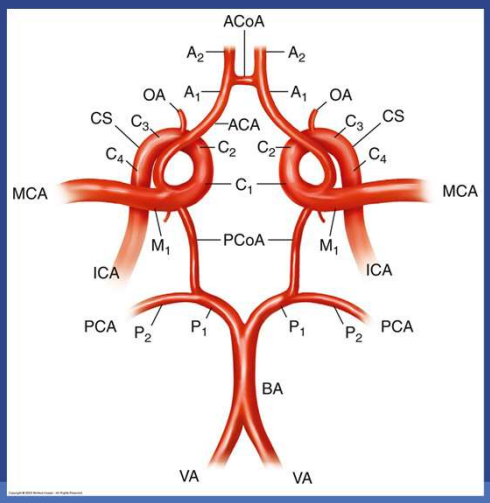

- ACA – Anterior cerebral artery
- ACoA – Anterior communicating artery
- BA – Basilar artery
- CS – Carotid siphon
- ICA – Internal carotid artery
- MCA – Middle cerebral artery
- OA – Ophthalmic artery
- PCA – Posterior cerebral artery
- PCoA – Posterior communicating artery
- VA – Vertebral artery [2]

Kupinski A. Diagnostic Medical Sonography: The Vascular System. 2020. Accessed Jul.1, 2026.

10

© Copyright. Society of Diagnostic Medical Sonography. All Rights Reserved.

Anterior Cerebral Artery

- Branch of Circle of Willis, fed by ICA
- Supplies: Paramedian Frontal and Parietal lobes
- Symptoms: [1]
  - Leg weakness
  - Leg sensory loss
  - Leg ataxia
  - Confusion
  - Agraphia (Inability to write)
  - Emotional disturbances
  - Abulia (Lack of ability to make decisions)
  - Akinetic mutism (inability to speak, loss of voluntary movement, and apparent loss of emotional feeling)

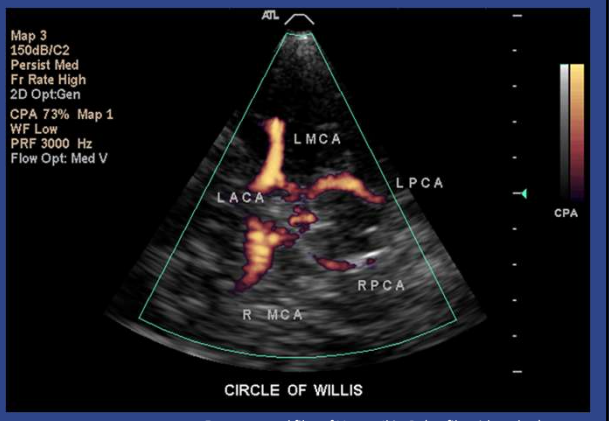

From personal files of Vargas-Ikits P. (on file with author)

11

Middle Cerebral Artery

- Largest branch of ICA
- Most common vessel affected
- Supplies: Frontal, Parietal, Temporal lobes, Deep nuclei
- Symptoms: [1]
  - Hemiparesis or hemiplegia
  - Hemisensory loss
  - Aphasia
  - Vision field disturbances
  - Neglect
  - Eye deviation
  - Movement disorders

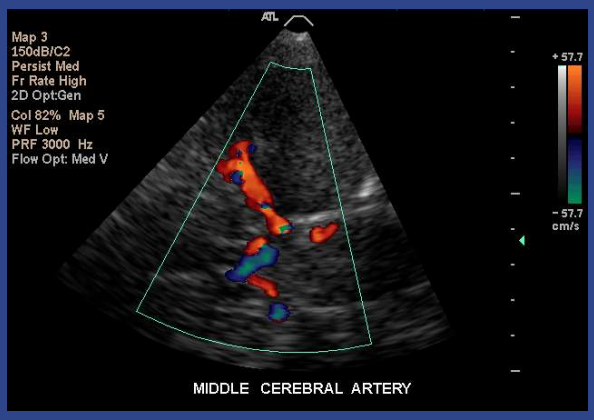

From personal files of Vargas-Ikits P. (on file with author)

12

© Copyright. Society of Diagnostic Medical Sonography. All Rights Reserved.

Middle Cerebral Artery

- Left MCA
  - Aphasia
  - Apraxia (Impairment of the ability to execute movement)
- Right MCA
  - Neglect
  - Dressing apraxia
  - Visual spatial deficits
  - Confabulation (Filling in of gaps in memory by unconstrained fabrication)



From personal files of Vargas-Ikits P. (on file with author).

13

MCA / ACA Bifurcation

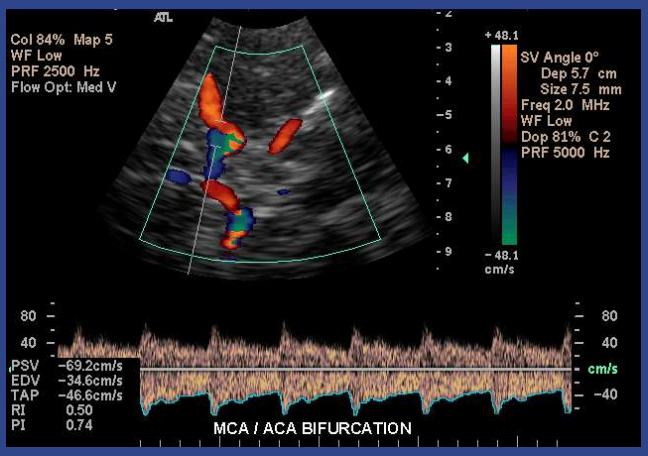

From personal files of Vargas-Ikits P. (on file with author).

14

© Copyright. Society of Diagnostic Medical Sonography. All Rights Reserved.

Lenticulostriate Arteries

- Branches of Anterior Choroidal or MCA
- Supply: Deep Nuclei, Internal capsule, Thalamus
- Classic location for lacunar infarct
- Manifestations [1]
  - Pure motor stroke
  - Pure sensory stroke
  - Dysarthria–clumsy hand syndrome
  - Language disturbances
  - Movement disorders
  - Ataxic hemiparesis

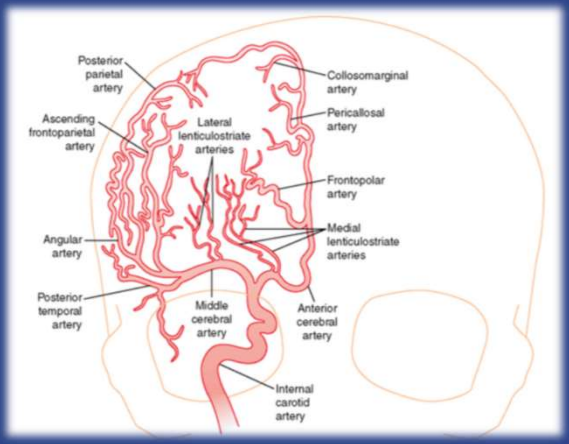

Kirton A, deVeber G. Cerebrovascular Disease in Children. 2016. https://neupsykey.com/cerebrovascular-disease-in-children/ Accessed Jul 8, 2026.

15

Posterior Cerebral Artery

- Branch of the Basilar artery
  - In some cases, might be a terminal branch of posterior communicating artery from anterior circulation
- Supplies: Occipital and Temporal lobes
- Symptoms [1]
  - Visual disturbances
    - Loss
    - Agnosia (colors, faces, objects)
  - Memory impairment
  - Aphasia
  - Sensory deficits
  - Alexia (Aphasia characterized by loss of ability to read) without agraphia

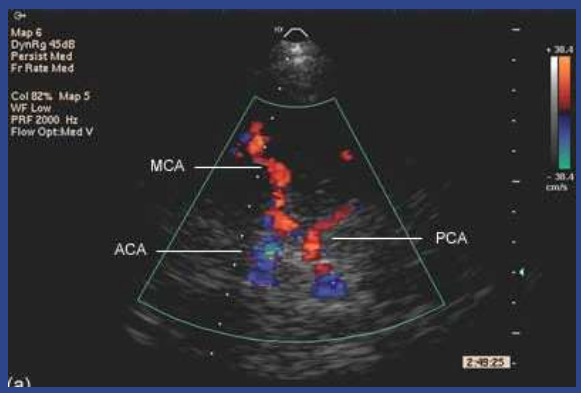

From personal files of Vargas-Ikits P. (on file with author).

16

© Copyright. Society of Diagnostic Medical Sonography. All Rights Reserved.

Vertebrobasilar System

- Two Vertebral Arteries → Basilar Artery
- Supply: brainstem, cerebellum, thalamus, PCA
- Manifestations: ANYTHING!
  - Cranial Nerves deficits
    - Dysarthria, dysphagia, facial droop, diplopia, nystagmus (involuntary rapid movement of the eyeballs)
  - Dyscoordination
  - Dizziness, vertigo
  - Nausea, emesis
  - Hiccups
  - Weakness
  - Ipsilateral face with contralateral body symptoms

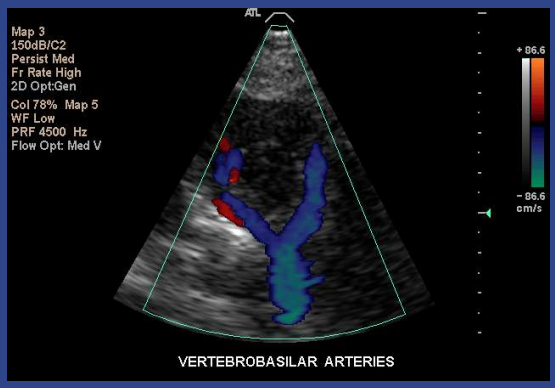

17

TCDI Clinical Applications[3]

- Diagnosis and follow-up of intracranial vascular disease
- Assessment of intracranial collateral pathways
- Evaluation of the hemodynamic effects of extracranial occlusive disease on intracranial blood flow
- Intraoperative monitoring
- Detection of cerebral emboli
- Monitoring vasospasm in subarachnoid hemorrhage
- Screening of children with sickle cell disease
- Documentation of the subclavian steal syndrome
- Evaluation of vertebrobasilar system
- Monitoring after head trauma
- Monitoring during anticoagulative or fibrinolytic therapy
- Detection of feeders of AVM
- Evaluation of migraine headaches
- Monitoring evaluation of cerebral circulatory arrest
- Determination of brain death

18

© Copyright. Society of Diagnostic Medical Sonography. All Rights Reserved.

Brain Cerebral Circulatory Arrest and ICP

Cerebral blood flow drastically changes when there is increased peripheral resistance. This occurs during brain death and extreme conditions of inflammation of the brain. TCD allows to determine cerebral perfusion pressure (CPP)

Progression of Brain Death

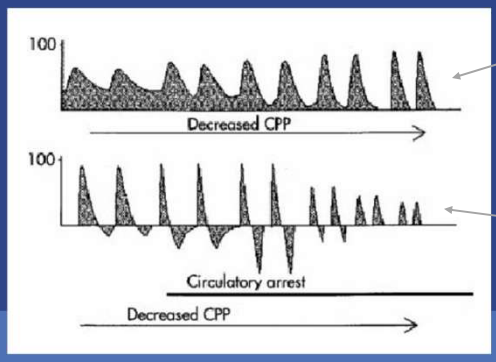

Flow becomes more resistive

No flow = Cerebral circulatory arrest

Purkayastha S, Sorond F. Transcranial Doppler Ultrasound: Technique and Application. 2013. https://www.researchgate.net/publication/235382817_Transcranial_Doppler_Ultrasound_Technique_and_Application. Accessed May 23, 2022.

19

Brain Death Determination

- Reverberating or oscillating pattern of flow.
- Normal arterial blood flow in systole and reversed flow in diastole secondary to the high distal brain resistant in brain dead patients.
- In advanced stages of brain death, the reverberating pattern may progress to *no flow.* [1]

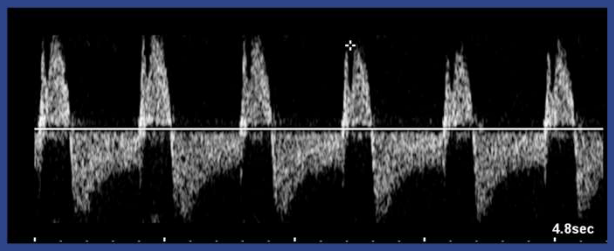

From personal files of Vargas-Ikits P. (on file with author).

20

© Copyright. Society of Diagnostic Medical Sonography. All Rights Reserved.

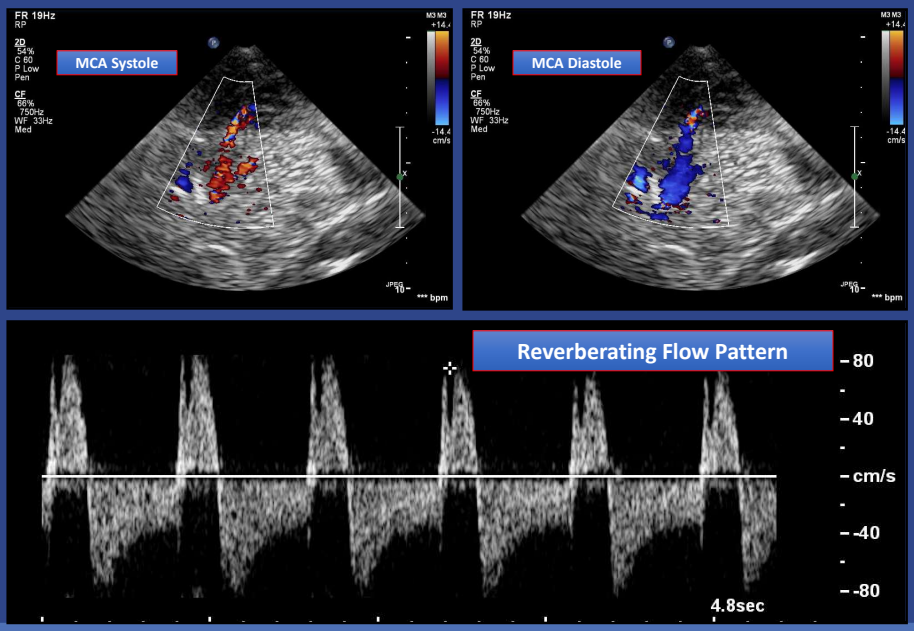

From personal files of Vargas-Ikits P. (on file with author).

21

AAN Recommendations on Use of Ancillary Testing

Transcranial Doppler Ultrasonography

TCD is useful only if a reliable signal is found. The abnormalities should include either reverberating flow or small systolic peaks in early systole. A finding of a complete absence of flow may not be reliable owing to inadequate transtemporal windows for insonation. There should be bilateral insonation and anterior and posterior insonation. The probe should be placed at the temporal bone, above the zygomatic arch and the vertebrobasilar arteries, through the suboccipital transcranial window. [4]

Insonation through the orbital window can be considered to obtain a reliable signal. TCD may be less reliable in patients with a prior craniotomy.

AAN Evidence-based Guideline Update: Determining Brain Death in Adults – Report of Quality Standards. 2010.

22

© Copyright. Society of Diagnostic Medical Sonography. All Rights Reserved.

Equipment

- Real-time duplex ultrasound system with color flow and spectral Doppler capability, using 2-2.5 MHz transducers
- TCDI transducers have a larger footprint than non-imaging transducers
  - Adjustable Doppler gate depth
  - PRF up to 20 kHz
  - Focusing on the ultrasonic beam at the distance of 40-60mm



Gettz L, Cutter N. 2022. 2021 Review: Transcranial Doppler Ultrasound Imaging. https://www.itnonline.com/article/2021-review-transcranial-doppler-ultrasound-imaging. Accessed May 28, 2026.

23

TCD

- Non-imaging TCD uses a 2-2.5 MHz pulsed wave Doppler transducer
- Vessels are identified by
  1. Depth of the sample volume
  2. Direction of flow
  3. Distance over which artery is traced
  4. Orientation of the transducer and the spatial relationship of each vessel[1]
- Great for monitoring studies when the transducer is attached to the head and specific arteries are examined over time

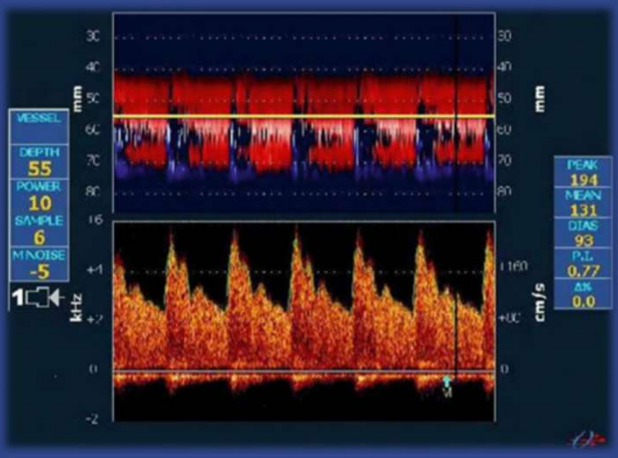

Prabhakar H. Neuromonitoring Techniques. 2025. https://www.sciencedirect.com/science/chapter/edited-volume/abs/pii/B9780443329029000192. Accessed May 1, 2026.

24

© Copyright. Society of Diagnostic Medical Sonography. All Rights Reserved.

Equipment

- A 2-2.5 MHz sector transducer
- Adjustable Doppler gate depth
- PRF up to 20 kHz
- Focusing on the ultrasonic beam at the distance of 40-60mm.
- On-line displayed TAV and PSV derived from the spectral analysis of the ultrasonic signals.

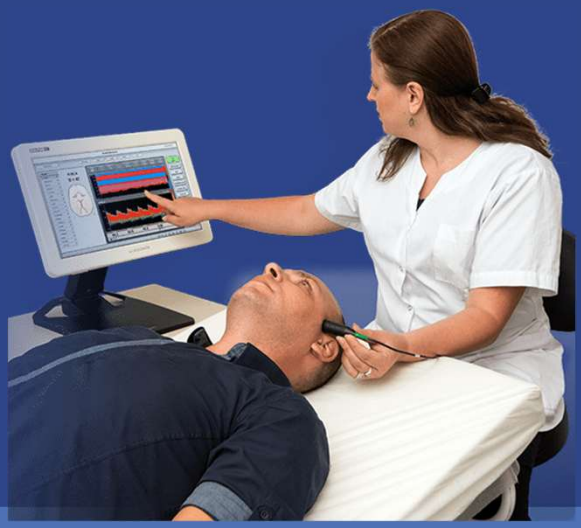

Viasonix. https://viasonix.com/products/transcranial-doppler/dolphin-max/. Accessed Jul 6, 2026.

25

Acoustic Windows

1. Transtemporal
   - MCA
   - ACA
   - ACoA
   - TICA
   - PCA
   - PCoA
2. Transorbital
   - Siphon
   - OA
3. Suboccipital or Transforaminal
   - VA
   - BA
4. Submandibular
   - Retromandibular ICA

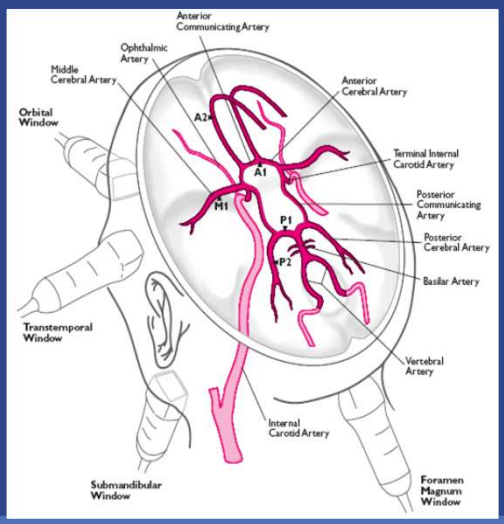

Pedicelli A, Bellitti A, Rollo M. Transcranial Color Doppler Sonography Today: When and How to Use it. 2005. https://epos.myesr.org/posterimage/esr/ecr2005/5788/mediagallery/108419?deliveroriginal=1. Accessed May 22, 2022.

26

© Copyright. Society of Diagnostic Medical Sonography. All Rights Reserved.

Acoustic Windows

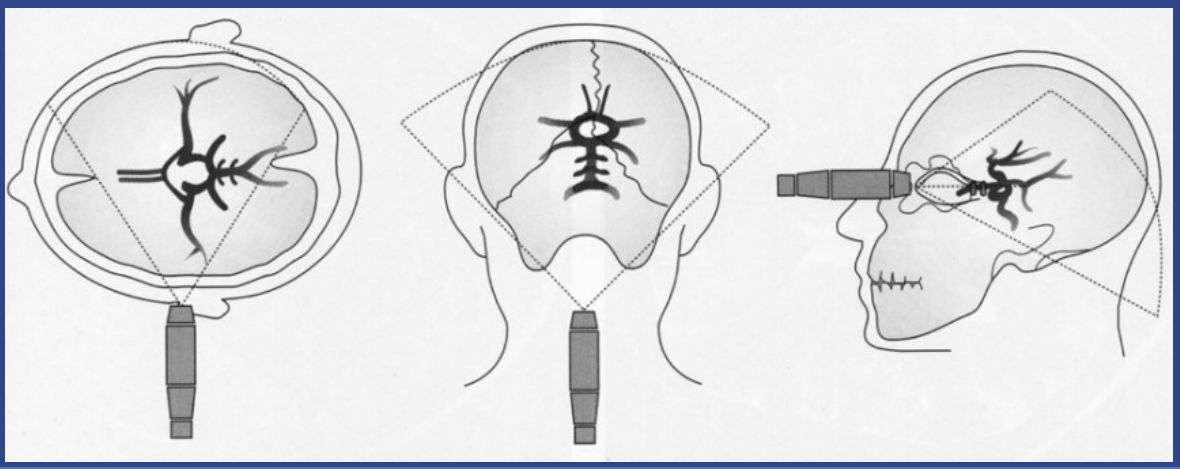

Neupsy Key. Introduction. 2017. https://neupsykey.com/introduction-34/. Accessed May 22, 2022.

27

Flow Detection

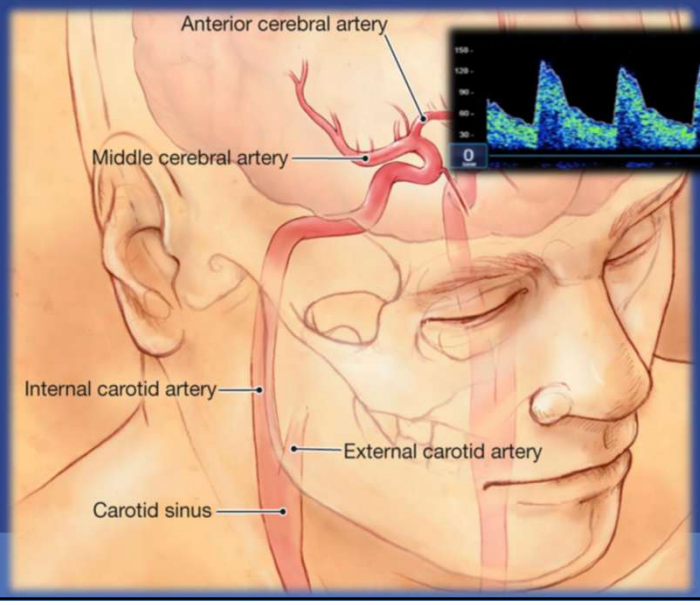

- The Doppler shift equation is heavily dependent on the angle of the beam to the blood flow and uses a 0º angle.
- The ideal angle is 0º
- A 90º produces no flow

Caplan. Review of Internal Carotid Artery Stenosis. 2008. ja.ma/1N1XNuR. Accessed May 22, 2022.

28

© Copyright. Society of Diagnostic Medical Sonography. All Rights Reserved.

Vessel Identification

Primary TCDI parameters for identifying the cerebral arteries:

1. Insonation depth
2. Direction of blood flow at insonation depth
3. Flow velocity
4. Probe position
5. Direction of the ultrasonic beam
6. Traceability of vessels



From personal files of Vargas-Ikits P. (on file with author).

29

Identification Criteria[2,3]

Artery	Window	Depth (mm)	Direction	Mean Flow Velocity
MCA	Temporal	40 to 60	Toward	55 ± 12 cm/s
ACA	Temporal	60 to 85	Away	50 ± 11 cm/s
PCA	Temporal	60 to 70	Toward/Away	40 ± 10 cm/s
TICA	Temporal	55 to 65	Toward	39 ± 09 cm/s
ICA (siphon)	Orbital	60 to 80	Toward/Away	45 ± 15 cm/s
OA	Orbital	40 to 60	Toward	20 ± 10 cm/s
VA	Occipital	60 to 80	Away	38 ± 10 cm/s
BA	Occipital	80 to 110	Away	41 ± 10 cm/s

30

© Copyright. Society of Diagnostic Medical Sonography. All Rights Reserved.

Intracranial Disease

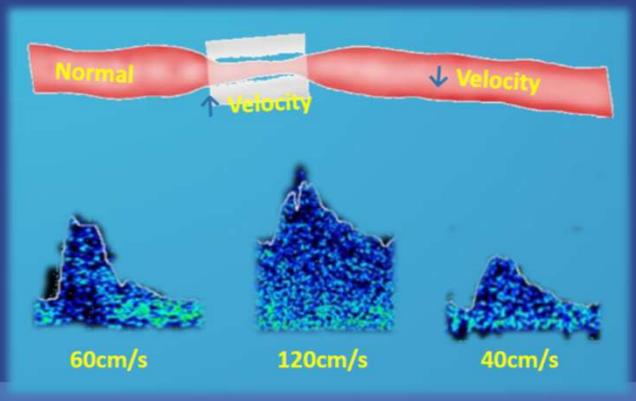

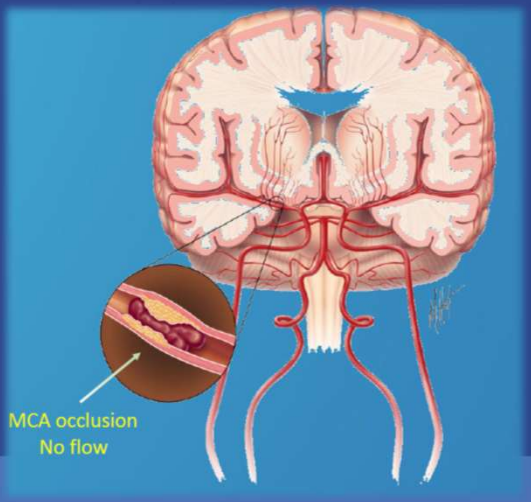

Neura Signal. Stenosis & Occlusion. 2021. Accessed May 20, 2022.

31

Identification of Stenosis & Occlusion

Definition of Stenosis with TCD

A relative increase in PSV of more than 30% is suspicious for hemodynamically significant stenosis, and a relative increase of more than 50% indicate a definite intracranial artery stenosis.

Definition of Occlusion with TCD

It can be detected by the absence of arterial signals at an expected depth; the presence of signals in vessels that communicate with the occluded artery; and altered flow in communicating vessels, indicating collateralization.[1]

32

© Copyright. Society of Diagnostic Medical Sonography. All Rights Reserved.

TCD Pitfalls & Diagnostic Accuracy[1,2,3]

1. Lack of flow signal due to an inadequate window
2. Misinterpretation of hyperdynamic collateral channels or AVM feeders
3. Displacement of arteries due to a space-occupying lesion
4. Misinterpretation of physiologic variables in the Circle of Willis
5. Misdiagnosis of vasospasm as stenosis
6. Misinterpretation of reactive hyperemia following spontaneous recanalization as stenosis

33

Limitations[2,3,5]

- Technologist dependent
- Improper instrument control settings
- Uncooperative patient or patient movement
- Absent or poor transtemporal window
- Anatomic variations
- Arterial misidentification
- Distal branch disease
- Distal basilar artery
- Misinterpretation of collateral channels or vasospasm as a stenosis
- Displacement of arteries by an intracranial mass or swelling

34

© Copyright. Society of Diagnostic Medical Sonography. All Rights Reserved.

PCoA & ACoA as Collaterals

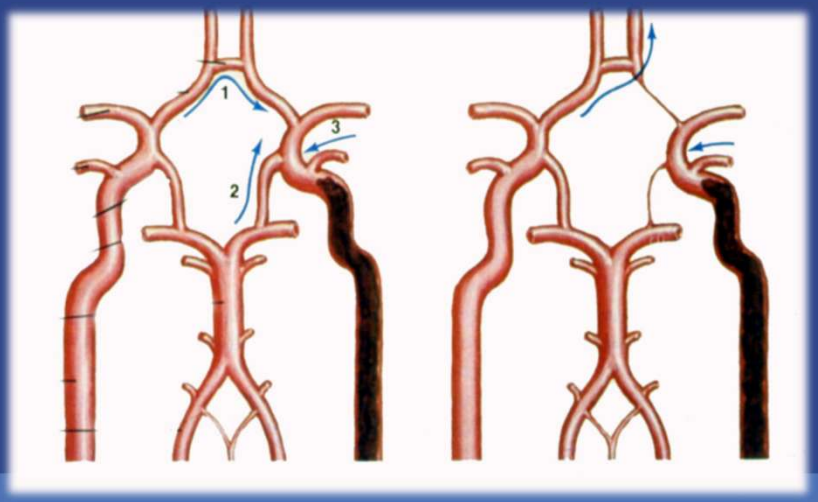

Daigle RJ. Techniques in Noninvasive Vascular Diagnosis. 2023. Accessed Jun.4, 2026.

35

Contralateral Hemisphere with RICA occlusion

- The key artery is the ACoA
- The complete pathway looks like this:

LCCA>LICA>LACA>ACoA>RACA>RMCA

36

© Copyright. Society of Diagnostic Medical Sonography. All Rights Reserved.

Posterior to Anterior with RICA Occlusion

- The key artery is the R PCoA
- The complete pathway looks like this:

Aorta>R SCA>R VA> R PCA>R PCoA>Dist ICA> RMCA

37

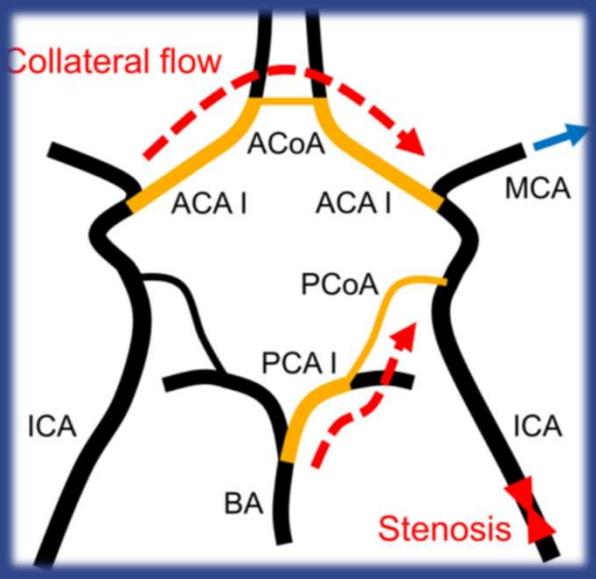

Yuhn C, Oshima M, Chen Y, Hayakawa M, Yamada S. Uncertainty quantification in cerebral circulation simulations focusing on the collateral flow: Surrogate model approach with machine learning. 2022. https://journals.plos.org/ploscompbiol/article?id=10.1371/journal.pcbi.1009996. Accessed May 22, 2022.

38

© Copyright. Society of Diagnostic Medical Sonography. All Rights Reserved.

Collateralization through the OA

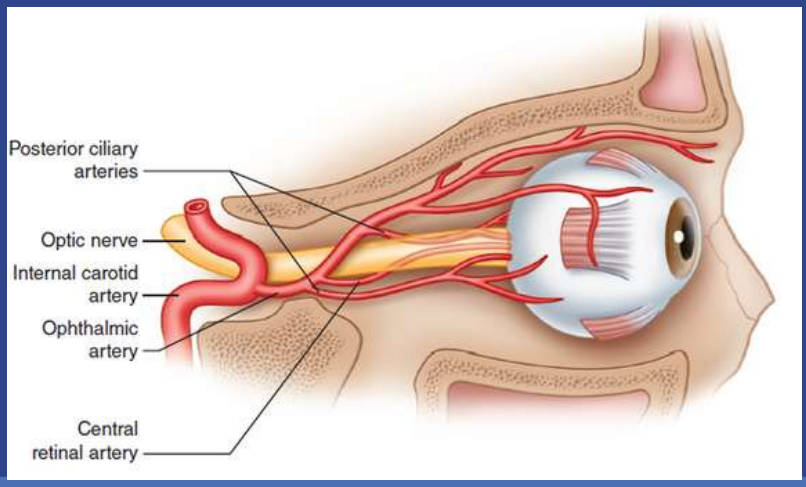

- The OA provides a pathway to the anterior circulation when the ICA is significantly blocked.
- This is called external to internal collateralization and is detected by flow reversal in the OA.

The Retina Reference. ND. https://www.retinareference.com/anatomy/. Accessed May13, 2026

39

ECA to ICA Branches with RICA Occlusion[5]

1. Aorta
2. Innominate
3. RCCA
4. RECA
5. RECA branches (STA, facial, maxillary)
6. ICA branches (supraorbital, frontal, nasal)
7. ROA
8. R Distal ICA (siphon)
9. R MCA

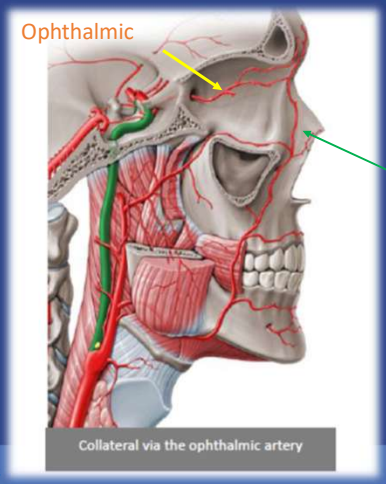

Sieroslawska A. External carotid artery and its branches. 2023. https://www.kenhub.com/en/library/anatomy/the-external-carotid-artery-and-its-branches. Accessed May 20, 2026.

40

© Copyright. Society of Diagnostic Medical Sonography. All Rights Reserved.

B-mode Image Optimization

- Landmarks vary with window location
- Observe sector width
- Use TGC to obtain image at greater depths
- Use high gray scale contrast (DR) to depict anatomy

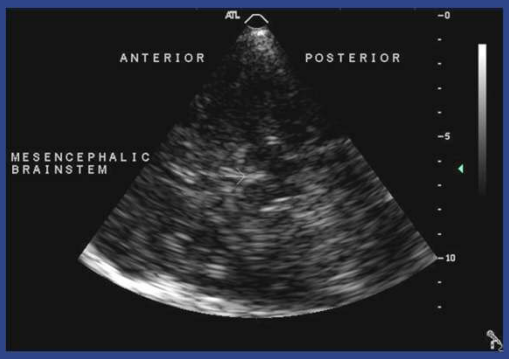

From personal files of Vargas-Ikits P. (on file with author).

41

Color Doppler Optimization

- Flow towards transducer is RED
- Flow away from transducer is BLUE
- Use high frame rate (reduce color box size)
- Adjust color scale (PRF)
- Low wall filter for detection of low velocity, low amplitude signals

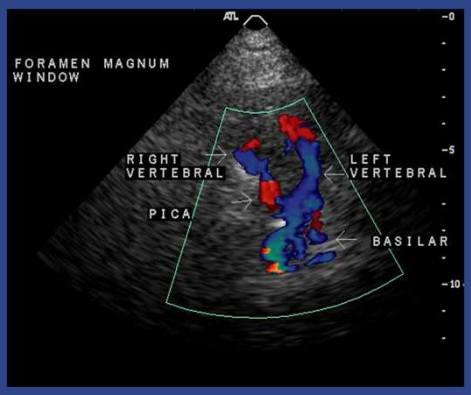

From personal files of Vargas-Ikits P. (on file with author).

42

© Copyright. Society of Diagnostic Medical Sonography. All Rights Reserved.

Spectral Doppler Optimization

- Increase Sample Volume size to obtain stronger signal
- Adjust scale and baseline to display entire signal
- Adjust gain to increase/decrease signal strength
- 0-degree angle or document angle used

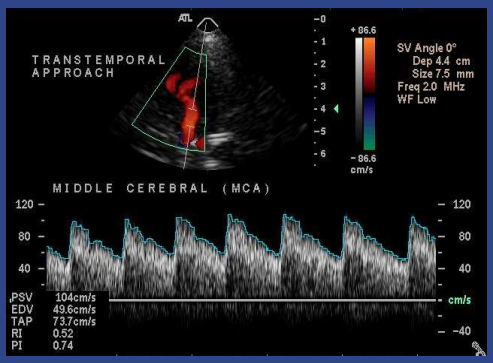

From personal files of Vargas-Ikits P. (on file with author).

43

Transtemporal Approach
Skull Base Landmarks

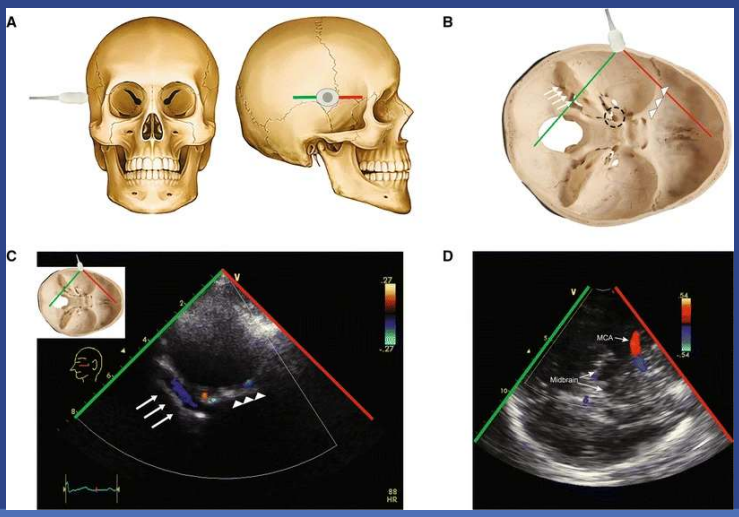

Couture E, Desjardins G, Denault A. Transcranial Doppler monitoring guided by cranial two-dimensional ultrasonography. 2017. https://link.springer.com/article/10.1007/s12630-017-0898-9/figures/1. Accessed May 23, 2022.

44

© Copyright. Society of Diagnostic Medical Sonography. All Rights Reserved.

Transtemporal Insonation Transducer Position[3,5]

- Above zygomatic arch
- Anterior to tragus of ear
- Axial scan plane
- Orientation marker towards nose

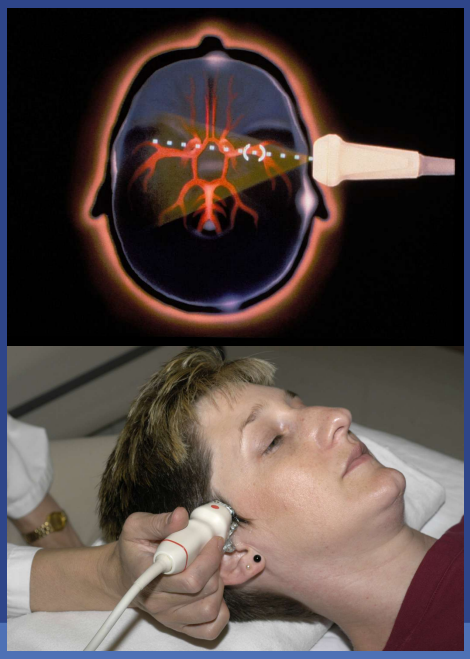

Daigle RJ. Techniques in Noninvasive Vascular Diagnosis. 2023. Accessed Jun.4, 2026.

45

Transtemporal Approach

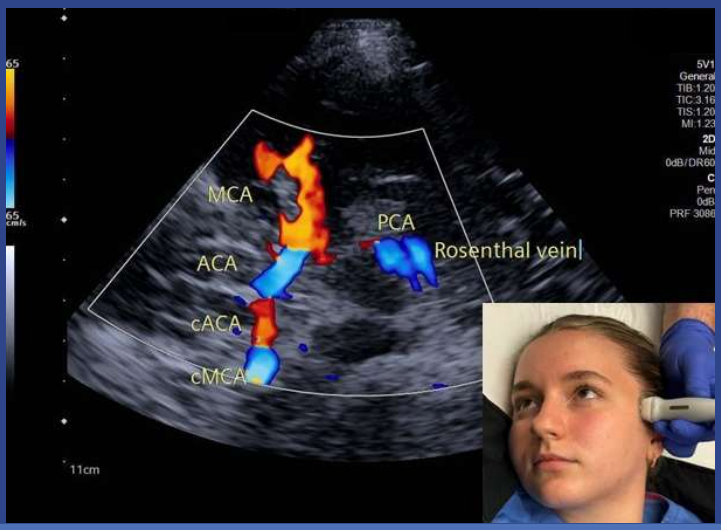

From personal files of Vargas-Ikits P. (on file with author).

46

© Copyright. Society of Diagnostic Medical Sonography. All Rights Reserved.

Transtemporal Approach
Axial Scan Plane
B-mode landmarks

Reflections from bones

Reflections from parenchyma

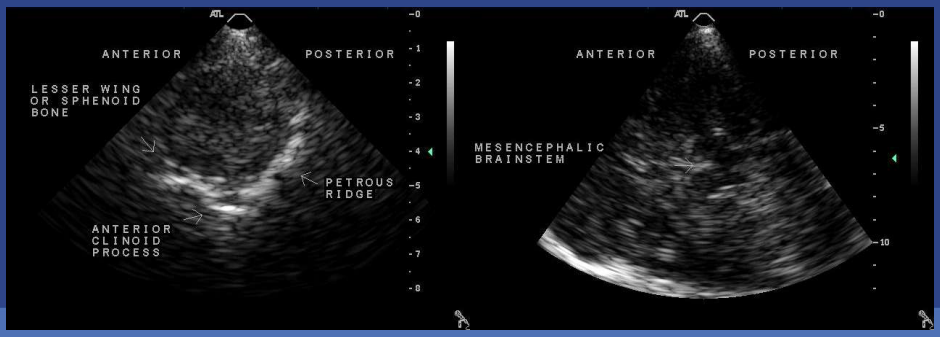

From personal files of Vargas-Ikits P. (on file with author).

47

Absent Temporal Bone Window

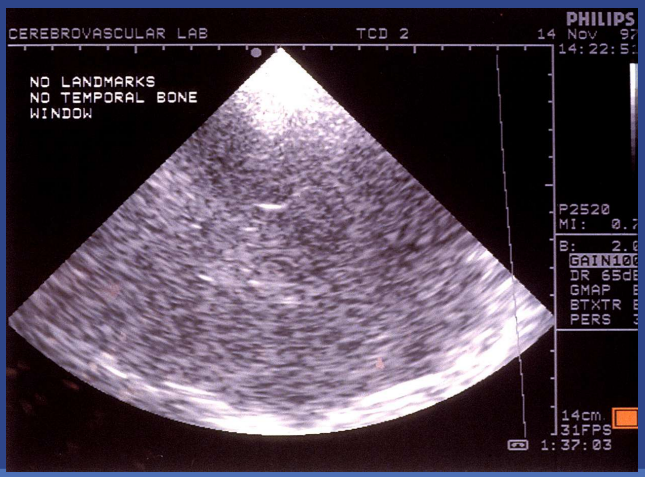

From personal files of Vargas-Ikits P. (on file with author).

48

© Copyright. Society of Diagnostic Medical Sonography. All Rights Reserved.

Transtemporal Approach
Terminal ICA

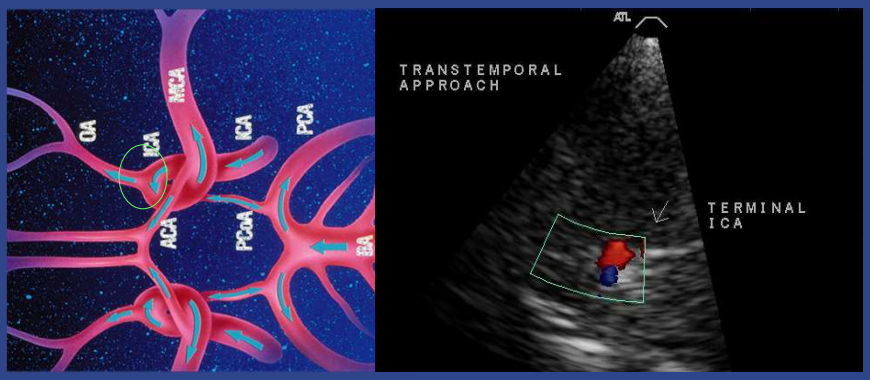

From personal files of Vargas-Ikits P. (on file with author).

TAMV 58 – 74 cm/sec

49

Transtemporal Approach
MCA

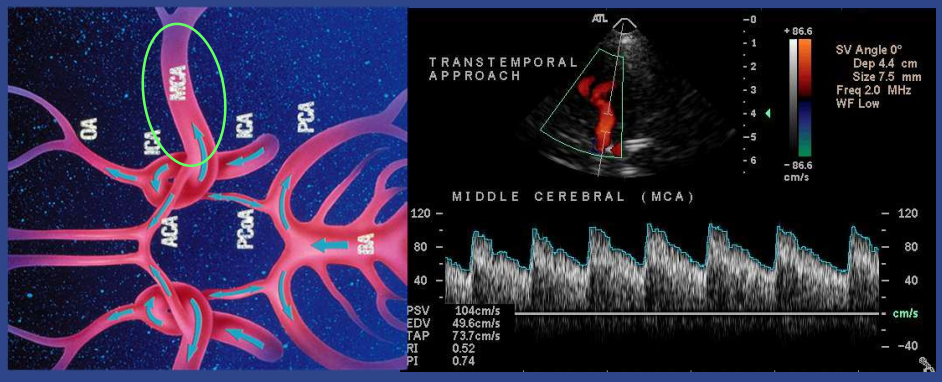

From personal files of Vargas-Ikits P. (on file with author).

TAMV 58 – 74 cm/sec

50

© Copyright. Society of Diagnostic Medical Sonography. All Rights Reserved.

Transtemporal Approach
MCA Branches

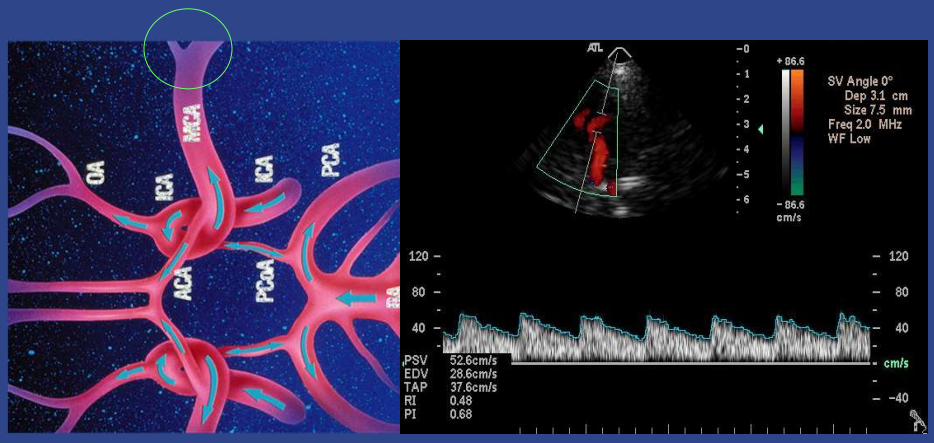

From personal files of Vargas-Ikits P. (on file with author).

51

Transtemporal Approach
ACA (A1)

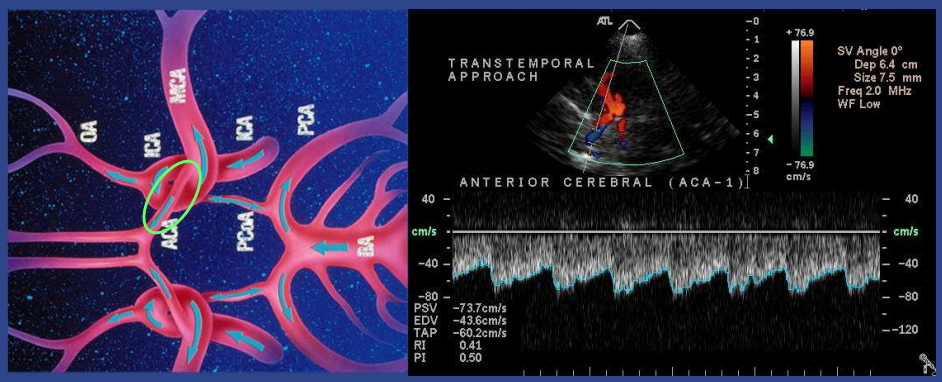

From personal files of Vargas-Ikits P. (on file with author).

TAMV 51 – 61 cm/sec

52

© Copyright. Society of Diagnostic Medical Sonography. All Rights Reserved.

Transtemporal Approach
PCA (P1)

Pre-communicating (P1)

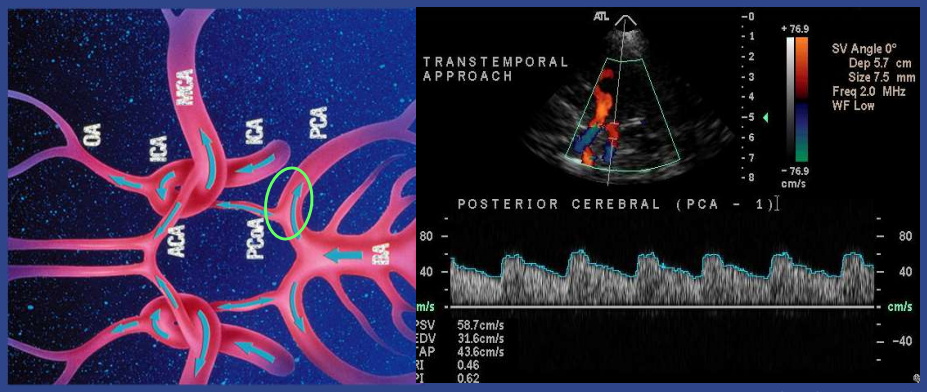

From personal files of Vargas-Ikits P. (on file with author).

TAMV 42 - 53 cm/sec

53

Transtemporal Approach
PCA (P2)

Post-communicating (P2)

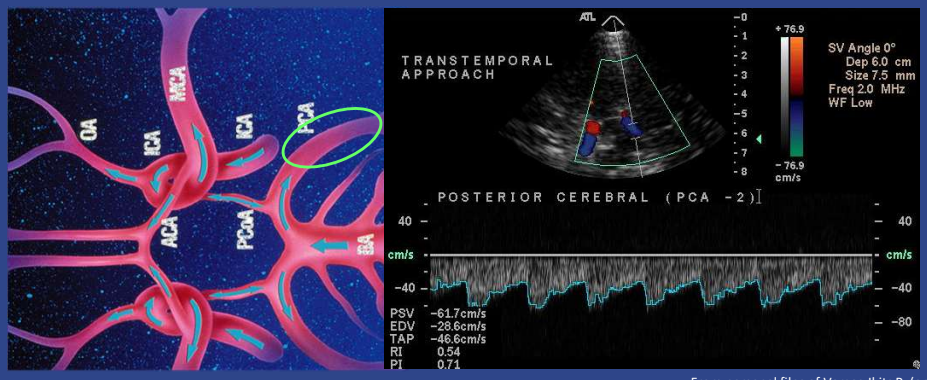

From personal files of Vargas-Ikits P. (on file with author).

TAMV 42 - 47 cm/sec

54

© Copyright. Society of Diagnostic Medical Sonography. All Rights Reserved.

Transorbital Approach
Reduce Power

Transducer A/P
Orientation marker
towards nose



Globe/optic nerve

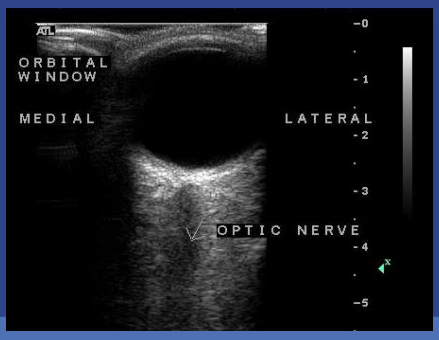

Daigle RJ. Techniques in Noninvasive Vascular Diagnosis. 2023. Accessed Jun.4, 2026.

55

Transorbital Approach

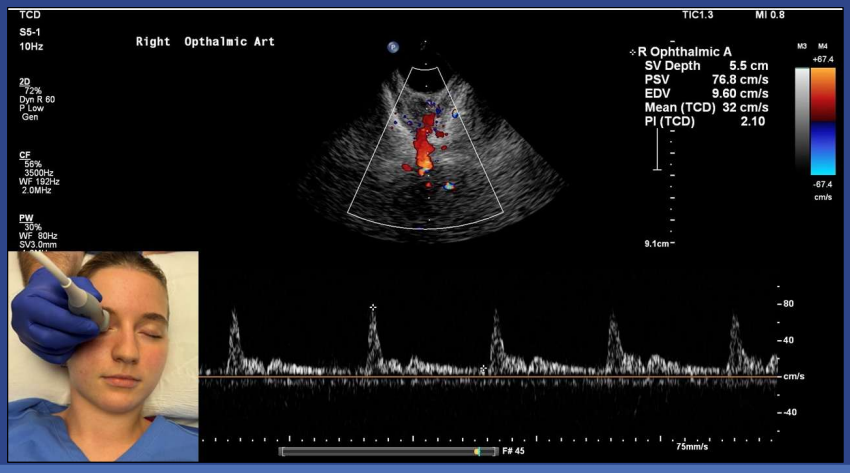

From personal files of Vargas-Ikits P. (on file with author).

56

© Copyright. Society of Diagnostic Medical Sonography. All Rights Reserved.

Orbital Approach

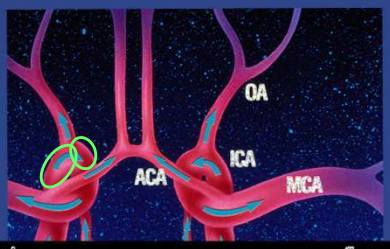

Carotid Siphon

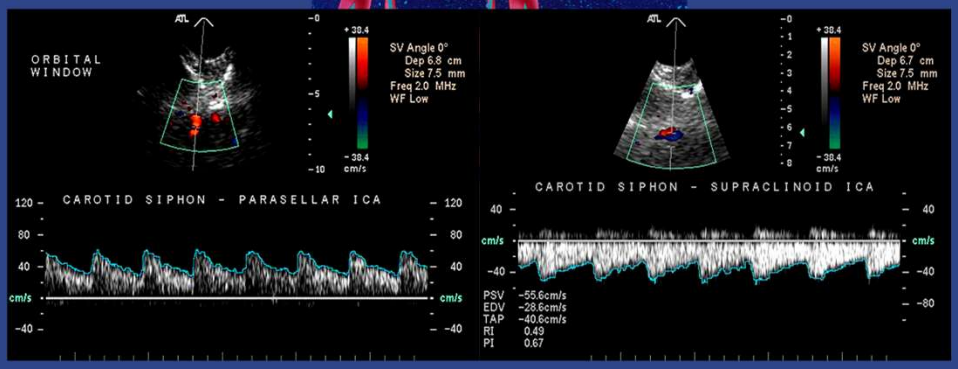

Parasellar ICA
TAMV 47 +/- 14cm/sec

Supraclinoid ICA
TAMV 41 +/- 11cm/sec

From personal files of Vargas-Ikits P. (on file with author).

57

Submandibular Approach

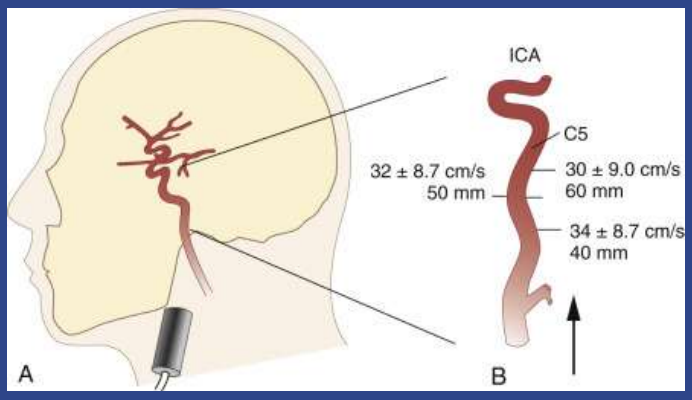



Radiology Key. Ultrasound Assessment of the intracranial Arteries. 2029. https://radiologykey.com/ultrasound-assessment-of-the-intracranial-arteries-2/. Accessed May 23, 2022.

Carrizosa. Transcranial Doppler Approaches: Acoustic Windows. 2021. https://link.springer.com/chapter/10.1007/978-3-030-81419-9_10. Accessed May 23, 2022.

58

© Copyright. Society of Diagnostic Medical Sonography. All Rights Reserved.

Submandibular Approach to ICA

- Calculation of Hemispheric Ratio
(MCA TAMV/ Submandibular ICA TAMV)
- Facilitates detection of dissections

Normal Hemispheric Ratio = 1.7 (1.1-2.3)



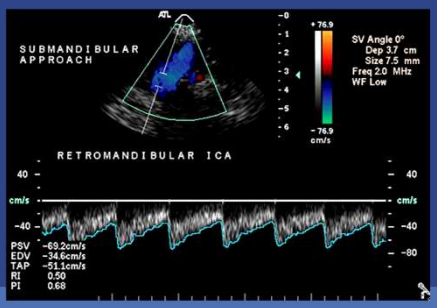

Daigle RJ. Techniques in Noninvasive Vascular Diagnosis. 2023. Accessed Jun.4, 2026.

From personal files of Vargas-Ikits P. (on file with author).

59

Submandibular Approach

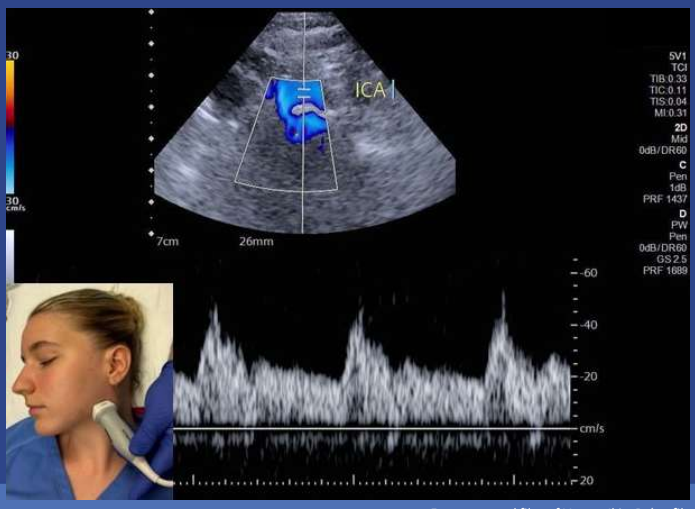

From personal files of Vargas-Ikits P. (on file with author).

60

© Copyright. Society of Diagnostic Medical Sonography. All Rights Reserved.

Suboccipital Approach

- Transducer at base of skull
- Ultrasound beam aimed towards nasion





Daigle RJ. Techniques in Noninvasive Vascular Diagnosis. 2023. Accessed Jun.4, 2026.

61

Suboccipital Approach
Foramen Magnum

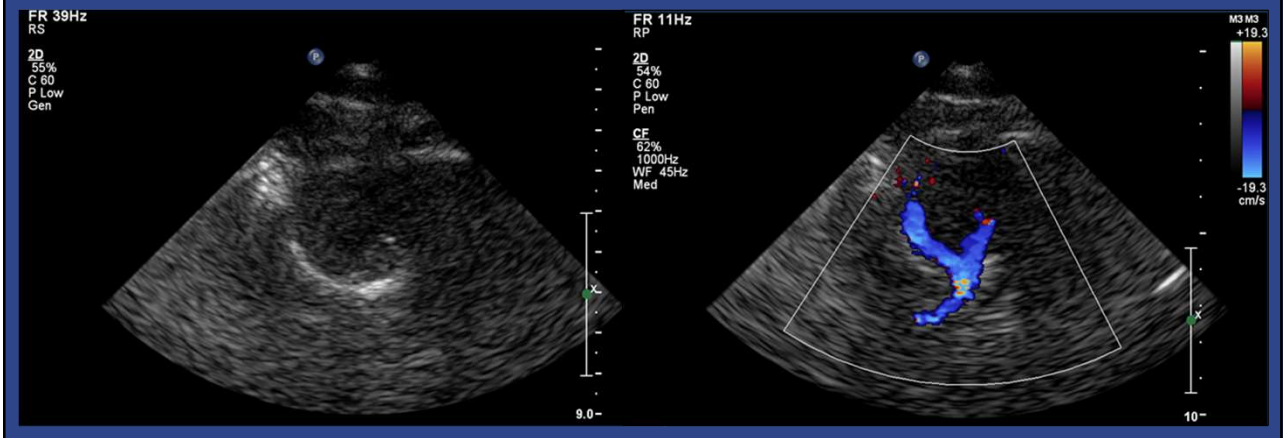

From personal files of Vargas-Ikits P. (on file with author).

62

© Copyright. Society of Diagnostic Medical Sonography. All Rights Reserved.

Suboccipital Approach Vertebral and Basilar Arteries

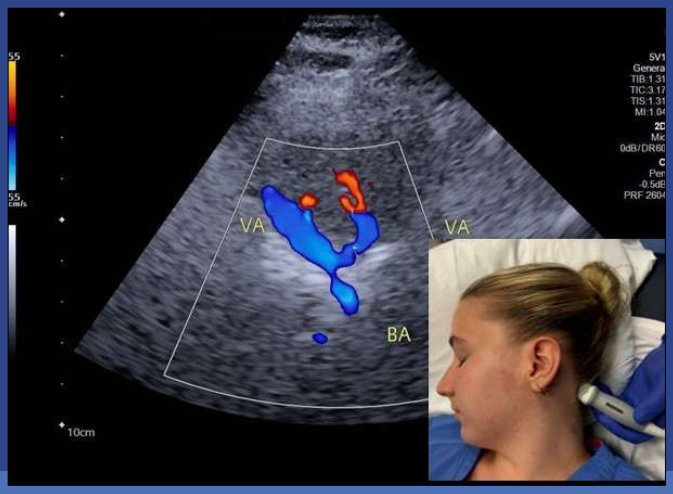

From personal files of Vargas-Ikits P. (on file with author).

63

Suboccipital Approach Foramen Magnum Window

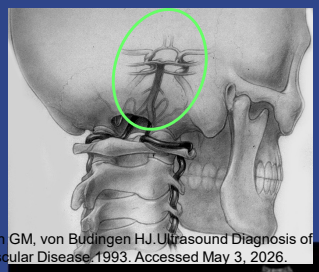

von Reutern GM, von Budingen HJ.Ultrasound Diagnosis of Cerebrovascular Disease.1993. Accessed May 3, 2026.



Daigle RJ. Techniques in Noninvasive Vascular Diagnosis. 2023. Accessed Jun.4, 2026.

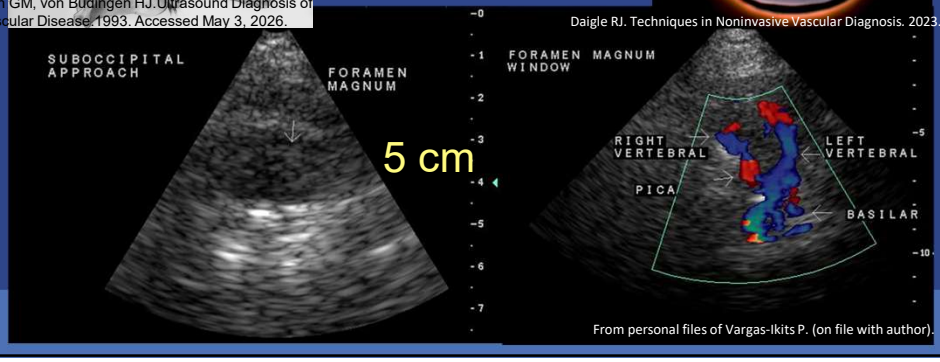

From personal files of Vargas-Ikits P. (on file with author).

64

© Copyright. Society of Diagnostic Medical Sonography. All Rights Reserved.

Suboccipital Approach

Vertebral TAMV
33 - 44 cm/sec

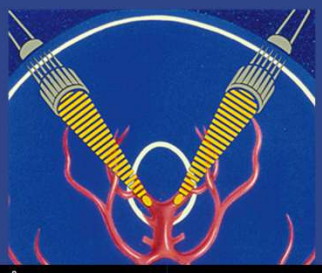

Basilar TAMV
35 - 50 cm/sec

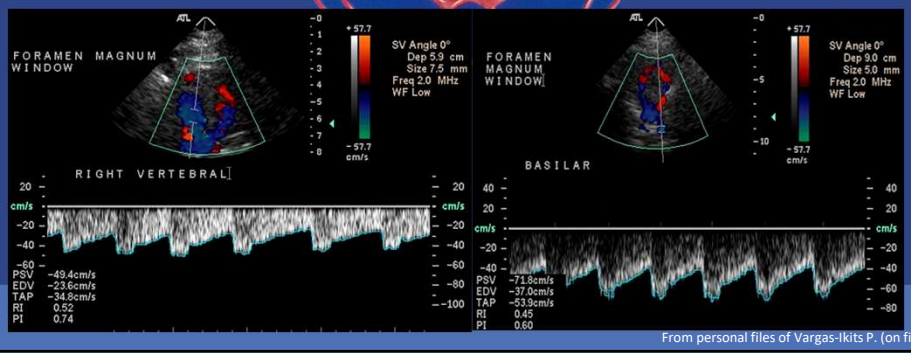

From personal files of Vargas-Ikits P. (on file with author).

65

Vertebral and Basilar Arteries

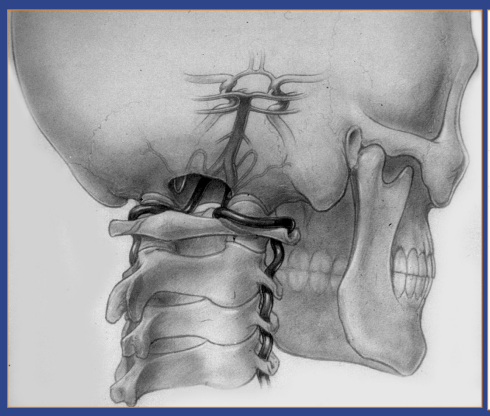

von Reutern GM, von Budingen HJ.Ultrasound Diagnosis of Cerebrovascular Disease.1993. Accessed May 3, 2026.

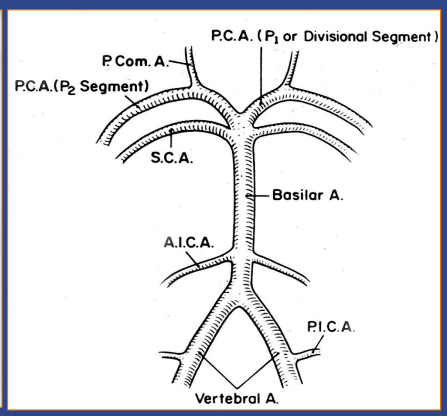

Wood JH. Cerebral blood flow: physiological and clinical aspects. 1987. Accessed May 3, 2026.

66

© Copyright. Society of Diagnostic Medical Sonography. All Rights Reserved.

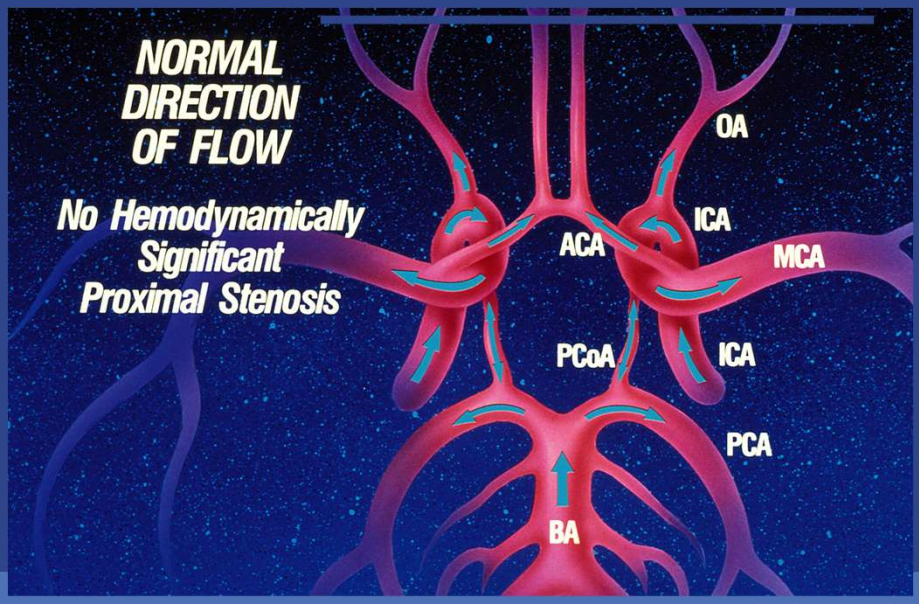

From personal files of Vargas-Ikits P. (on file with author).

67

Middle Cerebral Artery Vasospasm Criteria[3,4,6]

Vasospasm	Velocity (cm/s)	Lindegaard or Sviri Ratio
Mild	120-149	>3.0
Moderate	150-200	>3.0
Severe	>200	>6.0
Hyperdynamic Flow	>80	<3.0

68

© Copyright. Society of Diagnostic Medical Sonography. All Rights Reserved.

Factors Affecting TCD Velocities

CAUSE ↑ VELOCITIES[1]

1. Vasospasm
2. Intracranial atherosclerosis / ↑ Age
3. Hyperemia
4. Hypercapnea
5. Altered collaterals
6. Rewarming after hypothermia
7. Meningitis
8. Inhaled anesthetics
9. Sickle cell anemia
10. Pre-eclampsia

CAUSE ↓ VELOCITIES[1]

1. Increased ICP
2. Hypocapnea (hyperventilation)
3. Post-stenotic lesion
4. Hypotension
5. Hypothermia
6. Anesthetic induction agents except ketamine
7. Hepatic failure
8. Brain death
9. Pregnancy

69

Transcranial Doppler

ADVANTAGES

- Portability
- Easy to operate
- Cost effective

DISADVANTAGES

- Non-imaging makes identification difficult and uncertain
- Variations in anatomy may lead to misinterpretation
- Non versatile system

70

© Copyright. Society of Diagnostic Medical Sonography. All Rights Reserved.

Transcranial Doppler Imaging

ADVANTAGES	DISADVANTAGES
▪ Visual assistance ▪ Quicker vessel & collateral pathways identification ▪ Identification of anatomical variations ▪ Quicker identification of flow direction, turbulence ▪ Possibility of angle correction	▪ Harder to access windows vs. TCD ▪ Not as portable as conventional systems ▪ Knowledge of color Doppler principles are essential

71

Technical Hints

- A decreased sector size will improve frame rate and enhance quality of imaging.
- Keep the wall filter as low as possible so that low velocity, low amplitude signals can be detected.
- The scanning motion used to identify different parts of the Circle of Willis should be minimal.
- ***Learn your anatomy!*** Use color to show flow direction for vessel identification, and to demonstrate crossover or collateral flow.

72

© Copyright. Society of Diagnostic Medical Sonography. All Rights Reserved.

Technical Hints

- Normal flow velocities: MCA>ACA>PCA>Basilar>Vertebral.
- ACoA & PCoA will not be routinely insonated. These small vessels (<1mm) will dilate when acting as collaterals. [7]
- Four main collateral pathways can be distinguished:
  - Via the ACoA
  - Via the PCoA
  - Via the OA
  - Via the ipsilateral leptomeningeal arteries

73

Technical Hints

- With 80% ICA stenosis or more, the ipsilateral MCA velocity and the PI generally decrease as a result of vasodilatation in the distal arterial circulation ipsilateral to the obstruction.[8]
- Increased velocities and turbulence are encountered and usually indicate collateralization. [8]

74

© Copyright. Society of Diagnostic Medical Sonography. All Rights Reserved.

Remember!

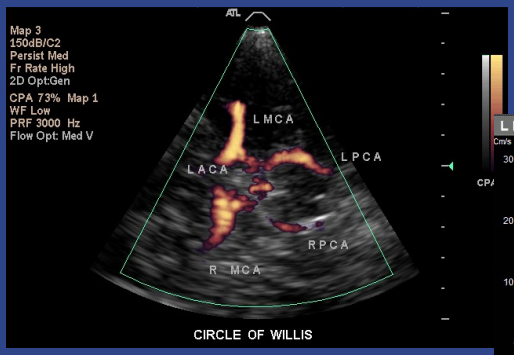

Road Map

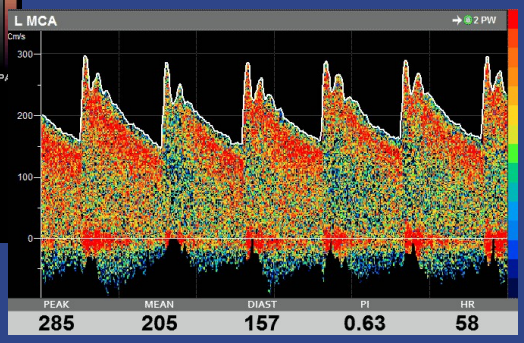

Diagnostic Data

From personal files of Vargas-Ikits P. (on file with author).

Goldemund. Transcranial Doppler Ultrasound. 2025. https://www.stroke-manual.com/transcranial-doppler-ultrasound/. Accessed May 24, 2022.

75

Case 1

- 68-year-old RH man with long-standing history of migraines including visual scotoma, and recent history of multiple closed head injuries brought himself to the emergency department two days after developing abrupt onset of visual loss in his left visual field.
- He denies any motor, sensory, coordination or speech changes.



From personal files of Vargas-Ikits P. (on file with author).

76

© Copyright. Society of Diagnostic Medical Sonography. All Rights Reserved.

Case 1

- He is a detailed historian and feels very strongly that he caused the stroke by looking at his laptop for too long.
- In the past if he looked at any type of fluorescent or strobe lights, he developed floaters, visual changes and bright spots in his vision.
- When his symptoms began this time, he had been looking at the computer for approximately two hours when he noticed floating black diamonds, moving from right to left in his visual field.

77

Case 1

Physical Exam:

- Alert, oriented
- Normal mentation
- Fluent speech
- Dense left homonymous hemianopsia
- No weakness
- No coordination deficits
- No sensory deficits

78

© Copyright. Society of Diagnostic Medical Sonography. All Rights Reserved.

Case 1

- Where is the lesion?
  - Why?
- What vessel is involved?
- What is the likely etiology?

79

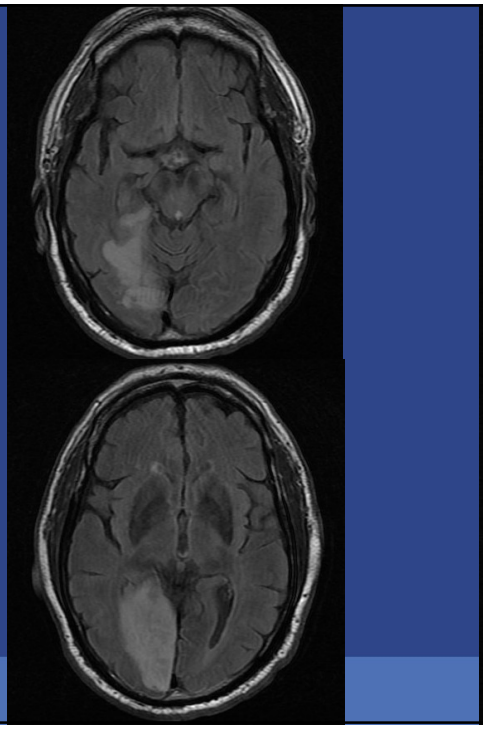

Czartoski T. TCD Neuroanatomy. 2009. Accessed May 7, 2026.

80

© Copyright. Society of Diagnostic Medical Sonography. All Rights Reserved.

Posterior Cerebral Artery

- Branch of the Basilar artery
  - In some cases, might be a terminal branch of Posterior communicating artery from anterior circulation
- Supplies: Occipital and Temporal lobes
- Symptoms
  - Visual disturbances
    - Loss
    - Agnosias (colors, faces, objects)
  - Memory impairment
  - Aphasia
  - Sensory deficits
  - Alexia without agraphia

81

Case 2

- 67-year-old male patient presented to the emergency room 1 hour after onset of left side weakness and numbness, and with some difficulty expressing himself.
- Head CT negative
- Phone consultation → rtPA given for acute stroke and patient was transferred to the hospital.



82

© Copyright. Society of Diagnostic Medical Sonography. All Rights Reserved.

Case 2

Physical Exam

- Sleepy but arousable
- Followed commands, both on the right side and midline
- Right gaze preference, but can look in all directions
- Incomplete left field cut
- Slight left facial droop with asymmetric smile
- Slight tongue deviation to the left

83

Case 2

- Motor
  - Flaccid throughout the left side, normal on the right.
  - He does withdraw aggressively pinch in LLE
- Sensory
  - He can feel sensation throughout his left side, but responses to examination are inconsistent, suggesting some neglect and lack of sensation on the left side.
- Left toe is briskly upgoing, right is downgoing

84

© Copyright. Society of Diagnostic Medical Sonography. All Rights Reserved.

Case 2

- Where is the lesion?
  - Why?
- What vessel is involved?
- What is the likely etiology?

85

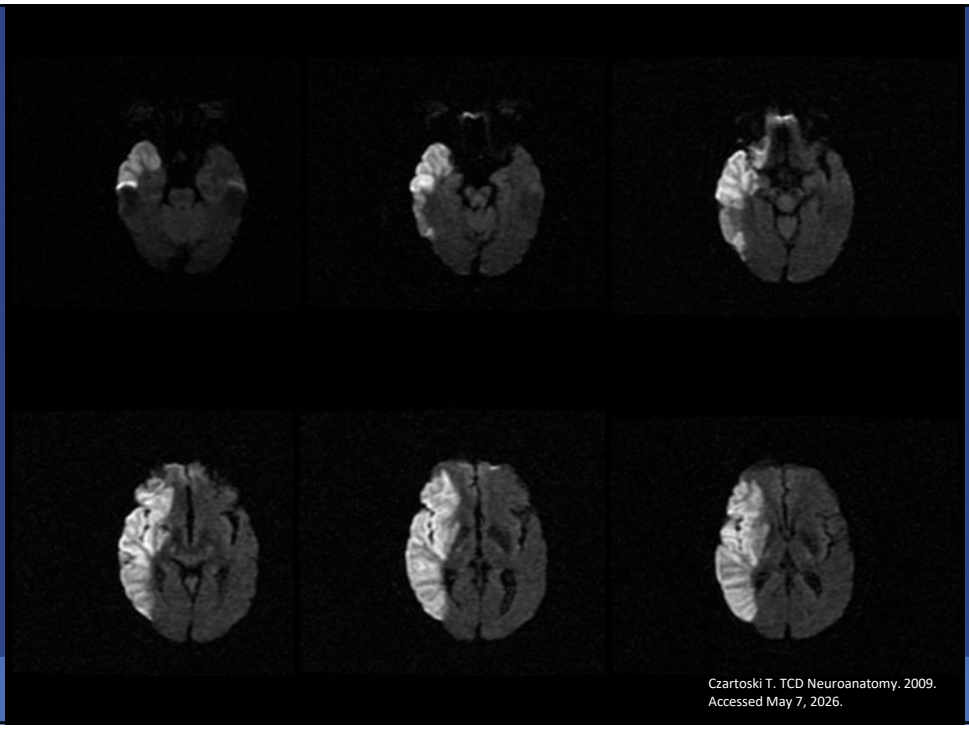

86

© Copyright. Society of Diagnostic Medical Sonography. All Rights Reserved.

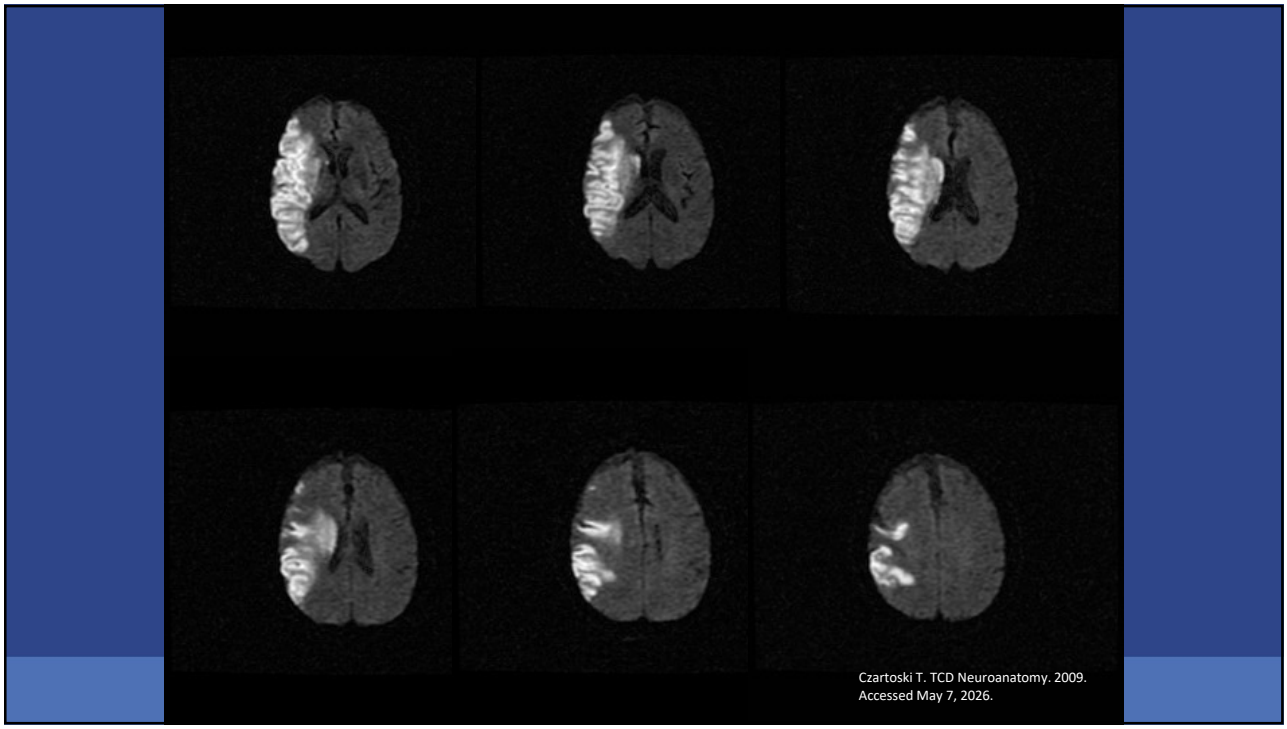

87

Middle Cerebral Artery

- Largest branch of ICA
- Most common vessel effected
- Supplies: Frontal, Parietal, Temporal lobes, deep nuclei
- Symptoms:
  - Hemiparesis or hemiplegia
  - Hemisensory loss
  - Aphasia
  - Vision field disturbances
  - Neglect
  - Eye deviation
  - Movement disorders

88

© Copyright. Society of Diagnostic Medical Sonography. All Rights Reserved.

Middle Cerebral Artery

- Left MCA
  - Aphasia
  - Apraxia
- Right MCA
  - Neglect
  - Dressing apraxia
  - Visual spatial deficits
  - Confabulation

89

Case 3

- 72-year-old man with abrupt onset of inability to speak
- Found at home by a neighbor motioning for help but unable to produce any words
- Unable to provide further details



90

© Copyright. Society of Diagnostic Medical Sonography. All Rights Reserved.

Case 3

- Frustrated gentleman sitting up in bed, waving his arms.
- Mute
- Cranial Nerves intact
- Follows simple commands but not multi-step or complex tasks.
- Intact strength, sensation, coordination, gait
- No visual disturbances

91

Case 3

- Where is the lesion?
  - Why?
- What vessel is involved?
- What is the likely etiology?

92

© Copyright. Society of Diagnostic Medical Sonography. All Rights Reserved.

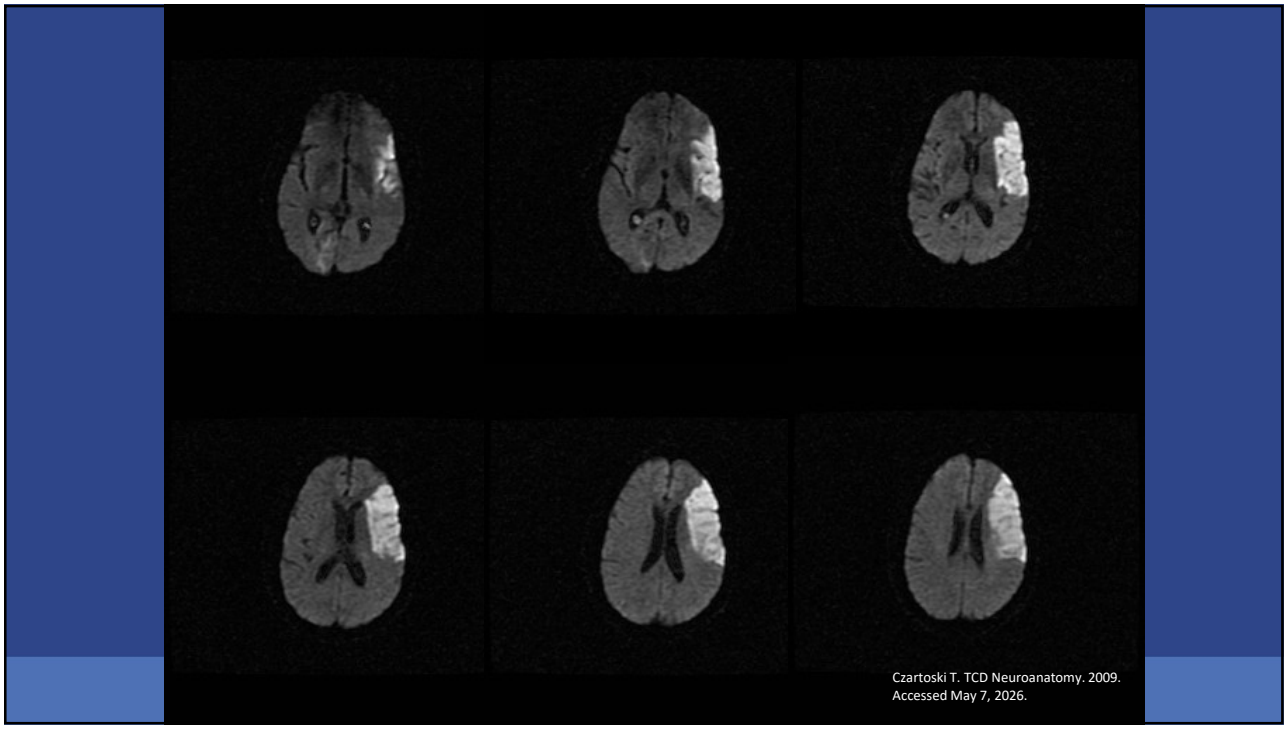

93

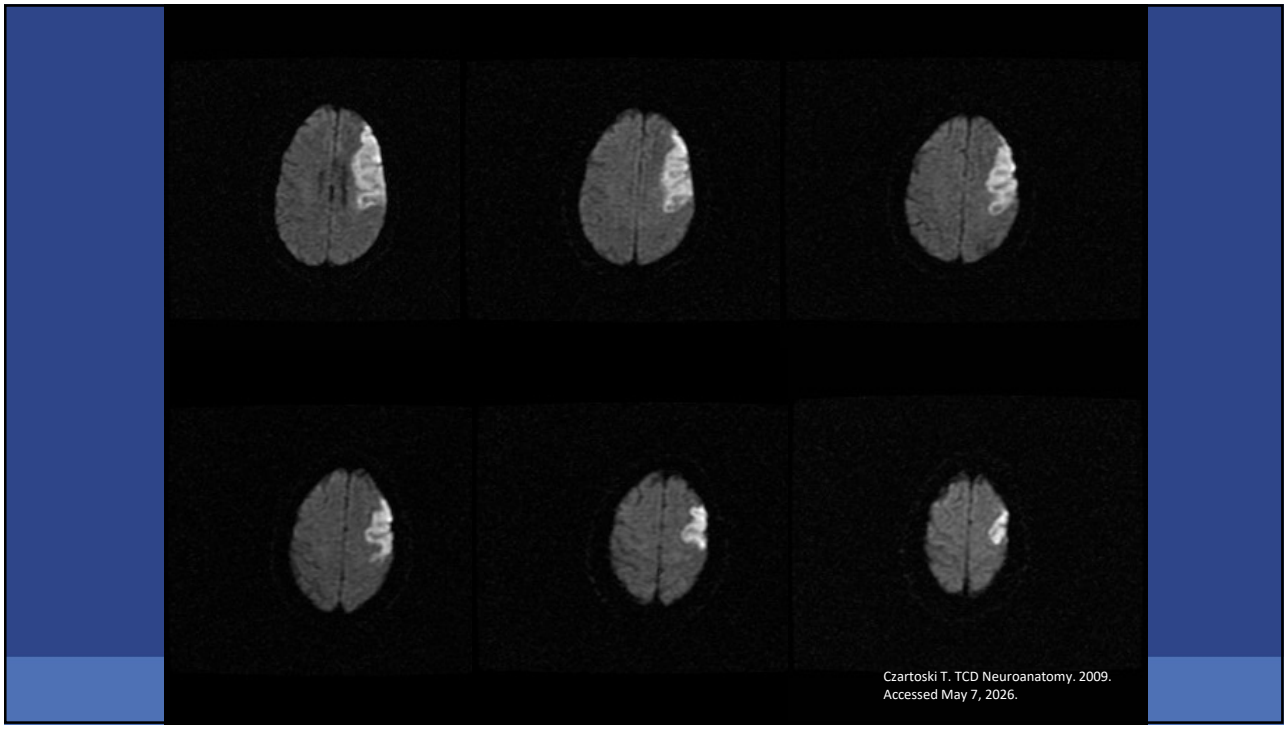

94

© Copyright. Society of Diagnostic Medical Sonography. All Rights Reserved.

Middle Cerebral Artery

- Left MCA
  - Aphasia
  - Apraxia
- Right MCA
  - Neglect
  - Dressing apraxia
  - Visual spatial deficits
  - Confabulation

95

References

1. Alexandrov AV. *Cerebrovascular Ultrasound in Stroke Prevention and Treatment*. John Wiley & Sons; 2011.
2. Kupinski AM. *Diagnostic Medical Sonography: The Vascular System*. LWW; 2022.
3. Pellerito JS, Polak JF. *Introduction to Vascular Ultrasonography*. Elsevier; 2020.
4. Wijdicks EFM, Varelas PN, Gronseth GS, Greer DM. Evidence-based guideline update: Determining brain death in adults: Report of the Quality Standards Subcommittee of the American Academy of Neurology. *Neurology*. 2010;74(23):1911-1918. doi:10.1212/wnl.0b013e3181e242a8
5. Daigle RJ. *Techniques in Noninvasive Vascular Diagnosis*. Summer Publishing LLC; 2023.
6. Kumar G, Alexandrov A. Vasospasm Surveillance With Transcranial Doppler Sonography in Subarachnoid Hemorrhage. *Journal of Ultrasound Medicine: Official Journal of the American Institute of Ultrasound in Medicine*2015;34(8):1345-1350. doi:10.7863/ultra.34.8.1345
7. Yuhn C, Oshima M, Chen Y, Hayakawa M, Yamada S. Uncertainty quantification in cerebral circulation simulations focusing on the collateral flow: Surrogate model approach with machine learning. *PLOS Computational Biology/PLoS computational biology*. 2022;18(7):e1009996. doi:10.1371/journal.pcbi.1009996
8. Zhao L, Barlinn K, Sharma VK, et al. Velocity Criteria for Intracranial Stenosis Revisited. *Stroke*. 2011;42(12):3429-3434. doi:10.1161/strokeaha.111.621235

96

© Copyright. Society of Diagnostic Medical Sonography. All Rights Reserved.

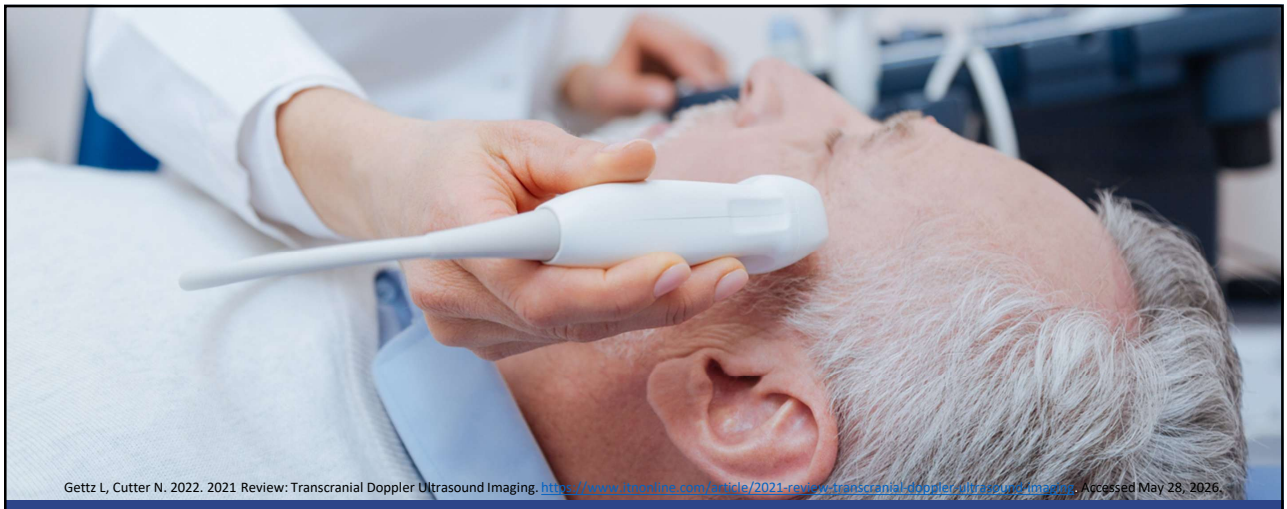

Gettz L, Cutter N. 2022. 2021 Review: Transcranial Doppler Ultrasound Imaging. https://www.lfmonline.com/article/2021-review-transcranial-doppler-ultrasound-imaging. Accessed May 28, 2026.

THANK YOU

Patricia Vargas-Ikits

pvargas2@touro.edu

97

© Copyright. Society of Diagnostic Medical Sonography. All Rights Reserved.