Unlocking the Power of Peripheral Arterial Physiologic Testing



Patricia Vargas-Ikits, DHSc, RVT
Professor & Founding Program Director
Diagnostic Medical Sonography Program
Touro University California

1

SPEAKER PRESENTATION DISCLAIMER

The content and views presented are made available for educational purposes only. The information presented are the opinions of the presenter and do not necessarily represent the views of the Society of Diagnostic Medical Sonography (SDMS) or its affiliated organizations, officers, Boards of Directors, or staff members.

The presenter is responsible for ensuring balance, independence, objectivity, scientific rigor, and avoiding commercial bias in their presentation. Before making the presentation, the presenter is required to disclose to the audience any relevant financial interests or relationships with manufacturers or providers of medical products, services, technologies, and programs.

The SDMS and its affiliated organizations, officers, Board of Directors, and staff members disclaim any and all liability for all claims that may arise out of the use of this educational activity.

2

© Copyright. Society of Diagnostic Medical Sonography. All Rights Reserved.

RESEARCH DISCLAIMER

The information presented in this presentation is based on research conducted to the best of the presenters' abilities and knowledge. Research involves uncertainty and is subject to limitations. The findings and conclusions presented herein may be influenced by various factors including but not limited to data quality, methodology, assumptions, and interpretation.

Research outcomes may not always accurately predict real-world scenarios or future events. While the presenter may make efforts to ensure the accuracy and reliability of the information presented, completeness or absolute correctness is not guaranteed. This presentation is intended for informational purposes only and should not be construed as professional advice. Participants are encouraged to independently verify any information provided and consult relevant experts or professionals where appropriate.

The SDMS and its affiliated organizations, officers, Board of Directors, and staff members disclaim any and all liability for all claims that may arise out of the use of this educational activity.

3

GENERATIVE AI DISCLAIMER

The presenter utilized the use of large language models (LLMs) and generative artificial intelligence (AI) as a productivity tool to assist in drafting and refining content in this presentation.

While these tools can aid in structuring ideas, summarizing, paraphrasing, and language polishing, they have inherent limitations and cannot replace human creativity, critical thinking, or expert judgment. AI-generated content may contain errors, biases, or gaps in knowledge.

This presentation is intended for informational purposes only and should not be construed as definitive or authoritative guidance. Participants are encouraged to critically evaluate the information presented and consult relevant experts as needed. The SDMS and its affiliated organizations, officers, Board of Directors, and staff members disclaim any and all liability for claims that may arise from the use or interpretation of this educational material.

4

© Copyright. Society of Diagnostic Medical Sonography. All Rights Reserved.

Objectives

1. Identify peripheral arterial disease and describe methods to estimate disease severity using physiologic testing.
2. Explain techniques used in arterial physiologic testing to determine whether symptoms are arterial in origin.
3. Describe the role of exercise testing and serial assessments in evaluating arterial response and monitoring disease progression.

5

Introduction

Arterial physiologic testing of the extremities is a common noninvasive and indirect diagnostic technique used to detect peripheral arterial atherosclerotic and microvascular disease and its severity.

Specific locations in the arterial tree are not assessed directly with physiologic techniques; instead, various segments of the arterial system are evaluated for presence of peripheral arterial disease based on waveform and pressure evaluation.

Waveforms can include pulse volume recordings (PVRs), continuous wave (CW), and photoplethysmographic waveforms.

6

© Copyright. Society of Diagnostic Medical Sonography. All Rights Reserved.

Upper Extremity Anatomy

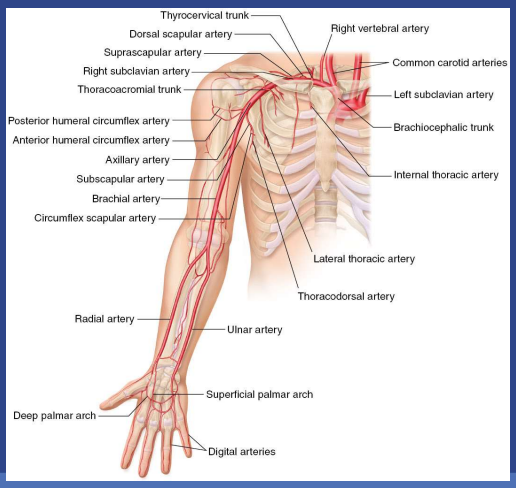

- The subclavian artery is located in the upper thorax, inferior to the clavicle. [1]
- The axillary artery is a continuation of the subclavian artery, beginning at the outer border of the first rib and courses through the axilla.
- The brachial artery is a continuation of the axillary artery, and it provides the main arterial supply to the arm.
- The brachial artery bifurcates into the radial and ulnar arteries after the antecubital fossa at the level of the elbow. In 15-20% of individuals this bifurcation may occur more proximally.
- The radial artery courses along the lateral aspect of the wrist.
- The ulnar artery courses medially in the forearm.

Kupinski A. Diagnostic Medical Sonography: The Vascular System. 2020. Accessed Jul.1, 2026.

7

Hand Anatomy

- The superficial palmar arch is a direct extension of the ulnar artery and gives rise to the digital arteries.
- The deep palmar arch is a direct extension of the radial artery and supplies blood flow to the thumb and index finger. [1]
- The superficial palmar arch is joined by a branch of the radial artery. The deep palmar arch is joined by a branch of the ulnar artery.
- These communicating branches may be absent resulting in incomplete palmar arches.

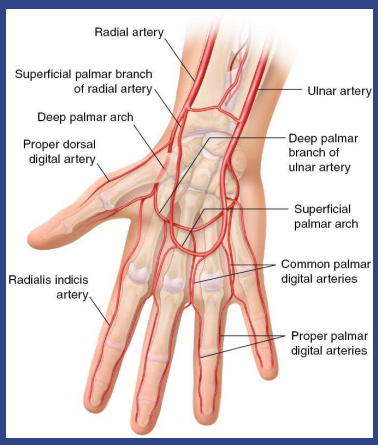

Kupinski A. Diagnostic Medical Sonography: The Vascular System. 2020. Accessed Jul.1, 2026.

8

© Copyright. Society of Diagnostic Medical Sonography. All Rights Reserved.

Lower Extremity Anatomy

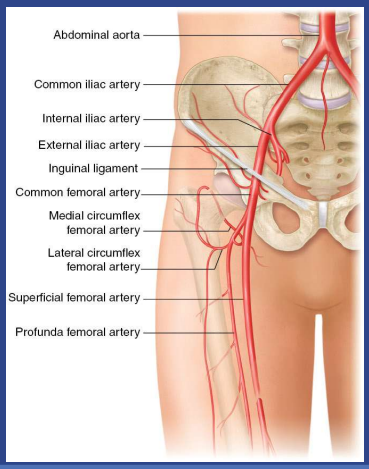

- The external iliac artery (EIA) is a continuation of the common iliac artery (CIA).
- The external iliac artery originates at the level of the sacroiliac joint.
- The common femoral artery (CFA) is the continuation of the EIA distal to the inguinal ligament.
- Approximately 5 cm distal to the inguinal ligament, the CFA bifurcates into the superficial femoral artery (SFA) and deep femoral artery (DFA), also called profunda femoral artery. [2]

Kupinski A. Diagnostic Medical Sonography: The Vascular System. 2020. Accessed Jul.1, 2026.

9

Lower Extremity Anatomy

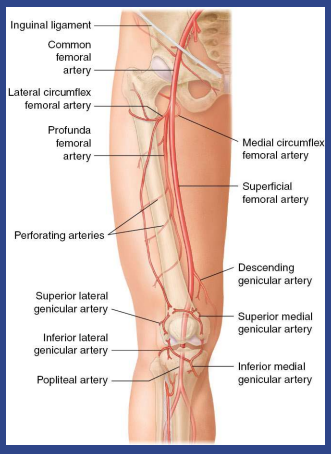

- After the adductor canal at the level of the distal thigh, the SFA becomes the popliteal artery.
- The popliteal artery bifurcates into the tibio-peroneal trunk (TPT) and the anterior tibial artery (ATA)

Kupinski A. Diagnostic Medical Sonography: The Vascular System. 2020. Accessed Jul.1, 2026.

10

© Copyright. Society of Diagnostic Medical Sonography. All Rights Reserved.

Lower Extremity Anatomy

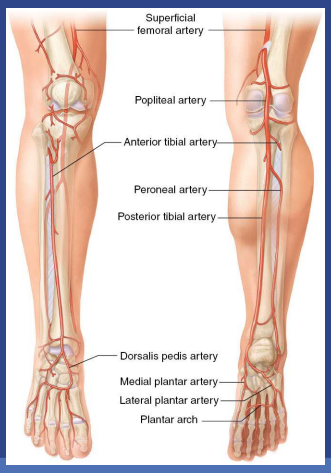

The anterior tibial artery (ATA) courses through the anterior compartment of the calf, descending along the anterior surface of the interosseous membrane and becomes the dorsalis pedis artery (DPA) at the level of ankle.

The TPT bifurcates into the posterior tibial artery (PTA) and peroneal artery (PER A).

The PTA courses medially down the calf and passes posterior to the medial malleolus at ankle level. It forms the medial and lateral plantar arteries.

The peroneal artery descends behind the fibula and communicates with the ATA near the lateral malleolus. [2]

Kupinski A. Diagnostic Medical Sonography: The Vascular System. 2020. Accessed Jul.1, 2026.

11

Patient Preparation for Indirect Physiologic Testing[2,3,4]

- The examination should be bilateral whenever possible so that flow in both limbs can be compared.
- The examination should be performed in a warm room so that the effects of peripheral vasoconstriction are minimized.
- The patient must be supine for the examination and ideally at rest for at least 10-15 minutes prior to the examination to stabilize systemic pressure and establish a reliable baseline reference.
- Smoking should be prohibited at least 10 minutes prior to the study as this may falsely lower the ankle-brachial index (ABI).

12

© Copyright. Society of Diagnostic Medical Sonography. All Rights Reserved.

Physical Examination

Physical examination is an essential part of arterial indirect physiologic testing, and this includes the observation of any indication of arterial disease and the palpation of pulses.

Physical Signs of Disease[3]

- Pallor, pain, paresis, pulselessness
- Coldness
- Dependent rubor
- Cyanotic toes
- Ulceration on feet or ankles
- Non-healing wound
- Blue toe syndrome

13

Palpation of Pulses

Palpation of peripheral pulses has traditionally been part of the physical examination. However, it is important to highlight that it provides subjective information. Limb pressure measurements provide objective information and are considered more reliable than pulse palpation.

Pulse Grading Scale:[3]

0 = No pulse
1 = Weak pulse
2 = Normal pulse
3 = Very strong pulse

14

© Copyright. Society of Diagnostic Medical Sonography. All Rights Reserved.

Contraindications[2,3,4]

A physiologic examination may be limited or contraindicated in patients with:

- Acute deep vein thrombosis (DVT) due to the potential of thrombus dislodgement.
- Extensive bandages or casts in the extremities to be evaluated.
- Ulceration, trauma, or a recent surgical procedure affecting the area to be evaluated.
- Dialysis access graft due to the potential of graft complications*.
- History of mastectomy with axillary node dissection to help minimize edema*.

**Ensure to obtain the patient's history prior to the examination.*

15

Essential Goals of Indirect Physiologic Testing[3]

Determine evidence of peripheral arterial disease (PAD).	If arterial disease is present provide estimate of severity and level of disease.	Assess blood flow in extremities and determine if symptoms are caused by arterial disease.
Evaluate how well the arteries respond to physical activity.	Track changes in arterial circulation over time, particularly in patients with known vascular disease.	Guide treatment decisions and intervention strategies.

16

© Copyright. Society of Diagnostic Medical Sonography. All Rights Reserved.

Indirect Physiologic Testing

Ankle Brachial Index (ABI)[2,5]

- The simplest and most common physiologic test.
- The ABI measures the ratio of the systolic blood pressure at the ankle level to the systolic blood pressure in the arm.
- A cuff is placed around each ankle and each upper arm. See the following section for additional information on cuff technique.
- Systolic pressure measurements from both the posterior tibial artery (PTA) and the dorsalis pedis artery (DPA) bilaterally are obtained using a CW Doppler.
- To ensure accurate ankle brachial indices, brachial arm pressures must be less than 200 mmHg, and the arterial signals must be multiphasic
- For each limb, the ABI is calculated as the highest ankle pressure (PT or DP) divided by the higher brachial (right or left) pressure.

Ankle Brachial Index (ABI) = Highest Ankle Pressure ÷ Highest Brachial Pressure

17

Indirect Physiologic Testing

Segmental Limb Pressures[2,3,4]

- This test is performed to obtain systolic blood pressures at multiple levels in the upper and lower extremities using a handheld Doppler device and blood pressure cuffs.
- **Cuff Size**
  - Width should be 20% wider than the diameter of the underlying limb
  - Cuff too narrow will lead to a falsely elevated pressure
  - Cuff too wide will lead to a falsely lower pressure

18

© Copyright. Society of Diagnostic Medical Sonography. All Rights Reserved.

Indirect Physiologic Testing

Pressure Cuff Application[2,5]

Blood pressure cuffs should be placed in the following locations:

Upper Extremity

- Upper arms – 10 cm, 12 cm cuff in a larger arm
- Lower arms (forearm) – 10 cm
- Wrists – 8 cm

Lower Extremity

- Upper arms – 10 or 12 cm
- Upper thighs – 12 cm
- Lower thighs – 12 cm
- Below knees – 10 cm
- Ankles – 10 cm
- Metatarsals – 6-8 cm

19

Indirect Physiologic Testing

Three-Cuff vs. Four-Cuff Method for Lower Extremities[2,3,4]

- The three-cuff method uses one large thigh cuff (17cm), one cuff below knee, and one cuff at the ankle.
- The four-cuff method uses two smaller thigh cuffs (12 cm), one cuff below knee, and one cuff at the ankle.
- Physiologic equipment can be preset for either cuff method.
- The four-cuff method provides the ability to differentiate ilio-femoral from femoral artery disease

20

© Copyright. Society of Diagnostic Medical Sonography. All Rights Reserved.

Four-Cuff Method



Kupinski A. Diagnostic Medical Sonography: The Vascular System. 2020. Accessed Jul.1, 2026.

21

Indirect Physiologic Testing

Cuff Application Tips[2,3,5]

- When applying arm cuffs, use a 12 cm cuff in patients with large arms.
- When applying arm cuffs, use an 8 cm cuff in pediatric patients
- When applying leg cuffs, use an extra-large cuff (22 cm) in patients with large thighs.
- When applying arm or leg cuffs, do not allow patients to lift their extremity to help. This results in muscle contraction to perform this movement and subsequent muscles relaxation often results in the cuff becoming loose.
- In the lower extremities, start the cuff placement with the bladder on the posterior-medial aspect of the limb.
- Place the high thigh cuff as proximal as possible.
- Place the calf cuff below the bony tibial tuberosity to avoid recording high pressure errors.

22

© Copyright. Society of Diagnostic Medical Sonography. All Rights Reserved.

Indirect Physiologic Testing

Recording Systolic Pressure

- With cuffs in place, a CW Doppler is used to insonate a blood vessel distal to the cuff.
- While listening to the arterial Doppler signal or viewing a tracing of the arterial waveform, pressure in the cuff is inflated until no signal is present.
- Pressure in the cuff is slowly released until a signal returns. This return indicates the systolic pressure under the cuff.
- Pressures can be recorded at each cuff level.

23

Indirect Physiologic Testing

Pulse Volume Recording (PVR)

- A PVR is a qualitative assessment used to measure the change in blood flow related to each cardiac cycle. The PVR instrument output is a waveform which reflects the global perfusion of the limb segment examined.
- Patients should be in a supine position with the cuffs previously placed for segmental pressure measurements.
- Cuffs are sequentially connected to the plethysmograph and inflated to approximately 65 ± 5 mmHg.
- At this pressure, venous outflow from that limb segment does not occur. The only change within the limb segment is the result of arterial inflow.
- The change in volume in the limb is detected as a change in pressure in the cuff. This pressure change is displayed as a waveform.
- Limb motion or tremor will affect waveform contour. Patients should not move or talk during the test to minimize motion artifacts while obtaining the tracing.
- PVR waveforms are recorded at each limb segment where a cuff is placed.
- To optimize waveform amplitude, set the PVR gain.
- To reduce PVR amplitude variability due to cuff air volume differences, be consistent when placing cuffs to ensure they are snug.

24

© Copyright. Society of Diagnostic Medical Sonography. All Rights Reserved.

Indirect Physiologic Testing

CW Doppler Waveforms

- The same CW Doppler used to obtain pressure measurements can provide a waveform which can be used to assess arterial perfusion.
- Position the CW Doppler of the region of the artery to be examined.
- The Doppler is moved slightly medially and laterally to optimize the signal.
- The angle of the Doppler is kept at about 45° to the skin. For the popliteal artery waveform, the angle of the Doppler is closer to 90° to the skin due to the position of the artery.

25

Indirect Physiologic Testing

Photoplethysmography

- Photoplethysmography (PPG) is used to assess blood flow in digits.
- A PPG uses infrared light to detect variations in the light reflected from underlying blood flow.
- A PPG placed over the digits can detect blood flow in tissue at a depth of 1-3 mm.
- Waveform obtained is similar to PVR waveform.
- The PPG may be attached to the digit with double-sided tape or a special clip holder.
- Toe pressures are obtained using a PPG.
- Pressures are obtained by placing small digital cuffs (2.0-2.5 cm diameter) on the great toe.
- Record systolic pressure with PPG transducer by inflating the cuff until waveform disappears and slowly deflate until PPG waveform returns.
- A Toe/Brachial Index can be calculated by dividing each toe pressure by the higher brachial pressure.



Kupinski A. Diagnostic Medical Sonography: The Vascular System. 2020. Accessed Jul.1, 2026.

26

© Copyright. Society of Diagnostic Medical Sonography. All Rights Reserved.

Non-Imaging Physiologic Evaluation

- Doppler Waveform Analysis
- Pressure Assessment
- Plethysmography
- Provocative Maneuvers

27

Non-Imaging Physiologic Evaluation[5]

- Doppler Waveform Analysis
  - Uses continuous-wave Doppler
  - Waveform is assessed
    - Phasicity
    - Amplitude
    - Contour

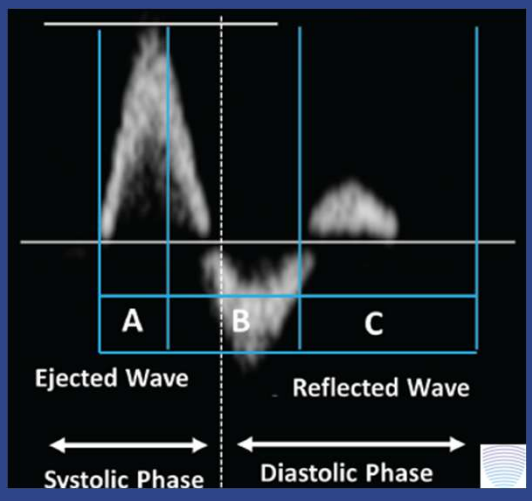

White-Melendez JM, Schroedter WB. The Art of Vascular Ultrasound. 2024. Accessed Jul.1, 2026.

28

© Copyright. Society of Diagnostic Medical Sonography. All Rights Reserved.

Non-Imaging Physiologic Evaluation[5]

- Doppler Waveform Analysis
  - Digital
  - Analog

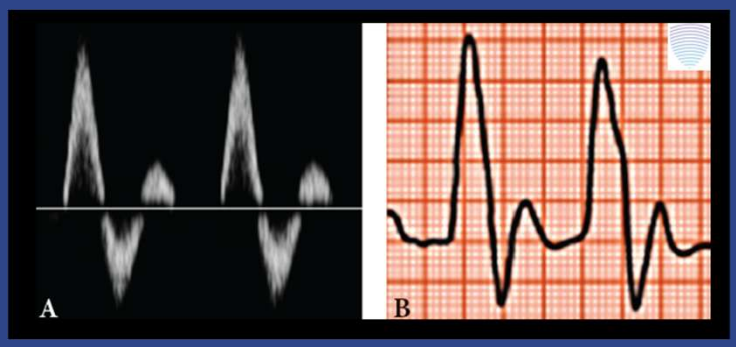

White-Melendez JM, Schroedter WB. The Art of Vascular Ultrasound. 2024. Accessed Jul.1, 2026.

29

Non-Imaging Physiologic Evaluation[5]

Pressure Assessment

A pneumatic cuff is inflated to occlude an artery and Doppler, or another sensor records visual and audible waveforms as blood returns

Single-level pressure: ankle pressure used to calculate an ABI or wrist pressure used to calculate a wrist-brachial index

Multiple-level lower extremity pressure assessment refers to segmental pressures of the thigh, calf, ankle, foot, and great toe and the upper extremity of the upper arm, forearm, wrist, and fingers

30

© Copyright. Society of Diagnostic Medical Sonography. All Rights Reserved.

Non-Imaging Physiologic Evaluation[5]

- Plethysmography
- PVR

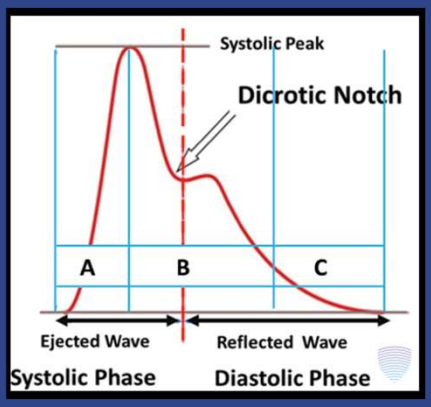

White-Melendez JM, Schroedter WB. The Art of Vascular Ultrasound. 2024. Accessed Jul.1, 2026.

31

Non-Imaging Physiologic Evaluation[5]

- Plethysmography
- PPG

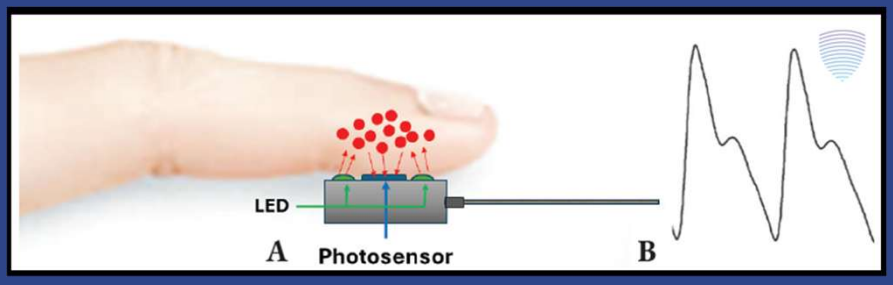

White-Melendez JM, Schroedter WB. The Art of Vascular Ultrasound. 2024. Accessed Jul.1, 2026.

32

© Copyright. Society of Diagnostic Medical Sonography. All Rights Reserved.

Doppler Waveform Analysis Technique

Have	Place	Visualize	Create	Obtain
Have the patient lie supine in a resting (basal) state. Consider room temperature as excessive heat and cold can trigger vasodilation and constriction.	Place the limb at the heart's approximate level to minimize hydrostatic pressure's effects.	Visualize the vessel's course through the limb and apply acoustic gel for contact.	Create a Doppler angle by tilting the transducer for a 40–60-degree angle of insonation.	Obtain signals from all major vessels: • CFA • SFA • Pop A • PTA • ATA / DPA

33

Doppler Waveform Analysis: Interpretation

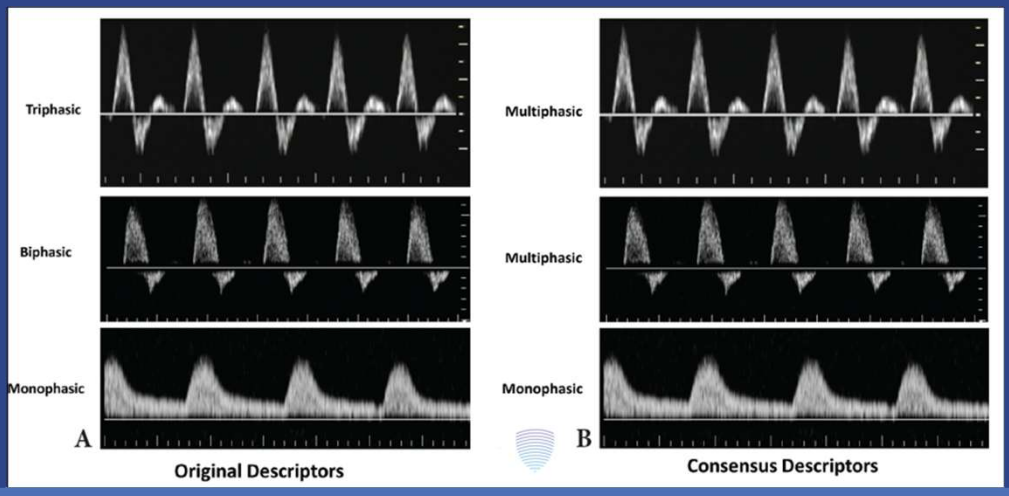

White-Melendez JM, Schroedter WB. The Art of Vascular Ultrasound. 2024. Accessed Jul.1, 2026.

34

© Copyright. Society of Diagnostic Medical Sonography. All Rights Reserved.

Pressure Assessment: ABI Interpretation Criteria

ABI Interpretation Summary

Index	Interpretation	Considerations
> 1.3	medial calcinosis	Perform toe pressures and PVRs.
1.0-1.3	normal	If symptomatic, perform provocative maneuvers.
>0.9 and <1.0	mild disease	If symptomatic, perform provocative maneuvers.
0.5-0.9	occlusive disease with claudication	If an index is 0.80-0.90 and the patient is symptomatic, perform provocative maneuvers.
>0.3 and <0.5	severe occlusive disease	Likely claudication and ischemia, possible rest pain and skin changes.
<0.3	critical occlusive disease	Likely ischemic rest pain, ulceration, and tissue necrosis.

White-Melendez JM, Schroedter WB. The Art of Vascular Ultrasound. 2024. Accessed Jul.1, 2026.

35

Pressure Assessments: Segmental Technique

Obtain segmental pressures in the proper order:[2]

- Upper Extremity: Obtain the brachial, then wait for a few minutes and obtain the radial and then ulnar.
- Lower Extremity: Obtain the arm, then the ankle pressure moving proximally: arm, ankle (dorsalis pedis and posterior tibial arteries), calf, above the knee, and lastly, the thigh.



Kupinski A. Diagnostic Medical Sonography: The Vascular System. 2020. Accessed Jul.1, 2026.

36

© Copyright. Society of Diagnostic Medical Sonography. All Rights Reserved.

Pressure Assessments: TBI Technique



White-Melendez JM, Schroedter WB. The Art of Vascular Ultrasound. 2024. Accessed Jul.1, 2026.

37

Pressure Assessments: TBI Interpretation

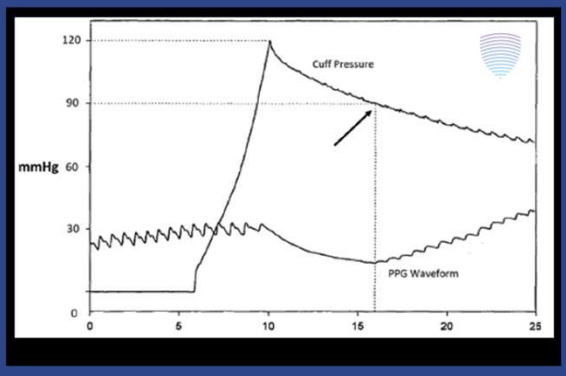

Interpreting Toe Pressures	
Normal	Index > 0.75
Severe peripheral disease	Index < 0.25
Poor healing potential	Absolute < 30 mmHg

White-Melendez JM, Schroedter WB. The Art of Vascular Ultrasound. 2024. Accessed Jul.1, 2026.

38

© Copyright. Society of Diagnostic Medical Sonography. All Rights Reserved.

Plethysmography: *Technique*

- Obtain pulse volume recordings by measuring the change in air volume, producing an analog waveform.
- Place pneumatic cuffs around the limb at specified levels.
- Inflate the with a measured amount of air to a pressure of approximately 40-65 mmHg, depending on the cuff size.
- Obtain photoplethysmography recordings of the changes in blood volumes within the subcutaneous tissues.
- Position the patient lying comfortably supine in a basal state. Elevate the heels slightly, observing for external pressure on a cuff.
- Place the limb at the approximate level of the heart.
- Apply cuffs as described for segmental pressures.
- Inflate an appropriate volume of air to the predetermined pressure level. Most instruments have self-calibration and allow automated presets. Follow manufacturers' recommendations for any calibration as necessary
- Note the pressure and volume of air used at each cuff.
- Use similar gain settings

39

Plethysmography: Interpretation[5]

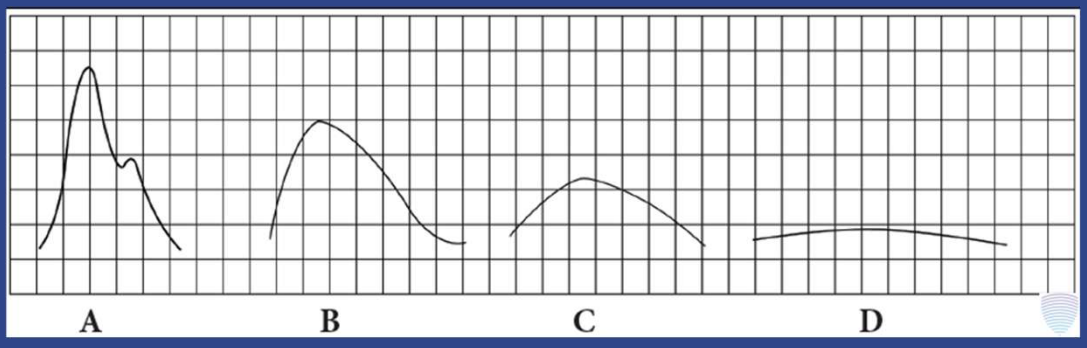

White-Melendez JM, Schroedter WB. The Art of Vascular Ultrasound. 2024. Accessed Jul.1, 2026.

40

© Copyright. Society of Diagnostic Medical Sonography. All Rights Reserved.

Evoking Perfusion Response with Manual Compression: Technique

1. Have the patient sit comfortably with their hands resting in their lap
2. Place a PPG sensor on the first or middle finger
3. Identify the radial and ulnar arteries at the wrist by palpating a pulse
4. Once the finger waveform is normal, compress the radial and ulnar arteries to occlude flow, observe a flatline

41

Evoking Perfusion Response with Manual Compression: Interpretation[5]

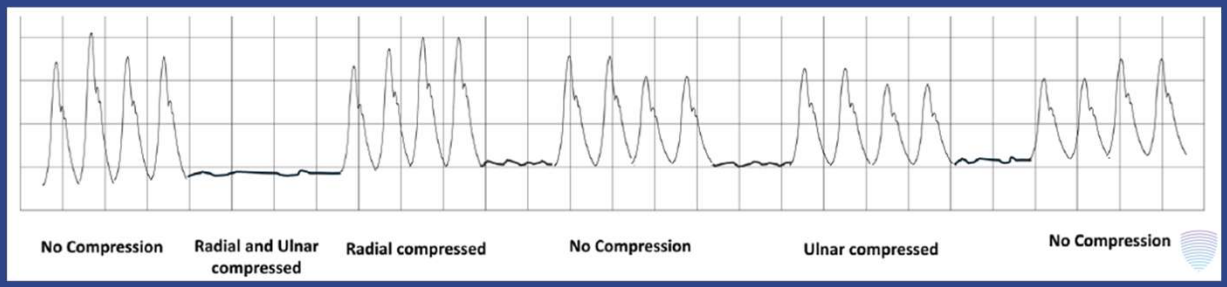

White-Melendez JM, Schroedter WB. The Art of Vascular Ultrasound. 2024. Accessed Jul.1, 2026.

42

© Copyright. Society of Diagnostic Medical Sonography. All Rights Reserved.

Evoking Perfusion Response with Manual Compression: Interpretation[5]

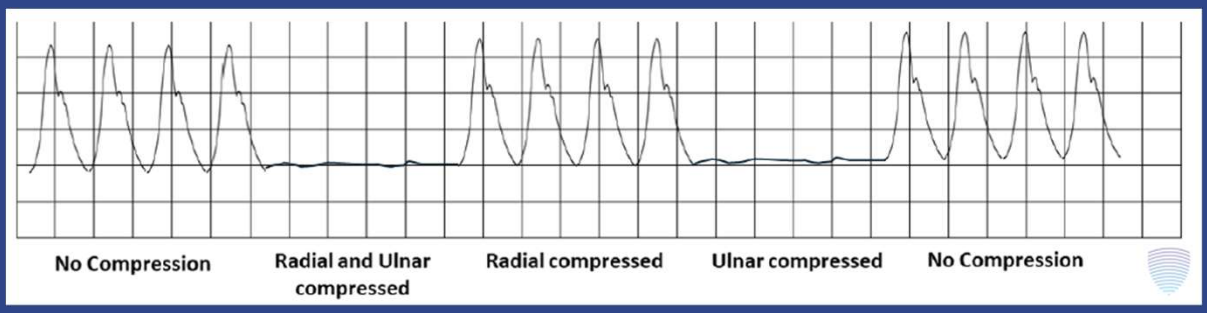

White-Melendez JM, Schroedter WB. The Art of Vascular Ultrasound. 2024. Accessed Jul.1, 2026.

43

Lower Extremity Arterial Physiologic Interpretation Criteria Summary

Vessel Disease		ABI	Doppler Waveform	PVR Waveform	PPG Waveform	TBI Pressure mmHg
	Medial Calcinosis	>1.3				TBI >0.75
	Normal	1.0-1.3				TBI >0.75
	Mild Disease	>0.9 - <1.0				Variable
	Occlusive Disease Claudication	0.5 - 0.9				Waveform and pressure variable dependent on severity and collateralization
	Severe Occlusive Disease	0.3 - <0.5				TBI <0.25
	Critical Occlusive Disease	<0.3				≤30 mmHg Poor healing potential
	Calcified Vessel with Critical ischemia	>1.3				≤30 mmHg Poor healing potential

White-Melendez JM, Schroedter WB. The Art of Vascular Ultrasound. 2024. Accessed Jul.1, 2026.

44

© Copyright. Society of Diagnostic Medical Sonography. All Rights Reserved.

Hemodynamic Factors Affecting an Indirect Physiologic Testing[3]

Advanced Age

Aging commonly leads to stiffer and less compliant arteries, which may affect the examination results.

Cardiac Conditions

Conditions such as heart failure or arrhythmias can alter systemic circulation. For instance, poor cardiac output can lead to reduced perfusion to the extremities, making it difficult to detect accurate signals in the extremities.

Hypertension

Patients with high blood pressure may show falsely elevated ABI results due to stiffened arteries.

Diabetes Mellitus

Diabetes can lead to microvascular and macrovascular changes, such as arterial calcification and endothelial dysfunction. Calcified arteries can cause falsely elevated ABI values, masking the presence of PAD.

Obesity

It can be difficult to obtain clear Doppler signals and accurate blood pressure measurements in obese patients. Obesity can attenuate the pressure changes detected with PVRs.

Cold Temperature

Cold temperature causes vasoconstriction, reducing blood flow to the extremities, which can lead to falsely low values.

Smoking

Smoking causes vasoconstriction and can alter vascular tones, which may lead to falsely high values.

Medications

Certain medications, such as vasodilators or vasoconstrictors, can alter blood pressure, potentially interfering with the test accuracy.

45

Non-invasive Vascular Testing Volume Plethysmography[3]

Normal

- Brisk Upstroke, Decline, Dicrotic Notch
- Increasing Amplitude Thigh to Calf, Decreasing at Ankle & Metatarsal Levels

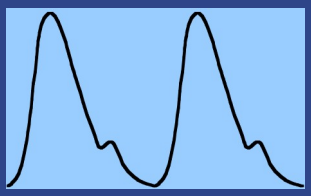

Abnormal

- Decreased Amplitude (vs Expected)
- Rounding of Waveform
- Loss of Dicrotic Notch

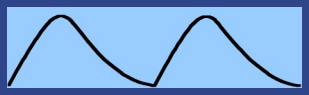

46

© Copyright. Society of Diagnostic Medical Sonography. All Rights Reserved.

Volume Plethysmography
Effect of Stenosis



- Measure change in volume of limb during cardiac cycle
- Dependent on:
  - Cardiac pump
  - Inflow vessels
  - Tissue type / Characteristics
    - Muscle >> Fat >> Bone; Edema

47

Volume Plethysmography
Effect of Collaterals

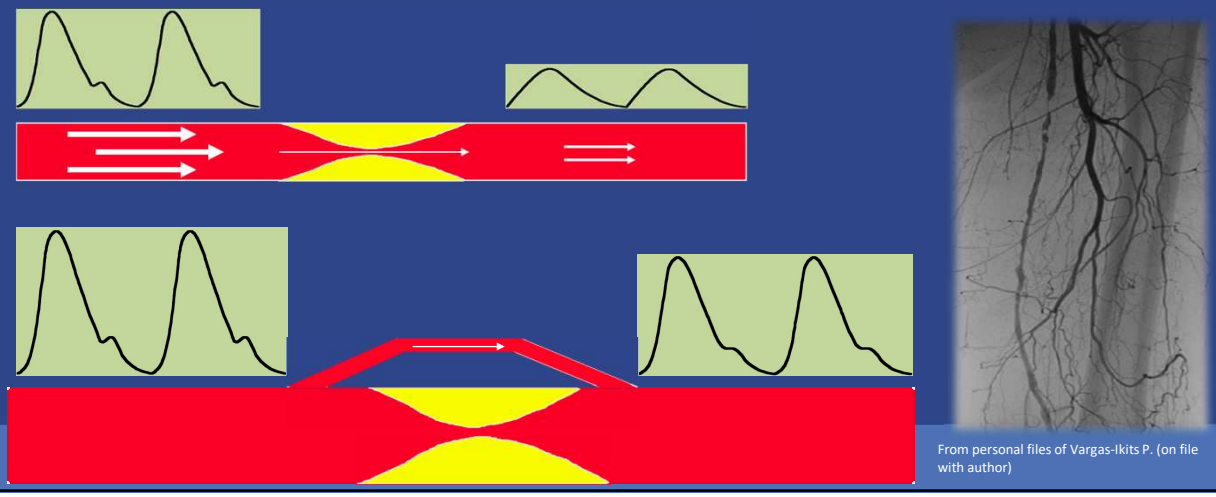

From personal files of Vargas-Ikits P. (on file with author)

48

© Copyright. Society of Diagnostic Medical Sonography. All Rights Reserved.

Compelling Cases

Case 1

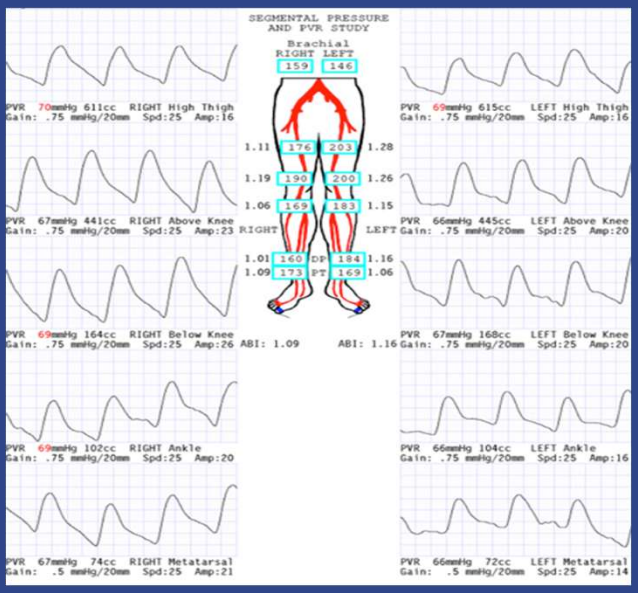

From personal files of Vargas-Ikits P. (on file with author)

© Copyright. Society of Diagnostic Medical Sonography. All Rights Reserved.

Case 2

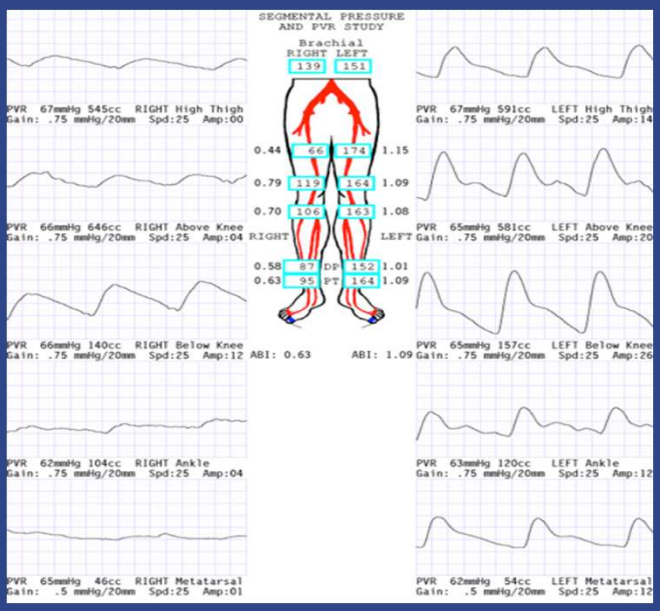

From personal files of Vargas-Ikits P. (on file with author)

51

Case 3

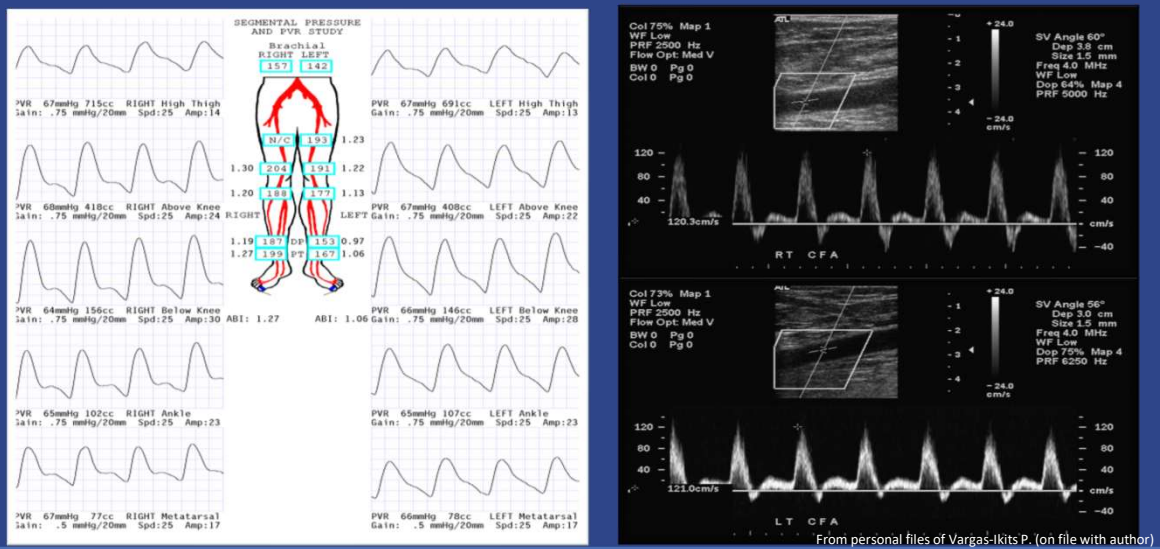

From personal files of Vargas-Ikits P. (on file with author)

Normal Exam

52

© Copyright. Society of Diagnostic Medical Sonography. All Rights Reserved.

Case 4

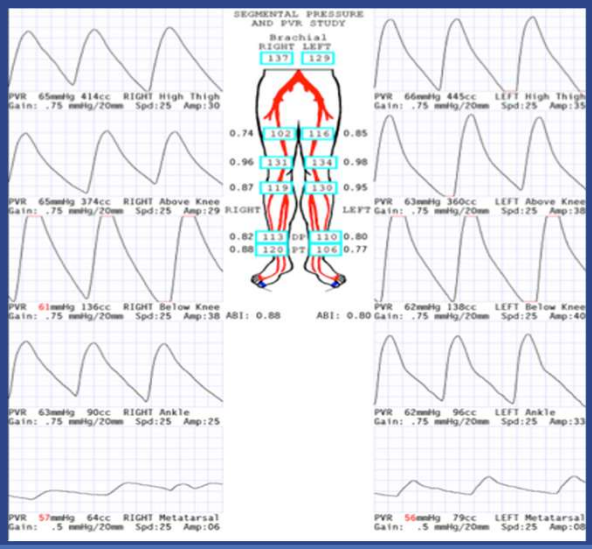

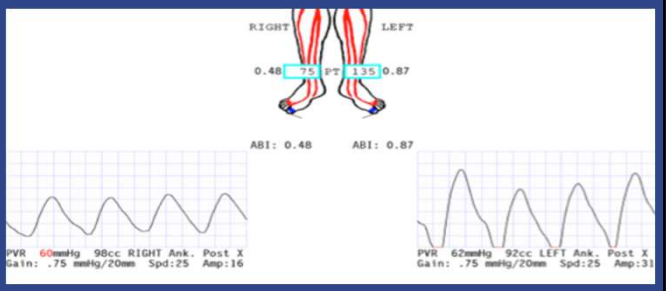

From personal files of Vargas-Ikits P. (on file with author)

Hemodynamic response to exercise

53

Case 5

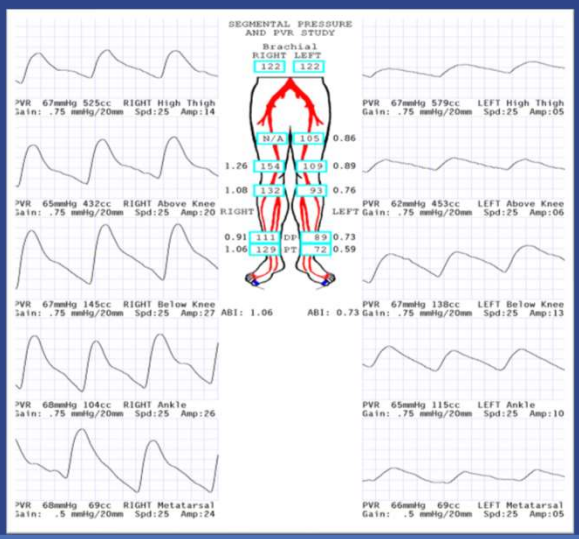

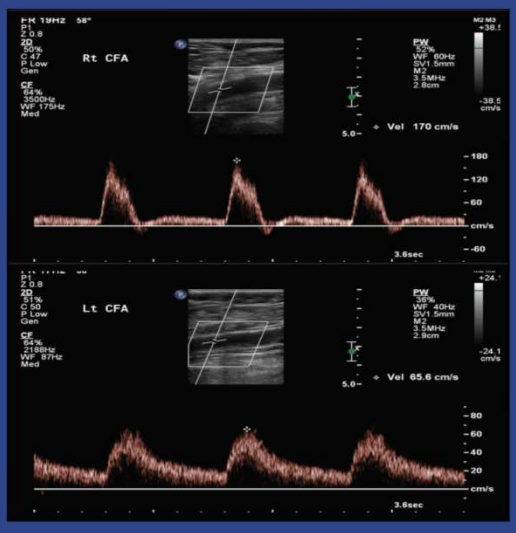

From personal files of Vargas-Ikits P. (on file with author)

Inflow Disease LT

54

© Copyright. Society of Diagnostic Medical Sonography. All Rights Reserved.

Case 6

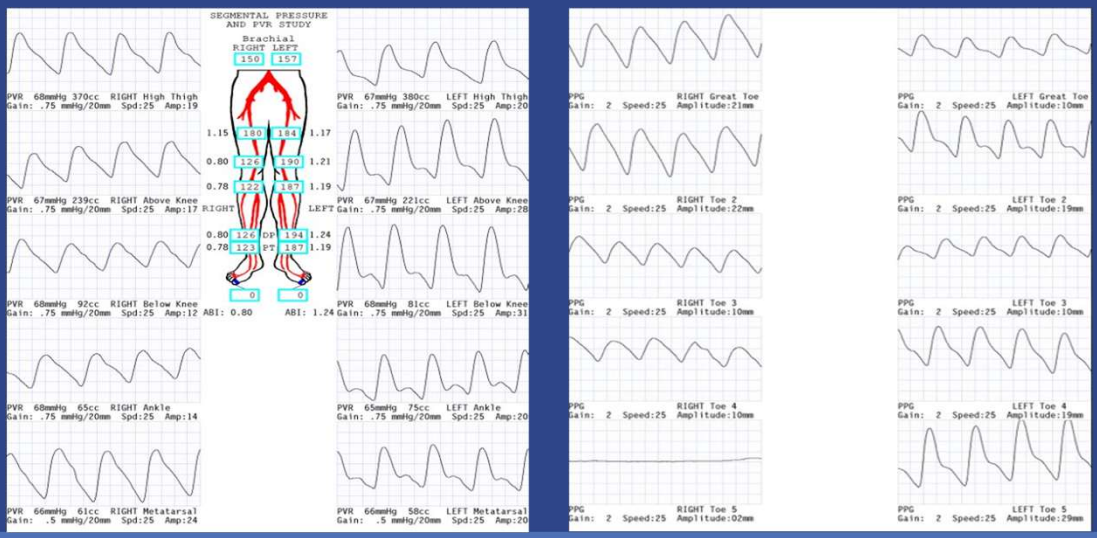

From personal files of Vargas-Ikits P. (on file with author)

55

Where is the disease?



From personal files of Vargas-Ikits P. (on file with author)

56

© Copyright. Society of Diagnostic Medical Sonography. All Rights Reserved.

Case 7

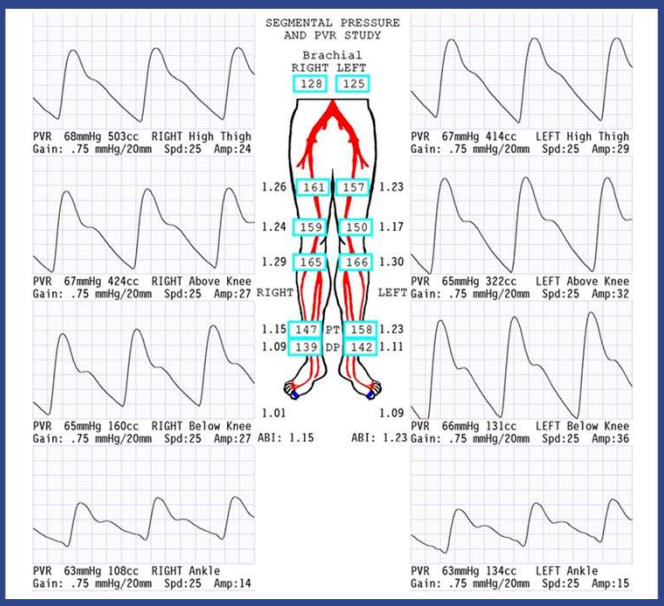

From personal files of Vargas-Ikits P. (on file with author)

57

Case 8

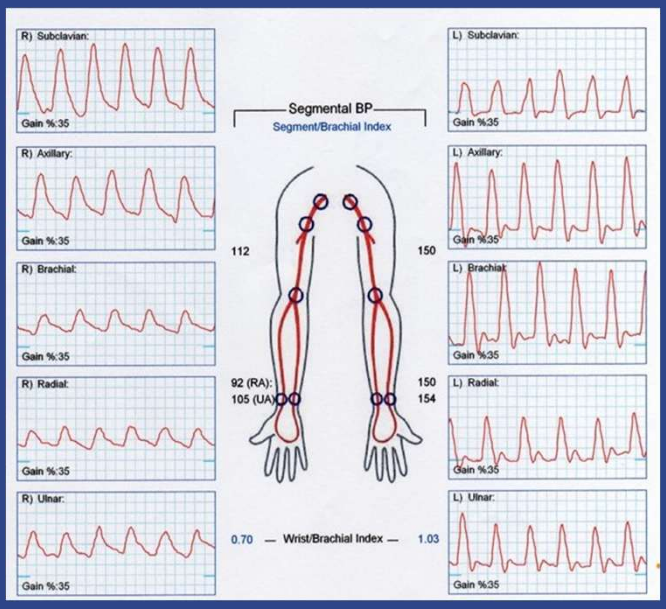

From personal files of Vargas-Ikits P. (on file with author)

RT Brachial A

58

© Copyright. Society of Diagnostic Medical Sonography. All Rights Reserved.

Case 9

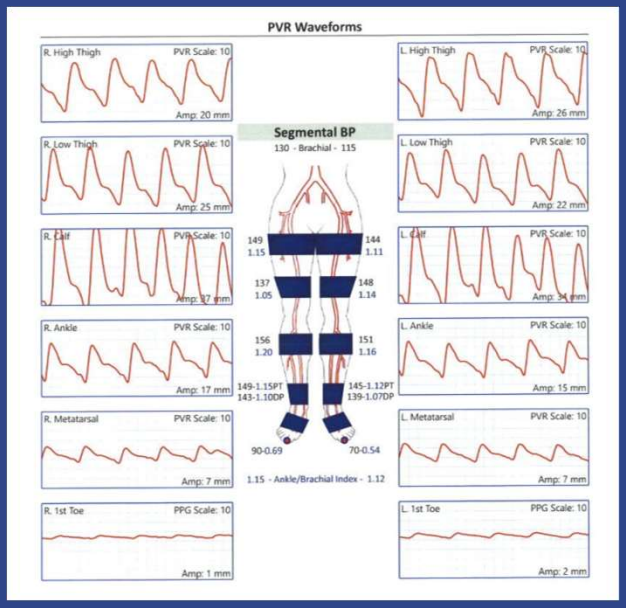

From personal files of Vargas-Ikits P. (on file with author)

Normal Study

59

Case 10

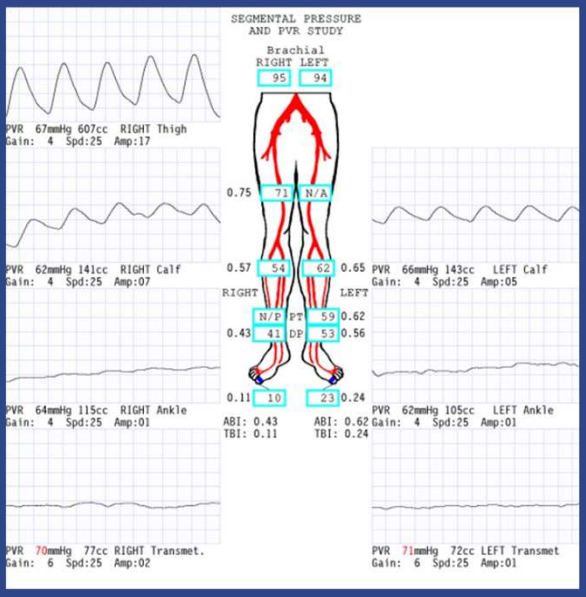

From personal files of Vargas-Ikits P. (on file with author)

Where is the disease?

60

© Copyright. Society of Diagnostic Medical Sonography. All Rights Reserved.

Case 10



RT SFA Collaterals

From personal files of Vargas-Ikits P. (on file with author)

61

Case 10

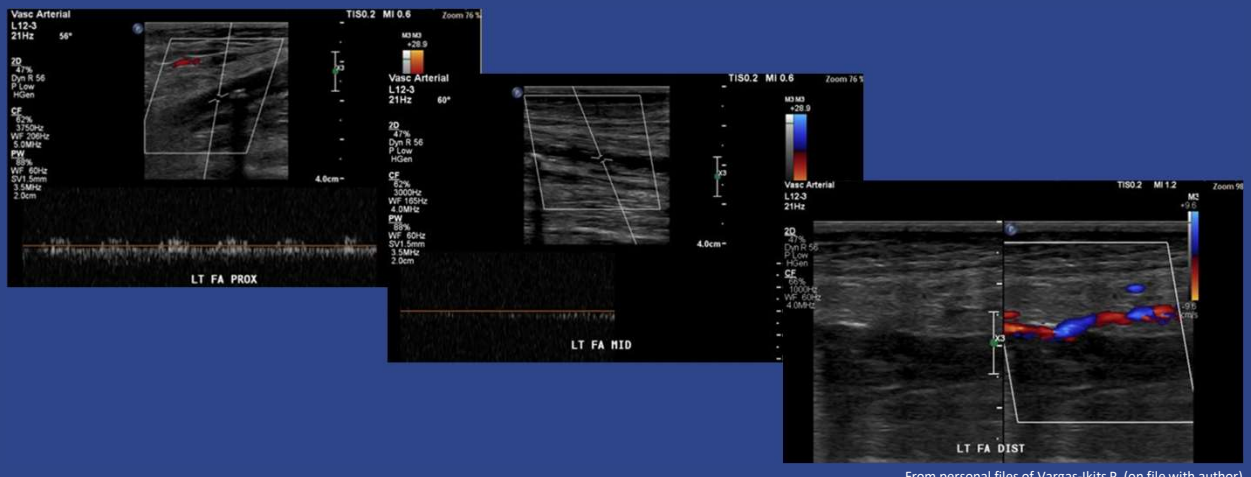

From personal files of Vargas-Ikits P. (on file with author)

LT SFA Occlusion

62

© Copyright. Society of Diagnostic Medical Sonography. All Rights Reserved.

Case 10

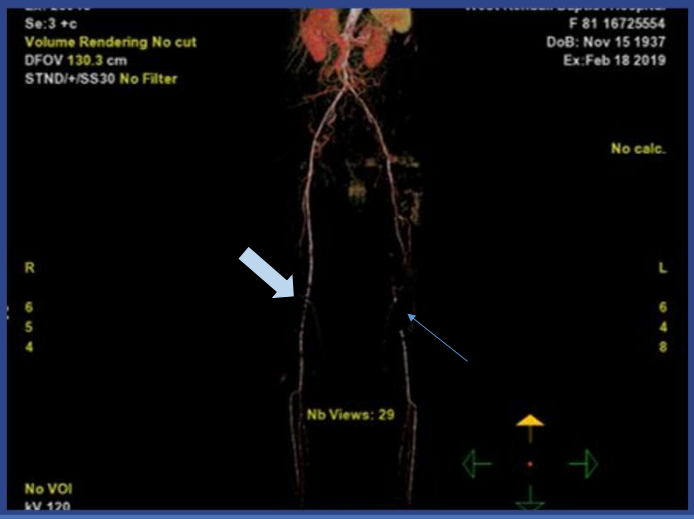

Collateralization

From personal files of Vargas-Ikits P. (on file with author)

63

Case 11

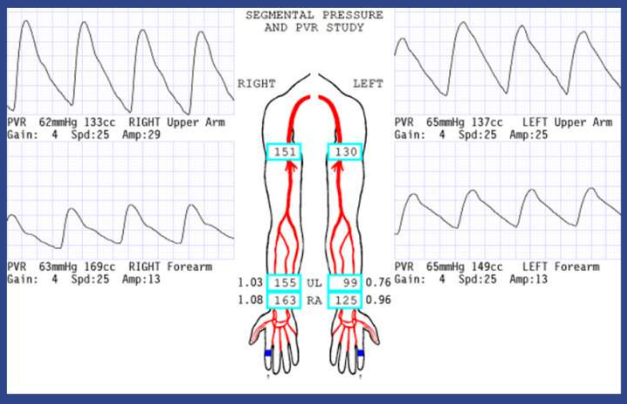

PVR & Segmental Pressures

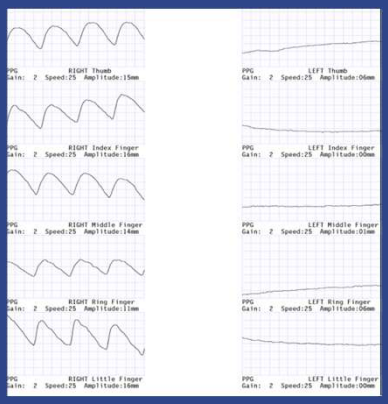

PPGs

Pre-Stent Placement

From personal files of Vargas-Ikits P. (on file with author)

64

© Copyright. Society of Diagnostic Medical Sonography. All Rights Reserved.

Case 11

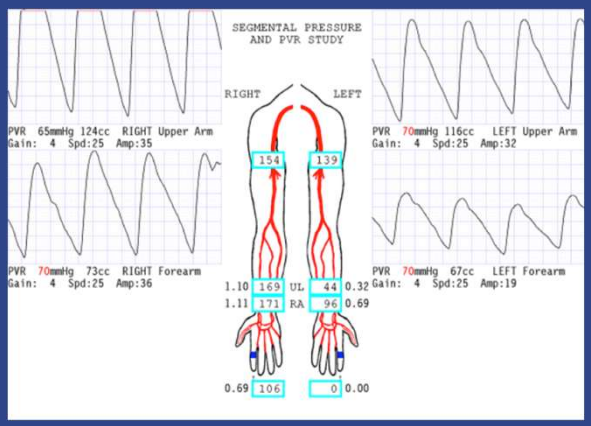

PVR & Segmental Pressures

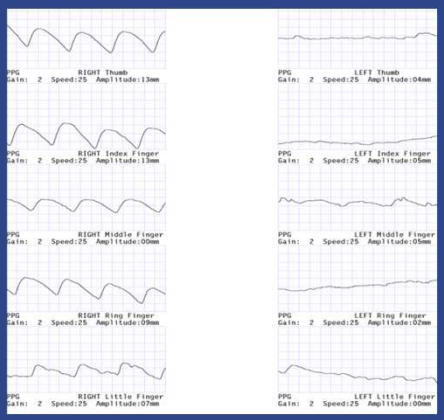

PPGs

1 Day Post-Stent Placement

From personal files of Vargas-Ikits P. (on file with author)

65

Case 11

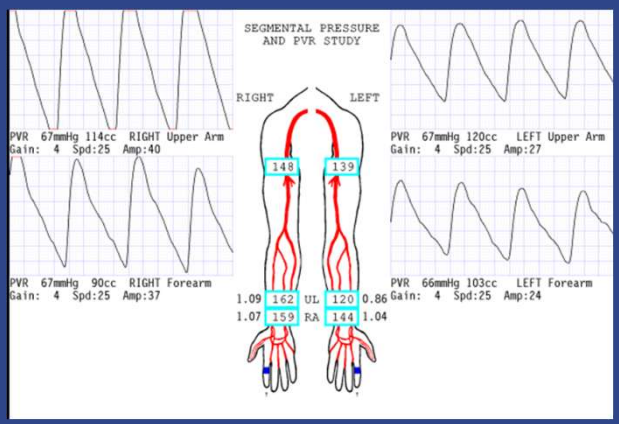

PVR & Segmental Pressures

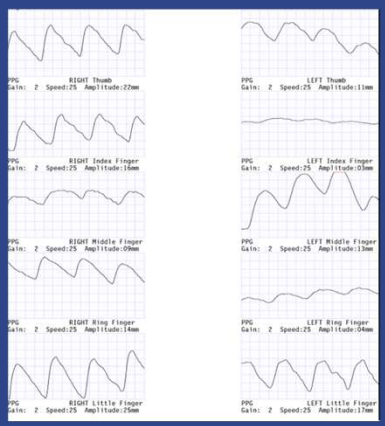

PPGs

1 Month Post-Stent Placement

From personal files of Vargas-Ikits P. (on file with author)

66

© Copyright. Society of Diagnostic Medical Sonography. All Rights Reserved.

Case 12

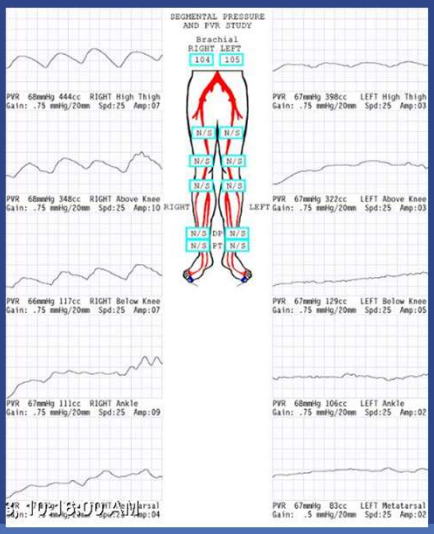

From personal files of Vargas-Ikits P. (on file with author)

RT to LT FEM-FEM Bypass Graft

67

Case 12



From personal files of Vargas-Ikits P. (on file with author)

RT to LT FEM-FEM Bypass Graft

68

© Copyright. Society of Diagnostic Medical Sonography. All Rights Reserved.

Case 12

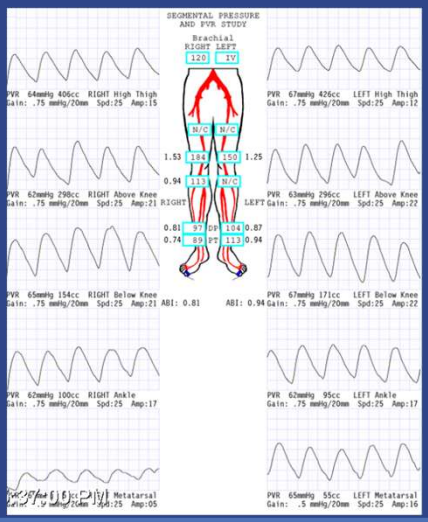

From personal files of Vargas-Ikits P. (on file with author)

1 Week Post- Procedure

69

Case 12

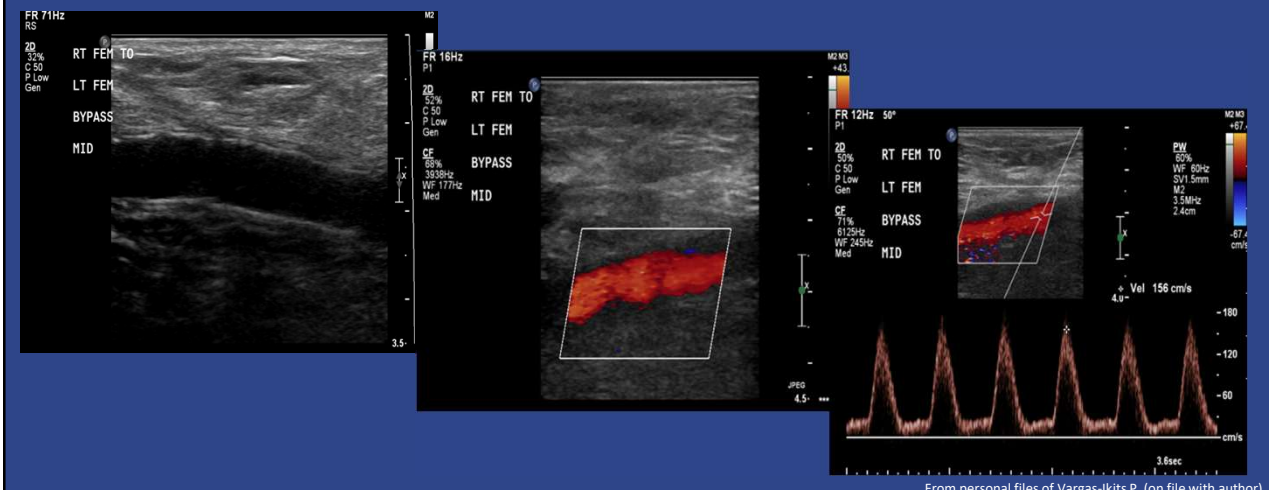

From personal files of Vargas-Ikits P. (on file with author)

RT to LT FEM-FEM Bypass Graft

70

© Copyright. Society of Diagnostic Medical Sonography. All Rights Reserved.

Case 13

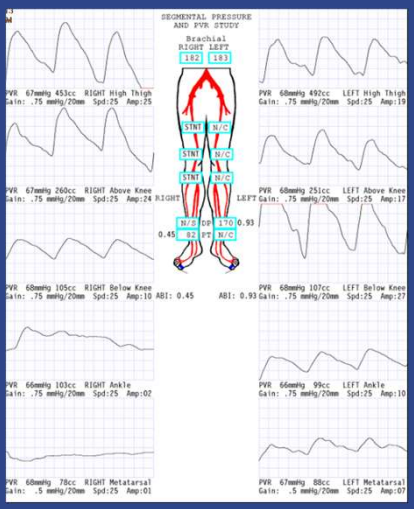

From personal files of Vargas-Ikits P. (on file with author)

Pre- Procedure

71

Case 13



From personal files of Vargas-Ikits P. (on file with author)

Bilateral Duplex Evaluation

72

© Copyright. Society of Diagnostic Medical Sonography. All Rights Reserved.

Case 13

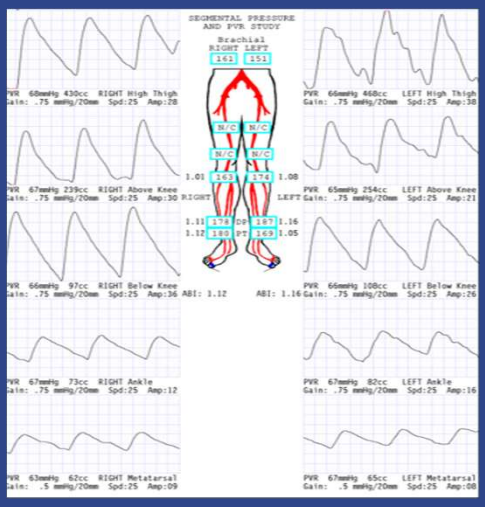

From personal files of Vargas-Ikits P. (on file with author)

1 Week Post- Procedure

73

Case 13





From personal files of Vargas-Ikits P. (on file with author)

Reconstitution

74

© Copyright. Society of Diagnostic Medical Sonography. All Rights Reserved.

References

1. ASSH. Find a Hand Surgeon | American Society for Surgery of the Hand. Assh.org. 2026. Accessed August 23, 2026. https://www.assh.org/handcare/anatomies
2. Kupinski AM. *Diagnostic Medical Sonography: The Vascular System*. LWW; 2022.
3. Daigle RJ. *Techniques in Noninvasive Vascular Diagnosis*. Summer Publishing LLC; 2023.
4. Pellerito JS, Polak JF. *Introduction to Vascular Ultrasonography*. Elsevier; 2020.
5. White-Melendez JM, Schroedter, WB. *The Art of Vascular Ultrasound*. ESP Inc; 2024.

75



THANK YOU

Patricia Vargas-Ikits

pvargas2@touro.edu

76

© Copyright. Society of Diagnostic Medical Sonography. All Rights Reserved.