Seeing Beyond the Blur: Ultrasound Enhancing Agents and Echocardiography

Raymond R. Musarra MBA, ACS, FASE

1

SPEAKER PRESENTATION DISCLAIMER

The content and views presented are made available for educational purposes only. The information presented are the opinions of the presenter and do not necessarily represent the views of the Society of Diagnostic Medical Sonography (SDMS) or its affiliated organizations, officers, Boards of Directors, or staff members.

The presenter is responsible for ensuring balance, independence, objectivity, scientific rigor, and avoiding commercial bias in their presentation. Before making the presentation, the presenter is required to disclose to the audience any relevant financial interests or relationships with manufacturers or providers of medical products, services, technologies, and programs.

The SDMS and its affiliated organizations, officers, Board of Directors, and staff members disclaim any and all liability for all claims that may arise out of the use of this educational activity.

2

© Copyright. Society of Diagnostic Medical Sonography. All Rights Reserved.

RESEARCH DISCLAIMER

The information presented in this presentation is based on research conducted to the best of the presenters' abilities and knowledge. Research involves uncertainty and is subject to limitations. The findings and conclusions presented herein may be influenced by various factors including but not limited to data quality, methodology, assumptions, and interpretation.

Research outcomes may not always accurately predict real-world scenarios or future events. While the presenter may make efforts to ensure the accuracy and reliability of the information presented, completeness or absolute correctness is not guaranteed. This presentation is intended for informational purposes only and should not be construed as professional advice. Participants are encouraged to independently verify any information provided and consult relevant experts or professionals where appropriate.

The SDMS and its affiliated organizations, officers, Board of Directors, and staff members disclaim any and all liability for all claims that may arise out of the use of this educational activity.

3

GENERATIVE AI DISCLAIMER

The presenter utilized the use of large language models (LLMs) and generative artificial intelligence (AI) as a productivity tool to assist in drafting and refining content in this presentation.

While these tools can aid in structuring ideas, summarizing, paraphrasing, and language polishing, they have inherent limitations and cannot replace human creativity, critical thinking, or expert judgment. AI-generated content may contain errors, biases, or gaps in knowledge.

This presentation is intended for informational purposes only and should not be construed as definitive or authoritative guidance. Participants are encouraged to critically evaluate the information presented and consult relevant experts as needed. The SDMS and its affiliated organizations, officers, Board of Directors, and staff members disclaim any and all liability for claims that may arise from the use or interpretation of this educational material.

4

© Copyright. Society of Diagnostic Medical Sonography. All Rights Reserved.

Objectives

- Explain the basic principles of bubble mechanics and contrast physics in echocardiography.
- Identify appropriate indications for the use of ultrasound enhancing agents to improve diagnostic accuracy.
- Describe techniques for optimizing contrast-enhanced echocardiographic imaging and interpretation of findings.

5

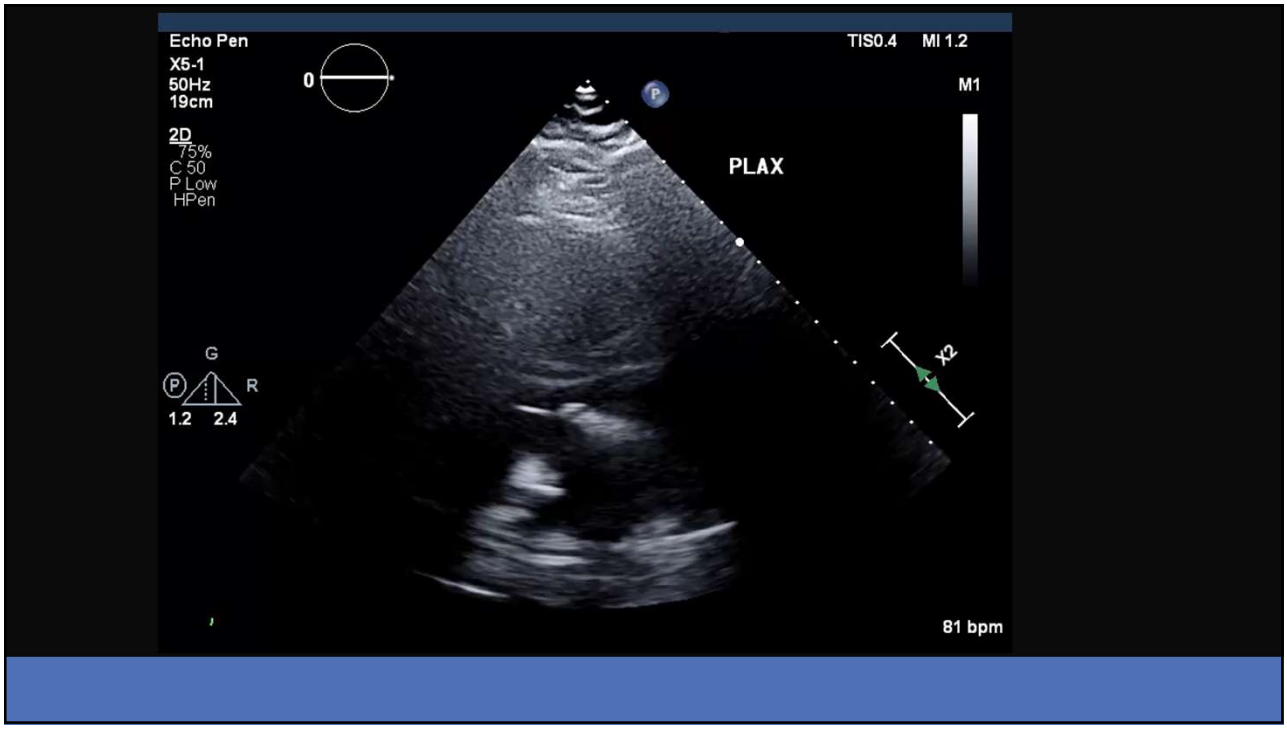

6

© Copyright. Society of Diagnostic Medical Sonography. All Rights Reserved.

ASE Guidelines

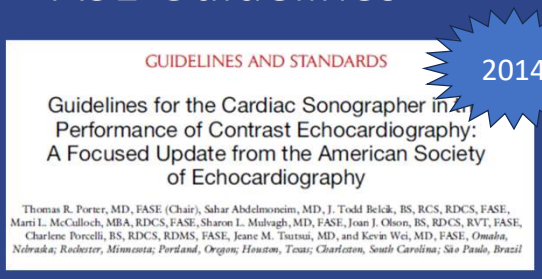

- Scenarios for usage
- Supportive for sonographer training (IV)
- Safety (Black box warnings with revisions)
- Discussion of Low Mechanical Index techniques
- Future initiatives (3D)

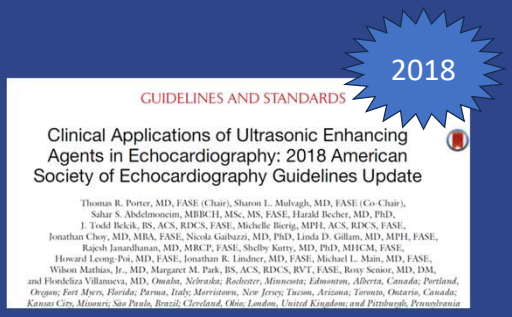

- Comparison of agents
- Imaging recommendations
- Clinical applications
- Updated safety information and indications
- Implementation strategies for labs
- Cost-effectiveness

7

Value

Accessibility	Can I get what I need or want from you?
Service	Is dealing with you a pleasant experience?
Effectiveness	Is what you're providing going to satisfy my need or want?
Costs	What's the cost to me and my family and is it worth it?



Keckly 2015

8

© Copyright. Society of Diagnostic Medical Sonography. All Rights Reserved.

Domains of Quality in Echocardiography



Patient Selection[1]



Image Acquisition

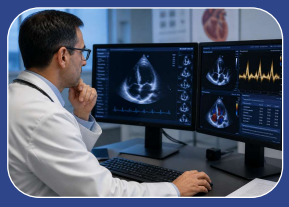

Image Interpretation[2]



Results Communication[1]

Samad 2016, [1]Microsoft 365, [2]Chat GPT

9

Ultrasound enhancing agent (UEA)

Class of products comprising of microbubbles to enhance ultrasound signals

Contrast = Ultrasound enhancing agent

UEA may limit confusion

Porter 2014

10

© Copyright. Society of Diagnostic Medical Sonography. All Rights Reserved.

Barriers to utilization

- Cost
- Time
- Sonographers too good!
- Echo machines are too good!
- Perfect patients

McCulloch 2014

11

SDMS scope of practice

STANDARD – EVALUATION OF THE DIAGNOSTIC SONOGRAPHIC EXAMINATION OR PROCEDURE IMAGES, FINDINGS, OR RESULTS

1.5 Careful evaluation of examination or procedure images, findings, or results in the context of the protocol is important to determine whether the goals have been met. In accordance with written supervising physician or facility policies, procedures, protocols, or other requirements of the jurisdiction where performed, the sonographer:

1.5.1 Determines that the examination, as performed, complies with the applicable protocol.

1.5.2 Identifies and documents any limitations to the examination or procedure (e.g., equipment failure, lack of patient cooperation or preparation).

1.5.3 Initiates additional techniques or procedures (e.g., administering intravenous ultrasound enhancing or other pharmacologic agents) or obtains additional images, when indicated.

1.5.4 Notifies appropriate healthcare provider(s) when immediate medical attention may be necessary, based on the examination or procedure images, findings, or results, or the patient's condition.

Scope 2023

12

© Copyright. Society of Diagnostic Medical Sonography. All Rights Reserved.

Clinical applications

FDA
- Suboptimal echocardiograms
- Opacify the LV chamber
- Improve delineation of LV endocardial border

- LV volumes
  - Increased accuracy and reproducible tracings as able to better visualize interface between blood pool and endocardium.
  - Better correlation with MRI
- Ejection fraction
  - Quantitation and enhanced accuracy impactful
    - Defibrillator, cardiotoxicity, intervention with valvular heart disease
- Regional wall motion
  - Dependent on image quality, assessment is subjective

Porter 2018, Ahmed 2026

13

Intracardiac abnormalities

- Intracardiac thrombi/masses
  - Identification of filling defects
  - Vascularity
- Apical abnormalities with hypertrophic cardiomyopathy
  - Apical aneurysm and thrombi
- Non-compaction cardiomyopathy
  - Identification of deep intertrabecular recesses
- Aneurysm (True & pseudo)
- RV assessment
- Left atrial appendage (TEE)
- Stress Echo

Porter 2018

14

© Copyright. Society of Diagnostic Medical Sonography. All Rights Reserved.

IAC Echo accreditation

Two or more LV segments can not be visualized adequately

- LV ejection fraction
- Regional wall motion assessment

Indication requires accurate analysis of regional wall motion

- Acute MI
- Apical hypertrophy



Status Active PolicyStat ID 18260077

Origination 05/2022
Last Approved 06/2025
Effective 06/2025
Last Revised 06/2025
Next Review 06/2028

Owner Raymond Musarra: Manager,HHVI Adult Echo Lab
Area Harrington HVI
Applicability System
References Dept Procedure, Harrington HVI - Echo Lab

University Hospitals

Administration of Ultrasound Enhancing Agent (UEA), 4.2.1 (UH SYSTEM INSTITUTE - HARRINGTON HVI PROCEDURE)

COPY

Purpose:

To provide a safe environment and guidelines for the administration of the ultrasound enhancing agents.

Procedure:

1. Ultrasound enhancing agents (UEA) are an integral part of an echocardiogram. Yet it is not required on every exam. As a result, an as needed (PRN) order is generated, by a physician, for each suboptimal echocardiogram.
2. Lexicomp houses the formulary information for our ultrasound enhancing agents.
3. Indications:
   1. When ASE/IAC Echocardiography guidelines for adequate images are not met.

Echocardiography 2025

15

Early data

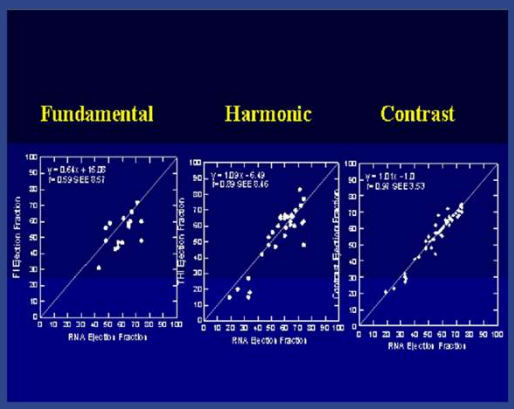

Calculation of EF and correlation with Radionuclide

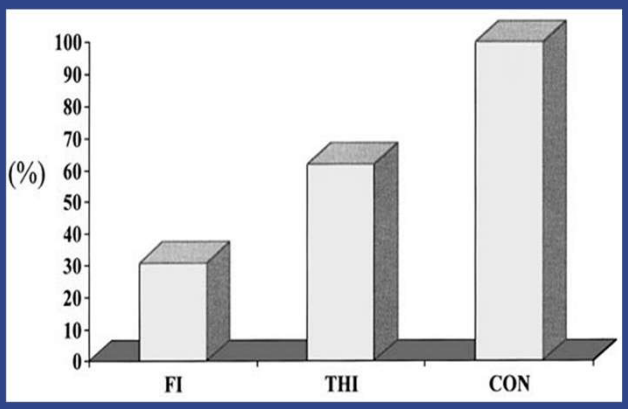

Feasibility of calculating LV ejection fraction

Mulvagh 2008

16

© Copyright. Society of Diagnostic Medical Sonography. All Rights Reserved.

Image Quality

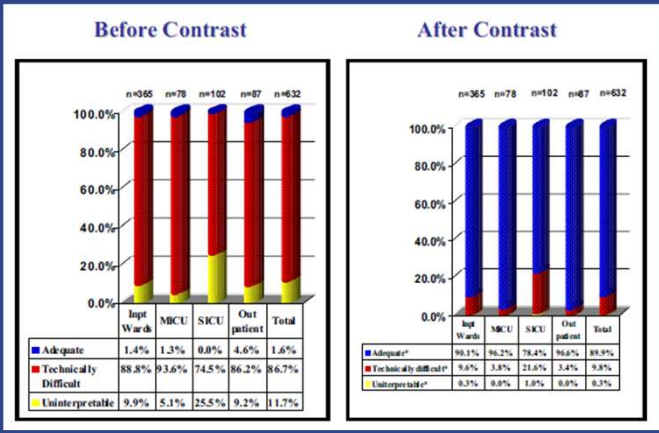

- Adequate exams went from 1.6% to 89.9% with UEA
- Uninterpretable went from 11.7% to 0.3%

EF assessment

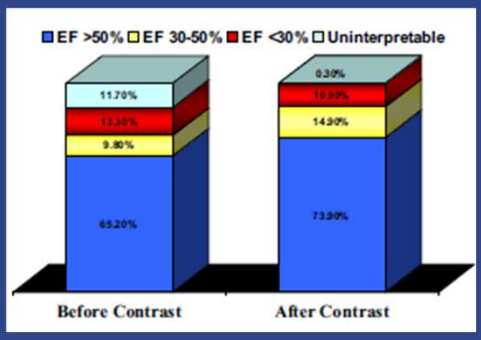

- Decrease in uninterpretable exams
- Overall increase in EF

Kurt 2009

17

Impact on Patient management

- UEA impacts study quality and assessment of EF/function
- Impactful to patient management, notably SICU population
- Based on this research, diagnostic cost-benefit of $122/patient

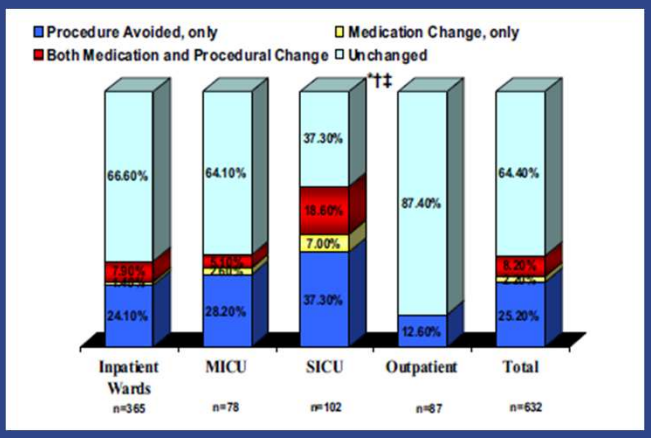

Kurt 2009

18

© Copyright. Society of Diagnostic Medical Sonography. All Rights Reserved.

JACC: CARDIOVASCULAR IMAGING
© 2014 BY THE AMERICAN COLLEGE OF CARDIOLOGY FOUNDATION
PUBLISHED BY ELSEVIER INC.
VOL. 7, NO. 1, 2014
ISSN 1936-878X/$36.00
http://dx.doi.org/10.1016/j.jcmg.2013.08.012

Acute Mortality in Critically Ill Patients Undergoing Echocardiography With or Without an Ultrasound Contrast Agent

Michael L. Main, MD,* Mark G. Hibberd, MD, PhD,† Amy Ryan, MS,‡ Timothy J. Lowe, PhD,‡ Paula Miller, BS,† Gajanan Bhat, PhD†
Kansas City, Missouri; North Billerica, Massachusetts; and Charlotte, North Carolina

- Follow-up study from Kurt et.al., and FDA questions re: safety of perflutren based UEA
- Comparison of 48-hour all-cause mortality
- Critically ill patients with an enhanced echo demonstrated a 28% lower mortality

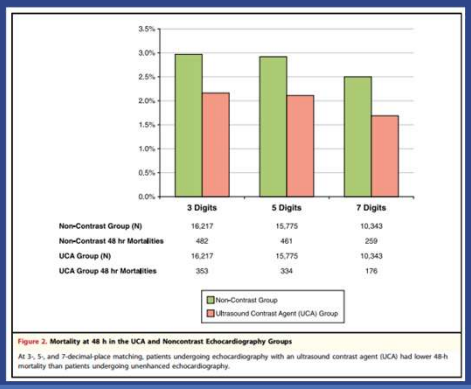

Figure 2. Mortality at 48 h in the UCA and Noncontrast Echocardiography Groups

At 3-, 5-, and 7-decimal-place matching, patients undergoing echocardiography with an ultrasound contrast agent (UCA) had lower 48-h mortality than patients undergoing unenhanced echocardiography.

Main 2014

19

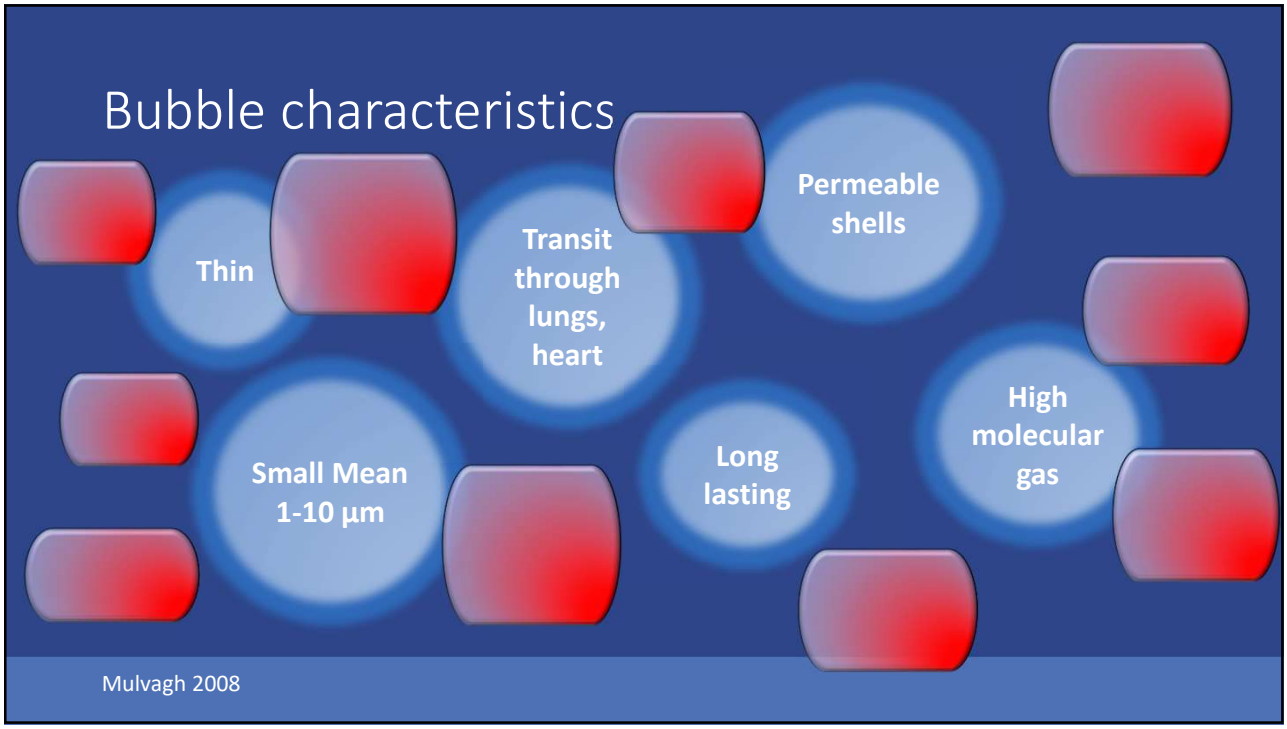

Mulvagh 2008

20

© Copyright. Society of Diagnostic Medical Sonography. All Rights Reserved.

Microbubble oscillation

- Microbubbles
  - ↑ compressible
  - < wavelength of U/S
  - Undergo volumetric oscillation
  - Vibration creates strong backscattered signals that allow blood pool visualization

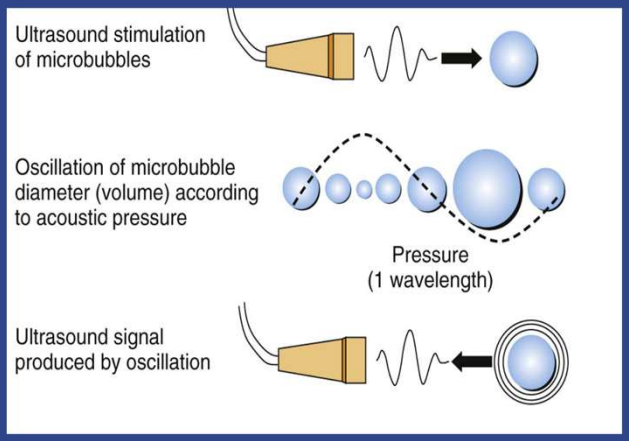

Lang 2011

21

Mechanical Index

- High power (MI > 0.3)
  - Oscillation large
  - Decreased LV opacification due to microbubble destruction
- Low power (MI 0.1-.03)
  - Low magnitude oscillation
  - LV opacification optimized

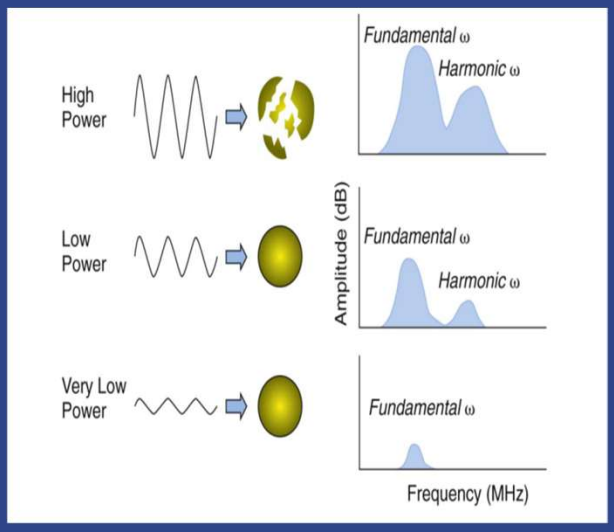

Lang 2011

Porter 2014

22

© Copyright. Society of Diagnostic Medical Sonography. All Rights Reserved.

Impact of Mechanical Index

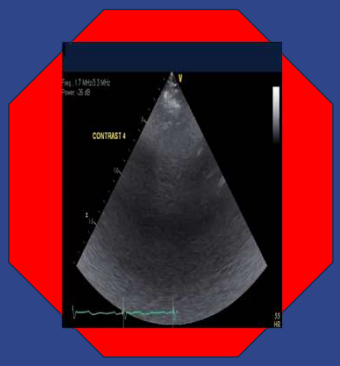

Very Low Power
MI 0.06



Low Power
MI 0.21



High Power
MI 1.2

23

Pulse Inversion

- Tissue cancellation technique
- Pulses of alternating polarity
- Tissue (linear) components cancel out
- Microbubbles (nonlinear) components do not cancel out allowing contrast visualization

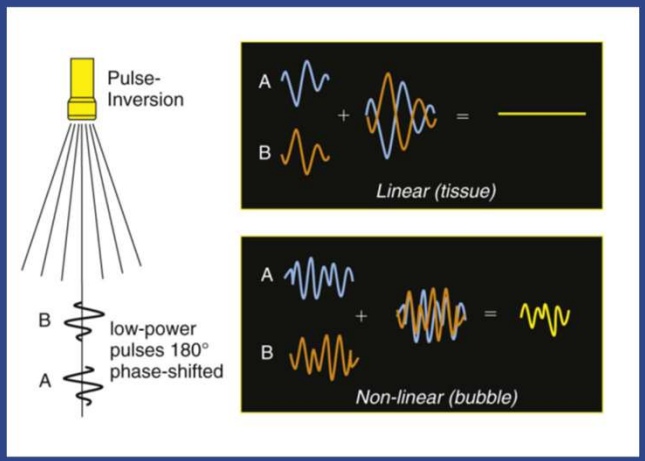

Lang 2011

Porter 2014

24

© Copyright. Society of Diagnostic Medical Sonography. All Rights Reserved.

Power Modulation

- Tissue cancellation technique
- Power varies between each pulse
  - Linear responses from tissue subtracted from eachother
  - Non-linear response detected from microbubbles

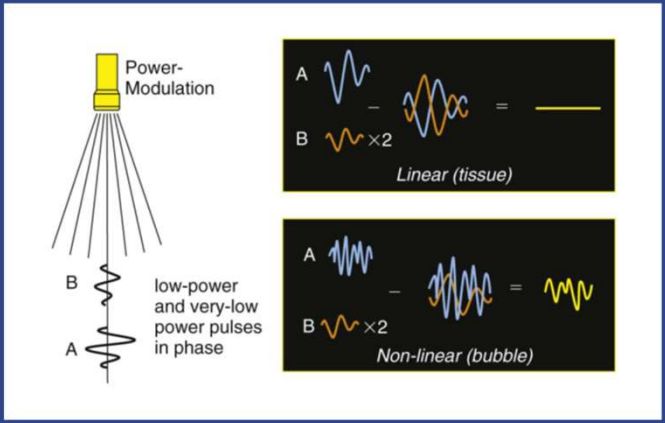

Lang, R. (2011). Dynamic echocardiography. St. Louis, MO: Saunders Elsevier

Porter 2014

25

Table 2 Common problems and artifacts encountered when using IV contrast

Typical location of artifact	Artifact/problem	Sonographer correction method	Key additional points
Apex-endocardial border	Swirling	Use real-time very low MI imaging Increase contrast infusion rate (Video 7; available at www.onlinejase.com)	Lower frame rate prevents apical destruction; also can move focus to near field.
Apex-myocardium	Reduced contrast	Increase near-field TGC under resting conditions; move focus temporarily to near field (Video 8; available at www.onlinejase.com)	If resting wall motion is normal, perfusion should be normal, so a defect in this setting is an artifact.
Basal segment–myocardium	Reduced myocardial contrast	Additional foreshortened apical windows to get basal segments in the near field (Video 9; available at www.onlinejase.com)	If resting wall motion is normal, perfusion is normal, and therefore there should be no resting contrast defects in the absence of wall motion abnormalities. Use this concept in setting up receiver gain during resting images, because during stress, perfusion alone can be abnormal.
LV cavity contrast	Inadequate using a continuous infusion	Check IV site to ensure not obstructed; increase infusion rate; ensure contrast is not too dilute and is staying adequately mixed	Could switch to a small bolus.
LV cavity contrast	Shadowing of basal/mid segments	Slow down infusion or reduce bolus size and flush rate	Infusion (compared with bolus) reduces shadowing problems and allows more rapid correction of the problem.

Porter 2014

26

© Copyright. Society of Diagnostic Medical Sonography. All Rights Reserved.

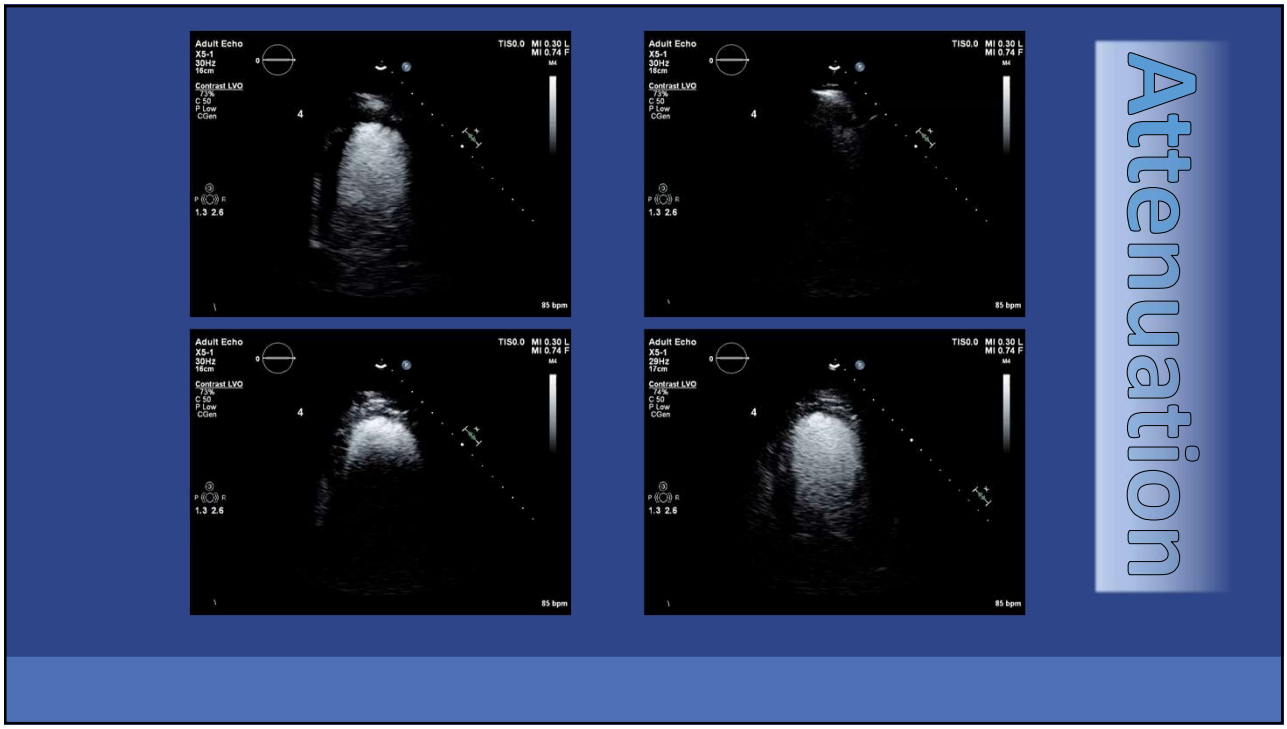

27

Swirling

- Use of real time low-MI
  - Harmonic imaging at high MI destructs microbubbles
- Increase infusion rate as concentration may be inadequate
- Decrease frame rate to lower apical microbubble destruction
- Move focus to the near field

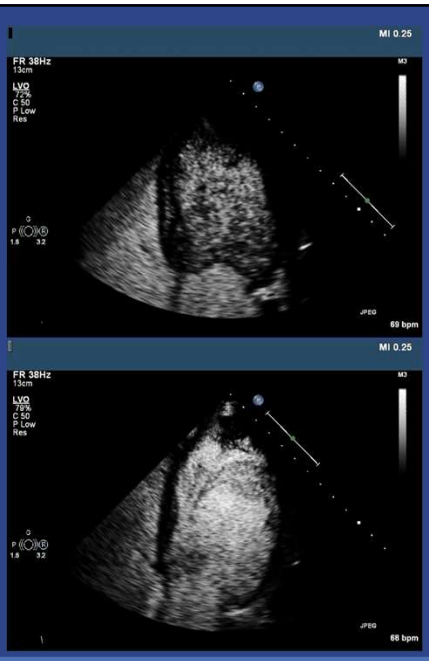

Porter 2014

28

© Copyright. Society of Diagnostic Medical Sonography. All Rights Reserved.

Inadequate (LV cavity)

- Check IV to ensure placement[1]
- Pump fist, bicep
- Re-mix contrast if needed[1]
- Increase infusion rate[1]
- Check port (90°angle)
- Injection of bolus[1] or flush

[1]Porter 2014

29

Reduced contrast (apex)

- Move focus to the apex
- Increase TGC's in near field




Porter 2014

30

© Copyright. Society of Diagnostic Medical Sonography. All Rights Reserved.

Importance of on-axis imaging

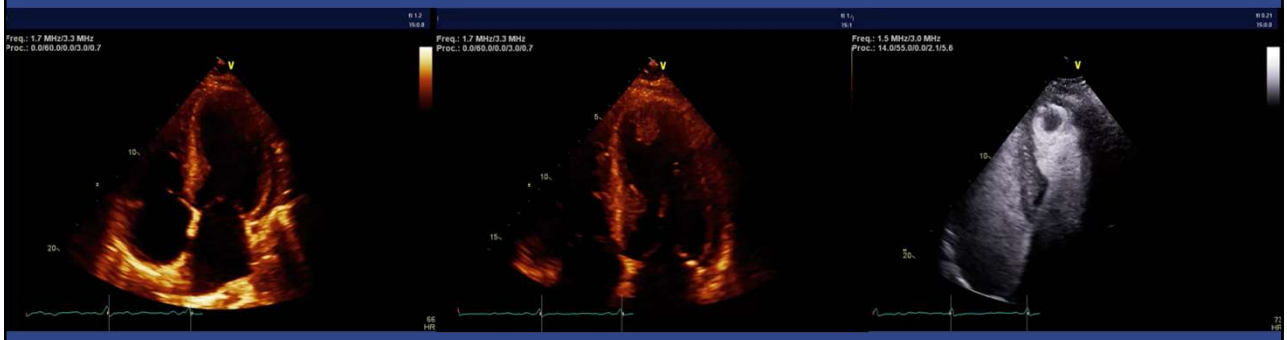

31

Contrast Exam

- Efficiency in workflows
  - Recognize needs early (pre-scan apical windows)
  - 60-second rule with stress echocardiography
- Optimization of images
  - Swirling and attenuation
  - Respiratory maneuvers and echo beds (cut-out)
- Consistent workflow
  - 4 chamber
  - Activate preset
  - Label images
- Communication to staff member administering



Lang 2011

32

© Copyright. Society of Diagnostic Medical Sonography. All Rights Reserved.

Clinical Pearls

- High flash impulse for 3-5 frames clears contrast from myocardium
  - Improved endocardial definition immediately post-impulse[1]
- Go in and out of contrast setting if high-flash unavailable
- Shadowing of the basal segments can be minimized through foreshortening the image[1]
- Perform 5-7 beat sweeps in technically difficult patients
- Swirling = too little contrast
- Attenuation = too much/fast contrast
- MI/Frequency/Focus/Frame rate
- Agitated saline exam (aka bubble study) first!

[1]Porter 2014

33

QA/QI

- Incorporate exams utilizing UEA's into your quality reviews
- Track UEA usage by site, sonographer, and if able, echo equipment
- Develop competencies/case reviews



34

© Copyright. Society of Diagnostic Medical Sonography. All Rights Reserved.

Case Studies

35

Case study 1

- 83-year-old female admitted to cardiac floor with hypotension
- History of dementia, HTN, diastolic heart failure. AKI, CKD III, and breast cancer
- Prior echo one month earlier for dyspnea
  - EF 30-35%
  - Terminated exam prior to UEA
- Limited echo ordered

36

© Copyright. Society of Diagnostic Medical Sonography. All Rights Reserved.

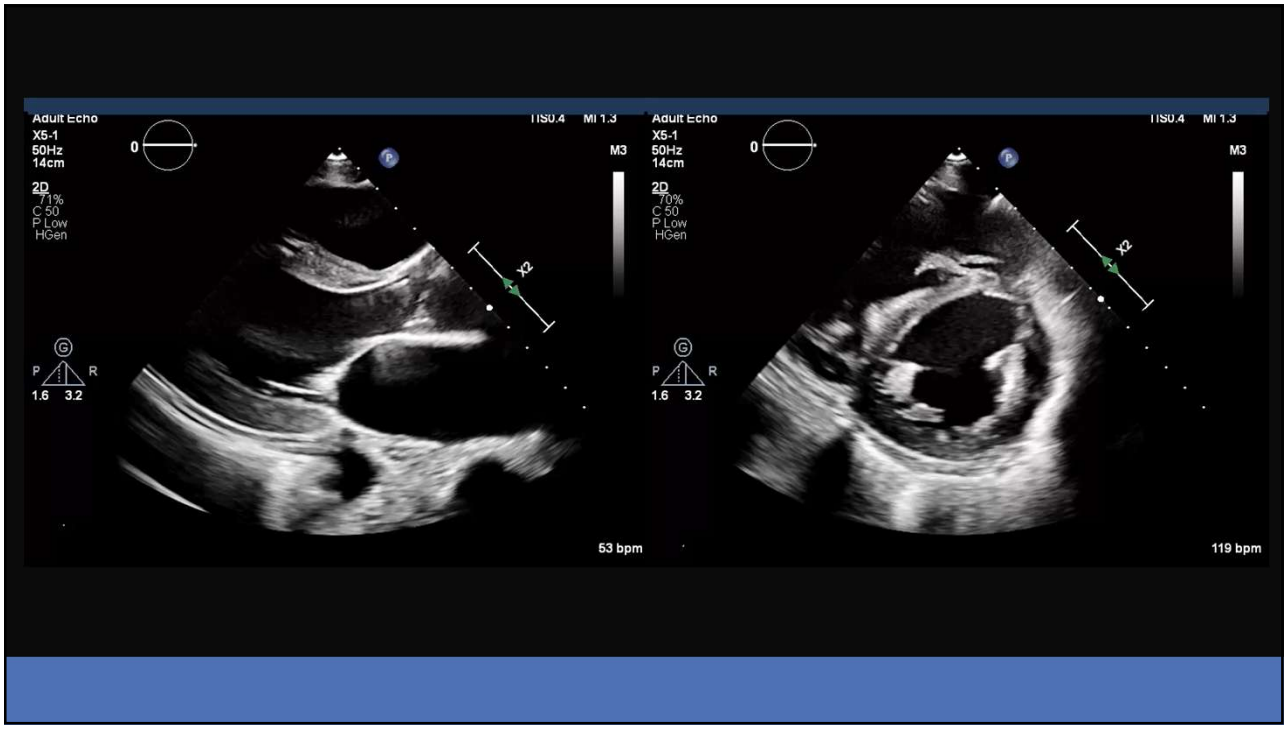

37

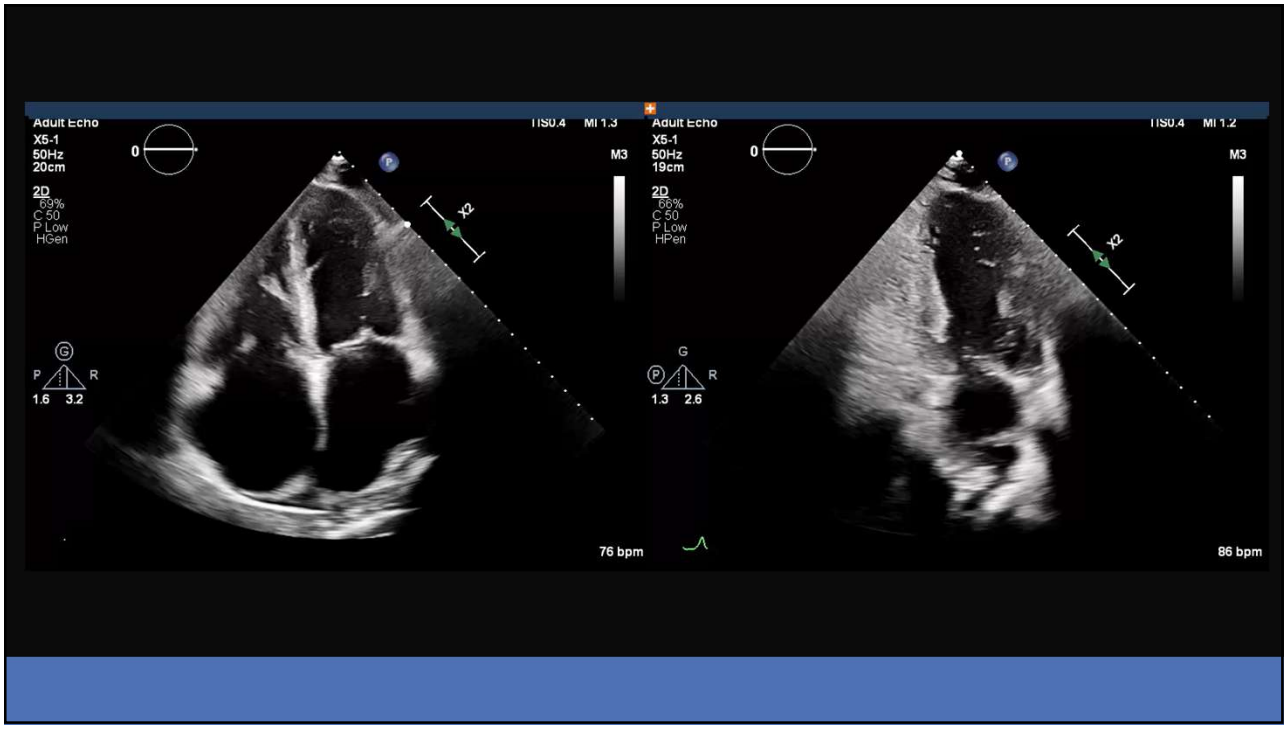

38

© Copyright. Society of Diagnostic Medical Sonography. All Rights Reserved.

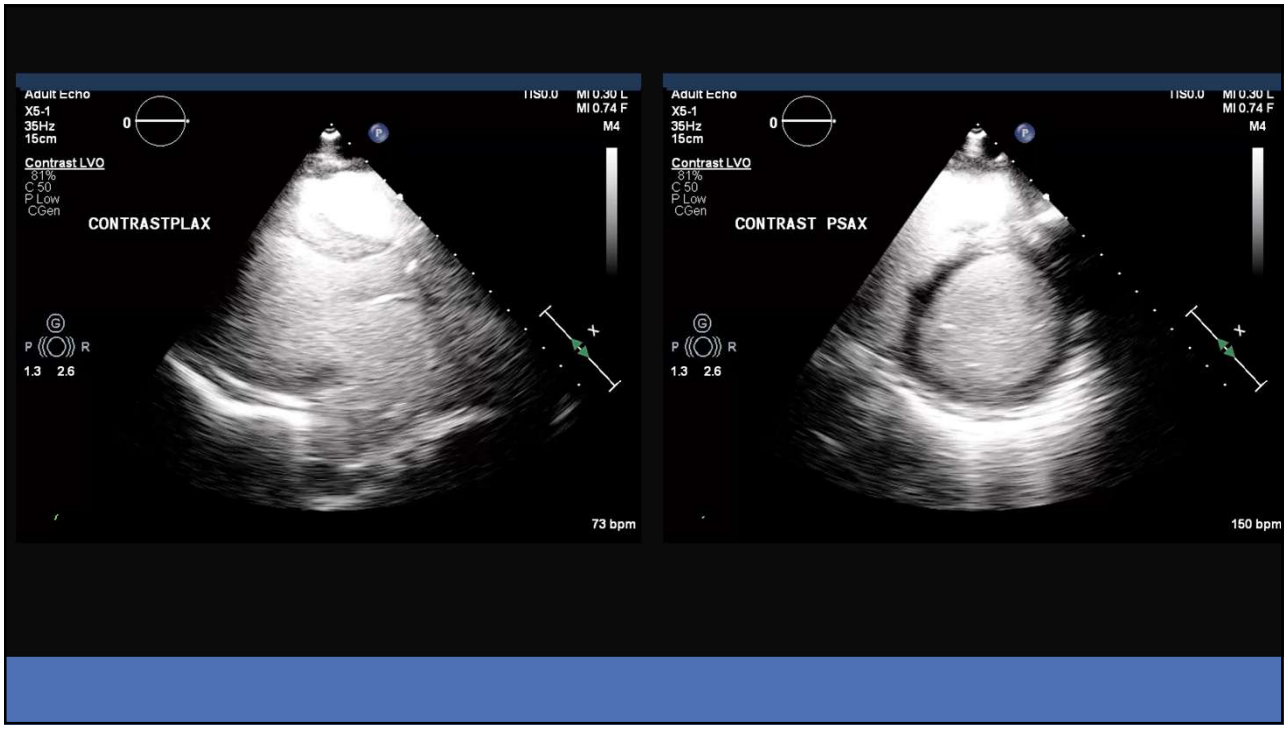

39

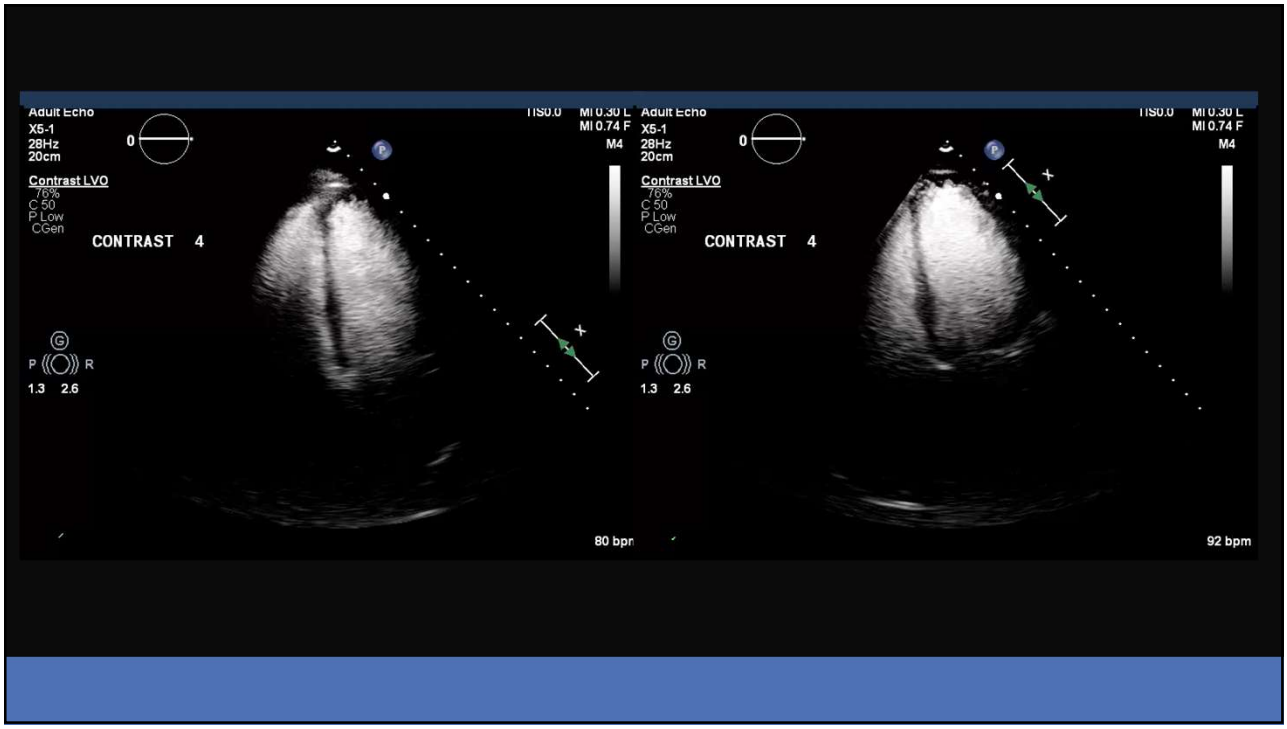

40

© Copyright. Society of Diagnostic Medical Sonography. All Rights Reserved.

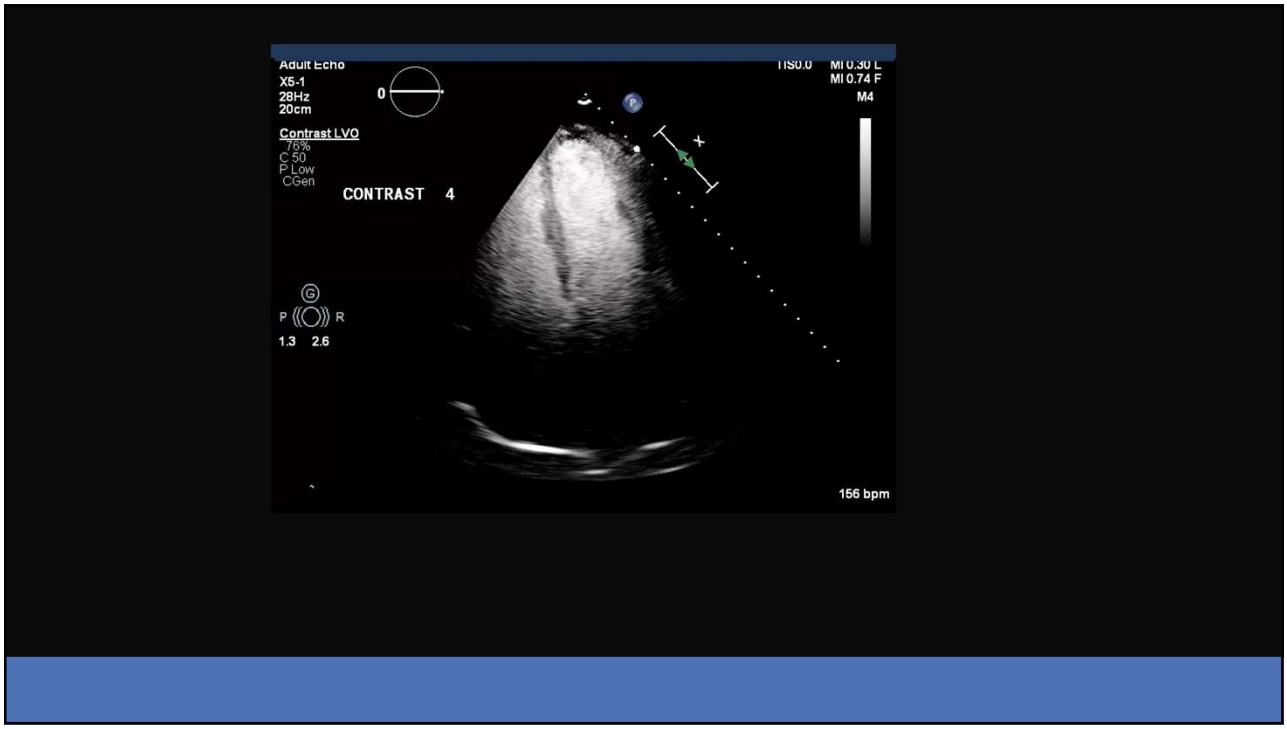

41

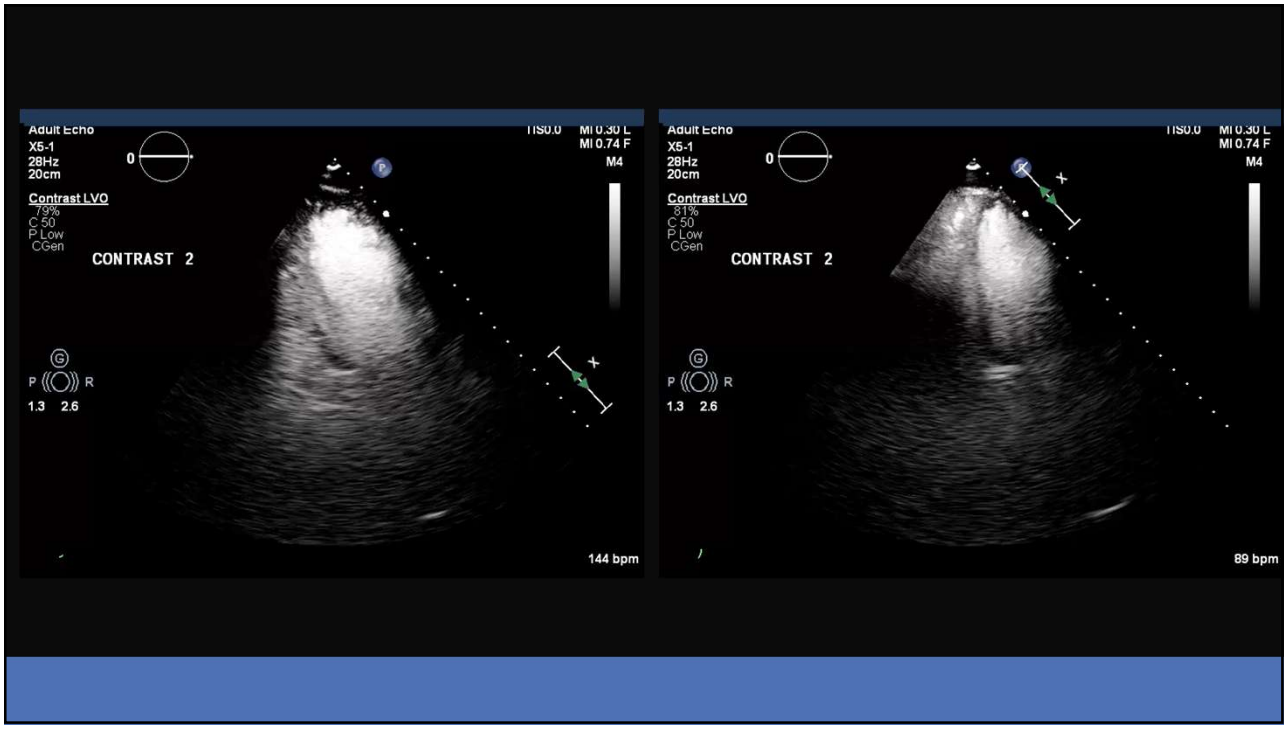

42

© Copyright. Society of Diagnostic Medical Sonography. All Rights Reserved.

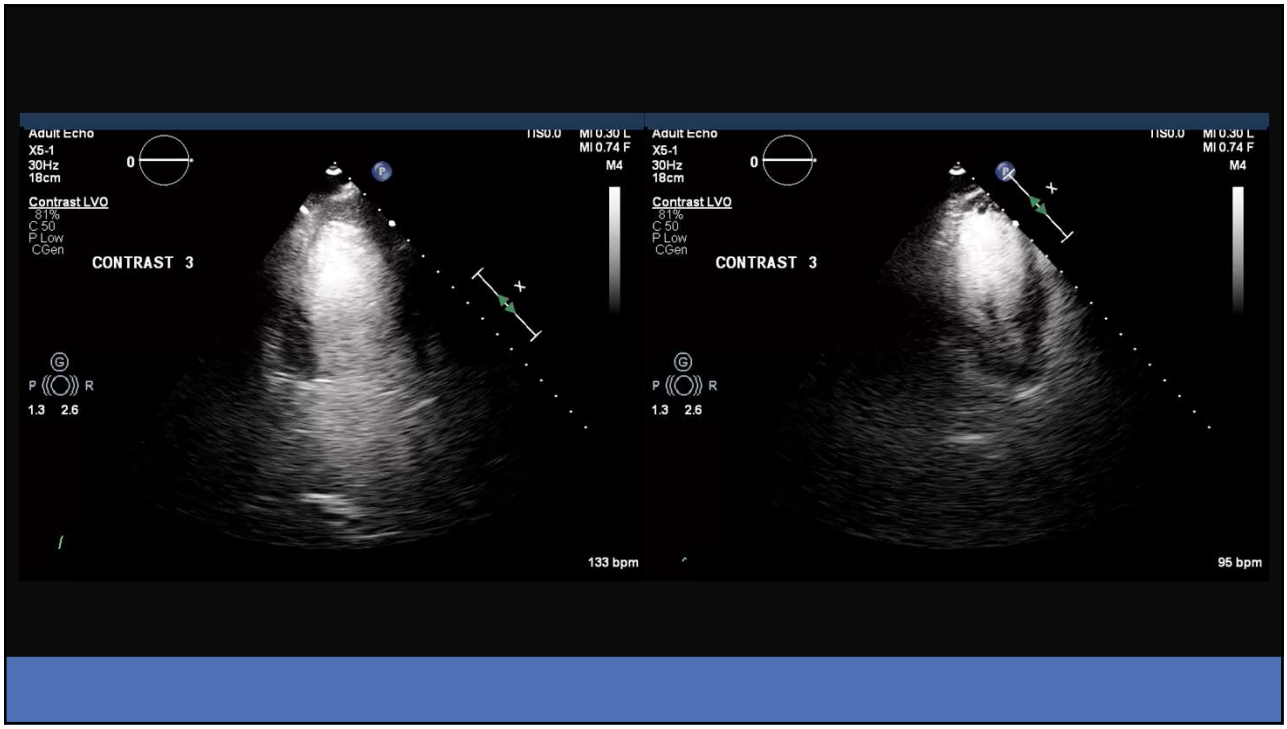

43

Echo Report

- Severely decreased LV systolic function
- EF 20-25%
- Small fixed LV thrombus in the apex, spherical in shape and solid in texture
  - Measures 5mm x 5mm

44

© Copyright. Society of Diagnostic Medical Sonography. All Rights Reserved.

Case study 2

- 86-year-old female, one day post TMVR for worsening hypoxic respiratory failure and thrombocytopenia thought to be due to severe mitral stenosis
- History of CVA, HFrEF, SSS sith PPM, A-fib, MVR 1998, TAVR 2021
- TEE one month prior, EF 35-40% with failure of mitral valve bioprosthesis (severe MS and MR), 3D MVA of 1cm²

45

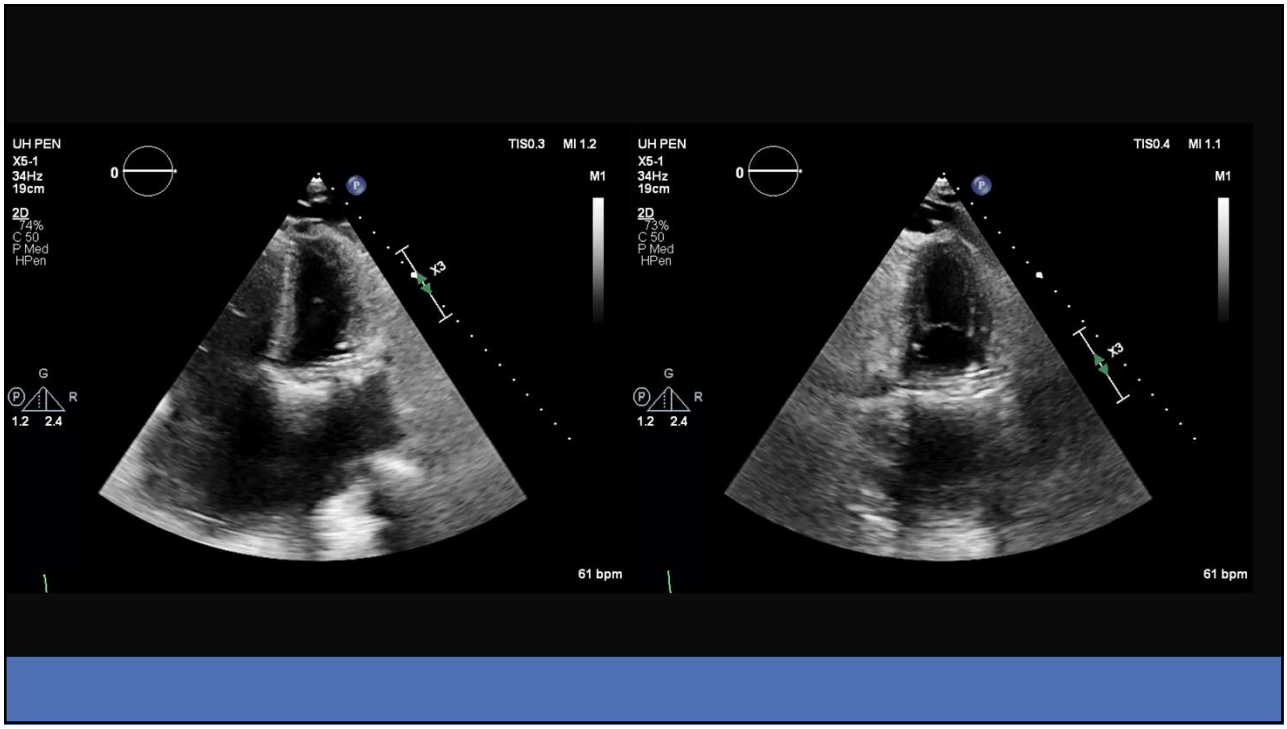

46

© Copyright. Society of Diagnostic Medical Sonography. All Rights Reserved.

2026 SDMS Annual Conference

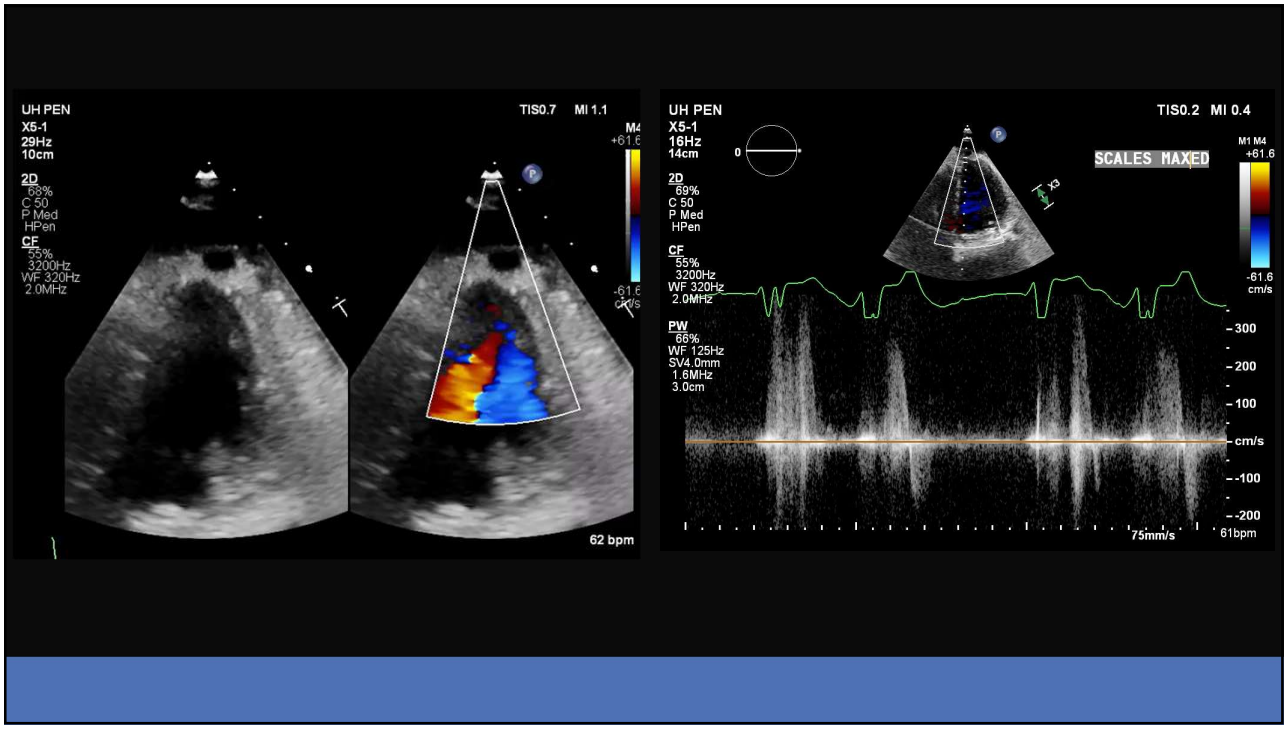

47

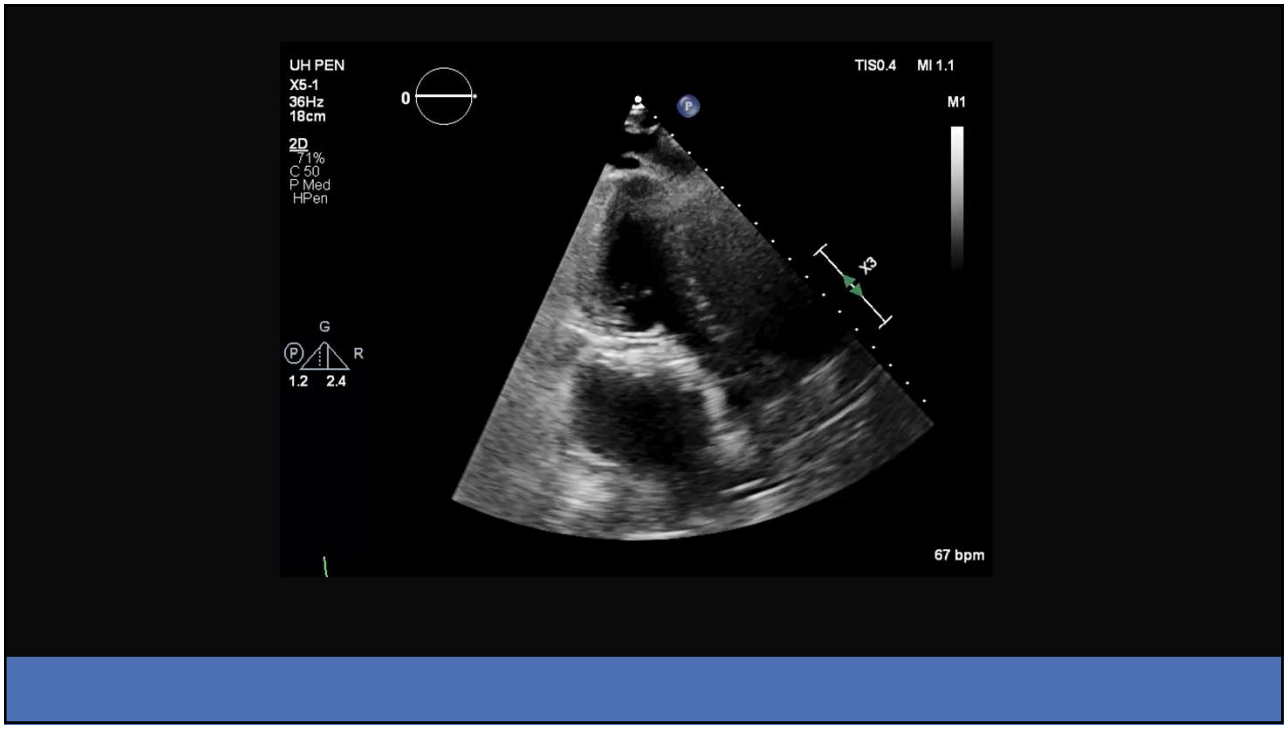

48

© Copyright. Society of Diagnostic Medical Sonography. All Rights Reserved.

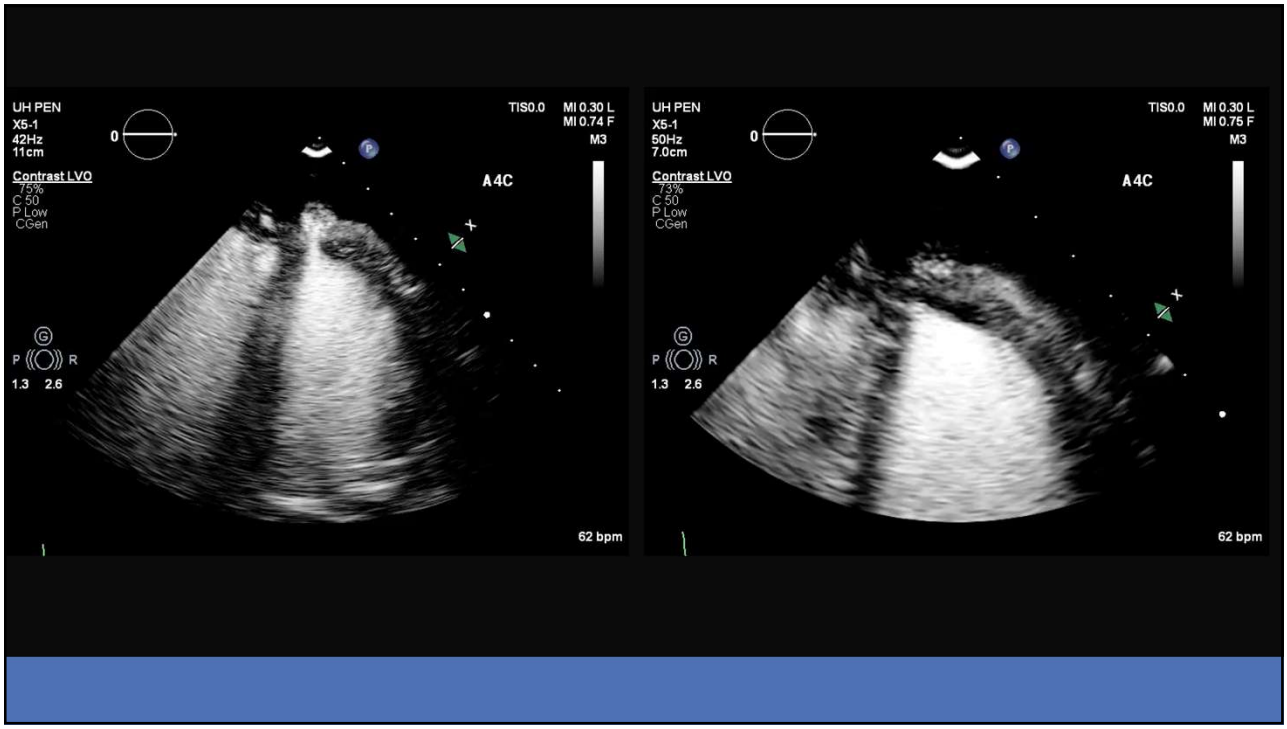

49

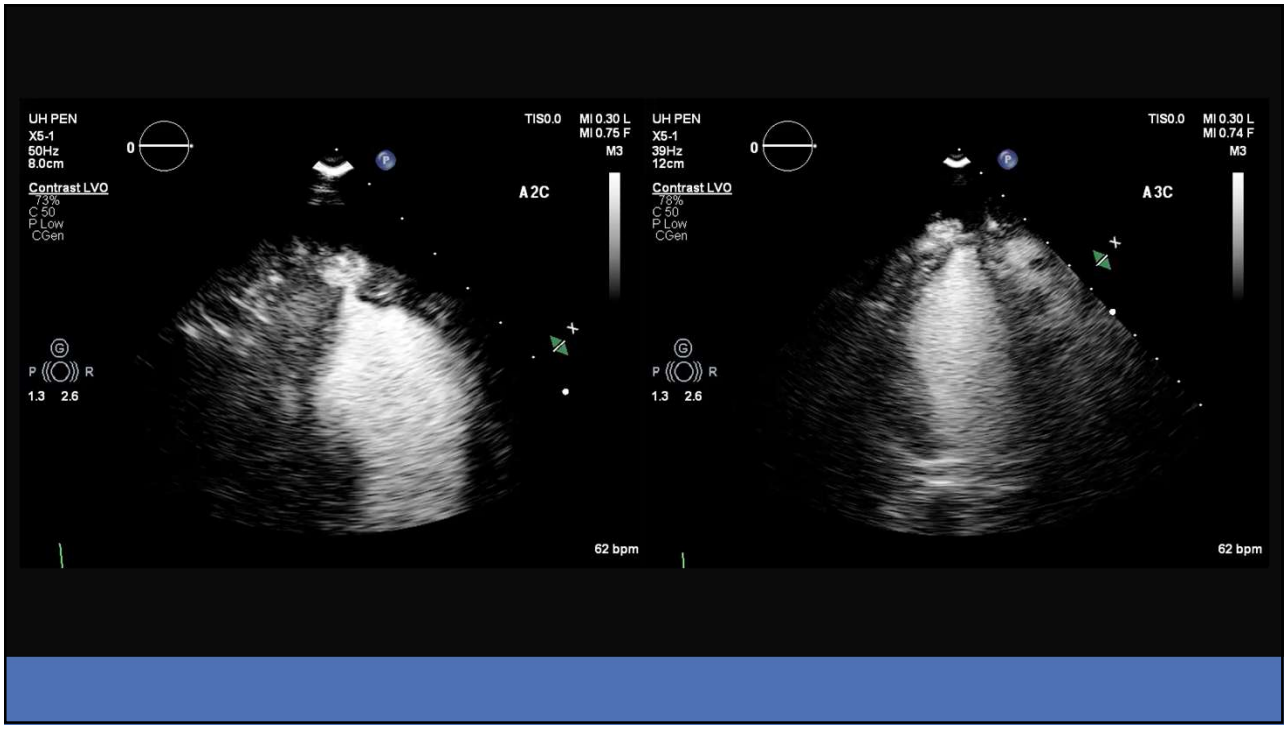

50

© Copyright. Society of Diagnostic Medical Sonography. All Rights Reserved.

Echo Report

- Echocardiographic findings consistent with a left ventricular apical pseudoaneurysm
- Narrow neck, 0.5 cm

51

Case 3

- 62-year-old female with known severe MR, systolic HF, non-compaction cardiomyopathy, HTN, and paroxysmal Afib
- Admitted to Advanced HF ICU, stat echo ordered for severe MR

52

© Copyright. Society of Diagnostic Medical Sonography. All Rights Reserved.

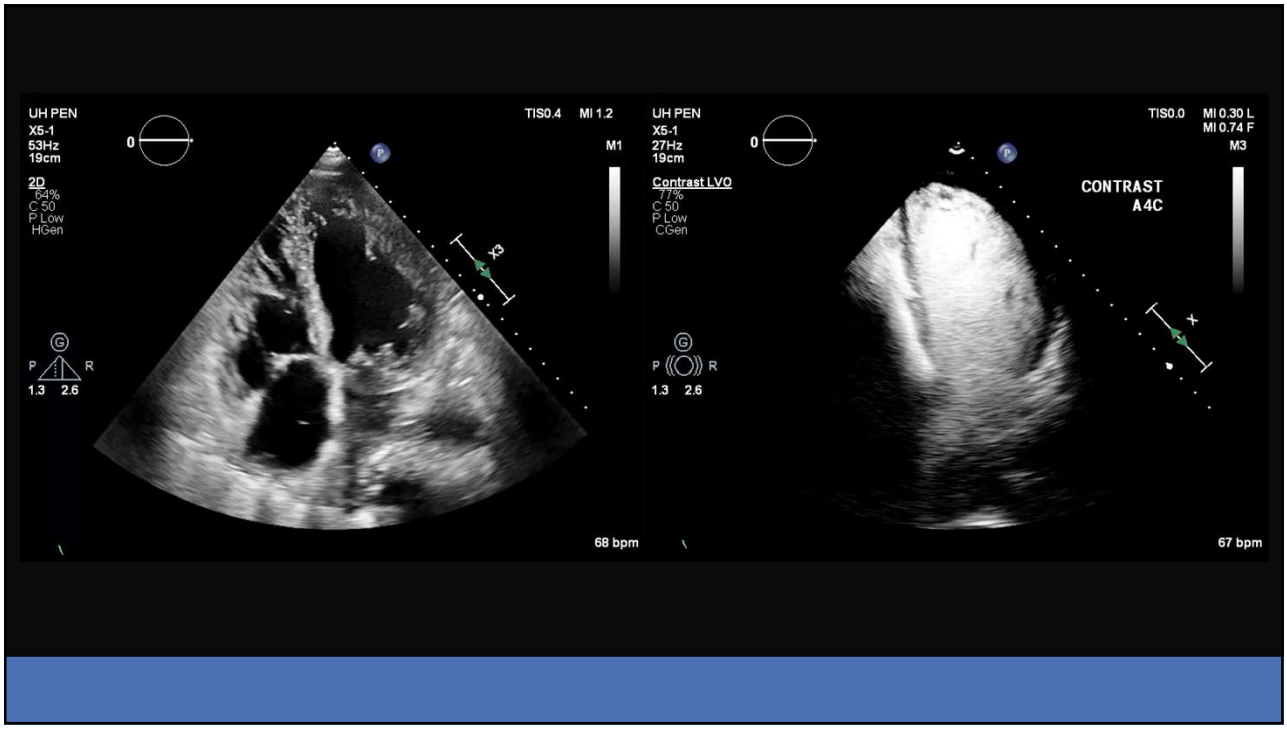

53

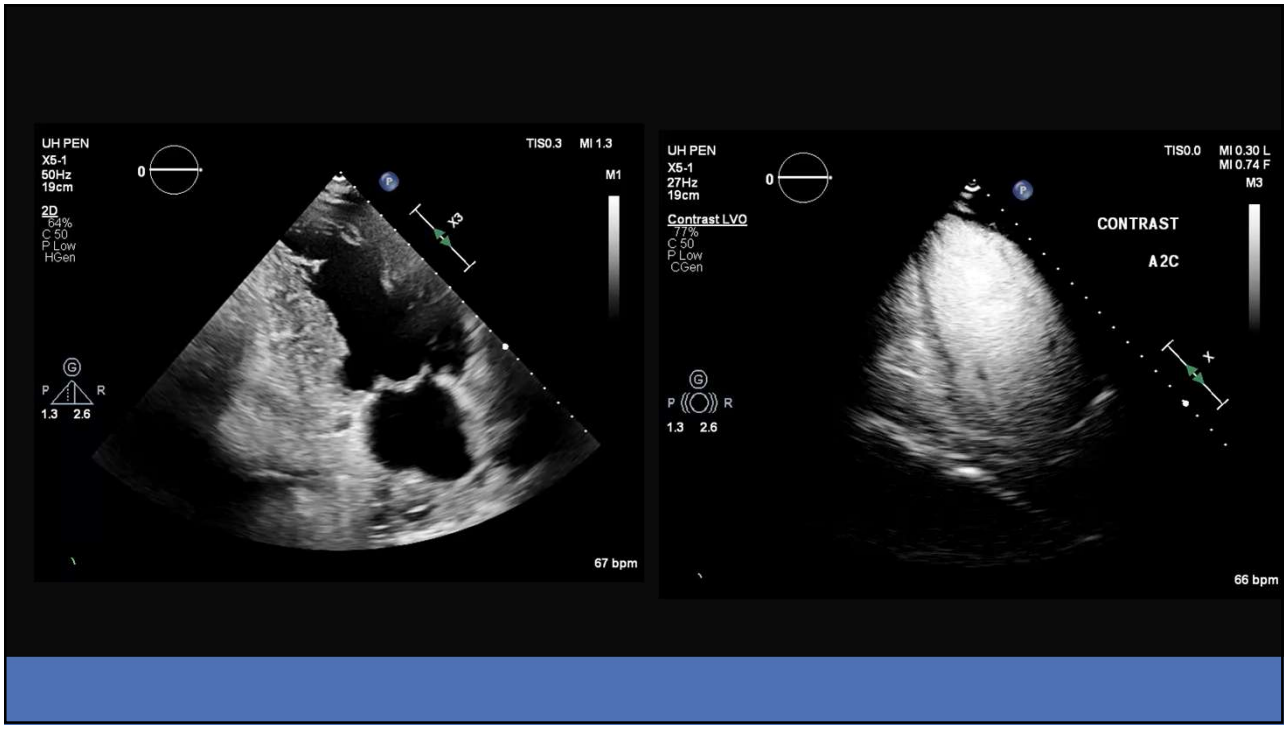

54

© Copyright. Society of Diagnostic Medical Sonography. All Rights Reserved.

2026 SDMS Annual Conference

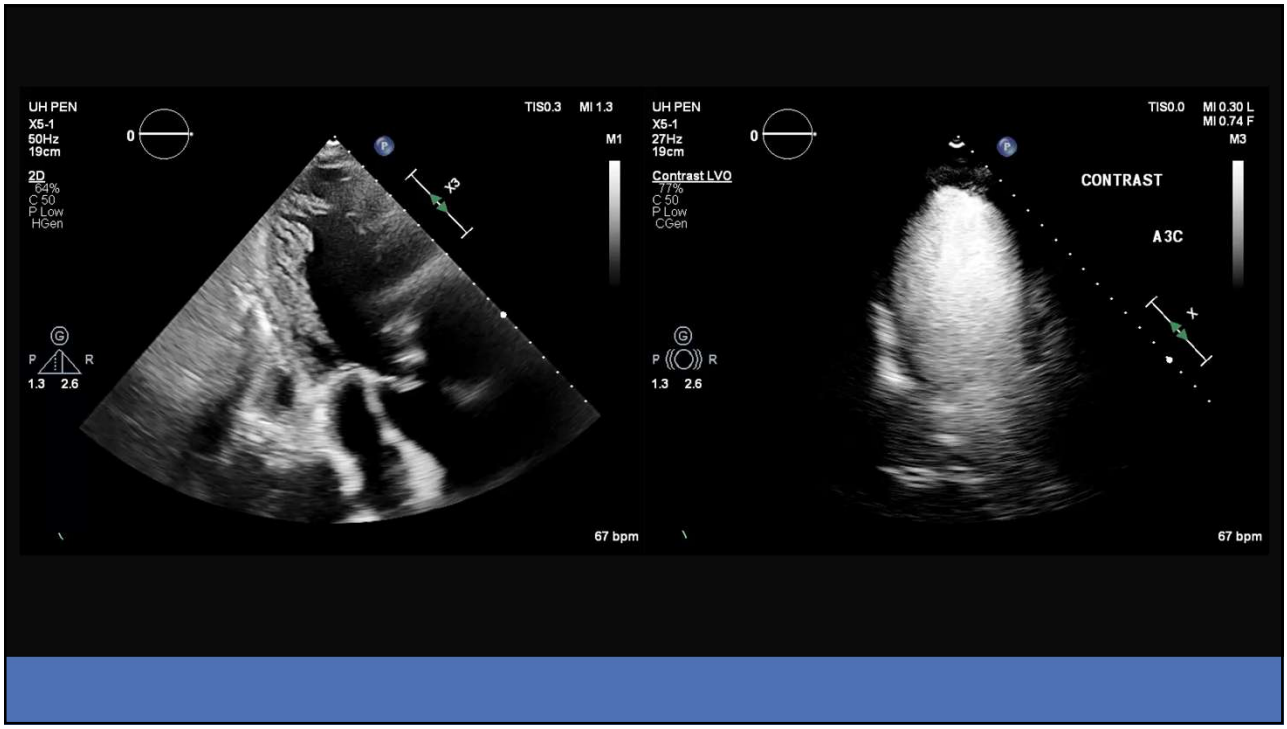

55

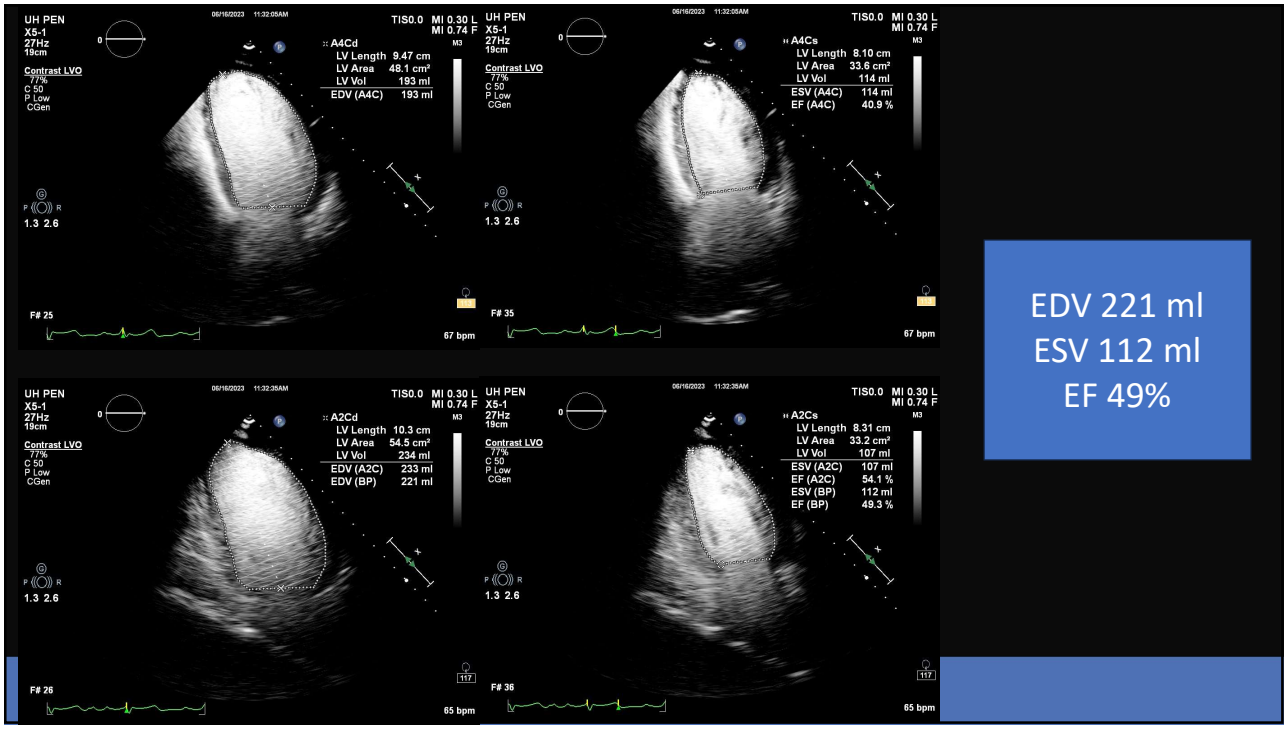

56

© Copyright. Society of Diagnostic Medical Sonography. All Rights Reserved.

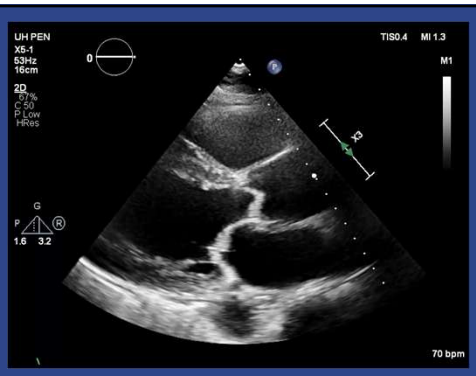





RVol = $SV_{mv} - SV_{lvo}$

Rvol = 109ml – 41.6ml

Rvol = 67.4ml

RF = 61.8%

Severe MR

57

Echo report

- EF 45-50%
- LV cavity size moderately dilated
- No LV thrombus
- Patient went to OR for MVr, TVr, LAAL, PFO closure and IABP

58

© Copyright. Society of Diagnostic Medical Sonography. All Rights Reserved.

Case 4

- 76 year-old male with non-ischemic cardiomyopathy, Heartmate 3 LVAD implanted 3-years earlier, paroxysmal A-fib, VT s/p ablation, HTN
- LVAD set at 5200 RPMs
- Patient admitted to Advanced Heart failure ICU, echo ordered for LVAD assessment

59

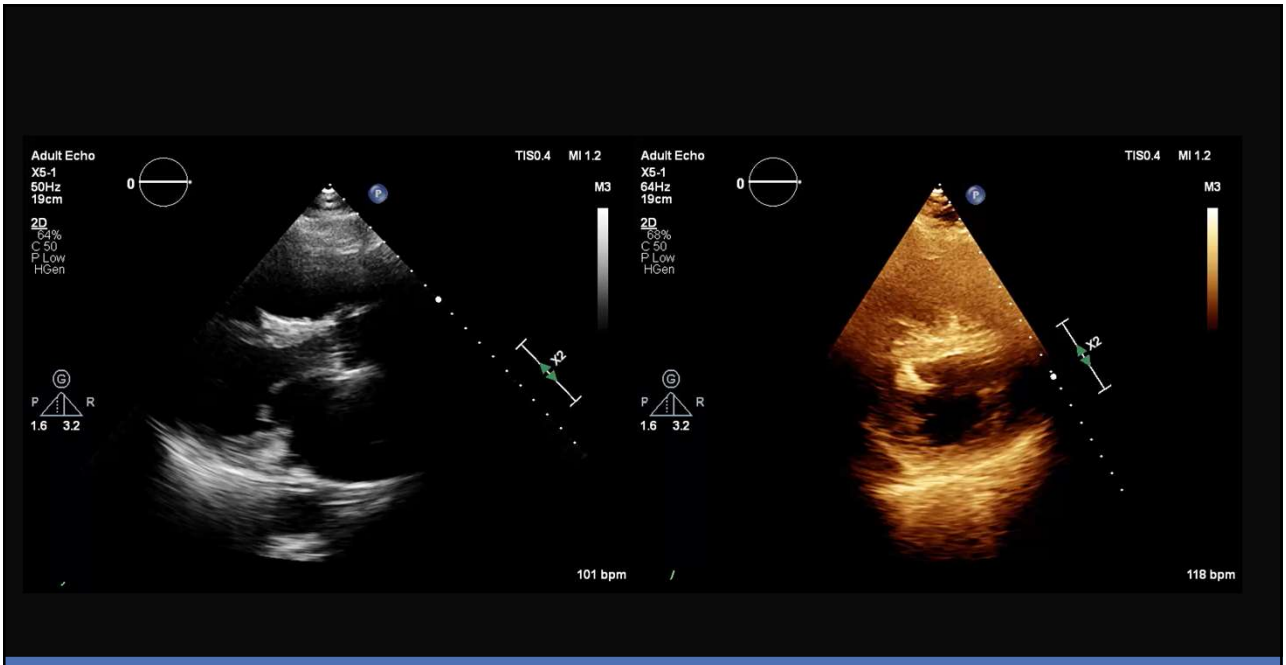

60

© Copyright. Society of Diagnostic Medical Sonography. All Rights Reserved.

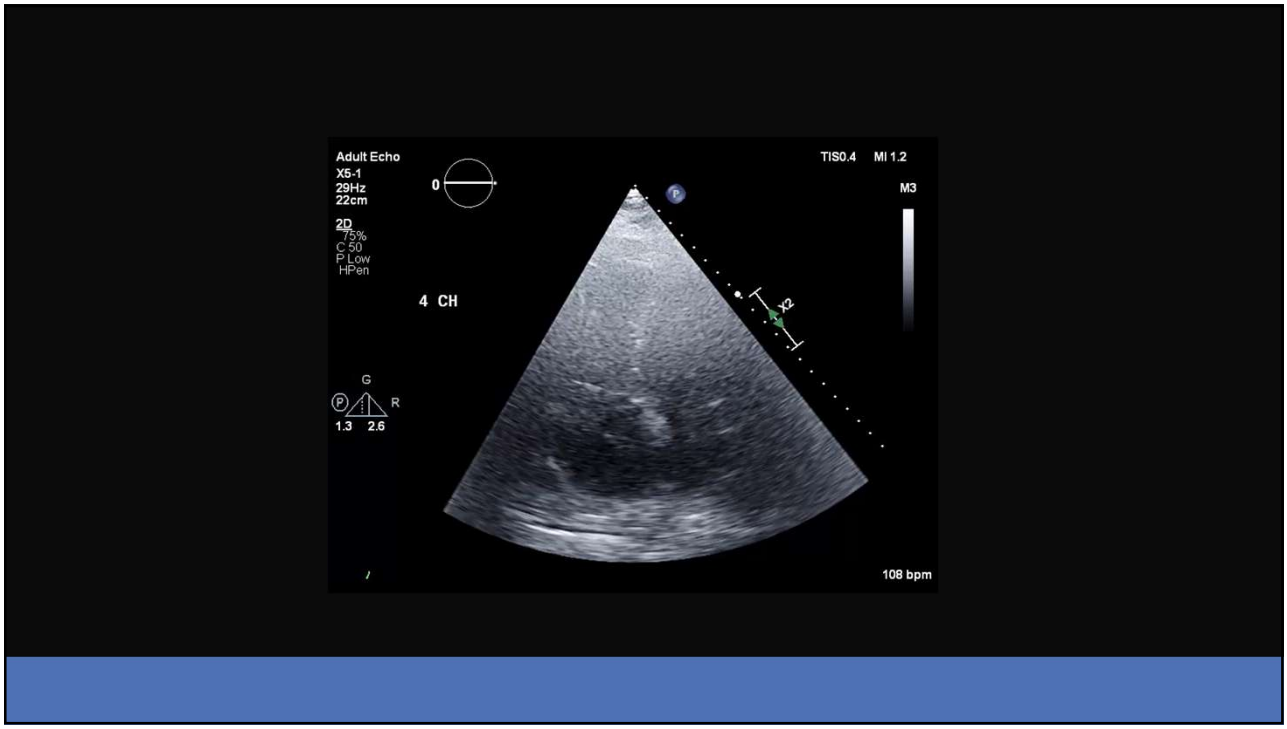

61

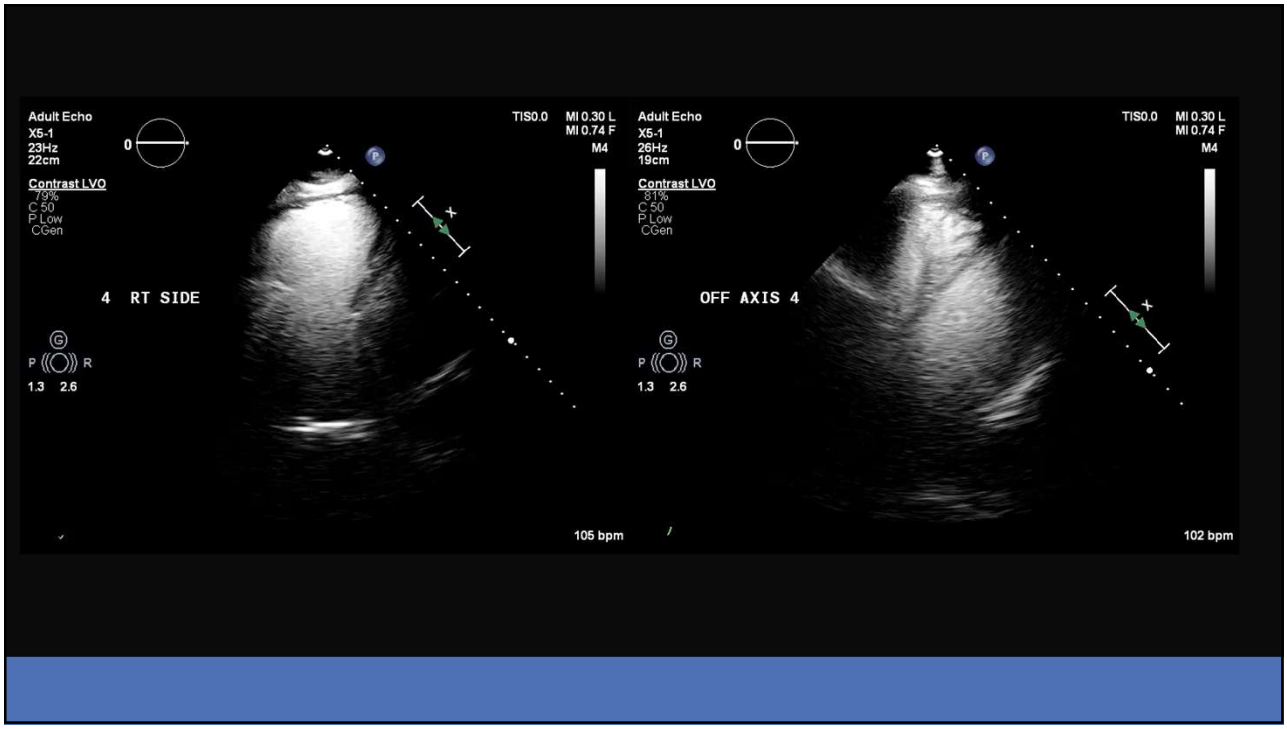

62

© Copyright. Society of Diagnostic Medical Sonography. All Rights Reserved.

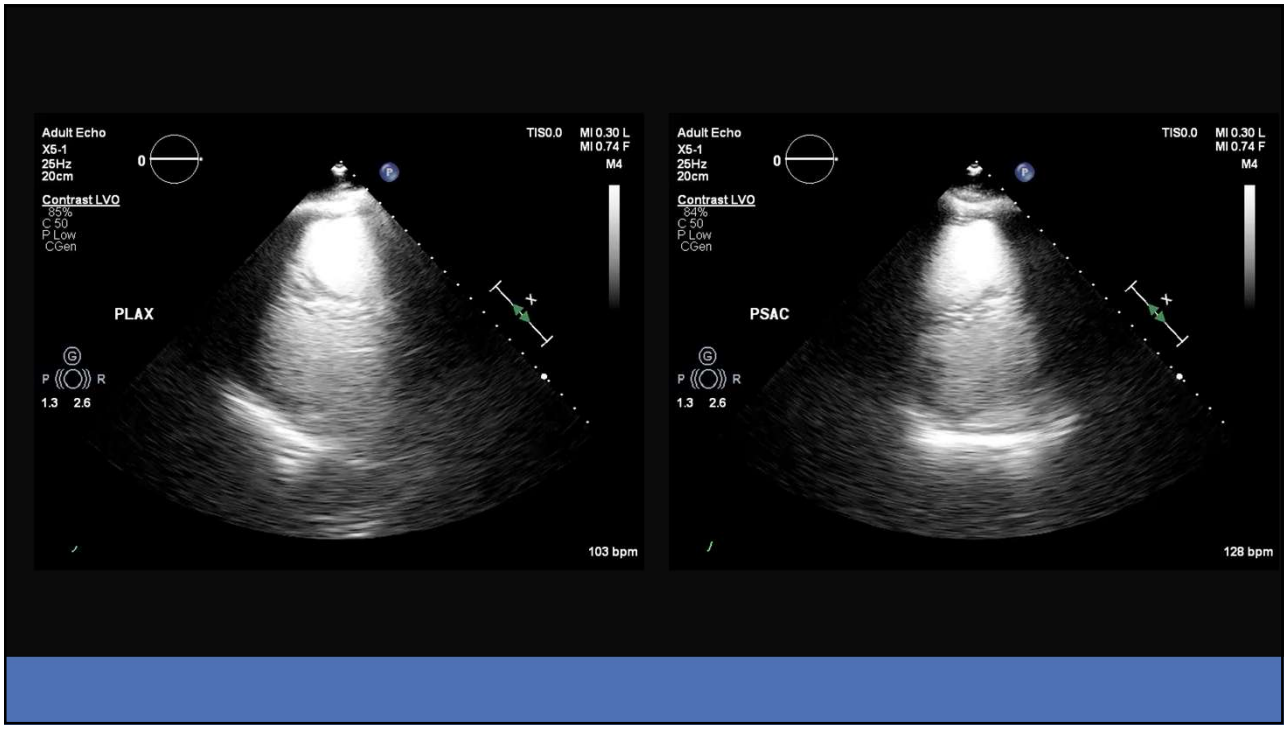

63

Echo Report

- Severely decreased systolic function
- EF 15-20%
- Severely enlarged right ventricle
- Severely reduced RV systolic function

64

© Copyright. Society of Diagnostic Medical Sonography. All Rights Reserved.

Case 5

- 67-year-old female post-op day 7 for mini-thoracotomy, pericardial window
- History of HTN, HLD, DMII, CAD, PCI x 2 (RCS/LCX/LAD), squamous cell carcinoma of lung with mets to left ribs, liver and adrenal glands
- Echo ordered for concern for cardiac mets

65

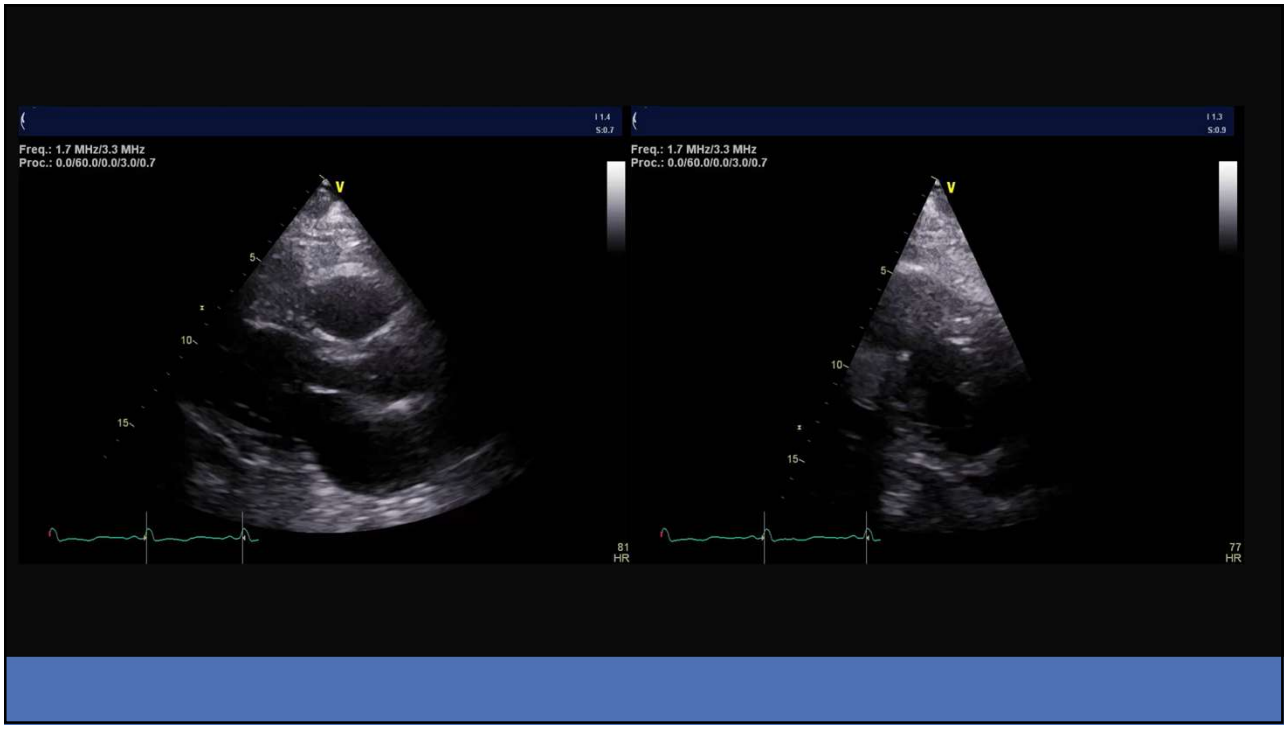

66

© Copyright. Society of Diagnostic Medical Sonography. All Rights Reserved.

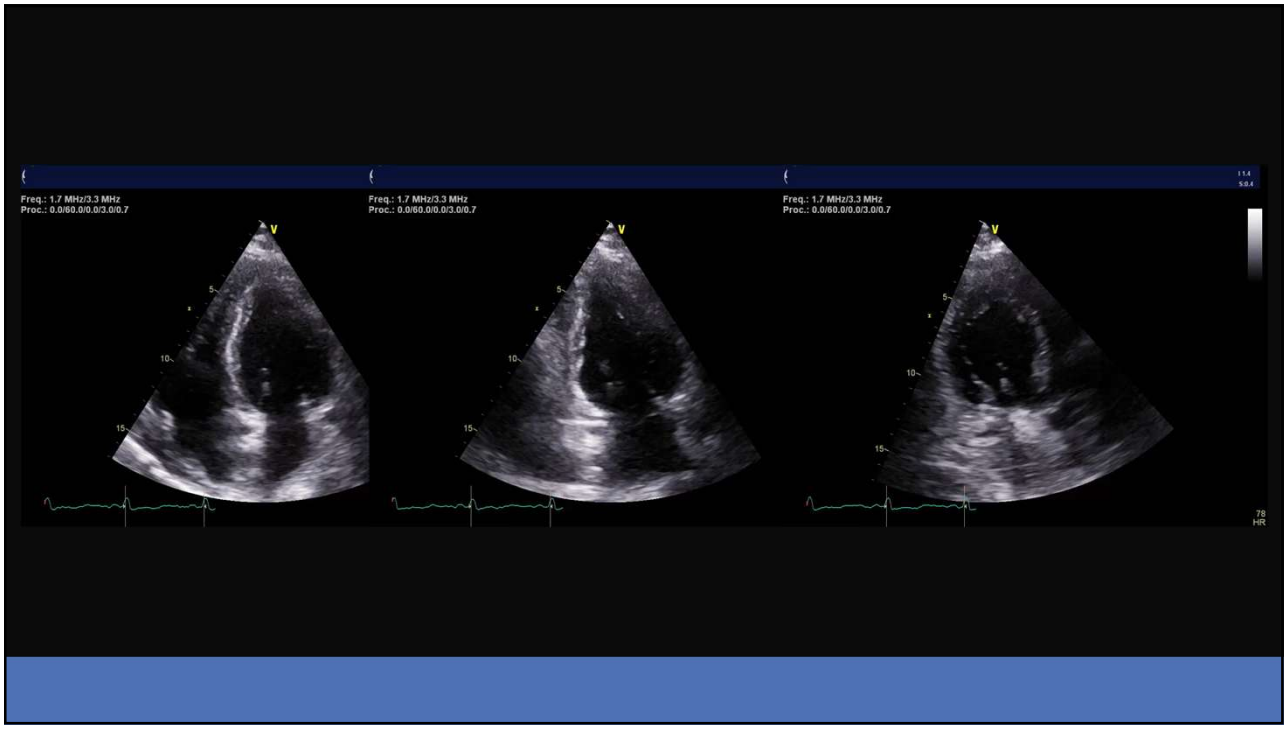

67

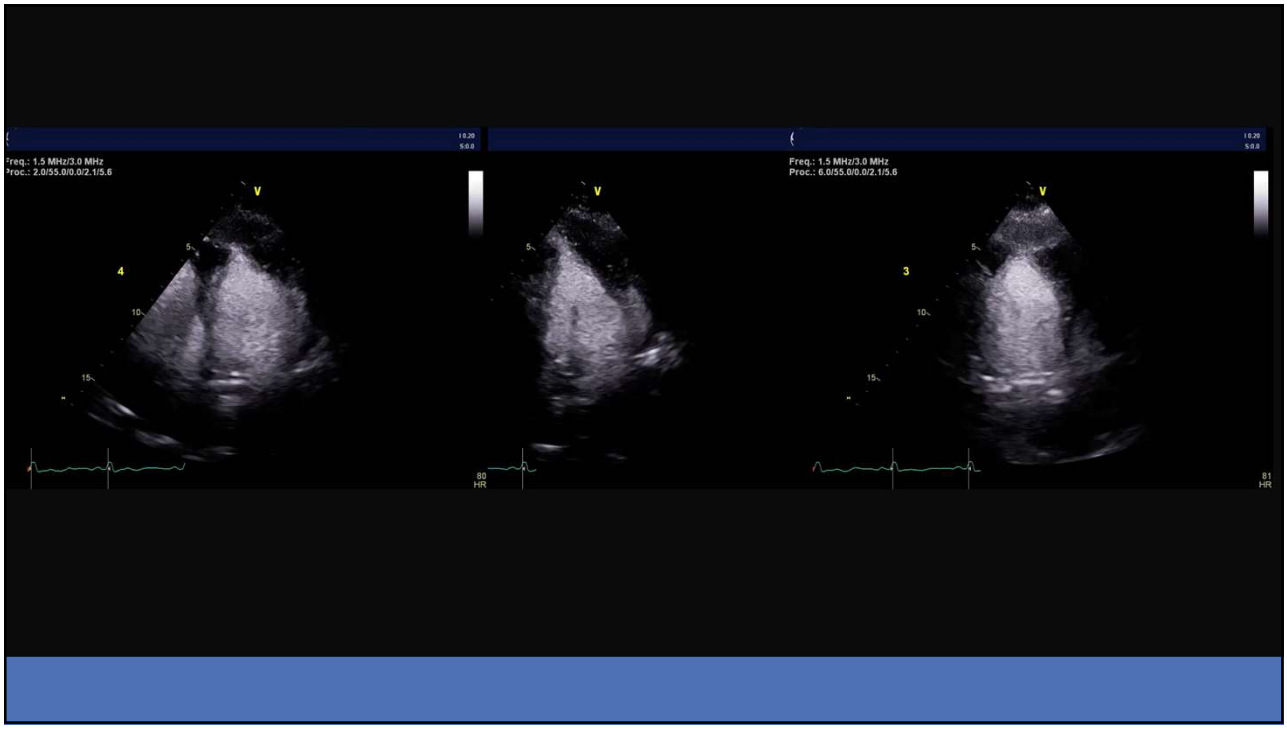

68

© Copyright. Society of Diagnostic Medical Sonography. All Rights Reserved.

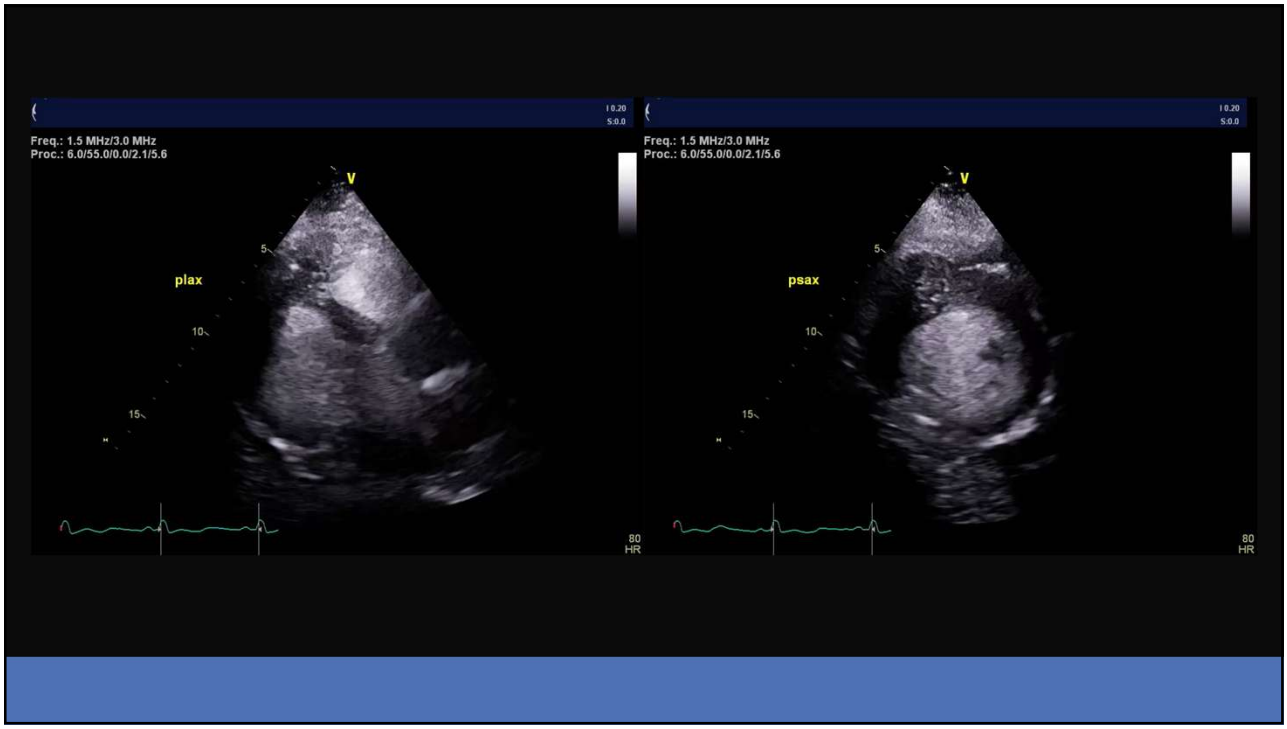

69



70

© Copyright. Society of Diagnostic Medical Sonography. All Rights Reserved.

Echo Report

- Normal LV function with an EF of 60-65%
- Layered echo density in the LV apex measuring 4x1.3cm, extending from the LV myocardium
- Echo density noted in RV apex measuring 1.8x2cm extending from the RV myocardium
- Global longitudinal strain is significantly reduced in the LV apex
- Findings concerning for cardiac metastasis
- Cardiac MRI recommended

71

Case 6

- 67 year old female presented for an outpatient echocardiogram for angina, known LVH and shortness of breath

72

© Copyright. Society of Diagnostic Medical Sonography. All Rights Reserved.

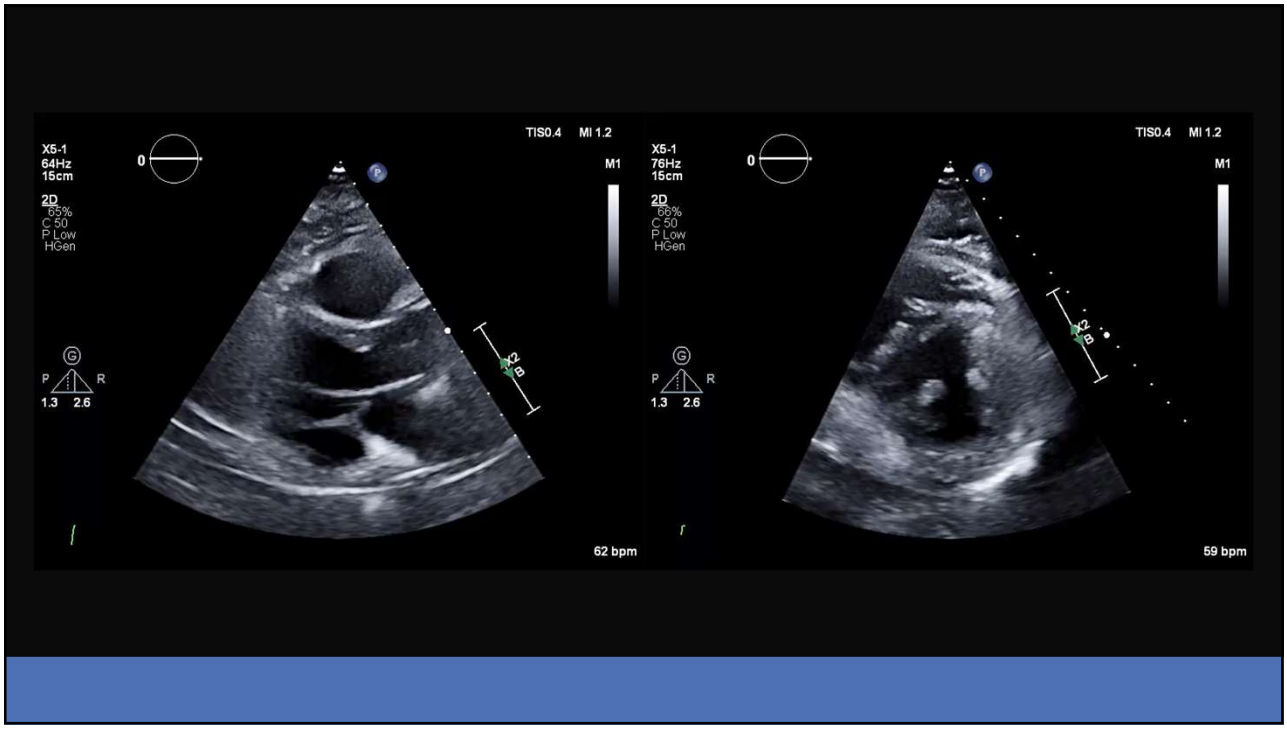

73

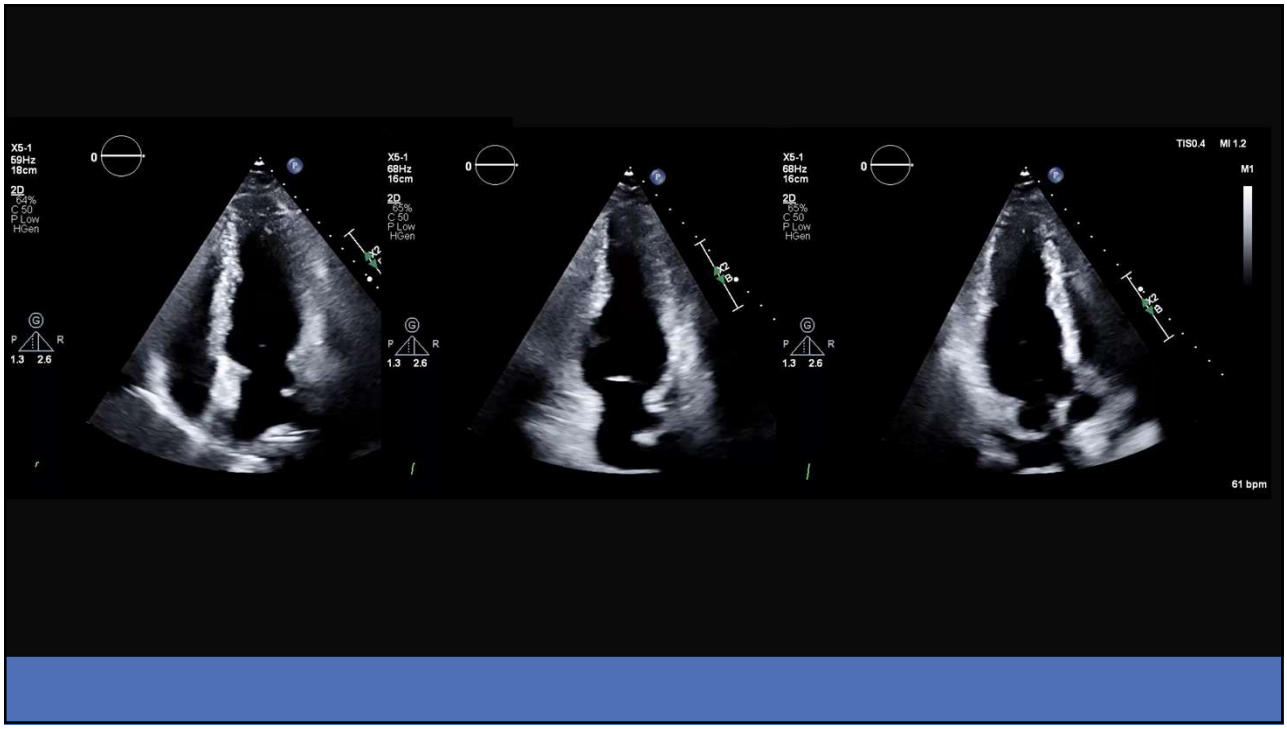

74

© Copyright. Society of Diagnostic Medical Sonography. All Rights Reserved.

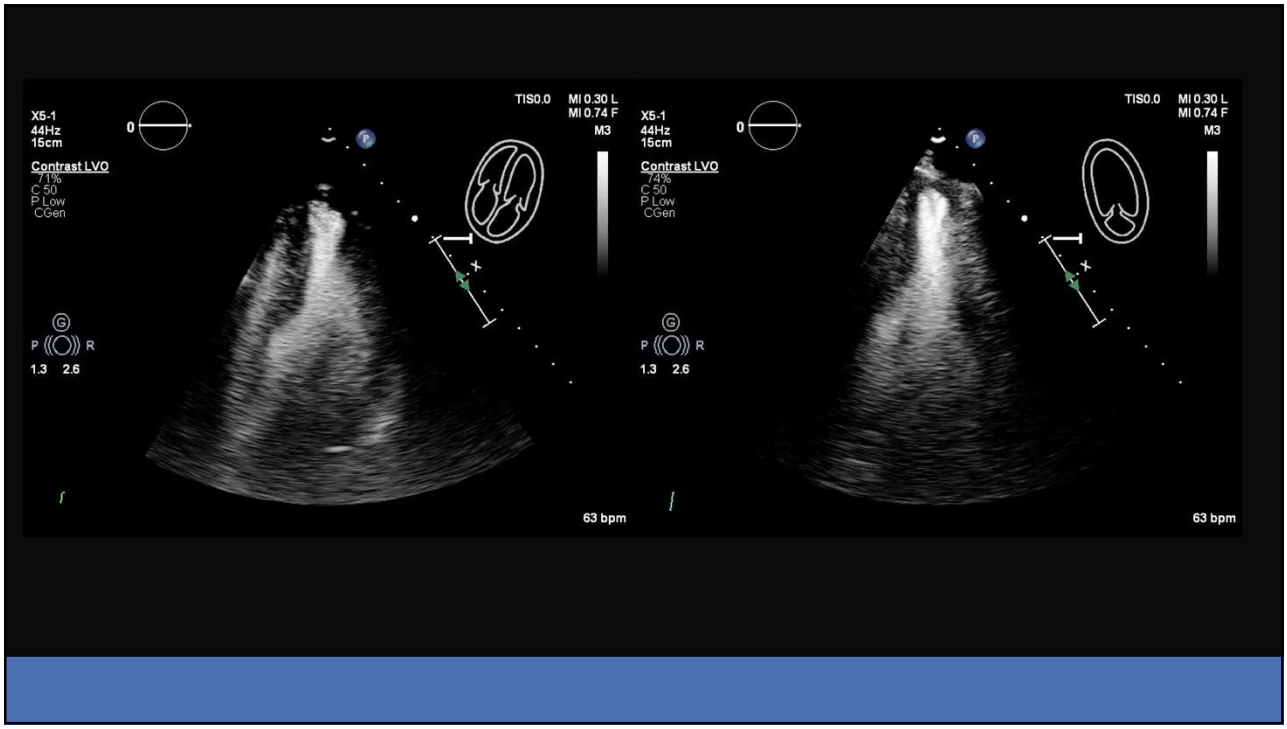

75

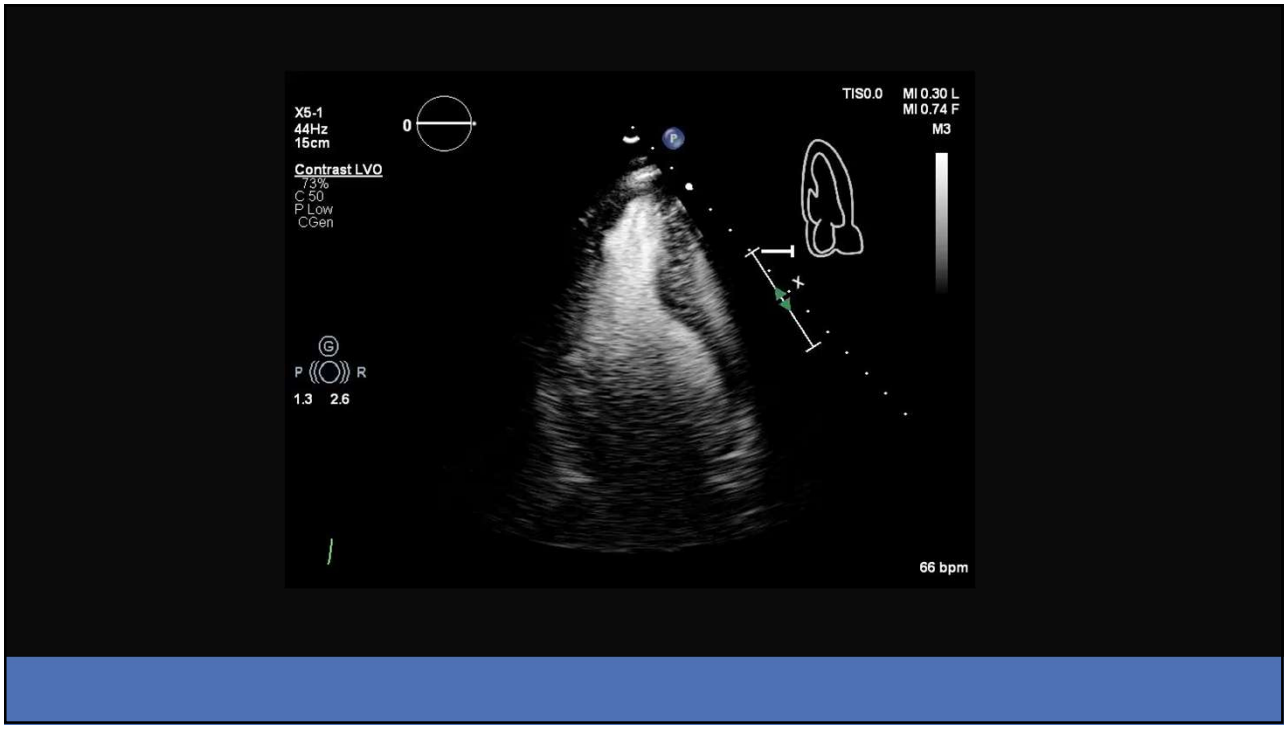

76

© Copyright. Society of Diagnostic Medical Sonography. All Rights Reserved.

Echo report

- Estimated EF of 55%
- Moderate, concentric LVH involving the apex
- Left ventricular apical aneurysm noted

77

1 year later

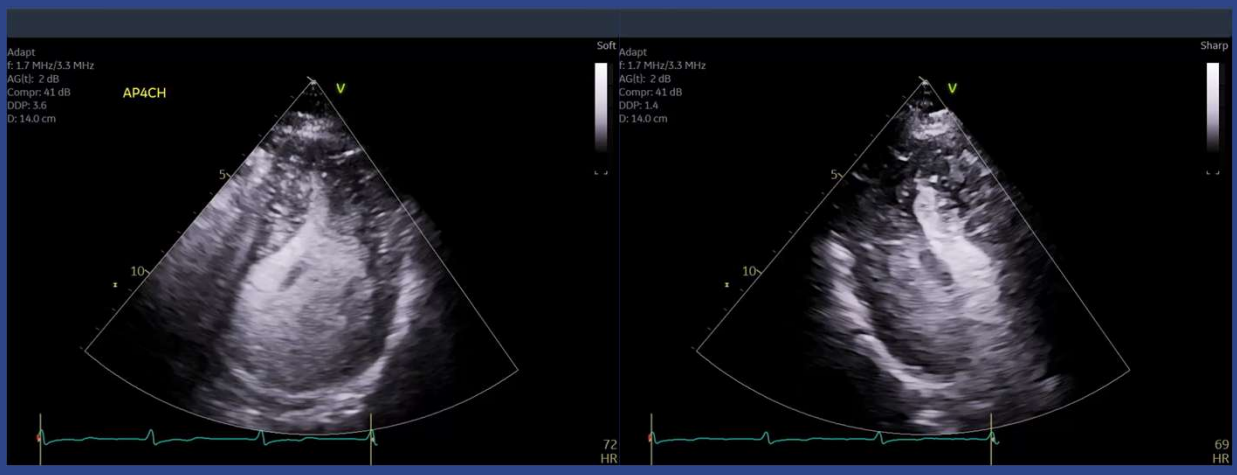

78

© Copyright. Society of Diagnostic Medical Sonography. All Rights Reserved.

2 years later

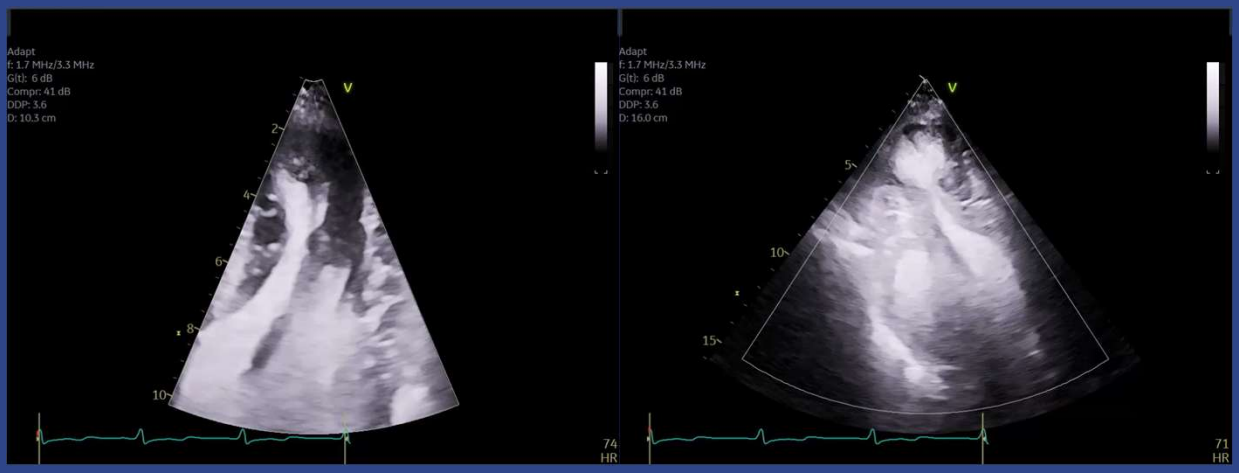

79

Closing thoughts

- Stay current with evolving contrast echocardiography standards and best practices
- Develop strong equipment knowledge and optimize system settings
- Partner with vendors to leverage education, support, and technology updates
- Recognize common UEA artifacts and know how to troubleshoot them effectively
- Incorporate ongoing QA/QI processes to ensure consistency and quality
- Foster clear communication among sonographers, physicians, and nurses
- Engage leadership to support resources, training, and program growth
- Focus on the ultimate goal: improved diagnostic confidence and better patient care



80

© Copyright. Society of Diagnostic Medical Sonography. All Rights Reserved.



Discussion and Questions

81

References

- Ahmed H. Contrast echocardiography: Contrast agents, safety, and imaging technique. [Internet]. UpToDate: 2026 Mar 11. Available from: https://www.uptodate.com/contents/contrast-echocardiography-contrast-agents-safety-and-imaging-technique/print
- Echocardiography accreditation standards & guidelines. (2026). Retrieved from https://intersocietal.org/programs/echocardiography/standards/
- Kurt M, Shaikh K, Peterson L, Kurrelmeyer K, Shah G, Nagueh S, Fromm R, Quinones M, Zoghbi W. (2009). Impact of contrast echocardiography on evaluation of ventricular function and clinical management in a large prospective cohort. Journal of the American College of Cardiology. 2009; 53(9): 802–810.
- Lang, R. M. Dynamic echocardiography. (city); Saunders/Elsevier; 2011. (page).
- Main M, Hibberd M, Ryan A, Lowe T, Miller P, Bhat G. Acute Mortality in Critically ill Patients Undergoing Echocardiography With or Without an Ultrasound Contrast Agent. JACC: Cardiovascular Imaging. 2014; 7(1).
- McCulloch, Marti. The value add of enhanced echocardiography and radiation safety for the sonographer. Journal of the American Society of Echocardiography. 2014; 27(8).
- Mulvagh S, Rakowski H, Vannan M, Abdelmoneim S, Becher H, Bierig M, Burns P, Castello R, Coon P, Hagen M, Jollis J, Kimball T, Kitzman D, Kronzon I, Labovitz A, Lang R, Mathew J, Moir W, Nagueh S, Pearlman A, Perez J, Porter T, Rosenbloom J, Strachen M, Thanigaraj S, Wei K, Woo A, Yu, Zoghbi A. American Society of Echocardiography Consensus Statement on the clinical applications of ultrasonic contrast agents in echocardiography. Journal of the American Society of Echocardiography. 2008; 21(11): 1179–1201.
- Keckly P. The Meaning of "Value" in Health care. [Internet]. The Health Care Blog: 2015 Dec 3. Available from: https://thehealthcareblog.com/blog/2015/12/03/the-meaning-of-value-in-health-care/
- Samad Z, Minter S, Armour A, Tinnemore A, Sivak JA, Sedberry B, Strub K, Horan SM, Harrison JK, Kisslo J, Douglas PS, Velazquez EJ. Implementing a Continuous Quality Improvement Program in a High-Volume Clinical Echocardiography Laboratory: Improving Care for Patients With Aortic Stenosis. Circ Cardiovasc Imaging. 2016 Mar;9(3).
- Scope of Practice and Clinical Standards for the Diagnostic Medical Sonographer. (2023). Retrieved from https://www.sdms.org/about/who-we-are/scope-of-practice
- Porter T, Abdelmoneim S, Belcik T, McCulloch M, Mulvagh S, Olson J, Porcelli C, Tsutsui J, Wei K. Guidelines for the cardiac sonographer in the performance of contrast echocardiography: A focused update from the American Society of Echocardiography. Journal of the American Society of Echocardiography. 2014; 27(8): 797–810.
- Porter T, Mulvagh S, Abdelmoneim S, Becher H, Belcik T, Bierig M, Choy J, Gaibazzi N, Gillam L, Janardhanan R, Kutty S, Leong-Poi H, Lindner J, Main M, Mathias W, Park M, Senior R, Villanueva F. Clinical applications of ultrasonic enhancing agents in echocardiography: 2018 American society of echocardiography guidelines update. Journal of the American Society of Echocardiography. 2018; 31(3): 241–274.

82

© Copyright. Society of Diagnostic Medical Sonography. All Rights Reserved.