Carotid Plaque Evaluation Using Risk Stratification and Ultrasound Imaging

The search for better carotid disease biomarkers …
la luta continua with Carotid Plaque-RADS

1

SPEAKER PRESENTATION DISCLAIMER

The content and views presented are made available for educational purposes only. The information presented are the opinions of the presenter and do not necessarily represent the views of the Society of Diagnostic Medical Sonography (SDMS) or its affiliated organizations, officers, Boards of Directors, or staff members.

The presenter is responsible for ensuring balance, independence, objectivity, scientific rigor, and avoiding commercial bias in their presentation. Before making the presentation, the presenter is required to disclose to the audience any relevant financial interests or relationships with manufacturers or providers of medical products, services, technologies, and programs.

The SDMS and its affiliated organizations, officers, Board of Directors, and staff members disclaim any and all liability for all claims that may arise out of the use of this educational activity.

2

© Copyright. Society of Diagnostic Medical Sonography. All Rights Reserved.

RESEARCH DISCLAIMER

The information presented in this presentation is based on research conducted to the best of the presenters' abilities and knowledge. Research involves uncertainty and is subject to limitations. The findings and conclusions presented herein may be influenced by various factors including but not limited to data quality, methodology, assumptions, and interpretation.

Research outcomes may not always accurately predict real-world scenarios or future events. While the presenter may make efforts to ensure the accuracy and reliability of the information presented, completeness or absolute correctness is not guaranteed. This presentation is intended for informational purposes only and should not be construed as professional advice. Participants are encouraged to independently verify any information provided and consult relevant experts or professionals where appropriate.

The SDMS and its affiliated organizations, officers, Board of Directors, and staff members disclaim any and all liability for all claims that may arise out of the use of this educational activity.

3

GENERATIVE AI DISCLAIMER

The presenter utilized the use of large language models (LLMs) and generative artificial intelligence (AI) as a productivity tool to assist in drafting and refining content in this presentation.

While these tools can aid in structuring ideas, summarizing, paraphrasing, and language polishing, they have inherent limitations and cannot replace human creativity, critical thinking, or expert judgment. AI-generated content may contain errors, biases, or gaps in knowledge.

This presentation is intended for informational purposes only and should not be construed as definitive or authoritative guidance. Participants are encouraged to critically evaluate the information presented and consult relevant experts as needed. The SDMS and its affiliated organizations, officers, Board of Directors, and staff members disclaim any and all liability for claims that may arise from the use or interpretation of this educational material.

4

© Copyright. Society of Diagnostic Medical Sonography. All Rights Reserved.

Carotid Plaque Evaluation Using Risk Stratification and Ultrasound Imaging

Disclosures and Contact Information

Richard Genova, BA, RVT, RPhS, NVS
Certified Neurovascular Specialist
Technical Director of the Neurovascular Ultrasound Lab
Weill Cornell Medicine—NY Presbyterian Hospital
New York, NY 10065

Member, Board of Directors, American Society of Neuroimaging (2022-present)
Member, Board of Directors, Vascular Testing, Intersocietal Accreditation Commission (2020-2025)

rig7007@med.cornell.edu
(212) 746-5458 office
(929) 783-3444 mobile
neurosonologist@protonmail.com
Linkedin.com/in/rgenova
X: @neurosonologist

I have nothing to disclose … my volunteer positions are non-remunerative.

Ulcerative plaque has long been recognized as a high stroke risk

Some examples of vulnerability-related ulcerative plaque:

a) mixed echogenic irregular ulcerated plaque extending to the internal carotid artery with a large concavity (arrow)

b) mixed echogenic plaque with hypoechoic internal segments (arrow), probable LRNC

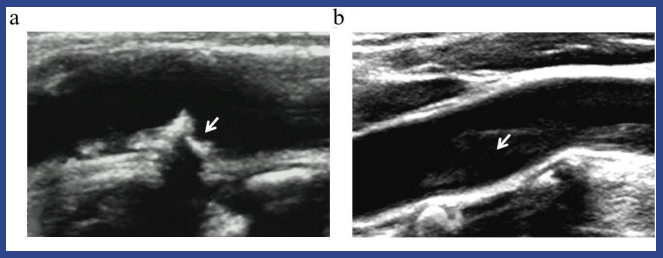

Source: "Systemic immune inflammation index is associated with ulcerative plaque in patients with acute ischemic stroke: A single center exploratory study," https://doi.org/10.21203/rs.3.rs-3096002/v1. (June 2023)

© Copyright. Society of Diagnostic Medical Sonography. All Rights Reserved.

Plaque morphology

Various attempts to standardize nomenclature and classification of plaque types using ultrasound have been attempted, but correlating disease burden with specific plaque characteristics has not been universally accepted.

7

Plaque morphology

This table of plaque morphology is from a reference guide for vascular technologists and reading physicians in vascular ultrasound from over a decade ago (2013).

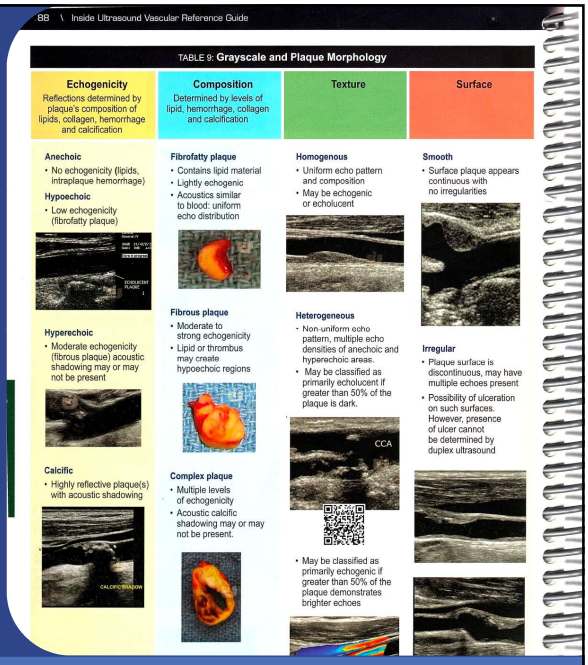

8

© Copyright. Society of Diagnostic Medical Sonography. All Rights Reserved.

NASCET and ECST: The ’80s and the ’90s

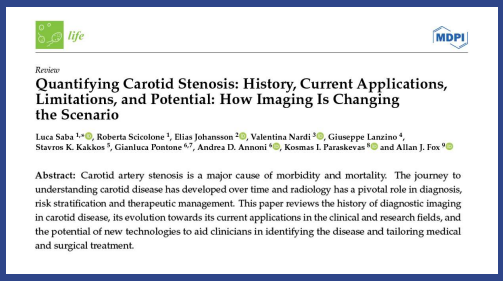

life

MDPI

Review

Quantifying Carotid Stenosis: History, Current Applications, Limitations, and Potential: How Imaging Is Changing the Scenario

Luca Saba [1,*], Roberta Scicolone [1], Elias Johansson [2], Valentina Nardi [3], Giuseppe Lanzino [4], Stavros K. Kakkos [5], Gianluca Pontone [6,7], Andrea D. Annoni [8], Kosmas I. Paraskevas [8] and Allan J. Fox [9]

Abstract: Carotid artery stenosis is a major cause of morbidity and mortality. The journey to understanding carotid disease has developed over time and radiology has a pivotal role in diagnosis, risk stratification and therapeutic management. This paper reviews the history of diagnostic imaging in carotid disease, its evolution towards its current applications in the clinical and research fields, and the potential of new technologies to aid clinicians in identifying the disease and tailoring medical and surgical treatment.

2. Models for Assessing the Degree of Carotid Stenosis

2.1. The NASCET

The North American Symptomatic Carotid Endarterectomy Trial (NASCET) [9,10,14], conducted between 1987 and 1996, randomizing 2885 patients, with 1415 cases in the surgical arm, stands as a cornerstone for the understanding and management of carotid artery disease. This landmark study was designed to evaluate the use and effectiveness of carotid endarterectomy (CEA) in patients with symptomatic carotid stenosis, including a focus on the degree of stenosis as an indication for intervention.

NASCET enrolled patients with symptoms of transient ischemic attack (TIA) or minor stroke and carotid stenosis ranging from 30% to 99%. The trial’s methodology was rigorous, employing DSA to assess the degree of stenosis. One of the study’s significant contributions was the use of a consistent method to calculate the degree of stenosis, which became widely adopted after the publication of the NASCET results, conditional upon two steps:

(1) To seek near-occlusion if present and, when found, not to apply the method;

(2) To identify two critical points on an angiographic image (Figure 1): (a) the narrowest diameter of the internal carotid artery (ICA) stenosis; (b) the normal diameter of the ICA well beyond the ICA bulb, where the arterial walls are parallel and unaffected by atherosclerotic plaques.

9

Using US, assessment according to NASCET criteria poses challenges in practical settings, namely high bifurcation, severe tortuosity, extreme plaque length, and acute thrombus, which can be difficult to visualize with B-mode imaging since it is weakly echogenic [27,28].

PSV measurements do not provide a morphological assessment in line with NASCET rules, which specifically require visualization of certain arterial segments [30,35–38].

The reliance on PSV as a surrogate marker for carotid stenosis introduces several limitations. Firstly, PSV measurements can be influenced by factors other than the degree of stenosis. Variations in cardiac output, blood pressure, and even contralateral carotid occlusion can affect PSV readings. Another limitation is the potential for interobserver variability in PSV measurements. Ultrasound is operator-dependent, and differences in probe placement, angle of insonation, and interpretation of the results can lead to variability in measurements. This inconsistency can be problematic, especially when making critical clinical decisions based on these values [39–41].

Furthermore, PSV as a standalone measurement does not provide a complete picture of the morphological characteristics of the stenotic lesion. Information about plaque composition, surface characteristics, and presence of ulceration, which are essential in assessing stroke risk and guiding management, are not discernible from PSV measurements alone [40].

The reliance on PSV also introduces a risk of oversimplification. Carotid stenosis is a complex pathological entity, and reducing its assessment to a single hemodynamic parameter may overlook the nuanced understanding required for optimal patient management [40].

- Cardiac output variations, BP, contralateral stenosis
- Interobserver and interoperator variability
- PSV misses morphological characteristics
- Plaque composition, surface and ulceration not discernible from PSV alone

10

© Copyright. Society of Diagnostic Medical Sonography. All Rights Reserved.

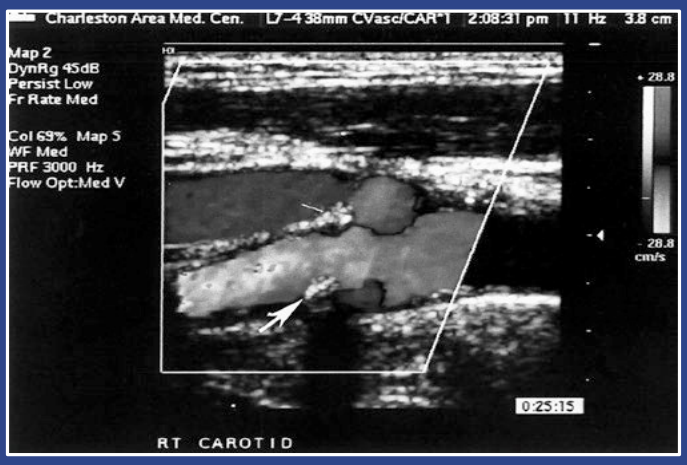

Calcified plaque with a very dense signal (acoustic shadowing)

Image above is from A.F. AbuRahma (ed.), Noninvasive Vascular Diagnosis (2017), DOI 10.1007/978-3-319-54760-2_7

11

Italian physicians and sonographers take a swing in 2016 – putting plaque characteristics on par with velocity criteria.

J Ultrasound (2016) 19:83–90
DOI 10.1007/s40477-016-0193-6

CrossMark

REVIEW PAPER

Searching the perfect ultrasonic classification in assessing carotid artery stenosis: comparison and remarks upon the existing ultrasound criteria

Chiara Mozzini[1] · Giuseppe Roscia[2] · Alder Casadei[3] · Luciano Cominacini[1]



The authors' proposal for grading the ica stenosis: the final "ten commands" for the colour Doppler sonographer

In the Authors' proposal, the evaluation of the ICA stenosis should be completed with the following information:

1. the plaque location;
2. the plaque extension and the plaque maximal diameter (mm), trasversal and/or longitudinal section;
3. the plaque surface details (smooth, irregular, very irregular);
4. the Gray-Weale echogenicity classification [16, 17] report: type 1: uniformly anechoic or hypoechoic; type 2: predominantly (>50 %) hypoechoic; type 3: predominantly (>50 %) hyperechoic; type 4: uniformly hyperechoic and type 5: uniformly echogenic with posterior shadowing (the so called calcified plaque);
5. the report of the area or diameter reduction (according to both the NASCET method and the ECST) with the clear declaration of the % of stenosis according to the NASCET method and, in brackets, to the ECST;
6. the intra-stenotic PSV and end diastolic flow velocity (cm/s), the pre- and post-stenotic PSV (cm/s) evaluation;
7. the carotid PSV ratio ICA/ACC;
8. the evaluation of the collateral flows;
9. the Doppler insonation angle;
10. the Trans-Cranial Colour Doppler (TCCD) evaluation.

Some remarks about some points: first of all, it seems reasonable the report of both ECST and NASCET stenosis percentage, as considered in the DEGUM classification, because of the relative difference of the percentage of the diameter reduction (local diameter reduction according to the ECST and distal diameter reduction according to the NASCET). The diameter related to the distal diameter better corresponds to the hemodynamic effects but the local

As reported [7], the consensus of th
ologists in Ultrasound recommended
waveform should be obtained with an
"less than or equal to 60°", while t
Research Group criteria [10] stated t
should be taken using the angle "as lo
Going on, in the Authors' opinion, th
has to be considered as correct if equal
than 60°, as previously recommended. T
point.
So, it is clear that the possible error
is the angle, due to its cosine functio
equation. The angle can be estimated
laminar flow conditions, but this is not
disturbed or turbulent flows. Any er
Doppler angle significantly increases
measurements and the final result of an i
angle is that the measured PSV increase
not tolerable accepting an insonation a
rect because of the percentage of PSV in
of the subsequent change in the carotid
classification. It is to mention, howe
conditions a low angle is very difficult
not realistic recommending an insonat
less than 30°. In fact, few examinations
with this angle, that is surely the best,
only in selected patients: so this value
the objective but, in Authors' opinion,
duty rule.
Authors care to remark the contribu
evaluation in the context of carotid ult
flow evaluation (in particular periorbital
circle) has been established [10] as add
evaluation of the ophthalmic artery,
important collateral artery between the
nal carotid arteries, is possible using th
ultrasound, but the collaterals of the
cating and posterior communicating a
TCCD. In severe stenosis or occlusio
sonographic evidence of collaterals. A
TCCD evaluation in patients with ICA

12

© Copyright. Society of Diagnostic Medical Sonography. All Rights Reserved.

2026 SDMS Annual Conference

North American Clinicians Aware

Carotid Plaque Ultrasonic Heterogeneity and Severity of Stenosis

Ali F. AbuRahma, MD; John T. Wulu, Jr, PhD; Brad Crotty

Background and Purpose—Several studies have reported on the correlation of ultrasonic carotid plaque morphology, cerebrovascular symptoms, and intraplaque hemorrhage. This study correlates ultrasonic carotid plaque morphology with the degree of carotid stenosis.

Conclusions—The higher the degree of carotid stenosis, the more likely it is to be associated with ultrasonic heterogeneous plaque and cerebrovascular symptoms. Heterogeneity of the plaque was more positively correlated with symptoms than with any degree of stenosis. These findings suggest that plaque heterogeneity should be considered in selecting patients for carotid endarterectomy. (*Stroke*. 2002;33:1772-1775.)

stenoses, in 72% of the arteries with ≥60% stenoses versus 24% of the arteries with <60% stenosis, and in 80% of the arteries with ≥70% stenoses versus 34% of the arteries with <70% stenoses ($P<0.0001$ and odds ratios of 8.0, respectively). Heterogeneous plaques were associated with an incidence of symptoms that was h homogeneous plaques for all grades of stenoses; percentages were, respectively, as follows: 68% vers stenosis; 76% versus 21% for 50% to <60% stenosis; 79% versus 23% for 60% to <70% stenosis, an for ≥70% to 99% stenosis ($P<0.0001$ and odds ratios of 8.9, 11.9, 12.6, and 13.7, respectively). plaques was more positively correlated with symptoms than with any degree of stenosis (regardless of Eighty percent of all heterogeneous plaques were symptomatic versus 58% for all stenoses ≥50%, 6 ≥60%, and 75% for all stenoses ≥70% ($P<0.0001$, $P<0.0001$, and $P=0.02$, respectively).

Conclusions—The higher the degree of carotid stenosis, the more likely it is to be associated with ultras plaque and cerebrovascular symptoms. Heterogeneity of the plaque was more positively correlated with symptoms than with any degree of stenosis. These findings suggest that plaque heterogeneity should be considered in selecting patients for carotid endarterectomy. (*Stroke*. 2002;33:1772-1775.)

Vascular Diagnostics

Carotid Doppler Velocity Measurements and Anatomic Stenosis: Correlation Is Futile

Vascular and Endovascular Surgery 46(6) 466-474 © The Author(s) 2012 Reprints and permission: sagepub.com/journalsPermissions.nav DOI: 10.1177/1538574412452159 http://ves.sagepub.com SAGE

Kirk W. Beach, PhD, MD[1,2], Daniel F. Leotta, PhD[1,3], and R. Eugene Zierler, MD[1,2]

Abstract

Background: Duplex ultrasound with Doppler velocimetry is widely used to evaluate the presence and severity of internal carotid artery stenosis; however, a variety of velocity criteria are currently being applied to classify stenosis severity. The

of all 3 velocity parameters was significantly lower in stented arteries than in native arteries. Conclusion: Although Doppler velocity criteria have been successfully used to classify the severity of stenosis in both native and stented carotid arteries, the relationship to angiographic stenosis contains significant variability. This analysis of published studies suggests that further refinements in Doppler velocity criteria will not lead to improved correlation with carotid stenosis as demonstrated by angiography. © The Author(s) 2012

3 velocity parameters and angiographic percent stenosis. The optimal peak systolic velocity thresholds for stenosis in stented carotid arteries were higher than those for native carotid arteries. Within each category of stenosis, the variability of all 3 velocity parameters was significantly lower in stented arteries than in native arteries. Conclusion: Although Doppler velocity criteria have been successfully used to classify the severity of stenosis in both native and stented carotid arteries, the relationship to angiographic stenosis contains significant variability. This analysis of published studies suggests that further refinements in Doppler velocity criteria will not lead to improved correlation with carotid stenosis as demonstrated by angiography.

13

From Correlation is Futile and ARIC to Carotid Artery Wall Imaging and RADS



Carotid Intima-Media Thickness and Presence or Absence of Plaque Improves Prediction of Coronary Heart Disease Risk

The ARIC (Atherosclerosis Risk In Communities) Study

Vijay Nambi, MD,*† Lloyd Chambless, PrtD,‡ Aaron R. Folsom, MD,§ Man Hu, MS,‡ Yijuan Hu, BS,‡ Tom Mosley, PrtD,‖ Kelly Volcik, PrtD,¶ Eric Boerwinkle, PrtD,¶ Christie M. Ballantyne, MD*†

Houston, Texas; Chapel Hill, North Carolina; Minneapolis, Minnesota; and Jackson, Mississippi

Conclusions Adding plaque and CIMT to TRF improves CHD risk prediction in the ARIC (Atherosclerosis Risk In Communities) study. (J Am Coll Cardiol 2010;55:1600–7) © 2010 by the American College of Cardiology Foundation

Review Article on Carotid Artery Stenosis and Stroke: Prevention and Treatment Part I

Asymptomatic Carotid Stenosis and Risk of Stroke (ACSRS) study: what have we learned from it?

Kosmas I. Paraskevas[1], Andrew N. Nicolaides[2], Stavros K. Kakkos[3]

Abstract: The Asymptomatic Carotid Stenosis and Risk of Stroke (ACSRS) study is the largest natural history study on patients with 50–99% asymptomatic carotid stenosis (ACS). It included 1,121 ACS individuals with a follow-up between 6 and 96 months (mean: 48 months). During the last 15 years, several important ACSRS substudies have been published that have contributed significantly to the optimal management of ACS patients. These studies have demonstrated that specific baseline clinical characteristics and ultrasonic plaque features after image normalization (namely carotid plaque type, gray scale median, carotid plaque area, juxtaluminal black area without a visible echogenic cup, discrete white areas in an echolucent part of a plaque, silent embolic infarcts on brain computed tomography scans, a history of contralateral transient ischemic attacks/strokes) can independently predict future ipsilateral cerebrovascular events. The ACSRS study provided proof that by use of a computer program to normalize plaque images and extract plaque texture features, a combination of features can stratify patients into various categories depending on their stroke risk. The present review will discuss the various reported predictors of future ipsilateral cerebrovascular events and how these characteristics can be used to calculate individual stroke risk.

© Annals of Translational Medicine. All rights reserved.
Ann Transl Med 2020;8(19):1271 | http://dx.doi.org/10.21037/atm.2020.02.156

14

© Copyright. Society of Diagnostic Medical Sonography. All Rights Reserved.

Ultrasound and carotid bifurcation atherosclerosis

Atherosclerotic plaques at the carotid bifurcation are a common problem in individuals over 50 years of age in developed countries. Although most of these plaques produce no ill effects, a small minority produce embolic strokes.



15

"Advances in medical therapy have greatly diminished cardiovascular risk including stroke risk of asymptomatic carotid plaques, raising the real possibility that few if any asymptomatic plaques have to be treated invasively. Of course, this like other future advances in the management of carotid plaque disease will have to be proven by appropriate randomized controlled trials. This volume will be an essential primer, a must read, for those who are designing and interpreting such trials, and for all others interested in the prevention of cardiovascular atherosclerotic disease in general as well as the management of carotid bifurcation plaques."

—Frank J. Veith

16

© Copyright. Society of Diagnostic Medical Sonography. All Rights Reserved.

A Bumpy Road to Risk Prediction—Carotid Plaque Assessment Debated

What's the goal? Is carotid disease imaging for treatment and stroke prevention broadly speaking, or is it a filter to determine the type of surgical revascularization?

17

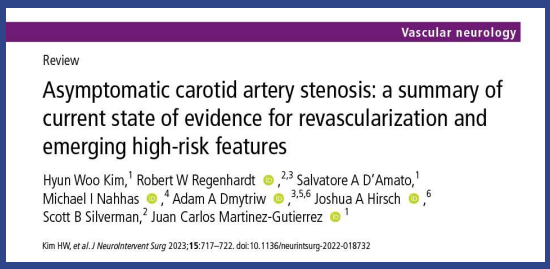
Vascular neurology

Review

Asymptomatic carotid artery stenosis: a summary of current state of evidence for revascularization and emerging high-risk features

Hyun Woo Kim,[1] Robert W Regenhardt,[2,3] Salvatore A D'Amato,[1] Michael I Nahhas,[4] Adam A Dmytriw,[3,5,6] Joshua A Hirsch,[6] Scott B Silverman,[2] Juan Carlos Martinez-Gutierrez[1]

Kim HW, *et al. J NeuroIntervent Surg* 2023;**15**:717–722. doi:10.1136/neurintsurg-2022-018732

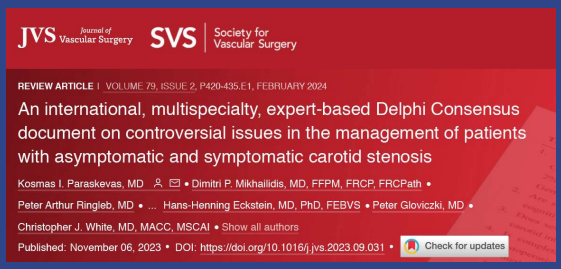
JVS Journal of Vascular Surgery | SVS Society for Vascular Surgery

REVIEW ARTICLE | VOLUME 79, ISSUE 2, P420-435.E1, FEBRUARY 2024

An international, multispecialty, expert-based Delphi Consensus document on controversial issues in the management of patients with asymptomatic and symptomatic carotid stenosis

Kosmas I. Paraskevas, MD • Dimitri P. Mikhailidis, MD, FFPM, FRCP, FRCPath • Peter Arthur Ringleb, MD • ... Hans-Henning Eckstein, MD, PhD, FEBVS • Peter Gloviczki, MD • Christopher J. White, MD, MACC, MSCAI • Show all authors

Published: November 06, 2023 • DOI: https://doi.org/10.1016/j.jvs.2023.09.031 • Check for updates

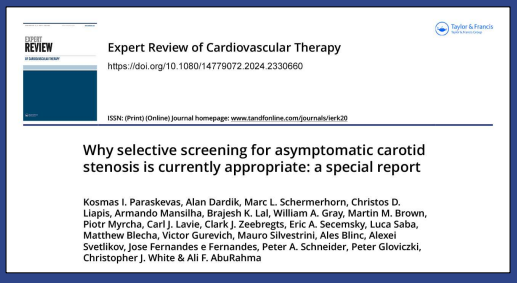
Expert Review of Cardiovascular Therapy

https://doi.org/10.1080/14779072.2024.2330660

ISSN: (Print) (Online) Journal homepage: www.tandfonline.com/journals/ierk20

Why selective screening for asymptomatic carotid stenosis is currently appropriate: a special report

Kosmas I. Paraskevas, Alan Dardik, Marc L. Schermerhorn, Christos D. Liapis, Armando Mansilha, Brajesh K. Lal, William A. Gray, Martin M. Brown, Piotr Myrcha, Carl J. Lavie, Clark J. Zeebregts, Eric A. Secemsky, Luca Saba, Matthew Blecha, Victor Gurevich, Mauro Silvestrini, Ales Blinc, Alexei Svetlikov, Jose Fernandes e Fernandes, Peter A. Schneider, Peter Gloviczki, Christopher J. White & Ali F. AbuRahma

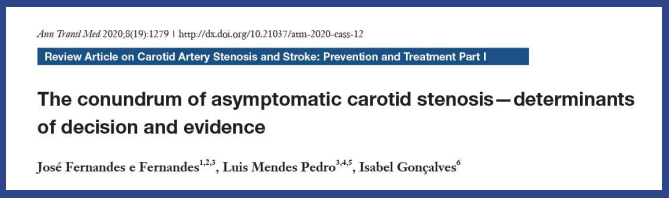
Ann Transl Med 2020;8(19):1279 | http://dx.doi.org/10.21037/atm-2020-cass-12

Review Article on Carotid Artery Stenosis and Stroke: Prevention and Treatment Part I

The conundrum of asymptomatic carotid stenosis—determinants of decision and evidence

José Fernandes e Fernandes[1,2,3], Luis Mendes Pedro[3,4,5], Isabel Gonçalves[6]

18

© Copyright. Society of Diagnostic Medical Sonography. All Rights Reserved.

Carotid Plaque-RADS
A Novel Stroke Risk Classification System

ABSTRACT

BACKGROUND Carotid artery atherosclerosis is highly prevalent in the general population and is a well-established risk factor for acute ischemic stroke. Although the morphological characteristics of vulnerable plaques are well recognized, there is a lack of consensus in reporting and interpreting carotid plaque features.

OBJECTIVES The aim of this document is to establish a consistent and comprehensive approach for imaging and reporting carotid plaque by introducing the Plaque-Reporting and Data System (RADS) score.

METHODS A panel of experts recognized the necessity to develop a classification system for carotid plaque and its defining characteristics. Using a multimodality analysis approach, the Plaque-RADS categories were established through consensus, drawing on existing published reports.

RESULTS The authors present a universal classification that is applicable to both researchers and clinicians. The Plaque-RADS score offers a morphological assessment in addition to the prevailing quantitative parameter of "stenosis." The Plaque-RADS score spans from grade 1 (indicating complete absence of plaque) to grade 4 (representing complicated plaque). Accompanying visual examples are included to facilitate a clear understanding of the Plaque-RADS categories.

CONCLUSIONS Plaque-RADS is a standardized and reliable system of reporting carotid plaque composition and morphology via different imaging modalities, such as ultrasound, computed tomography, and magnetic resonance imaging. This scoring system has the potential to help in the precise identification of patients who may benefit from exclusive medical intervention and those who require alternative treatments, thereby enhancing patient care. A standardized lexicon and structured reporting promise to enhance communication between radiologists, referring clinicians, and scientists. (J Am Coll Cardiol Img 2023;■:■–■) © 2023 by the American College of Cardiology Foundation.

- Establishes a consistent and comprehensive approach for imaging and reporting carotid plaque
- The Plaque-RADS score spans from Grade 1 (no plaque) to Grade 4 (complicated plaque)

Carotid Plaque-RADS
A Novel Stroke Risk Classification System

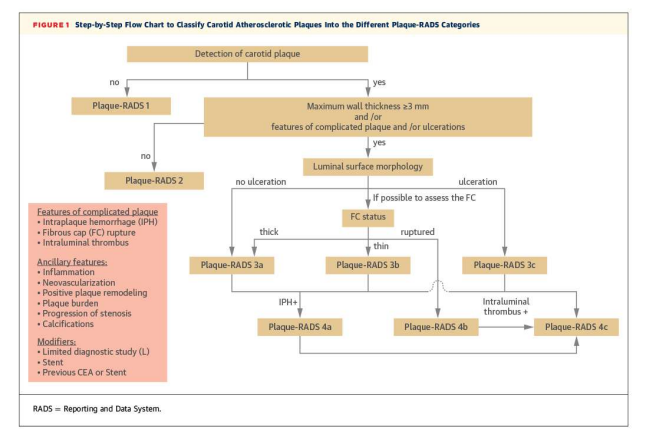

© Copyright. Society of Diagnostic Medical Sonography. All Rights Reserved.

We have known about these vulnerable carotid plaques for decades…

A prototype plaque classification scheme discussed in 2019*

*this is from Europe—we don't have vascular ultrasound microbubbles routinely available yet.

21

- Intraplaque hemorrhage
- LRNC
- Neovascularization
- Carotid plaque thickness
- Surface morphology
- Carotid plaque volume

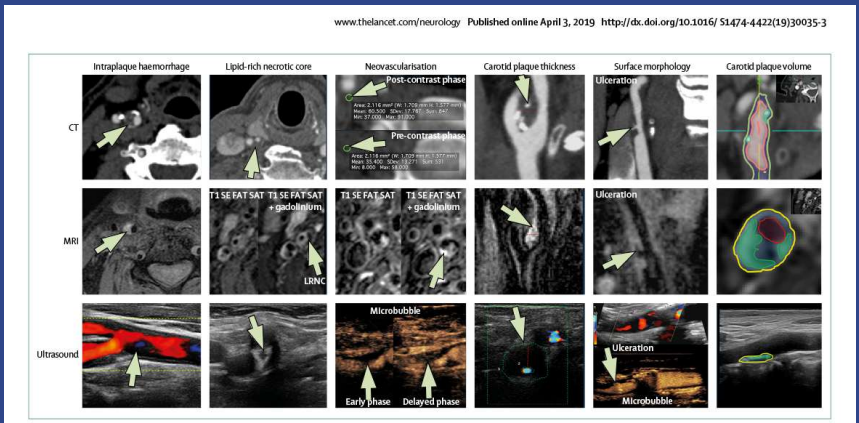

Figure 1: **Imaging features of plaque vulnerability**
Six features of carotid plaque vulnerability are shown in columns, and images were obtained by CT (upper row), MRI on a 3 Tesla scanner (middle row), and ultrasound (lower row). On ultrasound images, red colour indicates orthograde flow and blue colour shows retrograde flow. In the first column (intraplaque haemorrhage) and second column (LRNC), the arrow points to the feature detected. In the third column (neovascularisation), the arrows and green circles in the pre-contrast and post-contrast CT images (upper row) show how Hounsfield units increase after administration of contrast material. Similarly, in the MRI panel (middle row), after gadolinium contrast, the plaque (arrow) shows a significant increase in signal intensity because of enhancement of the plaque. The ultrasound images (lower row) show significant enhancement in the plaque (arrow) because of the presence of microbubble. Early phase is after 30 s and delayed phase is after 120 s. In the fourth column (carotid plaque thickness), the arrows indicate the plaque and the red dotted lines show the thickness of the plaque. The green dotted line in the ultrasound image represents the outer lumen of the plaque. In the fifth column (surface morphology), the arrows in all images show the ulcer. In the ultrasound images, the two panels show the difference in sensitivity using conventional B-mode colour Doppler and microbubble injection. In this case, the ulcer is visible only with the microbubble technique. The sixth column shows carotid plaque volume analysis and tissue segmentation. The red line shows the inner boundaries of the carotid plaque wall; the yellow line shows the outer boundary of the carotid plaque wall; the green colour represents the fatty component; the blue colour indicates the mixed component. IPH=intraplaque haemorrhage. LRNC=lipid-rich necrotic core. T1 SE FAT SAT=T1 spin-echo fat saturation MRI sequence.

22

© Copyright. Society of Diagnostic Medical Sonography. All Rights Reserved.

Carotid Plaque-RADS
A Novel Stroke Risk Classification System

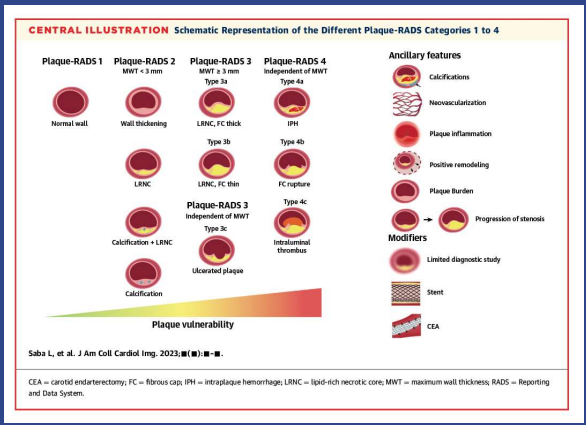

23

Carotid Plaque-RADS
A Novel Stroke Risk Classification System

TABLE 1 Summary of Plaque-RADS Categories Based on Imaging Findings and the Attributable Risk of Developing Symptoms

Plaque-RADS Score	Attributable Risk of Ipsilateral Cerebrovascular Events	Imaging Findings
1	Absent	Normal vessel wall
2	Low	MWT <3 mm
3	Moderate	MWT ≥3 mm or Healed ulcerated plaque
3a	Moderate	LRNC with intact thick FC (MWT ≥3 mm)
3b	Moderate	LRNC with thin FC (MWT ≥3 mm)
3c	Moderate	Healed ulcerated plaque
4	High	Complicated plaque (irrespective of MWT)
4a	High	IPH
4b	High	Ruptured FC
4c	High	Intraluminal thrombus
Ancillary features	Inflammation, neovascularization, positive plaque remodeling, plaque progression, calcifications	
Modifiers	Limited diagnostic study ("L"), presence of a stent ("Stent"), previous carotid endarterectomy ("CEA")	

FC = fibrous cap; IPH = intraplaque hemorrhage; LRNC = lipid-rich necrotic core;.
MWT = maximum wall thickness; RADS = reporting and data system.

REPORTING THE PLAQUE-RADS SCORE

For the structured reporting of a Plaque-RADS score, we recommend using the following syntax …
side of carotid:
stenosis degree/imaging modality
Plaque-RADS score/MWT/ancillary features/modifiers.

24

© Copyright. Society of Diagnostic Medical Sonography. All Rights Reserved.

Carotid Plaque-RADS
A Novel Stroke Risk Classification System

FIGURE 2 Plaque-RADS 1

Regular vessel wall

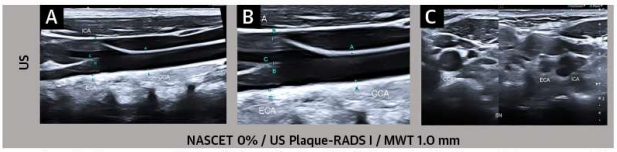

NASCET 0% / US Plaque-RADS I / MWT 1.0 mm

Ultrasound (US) shows regular wall in the common carotid artery (CCA) and bifurcation. (A to C) The vessel wall in ultrasound is homogenous and thin.

FIGURE 3 Plaque-RADS 2

Eccentric wall thickening
MWT < 3mm

Possible features:
- Small calcifications
- Small LRNC

Absence of features of complicated plaque

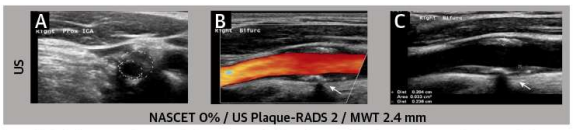

NASCET 0% / US Plaque-RADS 2 / MWT 2.4 mm

US shows eccentric wall thickening with speckled calcifications and acoustic shadowing (arrows). (A) Axial image. (B) Color Doppler image. (C) Longitudinal image.

25

Carotid Plaque-RADS
A Novel Stroke Risk Classification System

FIGURE 4 Plaque-RADS 3a

MWT ≥ 3mm

Moderate to large LRNC
Thick or indistinguishable FC

Possible features:
- Calcification

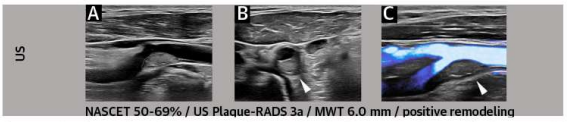

NASCET 50-69% / US Plaque-RADS 3a / MWT 6.0 mm / positive remodeling

US shows large plaque of the carotid bifurcation with uniform isoechoic echogenicity on B-mode imaging (arrowhead) consistent with LRNC and thick FC. Longitudinal (A) and transverse (B) views. (C) Microflow imaging.

FIGURE 5 Plaque-RADS 3b

MWT ≥ 3mm

Moderate to large LRNC
Thin FC

Possible features:
- Calcification

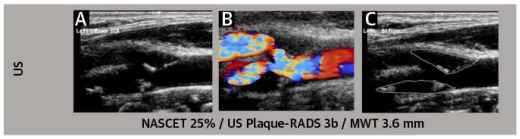

NASCET 25% / US Plaque-RADS 3b / MWT 3.6 mm

US shows complex plaque with presence of juxtaluminal black areas (JBAs) in both the anterior and posterior component of the plaque with 2 discrete white areas (DWAs) in the far wall component of the plaque consistent with a large LRNC or IPH at the origin of the left carotid bifurcation. Large sections of the plaque outline do not have a visible (ie, thin) FC. (A, C) B-mode images. (B) Color flow. (C) Outline of the anterior and posterior plaque components.

26

© Copyright. Society of Diagnostic Medical Sonography. All Rights Reserved.

Carotid Plaque-RADS
A Novel Stroke Risk Classification System

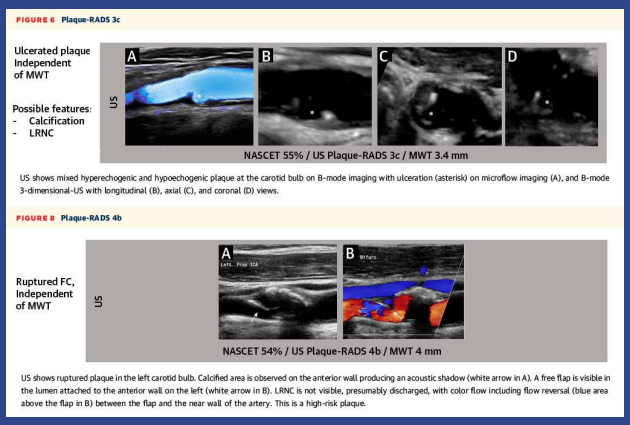

27

Better than just saying “nasty plaque”

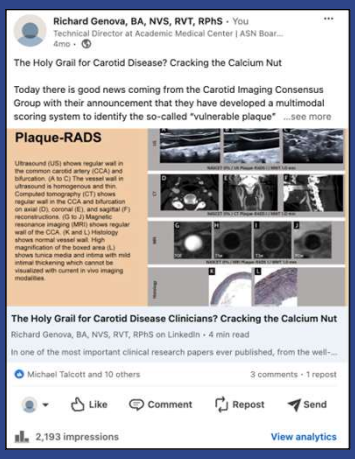



28

© Copyright. Society of Diagnostic Medical Sonography. All Rights Reserved.

Carotid Plaque-RADS

Ultrasound Teaching Deck — figures organized by RADS category

Schematics are original line drawings (free to reuse). No copyrighted journal figures are embedded — only citations and links to open-access sources.

29

Quick reference — category to figure

Cat.	Definition	Key US finding	Source figure
1	Normal wall, no plaque	Homogenous, thin wall	Saba Fig. 2
2	MWT < 3 mm	Eccentric thickening; speckled calcification, shadowing	Saba Fig. 3
3a	MWT ≥ 3 mm, LRNC + thick cap	Hyperechogenic intact cap	Saba paper / editorial
3b	MWT ≥ 3 mm, LRNC + thin cap	Juxtaluminal black area (JBA)	Saba paper / editorial
3c	Ulcerated plaque	Surface cavity / recess (CEUS)	Saba paper / editorial
4a	Intraplaque hemorrhage	JBA + discrete white areas; echolucent core	Saba Fig. 4; Gao 2026
4b	Fibrous cap rupture	Disrupted/absent cap outline (MRI confirms)	Saba Fig. 4
4c	Intraluminal thrombus	Echolucent mobile luminal material (color flow)	Saba paper

US is a gatekeeper (categories 1–2 and the 3-mm cutoff); MRI is most sensitive for IPH and cap rupture (category 4). Source: Saba L, et al. JACC Cardiovasc Imaging 2024;17(1):62–75.

30

© Copyright. Society of Diagnostic Medical Sonography. All Rights Reserved.

Plaque-RADS 1
Normal wall — no plaque

Risk: None

Original schematic



Published ultrasound figure — embedded



Sonographic appearance: Regular wall in the CCA and bifurcation; homogenous, thin vessel wall. Matched CT, MRI, and histology confirm a normal wall. AHA lesion-type I/II.

Figure / panel: Saba et al. 2024, Figure 2 (US panels A–C) ScienceDirect — Figure 2

RADS 1: A bigger picture

Claude thought this was an example of RADS 1 because the stent is showing thin echogenic lines.

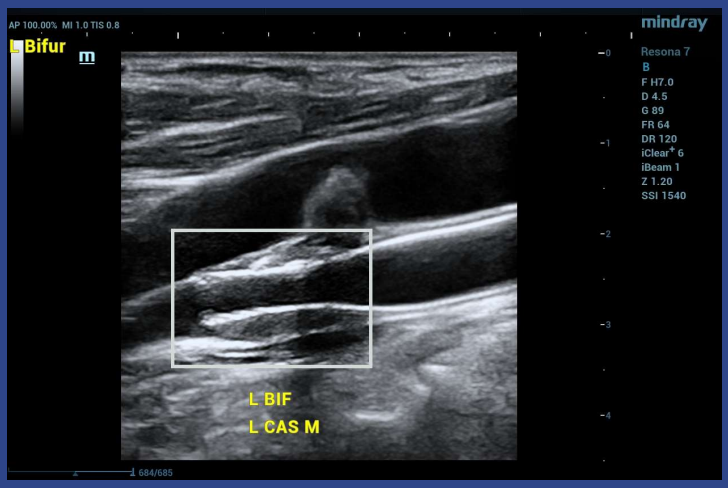

© Copyright. Society of Diagnostic Medical Sonography. All Rights Reserved.

RADS 1: A bigger picture

Claude thought this was an example of RADS 1 — even though the image clearly shows plaque and wall thickness being measured!

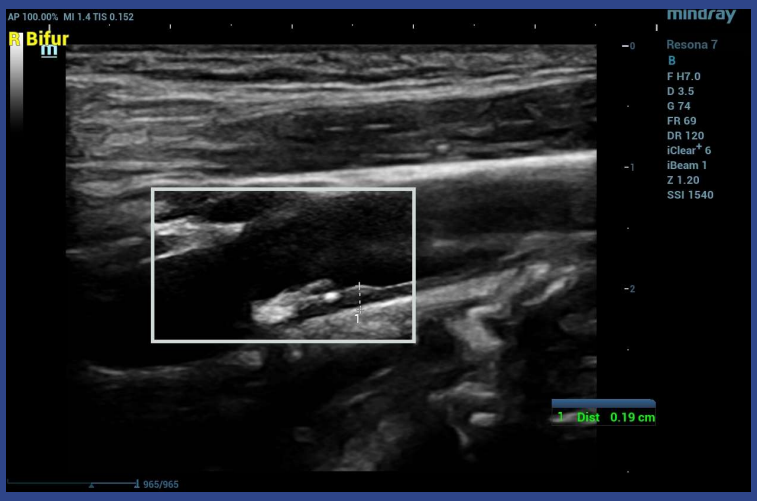

33

RADS 1: A bigger picture

Claude thought this was an example of RADS 1 — yes, there are thin echogenic lines, but there is wall thickening.

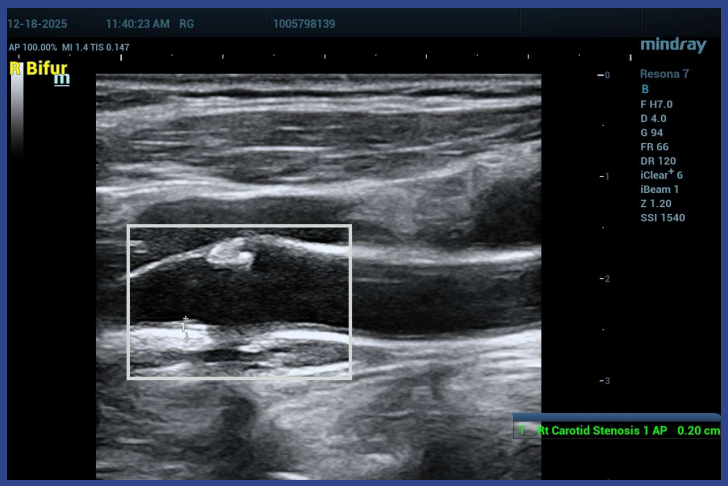

34

© Copyright. Society of Diagnostic Medical Sonography. All Rights Reserved.

Plaque-RADS 2
Wall thickening, MWT < 3 mm

Risk: Low

Original schematic



Published ultrasound figure — embedded

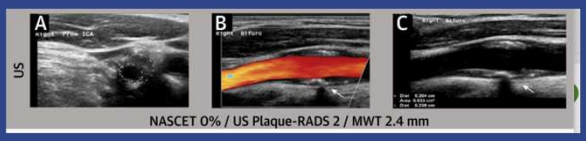

Sonographic appearance: Eccentric wall thickening with speckled calcifications and acoustic shadowing (arrows). No complicated features. Case series: Frontiers Cardiovasc Med 2025 (solitary RADS-2 plaque).

Figure / panel: Saba et al. 2024, Figure 3 ScienceDirect — Figure 3

RADS 2: Here we go, wall thickening & calcification

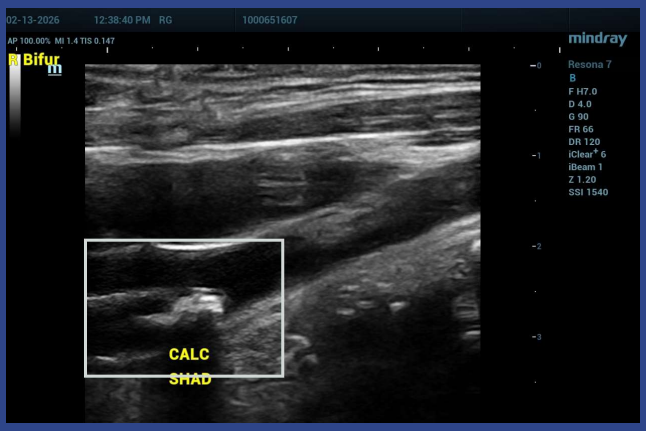

- Discrete calcification
- Sharp posterior shadow (labeled CALC SHAD)

© Copyright. Society of Diagnostic Medical Sonography. All Rights Reserved.

RADS 2: Here we go, wall thickening & calcification

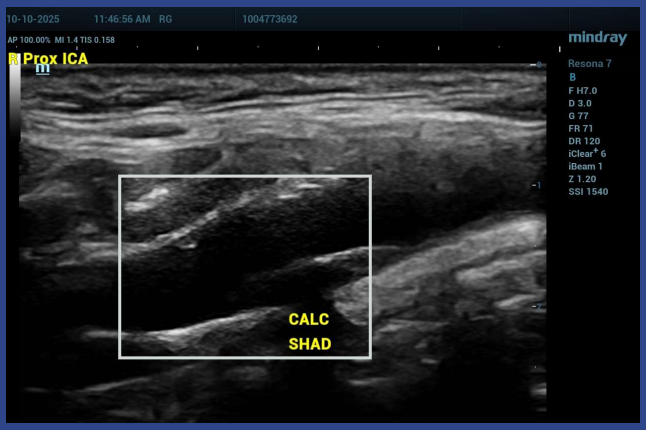

- Discrete calcification
- Sharp posterior shadow (labeled CALC SHAD)
- See figure 2C (Saba, JACC)

37

Plaque-RADS 3a
MWT ≥ 3 mm — LRNC + thick fibrous cap

Risk: Intermediate

Original schematic



Published ultrasound figure — embedded



Figure / panel: Saba et al. 2024 + JACC editorial (3a description) JACC editorial — multimodality classification

38

© Copyright. Society of Diagnostic Medical Sonography. All Rights Reserved.

RADS 3a: Hope it has a good cap



- Heterogeneous plaque
- Hyperechoic surface component over darker core

39

Plaque-RADS 3b
MWT ≥ 3 mm — LRNC + thin fibrous cap

Risk: Intermediate

Original schematic



Published ultrasound figure — embedded

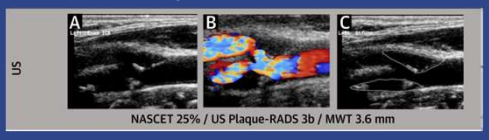

Sonographic appearance: A thin cap may appear as a juxtaluminal black area (JBA) at the lumen, with no visible bright cap line. Higher risk than 3a.
Figure / panel: Saba et al. 2024 + JACC editorial (3b description) JACC editorial — multimodality classification

40

© Copyright. Society of Diagnostic Medical Sonography. All Rights Reserved.

RADS 3b: Not a good cap

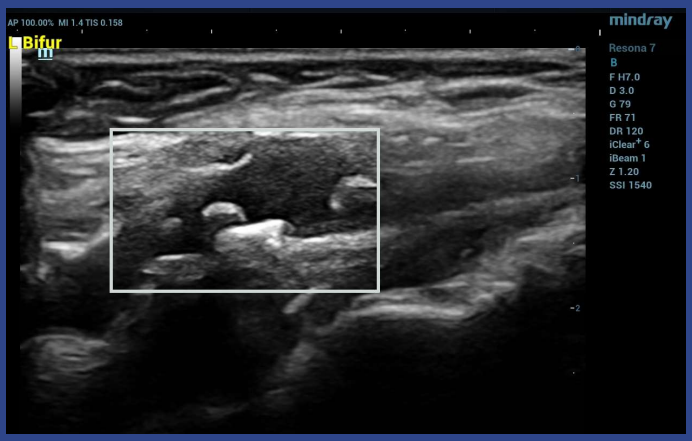

- Large echolucent plaque area reaching lumen
- No discrete bright cap seen

41

RADS 3b: Not a good cap

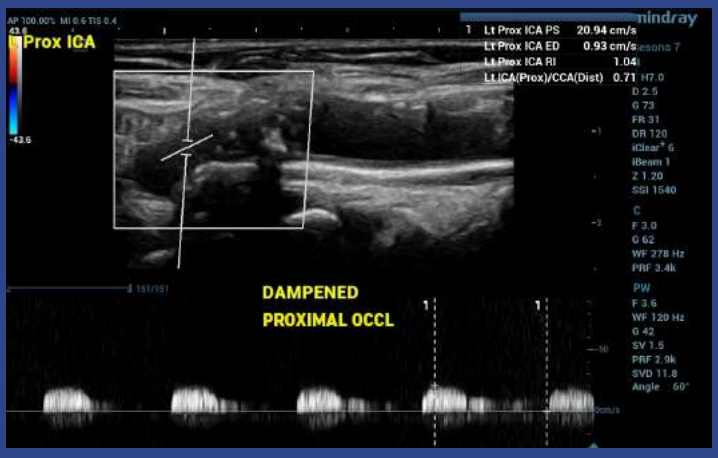

- Surprise!
- Prox ICA shows proximal occlusion
- Hemodynamics still matter

42

© Copyright. Society of Diagnostic Medical Sonography. All Rights Reserved.

RADS 3b: Left ECA demonstrates abnormal, non-resistive flow pattern

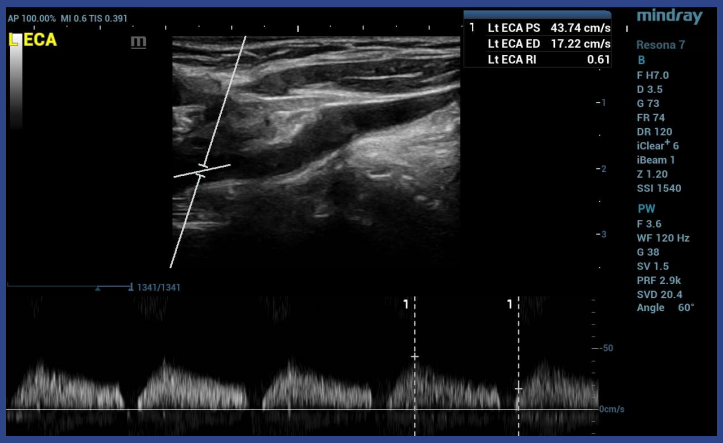

- Looks more like an ICA
- TCD revealed collateral flow via reversed OA

43

Plaque-RADS 3c
Ulcerated plaque (any wall thickness)

Risk: High

Original schematic



Published ultrasound figure — embedded

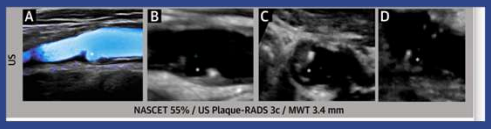

Sonographic appearance: Surface cavity / recess in the plaque. CT and MRI delineate the lumen best, but contrast-enhanced US (CEUS) can show the ulcer recess.

Figure / panel: Saba et al. 2024 (3c) — surface cavity ScienceDirect — main paper

44

© Copyright. Society of Diagnostic Medical Sonography. All Rights Reserved.

RADS 3c: A worrisome category

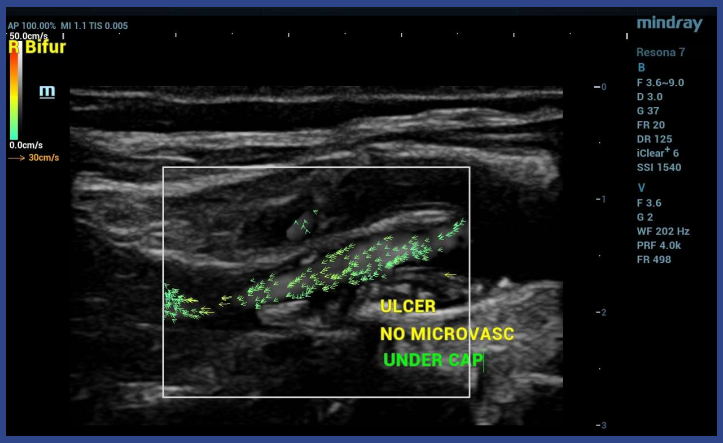

- Surface irregularity consistent with ulceration
- Vector Flow Imaging

45

RADS 3c: A worrisome category

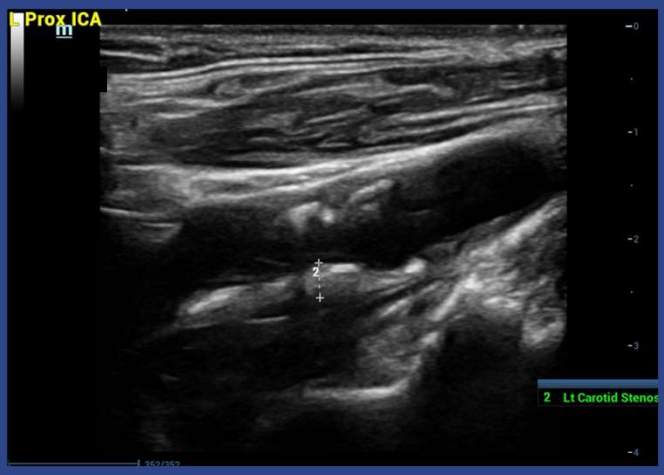

- At first glance, looks like there is a good hyperechoic cap
- Example of ulcerated carotid plaque in the near field

46

© Copyright. Society of Diagnostic Medical Sonography. All Rights Reserved.

RADS 3c: A worrisome category

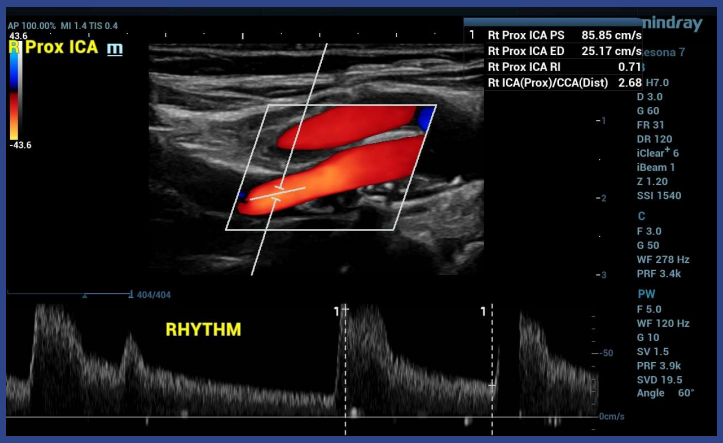

- Cardiac rhythm issue discovered incidentally

47

Plaque-RADS 4a
Intraplaque hemorrhage (IPH)

Risk: Highest

Original schematic



Published ultrasound figure — embedded

Sonographic appearance: Complex plaque: large echolucent core, juxtaluminal black areas, and discrete white areas. Confirm IPH on MRI (most sensitive modality).

Figure / panel: Saba et al. 2024, Figure 4 (US panels A–C); Gao 2026 (CEUS) Gao 2026 — US features predicting IPH

48

© Copyright. Society of Diagnostic Medical Sonography. All Rights Reserved.

Plaque-RADS 4b
Fibrous cap rupture

Risk: Highest

Original schematic



Published ultrasound figure — embedded

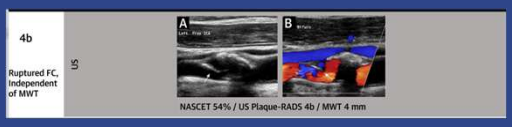

Sonographic appearance: Disrupted / discontinuous fibrous cap. US may show an interrupted bright cap line; MRI confirms rupture. Canonical figure pairs US + MRI + histology.

Figure / panel: Saba et al. 2024, Figure 4 (multimodal) ScienceDirect — Figure 4

Plaque-RADS 4c
Intraluminal thrombus

Risk: Highest

Original schematic

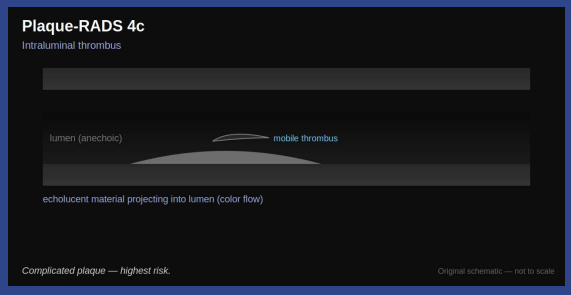

Published ultrasound figure — embedded

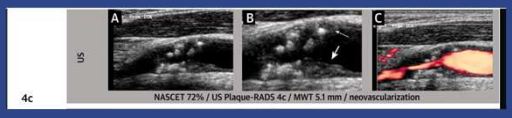

Sonographic appearance: Echolucent material projecting into the lumen, often mobile on color-flow imaging. Complicated plaque — highest stroke risk.

Figure / panel: Saba et al. 2024 (4c description) ScienceDirect — main paper

© Copyright. Society of Diagnostic Medical Sonography. All Rights Reserved.

RADS 4c: Some examples of occlusions (usually some speckles)

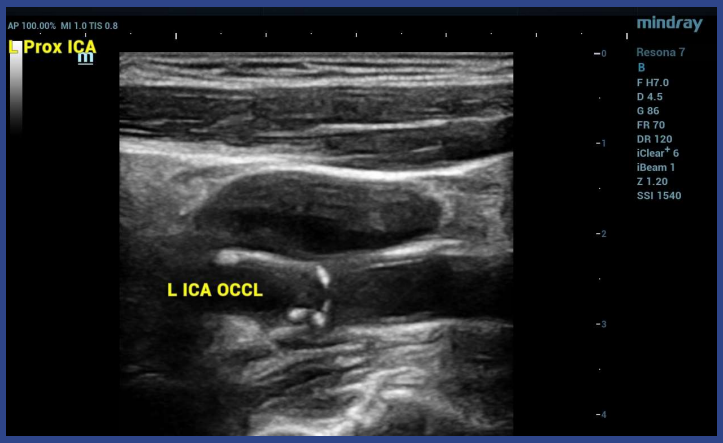

- Hypoechoic material filling ICA origin
- Excellent anatomic clarity

51

RADS 4c: More occlusions

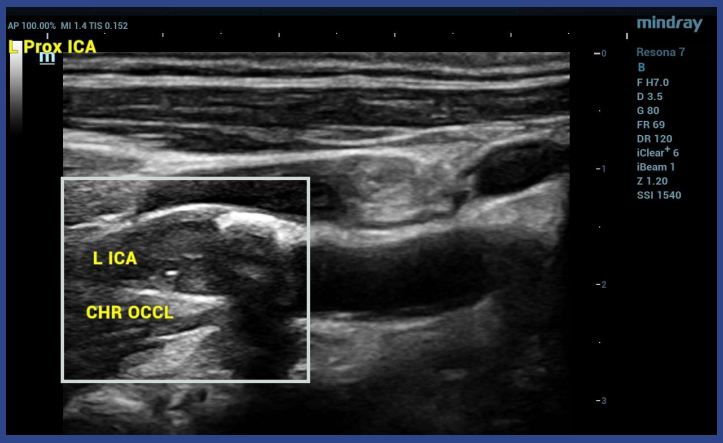

- Hypoechoic material filling ICA origin
- Excellent anatomic clarity

52

© Copyright. Society of Diagnostic Medical Sonography. All Rights Reserved.

RADS 4c: Garden variety occlusions (usually some speckles)

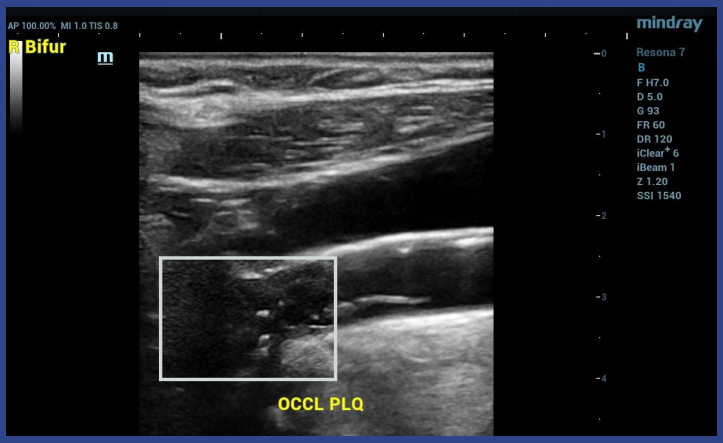

- Hypoechoic material filling ICA origin
- Excellent anatomic clarity

53

Validation studies with 2D clinical ultrasound applications

The predictive value of Plaque-RADS classification in two-dimensional carotid ultrasound for stroke risk stratification

Yuanfu Ouyang[1]^, Guorong Lyu[2]^, Shaomin Huang[1], Yanming Lin[1], Xiaoyan Tong[1]

Methods: In total, 2,023 patients undergoing carotid ultrasound were enrolled in this prospective cohort study. Stroke risk was stratified using Plaque-RADS categories 1–4. Based on clinical diagnosis, the patients were categorized into stroke and non-stroke groups. The associations between the Plaque-RADS categories and stroke prevalence/recurrence were analyzed by multivariate logistic regression, adjusted for gender, age, and diabetes mellitus. A linear trend test was performed across the ordinal categories.

Conclusions: The Plaque-RADS classification, as applied in 2D carotid ultrasound, effectively stratifies both initial and short-term recurrent stroke risk, supporting its integration into routine clinical practice for risk assessment.

54

© Copyright. Society of Diagnostic Medical Sonography. All Rights Reserved.

Examples of Plaque-RADS 1-4

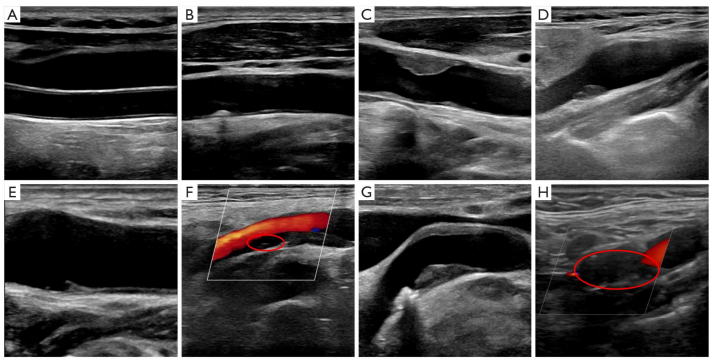

Figure 1 Plaque-RADS ultrasound classification diagram (A-H correspond to the characteristics of 1–4 categories of plaques). (A) Plaque-RADS 1 (no plaque); (B) Plaque-RADS 2 (thickness <3 mm); (C) Plaque-RADS 3a (thickness ≥3 mm, thick fibrous cap); (D) Plaque-RADS 3b (thickness ≥3 mm, thin fibrous cap); (E) Plaque-RADS 3c (ulcer plaque); (F) Plaque-RADS 4a (the areas indicated by red circle represent intraplaque hemorrhage); (G) Plaque-RADS 4b (ruptured fibrous cap); (H) Plaque-RADS 4c (the areas indicated by red circle represent intraluminal thrombus). Plaque-RADS, Plaque Reporting and Data System.

55

Risk stratification studies applying Carotid Plaque-RADS have started

JACC: CARDIOVASCULAR IMAGING
© 2024 BY THE AMERICAN COLLEGE OF CARDIOLOGY FOUNDATION
PUBLISHED BY ELSEVIER

ORIGINAL RESEARCH

Incremental Prognostic Value of Carotid Plaque–RADS Over Stenosis Degree in Relation to Stroke Risk

Zhe Huang, MD, Xue-Qing Cheng, MD, Rui-Rui Lu, MD, Xiao-Jun Bi, MD, PhD, Ya-Ni Liu, MD, PhD, You-Bin Deng, MD, PhD

OBJECTIVES This study aimed to determine the incremental prognostic value of Carotid Plaque-RADS over stenosis degree for stroke risk.

METHODS A retrospective analysis was performed on data from January 2010 to December 2021, involving subjects who underwent magnetic resonance imaging, computed tomography angiography, and ultrasound evaluations of the carotid artery. Disease-free survival (DFS) and recurrence-free survival (RFS) rates were compared across different stenosis degrees, Carotid Plaque-RADS categories, and their combination, using the Kaplan-Meier and net reclassification improvement formula.

CONCLUSIONS Carotid Plaque-RADS significantly improves stroke risk stratification over traditional stenosis grading, especially in mild/moderate stenosis cases. (JACC Cardiovasc Imaging. 2024;■:■–■) © 2024 by the American College of Cardiology Foundation.

56

© Copyright. Society of Diagnostic Medical Sonography. All Rights Reserved.

New and promising 2D clinical ultrasound applications

Evaluating plaque morphology with microvascular imaging, elastography, and vector flow imaging

57

Available now

- Point shear wave elastography (SWE)
- Microvascular ultrasound imaging (MUI)
- Contrast enhanced ultrasound (CEUS)*
- Ultrafast vector flow imaging (VFI)**

*Limited in the US for carotid by the FDA
** Not all major ultrasound vendors yet

58

© Copyright. Society of Diagnostic Medical Sonography. All Rights Reserved.

Microvascular ultrasound and Plaque-RADS

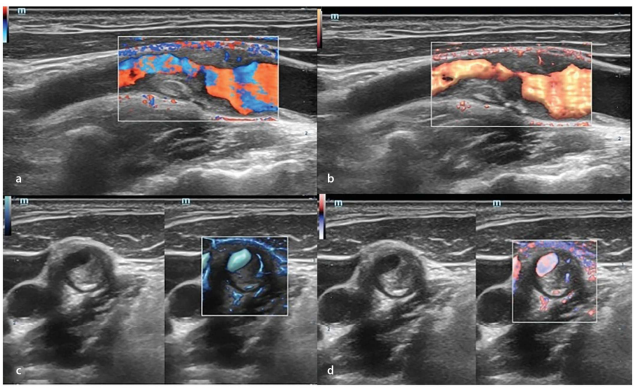

Figure 11. Microvascular ultrasound (US) imaging findings in complex plaques in the carotid bulb and proximal internal carotid artery causing high-grade carotid stenosis. Microvessel US imaging with different hues in longitudinal **(a, b)** and axial views **(c, d)** reveal tiny vessels at the anteriorly located plaque, representing neoangiogenesis.



Recent advances in vascular ultrasound imaging technology and their clinical implications

Oktar SÖ, Cerit MN, Şendur HN, Kılıç ACK. Recent advances in vascular ultrasound imaging technology and their clinical implications. Diagn Interv Radiol. 2026 Jan 2;32(1):47-56. doi: 10.4274/dir.2025.253448. Epub 2025 Aug 27.

SWE and Vector Flow Imaging

- Microvessel imaging also has potential for evaluating intraplaque neovascularization, a key factor in carotid plaque instability.
- The presence or progression of this neovascularization significantly affects the outcomes of vulnerable plaques, making its detection clinically important.

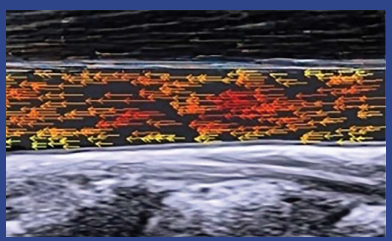

10.4274/dir.2025.253448. Epub 2025 Aug 27.

© Copyright. Society of Diagnostic Medical Sonography. All Rights Reserved.

SWE and Vector Flow Imaging

Shear wave elastography (SWE) imaging of plaques with different elastic properties: (a) SWE image displays a blue color at a hypoechoic plaque suggesting a soft texture; (b) B-mode image shows a mixed echogenicity of the plaque with hyperechoic areas suggesting calcifications. The SWE image shows a mixture of blue, red, and yellow colors, suggesting that the plaque contains stiff areas.

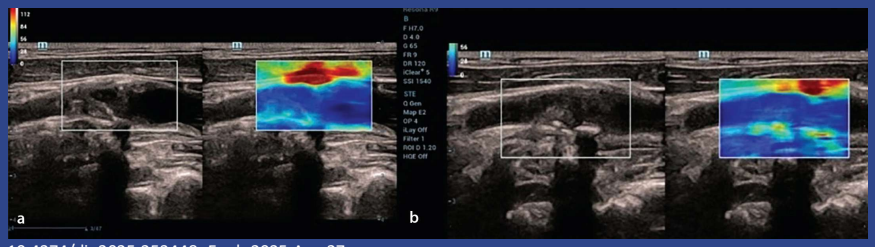

10.4274/dir.2025.253448. Epub 2025 Aug 27.

61

ULM Neovascular Imaging

Grading intraplaque neovascularization with SMI, CEUS, and ultrasound localization microscopy

Neovascularization is the vascular engine behind Plaque-RADS 3b–4a: microvessels feed plaque growth and set up intraplaque hemorrhage. This module covers how SMI and CEUS grade that neovascularity, and how super-resolution ULM imaging is pushing resolution down to the level of individual microvessels.

This pairs with Plaque-RADS 3b and 4a. One figure in this module is reproduced under CC BY 4.0 (see citation on that slide).

62

© Copyright. Society of Diagnostic Medical Sonography. All Rights Reserved.

Future Microvascular Imaging Ultrasound Localization Microscopy

Correlates: 3b–4a

Original schematic

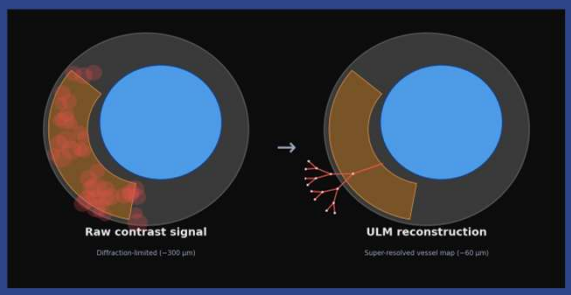

Published ultrasound figure — embedded

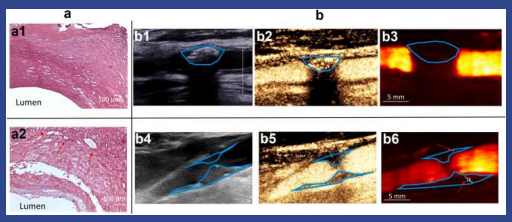

Sonographic appearance: ULM localizes individual microbubbles across many frames to map microvessels at ~60 µm resolution — far beyond CEUS's ~300 µm. Validated against histology.

Figure / panel: Leroy et al. 2024, Figure 4 (histology + grayscale/PD/CEUS, 2 patients) eBioMedicine 2024 — open access, CC BY 4.0

63

Carotid Plaque Evaluation Using Risk Stratification and Ultrasound Imaging

Thank you for participating!

Thanks to Dr. Babak Navi, MD, RPNI; Dr. Dana Leifer, MD, RPNI; and Dr. Nicholas Janocko, MD, RPNI (our vascular neurology team at Weill Cornell Medicine-New York Presbyterian Hospital) for implementing Carotid Plaque-RADS reporting in our dedicated neurovascular ultrasound lab.

Special thanks to Carla Michelini for production assistance.

64

© Copyright. Society of Diagnostic Medical Sonography. All Rights Reserved.