Stroke and Patent Foramen Ovale:

Transcranial Doppler for Right-to-Left Shunt Detection

1

SPEAKER PRESENTATION DISCLAIMER

The content and views presented are made available for educational purposes only. The information presented are the opinions of the presenter and do not necessarily represent the views of the Society of Diagnostic Medical Sonography (SDMS) or its affiliated organizations, officers, Boards of Directors, or staff members.

The presenter is responsible for ensuring balance, independence, objectivity, scientific rigor, and avoiding commercial bias in their presentation. Before making the presentation, the presenter is required to disclose to the audience any relevant financial interests or relationships with manufacturers or providers of medical products, services, technologies, and programs.

The SDMS and its affiliated organizations, officers, Board of Directors, and staff members disclaim any and all liability for all claims that may arise out of the use of this educational activity.

2

© Copyright. Society of Diagnostic Medical Sonography. All Rights Reserved.

RESEARCH DISCLAIMER

The information presented in this presentation is based on research conducted to the best of the presenters' abilities and knowledge. Research involves uncertainty and is subject to limitations. The findings and conclusions presented herein may be influenced by various factors including but not limited to data quality, methodology, assumptions, and interpretation.

Research outcomes may not always accurately predict real-world scenarios or future events. While the presenter may make efforts to ensure the accuracy and reliability of the information presented, completeness or absolute correctness is not guaranteed. This presentation is intended for informational purposes only and should not be construed as professional advice. Participants are encouraged to independently verify any information provided and consult relevant experts or professionals where appropriate.

The SDMS and its affiliated organizations, officers, Board of Directors, and staff members disclaim any and all liability for all claims that may arise out of the use of this educational activity.

3

Stroke and Patent Foramen Ovale: Transcranial Doppler for Right-to-Left Shunt Detection

Disclosures and Contact Information

Richard Genova, BA, RVT, RPhS, NVS
Certified Neurovascular Specialist
Technical Director of the Neurovascular Ultrasound Lab
Weill Cornell Medicine—NY Presbyterian Hospital
New York, NY 10065

rig7007@med.cornell.edu
(212) 746-5458 office
(929) 783-3444 mobile
neurosonologist@protonmail.com
Linkedin.com/in/rgenova
X: @neurosonologist

Member, Board of Directors, American Society of Neuroimaging (2022-present)
Member, Board of Directors, Vascular Testing, Intersocietal Accreditation Commission (2020-2025)

I have nothing to disclose … my volunteer positions are non-remunerative.

4

© Copyright. Society of Diagnostic Medical Sonography. All Rights Reserved.

Patent Foramen Ovale

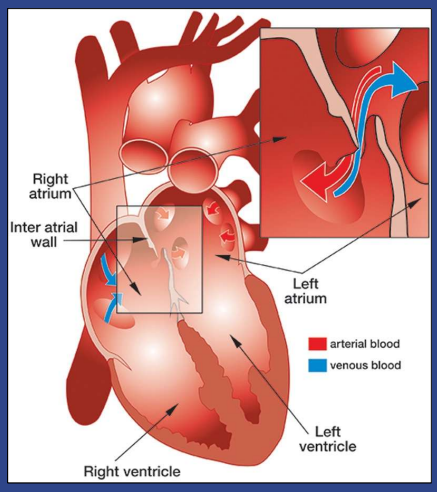

- Small hole upper chamber of heart. When patent, a connection remains between the right (venous) and left (arterial) sides of heart
- Supplies blood to fetus via umbilical cord, usually closes following birth
- 25% of population has PFO
- Size of the PFO on Spencer Scale Grading (I through V) in patients under age 60 is one of the most important parameters in predicting increased secondary stroke risk with an RLS
- Atrial Septal Defect is larger hole that is a result of lack of tissue formation in utero

5

Patent Foramen Ovale (PFO)

- Anatomy/Embryology
- LA>RA pressure should cause closure after birth
- PFO found in ~25% of population at autopsy
- Associated with ischemic stroke, migraine with aura
- Valsalva can increase RA>LA pressure, and cause transient shunt leading to paradoxical embolus

6

© Copyright. Society of Diagnostic Medical Sonography. All Rights Reserved.

Patent Foramen Ovale Stroke

- 20-30% of ischemic strokes are cryptogenic
- 50% of patients < 60 years old with cryptogenic stroke have a PFO—twice the prevalence in the general population
- The stroke mechanism may be PFO related (but still may be another occult cause)
- RoPE Scores may be used to identify patients with cryptogenic strokes who are likely to have pathogenic PFO rather than an incidental PFO.
- PASCAL [PFO-Associated Stroke CAusal Likelihood algorithm] combined RoPE Score with cardiac anatomic features and signs of concurrent VTE

"Risk of Paradoxical Embolism (RoPE)—Estimated Attributable Fraction Correlates with the Benefit of Patent Foramen Ovale Closure". David M. Kent et al., Stroke, 2020; 51: 3119-3123. DOI: 10.1161/STROKEAHA.120.029350

7

Patent Foramen Ovale Diagnostic Tests: What's Changed in the Last 40 Years?

- Transesophageal Echocardiogram (TEE)—allows PFO to be measured in diameter; however, a known PFO should be confirmed first to avoid patient undergoing invasive procedure unnecessarily. Small PFOs may still be missed because patient is unable to perform Valsalva maneuver while under sedation.
- Transthoracic Echo—often gives false negatives due to poor image quality and poor technique. No way to quantify PFO/no grading scale. Valsalva often obliterates the ultrasonic image.
- TCD—allows us to hear emboli passing to the Circle of Willis in real time (96% Sensitive 94% Specific), adequate Valsalva maneuver can be accomplished in most cases. Spencer Grading Scale allows for quantification of PFO size that correlates with closure decisions better than International Consensus Criteria.

8

© Copyright. Society of Diagnostic Medical Sonography. All Rights Reserved.

Monitoring Headframe Prototype 1986

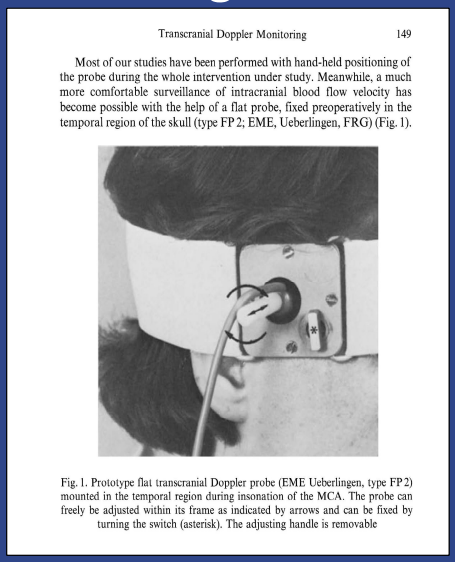

Transcranial Doppler Monitoring 149

Most of our studies have been performed with hand-held positioning of the probe during the whole intervention under study. Meanwhile, a much more comfortable surveillance of intracranial blood flow velocity has become possible with the help of a flat probe, fixed preoperatively in the temporal region of the skull (type FP 2; EME, Ueberlingen, FRG) (Fig. 1).

Fig. 1. Prototype flat transcranial Doppler probe (EME Ueberlingen, type FP 2) mounted in the temporal region during insonation of the MCA. The probe can freely be adjusted within its frame as indicated by arrows and can be fixed by turning the switch (asterisk). The adjusting handle is removable

Foreword from Merrill P. Spencer, MD, July 1986

Every few years a dissertation comes to the area of clinical application of medical technology which carries us forward as on a magic carpet into new regions of understanding and patient care. This book is such a magic carpet. It brings together, in a clear and incisive fashion, important hemodynamic principles with a simple noninvasive method of application to a part of the cerebral vasculature which has been relatively inaccessible. …The diligent application of the potentials of transcranial Doppler ultrasound brings new power to our efforts in understanding the cerebral circulation and the causes, treatment and prevention of cerebrovascular disorders.

Source: *Transcranial Doppler Sonography*, edited by R. Aaslid. Springer-Verlag/Wien New York 1986. Chapter 10. Transcranial Doppler Monitoring by E.B. Ringelstein

9

In the Early ’90s, Columbia Med School Clinicians Applied TCD to Paradoxical Stroke Cases

Transcranial Doppler ultrasound identifies patients with right-to-left cardiac or pulmonary shunts

M.I. Chimowitz, MD; J.J. Nemec, MD; T.H. Marwick, MBBS; R.J. Lorig, MD, PhD; A.J. Furlan, MD; and E.E. Salcedo, MD

Article abstract—We performed transcranial Doppler ultrasound (TCD) and transesophageal contrast echocardiography simultaneously in four patients. In one patient with a patent foramen ovale and another patient with pulmonary A-V fistulae, we detected micro air bubbles in the right middle cerebral artery three to five cardiac cycles after their appearance in the left atrium following intravenous injection of contrast. In two patients without right-to-left shunts, we did not detect air bubbles in the left atrium or middle cerebral artery following injection of contrast. These results show that TCD can identify patients with right-to-left cardiac or pulmonary shunts.

NEUROLOGY 1991;41:1902-1904

Vascular distribution of paradoxical emboli by transcranial Doppler

N. Venketasubramanian, MD; R.L. Sacco, MD; M. Di Tullio, MD; D. Sherman, MD; S. Homma, MD; and J.P. Mohr, MD

Article abstract—*Background and purpose.* Paradoxical embolism through a patent foramen ovale is a contributory mechanism to stroke and may be diagnosed by contrast echocardiography. The intracranial distribution of these emboli has not been previously reported. *Methods.* We used transcranial Doppler combined with agitated saline contrast injection to determine whether there was a preferential distribution of the contrast into the anterior or posterior intracranial circulation of patients with an acute stroke or transient ischemic attack. *Results.* Forty-nine patients were studied—27 men and 22 women, with a mean age of 62.7 ± 13.3 years (range, 29 to 85 years). Microcavitations were detected in the proximal right middle cerebral artery in 12 of 49 patients (24%). A patent foramen ovale was confirmed in all cases by simultaneous transesophageal echocardiography. Of the 12 patients, microcavitations were also detected in the proximal basilar artery in nine (75%). *Conclusions.* While paradoxical embolism appears to occur more frequently in the anterior circulation, the high rate of detection of microcavitations in the basilar artery suggests that paradoxical embolism to the posterior intracranial circulation may be more frequent than generally believed.

NEUROLOGY 1993;43:1533-1535

10

© Copyright. Society of Diagnostic Medical Sonography. All Rights Reserved.

Cardiology-Neurology Alliance Brings Forth TCD Power-M Mode

Power M-Mode Transcranial Doppler for Diagnosis of Patent Foramen Ovale and Assessing Transcatheter Closure

Merrill P. Spencer, MD
Mark A. Moehring, PhD
Jill Jesurum, PhD
William A. Gray, MD
John V. Olsen, MD
Mark Reisman, MD

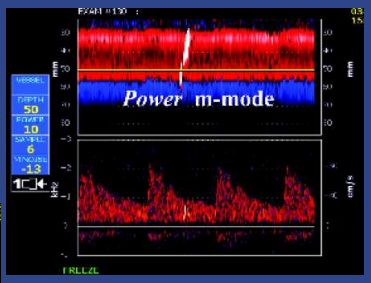

"Several findings in this study suggest pmTCD is a valid alternative to TEE in diagnosing PFO. These include its high sensitivity and the high significance of conductance grades greater than II in predicting whether a PFO is present and can be found by catheterization."

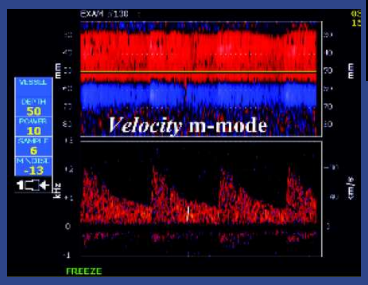

11

Using Digital Power M-Mode and Spectrogram Screens

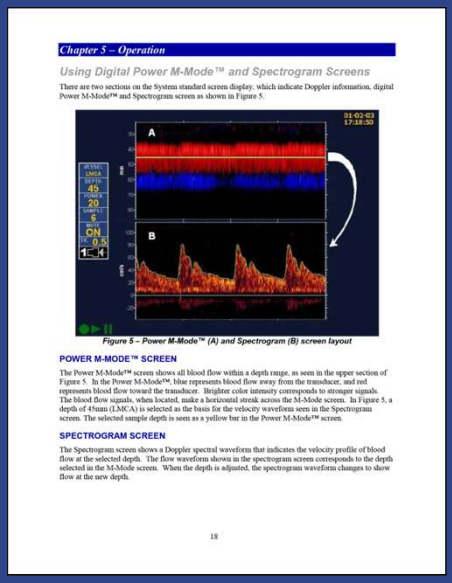

Chapter 5 – Operation

Using Digital Power M-Mode™ and Spectrogram Screens

There are two sections on the System standard screen display, which indicate Doppler information, digital Power M-Mode™ and Spectrogram screen as shown in Figure 5.

Figure 5 – Power M-Mode™ (A) and Spectrogram (B) screen layout

POWER M-MODE™ SCREEN

The Power M-Mode™ screen shows all blood flow within a depth range, as seen in the upper section of Figure 5. In the Power M-Mode™, blue represents blood flow away from the transducer, and red represents blood flow toward the transducer. Brighter color intensity corresponds to stronger signals. The blood flow signals, when located, make a horizontal streak across the M-Mode screen. In Figure 5, a depth of 45mm (LMCA) is selected as the basis for the velocity waveform seen in the Spectrogram screen. The selected sample depth is seen as a yellow bar in the Power M-Mode™ screen.

SPECTROGRAM SCREEN

The Spectrogram screen shows a Doppler spectral waveform that indicates the velocity profile of blood flow at the selected depth. The flow waveform shown in the spectrogram screen corresponds to the depth selected in the M-Mode screen. When the depth is adjusted, the spectrogram waveform changes to show flow at the new depth.

18

SCREEN DISPLAY FORMATS

There are two screen display formats: Standard and M-Mode

Standard Display Figure 6 shows M-Mode and Spectrogram screens of equal size. It displays the M-Mode screen at the top half of the display and the spectrogram at the lower half of the display. This mode is recommended for patient monitoring.

M-Mode Display Figure 7 emphasizes Power M-Mode™ data. The M-Mode screen is expanded, and the spectrogram screen is hidden. This display mode simplifies location of blood flow.

To switch Screen Display Mode:

- Press **MODE** to switch between Standard and M-Mode display formats. This change affects the display only, and not the format of recorded data.

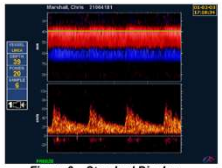

Figure 6 – Standard Display

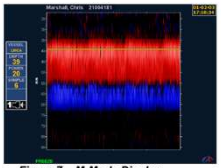

Figure 7 – M-Mode Display

12

© Copyright. Society of Diagnostic Medical Sonography. All Rights Reserved.

TCD Is Superior to TEE for Detection of High-Risk PFO

2014 International Stroke Conference

Sacco and Spence dialogue at 2014 ISC bears fruit a decade later.

- Wake up stroke, VM, dyspnea, prolonged inactivity or stasis, history of DVT, PE, varicose veins
- TCD is more predictive than TEE for finding high-risk RLS/PFO



https://www.youtube.com/watch?v=rmRq0TPNEmo

13

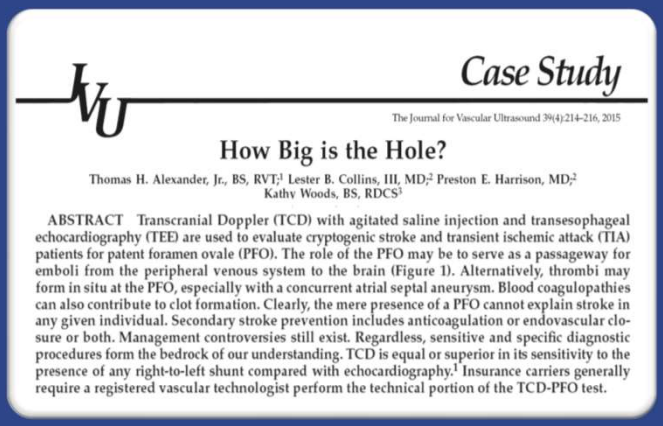

Case Study

The Journal for Vascular Ultrasound 39(4):214-216, 2015

How Big is the Hole?

Thomas H. Alexander, Jr., BS, RVT,[1] Lester B. Collins, III, MD,[2] Preston E. Harrison, MD,[2] Kathy Woods, BS, RDCS[3]

ABSTRACT Transcranial Doppler (TCD) with agitated saline injection and transesophageal echocardiography (TEE) are used to evaluate cryptogenic stroke and transient ischemic attack (TIA) patients for patent foramen ovale (PFO). The role of the PFO may be to serve as a passageway for emboli from the peripheral venous system to the brain (Figure 1). Alternatively, thrombi may form in situ at the PFO, especially with a concurrent atrial septal aneurysm. Blood coagulopathies can also contribute to clot formation. Clearly, the mere presence of a PFO cannot explain stroke in any given individual. Secondary stroke prevention includes anticoagulation or endovascular closure or both. Management controversies still exist. Regardless, sensitive and specific diagnostic procedures form the bedrock of our understanding. TCD is equal or superior in its sensitivity to the presence of any right-to-left shunt compared with echocardiography.[1] Insurance carriers generally require a registered vascular technologist perform the technical portion of the TCD-PFO test.



How Big Is the Hole?

14

© Copyright. Society of Diagnostic Medical Sonography. All Rights Reserved.

Etiologic Workup in Patients with Acute Ischemic Stroke ≤60 Years of Age: A Clinical Workflow Proposal

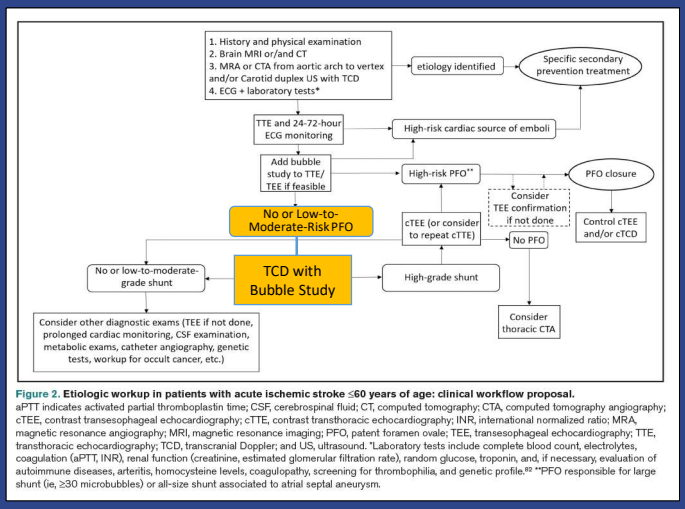

Figure 2. Etiologic workup in patients with acute ischemic stroke ≤60 years of age: clinical workflow proposal.
aPTT indicates activated partial thromboplastin time; CSF, cerebrospinal fluid; CT, computed tomography; CTA, computed tomography angiography; cTEE, contrast transesophageal echocardiography; cTTE, contrast transthoracic echocardiography; INR, international normalized ratio; MRA, magnetic resonance angiography; MRI, magnetic resonance imaging; PFO, patent foramen ovale; TEE, transesophageal echocardiography; TTE, transthoracic echocardiography; TCD, transcranial Doppler; and US, ultrasound. *Laboratory tests include complete blood count, electrolytes, coagulation (aPTT, INR), renal function (creatinine, estimated glomerular filtration rate), random glucose, troponin, and, if necessary, evaluation of autoimmune diseases, arteritis, homocysteine levels, coagulopathy, screening for thrombophilia, and genetic profile.[82] **PFO responsible for large shunt (ie, ≥30 microbubbles) or all-size shunt associated to atrial septal aneurysm.

Transcranial Doppler with Microbubbles: Screening Test to Detect and Grade Right-to-Left Shunt After an Ischemic Stroke: A Literature Review. Paola Palazzo, MD, PhD; Mirjam R. Heldner, MD, MSc; Nathalie Nasr, MD, PhD; Andrei V. Alexandrov, MD. *Stroke*. 2024;55:2932–2941. DOI: 10.1161/STROKEAHA.124.046907

15

Closing PFOs and the Role of TCD

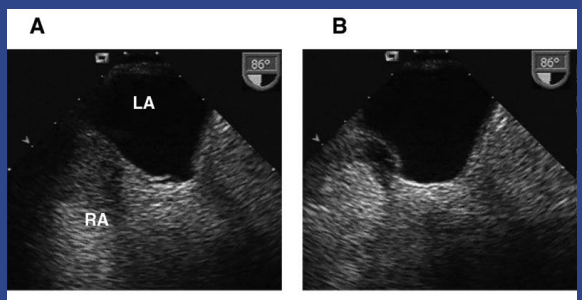

A: TEE False-negative injection (FNI) for PFO detection caused by absence of leftward bulging of interatrial septum. **B:** Another FNI caused by contrast-free blood that surges in from IVC sweeping contrast away from septum.

Right to left shunt (RLS) is a recognized risk factor for stroke. Current standard of care for RLS diagnosis includes transthoracic echocardiography (TTE) which is insensitive, transesophageal echocardiography (TEE) which is invasive, and transcranial Doppler (TCD) which has excellent sensitivity and specificity.

"TCD to evaluate postreperfusion therapy following acute ischemic stroke: A literature review" by Shahripour RB, Azarpazhooh MR, Akhuanzada H, Labin E, Borhani-Haghighi A, Agrawal K, Meyer D, Meyer B, Hemmen TM. *J Neuroimaging*. 2021;1–9. https://lnkd.in/dfjJcpTw

16

© Copyright. Society of Diagnostic Medical Sonography. All Rights Reserved.

Table. High-Risk Sources of Cardiac Embolism

Mechanical prosthetic valve
Atrial fibrillation or flutter
Left atrial or ventricular thrombus
Recent myocardial infarction (<4 wk)
Dilated cardiomyopathy
Infective endocarditis
Regional left ventricular akinesis
Atrial myxoma
Rheumatic heart disease
Patent foramen ovale with thrombus in situ

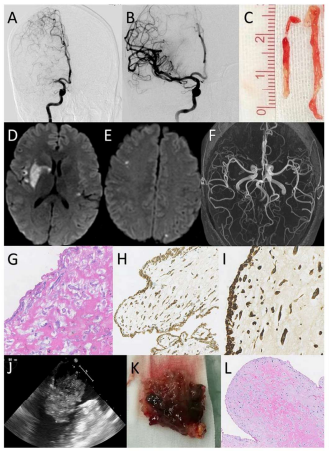



Kamel H, Healey JS. Cardioembolic Stroke. Circulation Research. 2017;120:514–526.

Rao J, et al. Mechanical Thrombectomy for Acute Ischemic Stroke in Patients With Cardiac Myxoma: A Case Series and Pooled Analysis. Front Neurol. 2022;13:877056

https://med.emory.edu/departments/emergency-medicine/sections/ultrasound/case-of-the-month/cardiac/endocarditis.html

17

Diagnostic work up

- CTA/MRA normal vessels
- TTE- normal, negative bubble study
- Cardiac rhythm monitoring- no afib
- CT C/A/P negative for malignancy
- DVT studies negative
- Hypercoagulable labs negative
- TCD bubble→ Large shunt/PFO (Spencer grade 4)
- TEE- small PFO, no atrial septal aneurysm
- Conclusion: Cardioembolic/PFO related

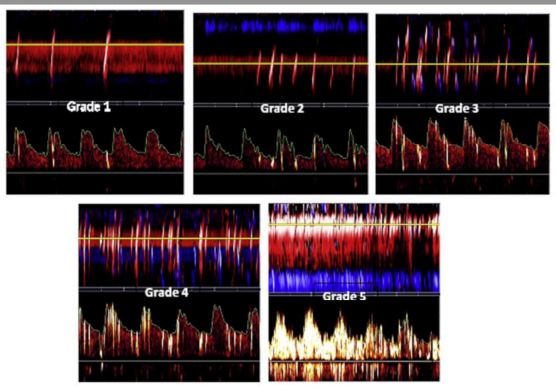

Spencer Grade 0, no microemboli detected;
Grade 1, 1-10 microemboli;
Grade 2, 11-30 microemboli;
Grade 3, 31-100 microemboli;
Grade 4, 101-300 microemboli;
Grade 5, > 300 microembol ("white out")

Tobe J, et al. Transcranial Doppler is Complementary to Echocardiography for Detection and Risk Stratification of Patent Foramen Ovale. Can J Cardiol. 2016:32(8):986.e9-986.e16.

18

© Copyright. Society of Diagnostic Medical Sonography. All Rights Reserved.

Clinical Case

- 30's F with positive ANA/mixed connective tissue disease on hydroxychloroquine
- LKW bedtime 9:30pm, woke up with left sided weakness at 4am
- NIHSS 9 (Left facial droop, dysarthria, LUE 0/5, sensory loss)
- Out of 4.5h window from LKW for thrombolysis
- CT-no hemorrhage or large infarct
- CTA no LVO, dissection, stenosis, carotid web
- Taken for hyperacute MRI

Weill Cornell Medical College | Used by permission of Nicholas Janocko, MD, RPNI | NewYork-Presbyterian Weill Cornell Medical Center

19

Wake-Up Stroke in Young Adults

NewYork-Presbyterian Hospital
227,404 followers
6mo •

In April, Krista Figari, 39, woke up early one morning and quickly became disoriented. She stumbled to the floor, having lost control of her left side. Krista was having a wake-up stroke, a type of #stroke that occurs during sleep. She called 911 and was rushed to #NYPWeillCornell, where her care team, led by vascular neurologist Dr. Nicholas Janocko, treated her with tenecteplase (TNK), a medicine used to dissolve blood clots. Five days later, Krista was discharged, having recovered with only slight weakness in her left hand and mild drooping in her face – symptoms that Krista says are undetectable today.

Tests revealed that her stroke was caused by a patent foramen ovale (PFO), a small hole in her heart. To reduce her risk of a future stroke, Krista returned to the hospital in July for a minimally invasive procedure to close the hole, performed by interventional cardiologist Dr. Harsimran Singh, and was home the next day.

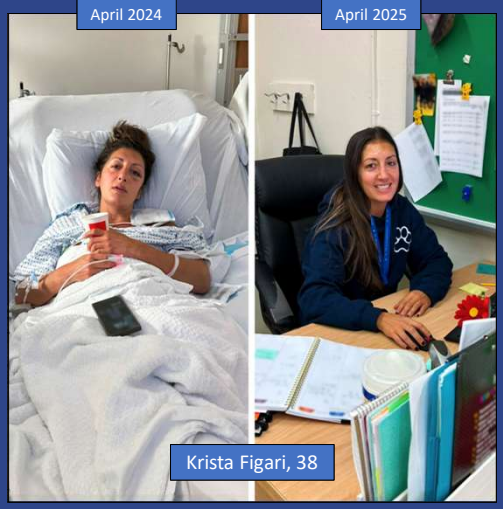

Though it had been several hours since the stroke began, Dr. Janocko explained, "we gave her TNK because the results of her imaging showed her stroke was still very recent and she'd benefit from it. Thankfully, she had a really good outcome."

Krista, a special education teacher, is now back at work at P.S. 205 in the Bronx, happily making a difference in her students' lives. "I'm very grateful for everything all the doctors and nurses did for me, from the ER to the neurology and cardiology teams," she said. "If it wasn't for them, I'm not sure where I'd be physically or mentally today. I feel very lucky!"

20

© Copyright. Society of Diagnostic Medical Sonography. All Rights Reserved.

Wake-Up Stroke in Young Adults

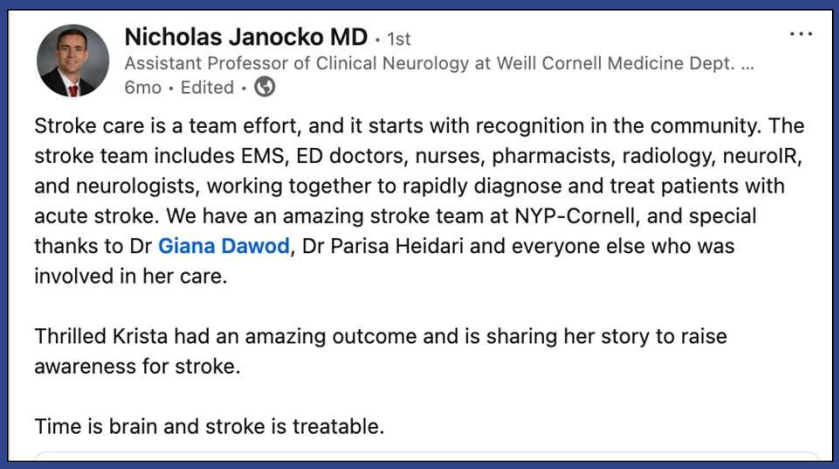

Nicholas Janocko MD · 1st
Assistant Professor of Clinical Neurology at Weill Cornell Medicine Dept. ...
6mo · Edited ·

Stroke care is a team effort, and it starts with recognition in the community. The stroke team includes EMS, ED doctors, nurses, pharmacists, radiology, neuroIR, and neurologists, working together to rapidly diagnose and treat patients with acute stroke. We have an amazing stroke team at NYP-Cornell, and special thanks to Dr **Giana Dawod**, Dr Parisa Heidari and everyone else who was involved in her care.

Thrilled Krista had an amazing outcome and is sharing her story to raise awareness for stroke.

Time is brain and stroke is treatable.

21

Wake-Up Stroke Traced to PFO



22

© Copyright. Society of Diagnostic Medical Sonography. All Rights Reserved.

Wake-Up Stroke Traced to PFO



23

In-Hospital Acute and Outpatient Lab Reports

- In hospital – Bubble Study negative
- <30 days later – Outpatient Neurovascular Ultrasound Lab Bubble Study positive for Spencer Grade IV right to left shunt/PFO
- PFO closed 7/15/2024

24

© Copyright. Society of Diagnostic Medical Sonography. All Rights Reserved.

Wake-Up Stroke Traced to PFO



How to tell if Valsalva is good

- ❖Must practice VM with patient before first injection
- ❖Must see ≥ 30% MFV change on practice VM
- ❖Or use a manometer and expect at least 40 mL Hg change
- ❖You will hear it

© Copyright. Society of Diagnostic Medical Sonography. All Rights Reserved.

PFO detection

- TTE Sensitivity ranges from 32% to 100%, Specificity 55% to 97%
- TEE range from 48% to 100%, Specificity ranges 83% to 100%
- TCD has the highest sensitivities ranging between 91% and 100%, specificity rates range between 78% and 100%
- Around 7% to 27% of TEE examinations are found to be false negatives that are later identified as positive on TCD

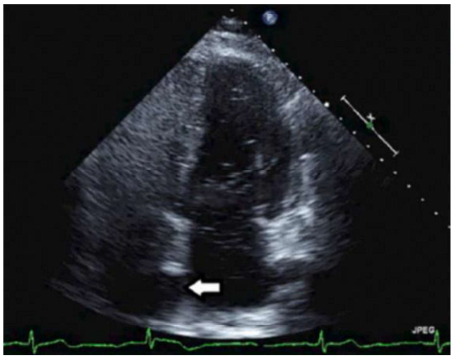

Stafford MB, Bagley JE, DiGiacinto D. Comparison of Transthoracic Echocardiography, Transesophageal Echocardiography, and Transcranial Doppler in the Detection of Patent Foramen Ovale as the Etiology for Cryptogenic Stroke. Journal of Diagnostic Medical Sonography. 2019;35(2):127-133.

Weill Cornell Medical College | Used by permission of Nicholas Janocko, MD, RPNI | NewYork-Presbyterian Weill Cornell Medical Center

27

Take Home Points

- High probability of cardioembolic stroke in young patients, especially if history of congenital heart disease or valve replacement
- Don't stop at the TTE; not PFO/shunt negative until TCD negative, often shunt size is Valsalva dependent
- PFO closure can reduce stroke risk in carefully selected patients, but the absolute risk is low

Weill Cornell Medical College | Used by permission of Nicholas Janocko, MD, RPNI | NewYork-Presbyterian Weill Cornell Medical Center

28

© Copyright. Society of Diagnostic Medical Sonography. All Rights Reserved.

Contrast TCD Protocol
(see procedure handout)

TCD with bubble test must be performed according to a rigorously standardized procedure.

1. The patient should be in the supine or upright sitting position, and an 18-gauge needle is inserted into the right cubital vein. Regarding position, Lao et al. found the highest microbubble yield in the upright sitting position, which seems to increase the accuracy of RLS grading but not the global sensitivity of cTCD.

29

Contrast TCD Protocol
(see procedure handout)

2. The contrast agent with microbubbles is prepared using 9 mL of isotonic saline solution and 1 mL of air, mixed via a 3-way stopcock by exchange of saline/air mixture between the 2 syringes and injected as a bolus. Adding a small amount (0.5 mL) of the patient's blood to bacteriostatic agitated saline solution increases the sensitivity of this exam. Commercial contrast agents as Echovist-300, which also contain microbubbles that are immediately trapped in the lung, are superior to agitated saline solution. However, due to the already high sensitivity of the standard test, the costs of the contrast agents, and the potential risk of allergic reaction, we suggest the use of the simple mixed saline solution….

30

© Copyright. Society of Diagnostic Medical Sonography. All Rights Reserved.

Headframe Fitting — It's an Art

(see procedure handout)

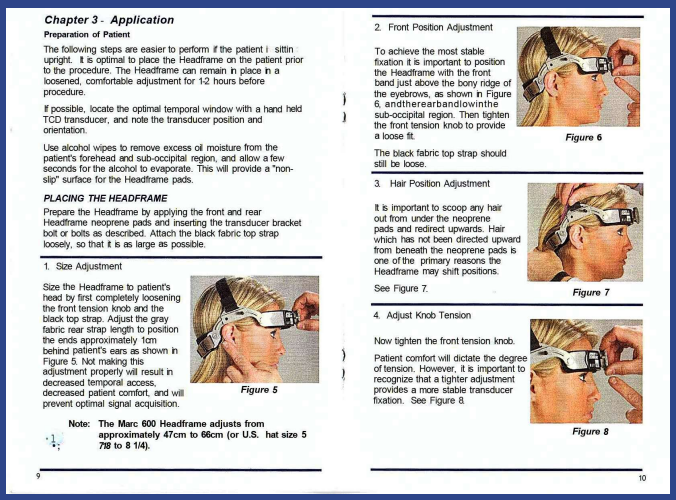

Chapter 3 - Application

Preparation of Patient

The following steps are easier to perform if the patient is sitting upright. It is optimal to place the Headframe on the patient prior to the procedure. The Headframe can remain in place in a loosened, comfortable adjustment for 12 hours before procedure.

If possible, locate the optimal temporal window with a hand held TCD transducer, and note the transducer position and orientation.

Use alcohol wipes to remove excess oil moisture from the patient's forehead and sub-occipital region, and allow a few seconds for the alcohol to evaporate. This will provide a "non-slip" surface for the Headframe pads.

PLACING THE HEADFRAME

Prepare the Headframe by applying the front and rear Headframe neoprene pads and inserting the transducer bracket bolt or bolts as described. Attach the black fabric top strap loosely, so that it is as large as possible.

1. Size Adjustment

Size the Headframe to patient's head by first completely loosening the front tension knob and the black top strap. Adjust the gray fabric rear strap length to position the ends approximately 1cm behind patient's ears as shown in Figure 5. Not making this adjustment properly will result in decreased temporal access, decreased patient comfort, and will prevent optimal signal acquisition.

Figure 5

Note: The Marc 600 Headframe adjusts from approximately 47cm to 66cm (or U.S. hat size 5 7/8 to 8 1/4).

9

2. Front Position Adjustment

To achieve the most stable fixation it is important to position the Headframe with the front band just above the bony ridge of the eyebrows, as shown in Figure 6, and the rear band low in the sub-occipital region. Then tighten the front tension knob to provide a loose fit.

Figure 6

The black fabric top strap should still be loose.

3. Hair Position Adjustment

It is important to scoop any hair out from under the neoprene pads and redirect upwards. Hair which has not been directed upward from beneath the neoprene pads is one of the primary reasons the Headframe may shift positions.

See Figure 7.

Figure 7

4. Adjust Knob Tension

Now tighten the front tension knob.

Patient comfort will dictate the degree of tension. However, it is important to recognize that a tighter adjustment provides a more stable transducer fixation. See Figure 8.

Figure 8

10

PFO Testing Protocol Tips and Tricks

- Sit patient up (air rises)
- Bubble Study Exam: Bilateral MCAs are insonated.
- Use a 20 gauge IV or larger if possible
- Use right antecubital fossa for IV placement, if possible, left arm can give false negative in patients with left persistent SVC
- Use bacteriostatic saline if possible
- Draw a few drops of blood into syringe if possible. This coats the bubbles and makes them stronger reflectors
- Check for patency of the peripheral IV in the AC vein. The syringe is filled with 9 cc of saline and 1 cc of air. Attach the saline-filled and the empty syringes to a 3-way stopcock that is attached to the IV. Agitate the saline between the 2 syringes until it becomes a frothy solution and inject rapidly into the IV.

© Copyright. Society of Diagnostic Medical Sonography. All Rights Reserved.

PFO Testing Protocol Tips and Tricks, continued

- Once the injection is complete the technologist begins timing for 45-60 seconds.
- Three injections at 3-4 minute intervals; monitoring is for one minute
- Make sure patient is able to perform adequate Valsalva maneuver prior to start of second and third injections
- Five seconds after the second and third injections, ask the patient to perform a Valsalva maneuver for 10 seconds and then slowly relax.
- TCD BUBBLE TEST for Cardiac Shunt Detection PFO TEST (Zsolt Garami, MD) See https://youtu.be/uFxBSxs2WJc

33

Evaluation of PFO Exams

- Spencer Grading Scale quantifies severity (size) of PFO
- Use the bilateral scale if only one MCA was able to be insonated

Spencer PFO Grading Scale for Bilateral MCAs

Grade	HITS
• Grade 0	0
• Grade I	1-10
• Grade II	11-30
• Grade III	31-100
• Grade IV	101-300
• Grade V	>300
• Grade V+	>> 300 (curtain sign)

Spencer PFO Grading Scale for Unilateral MCA

Grade	HITS
• Grade 0	0
• Grade I	1-5
• Grade II	6-15
• Grade III	16-50
• Grade IV	50-150
• Grade V	>150
• Grade V+	>>150 (curtain sign)

34

© Copyright. Society of Diagnostic Medical Sonography. All Rights Reserved.

Intensified Multidisciplinary Interest



35

"Robot-Assisted" TCD Bests Echo Bubble Studies


Stroke

CLINICAL AND POPULATION SCIENCES

Robot-Assisted Transcranial Doppler Versus Transthoracic Echocardiography for Right to Left Shunt Detection

CONCLUSIONS: raTCD was safe and ≈3 times more likely to diagnose RLS than TTE. TTE completely missed or underdiagnosed two thirds of large shunts diagnosed by raTCD. The raTCD device, used by health professionals with no prior TCD training, may allow providers to achieve the known sensitivity of TCD for RLS and patent foramen ovale detection without the need for an experienced operator to perform the test. Pending confirmatory studies, TCD appears to be the superior screen for RLS compared with TTE (funded by NeuraSignal).


AHA/ASA Journals

Stroke

Abstract WMP100: Multicenter Validation Study of Robot-Assisted Transcranial Doppler (raTCD) for Enhanced Right-to-Left Shunt Detection Compared to Transthoracic and Transesophageal Echocardiography

Abstract

Conclusions: This study represents the largest real-world study to date, validating raTCD against traditional diagnostic modalities. The study showed that raTCD detected 1.7 times the number of positive RLS/PFO compared to TTE, revealing the limitations of TTE as a screening modality for PFO in cryptogenic stroke. These results build upon the prospective multicenter BUBL Study reinforcing the imperative to incorporate raTCD into a new diagnostic algorithm for cryptogenic stroke workup.

36

© Copyright. Society of Diagnostic Medical Sonography. All Rights Reserved.

Features Associated with Thromboembolic Risk in ESUS Patients

- Embolic Stroke of Undetermined Source (ESUS)
- 1/6 patients with stroke
- Absence of clear cause like carotid stenosis, afib, etc.
- 25% ESUS have PFO (Patent Foramen Ovale)
- Estimated causal role of PFO in 4% of strokes, or half of those <age 60

Ntaios G, et al. Embolic strokes of undetermined source: a clinical consensus statement of the ESC Council on Stroke, the European Association of Cardiovascular Imaging and the European Heart Rhythm Association of the ESC. *European Heart Journal.* 2024;45:1701–1715.

Pathophysiology: *In situ* Thrombus Formation

- Consecutive patients with PFO (n=18)
- Excluded patients with known vascular risk factors
- High-resolution optical coherence tomography (OCT), catheter angiogram
- Included 11 patients with stroke, 7 without
- ***In situ* thrombus was found in all 11 patients with stroke and 1 of the non-stroke patients**
- Stroke patients had endocardial surface irregularity (9) or discontinuity (3)

© Copyright. Society of Diagnostic Medical Sonography. All Rights Reserved.

BUBL Study

- TCD 3x more likely to diagnose shunt than TTE
- TTE missed or underestimated size of shunt in 2/3

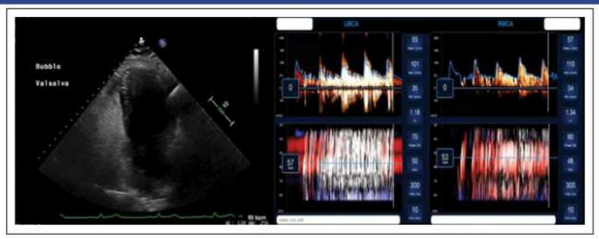

Figure 2. A transthoracic echocardiogram (TTE) and robot-assisted transcranial Doppler (raTCD) in one of the study subjects with a negative TTE and a strongly positive raTCD. The 4-chamber

Rubin MN, et al. Robot-Assisted Transcranial Doppler Versus Transthoracic Echocardiography for Right to Left Shunt Detection. *Stroke*. 2023;54(11):2842-2850.

Features Associated with Thromboembolic Risk in ESUS Patients

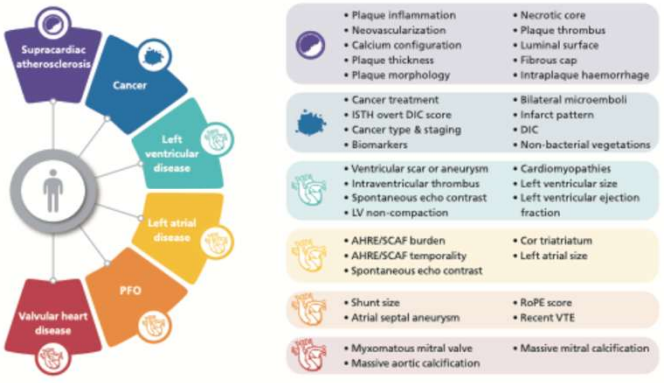

AHRE, atrial high-rate episode; DIC, disseminated intravascular coagulation; ISHT, International Society on Thrombosis and Haemostasis; LV, left ventricular; RoPE, Risk of Paradoxical Embolism; SCAF, subclinical atrial fibrillation; VTE, venous thromboembolism.

© Copyright. Society of Diagnostic Medical Sonography. All Rights Reserved.

PFOs and Stroke Prevention: Pregnancy and Postpartum

- History of stroke: closure not recommended
- Routine screening for PFO not recommended
- Screening for RLS with TCD can be considered for high-risk conditions

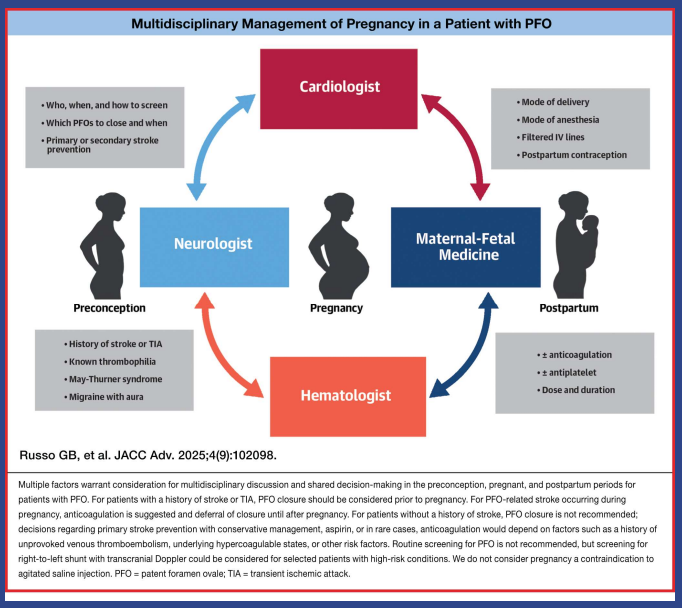

41

Case Closed After Two Decades of Clinical Trials

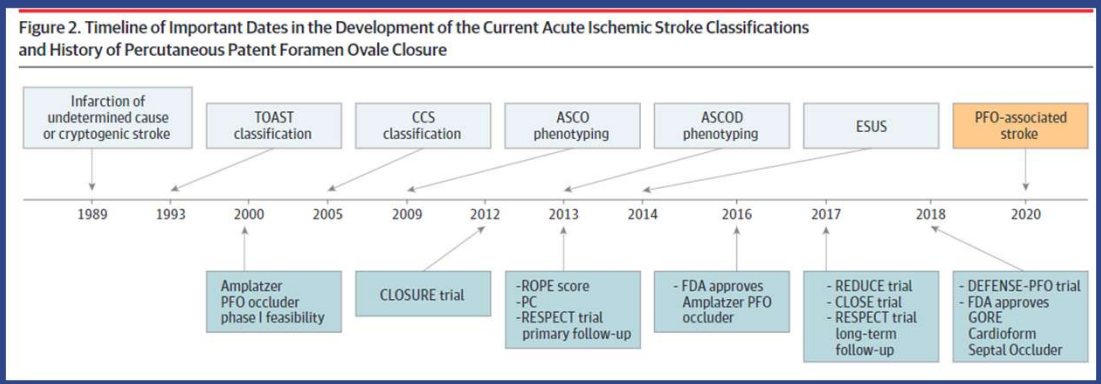

Elgendy AY, et al. Proposal for Updated Nomenclature and Classification of Potential Causative Mechanism in Patent Foramen Ovale-Associated Stroke. *JAMA Neurol.* 2020;77(7):878-886.

42

© Copyright. Society of Diagnostic Medical Sonography. All Rights Reserved.

Patent Foramen Ovale Management for Secondary Stroke Prevention: State-of-the-Art Appraisal of Current Evidence

- Recurrent stroke rates: 1.09% per year in the medical group vs 0.47% per year in the closure +medical group, Hazard Ratio 0.41.
- 59% relative reduction, absolute reduction 0.62% per year
- NNT (preventing 1 stroke over 5 years) = 32
- Immediate, serious, procedure-related complications were rare
  - access site or retroperitoneal hemorrhage (1%), pericardial tamponade (0.17%), and cardiac perforation (0.06%).
- PFO closure is associated with a 5x risk of AF compared with medical treatment
- 6.6% of patients with stroke undergoing PFO closure develop AF, 83% of AF cases detected within 45 days after closure, rate increases with age

Luciano A. Sposato, MBA; Catherine S.W. Albin, MD; Mitchell S.V. Elkind, MD; Hooman Kamel, MD, MS; Jeffrey L. Saver, MD; on behalf of the Roundtable of Academia and Industry for Stroke Prevention (RAISE) 2022

43

Key Study!

- Pooled individual patient data from all 6 randomized clinical trials that compared PFO closure plus medical therapy vs medical therapy alone in patients with PFO-associated stroke
- n= 3740 participants
- Classified based on probability stroke was PFO related
- Primary Efficacy Endpoint: Recurrent Ischemic Stroke

PASCAL Classification System[b]		
High RoPE Score (≥7)	High-risk PFO feature (LS and/or ASA)	PFO-related stroke
Absent	Absent	Unlikely
Absent	Present	Possible
Present	Absent	
Present	Present	Probable


JAMA | Original Investigation

Heterogeneity of Treatment Effects in an Analysis of Pooled Individual Patient Data From Randomized Trials of Device Closure of Patent Foramen Ovale After Stroke

David M. Kent, MD, MS; Jeffrey L. Saver, MD; Scott E. Kasner, MD; Jason Nelson, MS; John D. Carroll, MD; Gilles Chatellier, MD; Geneviève Derumeaux, MD; Anthony J. Furlan, MD; Howard C. Herrmann, MD; Peter Jüni, MD; Jong S. Kim, MD; Benjamin Koethe, MS; Pil Hyung Lee, MD; Benedicte Lefebvre, MD; Heinrich P. Mattle, MD; Bernhard Meier, MD; Mark Reisman, MD; Richard W. Smalling, MD, PhD; Lars Soendergaard, MD; Jae-Kwan Song, MD; Jean-Louis Mas, MD; David E. Thaler, MD, PhD

44

© Copyright. Society of Diagnostic Medical Sonography. All Rights Reserved.

Who Gets Closure?

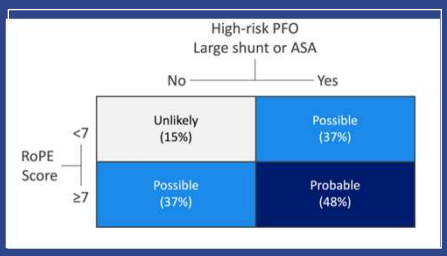

- Probable 90% relative reduction
- Possible 62% relative reduction
- Unlikely no difference



Figure 4. Suggested diagnostic algorithm for patent foramen ovale diagnosis and patient selection for patent foramen ovale (PFO) closure.

45

Importance of Proper Valsalva Maneuver: A Case Study

The following slides will contrast properly and improperly performed Valsalva maneuvers.

46

© Copyright. Society of Diagnostic Medical Sonography. All Rights Reserved.

Spencer Grade III RLS/PFO

Note no HITS at rest without VM becomes a Spencer Grade III RLS on first VM

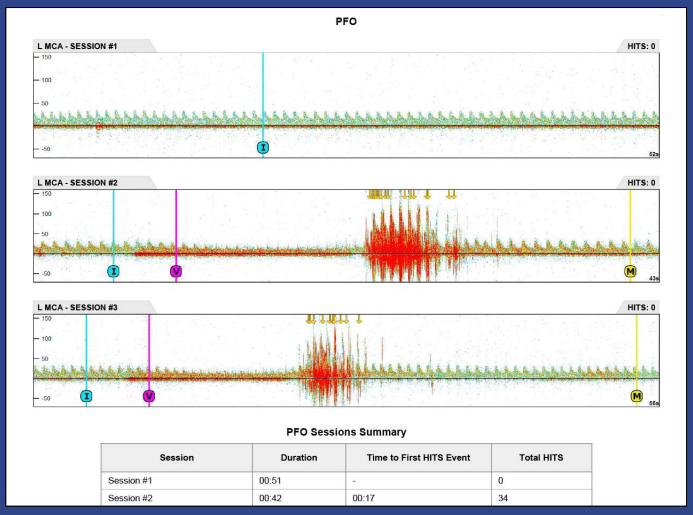

In RoPE and PASCAL scoring Spencer Grade III+ RLS can be a determining factor for closing

47

Cardiology didn't want to close

- TTE Bubble Study negative
- TEE Bubble Study negative
- Cardiac MRI Bubble Study negative

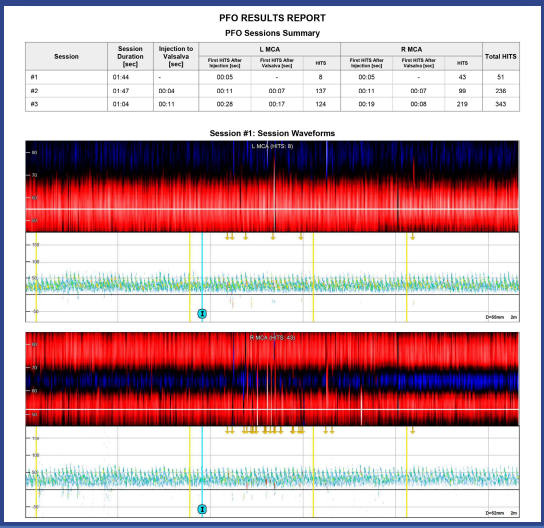

- But TCD shows large RLS/PFO
- Note Session 1 (no VM) is a Spencer Grade III shunt

48

© Copyright. Society of Diagnostic Medical Sonography. All Rights Reserved.

April 2026: Clinical history + TCD results = strong candidate for closure

Outlook

From Richard Genova
Date
To
Cc

1 attachment (30 MB)

Hello Dr.

The preliminary bubble study report for is in Epic and the imaging file is attached.

She has a Spencer Grade V shunt. Her exam could be useful for a case study because: 1) Her HITS are great eye candy with clear directionality; 2) she was negative on TTE bubble; 3) She has a history of migraine w/aura and 4) a son has a history of a symptomatic PFO.

Thanks,
Richard

49

In the meantime (between April & June)…patient had negative TEE bubble study and a negative cardiac CT for RLS

Outlook

Positive TCD but negative TTE/TEE/CT scan?

From
Date
To Richard Genova

Good morning,
Reaching out to you about an interesting situation I haven't encountered before. I have a young patient who had a TIA event, had a very positive TCD bubble study with valsalva, but negative TTE/TEE/pan CT scan for PFO or AVM/shunt.

Have you encountered situations like this before? I recommended a repeat TTE with strong valsalva, but wanted to reach out to you to see if you had any other thoughts.

Thanks

50

© Copyright. Society of Diagnostic Medical Sonography. All Rights Reserved.

TTE finds the bubbles with a rigorously supervised Valsalva

Outlook

Re: Positive TCD but negative TTE/TEE/CT scan?

From Richard Genova
Date
To

Thanks for the details! An additional bonus is you upping the game by echo techs.

Have a great weekend,
Richard

From:
Date:
To: Richard Genova
Subject: Re: Positive TCD but negative TTE/TEE/CT scan?

I talked with the cardiology team yesterday. They have a protocol (not sure about the details for the standard one), but this time they did multiple injections with good RA opacification and numerous valsalva attempts with the head of their echo lab present and were finally able to identify the PFO.

I think this reiterates what we already know about TCD sensitivity being much higher. Glad you will be able to use this for your conference presentation.

Thanks again, and have a nice holiday weekend,

51

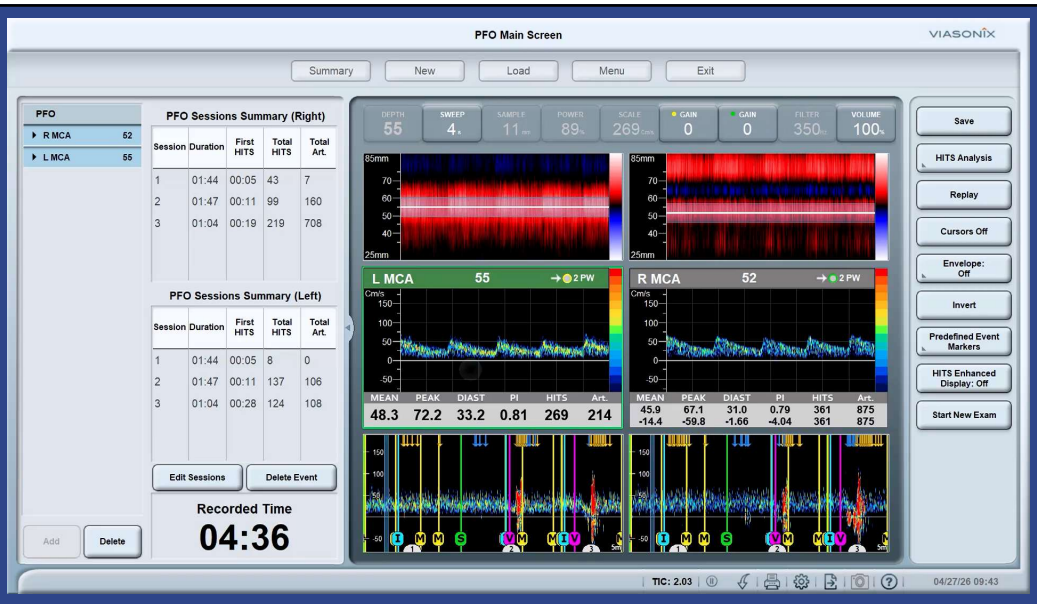

Note Session 2 with first VM attempt (Spencer Grade IV).

52

© Copyright. Society of Diagnostic Medical Sonography. All Rights Reserved.

Valsalva Second (Session 3)

Even better Valsalva produces even bigger shunt

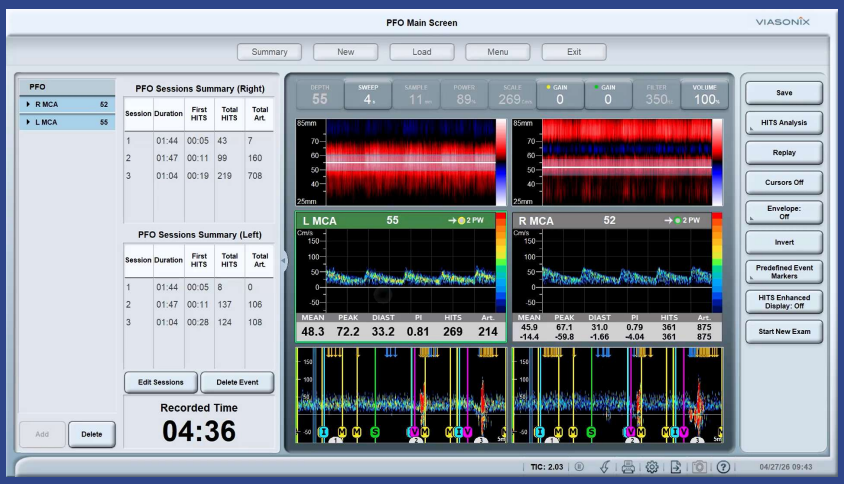

Note Session 3 with second VM attempt (Spencer Grade V).

Why we usually do two Valsalvas

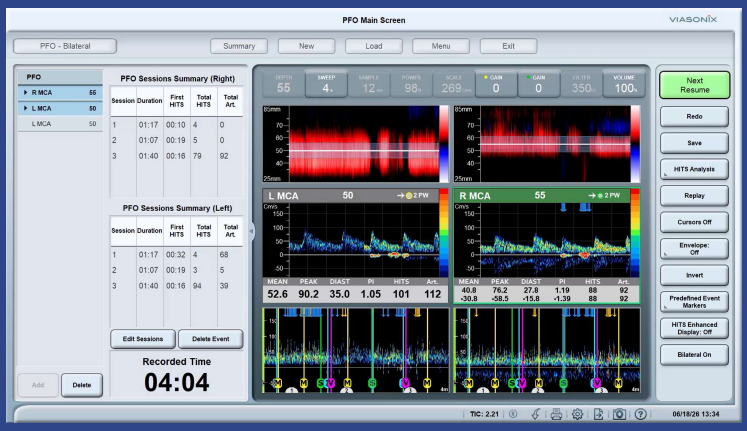

Note Session 2 with first VM attempt, still a Spencer Grade I.

© Copyright. Society of Diagnostic Medical Sonography. All Rights Reserved.

Third time's the charm (second Valsalva attempt done well)

- Don't give up!
- Coach the VM

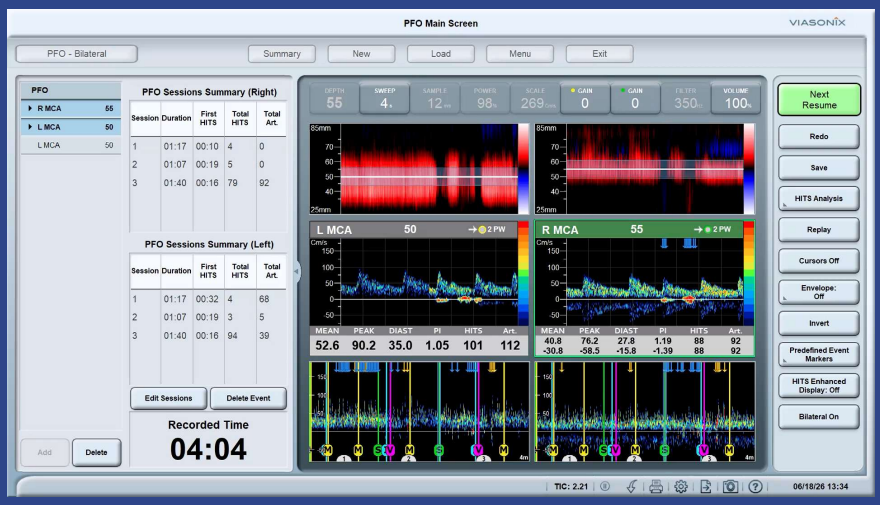

Note Session 3 with second VM attempt, now a Spencer Grade IV.

The IAC VALUE Study—We Still Need More TCD



Intersocietal Accreditation Commission Accreditation Status of Outpatient Cerebrovascular Testing Facilities Among Medicare Beneficiaries

The VALUE Study

"It is interesting that transcranial Doppler imaging was one of the most underused cerebrovascular testing procedures in this study. Many reasons for that finding exist, of which limited training available for transcranial Doppler ultrasound, operator dependency, and the functionality of the test as opposed to examination of the brain structure, which is preferred by physicians, may be most important. Nevertheless, there is a critical need for a systematic effort to educate and train sonographers and interpreting physicians in transcranial Doppler ultrasound. These efforts, together with accreditation of cerebrovascular testing facilities, may considerably reduce disparities in the quality of care delivered to Medicare patients at risk for stroke/TIA and other cerebrovascular diseases."

© Copyright. Society of Diagnostic Medical Sonography. All Rights Reserved.

IAC Recognizes the NVS Credential



"Kudos to the IAC for recognizing the NVS credential. The acceptance of the Neurovascular Specialist credential by the IAC Vascular Testing division means there is now no excuse for TCD to be performed in any clinical setting by a non-credentialed individual, nor for any facility performing TCD exams not to be accredited by the IAC."

John Bennett, PhD, RVT, NVS
Chair of the American Society of Neuroimaging Subcommittee for the NVS

"The recent approval of the NVS credential for carotid and TCD exams by the IAC Vascular Testing Board is a huge step forward for the neurovascular community. As many technologists and vascular neurologists in stroke units and vascular neurology outpatient clinics perform only transcranial Doppler and carotid examinations, this credential creates a pathway for vascular technologists, neurologists and other related vascular professionals to be recognized in the field. In addition, these individuals' possession of the NVS credential will significantly contribute to improved standards of care and health quality for our patients. I congratulate IAC Vascular Testing Board for taking this step forward.."

Tatiana Rundek, MD, PhD, FANA
Director of the Clinical Translational Research Division
Department of Neurology, University of Miami, Miller School of Medicine

57

Stroke and Patent Foramen Ovale: Transcranial Doppler for Right-to-Left Shunt Detection

Thank you for participating!

Thanks to Dr. Nicholas Janocko, MD, RPNI, and Krista Figari for sharing their case of a wake-up stroke and PFO closure. Also thanks to Dr. Eliza Miller, MD, RPNI for her contribution on pregnancy and post-partum stroke prevention. Special thanks to our vascular neurology PFO clinic team: Shivani Daryani, PA-C, and Carla Sherman, RN, and to Carla Michelini for production assistance.

58

© Copyright. Society of Diagnostic Medical Sonography. All Rights Reserved.