Sonography of Testicular and Scrotal Pathology

M. Robert De Jong, RDMS, RVT, FAIUM, FSDMS
Bob DeJong, LLC
Where an image is more than a picture

1

SPEAKER PRESENTATION DISCLAIMER

The content and views presented are made available for educational purposes only. The information presented are the opinions of the presenter and do not necessarily represent the views of the Society of Diagnostic Medical Sonography (SDMS) or its affiliated organizations, officers, Boards of Directors, or staff members.

The presenter is responsible for ensuring balance, independence, objectivity, scientific rigor, and avoiding commercial bias in their presentation. Before making the presentation, the presenter is required to disclose to the audience any relevant financial interests or relationships with manufacturers or providers of medical products, services, technologies, and programs.

The SDMS and its affiliated organizations, officers, Board of Directors, and staff members disclaim any and all liability for all claims that may arise out of the use of this educational activity.

2

© Copyright. Society of Diagnostic Medical Sonography. All Rights Reserved.

Ultrasound Images

- Unless specified all images are from my personal collection

3

Objectives

Describe	Describe the sonographic features of testicular torsion to support timely diagnosis.
Identify	Identify sonographic characteristics of testicular malignancies using standard imaging techniques to aid clinical assessment.
List	List common scrotal “cele” pathologies and associated findings for application in diagnostic sonography.

4

© Copyright. Society of Diagnostic Medical Sonography. All Rights Reserved.



5

Scrotal Anatomy

Fibromuscular pouch

- Keeps testicles at a slightly lower temperature for spermatogenesis

Divided into two compartments by midline raphe

- Testicle
- Epididymis
- Small amount of fluid
  - 2 -3 mL
- Spermatic cord
- Blood vessels

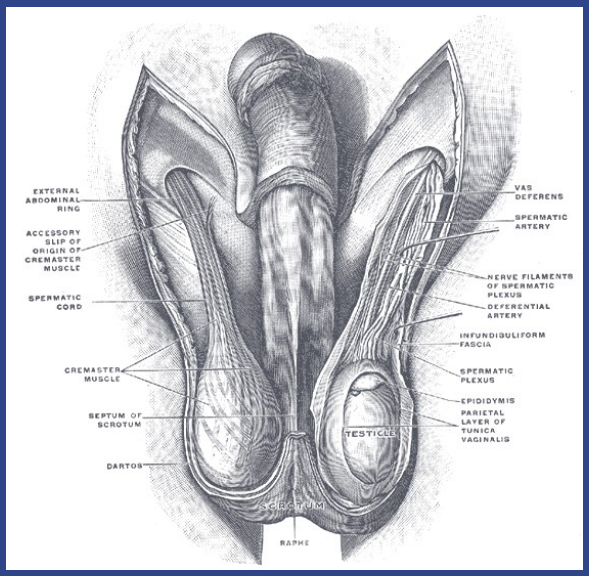

https://upload.wikimedia.org/wikipedia/commons/c/c3/Gray1144.png?utm_source=commons.wikimedia.org&utm_campaign=index&utm_content=original

6

© Copyright. Society of Diagnostic Medical Sonography. All Rights Reserved.

Seminiferous Tubules

- Highly coiled structures for spermatogenesis
- Contains roughly 250 functional compartments called lobules, with each lobule housing one to four seminiferous tubules
- Wall of each tubule is lined with a complex layer of tissue called the germinal epithelium
- Contains two primary cell types
  - Germ
  - Sertoli

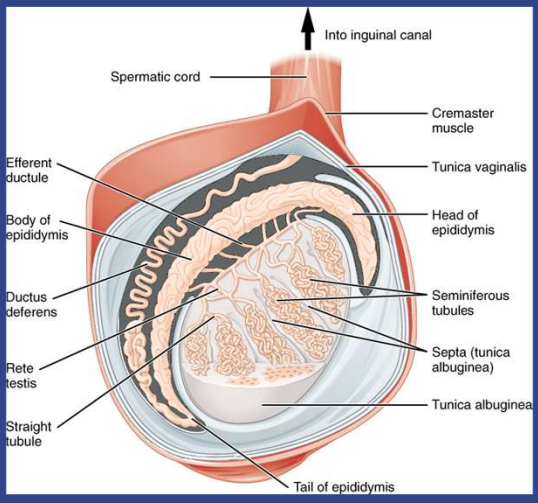

(Image credit: "Anatomy of the Testis" by OpenStax is licensed under CC BY 4.0, modifications by Jennifer Lange.)

7

Germ Cells

Unique cells possess ability to transmit genetic information

- Located within the seminiferous tubules
- Only cells in body that have half amount of chromosomes
- Cells responsible for producing sperm
- Cannot mature on their own and require a regulated environment provided by two key somatic cells
  - Sertoli
  - Leydig
- Primary origin of most testicular cancers
- Failure to develop normally is leading cause of male infertility

8

© Copyright. Society of Diagnostic Medical Sonography. All Rights Reserved.

Sertoli Cells

- Physically and chemically support, protect, and nourish developing sperm cells throughout spermatogenesis process
- Without functioning Sertoli cells, mature sperm cannot form
- Form a tight, continuous seal that separates seminiferous tubules from bloodstream protecting developing sperm from body's immune system

9

Leydig Cells

- Specialized hormone-producing cells located in interstitium surrounding seminiferous tubules
- Primary function is synthesis and secretion of testosterone

10

© Copyright. Society of Diagnostic Medical Sonography. All Rights Reserved.

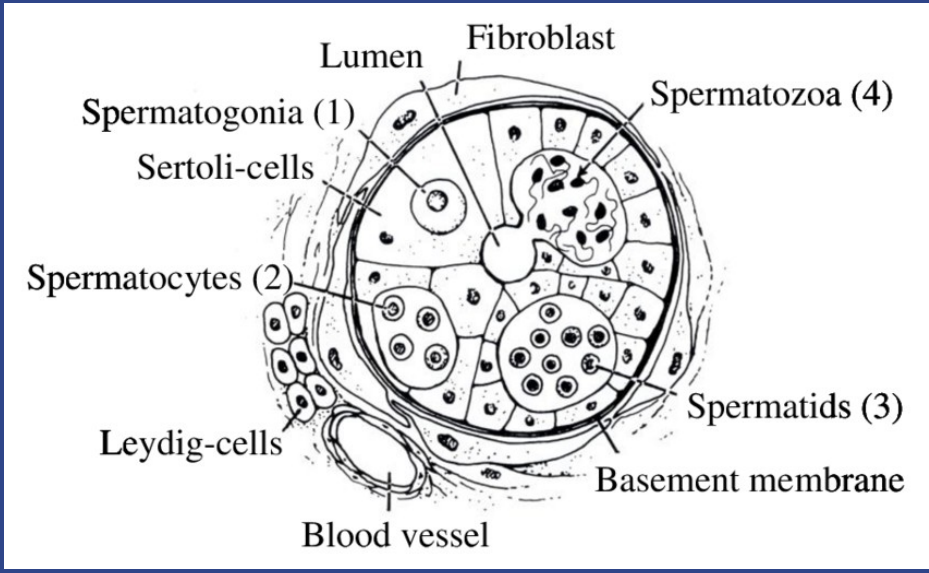

Cross-section of testicular lobule with spermatocytes (germ cells surrounded by Sertoli-cells) containing the different stages of sperm development. The number shows the chronological order in development. (Illustration: Stein H. Mortensen, IMR).

11

Exocrine Function

- 90% of cells
- Seminiferous tubules
  - Secrete an aqueous secretion to aid with sperm transport
- Seminiferous tubules empty into straight tubules
- Lead to rete testis
- Exits the testis through mediastinum testis into efferent ducts

12

© Copyright. Society of Diagnostic Medical Sonography. All Rights Reserved.

- Straight Tubules
  - Converge toward center of testis
- Rete Testis
  - Tight network of collection channels that prevents backflow
- Efferent Ductules
  - Small exit canals that drains contents out of the main testicle body into epididymis

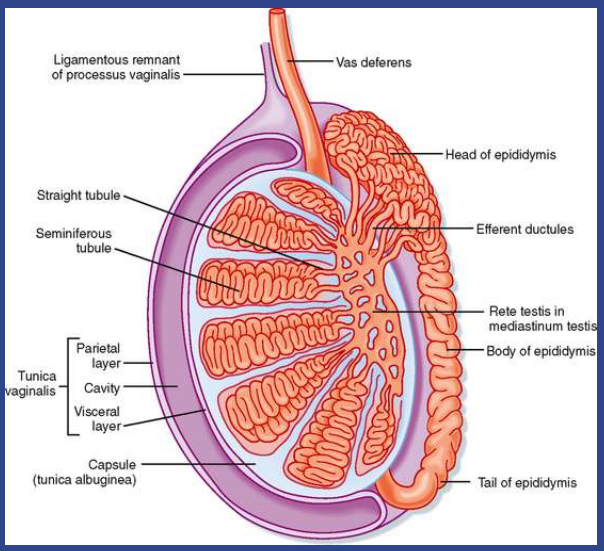

(Modified from Drake RL et al: Gray's Anatomy for Students. Philadelphia, Churchill Livingstone, 2005.)

13

Endocrine Function

10 % of cells

Leydig cells

- Located between seminiferous tubules
- Produce Testosterone

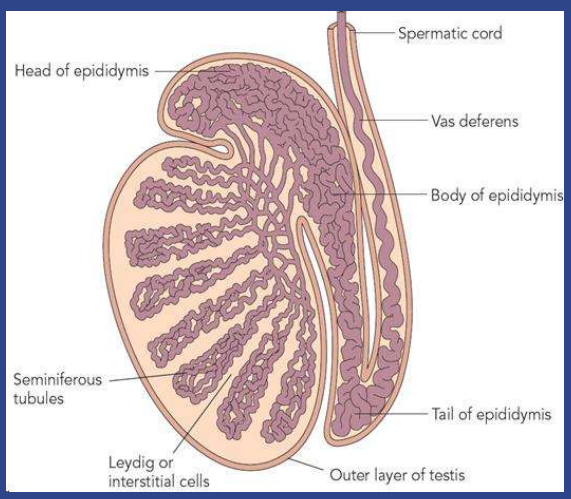

https://cdn.citl.illinois.edu/courses/CHLH206/ch3_4_anatomy_lecture/web_data/file19contents.htm

14

© Copyright. Society of Diagnostic Medical Sonography. All Rights Reserved.

Tunica Vaginalis

- Derived from processus vaginalis of peritoneum
- Precedes descent of testicle from abdomen into scrotum
- After descent portion which extends from inguinal ring to near upper part of testicle becomes obliterated
- Lower portion is a shut sac, which covers surface of testis, and is reflected on to internal surface of scrotum

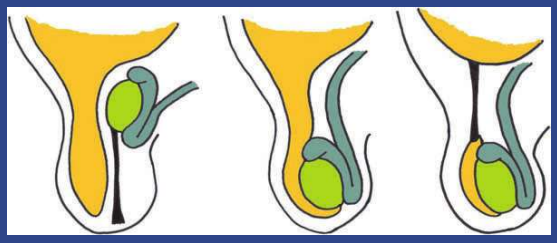

https://www.researchgate.net/figure/Diagram-shows-the-normal-embryologic-development-of-the-processus-vaginalis-which-arises_fig18_38114304

15

Tunica Vaginalis Double Membrane

Parietal layer

- Lines scrotal wall

Visceral layer

- Covers greater part of testicle and epididymis

Closed potential space situated between two layers, normally containing 1–2 mL of serous fluid

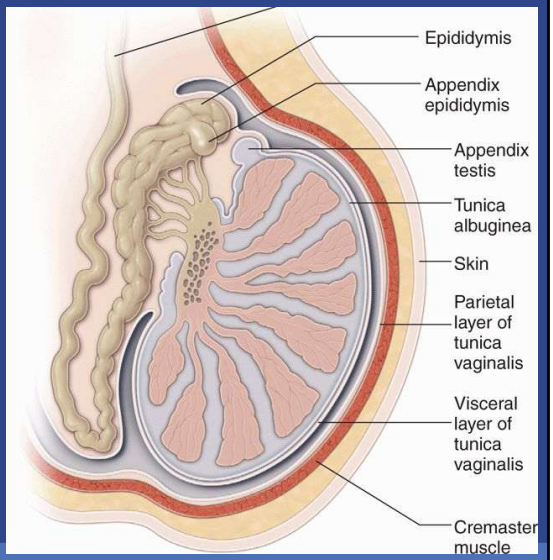

https://radiologykey.com/testicular/

16

© Copyright. Society of Diagnostic Medical Sonography. All Rights Reserved.

Tunica Vaginalis

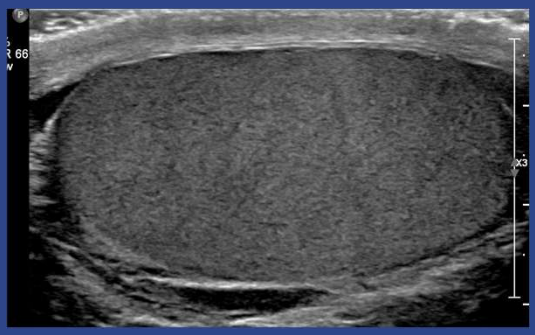

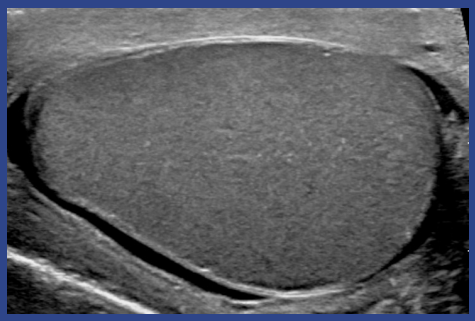

17

Bare Area

- Bare area formed posteriorly where visceral tunica vaginalis reflects to internal surface of scrotal wall, parietal layer
- Anchors the testicle firmly to the back of the scrotal wall to prevent torsion
- Incomplete posterior coverage allows essential anatomy to connect directly to the gland

18

© Copyright. Society of Diagnostic Medical Sonography. All Rights Reserved.

Bare Area



19

Tunica Albuginea

- Fibrous covering of the testicle
- Covered by the visceral layer of the tunica vaginalis
- Echogenic on ultrasound
  - Includes tunica vaginalis
- Penetrates inward to create septa that partition the testis into lobules where sperm production occurs

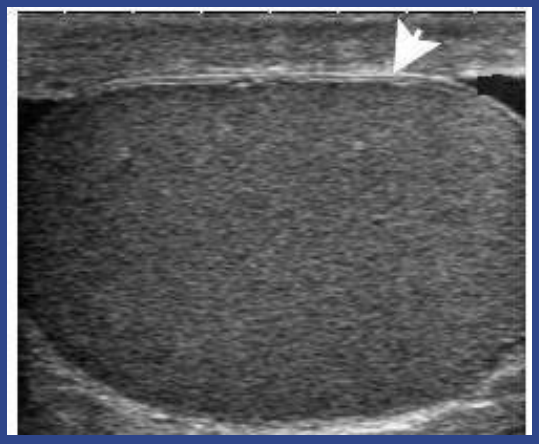

20

© Copyright. Society of Diagnostic Medical Sonography. All Rights Reserved.

Mediastinum Testis

The **mediastinum** is an infolding of the tunica albuginea that marks the entry and exit portal for the testicular arteries, veins, and ducts.

Bright, echogenic line that courses cranio-caudad within testis

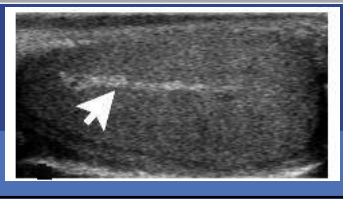

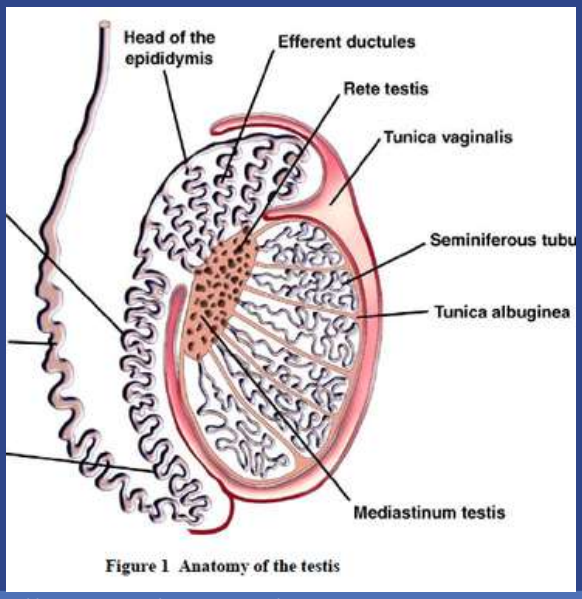

Figure 1 Anatomy of the testis

https://quizlet.com/107206062/male-reproductive-histology-flash-cards/

21

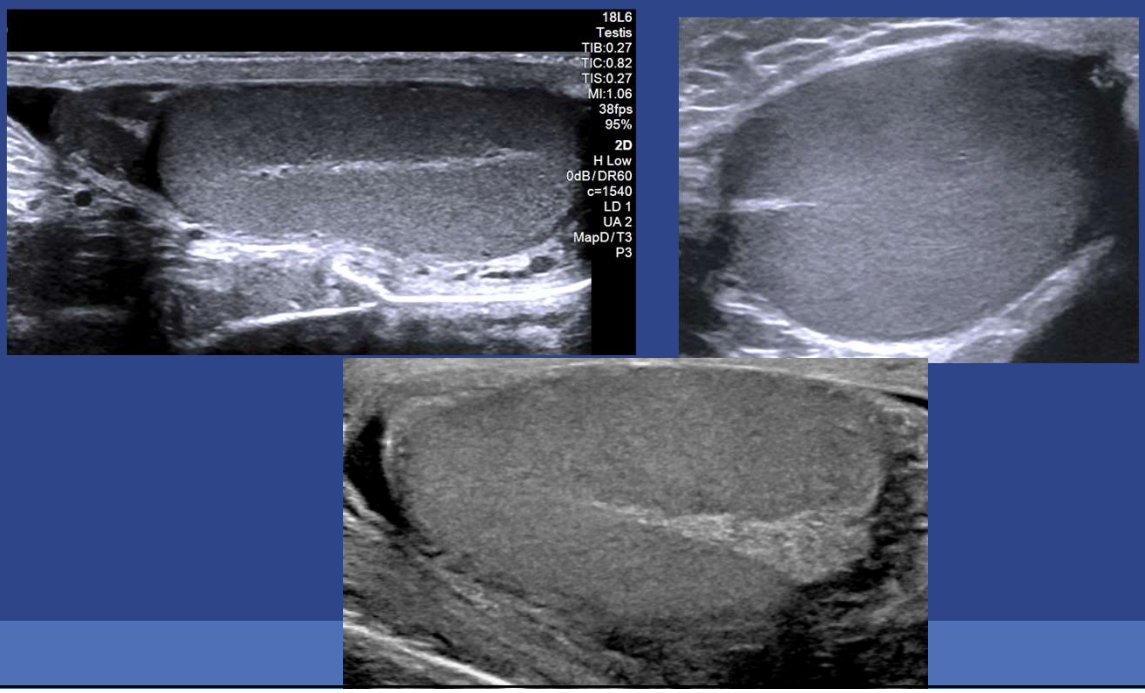

22

© Copyright. Society of Diagnostic Medical Sonography. All Rights Reserved.

Rete Testis

Seminiferous tubules end as short, straight tubules that enter the rete testis

- Converge toward mediastinum testis to form rete testis

Mesh-like reservoir network inside the mediastinum

Collects immature sperm and fluid from the seminiferous tubules and transports them toward efferent ducts

Anatomical bridge connecting site of sperm production to the site of sperm maturation and storage

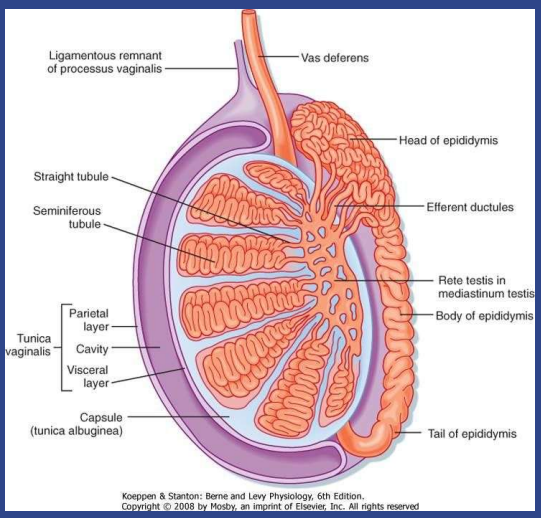

23

Rete Testis

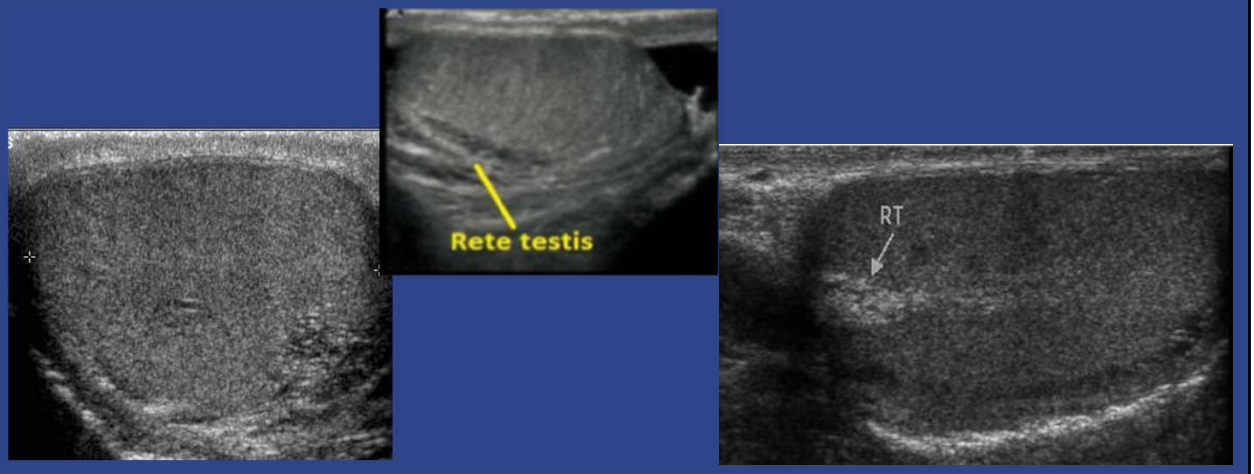

https://edcentral.co/wp-content/uploads/2022/05/Sonography_of_the_Testis.pdf

https://radiologykey.com/the-scrotum-and-penis/

24

© Copyright. Society of Diagnostic Medical Sonography. All Rights Reserved.

Dilated Rete Testis

- Benign condition
- Often bilateral
- More common in men over the age of 55 years
- Complete or partial obstruction of efferent ductules

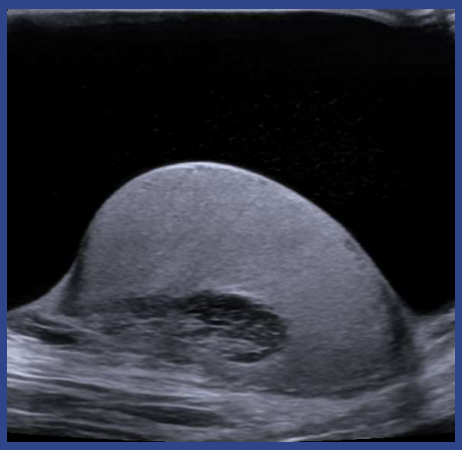

25

Epididymis

- Comma shaped narrow, tightly-coiled tube connecting the efferent ducts to the vas deferens
  - 6 to 7 cms length
  - When uncoiled, measures approximately 6 meters in length
- Runs along the posterior aspect of the testicle in a craniocaudal fashion
- At lower pole abruptly turns cephalad to become the vas deferens

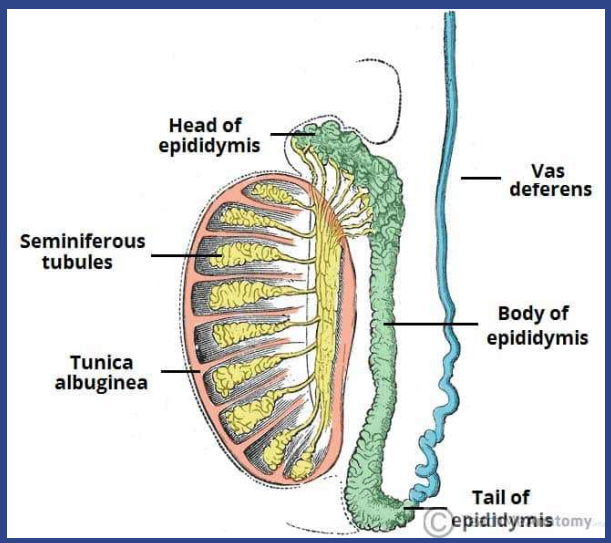

https://teachmeanatomy.info/pelvis/the-male-reproductive-system/testes-epididymis/

26

© Copyright. Society of Diagnostic Medical Sonography. All Rights Reserved.

Epididymis

Dvided into three main regions

- Head (caput epididymidis), located superiorly over the upper pole of the testis
- Body (corpus epididymidis), extending along the posterior aspect
- Tail (cauda epididymidis), positioned inferiorly near the lower pole

Head receives efferent ductules from the rete testis and tail connects to vas deferens

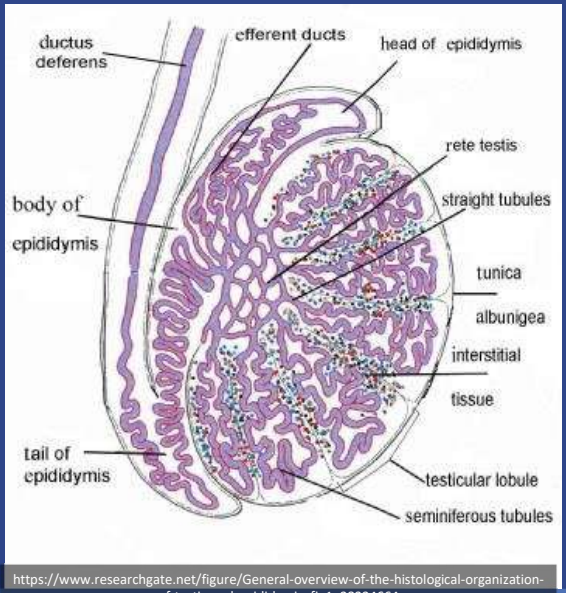

https://www.researchgate.net/figure/General-overview-of-the-histological-organization-of-testis-and-epididymis_fig1_28324664

27

Epididymis

Receives immature sperm to its head from efferent ducts

Epididymis plays a critical role in sperm maturation, enabling spermatozoa to acquire progressive motility, fertilizing capacity, and protection against the female reproductive tract environment

Stores mature sperm for up to 2 weeks until ejaculation

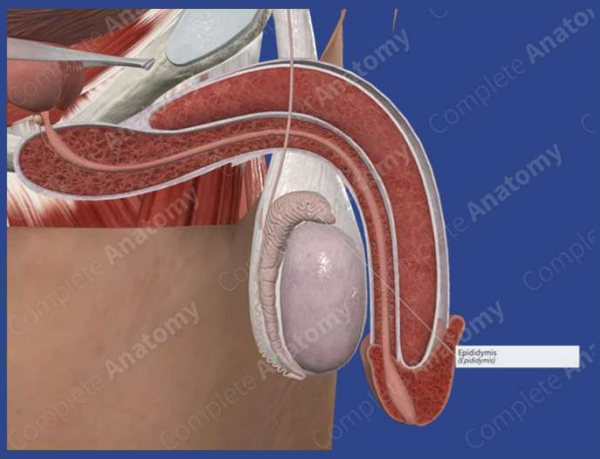

https://www.elsevier.com/resources/anatomy/urogenital-system/male-genital-system/epididymis/25145

28

© Copyright. Society of Diagnostic Medical Sonography. All Rights Reserved.

Epididymis

Curved structure

- 6 - 7 cm in length

Divided into 3 parts

- Head
  - Measures less than 1 cm
  - Superolaterally located to testicle
  - Similar in echo texture and echogenicity to the testicle
- Body
  - Narrow
  - Posterolateral to testicle
  - Usually not seen with US
  - Where sperm mature
- Tail
  - Tapers to a point
  - Continuous with the vas deferens

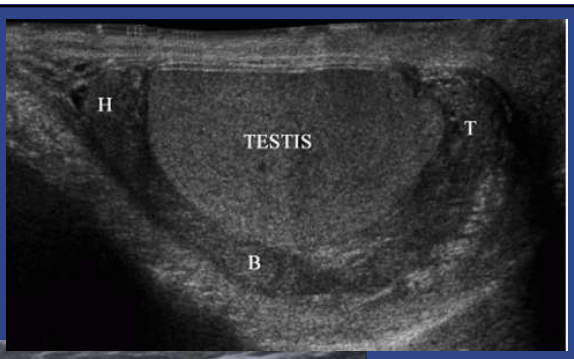



https://radiologykey.com/the-scrotum-and-penis/

Undescended testicle

29

Epididymis

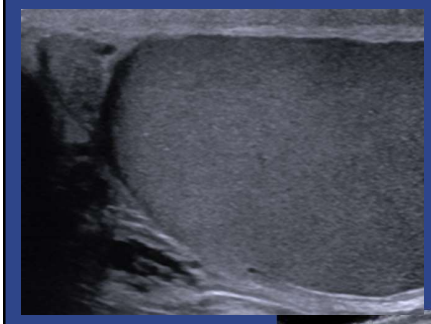

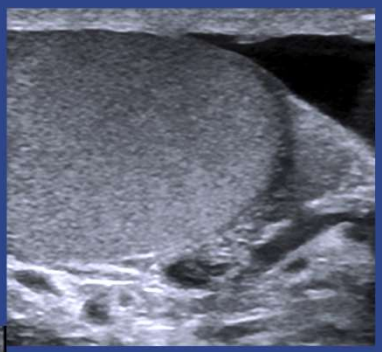

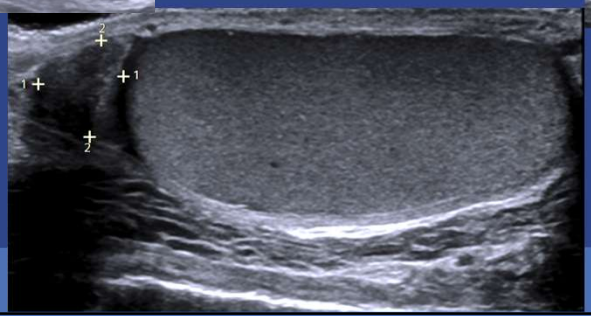

30

© Copyright. Society of Diagnostic Medical Sonography. All Rights Reserved.

Spermatic Cord

Runs from the deep inguinal ring down to each testicle

Contains

- Vas deferens
- Arteries
- Pampiniform plexus
- Nerves
- Lymphatic vessels

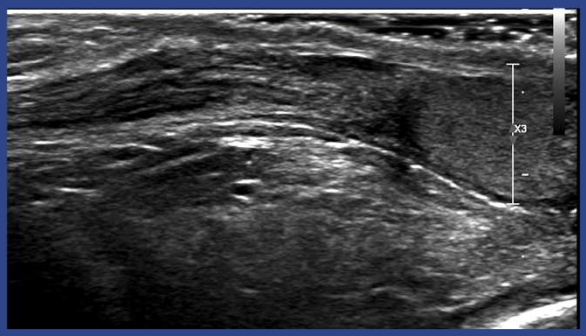

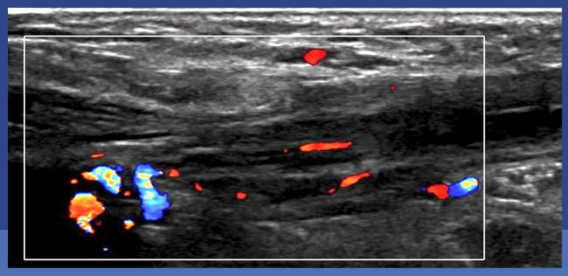

31

Breast Cancer “Ribbon”

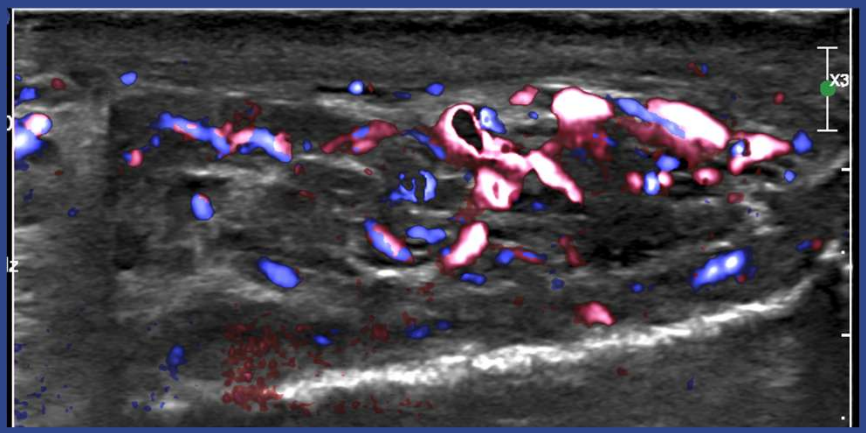

32

© Copyright. Society of Diagnostic Medical Sonography. All Rights Reserved.

Appendix Testicle

- Small protuberance off the superior aspect of the testicle
- Attached to the tunica vaginalis
- Just beneath the head of the epididymis
- Seen in 76-83% of men
- Remnant of the upper end of the Müllerian duct
  - Forms female reproductive organs

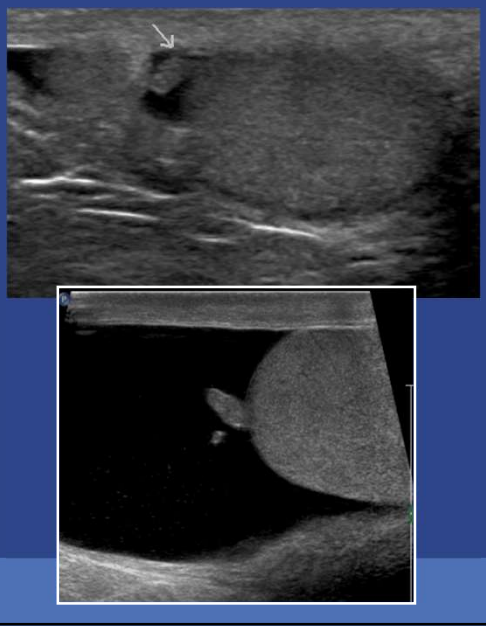

33

Arterial Supply

- Testicular artery supplies testicles and epididymis
  - Comes off anterior Aorta below level of renal arteries
- Artery of the ductus deferens or deferential artery supplies ductus deferens and epididymis
  - Branch of superior vesicle artery
    - Branch of internal iliac artery
  - Runs with ductus deferens within spermatic cord
  - Terminates with an anastomosis with testicular artery

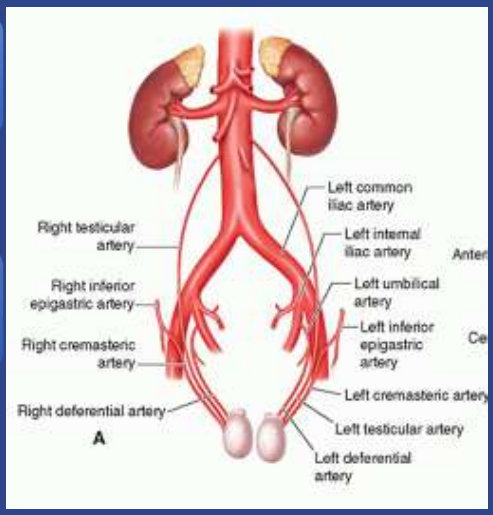

https://radiologykey.com/the-scrotum-and-penis/

34

© Copyright. Society of Diagnostic Medical Sonography. All Rights Reserved.

Arterial Supply

Cremasteric artery supplies scrotal wall and muscles

- Branch of inferior epigastric artery
  - Branch of external iliac artery
- Runs with spermatic cord
- Terminates in capsular arteries close to mediastinum and anastomoses with testicular artery

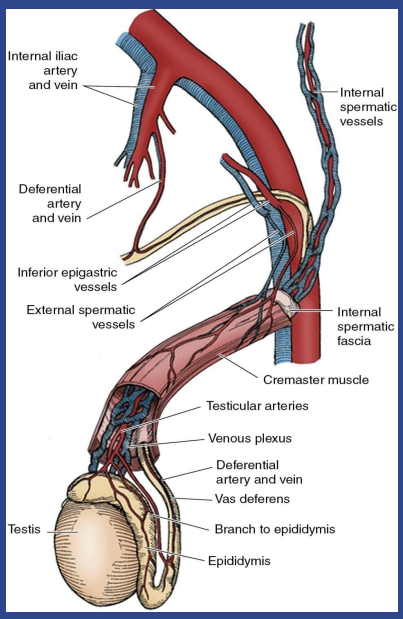

https://abdominalkey.com/male-reproductive-physiology/

35

Arterial Flow

Testicular artery

- Enters tunica albuginea in mediastinum and branches into

Capsular arteries

- Run over the testicular surface and give off

Centripetal arteries

- Run from surface to mediastinum along the septa
- Before reaching the mediastinum curve backwards and become

Recurrent rami

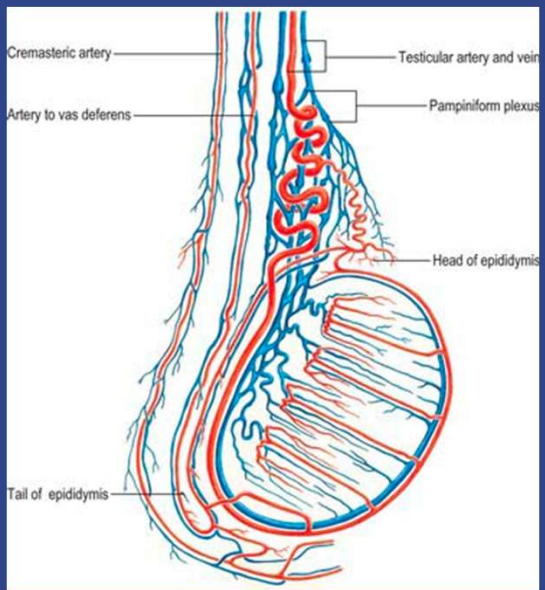

https://clinicalgate.com/male-reproductive-system/

36

© Copyright. Society of Diagnostic Medical Sonography. All Rights Reserved.

Arterial Flow



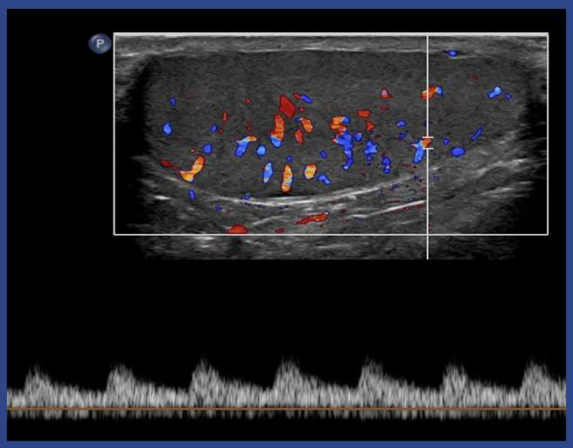

Transmediastinal Artery

37

Venous Drainage

Veins emerge from the back of testicle, and receive tributaries from the epididymis

Unite to form the convoluted Pampiniform plexus

- Eventually join to become one vein

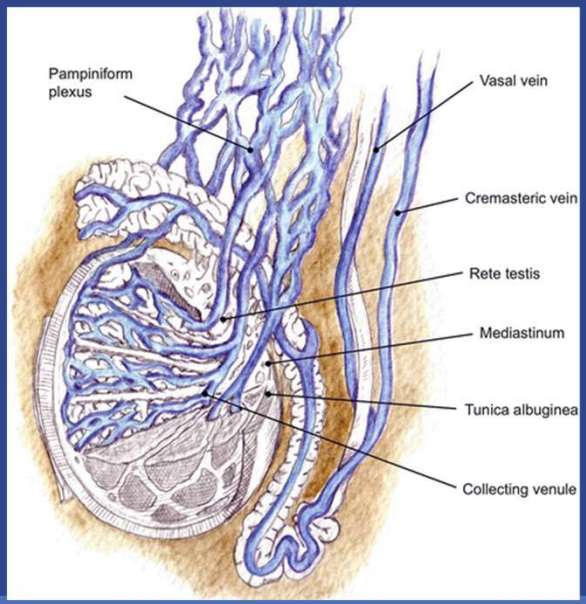

González J., Ciancio G. (2014) Vascular Diseases of the Testis. In: Lanzer P. (eds) PanVascular Medicine. Springer, Berlin, Heidelberg

38

© Copyright. Society of Diagnostic Medical Sonography. All Rights Reserved.

Testicular Veins

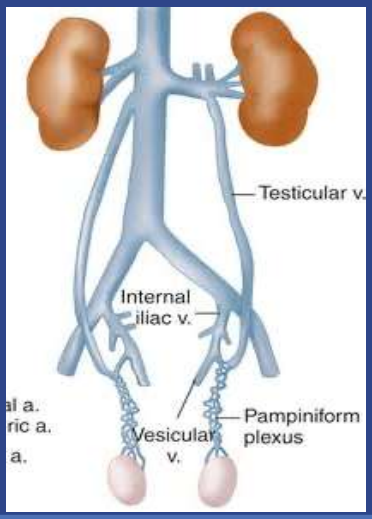

- Right testicular vein drains into IVC
- Left testicular vein drains into left renal vein
- Testicular veins have valves

https://quizlet.com/845036926/blood-supply-of-testes-flash-cards/

39

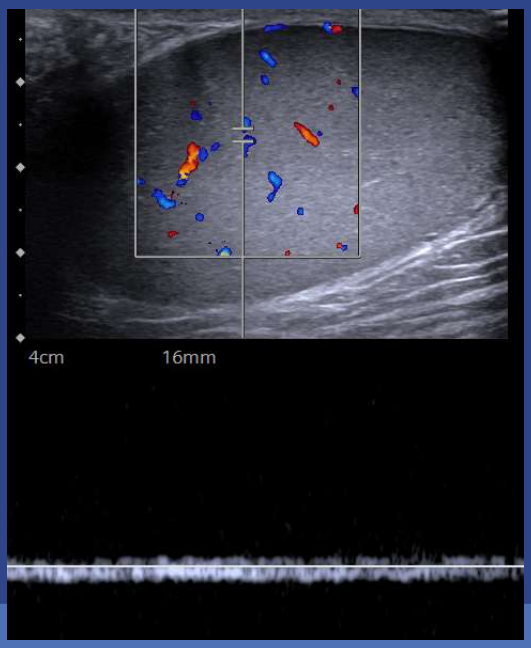

Venous Flow

- Look for darker colors = slow flow

40

© Copyright. Society of Diagnostic Medical Sonography. All Rights Reserved.

Comparing Color



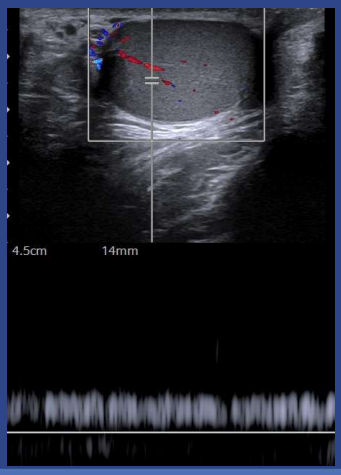

41

Sonographic Techniques

High frequency linear array transducer

- > 10 MHz

Look for symmetry



42

© Copyright. Society of Diagnostic Medical Sonography. All Rights Reserved.

Sonographic Techniques

Watch gel temperature

- Cold gel will cause the scrotum to contract making it difficult to scan the testicles

Keep the patient covered as much as possible and curtains pulled with door closed to insure patient privacy

To evaluate small, palpable nodules, the testicle can be held and supported by the sonographer's gloved hand

- Inform patient before you touch him

Patient can stabilize the testicle and point to area of concern/pain

43

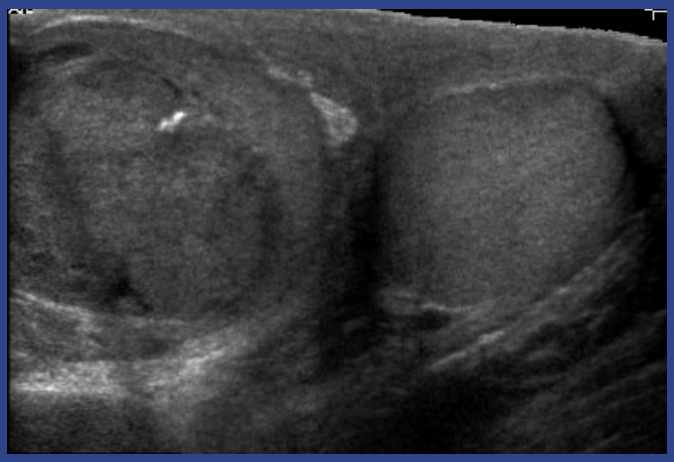

Pathology of the Testicles

44

© Copyright. Society of Diagnostic Medical Sonography. All Rights Reserved.

Scrotal Pathololgy

Most intratesticular masses are malignant

Most extratesticular pathology is benign or of an infectious process

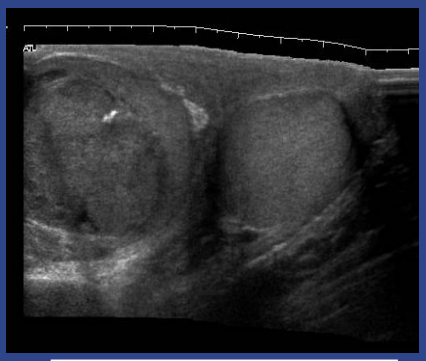

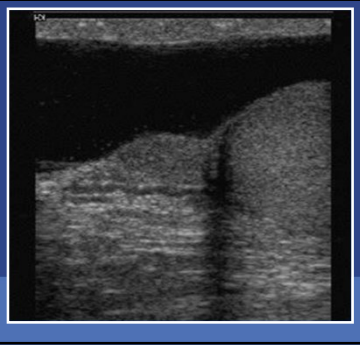

45

Testicular Cancer Statistics for 2026

- About 9,810 new cases diagnosed
  - 1 of every 250 males will develop testicular cancer at some point during their lifetime
- About 630 deaths
  - Risk of dying from very low - about 1 in 5,000
- 5-year relative survival rate in the US is > 95%
- Incidence rate been increasing
  - Mostly in seminomas
- Average age at the time of diagnosis 33
  - Largely a disease of young and middle-aged men
  - 6% of cases occur in children and teens
  - 8% occur in men over the age of 55

https://seer.cancer.gov/statfacts/html/testis.html

46

© Copyright. Society of Diagnostic Medical Sonography. All Rights Reserved.

Testicular Cancer

- 1-2 % of malignancies in men
- 4-5x more common in white males
- Most common cancer in men between ages of 15 and 34
- 75% of cases of testicular cancer occur in men between 20 and 49
- Testicular cancer is one of the most treatable forms of cancer



47

Testicular Cancer

- More than 90% of testicular cancers start in germ cells
  - Cells that make sperm.
- Two main types of testicular germ cell tumors
  - Seminomas
  - Nonseminomas
- Grow and spread differently and are treated differently

48

© Copyright. Society of Diagnostic Medical Sonography. All Rights Reserved.

Seminomas vs Non-Seminomas

- Nonseminomas tend to grow and spread more quickly than seminomas
- Seminomas are more sensitive to radiation.
- A testicular tumor that contains both seminoma and nonseminoma cells is treated as a nonseminoma
- Pure seminomas can raise HCG levels but never AFP levels
- Non-seminomas often raise AFP and/or HCG levels

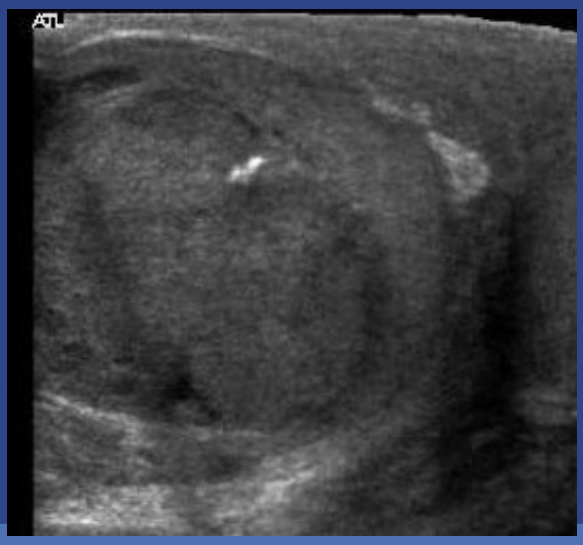

49

Tumor Markers

hCG- human chorionic gonadotropin

- Not detectable in healthy males
- Secreted by trophoblastic cells
- Elevates with
  - Choriocarcinoma
  - Embryonal cell
- May elevate with seminomas

AFP- alpha-fetoprotein

- Detectable only in minute amounts in healthy males
- Secreted by yolk sac cells
- Produced in presence of nonseminoma germ cell tumors
  - Embryonal cell
  - Yolk sac
- Never produced by pure seminomas or choriocarcinomas

50

© Copyright. Society of Diagnostic Medical Sonography. All Rights Reserved.

50

Testicular Cancer: Pure Germ Cell Tumors

Cells that make sperm

Types

- 1. Seminoma
- 2. Embryonal carcinoma
- 3. Teratoma
- 4. Choriocarcinoma
- 5. Yolk sac

51

Testicular Cancer Mixed Germ Cell Tumor

Variable in appearance and prognosis

Embryonal present in 40% of tumors

Yolk sac most common in children

- Responds well to chemo
- Almost always secretes AFP

52

© Copyright. Society of Diagnostic Medical Sonography. All Rights Reserved.

Metastatic Spread

Retroperitoneal lymph nodes most common site for metastatic spread

- **Paraaortic lymph nodes**
  - **Aortic and IVC areas**
- Distant metastasis
  - Lungs
  - Liver
  - Brain
  - Bone
  - Kidney
  - Adrenal gland
  - Spleen

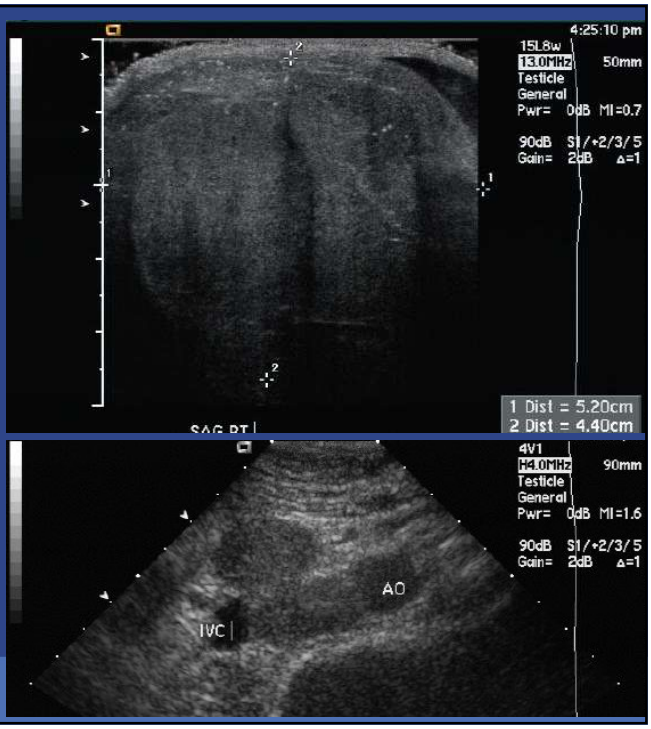

53

Nodes – Area of Renal Vessels
Lymph nodes follow veins

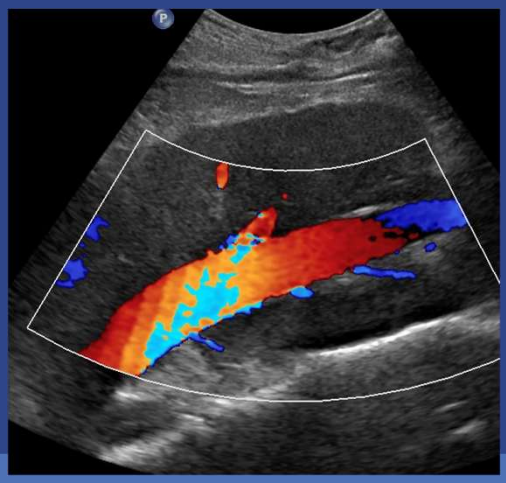



54

© Copyright. Society of Diagnostic Medical Sonography. All Rights Reserved.

Seminoma

- Most common SINGLE cell type
- Peak incidence in 4th and 5th decades
- Common cell type in mixed
- 40% of tumors
- 5-year survival rate is 95% to 99%

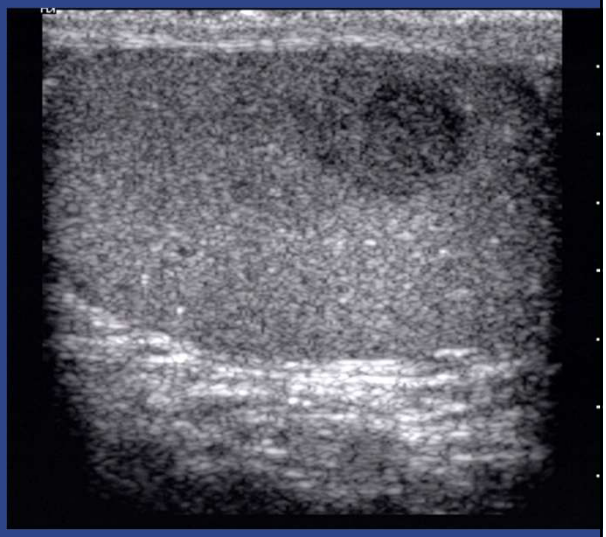

55

Seminoma

Sonographic Features

- Hypoechoic, homogenous, low reflevtivity
- Corresponds to histological findings of uniform cells containing clear cytoplasm

AFP negative

bHCG may be elevated

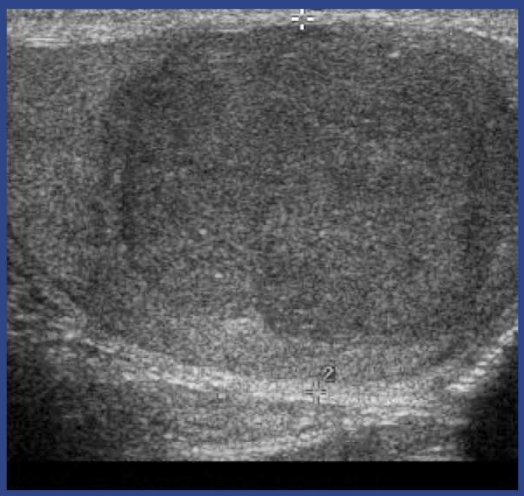

56

© Copyright. Society of Diagnostic Medical Sonography. All Rights Reserved.

Non-Seminomas

Grow more quickly and are less responsive to radiation and chemotherapy

Non-seminomas often raise AFP and/or HCG levels.

Types

- Embryonal carcinoma
- Teratoma
- Yolk sac tumors
- Choriocarcinoma

57

Embryonal carcinoma

These cells are found in about 40% of testicular tumors

When seen under a microscope can look like tissues of very early embryos

This type of non-seminoma tends to grow rapidly and spread outside the testicle

5-year survival rate is roughly 80% to 85% with distant mets

Elevated AFP and/or HCG

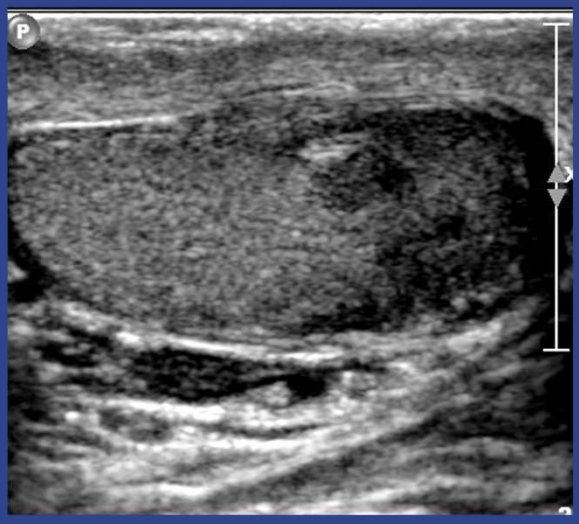

58

© Copyright. Society of Diagnostic Medical Sonography. All Rights Reserved.

Yolk Sac

- Named because cells look like yolk sac of an early embryo
- Most common malignant mass in pediatrics
  - AKA infantile embryonal carcinoma
  - 5 year survival rate is 98%
- Most will have elevated AFP
- Hypoechoic with echogenic foci



59

Choriocarcinoma

- Rare and fast-growing
- "Burned Out" tumors
- Cancer grows so fast that it outgrows its own blood supply essentially destroys itself

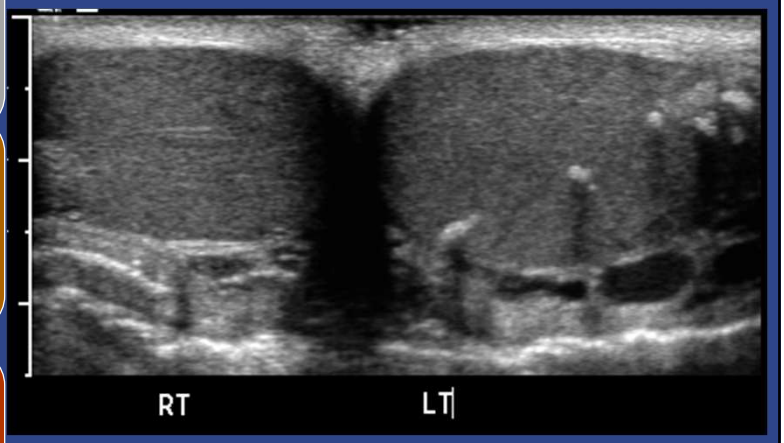

60

© Copyright. Society of Diagnostic Medical Sonography. All Rights Reserved.

Choriocarcinoma

Produces very high levels of hCG disrupting body's normal systems leading to testicular shrinkage and gynecomastia

Manifest as symptoms of metastatic disease as opposed to abnormal finding on testicular examination

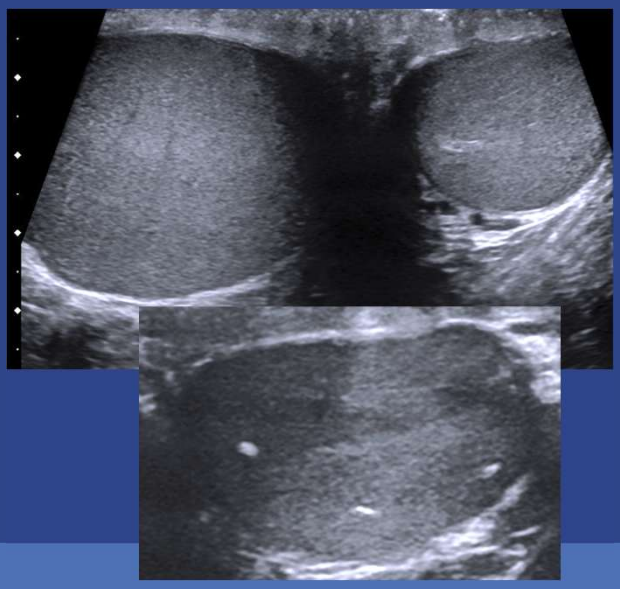

61

Choriocarcinoma

Metastasizes

- Lungs (most common place)
- Liver
- GI tract
- Adrenal gland
- Spleen
- Brain

Highly malignant

- 5 -year survival rate 1%

High levels of hCG

- Gynecomastia

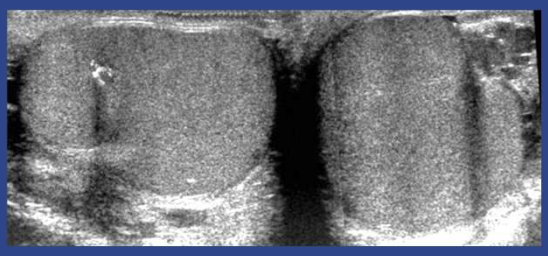

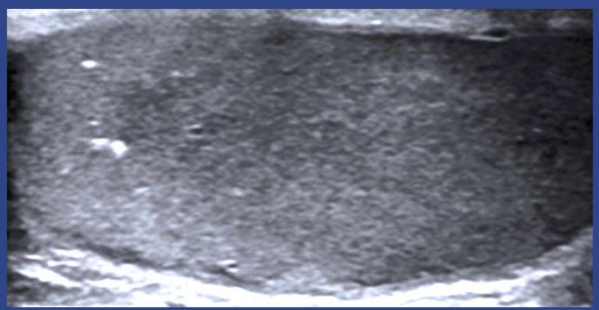

62

© Copyright. Society of Diagnostic Medical Sonography. All Rights Reserved.

Mixed Germ Cell

- Most frequent type of testicular tumor
- Contains more than one type of germ cell
  - Embryonal carcinoma and teratoma with or without seminoma
- Heterogeneous
  - Cystic areas
  - Coarse calcifications
- Elevated AFP and / or bHCG
- 5-year survival rate is roughly 72% to 85% with distant mets

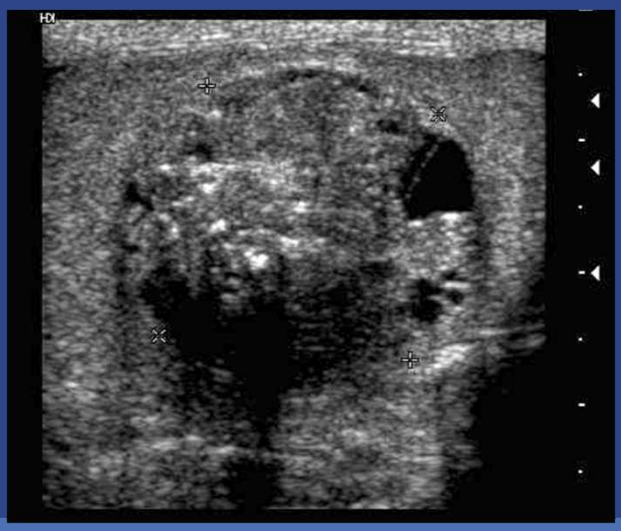

63

Sex Cord Stromal Tumors

- Leydig
- Sertoli

64

© Copyright. Society of Diagnostic Medical Sonography. All Rights Reserved.

Leydig Cell Tumor

- Cause significant changes in estrogen and testosterone levels
- Blood tests may reveal elevated levels of testosterone or estrogen
- Hormonal imbalances cause gynecomastia, erectile dysfunction, loss of libido, and infertility
- 1% to 3% of all testicular tumors
- Usually unilateral
- More common than Sertoli

65

Leydig Cell Tumor

- Boys, ages 5 to 10,frequently exhibit signs of precocious puberty, such as rapid growth, pubic hair, and vocal changes
  - Always benign
- 30–60 years of age
  - Approximately 5% to 10% of these tumors are malignant and spread to the lymph nodes, lungs, or liver
- Leydig cells tumors most often cured with surgery and combined with chemotherapy or targeted radiation
- If the tumor is malignant and spread average survival time is 1 to 2 years

66

© Copyright. Society of Diagnostic Medical Sonography. All Rights Reserved.

Leydig Ultrasound Appearance

- Echogenicity: Often hypoechoic
- Shape and Margins: Usually round or lobulated, with clear edges
- Calcifications: The large-cell calcifying subtype shows bright spots with dark acoustic "shadows" trailing behind them.
- Blood Flow: Color Doppler often reveals blood vessels feeding the mass

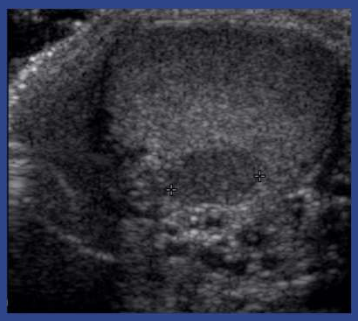

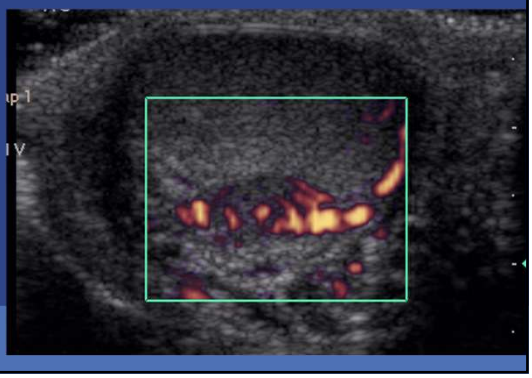

67

Sertoli

- Account for less than 1% of testicular neoplasms
- Most common symptom is a painless, solid lump
- Because some tumors secrete estrogen, up to one-third develop gynecomastia
- Diagnosed in men between 30 and 50 years old
- Approximately 10% to 25% exhibit malignant behavior.
  - Remain localized, 5-year overall survival rate is **77%**
  - Metastatic disease is roughly 20 months, as tumors do not respond well to standard chemotherapy or radiation

68

© Copyright. Society of Diagnostic Medical Sonography. All Rights Reserved.

Sertoli Ultrasound Appearance

- Hypoechoic, round intratesticular mass
  - Imaging features mimic common malignancies like seminomas
- Most often unilateral
- Difficult to differentiate from other testicular tumors



https://www.urology-textbook.com/germ-cell-tumor.html

69

Lymphoma

- Most common secondary tumor
- Most common bilateral tumor
- Most common tumor in men > 50 yrs
- Multiple hypoechoic lesions
  - Usually bilateral
- Outlook depends on the type and stage of lymphoma



70

© Copyright. Society of Diagnostic Medical Sonography. All Rights Reserved.

Lymphoma

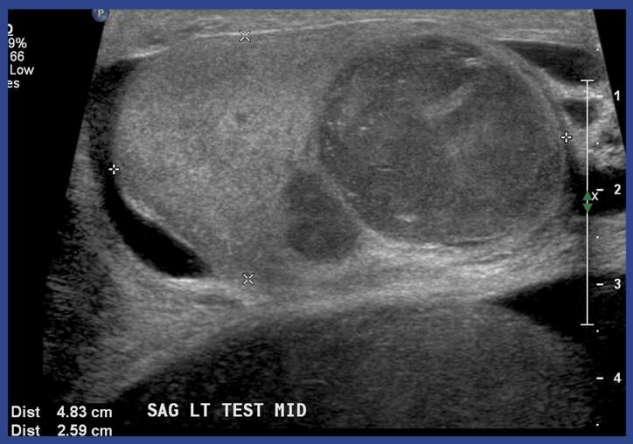

Diffuse



71

Blood Barrier

- Physical barrier between blood vessels and the seminiferous tubules
- Formed by tight, occluding and adhesion junctions between adjacent Sertoli cells
- Blood-testes barrier enables testicles to maintain a fluid balance that is good for sperm development
- Protects the developing sperm from the body's immune system, which would attack the immature sperm
- Chemotherapy won't cross allows leukemic cells to grow there

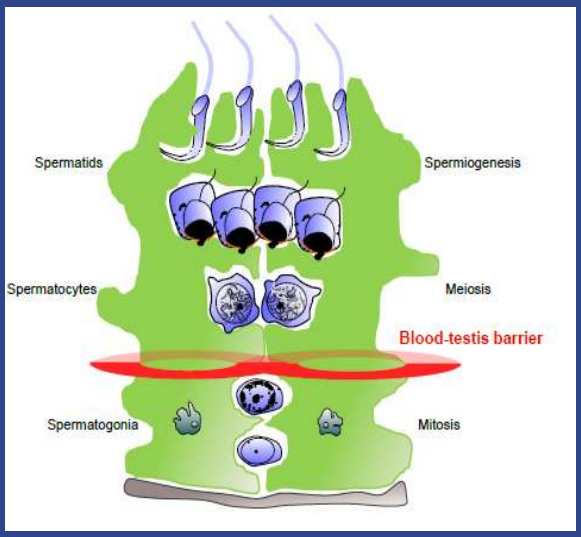

72

© Copyright. Society of Diagnostic Medical Sonography. All Rights Reserved.

Leukemia

- Leukemia infiltrates testicle
- Testicle is a sanctuary organ
  - Blood-gonad barrier inhibits chemotherapy
- Most often seen in pediatric patients
- Radiation or surgery to remove the testicle
- Sonographic Appearance
  - Hypoechoic area

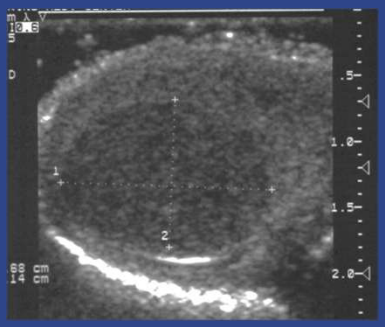

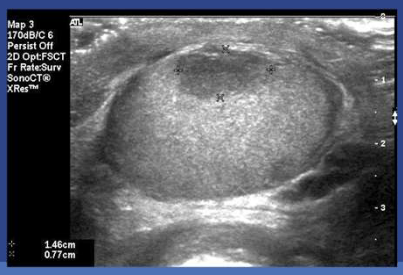

73

Leukemia

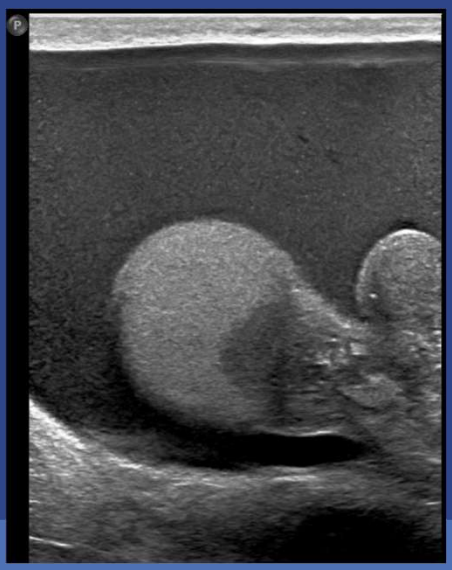

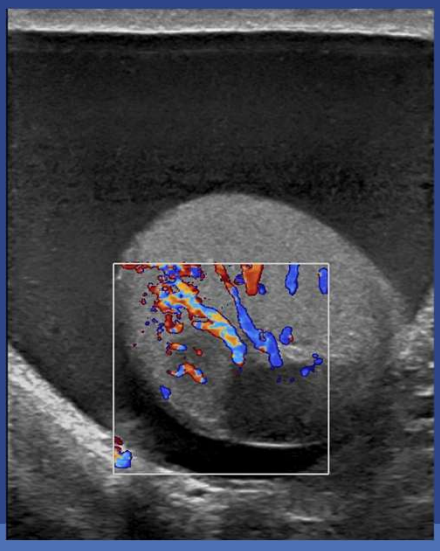

74

© Copyright. Society of Diagnostic Medical Sonography. All Rights Reserved.

Microlithiasis

- About 5% of men have microlithiasis
- Over 98% of men with microlithiasis will never develop a tumor
- Usually bilateral
  - 80%
- Calcifications in seminiferous tubules
- Multiple punctate hyperechoic foci

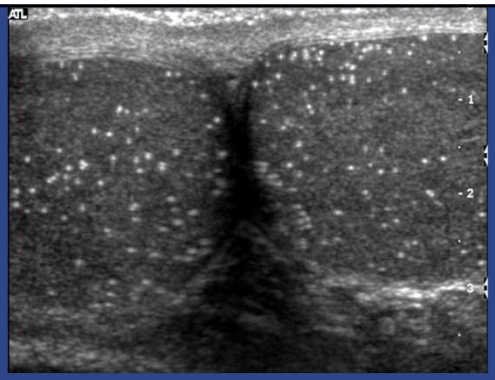

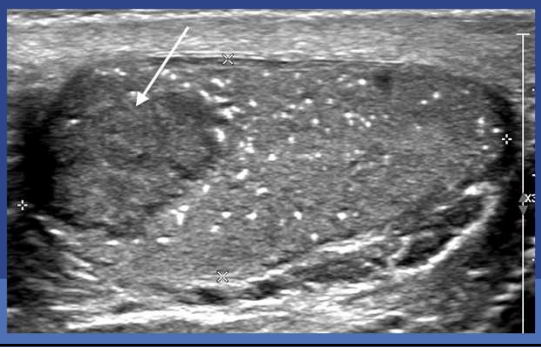

75

Cystic Lesions

76

© Copyright. Society of Diagnostic Medical Sonography. All Rights Reserved.

Tunica Albuginea Cyst

- Most common extratesticular benign lesion
- Presents as palpable mass
- Located on edge of testicle
- 40 -60 years of age
- Criteria of cyst

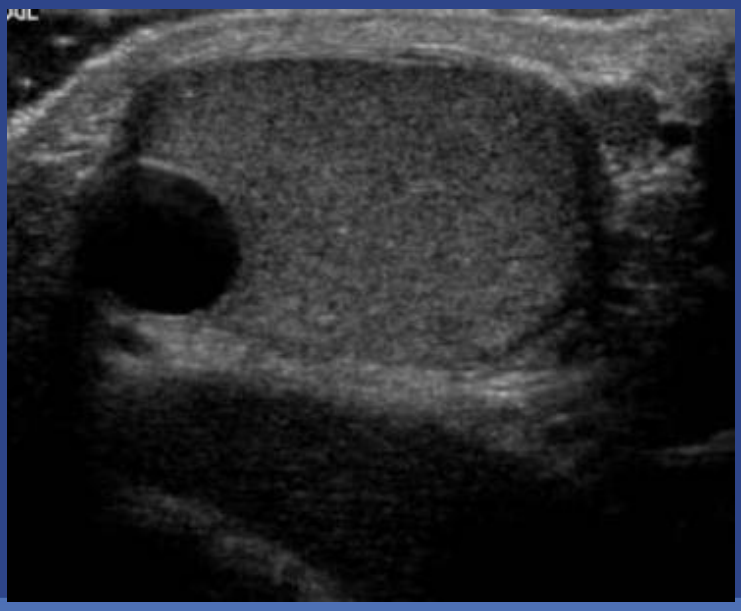

77

Tunica Albuginea Cyst

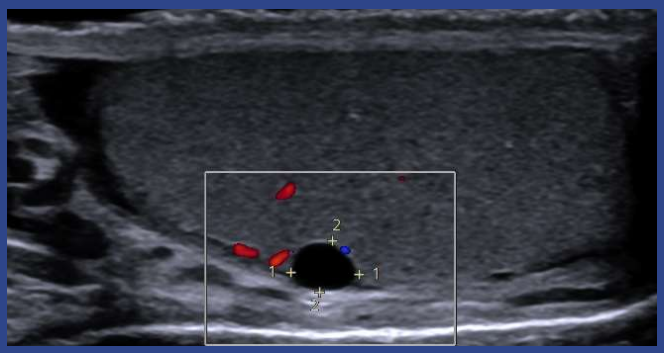

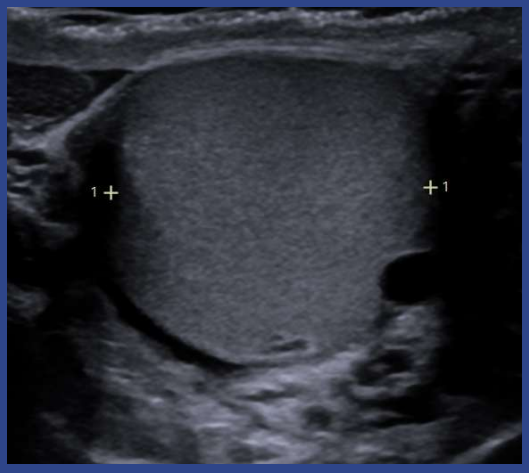

78

© Copyright. Society of Diagnostic Medical Sonography. All Rights Reserved.

Epididymal Head Cysts

- Cyst in head of epididymis composed of clear serous fluid
- Generally thought to result from a minor blockage or inflammation within the efferent tubules
- Found in up to 30% of adult men
- Does not increase risk of cancer or cause infertility

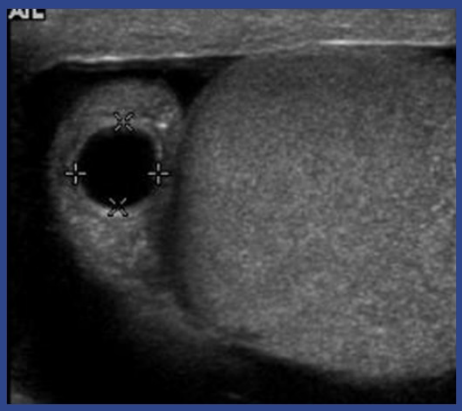

79

Epididymal Head Cysts

- Most are entirely painless and discovered incidentally during a doctor's exam or testicular self-inspection
- May be hard to differentiate from spermatocele
  - Less common than spermatoceles

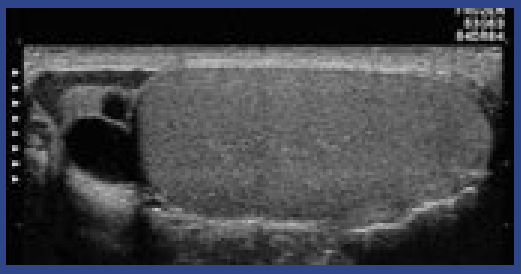

80

© Copyright. Society of Diagnostic Medical Sonography. All Rights Reserved.

Epididymal Head Cyst

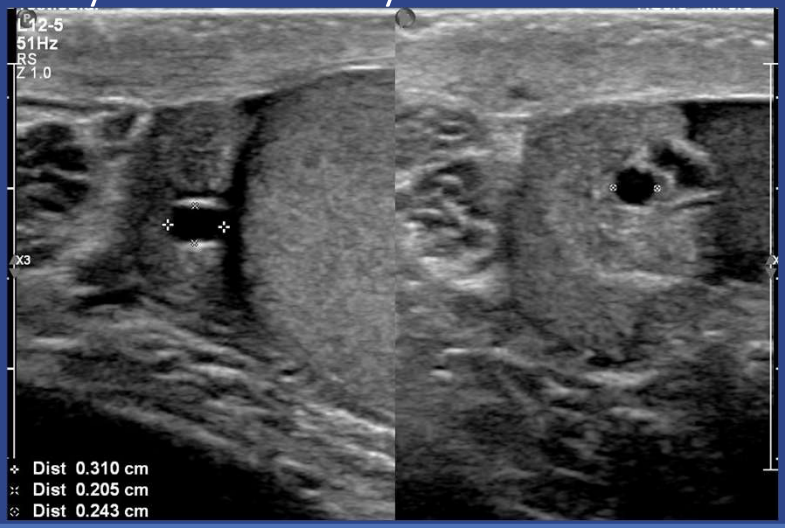

81

Spermatocele

Most common cystic condition encountered within the scrotum

- Common benign finding on routine physical examination

Filled with a clear or milky fluid that may contain non-active sperm

Blockage in one of tubes within epididymis preventing sperm transportation and cause fluid to back up

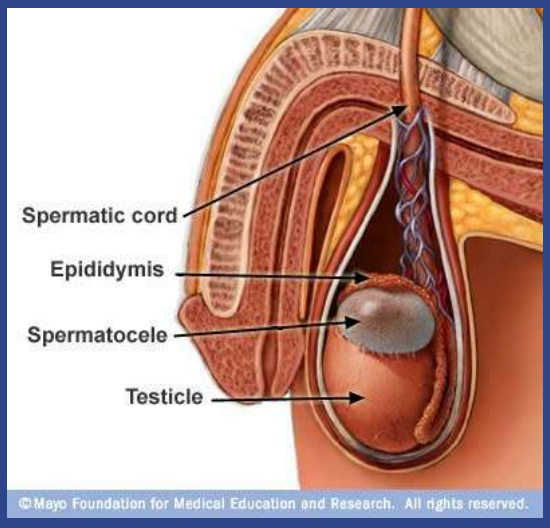

82

© Copyright. Society of Diagnostic Medical Sonography. All Rights Reserved.

Spermatocele

Affecting nearly 1-3 adult men

Does not affect fertility or increase risk of cancer

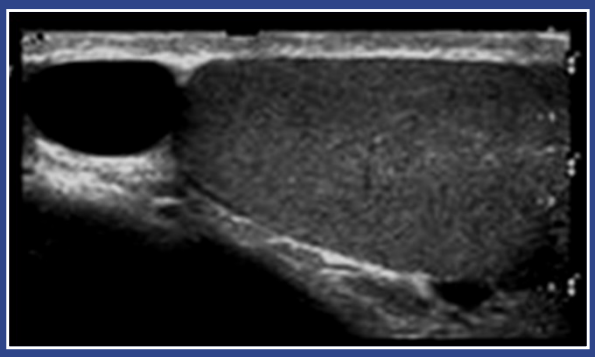

83

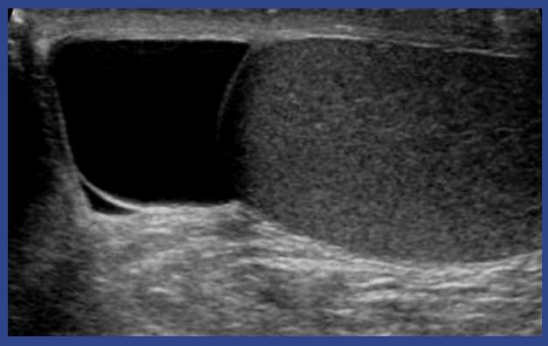

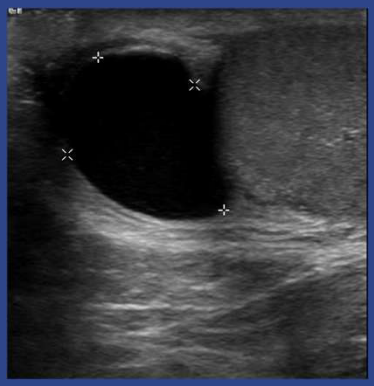

84

© Copyright. Society of Diagnostic Medical Sonography. All Rights Reserved.

Epididymal Head Cyst VS Spermatocele

- Benign, fluid-filled sacs that develop within epididymis
- Clinically identical in presentation, management, and lack of serious health risks
- Primary difference lies in composition of the fluid inside the cyst
- If become painful or excessively large surgical removal

85

Fluid Collections

86

© Copyright. Society of Diagnostic Medical Sonography. All Rights Reserved.

Hydrocele

Collection of serous fluid between the 2 layers of the tunica vaginalis

Cover anterior and lateral surfaces the testicle

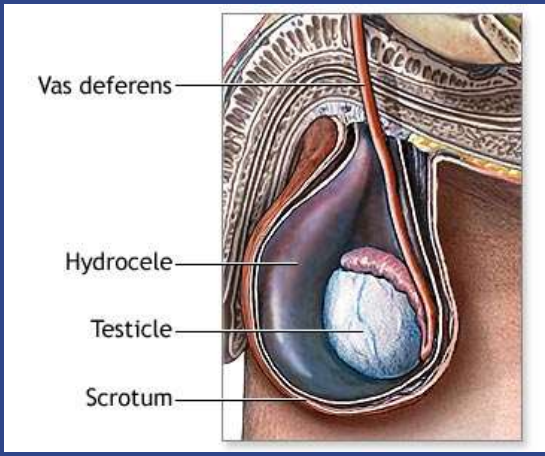

https://medlineplus.gov/ency/imagepages/19667.htm

87

Hydroceles

Inflammatory

- Neoplasms
- Trauma
- Idiopathic

Simple hydrocele

- Echo-free fluid

Complex hydrocele

- Infected
- Hematocele

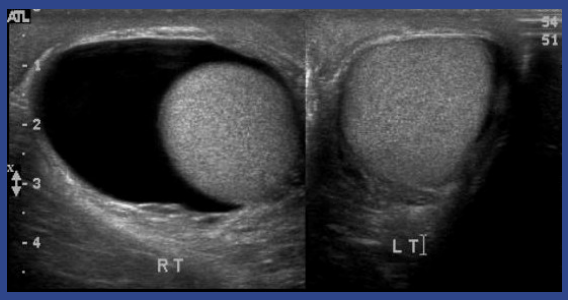



88

© Copyright. Society of Diagnostic Medical Sonography. All Rights Reserved.

Large Hydroceles May Need "Abdomial" Tx



protein aggregates

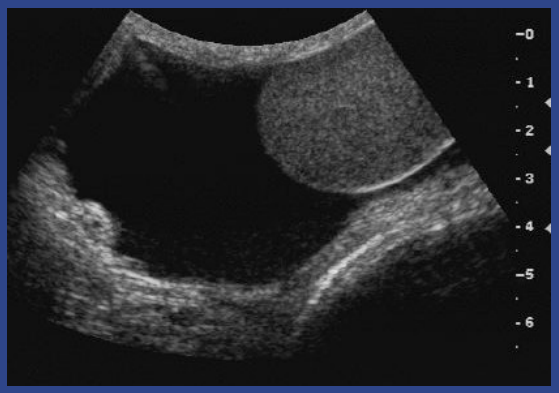

89

Varicocele

Abnormal dilation of veins of the pampiniform plexus

More common on left

- Left testicular vein inserts at a 90° angle

Occurs in approximately 15-20% of all men and in 40% of infertile men

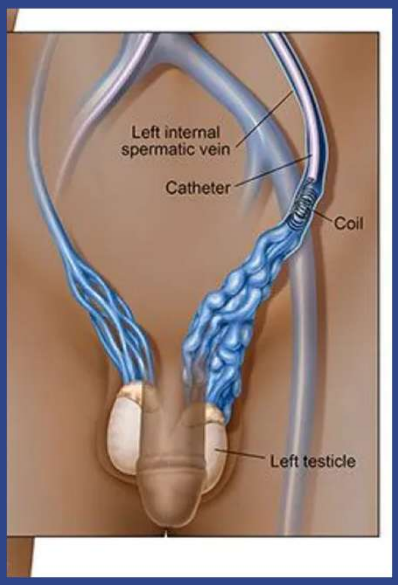

https://www.fvhospital.com/en/health-blog-post/varicocele/

90

© Copyright. Society of Diagnostic Medical Sonography. All Rights Reserved.

Varicocele

Primary varicocele

- Usually left
- Can be right or bilateral
- Caused by defective valves
  - Results in backflow of blood into pampiniform plexus causing increased pressure
    - Can lead to damage to testicular tissue

Secondary varicocele

- Due to compression of the venous drainage of the testicle
- Pelvic or abdominal malignancy is a concern when a right-sided varicocele is newly diagnosed in a patient older than 40 years of age

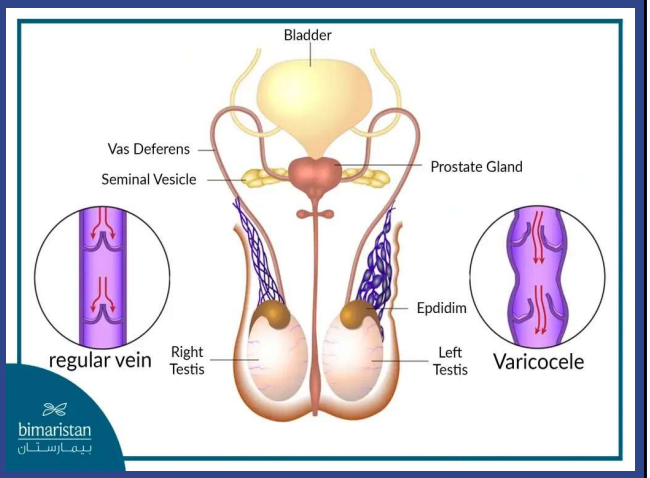

https://bi-maristan.com/en/urology/andrology/varicocele-causes/

91

Varicocele

Clinical Findings

- Sack of worms

Dull, heavy, or throbbing discomfort in the scrotum.

Discomfort that worsens with prolonged standing or physical activity and improves when lying flat

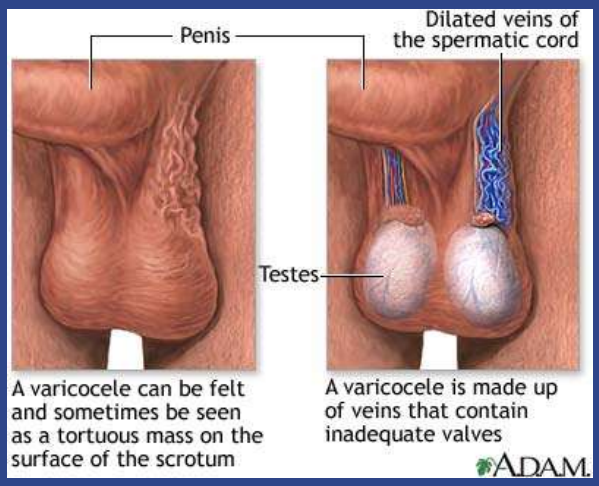

https://ssl.adam.com/content.aspx?productid=117&pid=2&gid=19472&site=annumr.adam.com&login=TRUV1989

92

© Copyright. Society of Diagnostic Medical Sonography. All Rights Reserved.

Sonographic findings

- Multiple twisted, fluid-filled tubes that resemble a "serpentine" pattern
- Veins measure > 3mm
- Increased color fill-in with Valsalva



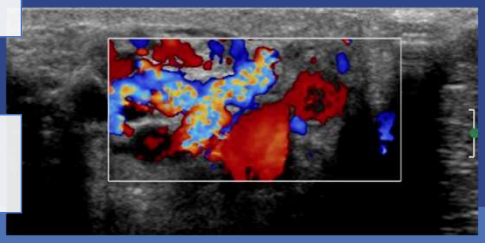

93

Valsalva



94

© Copyright. Society of Diagnostic Medical Sonography. All Rights Reserved.

Painful Scrotum/Testicle

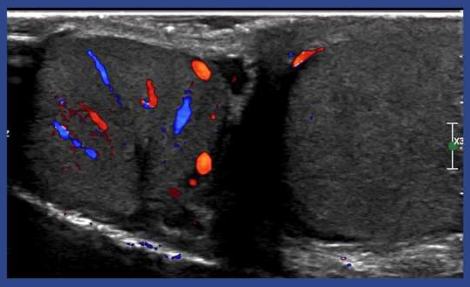

vs

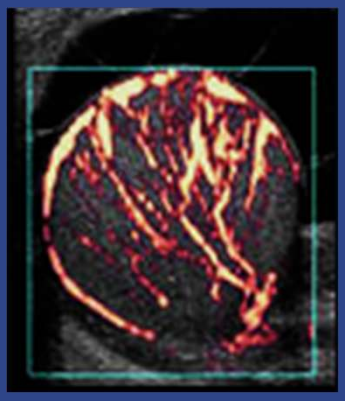

95

Acute Scrotum

Sudden onset of testicular pain

Causes

- Inflammation
  - Most frequent cause
- Torsion

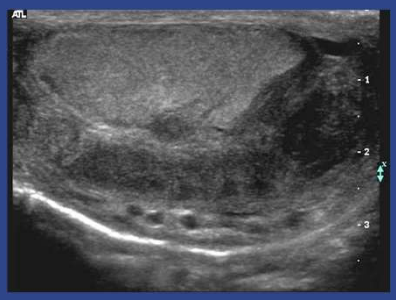

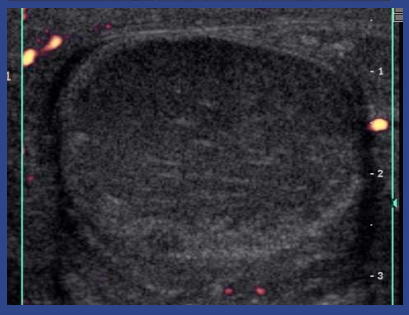

96

© Copyright. Society of Diagnostic Medical Sonography. All Rights Reserved.

Epididymitis

Causes

- Ascending infection
  - Urethra
  - Prostate
  - Bladder
- *Chlamydia trachomatis*
  - Under 35
  - STD
- *Escherichia coli*
  - Over 35
  - Urinary tract obstruction
    - BPH

Symptoms

- Warmth and swelling of scrotum
- Scrotal pain
- Reddening of scrotal skin
- Reactive hydrocele

May lead to epididymo-orchitis or abscess

97

Sonography Features

Enlarged hypoechoic epididymis

Increased flow on color Doppler

Scrotal skin thickening on affected side

Reactive hydrocele

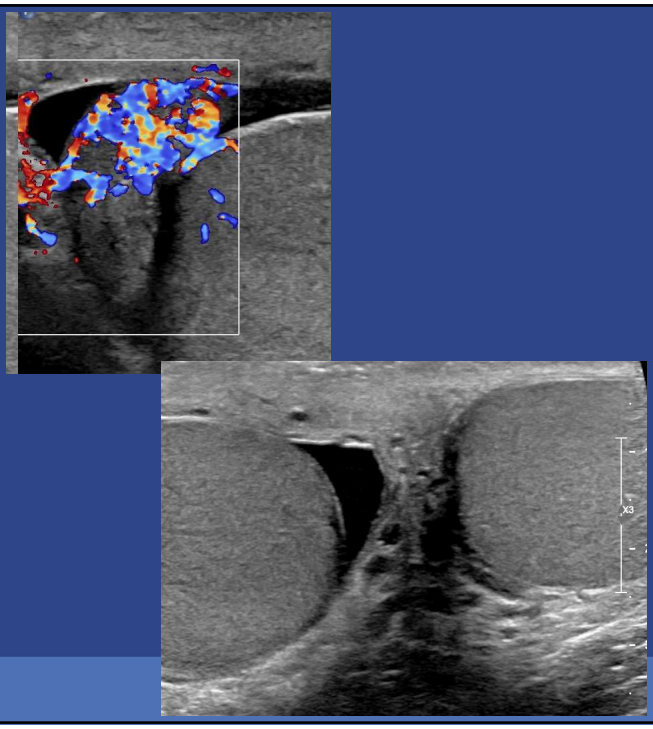

98

© Copyright. Society of Diagnostic Medical Sonography. All Rights Reserved.

Epididymitis

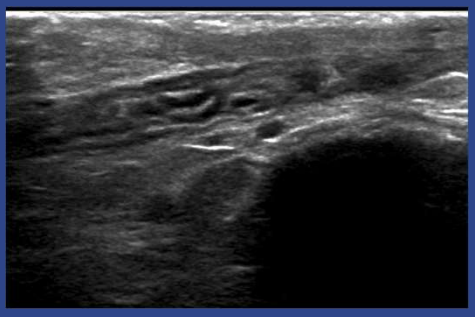



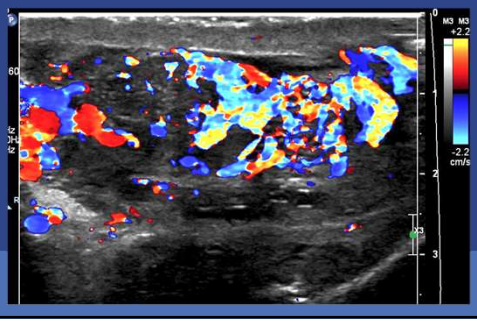

99

Epididymo-orchitis

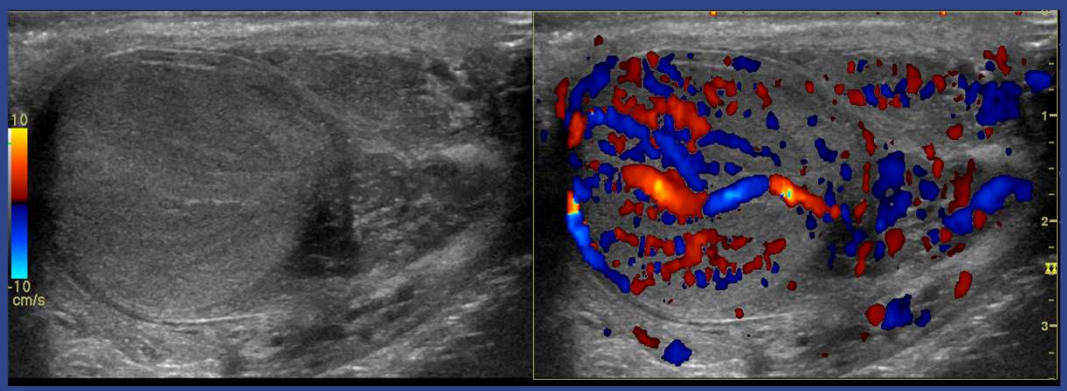

100

© Copyright. Society of Diagnostic Medical Sonography. All Rights Reserved.

Scrotal Pearl

Torsion of testicular appendix is most common cause of acute scrotal pain in prepubertal children

- Can mimic clinically testicular torsion

Appendix testis falls off

Mobile echogenic structure at bottom of scrotum

Peak age 7 to 12-year-old boys

- May be related to prepubertal enlargement

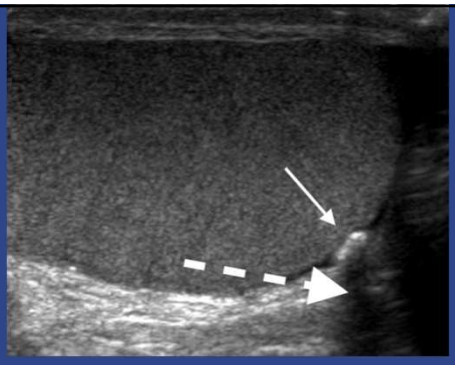

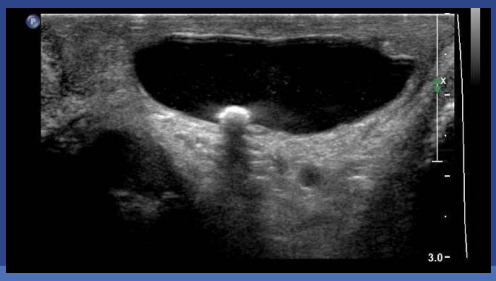

101

Torsion

Testicular torsion occurs when testicle rotates, twisting the spermatic cord that brings blood to the testicle

The reduced blood flow causes sudden and often severe pain and swelling

Most common between ages 12 - 18

True urologic emergency

Testicular viability significantly decreases 6 hours after onset of symptoms

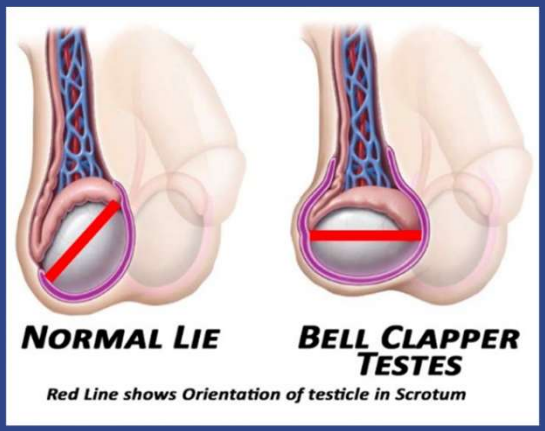

https://emottawablog.com/2023/07/testicular-torsion/

102

© Copyright. Society of Diagnostic Medical Sonography. All Rights Reserved.

Torsion

Caused by abnormal suspension of testicle in scrotal sac

Bell and clapper deformity

- Tunica vaginalis has abnormally high attachment to spermatic cord, leaving testis free to rotate
- Normal posterior attachment of the testicle to scrotum is absent
- Allows testicle to hang freely and swing like a bell clapper

Usually bilateral



https://www.amazon.com/dp/B09D3JMVHL?lv=shuf&channelId=500&plpRedirect=mhFallback&th=1

103

Bell Clapper

Anatomical defect in the tunica vaginalis allowing testicle to rotate when cremasteric muscle contracts

Twisting of testicle initially causes compromised venous return and can lead to arterial obstruction

Need 540° for complete torsion

Prolonged testicular torsion will result in the death of testicle

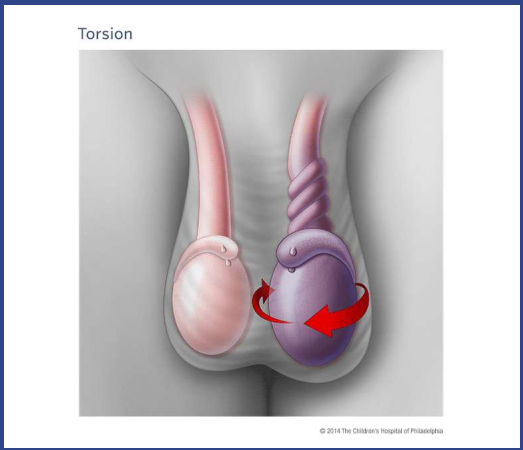

104

© Copyright. Society of Diagnostic Medical Sonography. All Rights Reserved.

Torsion

- Testicular torsion ranges from 180 degrees (half a turn) to 720 degrees (two full turns).
- Twists of less than 360 degrees typically block blood flowing *out* of the testicle
- Twists greater than 540 degrees block blood flowing *in*, becoming a critical medical emergency.

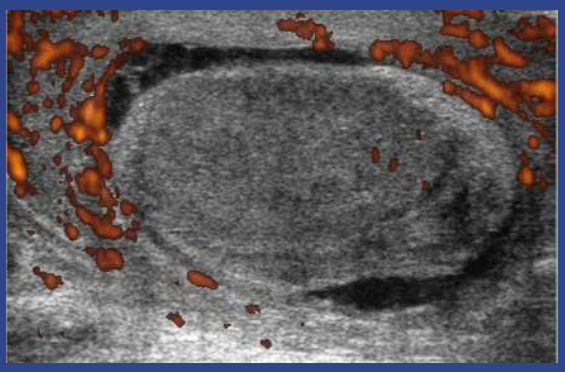

105

Torsion

Salvage rates

- 80 -100% - first 6 hours
- 70% - 6 - 12 hours
- 20% - 12 - 24

Sonographic findings

- Swollen hypoechoic testicle
- Lack of flow inside testicle
- Pediatrics can be very difficult
  - Use abdominal transducer

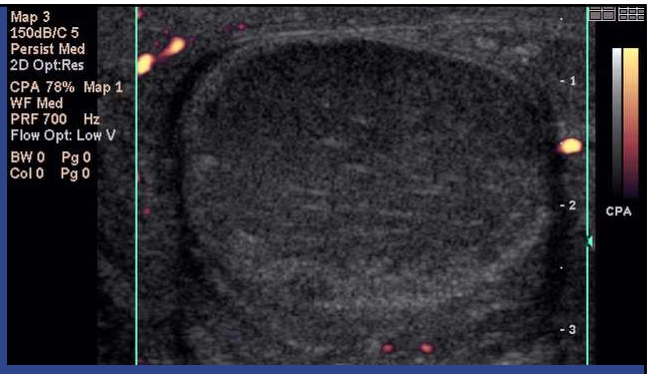

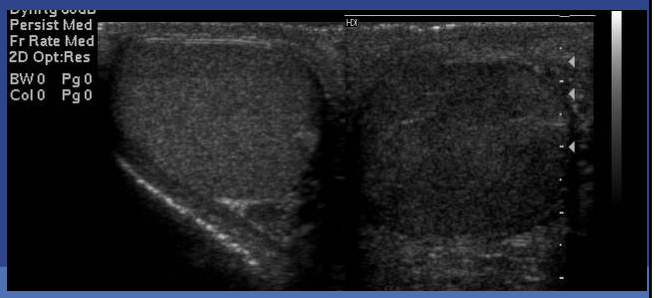

106

© Copyright. Society of Diagnostic Medical Sonography. All Rights Reserved.

Sonographic Exam

Gray

- Gray Scale
  - Quickly scan for any intra-testicular pathology
  - Evaluate for any abnormalities

Color

- Color Doppler
  - Scan unaffected side first
  - Adjust color gain, wall filter and color velocity scale to proper flow settings
  - Obtain Doppler signal of intra-testicular artery

107

Sonographic Exam

Evaluate side in question

DO NOT CHANGE ANY CONTROLS

- Increased flow = epididymitis
- No flow = suspect torsion
  - Adjust controls further to try and elicit any signal
- Pitfall
  - Do not confuse peri-testicular flow for intra-testicular flow

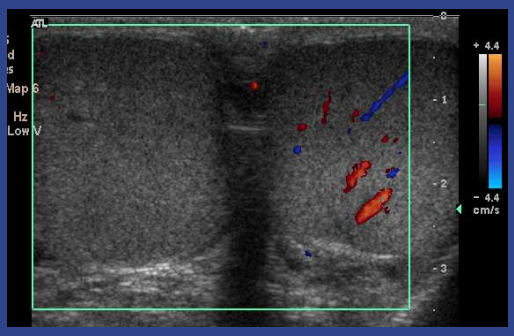

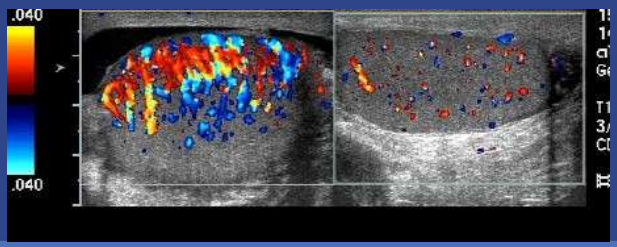

108

© Copyright. Society of Diagnostic Medical Sonography. All Rights Reserved.

Torsion

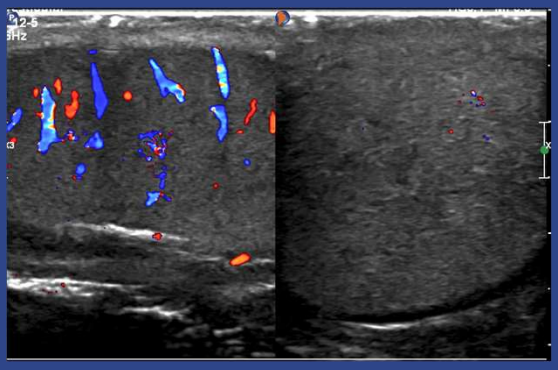

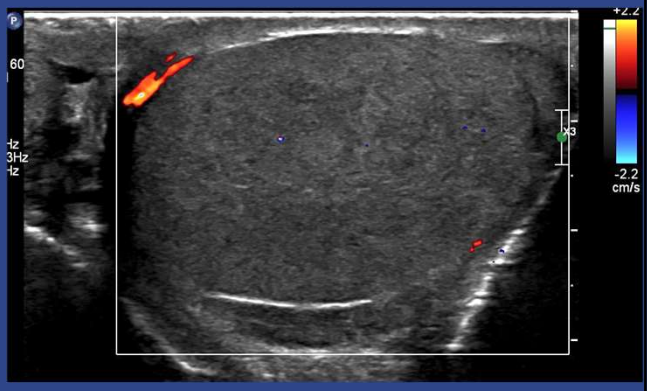

109

Torsion

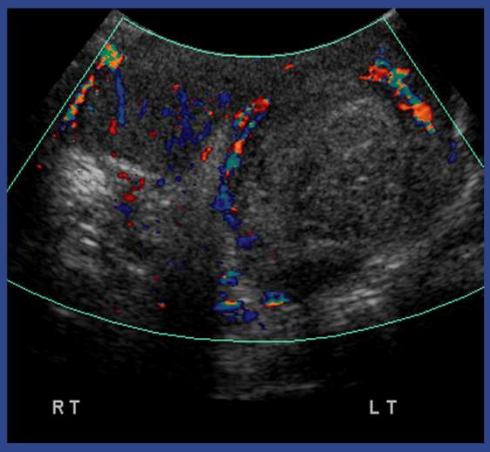

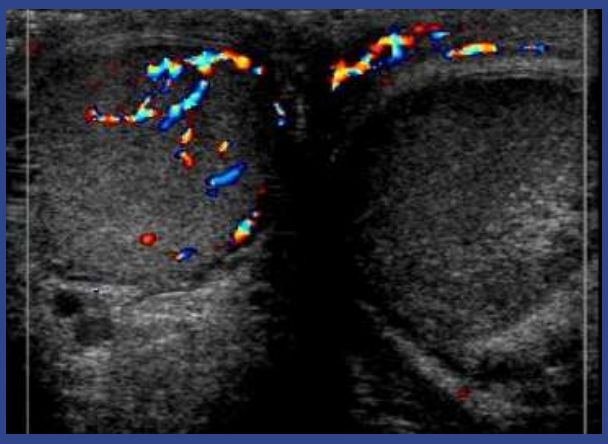

110

© Copyright. Society of Diagnostic Medical Sonography. All Rights Reserved.

Whirlpool Sign

- Whirlpool sign is an acute rotation of spermatic cord observed transverse plane
- Defined as abrupt change in course of spermatic cord with a spiral twist at external inguinal ring
- Reliable and direct sonographic sign that implies torsion of spermatic cord and testis

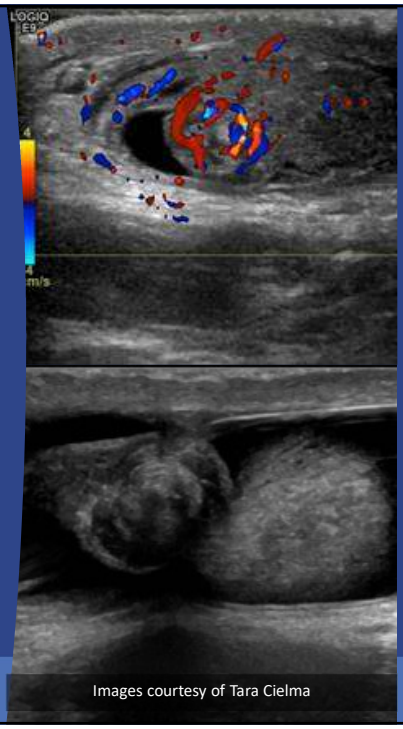

Images courtesy of Tara Cielma

111

Whirlpool Sign

- Whirlpool sign can be present even when Doppler shows normal blood flow to the testicle
- Spiral-like pattern caused by twisting of spermatic cord
- Clinicians rely on physical twist rather than waiting for blood flow to cease, which can take hours to become apparent
- Sensitivity of 73-92% and a specificity of up to 99%, making it incredibly accurate

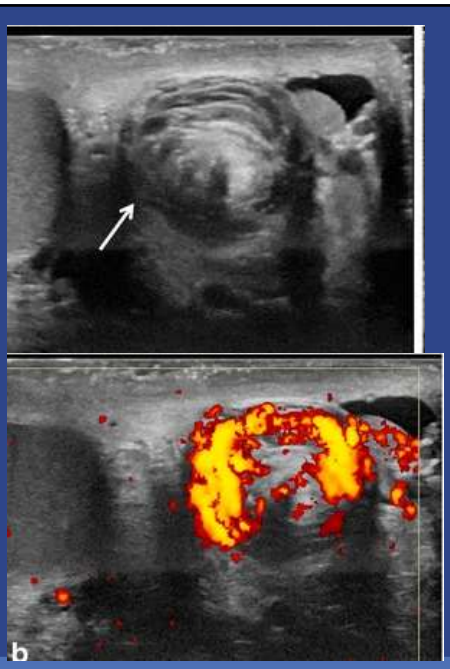

https://link.springer.com/article/10.1007/s00247-018-4093-0/figures/2

112

© Copyright. Society of Diagnostic Medical Sonography. All Rights Reserved.

Torsion and Detorsion

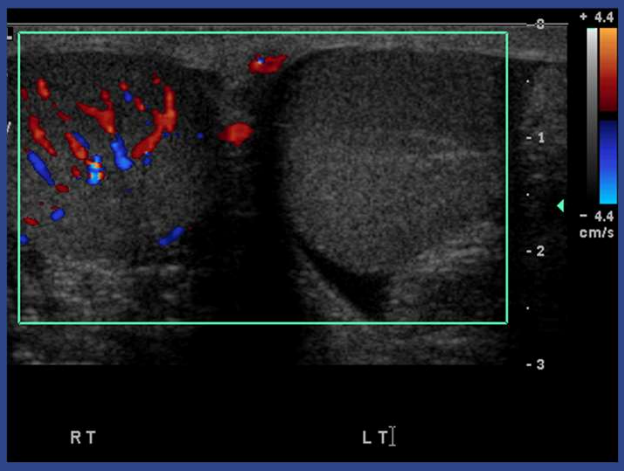

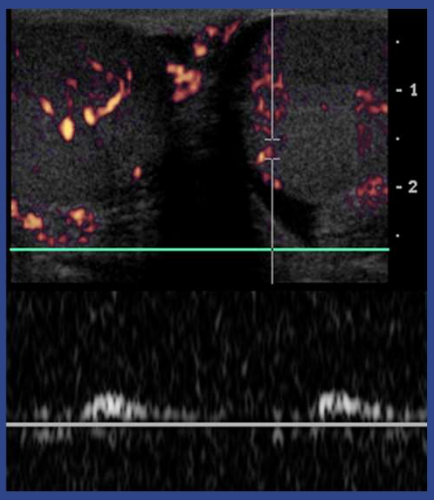

113

Detorsion

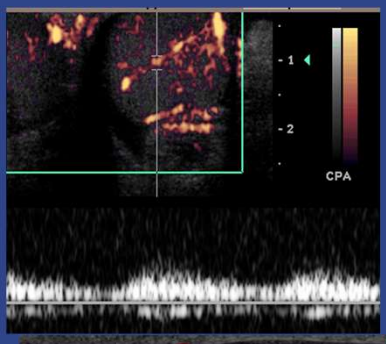

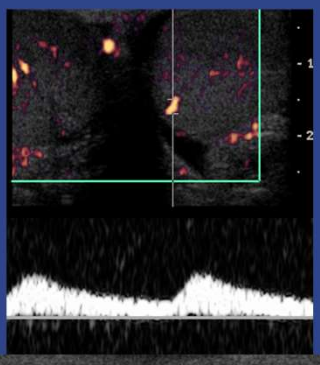

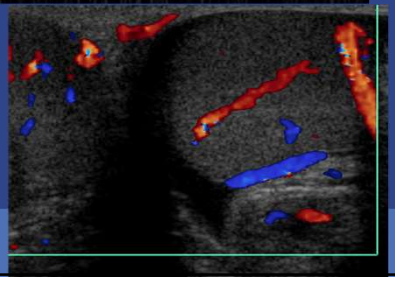

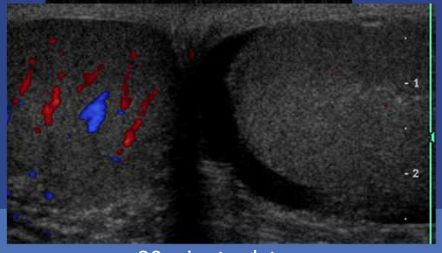

20 minutes later

114

© Copyright. Society of Diagnostic Medical Sonography. All Rights Reserved.

Nonscrotal Causes of Acute Scrotal Pain

- Referred for scrotal US
- Exam is normal
- Spermatic nerves originate from renal and intermesenteric plexus
- Reasons
  - Kidney stone
  - Retroperitoneal hematoma
  - Retroperitoneal Mass
  - Acute pancreatitis
- Inguinal hernia
  - Causes testicular ischemia
  - Direct compression of nerves

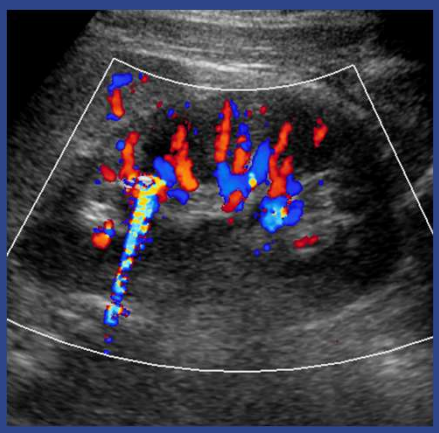

115

References

1. DeJong MR. *Sonography Scanning: Principles and Protocols, 5th Edition.* Saunders;2020
2. Hagen-Ansert SL. *Textbook of Diagnostic Sonography, 9th Edition.* Elsevier; 2022
3. Nolan T, Kawamura D. *Diagnostic Medical Sonography Series: Abdomen and Superficial Structures 5th Edition.* Wolters Kluwer Health; 2022
4. Rumack CM, Wilson SR, Charboneau JW, Levine D. *Diagnostic Ultrasound 4th Edition.* Mosby 2011
5. Patel AP. Anatomy and physiology of chronic scrotal pain. *Transl Androl Urol*. 2017;6(Suppl 1):S51-S56. doi:10.21037/tau.2017.05.32
6. *https://emedicine.medscape.com/article/1899075-overview#showall*

116

© Copyright. Society of Diagnostic Medical Sonography. All Rights Reserved.

References

7. Gaddam SJ, Bicer F, Chesnut GT. Testicular Cancer. [Updated 2023 May 27]. In: StatPearls [Internet]. Treasure Island (FL): StatPearls Publishing; 2026 Jan-. Available from: https://www.ncbi.nlm.nih.gov/books/NBK563159/

8. https://en.wikipedia.org/wiki/Spermatocele

9. https://en.wikipedia.org/wiki/Epididymal_cyst.

10. Huzaifa M, Moreno MA. Hydrocele. [Updated 2023 Jul 3]. In: StatPearls [Internet]. Treasure Island (FL): Stat Pearls Publishing; 2026 Jan-. Available from: https://www.ncbi.nlm.nih.gov/books/NBK559125/

11. D'Souza D, Silverstone L, Knipe H, et al. Varicocele. Reference article, Radiopaedia.org (Accessed on 14 Aug 2026) https://doi.org/10.53347/rID-4631

12. Gaillard F, Silverstone L, Le L, et al. Testicular torsion. Reference article, Radiopaedia.org (Accessed on 14 Aug 2026) https://doi.org/10.53347/rID-10959

117

- Questions?

118

© Copyright. Society of Diagnostic Medical Sonography. All Rights Reserved.