Liver Elastography: Why do we do it? How do we do it? Where are we going?

Ryan Fuller, BS, RDMS, RDCS, RVT

1



Presenter(s): Ryan Fuller, BS, RDMS, RDCS, RVT
Clinical Luminary Manager, Philips Healthcare

Ryan Fuller has worked in ultrasound for more than 30 years across community hospital, university hospital, and commercial environments. His clinical experience spans radiology, cardiology, and point-of-care ultrasound, providing a broad foundation in diagnostic medical sonography. Ryan Fuller has also held roles in clinical applications, marketing, and personnel management, contributing to a comprehensive understanding of both clinical practice and the business of ultrasound. In his current role, he supports key opinion leaders and collaborates on initiatives including product development and professional engagement. Ryan Fuller has participated in numerous projects, including society work groups and national speaking engagements. He values the collaborative nature of the profession and the contributions of the sonography community.

2

© Copyright. Society of Diagnostic Medical Sonography. All Rights Reserved.

SPEAKER PRESENTATION DISCLAIMER

The content and views presented are made available for educational purposes only. The information presented are the opinions of the presenter and do not necessarily represent the views of the Society of Diagnostic Medical Sonography (SDMS) or its affiliated organizations, officers, Boards of Directors, or staff members.

The presenter is responsible for ensuring balance, independence, objectivity, scientific rigor, and avoiding commercial bias in their presentation. Before making the presentation, the presenter is required to disclose to the audience any relevant financial interests or relationships with manufacturers or providers of medical products, services, technologies, and programs.

The SDMS and its affiliated organizations, officers, Board of Directors, and staff members disclaim any and all liability for all claims that may arise out of the use of this educational activity.

3

Disclosures:

- Employee, Philips Healthcare

4

© Copyright. Society of Diagnostic Medical Sonography. All Rights Reserved.

Liver Elastography: Why do we do it? How do we do it? Where are we going?

Objectives

- Explain the clinical indications for performing liver elastography to support diagnostic decision-making.
- Describe the technical principles of elastography and apply appropriate examination techniques to obtain accurate results.
- Identify emerging methods for liver quantification and summarize current treatment options for liver disease.

5

Clinical Indications for Liver Elastography

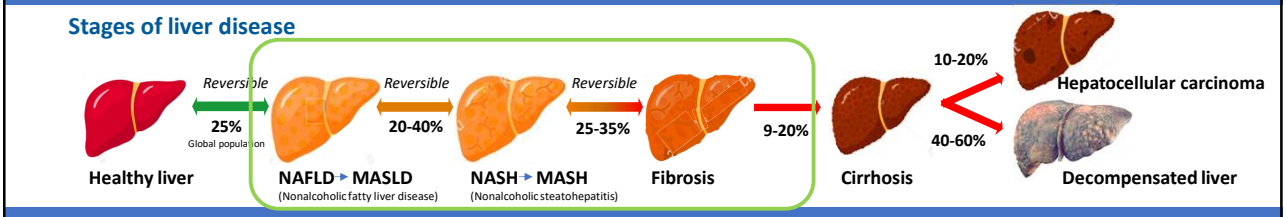

- **According to CDC – Liver disease is top 15 causes of death in the United States**
- **Chronic Liver Disease and Cirrhosis affects 1.8% of the population[1]**
- **MASLD (Metabolic Dysfunction - Associated Steatotic Liver Disease) has shown a prevalence of 25% of the world'spopulation[2]**

6

© Copyright. Society of Diagnostic Medical Sonography. All Rights Reserved.

Clinical Indications for Liver Elastography

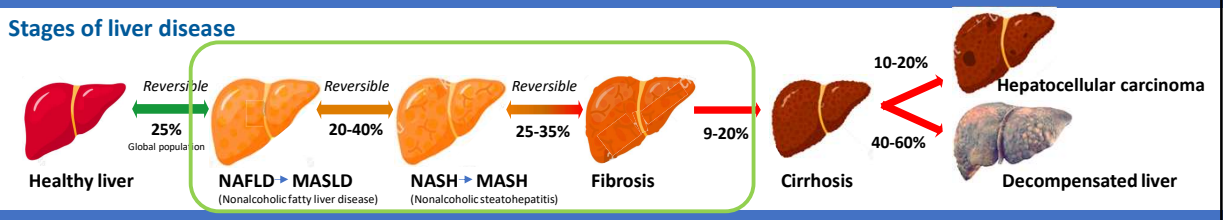

In 2023

NAFLD (Non-Alcoholic Fatty Liver Disease) was updated to MASLD (Metabolic dysfunction - Associated Steatotic Liver Disease)

NASH (Non-Alcoholic Steato-Hapeatitis) was updated to MASH (Metabolic dysfunction - Associated Steato-Hepatitis)

7

Clinical Indications for Liver Elastography

Origins of Liver Fibrosis

Viral	Cholestatic Disease	MASLD/MASH	Alcohol Related Liver Disease
• Hepatitis A • Hepatitis B • HIV/Hep C	• Intrahepatic Cholestasis • Extrahepatic Cholestasis	• Obesity • Type 2 Diabetes • High Cholesterol	• Excessive Alcohol use

8

© Copyright. Society of Diagnostic Medical Sonography. All Rights Reserved.

Distinguishing causes of Steatotic Liver Disease

Cardiometabolic Criteria
- BMI ≥ 25 kg/m²
- Fasting Glucose ≥ 100 mg/dL
- BP ≥ 130/85 mmHg
- Triglycerides ≥ 150 mg/dL
- HDL ≤ 40 mg/dL male
- HDl ≤ 50 mg/dL female

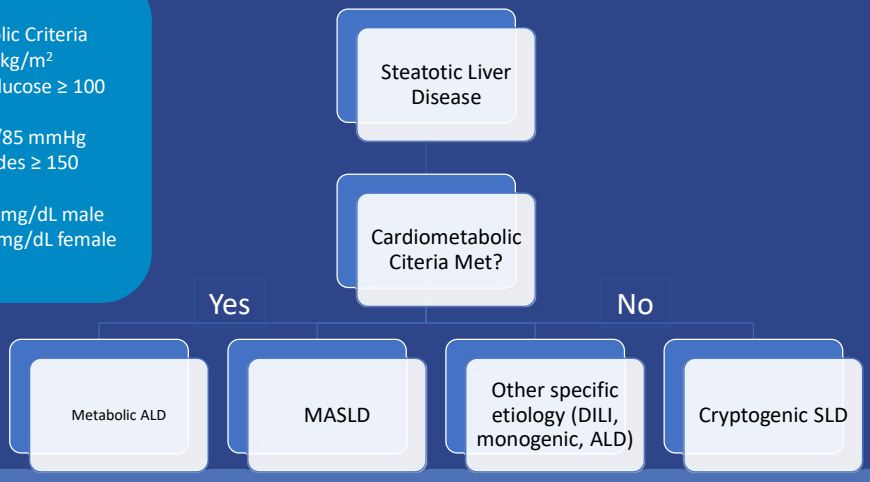

9

Liver Elastography

© Koninklijke Philips N.V.

10

© Copyright. Society of Diagnostic Medical Sonography. All Rights Reserved.

Ultrasound Elastography
History

- Also known as “elasticity”, was first introduced in the early 1990s
  - Jonathan Ophir and colleagues
    - 1991 – Houston, TX[3]
- Refers to the measurement of ***elastic*** properties of tissues, based on the well-established principle that malignant tissue is ***harder*** (or stiffer) than benign tissue
- Evaluates tissue elasticity & analyzes tissue movement
- Provides tissue stiffness information

11

Elastography for Medical Applications

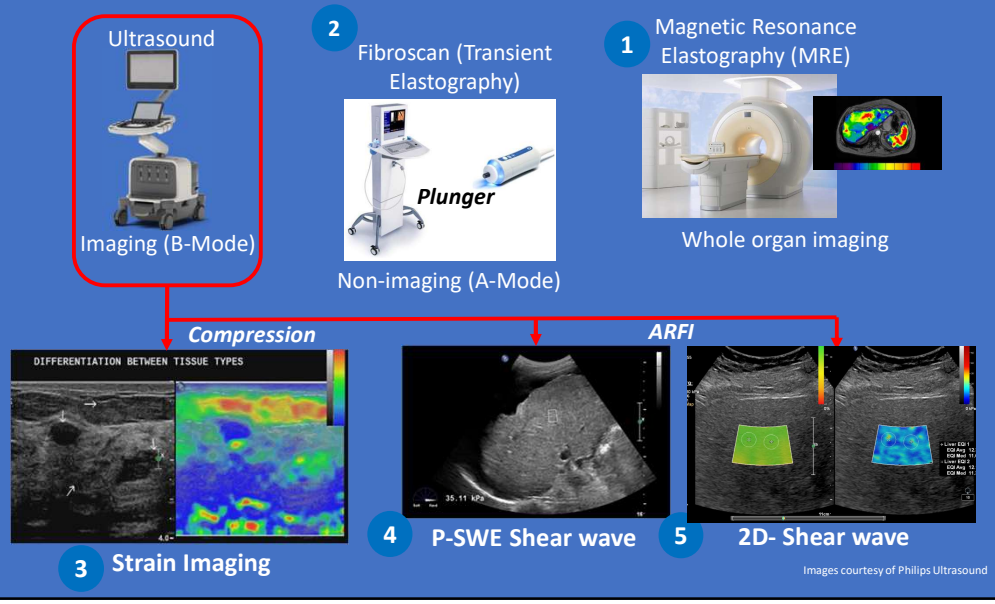

12

© Copyright. Society of Diagnostic Medical Sonography. All Rights Reserved.

Liver Elastography
Shearwave Imaging

- Some of the ultrasound energy/motion is transmitted to tissue
  - Acoustic radiation force “pushes” tissue away from transducer
- This “push” shifts the tissue by few micrometers
- The movement generates transverse (shear) waves across tissue
- Shear waves move slow in soft tissue and faster in stiffer tissue

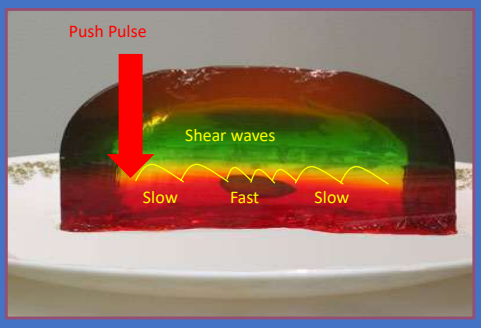



Images courtesy of Philips Ultrasound

13

Liver Elastography



P- SWE: Push pulses (multiple) @ single location

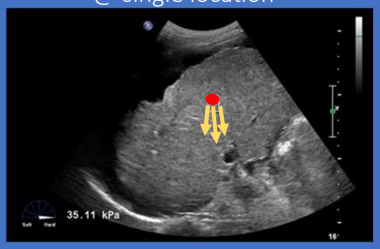

2D-SWE: Push pulses (multiple) @ many locations

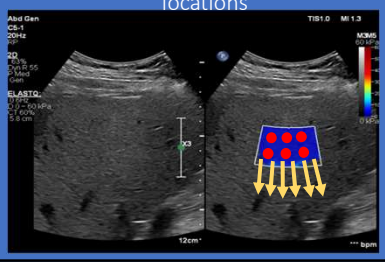

- 2D - Shear wave Imaging provides color coded stiffness/velocity map over a large ROI
- Adjustable ROI can be placed, and measurement obtained

Images courtesy of Philips Ultrasound

14

© Copyright. Society of Diagnostic Medical Sonography. All Rights Reserved.

Liver Elastography Acquisition

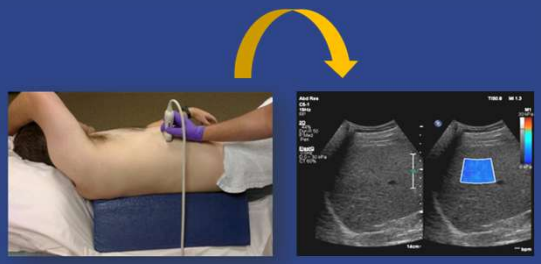

Images courtesy of Philips Ultrasound

15

Liver Elastography Imaging
Patient Prep

- Patient's preparation
- Fast for at least 6 hours prior to the examination
- Supine or left lateral oblique decubitus position with the right arm in maximal extension





16

© Copyright. Society of Diagnostic Medical Sonography. All Rights Reserved.

Liver Elastography Imaging
Transducer Position and Segments

- Ensure good transducer contact with adequate gel
- Transducer position: right intercostal space and aligned with the ribs
- Image liver segment 7 or 8 keeping the liver capsule parallel to the transducer surface

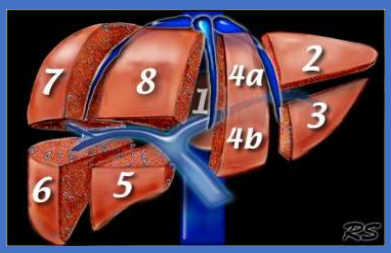



17

Liver Elastography Imaging
Acquisition Hazards



Do not place transducer across ribs

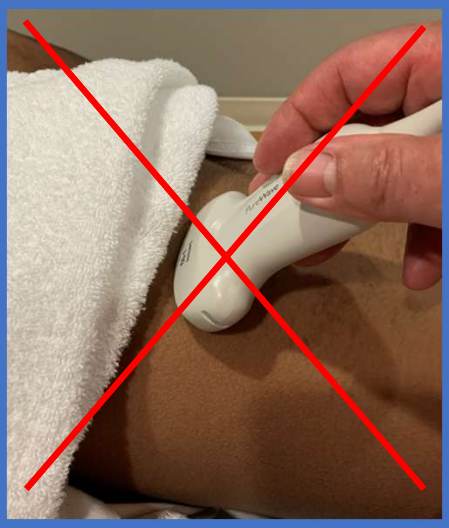

Do not angle transducer to liver capsule

18

© Copyright. Society of Diagnostic Medical Sonography. All Rights Reserved.

Liver Elastography Imaging

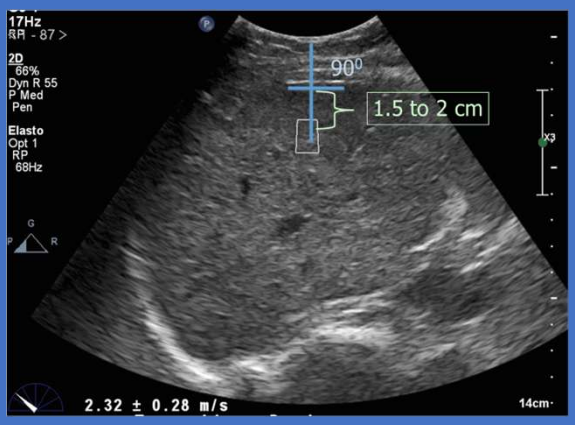

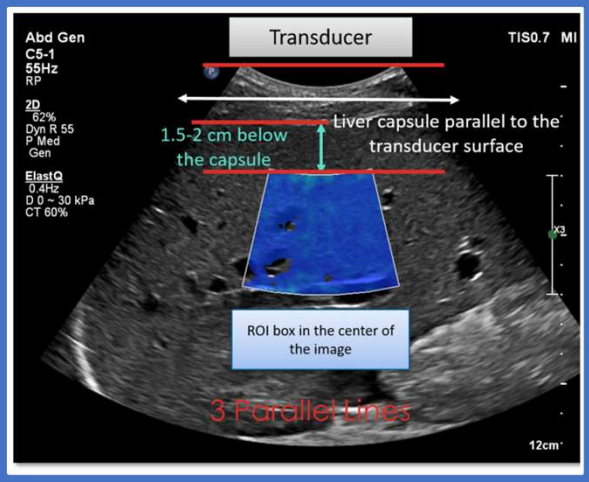

Keep ROI sampling box 1.5-2.0cm from liver capsule

Images courtesy of Philips Ultrasound

19

Liver Elastography Imaging
ROI Sampling Box Positioning

- Position the ROI box in the center of the image and 1.5-2 cm below the liver capsule
- Do not place the ROI box on or near a rib shadow or liver capsule
- Ask the patient to pause breathing in a relaxed manner, rather than taking and holding a deep breath
- Wait for a stable image
- Freeze, measure or acquire a Cineloop

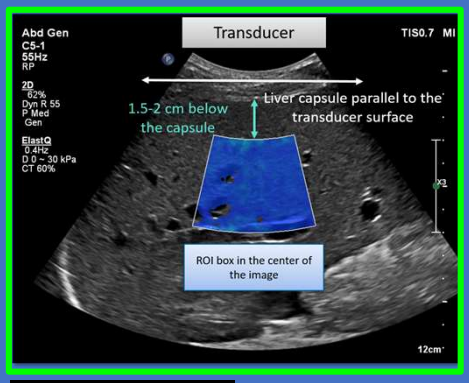

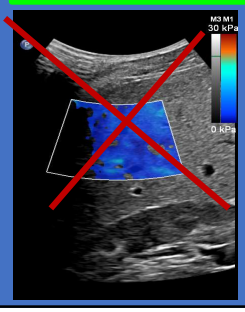

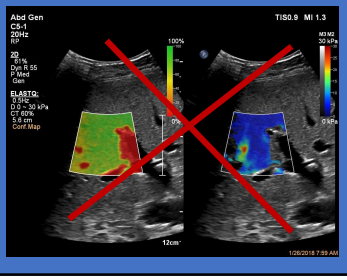

Images courtesy of Philips Ultrasound

20

© Copyright. Society of Diagnostic Medical Sonography. All Rights Reserved.

Liver Elastography Imaging
ROI Sampling

- Review Cineloop to identify frames where the tissue is stable, and the color stiffness map is consistent
- Measure areas of most representative color that change the least over time
- Avoid measuring over rib shadows or areas near blood vessels
- Verify that the calipers are placed in areas with high confidence (green)

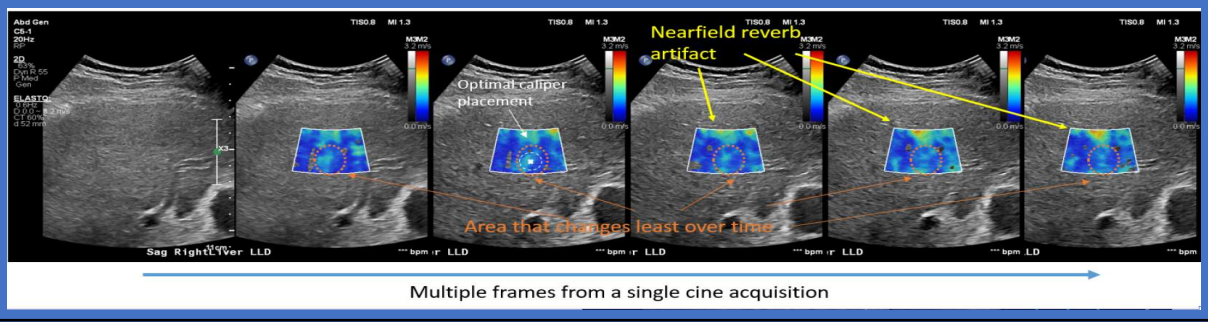

21

Auto Elastography
Optimal frame selection

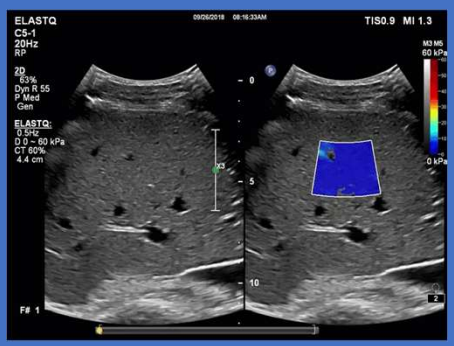

Step 1: Elastography sequence acquisition



Step 2: Confidence thresholding

Highest Confidence



Step 3: Highest similarity to adjacent frames

Highest Similarity



Images courtesy of Philips Ultrasound

22

22

© Copyright. Society of Diagnostic Medical Sonography. All Rights Reserved.

Auto Elastography
Optimal ROI placement

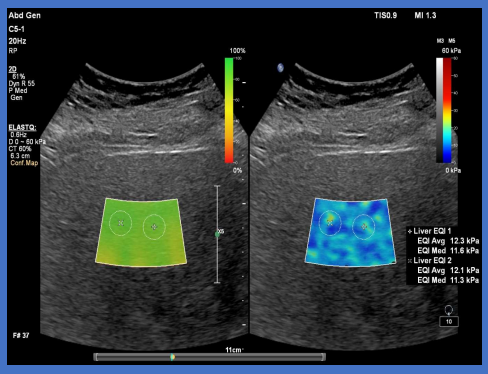

Step 1: Eliminate low-confidence regions

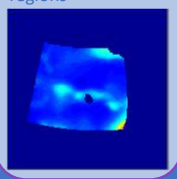

Step 2: Eliminate high-variability regions

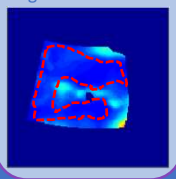

Step 3: Choose ROI with lowest local variability



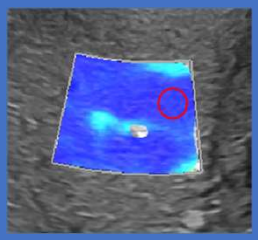

1. Find a high-confidence area free of artifacts
2. Place in the region where stiffness values are representative of what is in the ElastQ box

Images courtesy of Philips Ultrasound

23

23

Liver Elastography Imaging
Confidence Map

- Can be used to assess the quality of the measurement. Determine if there was motion etc.
- Stop Light map – green =go = good data, yellow caution=not so good data, red=stop= data is not useable.
- Use the quality Map to determine where to place ROIs

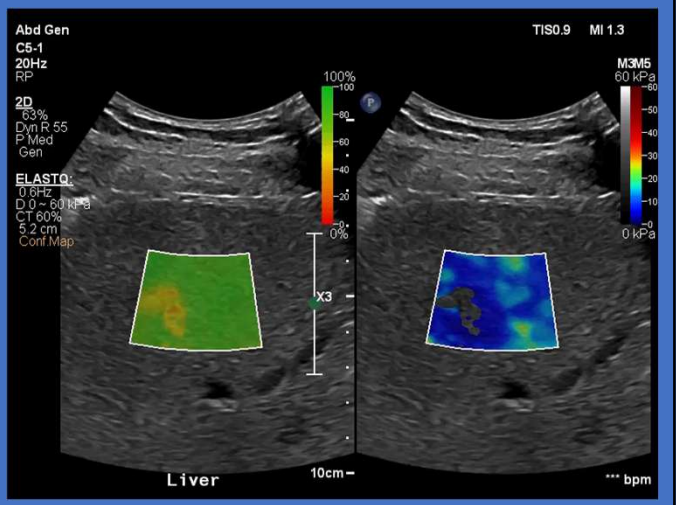

Images courtesy of Philips Ultrasound

24

© Copyright. Society of Diagnostic Medical Sonography. All Rights Reserved.

Liver Elastography Imaging
Understanding Elastography Statistics

- Elastography units:
  - Shear Wave velocity is measured in m/s
  - By applying the equation for Youngs Modulus, the results can be displayed in pressure values kPa
  - Shear wave elastography values are presented in either velocity (m/s) or stiffness (kPa) units.
  - Stiffer tissues will show higher m/s and kPa values.

Example (SW velocity 1.5m/s) = 5kPa

25

Liver Elastography Imaging
Understanding Elastography and Statistics

- Median (Med): The median is the number that divides the set of data points in half: 50% are higher than the median and 50% are lower. The median can be found by choosing the middle value in a set of data points.
- Interquartile range (IQR): The Interquartile Range is a measure of variability, based on dividing a data set into quartiles. The top and bottom quartiles are removed from the data set, thus leaving the "middle fifty" of the data.
- IQR/Med: The interquartile range divided by the median value provides an indicator of data quality. IQR/Med can be presented as a ratio (e.g., 0.23) or percentage (23%).
- Since m/s to kPa conversion is non-linear, IQR/Med calculated from m/s will be smaller than corresponding value from kPa.
- **The most important consistency standard is an IQR/Med of 30% (0.3) or less in kilopascals (kPA) and 15% (0.15) or less for measurements in velocity (in meters per second)**
- https://doi.org/10.1148/radiol.2020192437

26

© Copyright. Society of Diagnostic Medical Sonography. All Rights Reserved.

Median and IQR Example

10 ElastQ measurements in kPa	Sorted from low to high	Sorted, middle 50% of data
4.77	4.15	4.15
4.47	4.47	4.47
4.15	4.77	4.77
5.56	5.17	5.17
6.02	5.56	5.56
6.22	6.02	6.02
6.32	6.06	6.06
6.06	6.16	6.16
6.16	6.22	6.22
5.17	6.32	6.32

*Median = **5.79 kPa***

Middle 50%

IQR = 6.16 – 4.77

*IQR = **1.39 kPa***

IQR/Med = $\frac{1.39}{5.79}$

*IQR/Med = **24%***

27

Liver Elastography Imaging
How to report results

SRU Consensus Best Practices:

- Report the median stiffness value
- Report the IQR/Median as quality of measurement
- To allow for improved reproducibility of serial measurements, the patient position and equipment used both machine manufacturer and transducer frequency should be reported, so that similar equipment and technique are used on subsequent studies
- Discussion of how results are being reported with referring doctors is recommended.

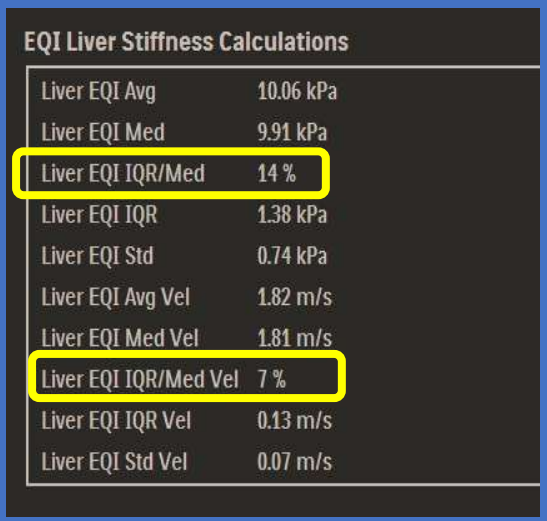

28

© Copyright. Society of Diagnostic Medical Sonography. All Rights Reserved.

Fibrosis Score

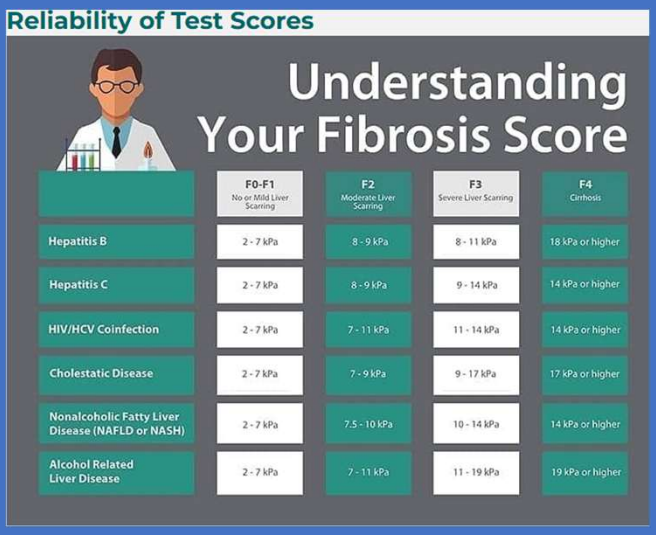

LiverFoundation.ORG American Liver Foundation

29

SRU Consensus Statement

Update to the Society of Radiologists in Ultrasound Liver Elastography Consensus Statement

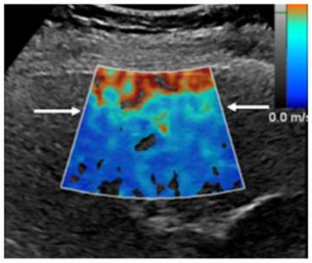

Image demonstrates area of increased stiffness (red and teal, arrows) due to reverberation artifact. The reverberation artifact occurs below the liver capsule in both point SWE and 2D SWE.

- The variability between consecutive liver stiffness acquisitions, assessed by means of the interquartile range–to-median ratio, is the most important quality criterion; when this ratio is greater than 30% for measurements given in kilopascals or greater than 15% for measurements given in meters per second, the accuracy is reduced.
- The Society of Radiologists in Ultrasound continues to recommend a low cutoff value below which there is a high probability of no or mild fibrosis and recommends a high cutoff value above which there is a high probability of compensated advanced chronic liver disease (cACLD).

Barr RG et al. Published Online: June 9, 2020
https://doi.org/10.1148/radiol.2020192437
Radiology

30

© Copyright. Society of Diagnostic Medical Sonography. All Rights Reserved.

Chronic Liver Disease Cutoff

Table 2: Recommendation for Interpretation of Liver Stiffness Values Obtained with ARFI Techniques in Patients with Viral Hepatitis and NAFLD

Liver Stiffness Value	Recommendation
≤5 kPa (1.3 m/sec)	High probability of being normal
<9 kPa (1.7 m/sec)	In the absence of other known clinical signs, rules out cACLD. If there are known clinical signs, may need further test for confirmation
9–13 kPa (1.7–2.1 m/sec)	Suggestive of cACLD but need further test for confirmation
>13 kPa (2.1 m/sec)	Rules in cACLD
>17 kPa (2.4 m/sec)	Suggestive of CSPH

Note.—ARFI = acoustic radiation force impulse, cACLD = compensated advanced chronic liver disease, CSPH = clinically significant portal hypertension, NAFLD = non-alcoholic fatty liver disease.

https://doi.org/10.1148/radiol.2020192437

31

WFUMB guidelines

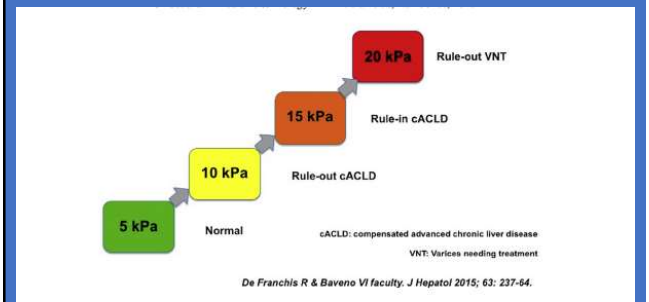

Fig. 1. Rule of 5. cACLD = compensated advanced chronic liver disease; VNT = varices needing treatment. Reprinted, with permission, from de Franchis and Baveno (2015).



ARTICLE IN PRESS

Ultrasound in Med. & Biol., Vol. 00, No. 00, pp. 1–22, 2018
Copyright © 2018 The Author(s). Published by Elsevier Inc. on behalf of World Federation for Ultrasound in Medicine & Biology. This is an open access article under the CC BY-NC-ND license. (http://creativecommons.org/licenses/by-nc-nd/4.0/)
Printed in the USA. All rights reserved.
0301-5629/$ - see front matter
https://doi.org/10.1016/j.ultrasmedbio.2018.07.008

● *Review*

LIVER ULTRASOUND ELASTOGRAPHY: AN UPDATE TO THE WORLD FEDERATION FOR ULTRASOUND IN MEDICINE AND BIOLOGY GUIDELINES AND RECOMMENDATIONS

GIOVANNA FERRAIOLI,* VINCENT WAI-SUN WONG,† LAURENT CASTERA,‡ ANNALISA BERZIGOTTI,§ IOAN SPOREA,¶ CHRISTOPH F DIETRICH,‖ BYUNG IHN CHOI,# STEPHANIE R. WILSON,** MASATOSHI KUDO,†† and RICHARD G. BARR‡‡

*Ultrasound Unit, Department of Clinical Sciences and Infectious Diseases, Fondazione IRCCS Policlinico San Matteo, School of Medicine, University of Pavia, Pavia, Italy; †Department of Medicine and Therapeutics, Chinese University of Hong Kong, Hong Kong; ‡Service d'Hepatologie, Hopital Beaujon, Clichy, Assistance Publique-Hopitaux de Paris, INSERM UMR 1149 CRI, Universite Denis Diderot Paris-VII, Paris, France; §Swiss Liver Center, Hepatology, University Clinic for Visceral Surgery and Medicine, Inselspital, University of Bern, Switzerland; ¶Department of Gastroenterology and Hepatology, University of Medicine and Pharmacy, Timisoara, Romania; ‖Medizinische Klinik 2, Caritas-Krankenhaus, Bad Mergentheim, Germany; #Department of Radiology, Seoul National University Hospital, Seoul, South Korea; **Department of Diagnostic Imaging, Foothills Medical Centre, University of Calgary, Calgary, Alberta, Canada; ††Department of Gastroenterology and Hepatology, Kindai University School of Medicine, Osaka Sayama, Japan; and ‡‡Department of Radiology, Northeastern Ohio Medical University and Southwoods Imaging, Youngstown, Ohio, USA

(*Received* 1 *May* 2018; *revised* 2 *July* 2018; *in final from* 13 *July* 2018)

Abstract—The World Federation for Ultrasound in Medicine and Biology has produced these guidelines for the use of elastography techniques in liver diseases. For each available technique, the reproducibility, results and limitations are analyzed, and recommendations are given. This set of guidelines updates the first version, published in 2015. Since the prior guidelines, there have been several advances in technology. The recommendations are based on the international published literature, and the strength of each recommendation is judged according to

32

32

© Copyright. Society of Diagnostic Medical Sonography. All Rights Reserved.

New Techniques for Liver Quantification

Images courtesy of Philips Ultrasound

33

Clinical Indications for Liver Quantification

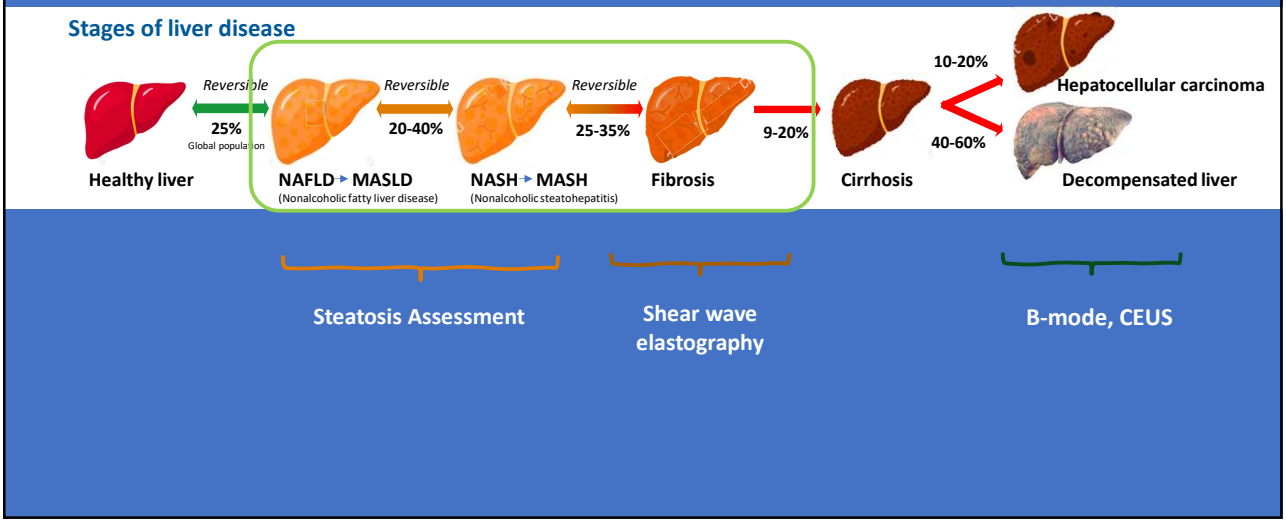

34

© Copyright. Society of Diagnostic Medical Sonography. All Rights Reserved.

Steatosis Assessment

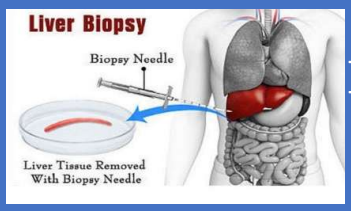

Liver Biopsy
+ Gold Standard
- Invasive, Higher Risk



Ultrasound
+ Non-Invasive, Low Risk
+ Widespread Access
+ Real-time
+ Good for Screening
+/- Growing Acceptance



MR-PDFF
+ Well Accepted
+ Non-Invasive, Low Risk
+ 3D measurement
- Somewhat Limited Access

35

Attenuation Imaging

Principle and expected clinical benefits



What is Ultrasound Attenuation

Attenuation is the rate at which sound is absorbed when propagating in tissue. Sound will propagate deeper when subjected to a lower attenuation coefficient.

For light, murky water has higher attenuation than clean water and blocks light transmission

Why is this important

Fatty inclusions in the liver increases attenuation. Fatty livers normally appear bright and are highly absorbing.

Attenuation is measured by dB/cm/MHz

36

36

© Copyright. Society of Diagnostic Medical Sonography. All Rights Reserved.

Steatosis Assessment

- Attenuation
  - Can be a similar to display as 2D SWE
  - Measurement units are dB/cm/MHz (attenuation coefficient)
  - Described as CAP (Controlled Attenuation parameter) for Fibroscan
  - S0-S1 ~ 0.64[4]

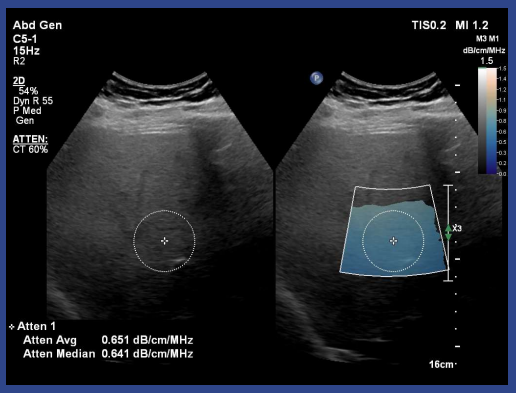

Images courtesy of Philips Ultrasound

37

Steatosis Assessment

Hepato-Renal Index (HRI)

- Compares grayscale intensity
- Results are a ratio of Liver to Kidney
- S0-S1 ~ 2.24[4]



Images courtesy of Philips Ultrasound

38

© Copyright. Society of Diagnostic Medical Sonography. All Rights Reserved.

Steatosis Assessment

Backscatter

- Scattered compression waves reflected back to transducer
- Only used currently combined with attenuation[5]

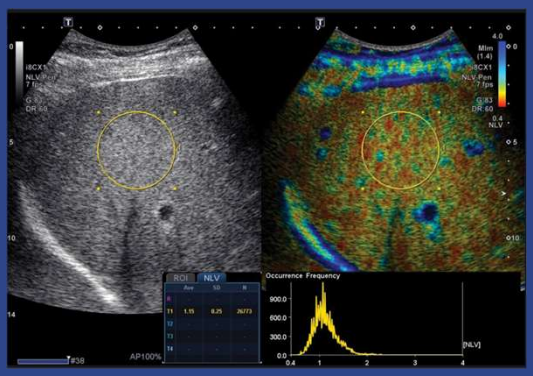

Wear KA et al. Published Online: October 18, 2022
https://doi.org/10.1148/radiol.220606

39

Steatosis Assessment

- Speed of Sound
- Measures speed of sound in transmission
- The SoS measurements for liver tissue can be based on four techniques: focusing, spatial coherence, compounding, and single-path transmission[5]
- Cutoff for Steatosis assessment – 1555m/s[5]

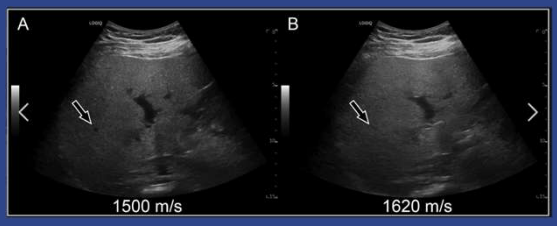

UMBjournal.org

40

© Copyright. Society of Diagnostic Medical Sonography. All Rights Reserved.

Steatosis Assessment

- Composite quantitative techniques
- Multi-parametric quantification technique
- Currently using attenuation and backscatter
- Known as “Ultrasound Fat Fraction”
- Displayed in %
- Mild Steatosis ≥5%

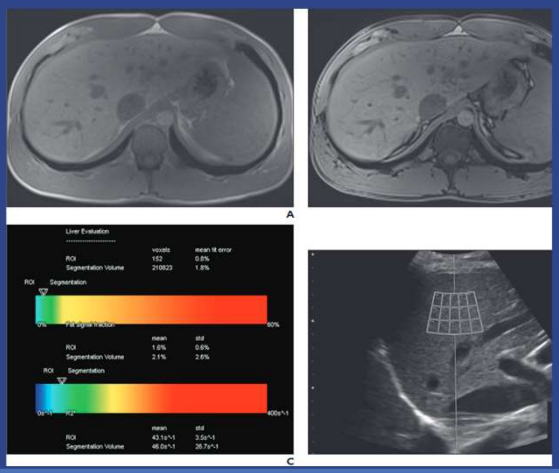

AJRonline Kubale et al

41

Bibliography

1. Centers for Disease Control and Prevention, National Center for Health Statistics. National Vital Statistics System, Mortality 2018-2023 on CDC WONDER Online Database, released in 2024. Data are from the Multiple Cause of Death Files, 2018-2023, as compiled from data provided by the 57 vital statistics jurisdictions through the Vital Statistics Cooperative Program.

2. Younossi ZM, Koenig AB, Abdelatif D, Fazel Y, Henry L, Wymer M. Global epidemiology of nonalcoholic fatty liver disease-Meta-analytic assessment of prevalence, incidence, and outcomes. Hepatology 2016;64(1):73–84.

3. Bibliography Ultrasound Int Open 2024; 10: a23786926 DOI 10.1055/a23786926 ISSN 2509596X © 2024. The Author(s).

4. Pirmoazen AM, Khurana A, Loening AM, Liang T, Shamdasani V, Xie H, El Kaffas A, Kamaya A. “Diagnostic Performance of 9 Quantitative Ultrasound Parameters for Detection and Classification of Hepatic Steatosis in Nonalcoholic Fatty Liver Disease.” *Invest Radiol*. 2022 Jan 1;57(1):23-32.

5. Ultrasound in medicine and Biology
Volume 50, Issue 8. August 2024, pages 1088-1098

42

© Copyright. Society of Diagnostic Medical Sonography. All Rights Reserved.

Bibliography

Update to the Society of Radiologists in Ultrasound Liver Elastography Consensus Statement

Richard G. Barr, MD, PhD • Stephanie R. Wilson, MD • Deborah Rubens, MD • Guadalupe Garcia-Tsao, MD • Giovanna Ferraioli, MD

From the Department of Radiology, Northeastern Ohio Medical University, Rootstown, Ohio (R.G.B.); Department of Radiology, University of Calgary, Calgary, Canada (S.R.W.); Departments of Imaging Science, Oncology, and Biomedical Engineering, University of Rochester Medical Center, Rochester, NY (D.R.); Section of Digestive Diseases, Department of Medicine, Yale University, New Haven, Conn (G.G.T.); and Ultrasound Unit, Department of Clinical Sciences and Infectious Diseases, Fondazione IRCCS Policlinico San Matteo, University of Pavia, Pavia, Italy (G.F.). Received October 31, 2019; revision requested December 11; revision received April 2, 2020; accepted April 23. **Address correspondence to** R.G.B., Southwoods Imaging, 7623 Market St, Youngstown, OH 44512 (e-mail: *rgbarr525@gmail.com*).

Conflicts of interest are listed at the end of this article.

Radiology 2020; 00:1–12 • https://doi.org/10.1148/radiol.2020192437 • Content codes:

WFUMB Guidelines/Guidance on Liver Multiparametric Ultrasound. Part 2: Guidance on Liver Fat Quantification

Giovanna Ferraioli [a], Richard Gary Barr [b], Annalisa Berzigotti [c], Ioan Sporea [d], Vincent Wai-Sun Wong [e f], Thomas Reiberger [g h], Thomas Karlas [i], Maja Thiele [j k], Ana Carolina Cardoso [l], Oyekoya Taiwo Ayonrinde [m n o], Laurent Castera [p q], Christoph Frank Dietrich [r], Hiroko Iijima [s t], Dong Ho Lee [u], William Kemp [v w], Claudia P. Oliveira [x], Shiv Kumar Sarin [y]

43

Bibliography

Wfumb Guidelines and Recommendations on the Clinical use of Ultrasound Elastography

WFUMB Guidelines and Recommendations for Clinical Use of Ultrasound Elastography: Part 3: Liver

Author links open overlay panel Giovanna Ferraioli MD [1], Carlo Filice MD [1], Laurent Castera MD, PhD [2], Byung Ihn Choi MD [3], Ioan Sporea MD [4], Stephanie R. Wilson MD [5], David Cosgrove MD [6], Christoph F. Dietrich MD [7], , Jeffrey C. Bamber PhD [8], Richard Barr MD, PhD [10], Yi-Hong Chou MD [11], Hong Ding MD [12], , Mireen Friedrich-Rust MD [14], Timothy J. Hall PhD [15], , Kathryn R. Nightingale PhD [17], Mark L. Palmeri MD, PhD [17], Fritz Schafer MD [18]…

https://doi.org/10.1016/j.ultrasmedbio.2015.03.007Get rights and content

Under a Creative Commons license

Ultrasound-Derived Fat Fraction for Hepatic Steatosis Assessment: Prospective Study of Agreement With MRI PDFF and Sources of Variability in a Heterogeneous Population

Reinhard Kubale, MD[1], Guenther Schneider, MD[1], Carl P. N. Lessenich, MD[1], Arno Buecker, MD[1], Sebastian Wassenberg, MS[2], Gabriela Torres, PhD[3], Arati Gurung, PhD[3], Timothy Hall, PhD[4], Yassin Labyed, PhD, MBA[3]

44

© Copyright. Society of Diagnostic Medical Sonography. All Rights Reserved.

- To add additional slides, right click on the current slide and select "duplicate slide". This action will carry over all formatting.

45

- Feel free to use a solid black background for images. It makes them pop more, and allows the audience to see the image more clearly.

46

© Copyright. Society of Diagnostic Medical Sonography. All Rights Reserved.