Small Patients, Big Impact

Sonography of Germinal Matrix Hemorrhages

Stephanie Nuñez, MA, RDMS, RVT
Doña Ana Community College

1

SPEAKER PRESENTATION DISCLAIMER

The content and views presented are made available for educational purposes only. The information presented are the opinions of the presenter and do not necessarily represent the views of the Society of Diagnostic Medical Sonography (SDMS) or its affiliated organizations, officers, Boards of Directors, or staff members.

The presenter is responsible for ensuring balance, independence, objectivity, scientific rigor, and avoiding commercial bias in their presentation. Before making the presentation, the presenter is required to disclose to the audience any relevant financial interests or relationships with manufacturers or providers of medical products, services, technologies, and programs.

The SDMS and its affiliated organizations, officers, Board of Directors, and staff members disclaim any and all liability for all claims that may arise out of the use of this educational activity.

2

© Copyright. Society of Diagnostic Medical Sonography. All Rights Reserved.

GENERATIVE AI DISCLAIMER

The presenter utilized the use of large language models (LLMs) and generative artificial intelligence (AI) as a productivity tool to assist in drafting and refining content in this presentation.

While these tools can aid in structuring ideas, summarizing, paraphrasing, and language polishing, they have inherent limitations and cannot replace human creativity, critical thinking, or expert judgment. AI-generated content may contain errors, biases, or gaps in knowledge.

This presentation is intended for informational purposes only and should not be construed as definitive or authoritative guidance. Participants are encouraged to critically evaluate the information presented and consult relevant experts as needed. The SDMS and its affiliated organizations, officers, Board of Directors, and staff members disclaim any and all liability for claims that may arise from the use or interpretation of this educational material.

3

Objectives

- Demonstrate an organized approach to neonatal cranial sonography
- Describe the anatomy, risk factors, and pathophysiology associated with germinal matrix hemorrhage (GMH)
- Differentiate the sonographic characteristics of various grades of germinal matrix hemorrhage
- Apply practical scanning strategies to improve confidence and accuracy when performing neonatal cranial examinations

4

© Copyright. Society of Diagnostic Medical Sonography. All Rights Reserved.

A simple approach to an unfamiliar examination

Objective : Demonstrate an organized approach to neonatal cranial sonography, including standard imaging planes and scanning techniques

5

Why sonography?

- Portable bedside examination
  - Crucial for unstable neonates
- No radiation
- Excellent visualization through fontanelles
- Ideal for serial study follow-ups

[Sources 1, 2]

6

© Copyright. Society of Diagnostic Medical Sonography. All Rights Reserved.

When is it performed?

- Routine screening in very preterm infants, usually beginning 72 hours after birth
- If patient begins deteriorating
- Signs of neurological dysfunction

[Sources 2,3]

7

Equipment and patient preparation

The technical side

- High frequency transducer with small footprint
- Warm gel
- Extra attention to hand hygiene and machine disinfection prior to starting

The patient side

- Frequently performed in the NICU
- These babies are *fragile*
- Be incredibly cautious of lines, breathing tubes, etc.
- Scan through incubator whenever possible
- Ask for help before repositioning baby

[Sources 1, 2]

8

© Copyright. Society of Diagnostic Medical Sonography. All Rights Reserved.

Scanning planes

- Anterior fontanelle
  - Primary window
  - Allows thorough visualization of ventricles and region of the germinal matrix
- Posterior fontanelle
  - Allows visualization of the occipital horns and posterior fossa
- Mastoid fontanelle
  - Allows visualization of the cerebellum, fourth ventricle, and posterior fossa pathology

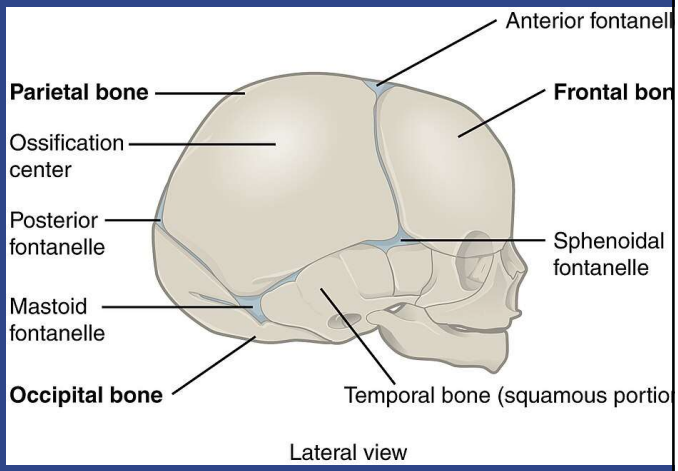

[Sources 1, 2]

OpenStax College, CC BY 3.0 <https://creativecommons.org/licenses/by/3.0>, via Wikimedia Commons

9

Scan technique

- Probe is placed on the anterior fontanelle with *light pressure*
- Coronal sweep from anterior to posterior
- Sagittal sweeps
  - Midline to right
  - Midline to left
- Images should ideally be symmetrical

[Sources 1, 2]

10

© Copyright. Society of Diagnostic Medical Sonography. All Rights Reserved.

Coronal sweep (anterior to posterior)

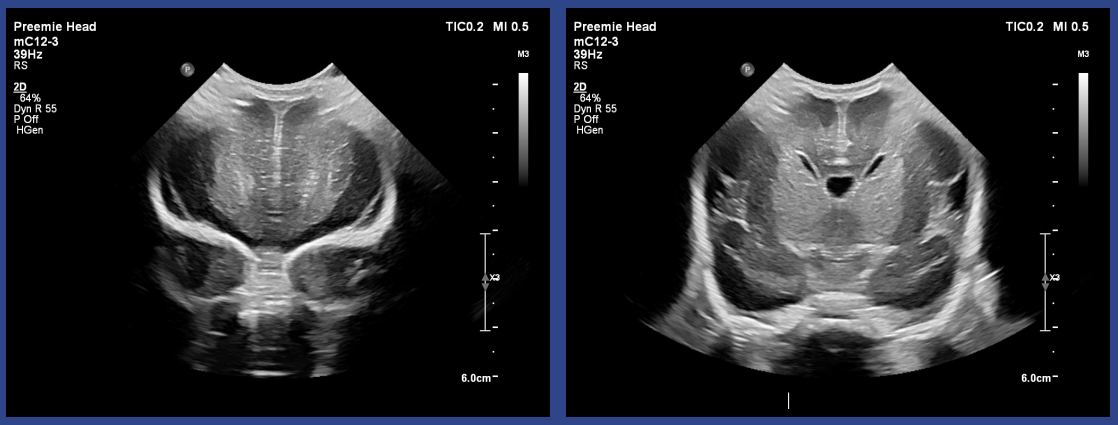

Case courtesy of Ryan Thibodeau, Radiopaedia.org, rID: 172657

11

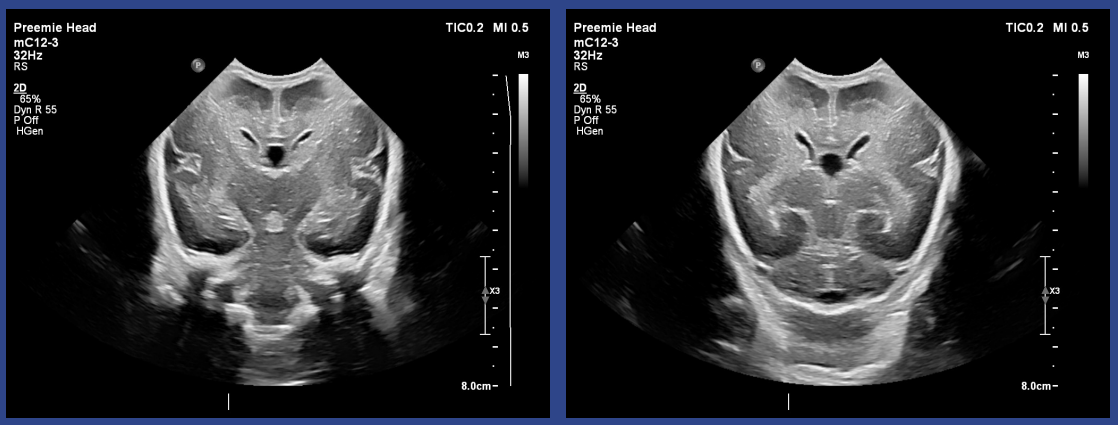

Case courtesy of Ryan Thibodeau, Radiopaedia.org, rID: 172657

12

© Copyright. Society of Diagnostic Medical Sonography. All Rights Reserved.

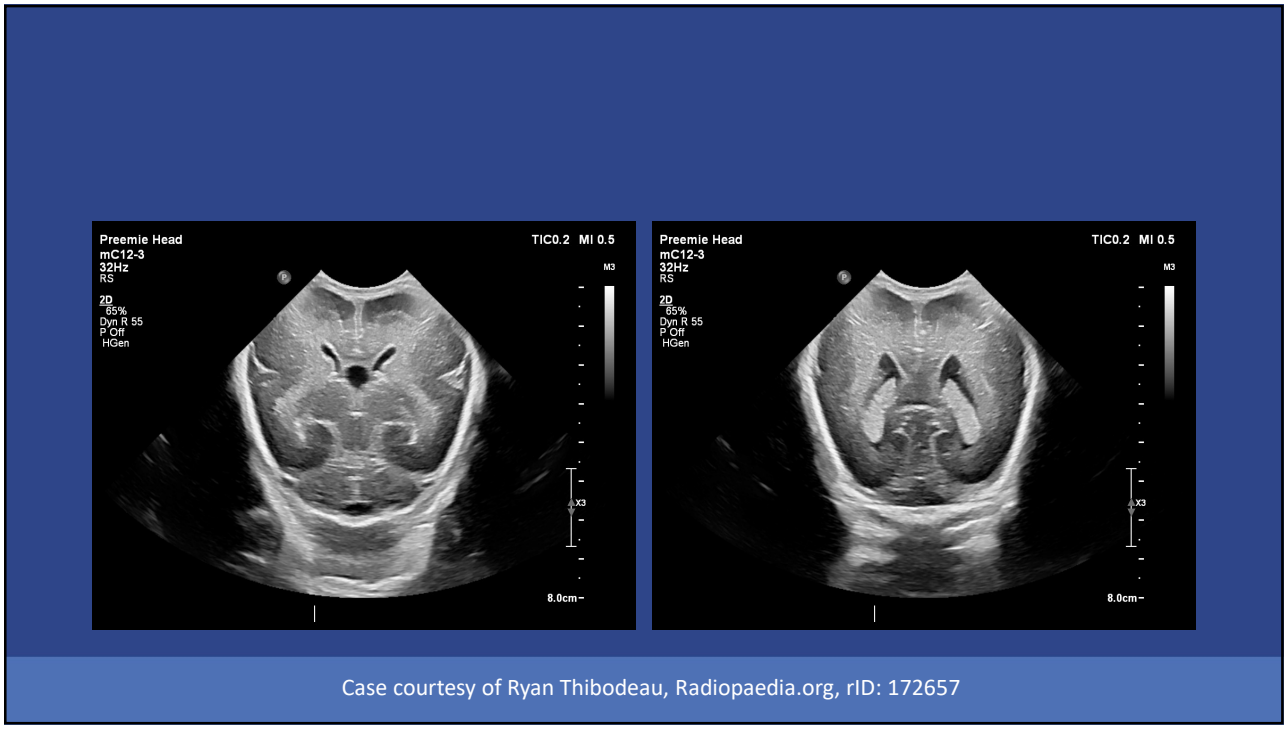

13



14

© Copyright. Society of Diagnostic Medical Sonography. All Rights Reserved.

Sagittal sweep (midline to right)

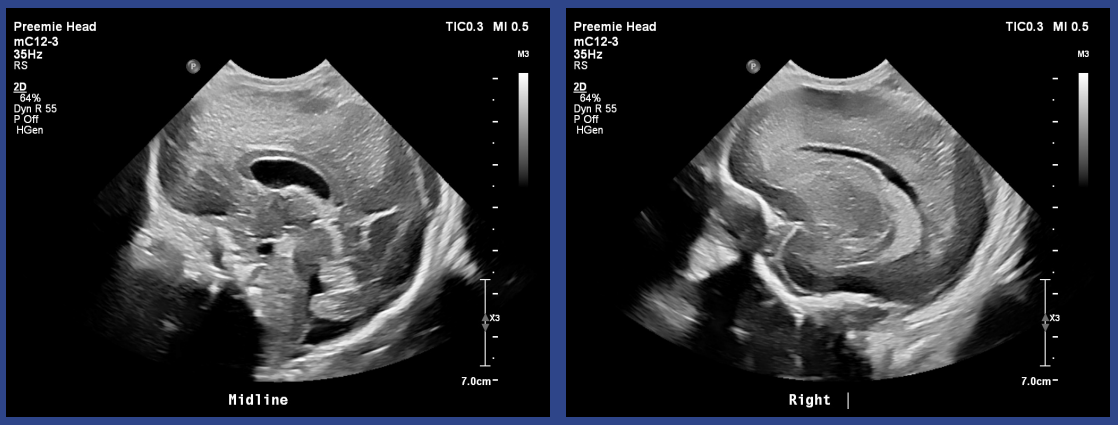

Case courtesy of Ryan Thibodeau, Radiopaedia.org, rID: 172657

15

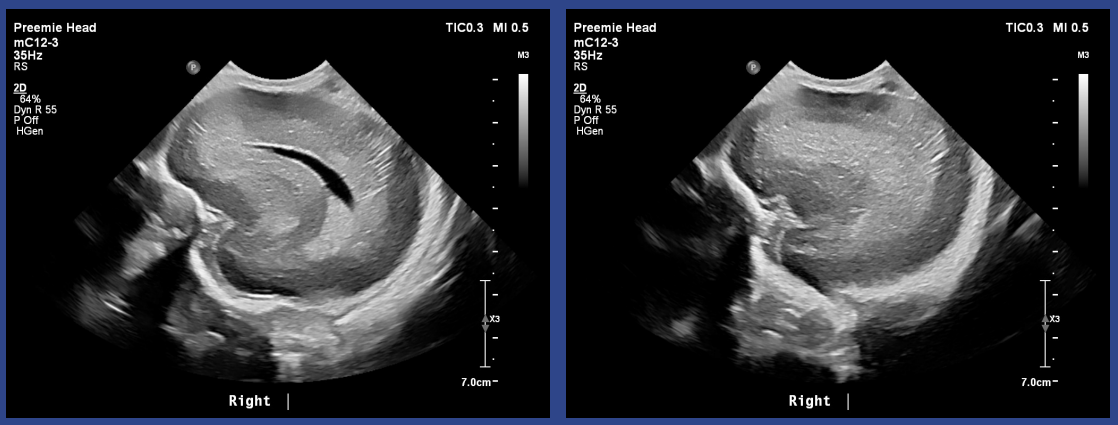

Case courtesy of Ryan Thibodeau, Radiopaedia.org, rID: 172657

16

© Copyright. Society of Diagnostic Medical Sonography. All Rights Reserved.

Consider midline anatomy

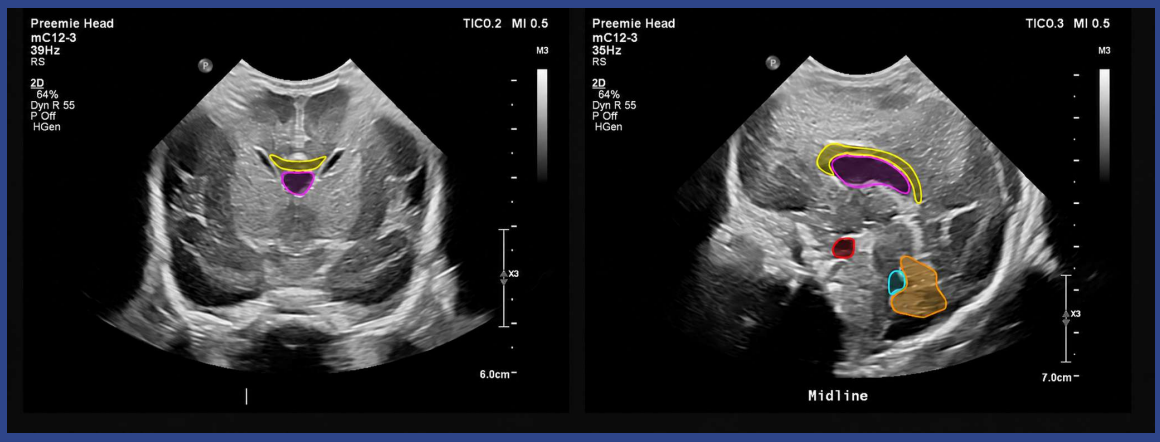

Case courtesy of Ryan Thibodeau, Radiopaedia.org, rID: 172657

17

Quick comparison: Premature vs. full term

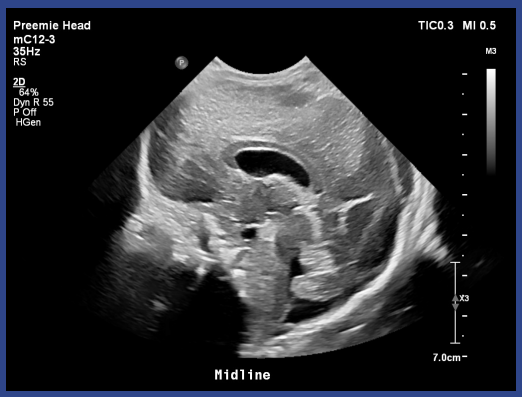

Case courtesy of Ryan Thibodeau, Radiopaedia.org, rID: 172657

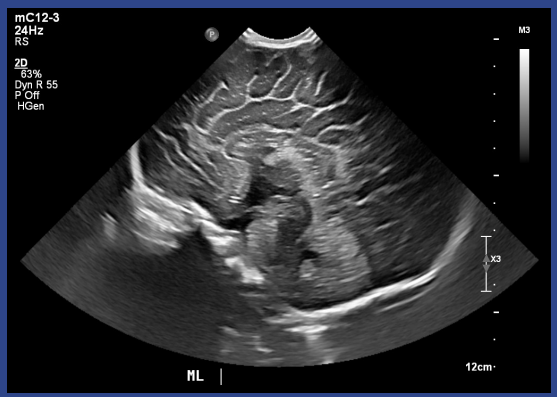

Case courtesy of Ryan Thibodeau, Radiopaedia.org, rID: 183708

18

© Copyright. Society of Diagnostic Medical Sonography. All Rights Reserved.

Quick comparison: Premature vs. full term



Case courtesy of Ryan Thibodeau, Radiopaedia.org, rID: 172657



Case courtesy of Ryan Thibodeau, Radiopaedia.org, rID: 183708

19

Why GMH occurs

Objective 2: Describe the anatomy, risk factors, and pathophysiology associated with germinal matrix hemorrhage (GMH)

20

© Copyright. Society of Diagnostic Medical Sonography. All Rights Reserved.

The germinal matrix

- Temporary, highly vascular neurodevelopmental region
- Fragile capillaries
- Located beneath the ependymal lining of the ventricular system
- Most prominent near caudothalamic groove
- Regresses closer to term

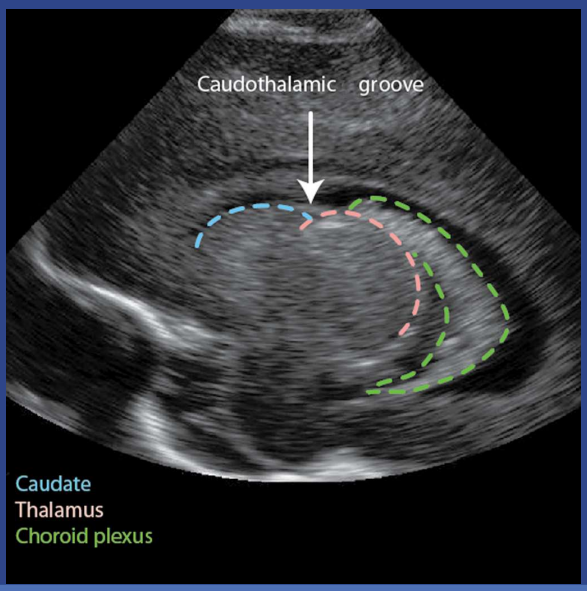

[Sources 2-5]

Case courtesy of Frank Gaillard, Radiopaedia.org, rID: 8353

21

Smallest patients, biggest risk

- Early gestational age
- Very low birth weight
- Fetal or neonatal distress
- Mechanical ventilation
- Bleeding disorders

[Sources 2-5]

22

© Copyright. Society of Diagnostic Medical Sonography. All Rights Reserved.

How hemorrhage develops

- Rupture of the unstable vascular network leads to bleeding in the subependymal layer
  - Grades of GMH vary based on severity
  - Pattern and extent determine classification

[Sources 2-5]

23

Objective 3

Differentiate the sonographic characteristics of the various grades of germinal matrix hemorrhage

24

© Copyright. Society of Diagnostic Medical Sonography. All Rights Reserved.

GMH grading

- I
  - Confined to the subependymal layer
- II
  - Extending into ventricular system, without hydrocephalus
- III
  - Extending into the ventricular system, *with* hydrocephalus
- IV
  - Hemorrhage extending beyond the ventricular system into the brain parenchyma, with or without hydrocephalus

[Sources 2-5]

25

Grade I

- AKA subependymal hemorrhage (SEH)
- Typically seen along the caudothalamic groove
- Can appear isoechoic to the adjacent choroid plexus

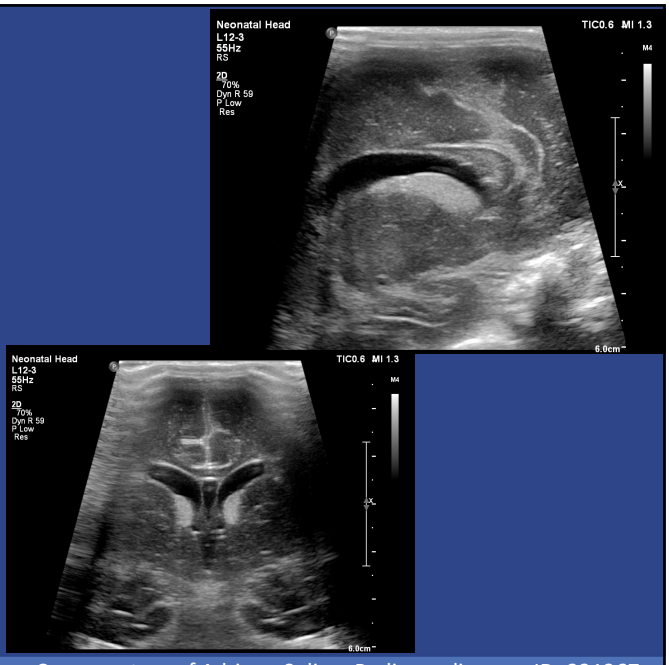

Case courtesy of Adriano Solino, Radiopaedia.org, rID: 231367

[Sources 2,3,5]

26

© Copyright. Society of Diagnostic Medical Sonography. All Rights Reserved.

Grade II

- Hemorrhage extends beyond subependymal layer into the lateral ventricle, but does not extend beyond that
- **No ventricular dilation seen



[Sources 2,3,5]

Case courtesy of The Radswiki, Radiopaedia.org, rID: 11452

27

Grade III

- Hemorrhage extends beyond subependymal layer into the lateral ventricle, but does not extend beyond that
- **Ventricular dilation present
- Can appear mobile within the dilated ventricle

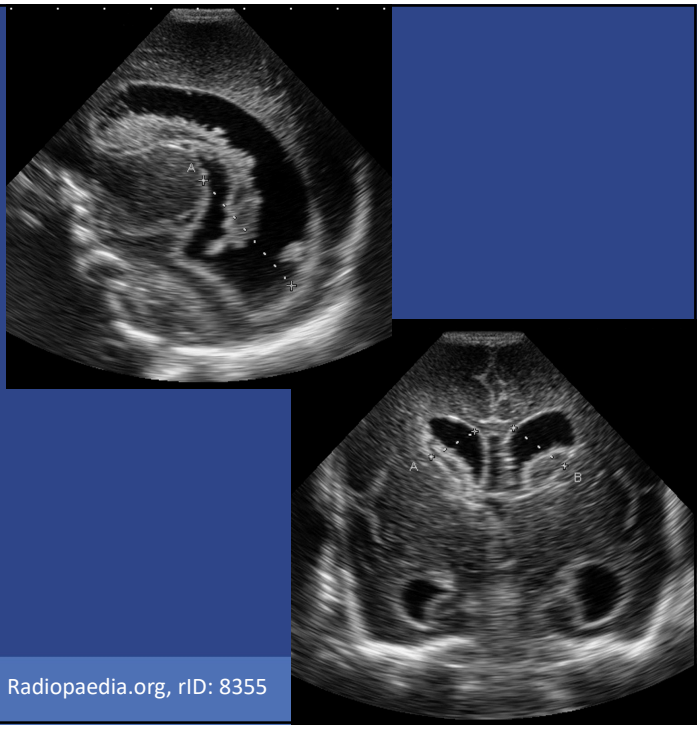

[Sources 2,3,5]

Case courtesy of Frank Gaillard, Radiopaedia.org, rID: 8355

28

© Copyright. Society of Diagnostic Medical Sonography. All Rights Reserved.

Grade IV *traditional term*

- May also be referred to as intraparenchymal hemorrhage (IPH)
  - Recent shift to periventricular hemorrhagic infarction (PVHI) [4,5]
- Hemorrhage extends beyond the ventricular system into the brain parenchyma
- Involvement of the brain cortex is automatically grade IV, regardless of whether there is dilation or not

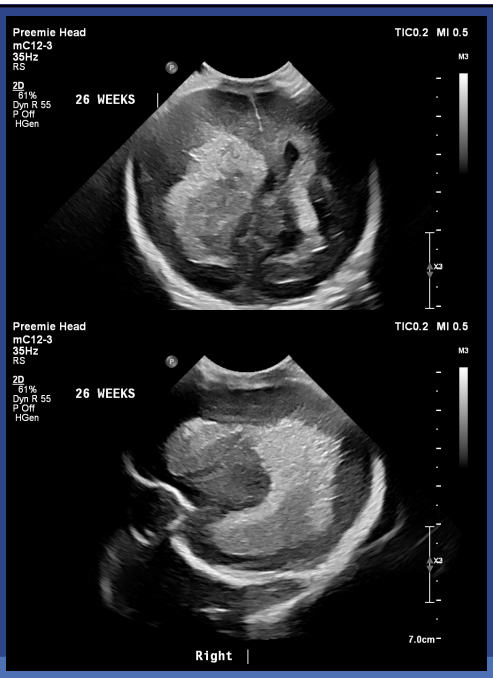

[Sources 2,3,5]

Case courtesy of Ryan Thibodeau, Radiopaedia.org, rID: 174523

29

Grade	Location	Ventricular extension	Ventricular dilation	Key sonographic feature
I	Germinal matrix/subependymal layer	No	No	Echogenic focus at the caudothalamic groove
II	Germinal matrix & ventricle	Yes	No	Blood products within ventricle
III	Germinal matric & ventricle	Yes	Yes	Blood products within enlarged ventricle
IV	Extension into the white matter of the brain	Yes	Variable	Extension of blood products and/or infarction beyond the ventricle into the cerebral cortex

[Sources 2-5]

30

© Copyright. Society of Diagnostic Medical Sonography. All Rights Reserved.

Grades one through four



Case courtesy of Adriano Solino, Radiopaedia.org, rID: 231367



Case courtesy of The Radswiki, Radiopaedia.org, rID: 11452

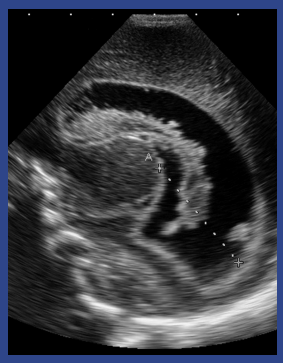

Case courtesy of Frank Gaillard, Radiopaedia.org, rID: 8355



Case courtesy of Ryan Thibodeau, Radiopaedia.org, rID: 174523

31

Objective 4

Apply practical scanning strategies to improve confidence and accuracy when performing neonatal cranial examinations

32

© Copyright. Society of Diagnostic Medical Sonography. All Rights Reserved.

Case 1: Normal or abnormal?

Initial scan

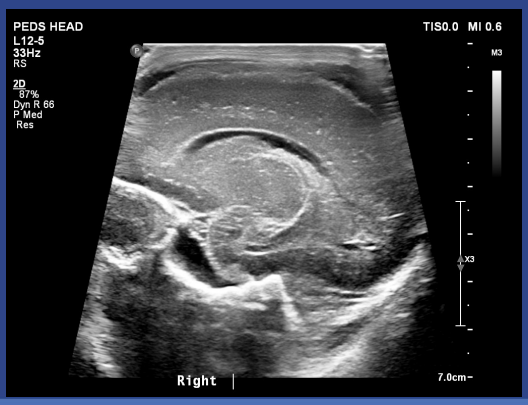

One day later

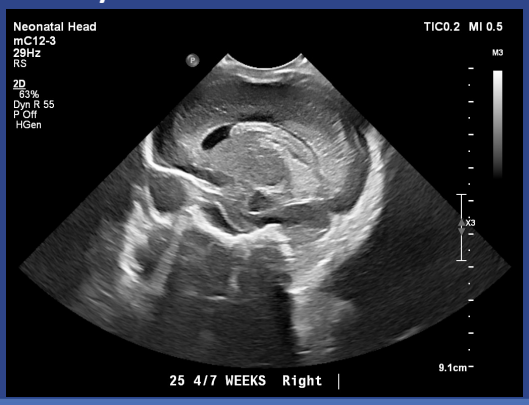

Case courtesy of Ryan Thibodeau, Radiopaedia.org, rID: 174523

33

Case 1, continued

Two days after initial scan

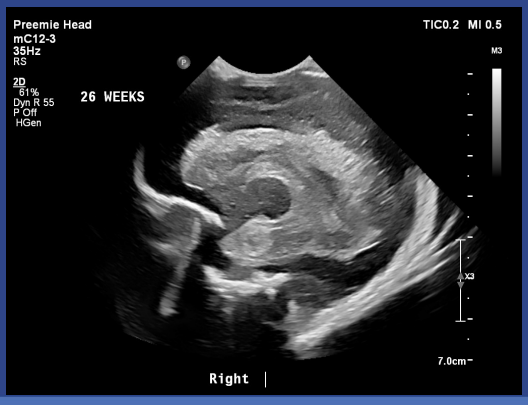

Four days after initial scan



Case courtesy of Ryan Thibodeau, Radiopaedia.org, rID: 174523

34

© Copyright. Society of Diagnostic Medical Sonography. All Rights Reserved.

Case 1, continued

A month and a half later

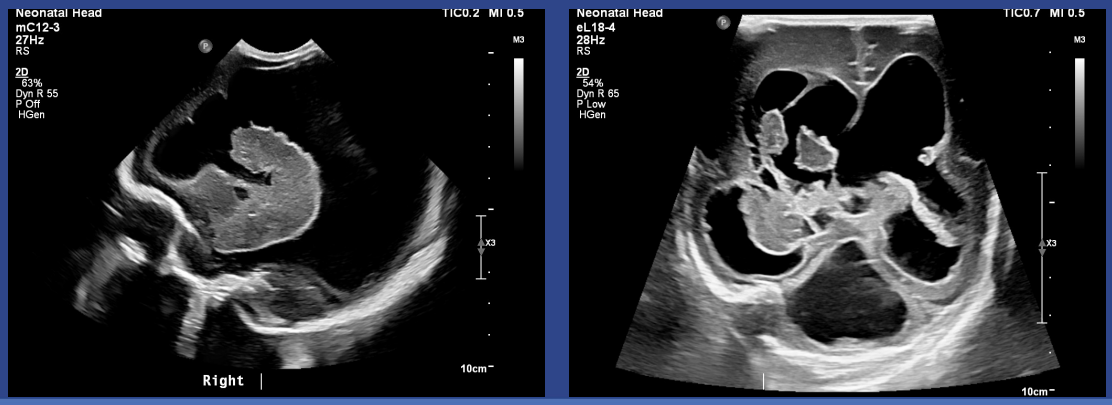

Case courtesy of Ryan Thibodeau, Radiopaedia.org, rID: 174523

35

Case 2: What seems off here?





Image produced by presentation author, July 2026

Case courtesy of Mostafa Elfeky, Radiopaedia.org, rID: 194347

36

© Copyright. Society of Diagnostic Medical Sonography. All Rights Reserved.

Comparison

Case 2

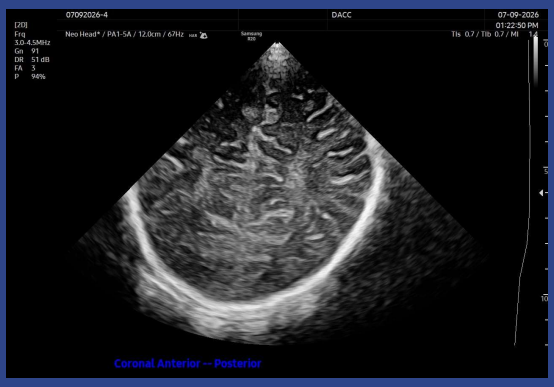

Image produced by presentation author, July 2026

Grade IV example

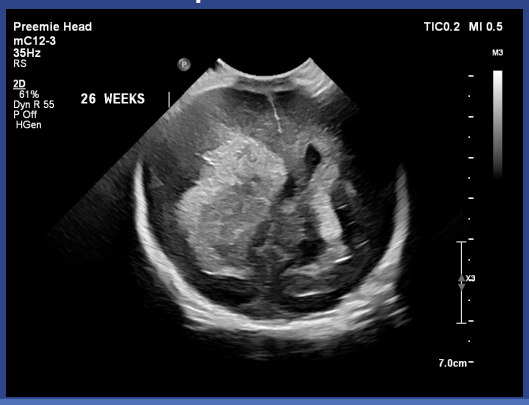

Case courtesy of Ryan Thibodeau, Radiopaedia.org, rID: 174523

37

Acknowledgement

Thank you to the imaging professionals who share their work and make teaching, both in the classroom and at professional conferences, more meaningful.

Radiopaedia case images used with permission.

38

© Copyright. Society of Diagnostic Medical Sonography. All Rights Reserved.

Radiopaedia case image credits

Case courtesy of Ryan Thibodeau, Radiopaedia.org, rID: 172657.

Case courtesy of Ryan Thibodeau, Radiopaedia.org, rID: 183708.

Case courtesy of Frank Gaillard, Radiopaedia.org, rID: 8353.

Case courtesy of Adriano Solino, Radiopaedia.org, rID: 231367.

Case courtesy of The Radswiki, Radiopaedia.org, rID: 11452.

Case courtesy of Frank Gaillard, Radiopaedia.org, rID: 8355.

Case courtesy of Ryan Thibodeau, Radiopaedia.org, rID: 174523.

Case courtesy of Mostafa Elfeky, Radiopaedia.org, rID: 194347.

39

References

1. American Institute of Ultrasound in Medicine. AIUM practice parameter for the performance of neurosonography in neonates and infants, 2024 revision. J Ultrasound Med. 2024;43:E50-E55. doi:10.1002/jum.16551.
2. Caro-Domínguez P, Lecacheux C, Hernandez-Herrera C, Llorens-Salvador R. Cranial ultrasound for beginners. Transl Pediatr. 2021;10(4):1117-1137. doi:10.21037/tp-20-399.
3. Gupta P, Sodhi KS, Saxena AK, Khandelwal N, Singhi P. Neonatal cranial sonography: a concise review for clinicians. J Pediatr Neurosci. 2016;11(1):7-13. doi:10.4103/1817-1745.181261.
4. Ní Leidhin C, Paddock M, Parizel PM, Warne RR, Shipman P, Lakshmanan R. Paediatric cranial ultrasound: assessment of the preterm brain. Insights Imaging. 2025;16(1):158. doi:10.1186/s13244-025-02030-5.
5. Rumack CM, Levine D, editors. Diagnostic ultrasound. 6th ed. Philadelphia (PA): Elsevier; 2024. 2 volumes.

40

© Copyright. Society of Diagnostic Medical Sonography. All Rights Reserved.