2026 SDMS Annual Conference

Intracardiac Echocardiography from a Sonographer's Perspective





Sydni Hennemann BS ACS
RDCS RCCS FASE

1

SPEAKER PRESENTATION DISCLAIMER

The content and views presented are made available for educational purposes only. The information presented are the opinions of the presenter and do not necessarily represent the views of the Society of Diagnostic Medical Sonography (SDMS) or its affiliated organizations, officers, Boards of Directors, or staff members.

The presenter is responsible for ensuring balance, independence, objectivity, scientific rigor, and avoiding commercial bias in their presentation. Before making the presentation, the presenter is required to disclose to the audience any relevant financial interests or relationships with manufacturers or providers of medical products, services, technologies, and programs.

The SDMS and its affiliated organizations, officers, Board of Directors, and staff members disclaim any and all liability for all claims that may arise out of the use of this educational activity.

2

© Copyright. Society of Diagnostic Medical Sonography. All Rights Reserved.

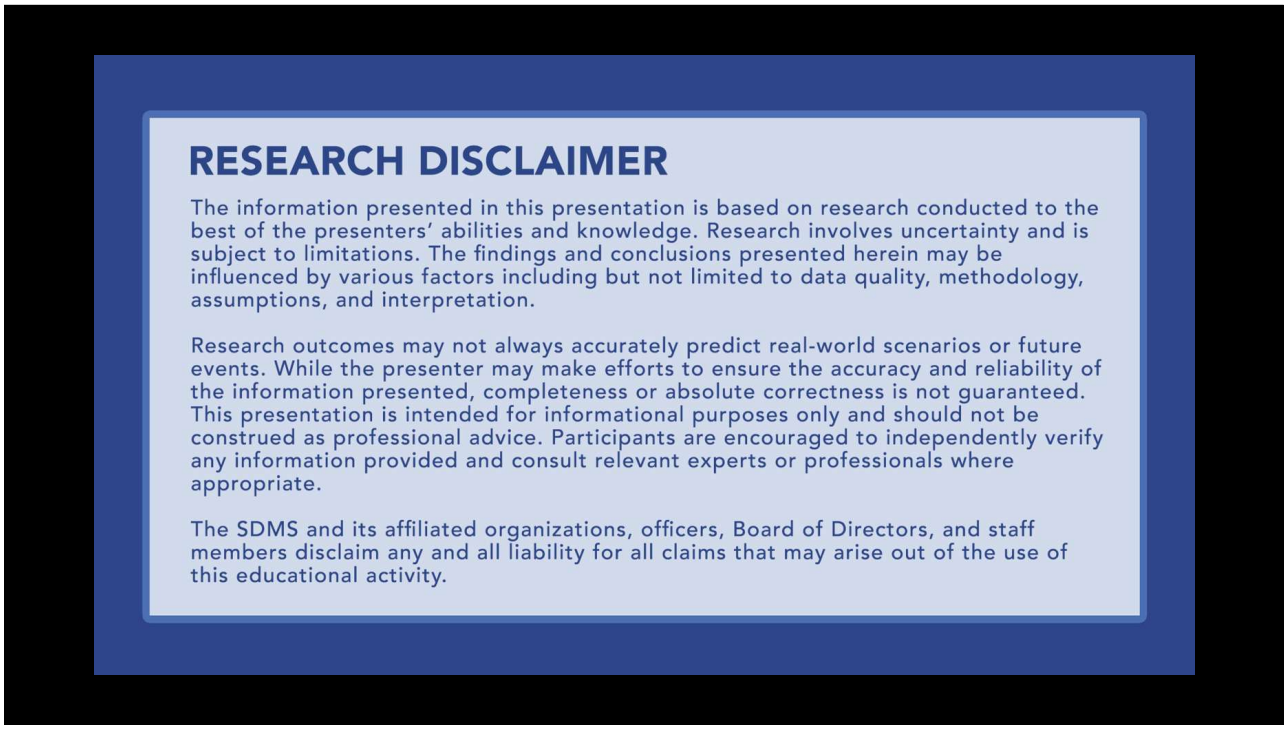

3

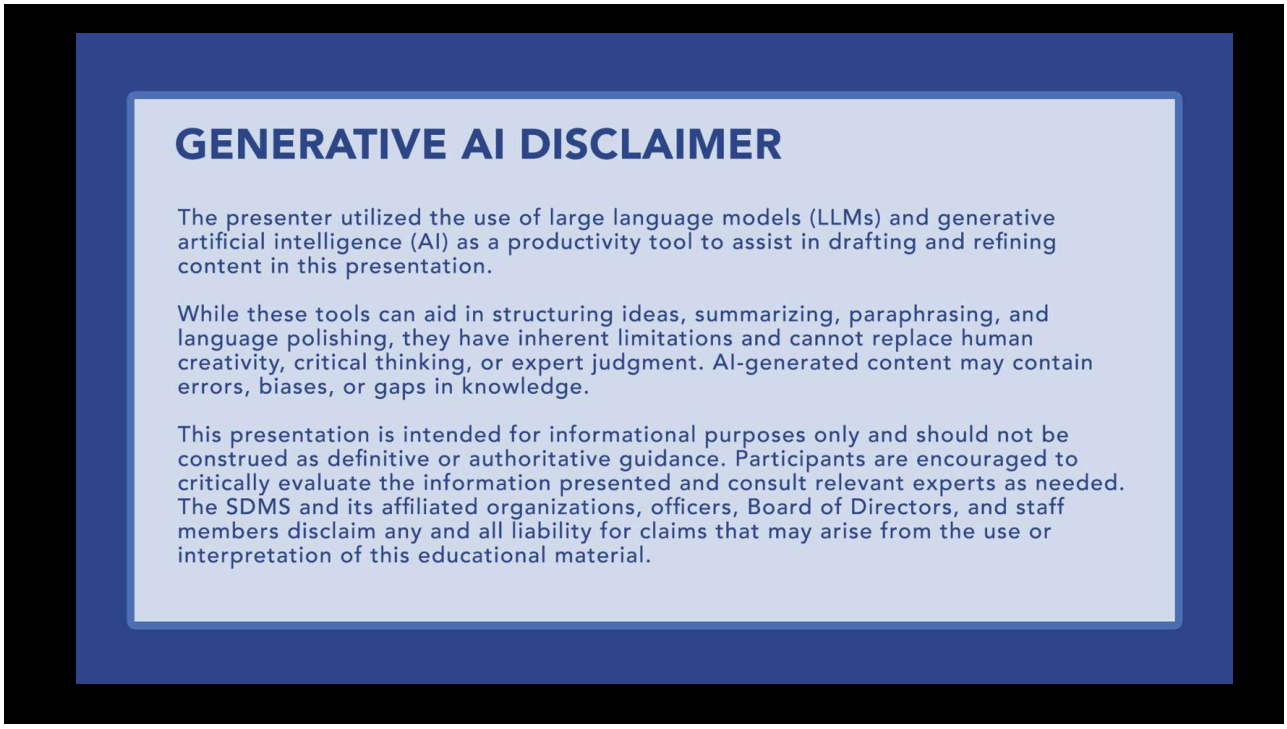

4

© Copyright. Society of Diagnostic Medical Sonography. All Rights Reserved.

No Disclosures

Learning and growing continuously!

5

Sharing Insights Without Bias

- Multiple Sources of Information-Unbiased Perspective-Personal Growth and Experience
- The presentation draws from diverse sources, ensuring comprehensive and balanced insights for the audience.
- The speaker's viewpoint remains impartial, presenting facts as shared and reflecting only vendor selection by the facility.
- Over two years, personal growth and firsthand experience have shaped the speaker's understanding and approach to this opportunity.

6

© Copyright. Society of Diagnostic Medical Sonography. All Rights Reserved.

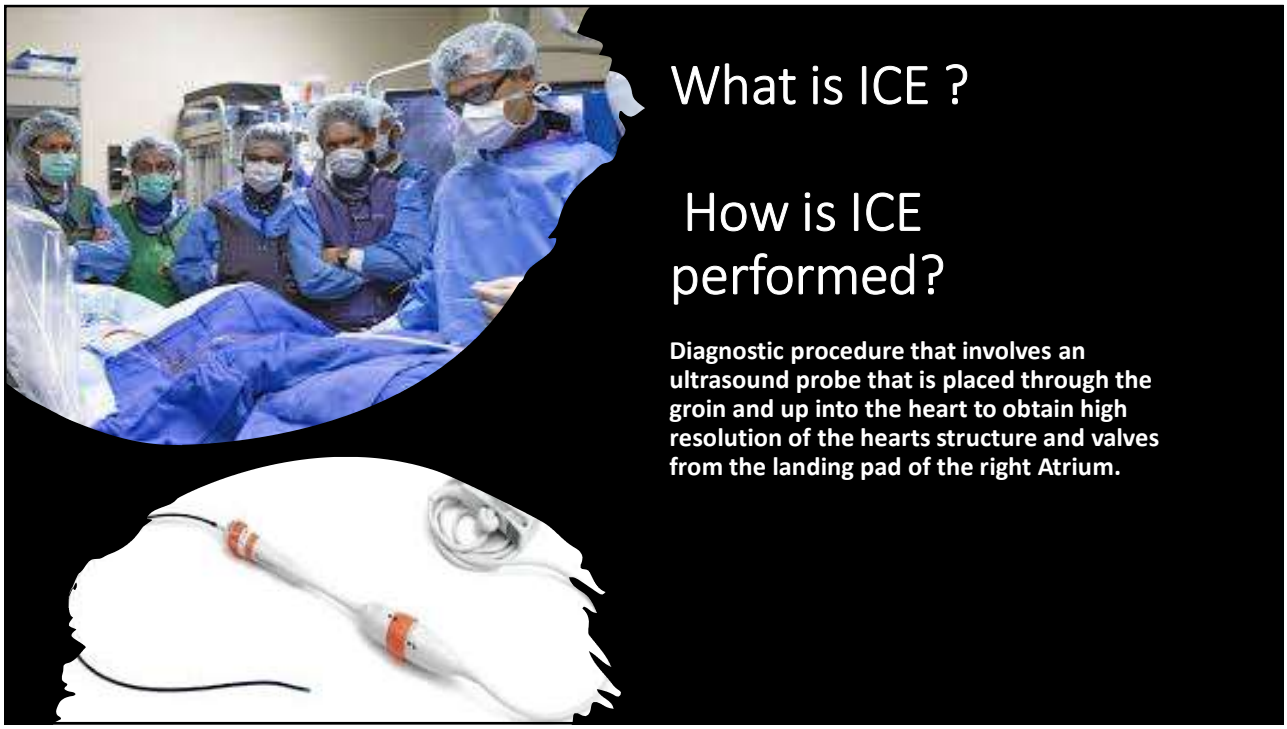

7

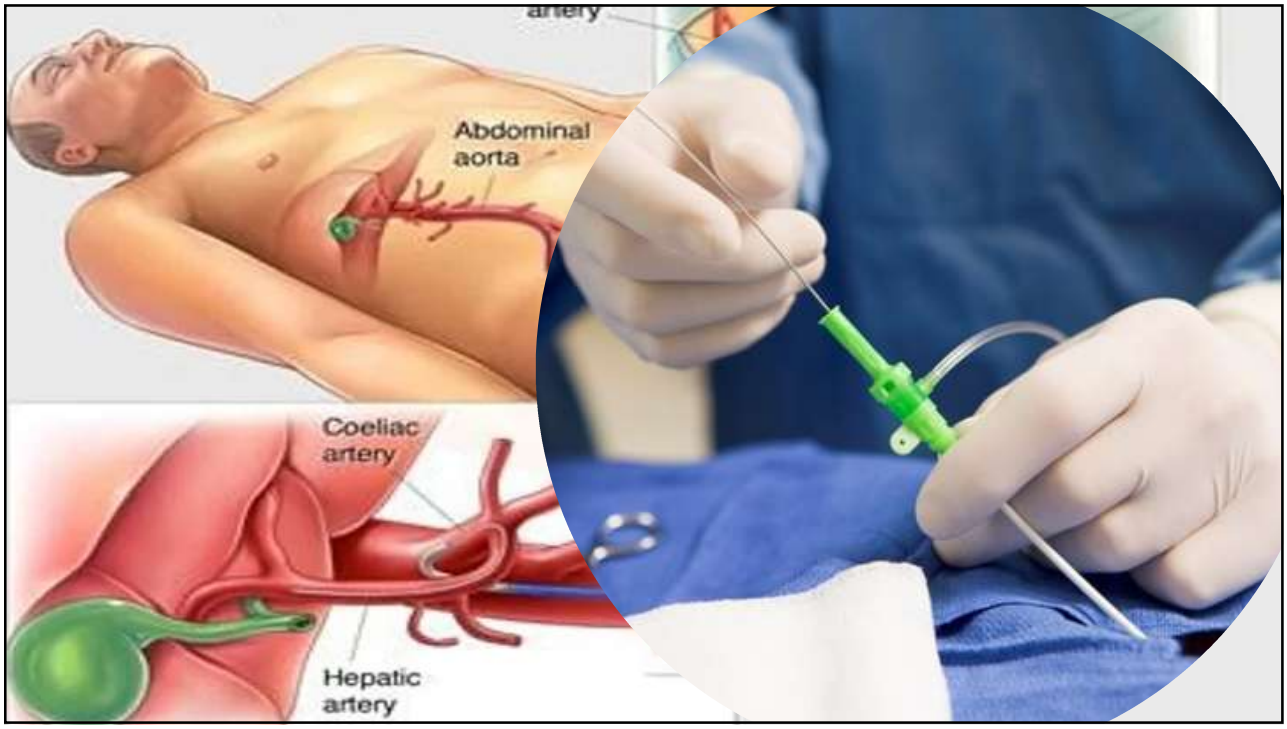

8

© Copyright. Society of Diagnostic Medical Sonography. All Rights Reserved.

Objectives:

- Describe the historical development and clinical applications of intracardiac echocardiography to support foundational knowledge.
- Identify the strengths and limitations of intracardiac echocardiography to inform appropriate clinical use.
- Recognize emerging trends in intracardiac echocardiography for application in evolving sonography practice.

9

Historical Info: ICE emerged in 1960!!

- Research started exploring the use of ICE with a mechanical 4 element probe.
- By '69 element phased 32-element
- '81 a 7.5 MHz flexible coaxial cable, used in 20 patients. This made a huge step in the advancement of technology

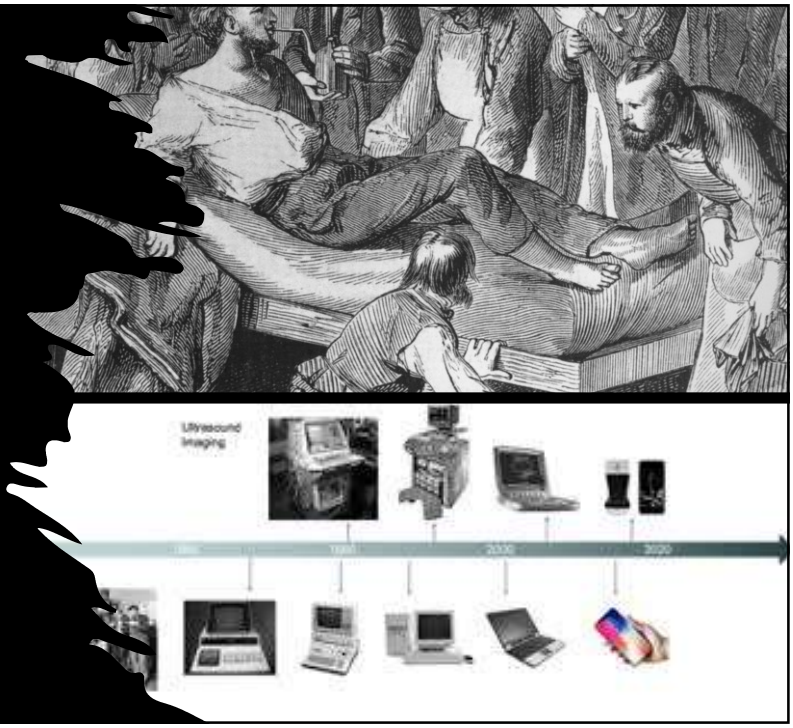

10

© Copyright. Society of Diagnostic Medical Sonography. All Rights Reserved.

ICE didn't appear suddenly — it emerged because two imaging gaps became impossible to ignore in the 1990s:



1. TEE wasn't ideal for long, catheter-based EP procedures.

(Not comfortable for multi-hour ablations.)

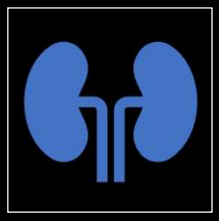

2. Fluoroscopy exposed patients and staff to significant radiation and provided no soft-tissue detail. --Growing pressure for safer imaging alternatives.

<u>The gap -- Clinicians needed an imaging tool that was real-time, continuous, comfortable, and radiation-free.</u>

11

ICE Historical Timeline

1990s — The Problem Becomes Obvious

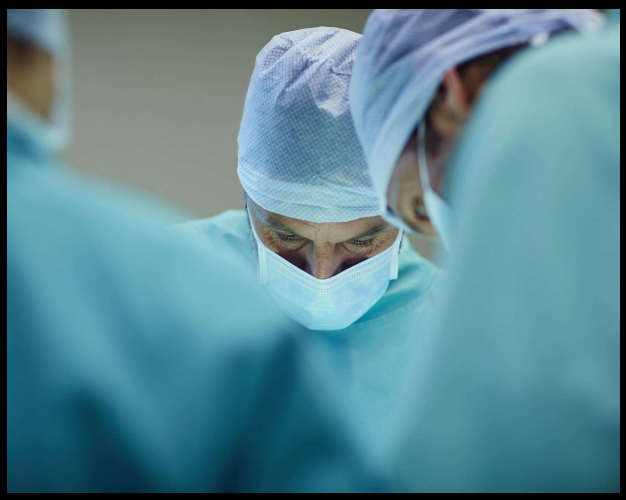

EP procedures (especially AF ablation) were getting longer and more complex. TEE couldn't stay in place comfortably for multi-hour cases. Fluoroscopy was the default, but radiation exposure was becoming a major concern.

12

© Copyright. Society of Diagnostic Medical Sonography. All Rights Reserved.

Mid-1990s — Early Prototypes

- Researchers began experimenting with miniature ultrasound transducers mounted on catheter tips. The goal: real-time imaging from inside the heart without relying on TEE or fluoroscopy

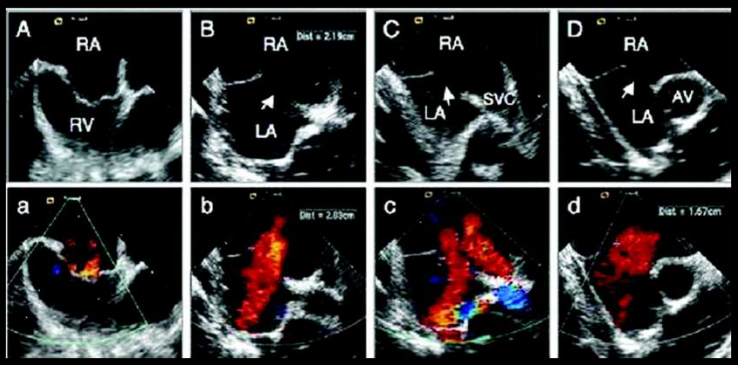


Intracardiac Echocardiography During Interventional and Electrophysiological Cardiac Catheterization

13

1998–2000 — First Commercial ICE Catheters

- Companies released the first phased-array ICE catheters.
- EP labs were the earliest adopters because they needed septal visualization and catheter guidance.



14

© Copyright. Society of Diagnostic Medical Sonography. All Rights Reserved.

2000s — Rapid Adoption in EP

- ICE became standard for: Transseptal puncture
  - AF ablation
  - Mapping catheter placement
  - Radiation-reduction benefits accelerated adoption.

2010s — Expansion Beyond EP

- Structural heart procedures began using ICE (e.g., Watchman, ASD/PFO closure).Improved catheter resolution made ICE more versatile.

15

2020s — Modern ICE

- High-resolution imaging, 3D ICE development, and integration with mapping systems. Increasing interest in reducing TEE dependence during structural interventions.

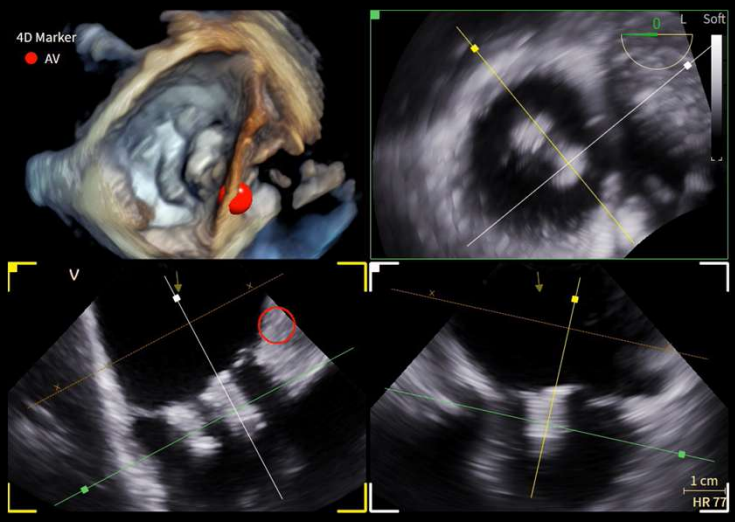

16

© Copyright. Society of Diagnostic Medical Sonography. All Rights Reserved.

Clinical Applications

Designed for Safety– enhancing the patient safety by reducing radion exposure, allowing for ZERO fluoroscopy workflows.

Structural Heart Procedures- getting most recognized in LAAO procedures however also helpful in Tricuspid Valve cases and introductory to Mitral Valve cases as well.

Cardiac Ablation – Used to guide in procedures for patients with a fib

17

Clinical Applications — Electrophysiology (EP)

Transseptal Puncture Guidance

- Visualizes septal tenting
- Confirms needle position
- Reduces reliance on fluoroscopy

Atrial Fibrillation Ablation

- Monitors catheter-tissue contact
- Helps identify gaps or poor contact
- Detects early complications (effusion)

Other EP Uses

- VT ablation (selected cases) (PVC & VT)
- Visualizing intracardiac anatomy during complex arrhythmia procedures

Mapping Catheter Placement

- Confirms catheter location in atria/ventricles
- Improves accuracy of 3D mapping systems

18

© Copyright. Society of Diagnostic Medical Sonography. All Rights Reserved.

Clinical Applications — Structural & Device Procedures

ASD/PFO Closure

- Defines defect size and rims
- Guides device deployment
- Confirms final device position

Left Atrial Appendage Occlusion

- Assesses LAA anatomy
- Guides device placement and seal
- Monitors for complications

Valve-Related Procedures (Selected Cases)

- Supports intracardiac visualization when TEE is limited
- Helps guide catheter positioning

Device & Lead Procedures

- Lead extraction: monitors for effusion/tamponade
- Device implantation: assists when fluoroscopy views are inadequate

Safety Monitoring Across Procedures

- Early detection of:
  - Pericardial effusion
  - Thrombus
  - Catheter-induced injury

19

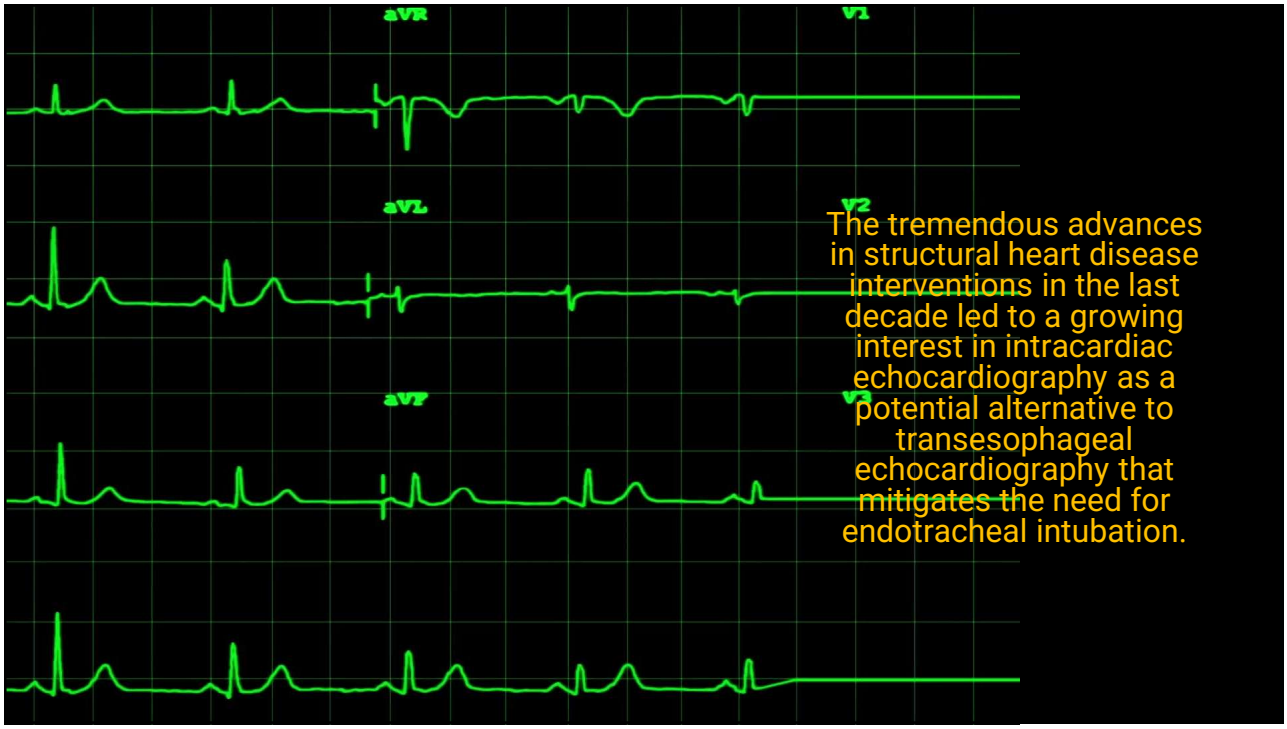

20

© Copyright. Society of Diagnostic Medical Sonography. All Rights Reserved.

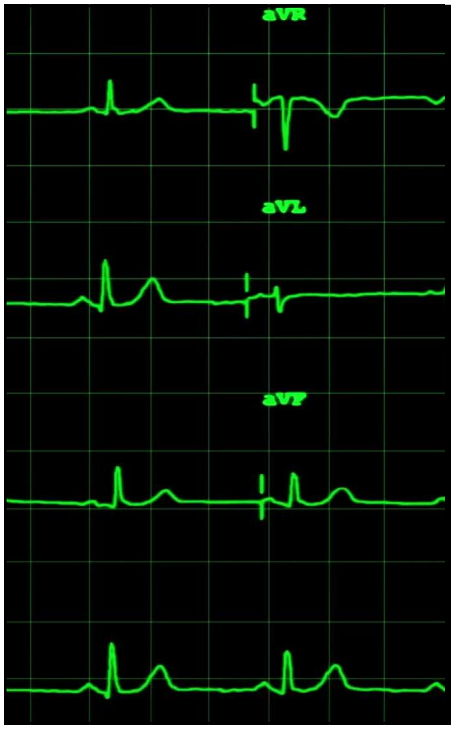

Intracardiac echocardiography has historically been used to guide a limited number of transcatheter cardiac interventions

Because of issues pertaining to cost, limitations of the current devices, the steep learning curve, and the tremendous advances in transesophageal echocardiography (TEE), the use of ICE in structural heart disease (SHD) remained limited.

21



Strengths of Intracardiac Echocardiography (ICE)

Real-Time Intracardiac Visualization	Direct views of septum, valves, and catheter-tissue contact	Helps guide precise catheter manipulation	**Radiation Reduction**	Decreases fluoroscopy time
Protects both patients and staff	Especially valuable in high-volume EP labs	**Continuous Imaging Without Sedation**	Unlike TEE, ICE does not require general anesthesia	Can remain in place comfortably for multi-hour procedures
Improved Procedural Safety	Early detection of pericardial effusion	Identifies thrombus formation	Monitors catheter-induced injury	**Enhanced Guidance for Complex Procedures**
	Transseptal puncture	AF ablation	Structural interventions (ASD/PFO closure, LAAO)	

22

© Copyright. Society of Diagnostic Medical Sonography. All Rights Reserved.

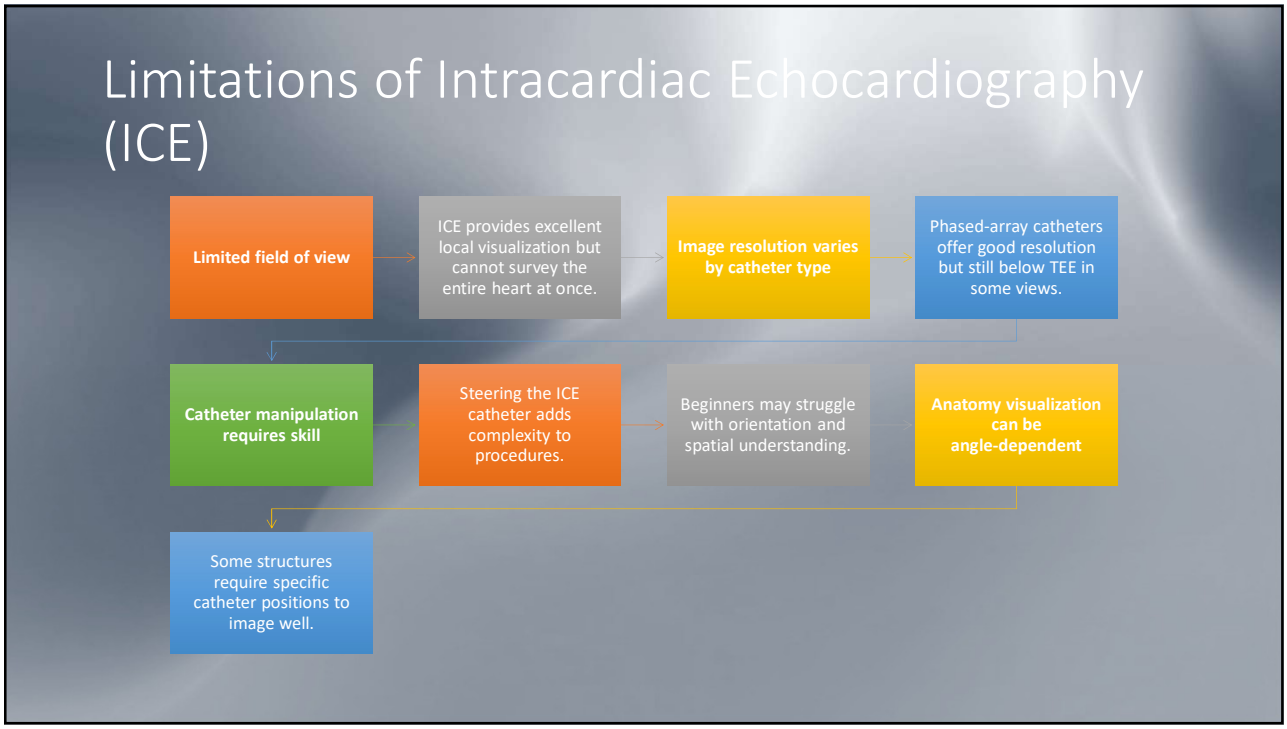

23

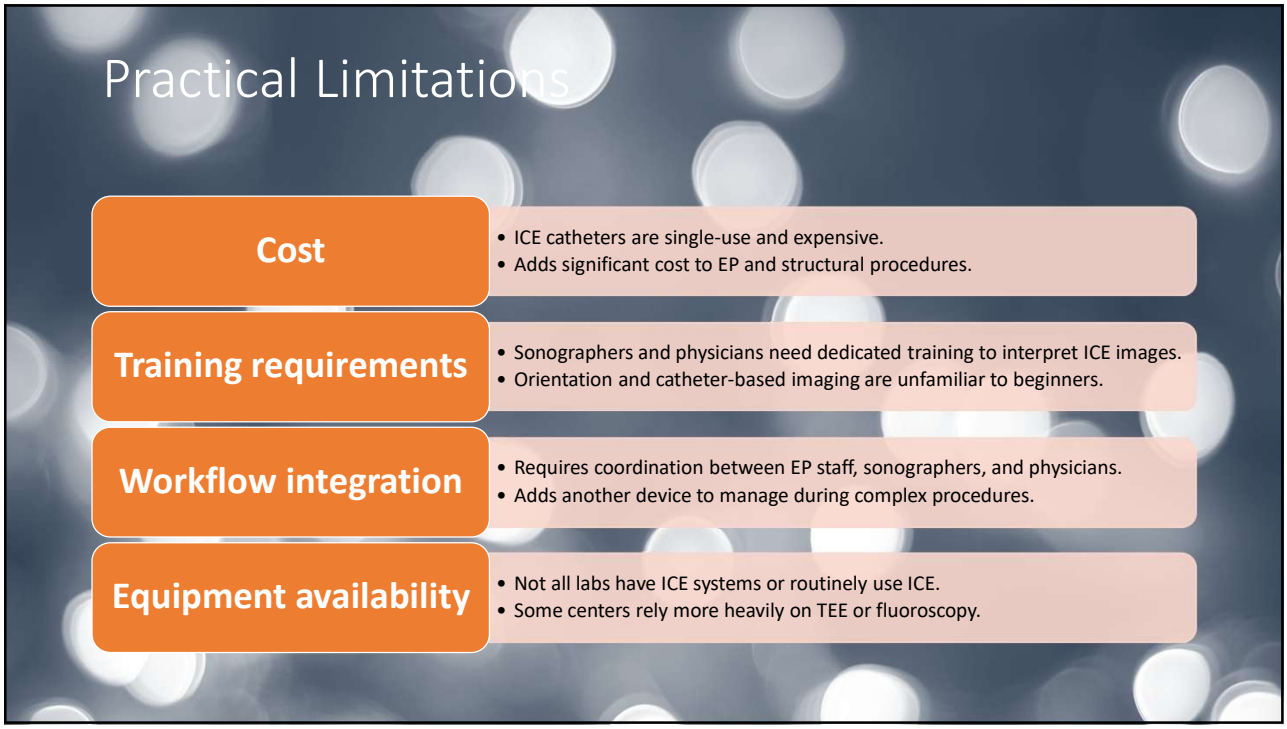

24

© Copyright. Society of Diagnostic Medical Sonography. All Rights Reserved.

Emerging Trends — Implications for Sonographers

- EXPANDING SKILL SET
- GREATER INVOLVEMENT IN EP & STRUCTURAL PROCEDURES
- WORKFLOW INTEGRATION
- TRAINING & PROFESSIONAL DEVELOPMENT

25

Summary — Intracardiac Echocardiography (ICE)

Let's recap up to this:

- Why ICE Emerged
- How ICE Developed
- Clinical Applications
- Strengths
- Limitations
- Emerging Trends



26

© Copyright. Society of Diagnostic Medical Sonography. All Rights Reserved.

Future Directions in Intracardiac Echocardiography (ICE)

3D ICE Development

AI-Enhanced Image Interpretation

Algorithms under development to assist with:

May support real-time decision-making during EP and structural procedures

Robotic & Remote Catheter Navigation

Fusion Imaging & Advanced Mapping Integration

ICE increasingly fused with 3D electroanatomic maps

Broader Use in Structural Heart Interventions

Growing interest in ICE-guided:

Potential shift toward ICE-dominant imaging in labs aiming to reduce anesthesia and fluoroscopy

27

ICE Catheter Types

Phased-array ICE catheters

- Most commonly used
- Provide steerable, high-resolution intracardiac imaging
- Typical size: **8–10 Fr**

Rotational ICE catheters

- Older technology
- Limited use today
- Narrow field of view

28

© Copyright. Society of Diagnostic Medical Sonography. All Rights Reserved.



Catheter Steering Basics

- Catheter has **anterior/posterior** and **left/right** steering controls
- Fine steering adjustments change imaging windows dramatically
- Beginners should understand:
  - Small movements = big changes in view
- Orientation is based on catheter position in the **right atrium**

29

Where ICE Lives in the Heart

ICE catheter is almost always positioned in the **right atrium (RA)**



From the RA, you can visualize:

- Interatrial septum
- Left atrium
- LAA
- Pulmonary veins
- Mitral valve
- Aortic root
- Right-sided structures

30

© Copyright. Society of Diagnostic Medical Sonography. All Rights Reserved.

Core Imaging Principles

ICE IS **NEAR-FIELD IMAGING** → STRUCTURES CLOSEST TO THE CATHETER APPEAR BEST

ORIENTATION IS **CATHETER-CENTRIC**, NOT PATIENT-CENTRIC

BEGINNERS MUST LEARN TO IDENTIFY ANATOMY FROM **UNCONVENTIONAL ANGLES**

31

ICE Setup & Initial RA Survey (Transseptal Workflow)

1. Catheter Positioned in the Right Atrium (RA)

- ICE catheter sits in the mid-RA

2. Identify Key RA Landmarks

- **Right atrial free wall**
- **Tricuspid valve**
- **Right ventricle inflow**
- **Superior vena cava (SVC)**
- **Inferior vena cava (IVC)**

3. Sweep Posteriorly Toward the Interatrial Septum (IAS)

•IAS appears as a smooth, bright line

•You should see:

- **Fossa ovalis** (thinner, slightly recessed area)
- **Thicker muscular rims** surrounding it

•This is the target zone for transseptal puncture

4. Confirm You Have a True Septal View

•Septum should appear **flat**, not curved away

•No dropout

•No "pseudo-septum" (common beginner pitfall)

32

© Copyright. Society of Diagnostic Medical Sonography. All Rights Reserved.

ICE Guidance for LAAO — Device Sizing & Positioning

1. Visualize the Left Atrial Appendage (LAA) Anatomy

- From the RA, sweep posteriorly across the IAS into the LA
- Identify:
- Confirm you have a stable, reproducible view before sizing

2. Assess LAA Dimensions

- ICE helps estimate:
- asurements should correlate with CT/TEE sizing
- Beginners should focus on **consistency** rather than perfect precision

3. Identify LAA Morphology

- Common shapes: windsock, chicken-wing, cactus, cauliflower

4. Guide Device Positioning Before Deployment

- Watch the **delivery sheath** enter the LAA
- Confirm:
- ICE should show the device sitting **coaxially** with the LAA

5. Pre-Deployment Safety Checks

33

Sonographer Roles in EP & Structural Lab Workflow

1. **Pre-Procedure Preparation**
2. **Intra-Procedure Imaging Support**
3. **Safety Monitoring**
4. **Workflow Coordination**
5. **Post-Procedure Responsibilities**

34

© Copyright. Society of Diagnostic Medical Sonography. All Rights Reserved.



35

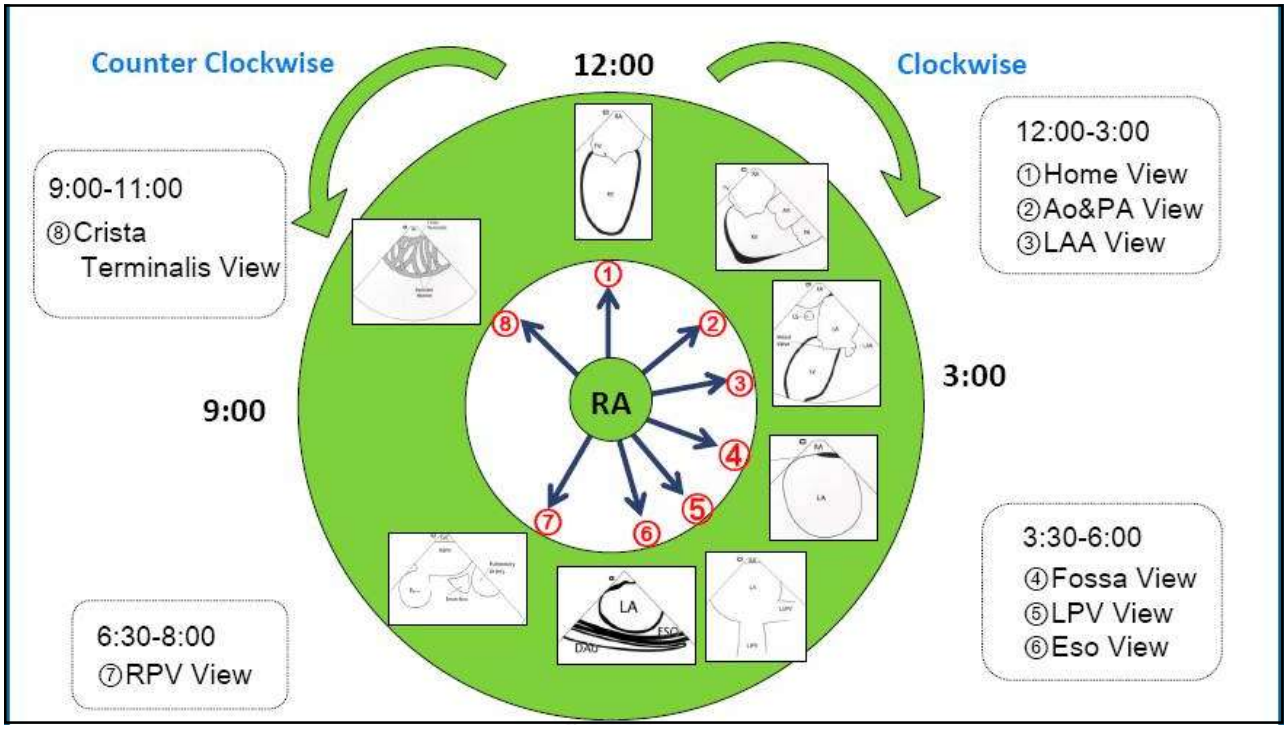

36

© Copyright. Society of Diagnostic Medical Sonography. All Rights Reserved.

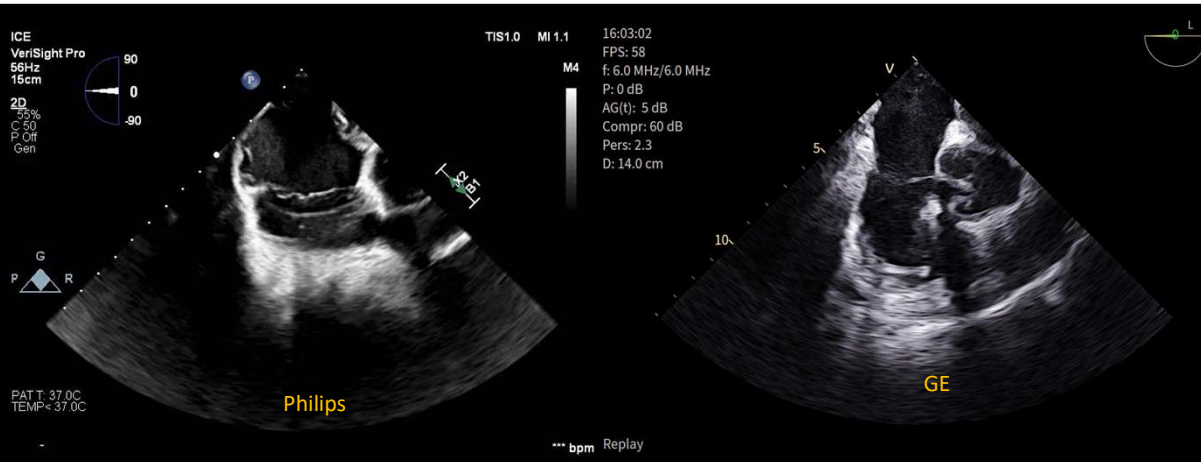

Home View (0°/RA View): Displays the right atrium, tricuspid valve (TV), and right ventricle (RV). Used for overall navigation.

37

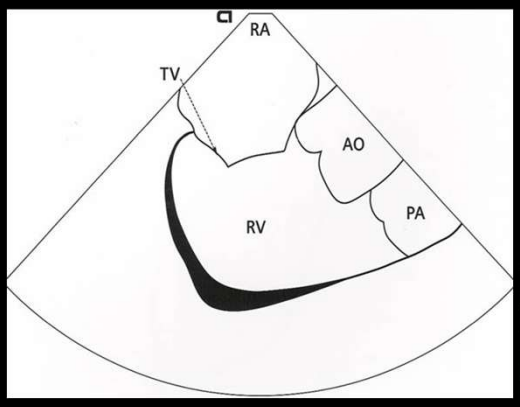

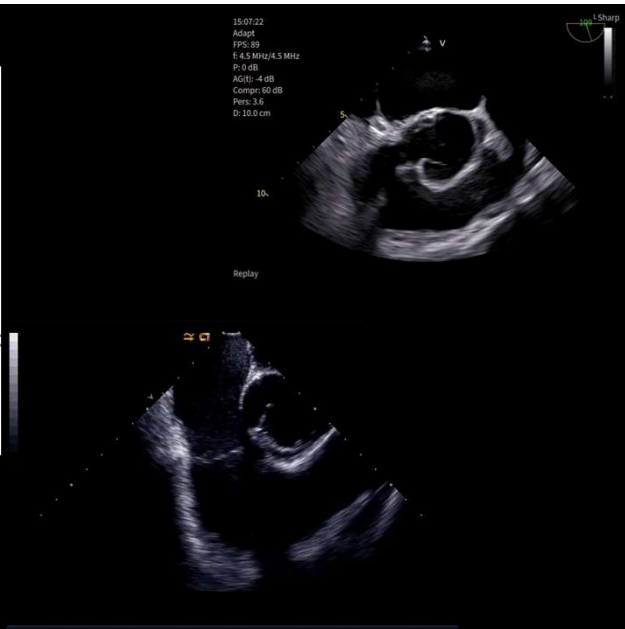

- RVOT View: Clockwise rotation from Home View displays the Right Ventricular Outflow Tract (RVOT) and aortic valve.

38

© Copyright. Society of Diagnostic Medical Sonography. All Rights Reserved.

- **LVOT View**: Further clockwise rotation shows the Left Ventricular Outflow Tract (LVOT) and aortic valve.

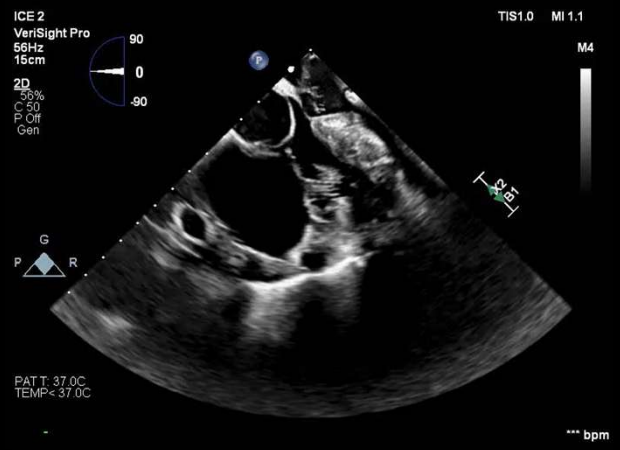

39

Left Atrial Appendage (LAA) View: Further clockwise rotation shows the LAA and mitral valve, often with the Circumflex Artery visible.

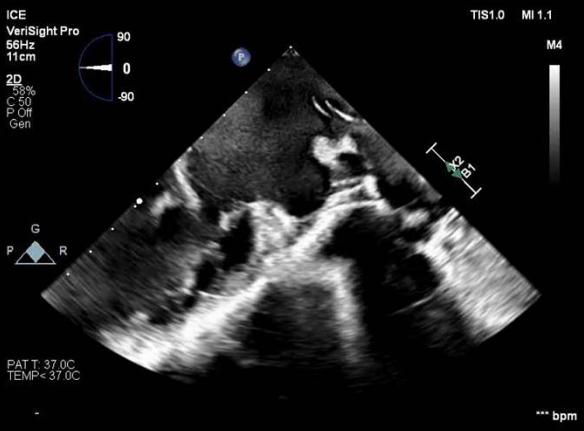

40

© Copyright. Society of Diagnostic Medical Sonography. All Rights Reserved.

- Pulmonary Vein (PV) Views: Continued clockwise rotation captures the Left and Right Superior/Inferior Pulmonary Veins.

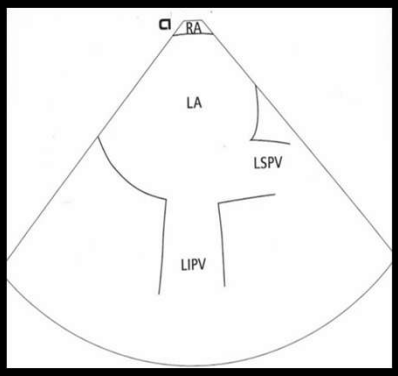



41

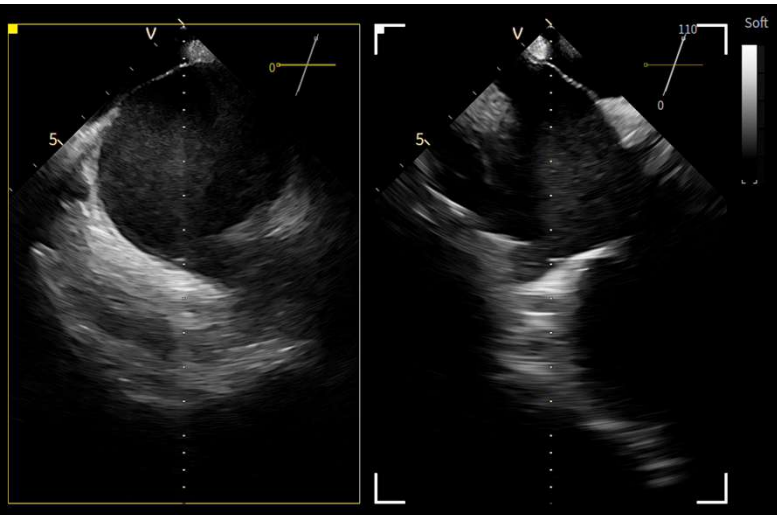

- Septal View/Interatrial Septum: Obtained by rotating the transducer towards the posterior/rightward direction to visualize the atrial septum (fossa ovalis), coronary sinus, and superior vena cava (SVC).

42

© Copyright. Society of Diagnostic Medical Sonography. All Rights Reserved.

ICE Guidance for LAAO — Device Deployment, Seal Assessment & Post-Release Safety

1. Visualize the Device in the LAA Before Release

- Confirm the device is **coaxial** with the LAA
- Device should sit in the **landing zone**, not too proximal or too deep
- Look for: Sweep across multiple ICE windows to confirm stability

2. Watch the Deployment Sequence

- Observe the **delivery sheath** retracting
- Device should expand smoothly without jumping or shifting
- ICE should show:

3. Perform the "PASS" or "CLOSE" Seal Assessment

Position:

- Device sits at the landing zone
- No protrusion into the LA

- **Anchor:**
  - Device appears stable with no rocking
  - Anchors engaged symmetrically
- **Size:**
  - Device fully expanded
  - No excessive compression or under-expansion
- **Seal:**
  - No visible gaps around the device
  - LAA ostium appears fully covered

4. Post-Release Safety Monitoring

- Sweep the **pericardial space** for effusion
- Reassess the **LAA wall** for abnormal motio or injury
- Confirm **no thrombus** formation
- Re-evaluate device position after release t ensure stability
- Check for **interference with adjacent structures** (mitral valve, pulmonary veins)

5. Final Confirmation

- Device remains stable across multiple view
- No effusion
- No thrombus
- Seal appears complete
- Procedure can proceed to closure

43

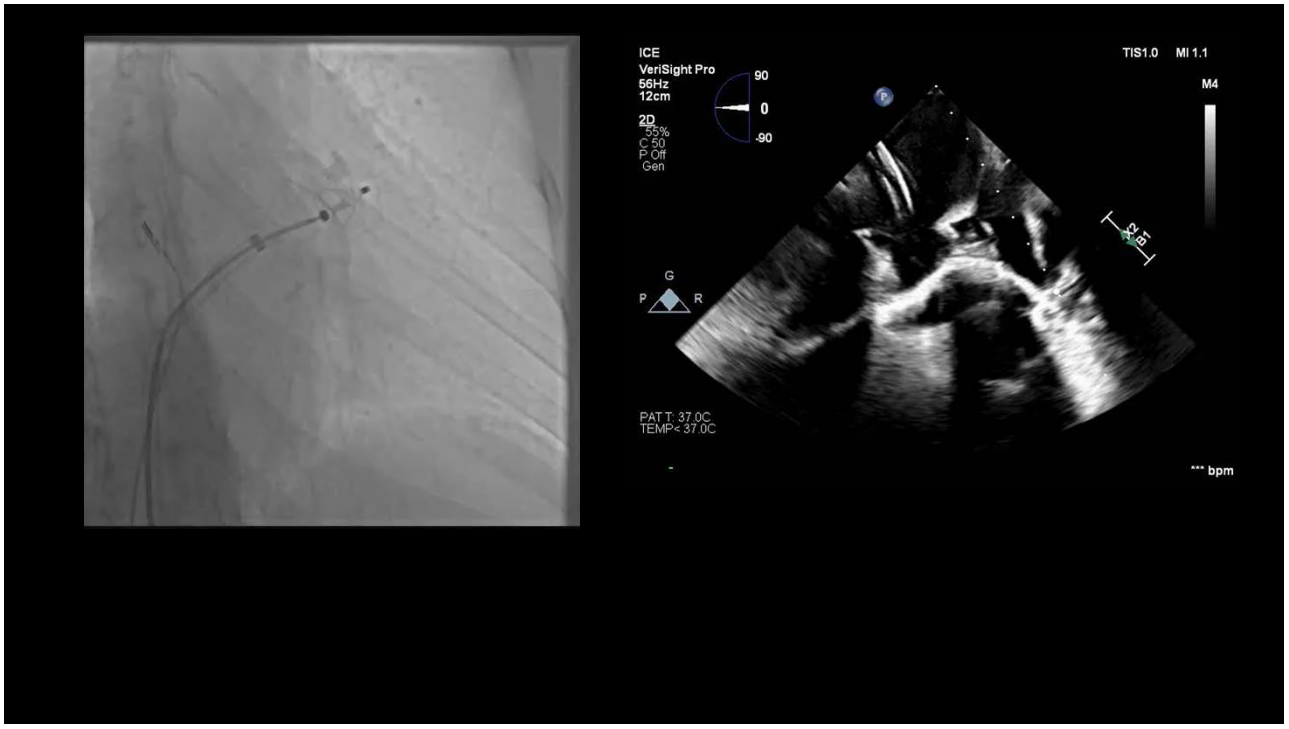

44

© Copyright. Society of Diagnostic Medical Sonography. All Rights Reserved.

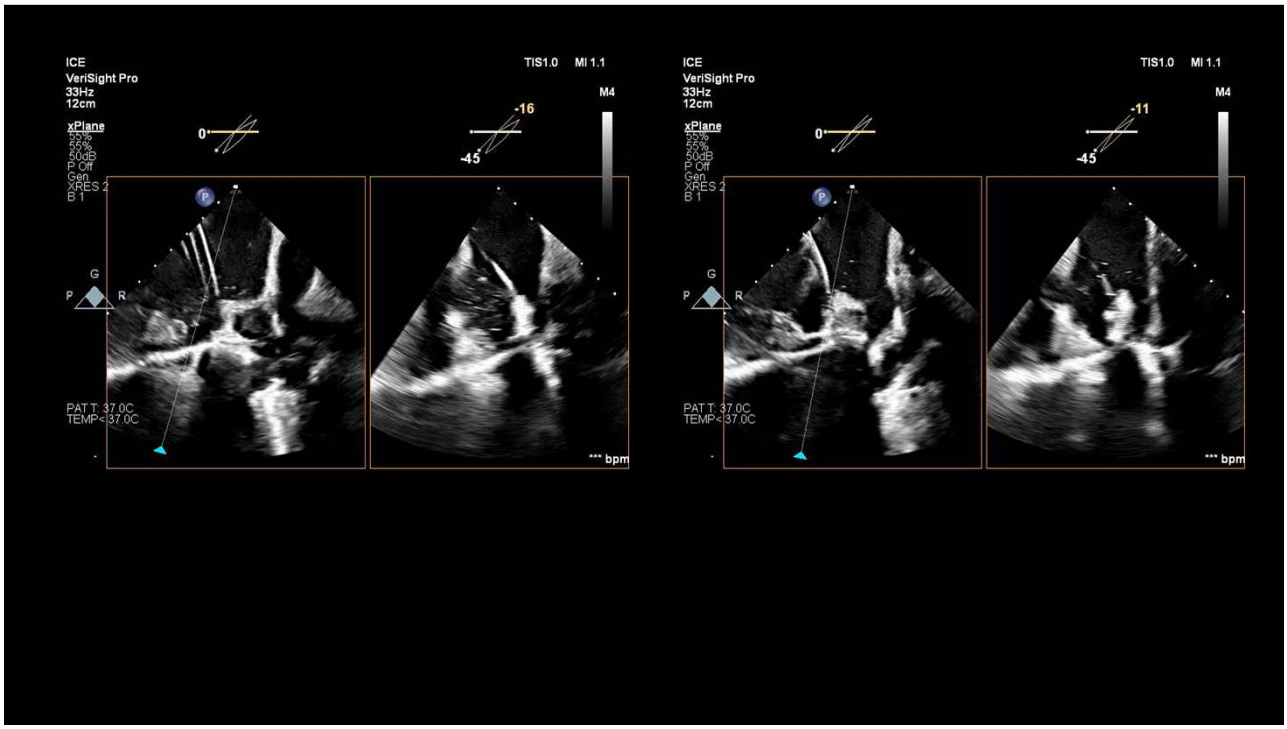

45

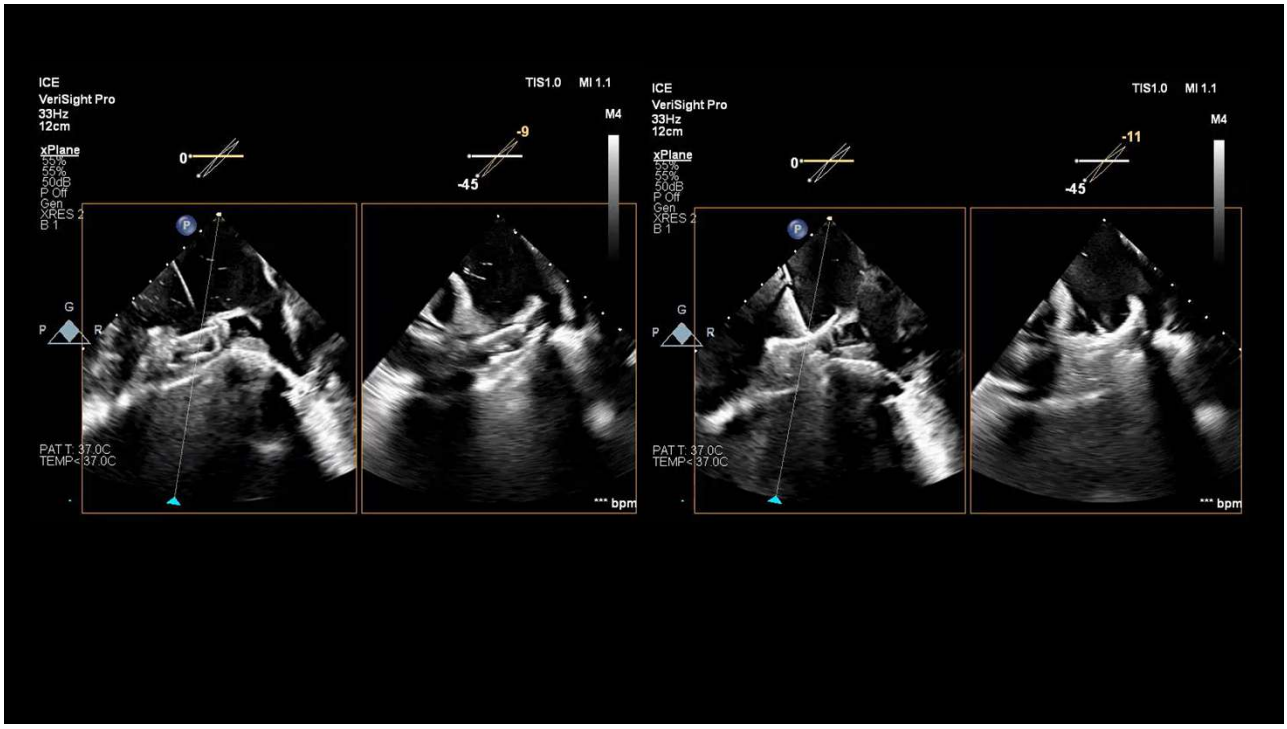

46

© Copyright. Society of Diagnostic Medical Sonography. All Rights Reserved.

Tug Test

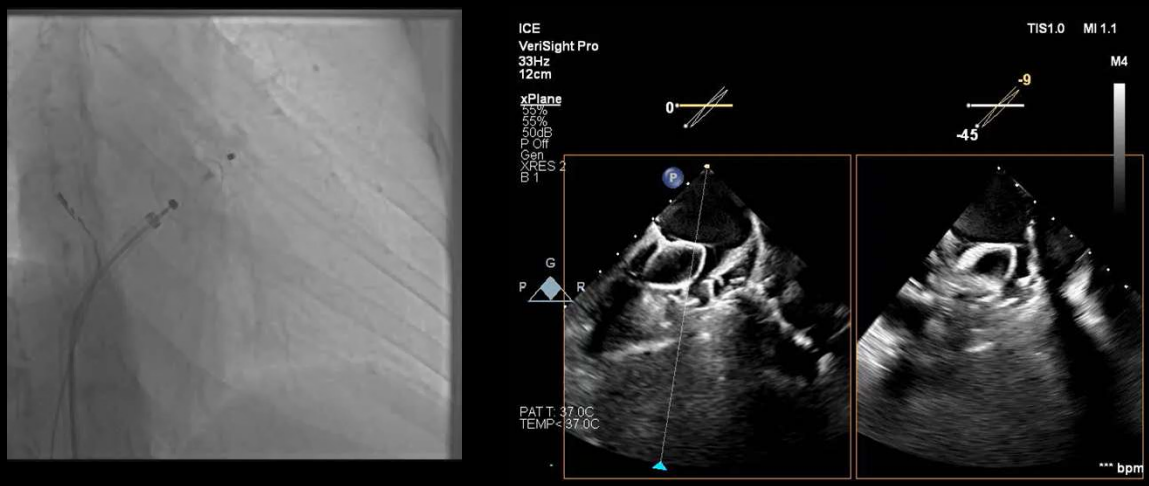

47

LAAO Device — LAA View

Normal / Correct Position

- Device centered in **landing zone**
- Symmetric expansion
- Anchors engaged
- No protrusion into LA **Abnormal / Concerning**
- Device tilted or off-axis
- Proximal seating (too shallow)
- Deep seating (too distal)
- Gaps around device (poor seal)
- Device rocking or unstable

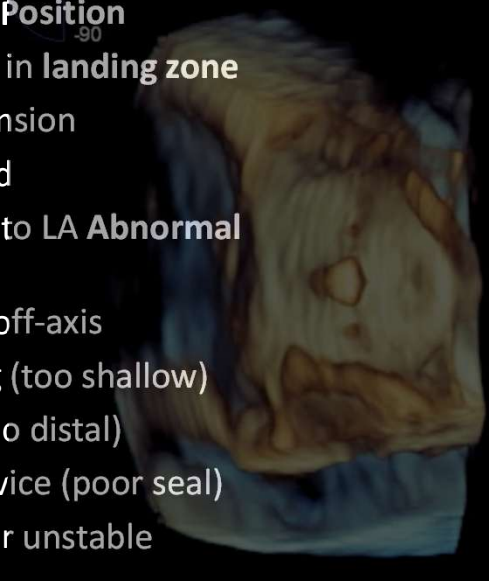

48

© Copyright. Society of Diagnostic Medical Sonography. All Rights Reserved.

Integrating ICE Into Lab Workflow & Evolving Sonographer Practice

Why Workflow Integration Matters

- Sonographers play a growing role in **real-time procedural imaging**, not just pre-procedural echo
- Effective ICE use requires coordination across EP physicians, structural cardiologists, anesthesia, and device teams

Why Emerging Trends Matter

- Labs adopting **low-fluoro or zero-fluoro workflows** rely heavily on ICE
- Sonographers must adapt to evolving procedural environments and imaging demands

49

The Future of Sonographer Practice in ICE-Driven Labs

1. Increasing Procedural Leadership
2. Adoption of New Imaging Technologies
3. Evolving Workflow Expectations

4. Expanded Training & Credentialing
   - More labs will require formal ICE competency
   - ACS-level roles will emphasize procedural imaging mastery
   - Continuing education will focus on advanced ICE techniques and emerging technologies

5. A New Professional Identity
   - Sonographers shift from "image acquisition" to procedural imaging specialists
   - ICE becomes a core part of the sonographer's identity in EP and structural heart teams
   - The future favors sonographers who combine technical skill, procedural insight, and adaptability

50

© Copyright. Society of Diagnostic Medical Sonography. All Rights Reserved.

Essential Skills for Sonographers in Evolving ICE Practice

1. Technical Imaging Skills

- Orientation mastery

2. Procedural Workflow Skills

3. Professional Development & Advanced Practice Skills

- ICE-specific training
- ACS-level competencies
- Adaptability to emerging trends

51

ICE Interpretation: From Beginner to Intermediate Focus:

- Recognizing normal vs abnormal anatomy
- Identifying catheter position errors
- Distinguishing artifact vs pathology
- Understanding LA/LAA variants
- Interpreting device seating and seal Why it fits:
- Deepens the learner's ability to "read" ICE, not just acquire it
- Perfect for sonographers transitioning into procedural roles

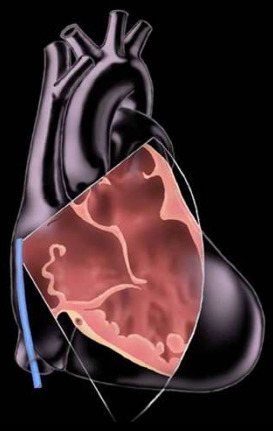

52

© Copyright. Society of Diagnostic Medical Sonography. All Rights Reserved.

Catheter & Device Position Interpretation Using ICE Protocol Views

- **Transseptal Needle & Sheath — IAS View**
- **Normal / Correct Position**
- Needle tip clearly visualized approaching the **fossa ovalis**
- Smooth, symmetric **tenting** toward LA
- Sheath aligned coaxially with septum **Abnormal / Concerning**
- Needle tip not visible (dangerous)
- Tenting on **muscular rim** instead of fossa
- Off-axis approach (needle angled superior/inferior)
- No tenting → needle not on septum

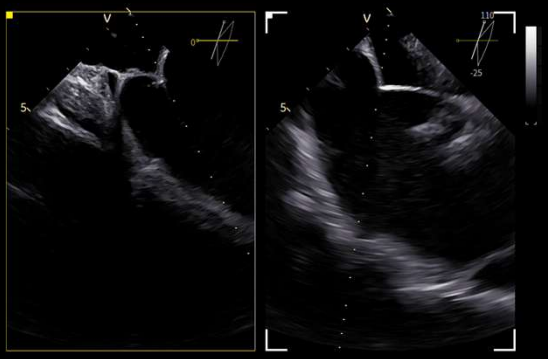

53

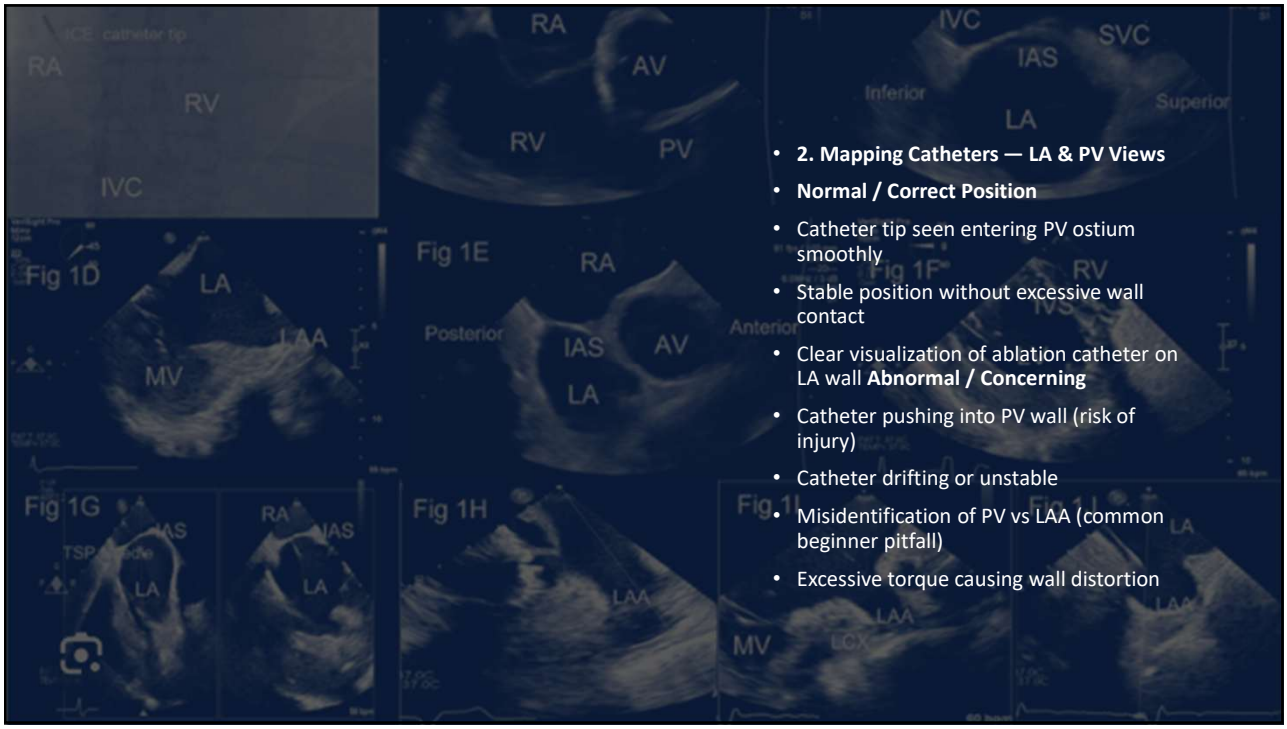

- **2. Mapping Catheters — LA & PV Views**
- **Normal / Correct Position**
- Catheter tip seen entering PV ostium smoothly
- Stable position without excessive wall contact
- Clear visualization of ablation catheter on LA wall **Abnormal / Concerning**
- Catheter pushing into PV wall (risk of injury)
- Catheter drifting or unstable
- Misidentification of PV vs LAA (common beginner pitfall)
- Excessive torque causing wall distortion

54

© Copyright. Society of Diagnostic Medical Sonography. All Rights Reserved.



Sheaths & Guidewires — RA, IAS, LA Views

Normal / Correct Position

- Smooth advancement through RA → IAS → LA
- Guidewire clearly seen in target chamber
- No excessive wall contact **Abnormal / Concerning**
- Guidewire entering wrong chamber
- Sheath pushing septum excessively
- Wall tenting in unintended locations
- Guidewire whipping or unstable

6. Pericardial Space — Safety Interpretation

Normal

- No fluid
- Clear epicardial/pericardial separation **Abnormal / Concerning**
- New anechoic fluid → effusion
- Echo-bright clot → hemopericardium
- RA/RV diastolic collapse → tamponade
- Rapid fluid accumulation → emergency

55

1. Dropout vs True Septal Defect — IAS View

2. Near-Field Clutter vs Thrombus — RA/LA Views

3. Reverberation vs Device Malposition — LAAO Views

4. Acoustic Shadow vs Wall Injury — LA/LAA Views

5. Mirror Image vs Extra Structure — PV/Mitral Views

6. Gain-Related Noise vs Sludge — LAA View

7. Motion Artifact vs Tamponade — Pericardial Space

56

© Copyright. Society of Diagnostic Medical Sonography. All Rights Reserved.

In Conclusion today:

- **We covered the historical development & clinical applications of ICE**
- **Strengths and limitations of ICE for appropriate clinical use**
- **Emerging trends in ICE for evolving sonography practice**
- This presentation doesn't just teach ICE — **it prepares sonographers for the future of cardiac imaging.**

57

Thank You

- **The future belongs to imaging specialists who combine technical excellence, procedural insight, and adaptability — and ICE is the modality that brings all three together.**

58

© Copyright. Society of Diagnostic Medical Sonography. All Rights Reserved.