2026 SDMS Annual Conference



Neoplastic Mutations and Cardiac Involvement

Sydni Hennemann BS ACS RDCS RCCS FASE

Barnes Jewish Hospital &
Washington university, St.Louis, MO

1

No Disclosures

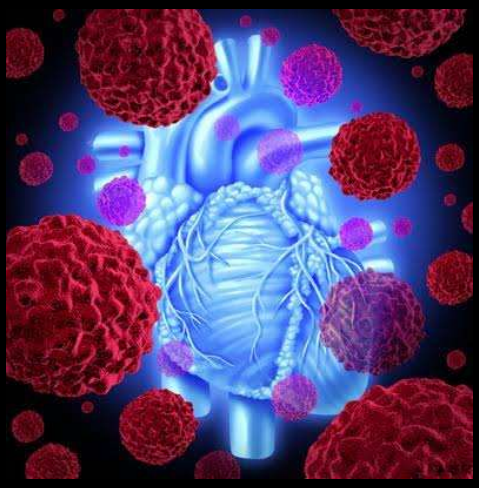

2

© Copyright. Society of Diagnostic Medical Sonography. All Rights Reserved.

2026 SDMS Annual Conference

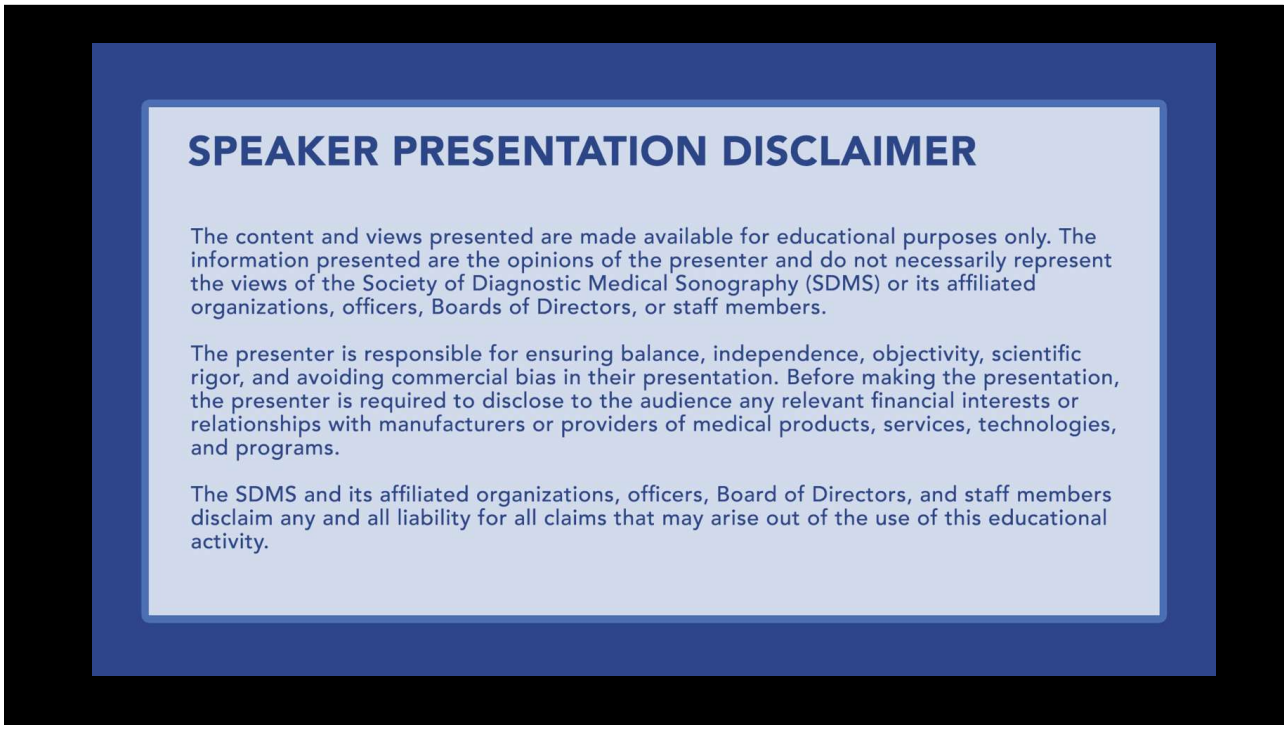

3

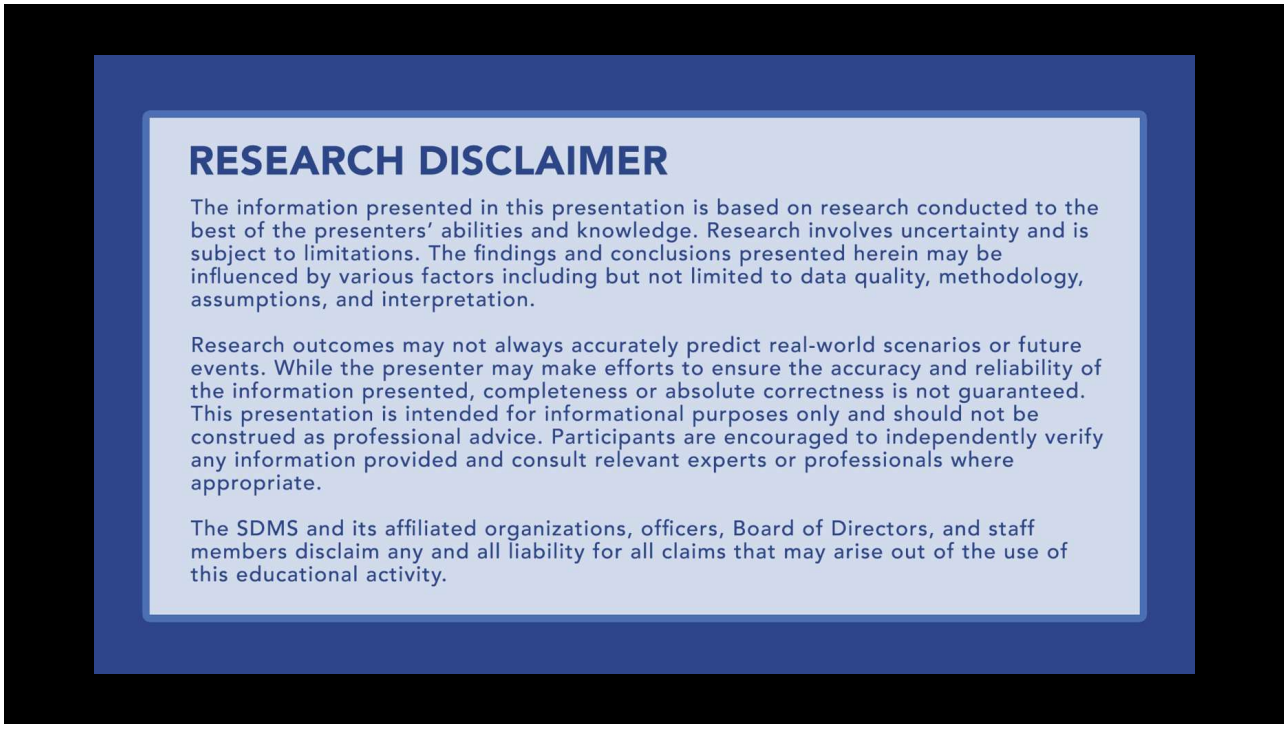

4

© Copyright. Society of Diagnostic Medical Sonography. All Rights Reserved.

GENERATIVE AI DISCLAIMER

The presenter utilized the use of large language models (LLMs) and generative artificial intelligence (AI) as a productivity tool to assist in drafting and refining content in this presentation.

While these tools can aid in structuring ideas, summarizing, paraphrasing, and language polishing, they have inherent limitations and cannot replace human creativity, critical thinking, or expert judgment. AI-generated content may contain errors, biases, or gaps in knowledge.

This presentation is intended for informational purposes only and should not be construed as definitive or authoritative guidance. Participants are encouraged to critically evaluate the information presented and consult relevant experts as needed. The SDMS and its affiliated organizations, officers, Board of Directors, and staff members disclaim any and all liability for claims that may arise from the use or interpretation of this educational material.

5

OBJECTIVES:

1. Identify echocardiographic findings associated with cardiac involvement i neoplastic disease to support early recognition.
2. Describe the role of echo evaluation including global longitudinal strain an monitoring disease progression and cardiotoxicity.
3. Recognize the clinical value of echocardiography in guiding management decisions within cardio-oncology care.

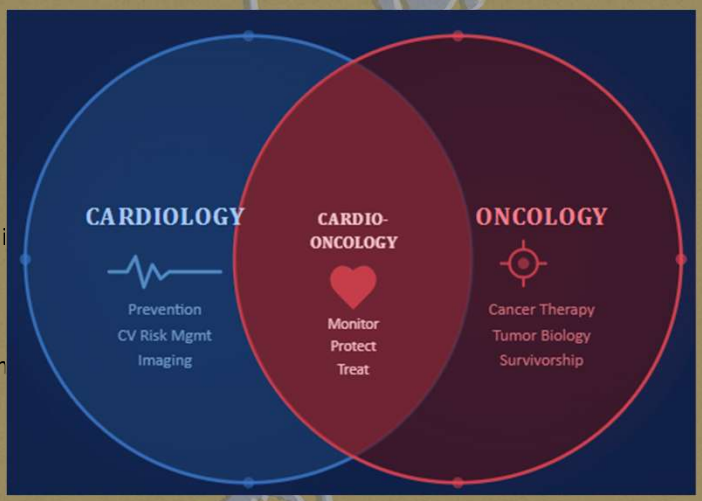

6

© Copyright. Society of Diagnostic Medical Sonography. All Rights Reserved.

Why Cardio-Oncology Matters



Rising cancer survivorship

Increased exposure to cardiotoxic therapies

Echo as frontline modality

7

What Sonographers Should Document

- Precise GLS values
- Vendor consistency
- Regional strain abnormalities
- EF + LV volumes
- Pericardial findings

8

© Copyright. Society of Diagnostic Medical Sonography. All Rights Reserved.

NEOPLASTIC CARDIAC INVOLVEMENT

Neoplastic refers to the abnormal, unregulated, and excessive growth of cells in the body, typically resulting in a tumor (which can be benign or cancerous) (NIH)

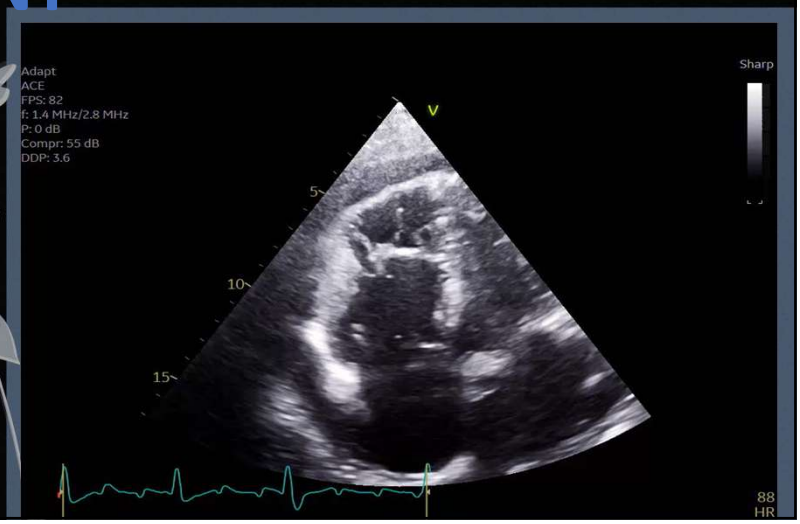

9

Primary and Secondary Cardiac Tumors: Types and Descriptions

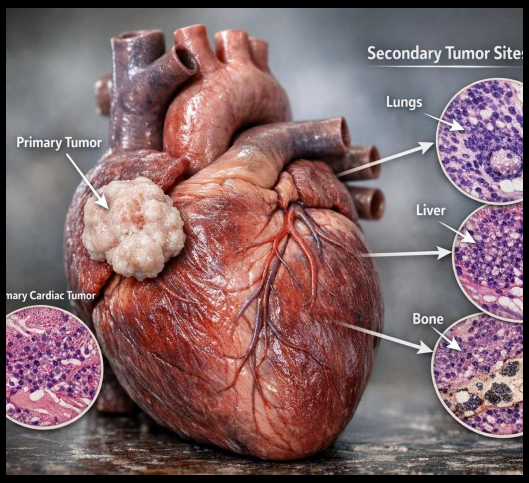

Primary Cardiac Tumors

Primary cardiac tumors such as myxomas and sarcomas are rare but critical to diagnose for proper treatment planning.

Secondary Cardiac Tumors

Secondary cardiac tumors arise from metastases and are more common than primary tumors in the heart.

Classification Importance

Classifying tumors by histology, location, and malignancy helps guide tailored management and treatment strategies.

10

© Copyright. Society of Diagnostic Medical Sonography. All Rights Reserved.

Pathways of Cardiac Involvement

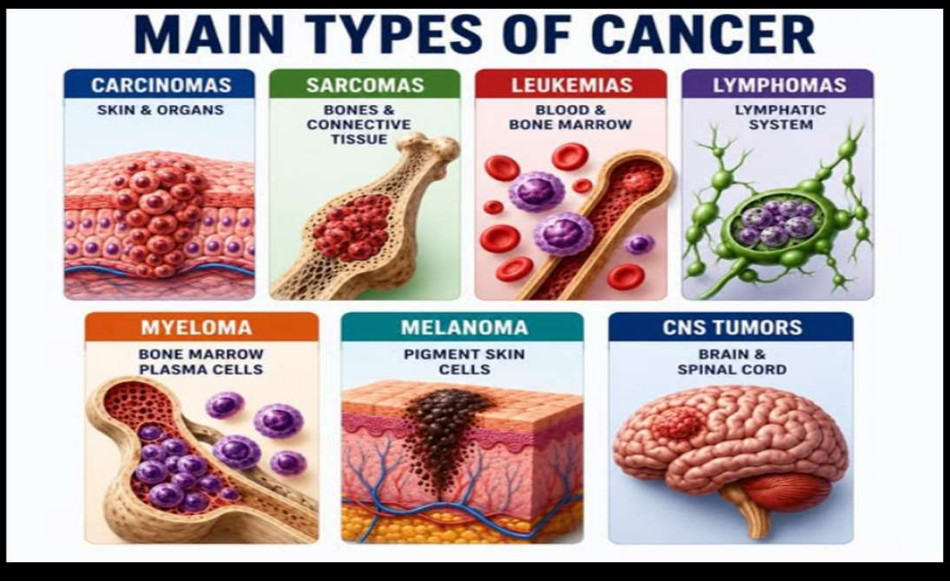

11

COMMON PRIMARY SOURCES

1. Melanoma
2. Lung cancer
3. Breast cancer
4. Lymphoma
5. Sarcoma

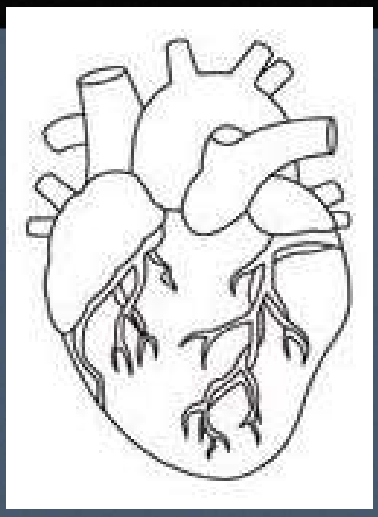

12

© Copyright. Society of Diagnostic Medical Sonography. All Rights Reserved.

MELANOMA

Pt presentation:

recurrent right neck melanoma with nodal involvement who presents for consultation for surgical tumor harvest for tumor-infiltrating lymphocyte therapy.



13

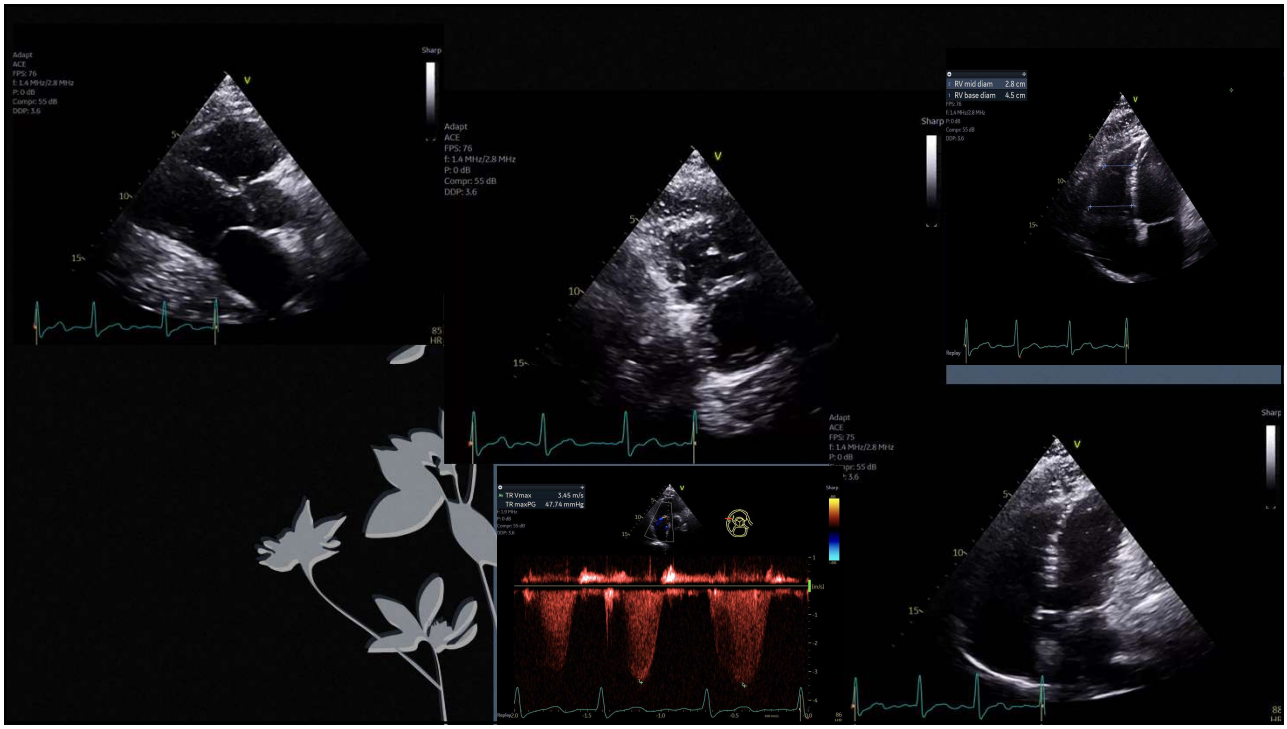

14

© Copyright. Society of Diagnostic Medical Sonography. All Rights Reserved.

2026 SDMS Annual Conference

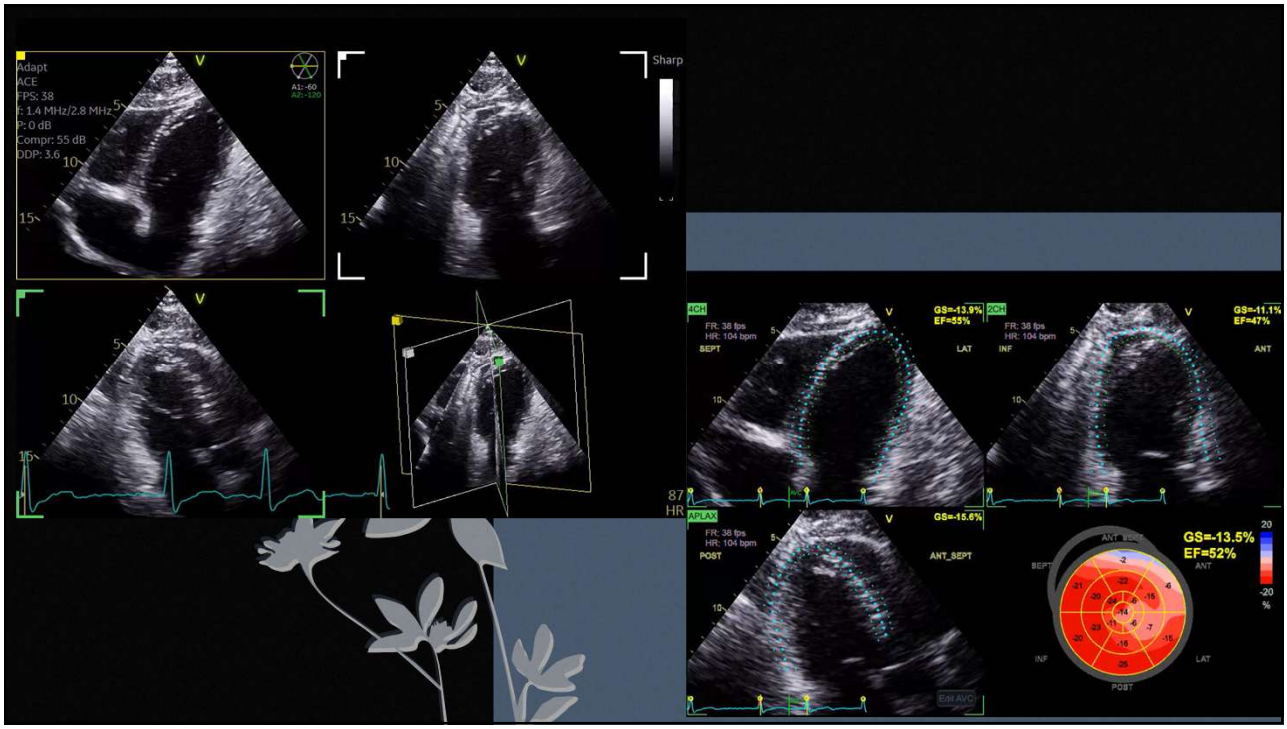

15

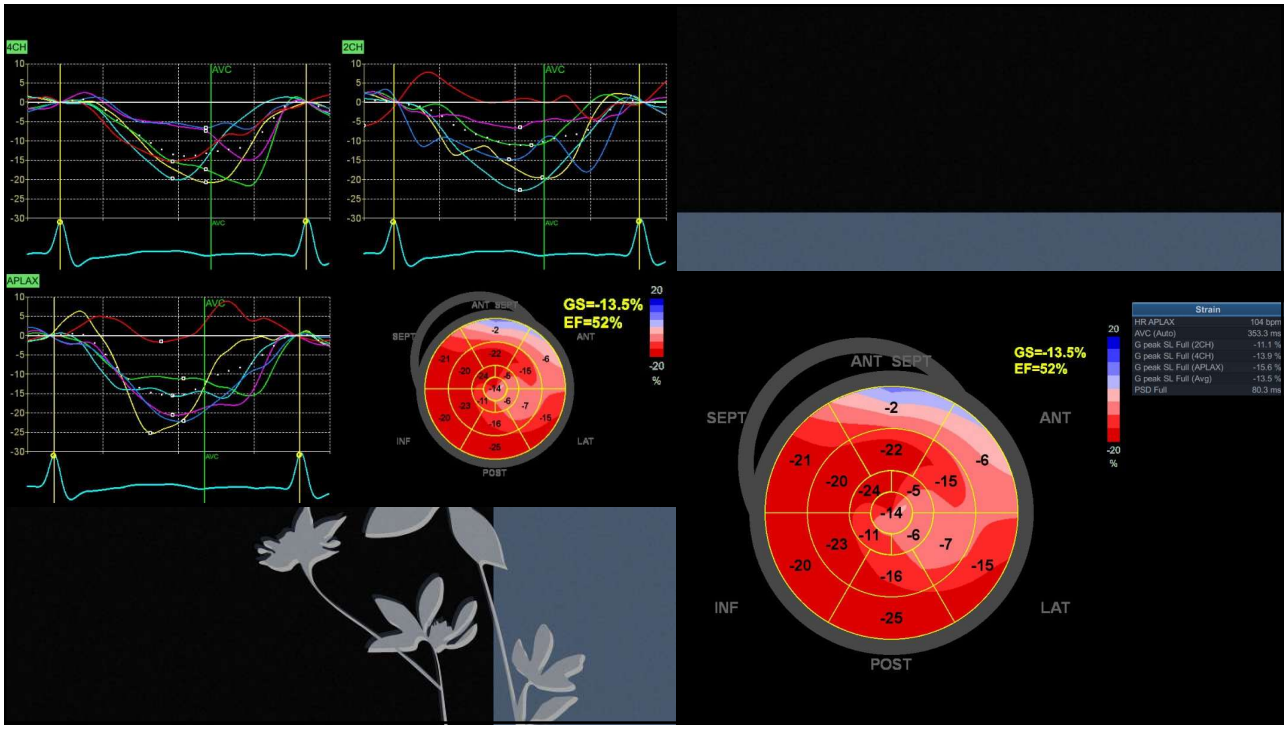

16

© Copyright. Society of Diagnostic Medical Sonography. All Rights Reserved.

LUNG METS/ LEIOMYOSARCOMA

Presented to the ICU s/p planned ex lap, removal of pelvic masses, tumor debulking for abd/pelvic masses c/f leiomyosarcoma. Intra-op course c/b hemorrhagic shock requiring multiple boxes of MTP

1. Abdominopelvic masses which are suspicious for leiomyosarcoma.
2. Pulmonary nodules.

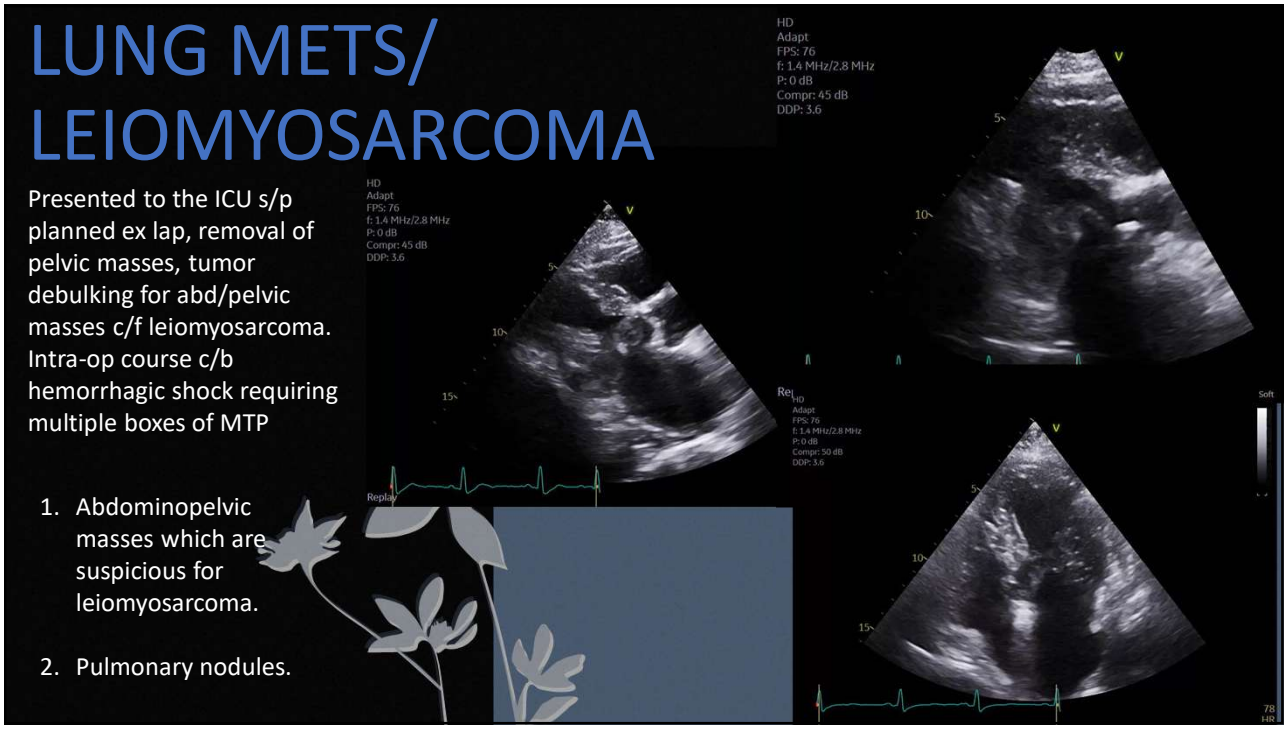

17

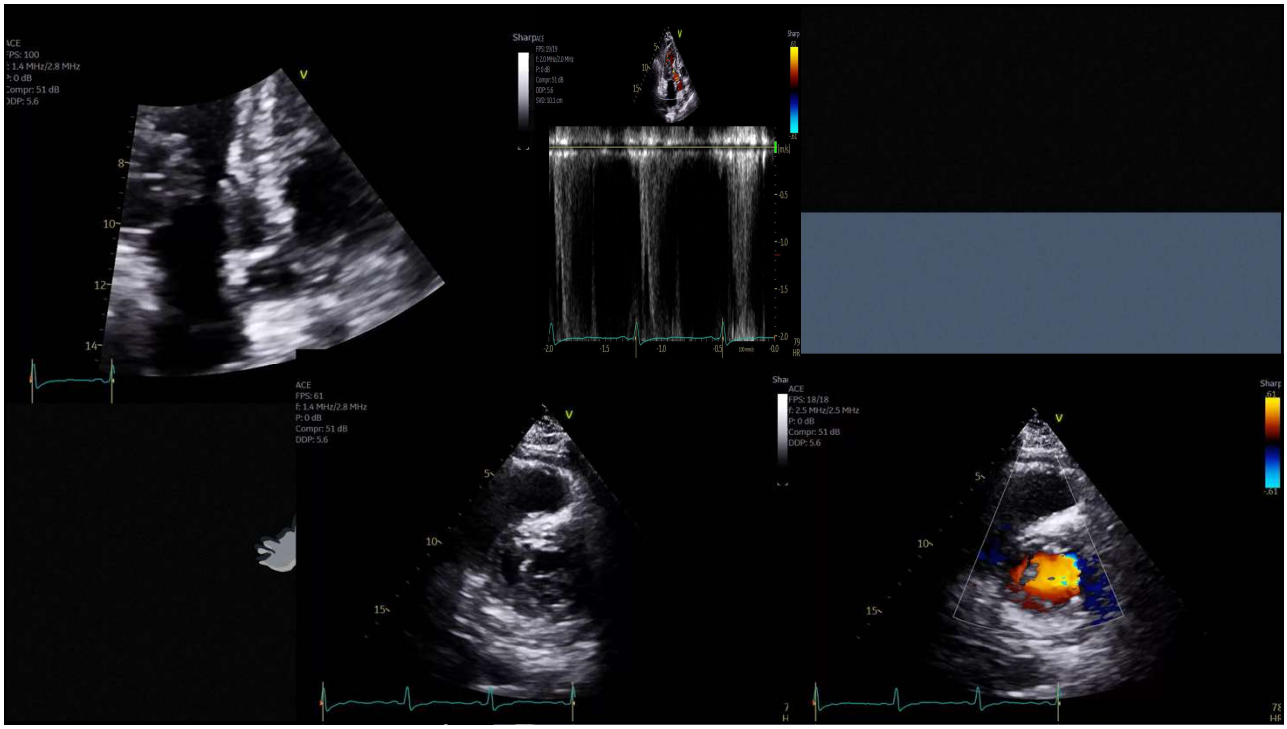

18

© Copyright. Society of Diagnostic Medical Sonography. All Rights Reserved.

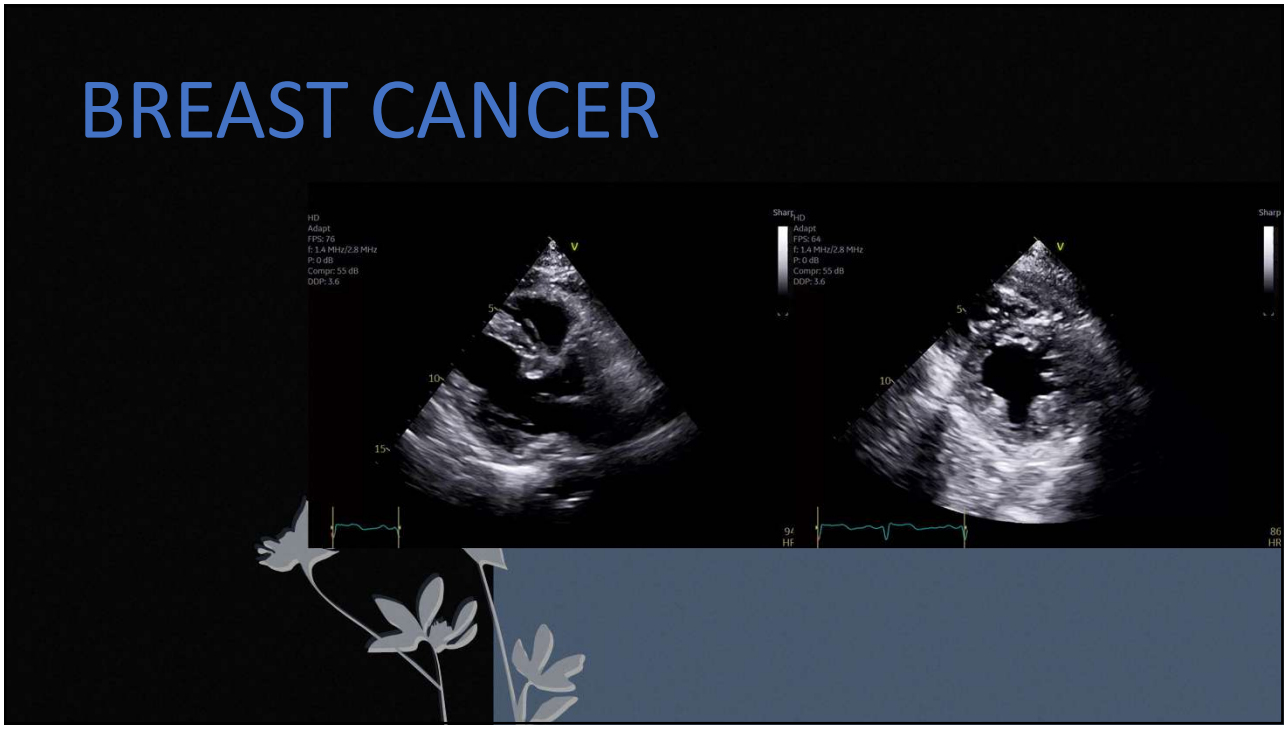

19

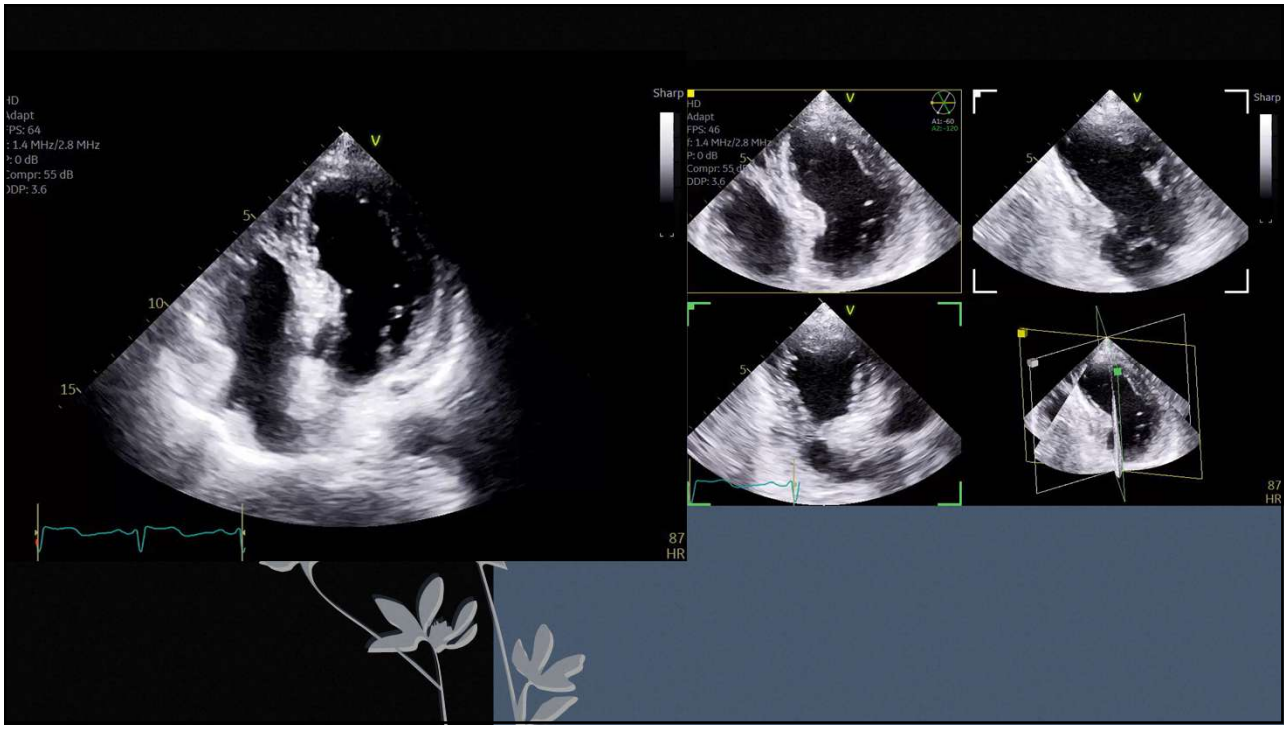

20

© Copyright. Society of Diagnostic Medical Sonography. All Rights Reserved.

2026 SDMS Annual Conference

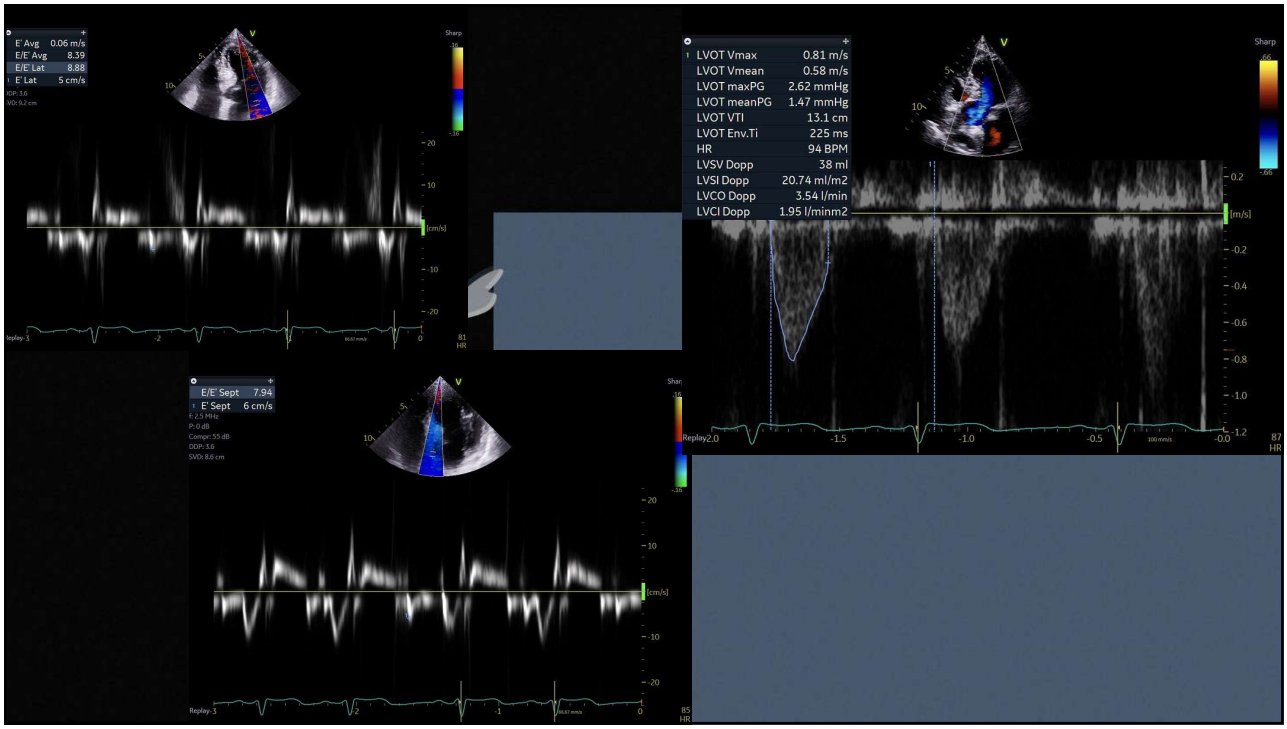

21

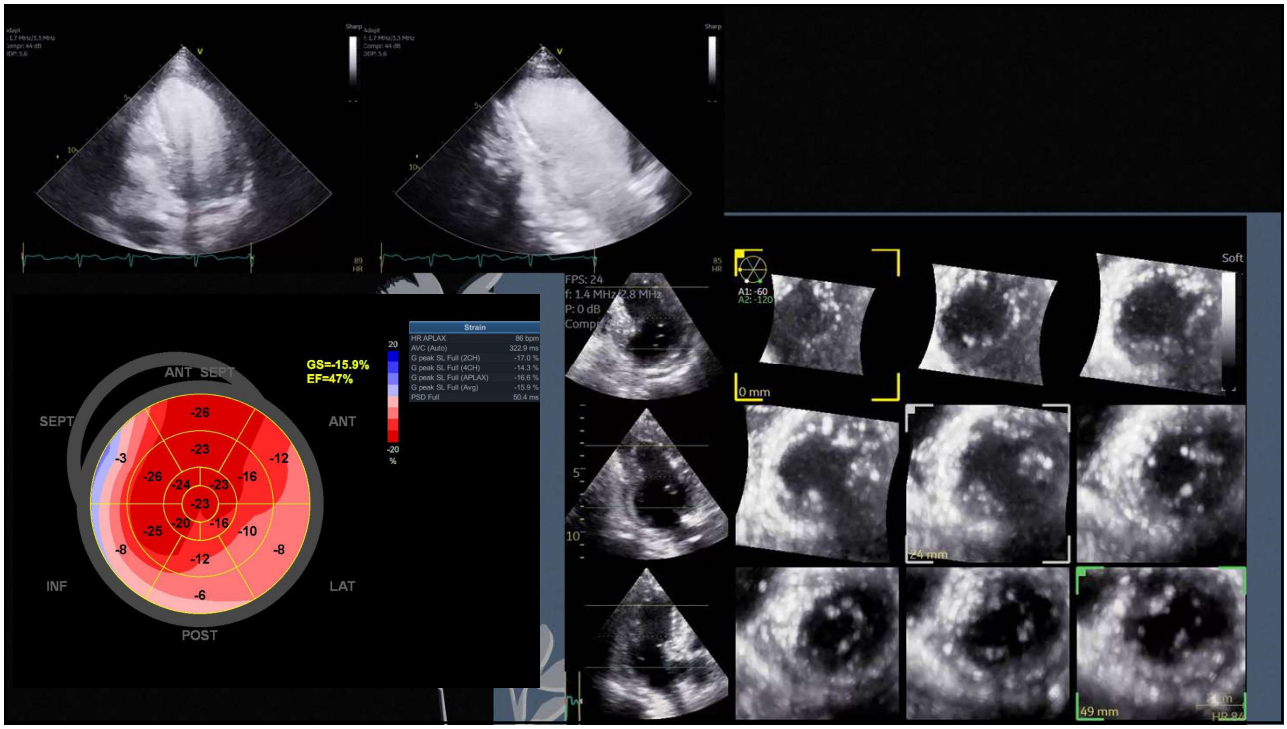

22

© Copyright. Society of Diagnostic Medical Sonography. All Rights Reserved.

METS TO THE RVOT

81 y.o. male with metastatic cancer in the setting of gastroesophageal cancer and presumed primary triple negative breast cancer with the progression of disease on multiple therapies (metastases to heart, lung, and liver), AFib on Eliquis who presented to ED as instructed by his oncologist for abnormal imaging findings.

23



24

© Copyright. Society of Diagnostic Medical Sonography. All Rights Reserved.

2026 SDMS Annual Conference

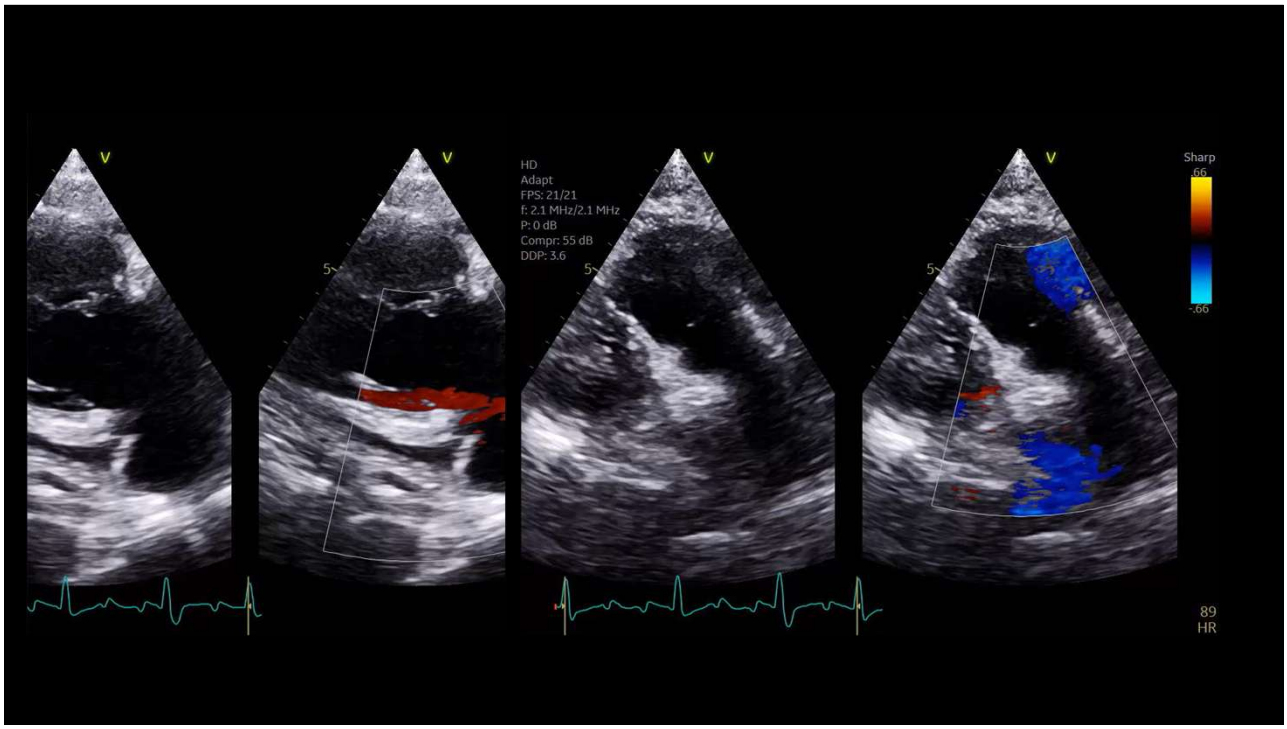

25

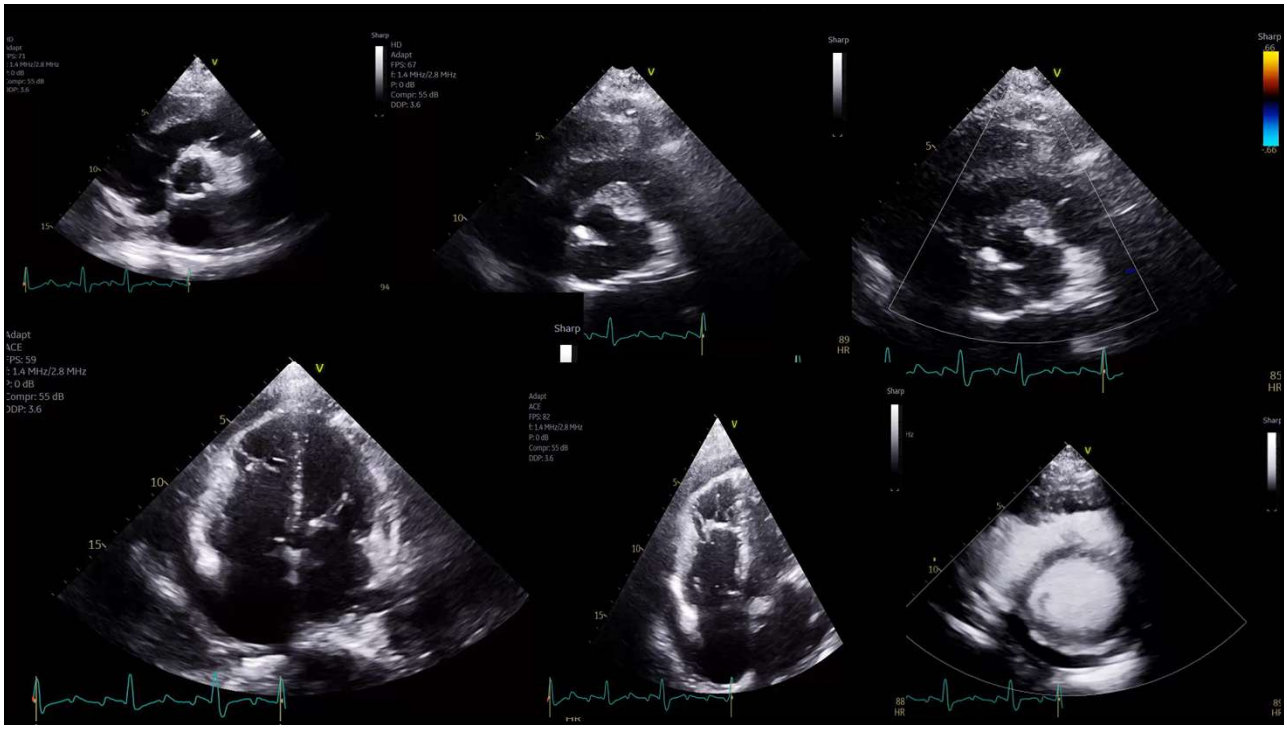

26

© Copyright. Society of Diagnostic Medical Sonography. All Rights Reserved.

2026 SDMS Annual Conference

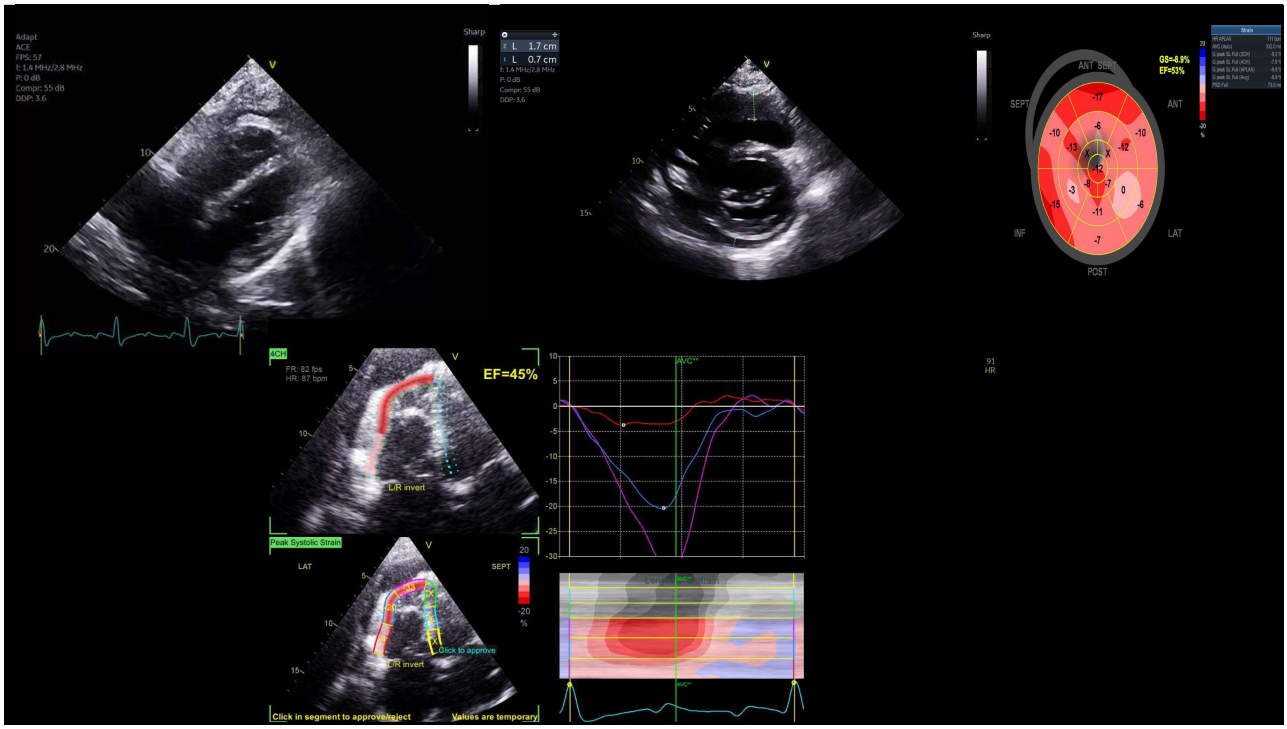

27

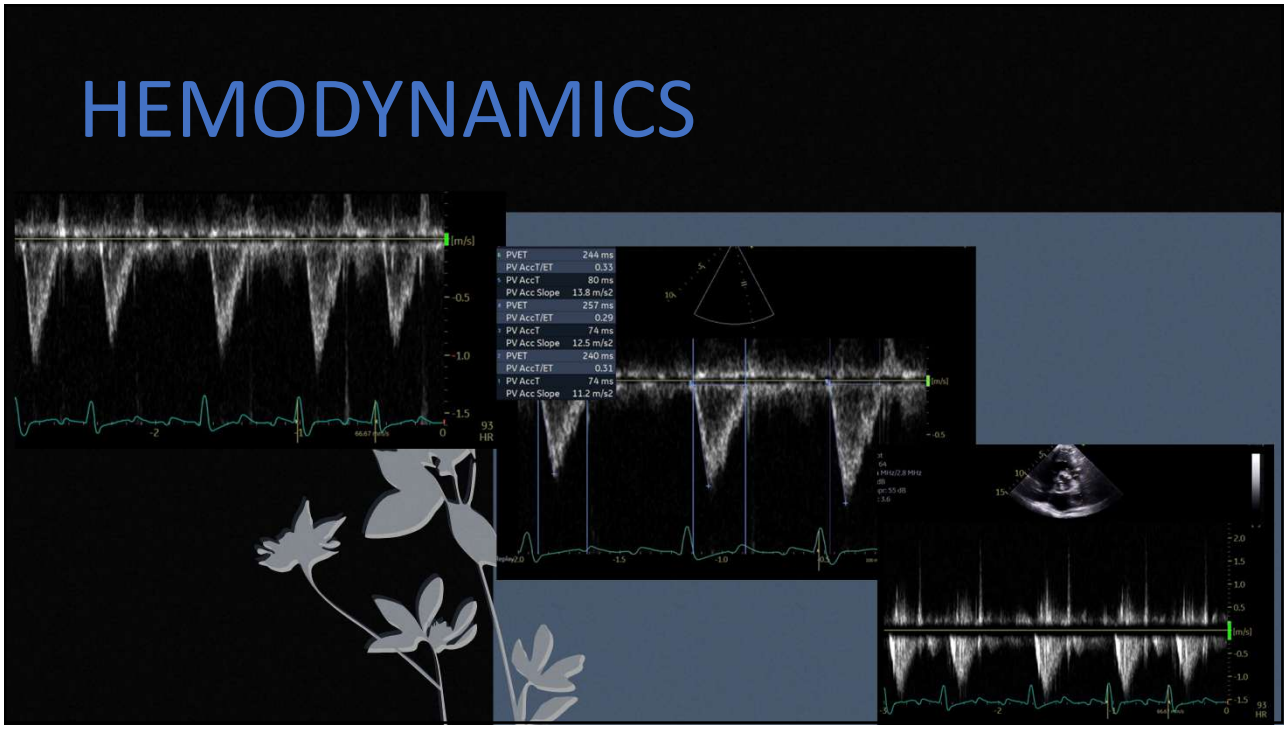

28

© Copyright. Society of Diagnostic Medical Sonography. All Rights Reserved.

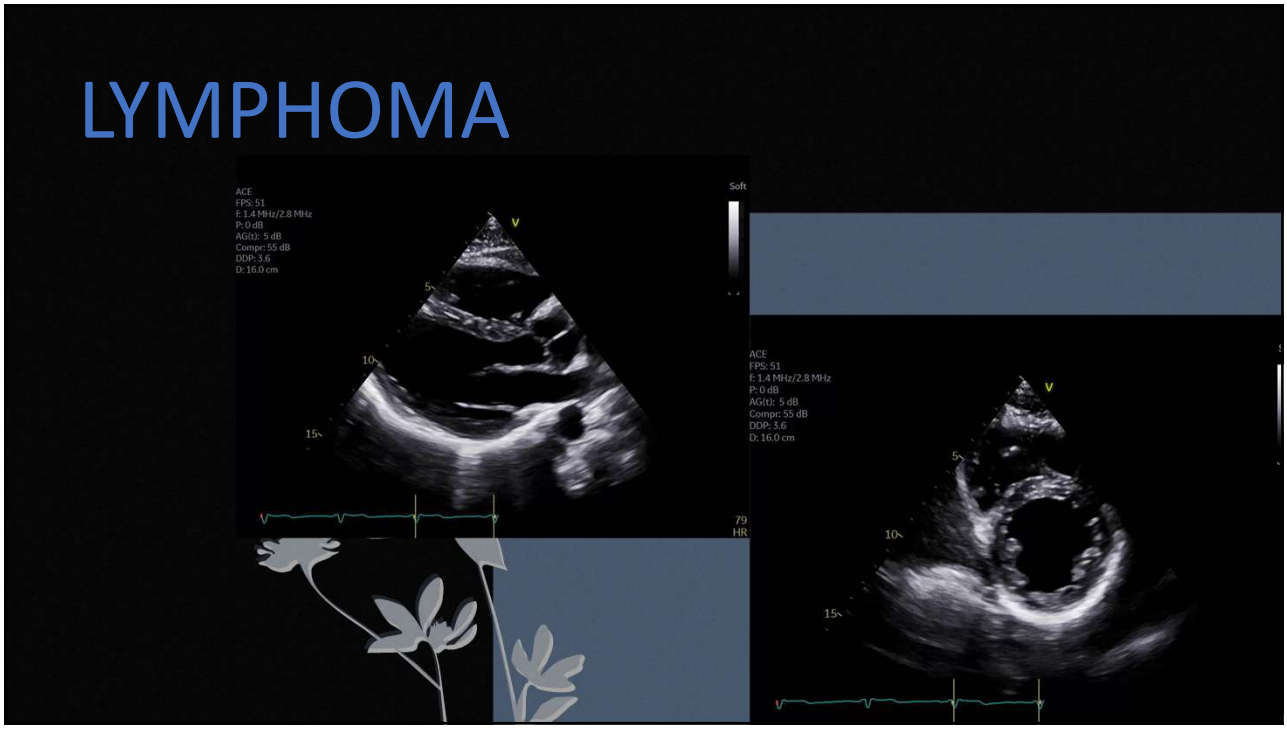

29

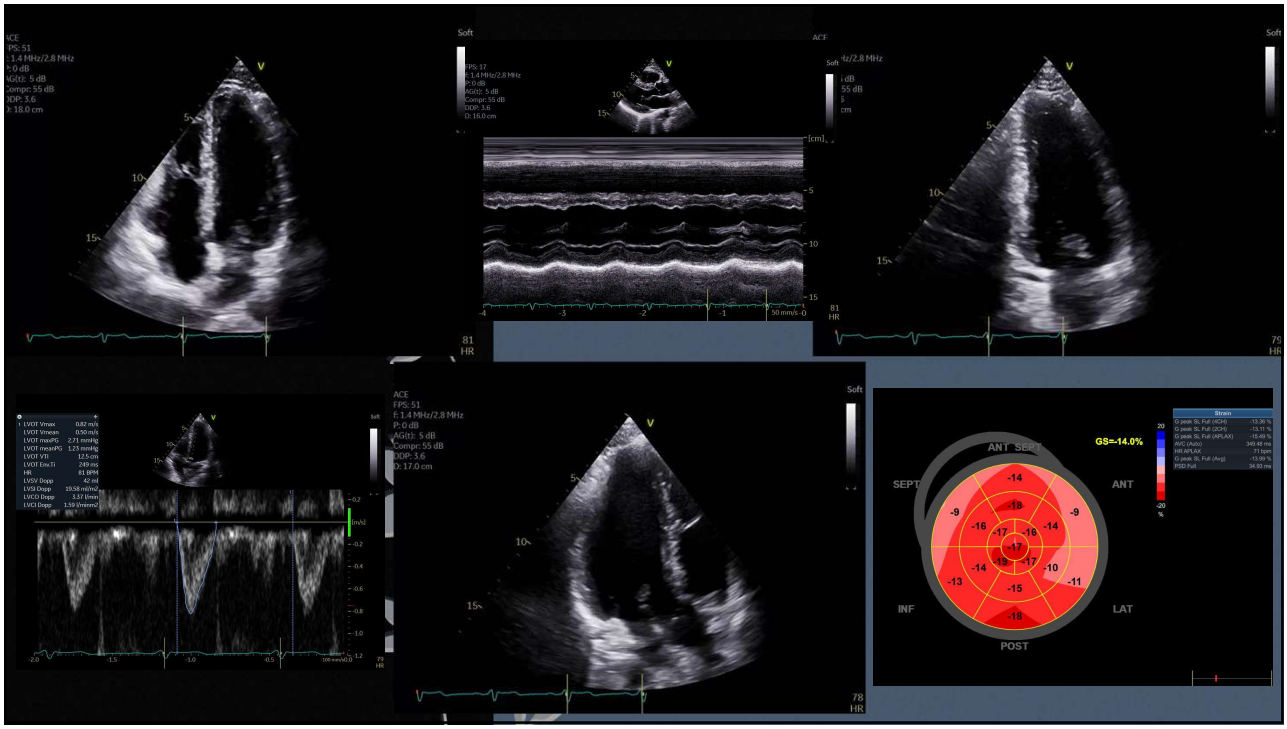

30

© Copyright. Society of Diagnostic Medical Sonography. All Rights Reserved.

2026 SDMS Annual Conference

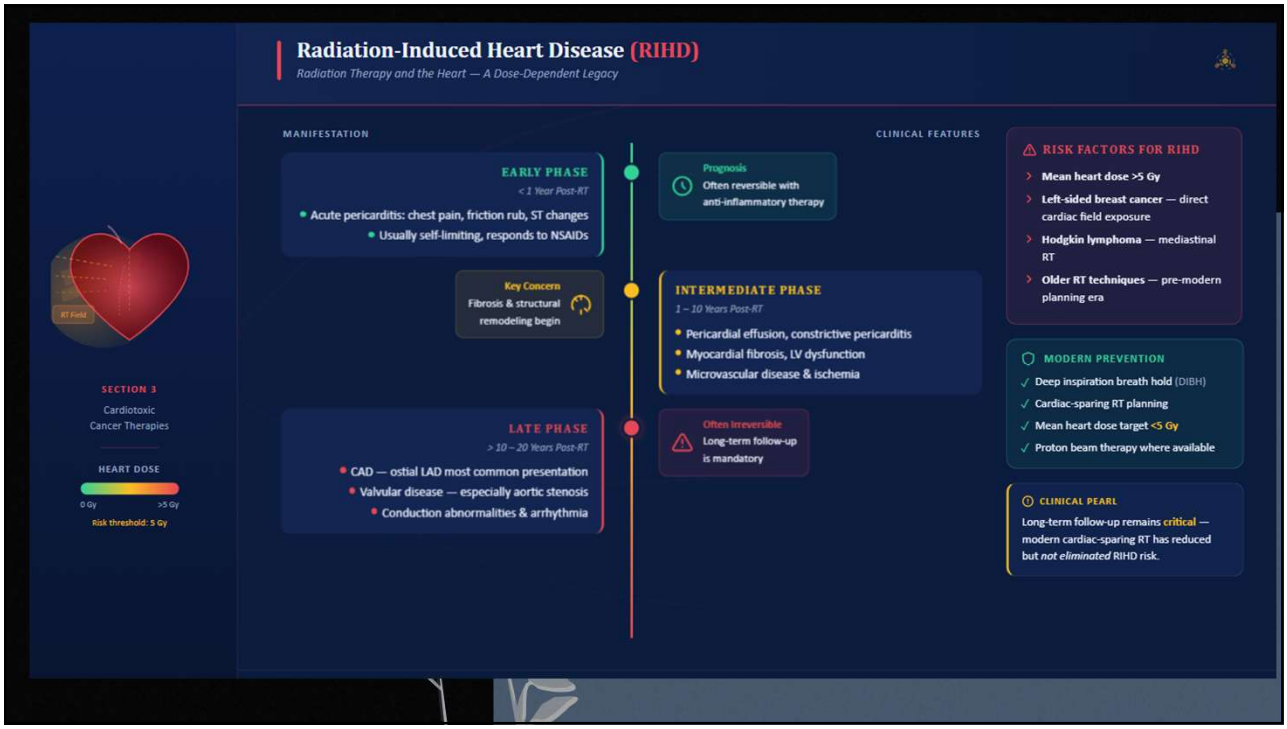

31

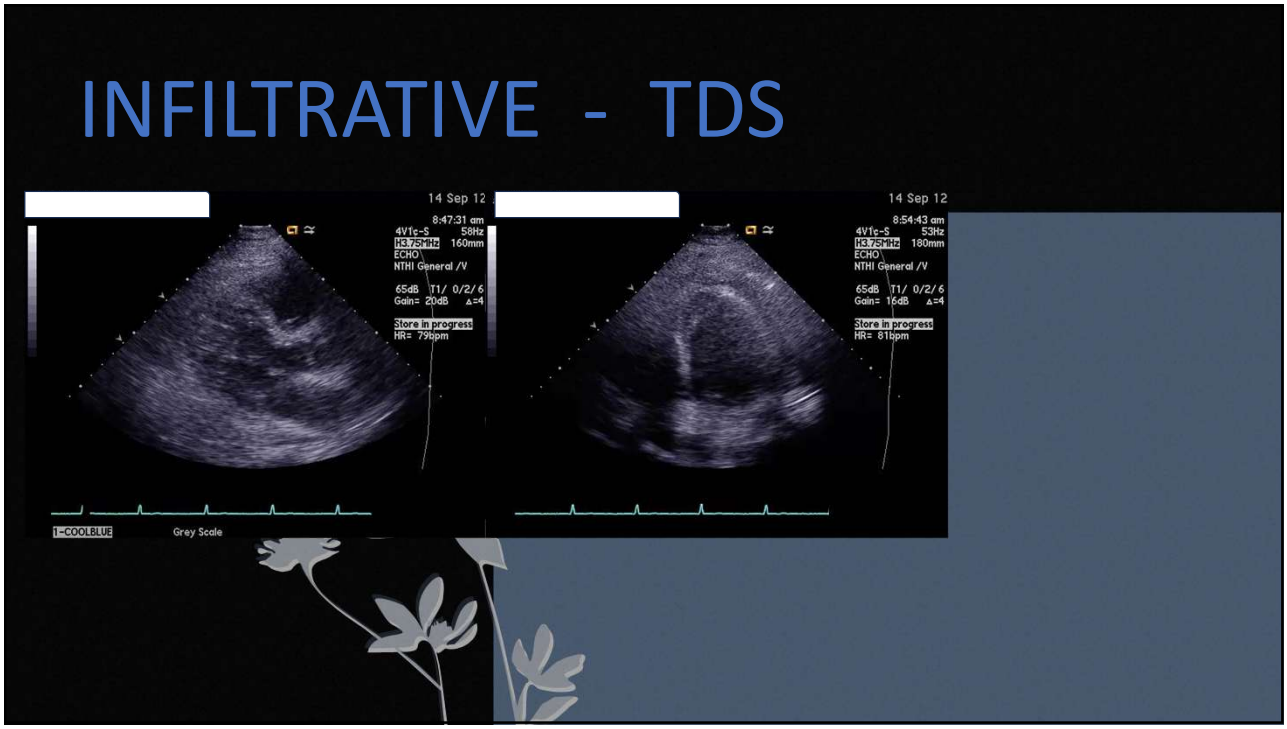

32

© Copyright. Society of Diagnostic Medical Sonography. All Rights Reserved.

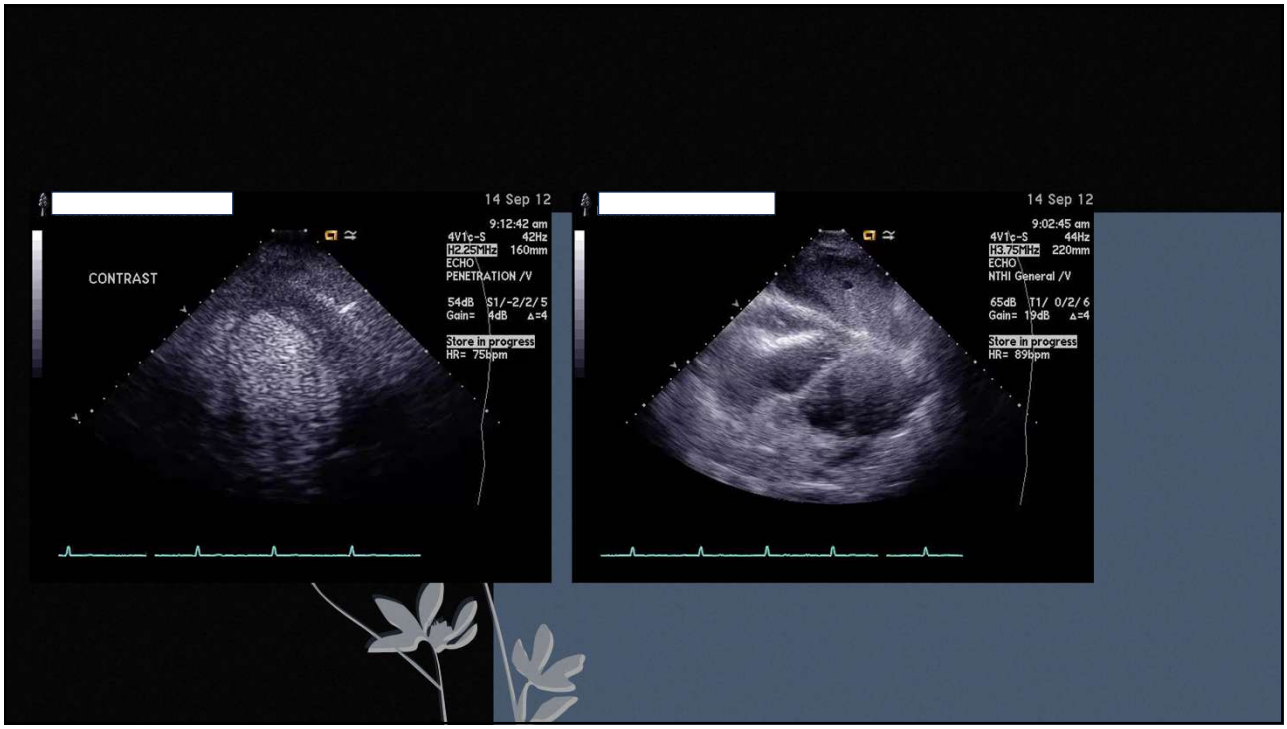

33

SARCOMA

According to the American Cancer Society, sarcoma, often called 'the forgotten cancer,' makes up approximately 1 percent of all adult cancer diagnoses.

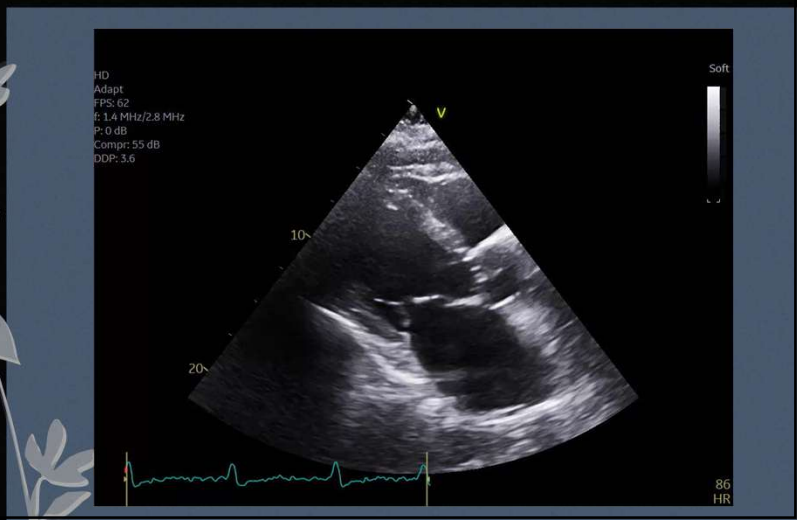

34

© Copyright. Society of Diagnostic Medical Sonography. All Rights Reserved.

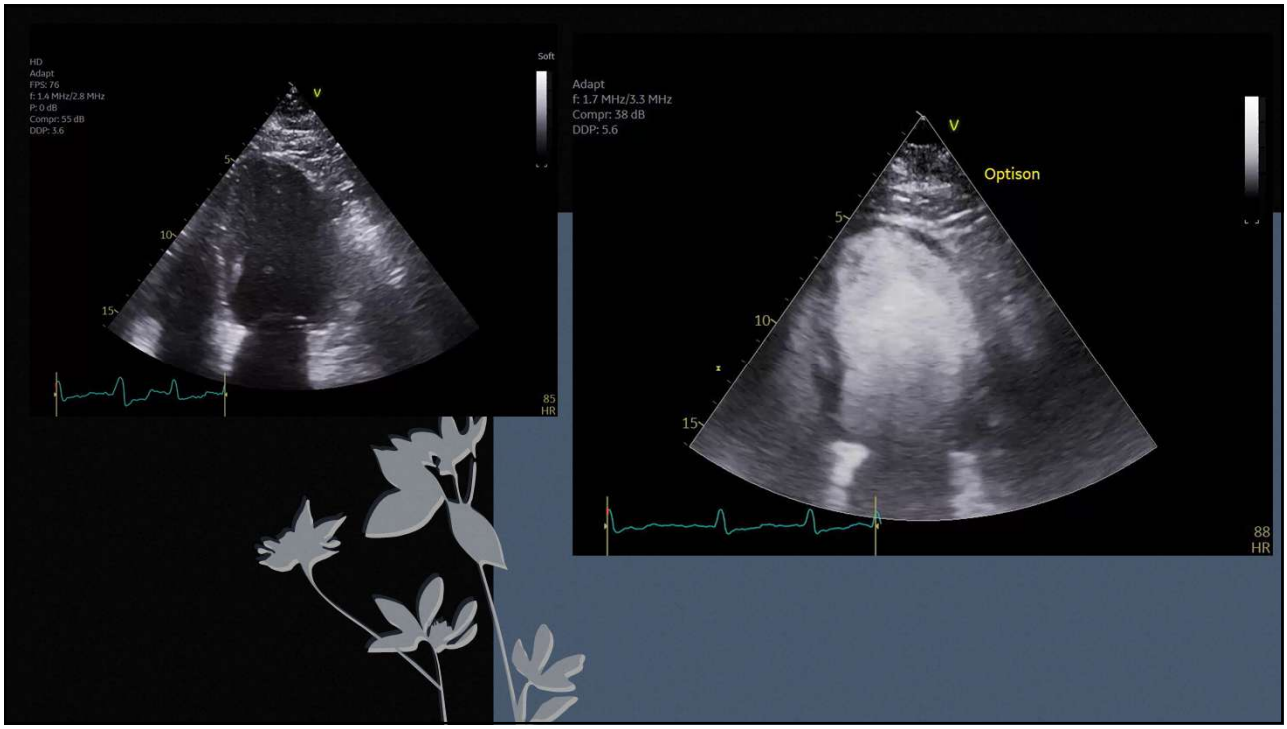

35

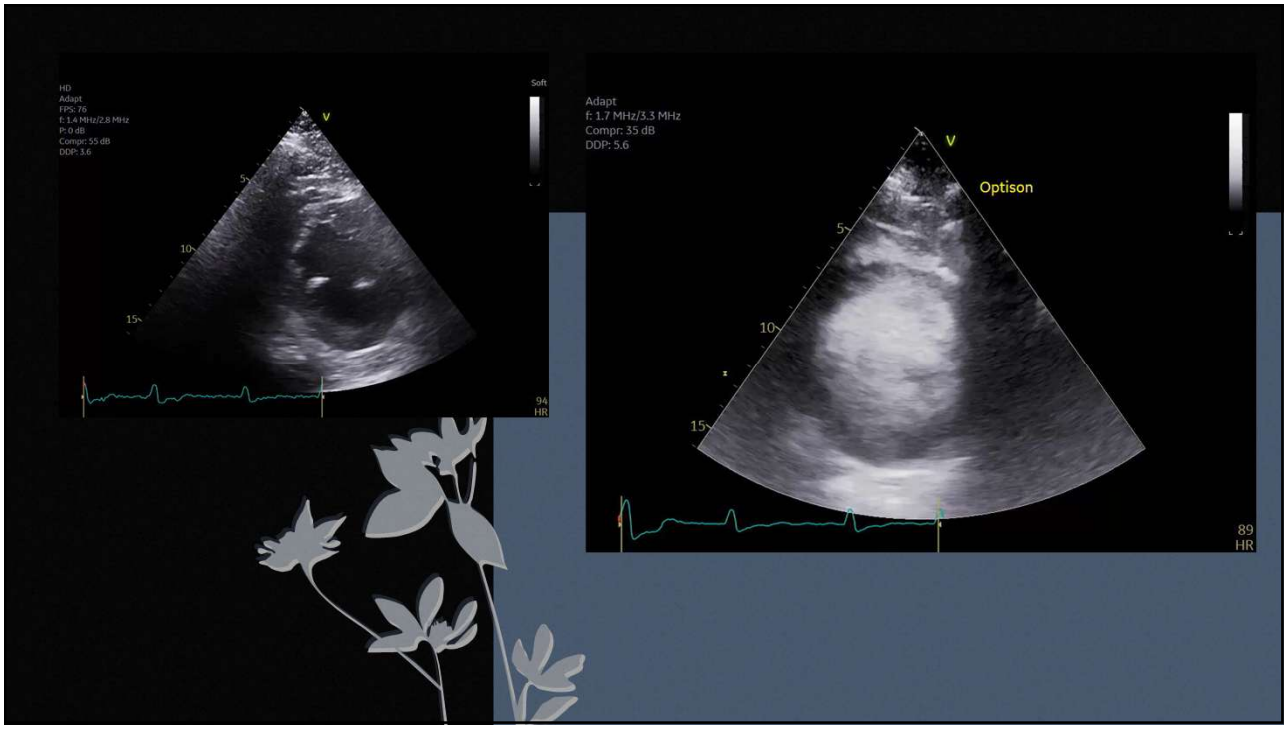

36

© Copyright. Society of Diagnostic Medical Sonography. All Rights Reserved.

2026 SDMS Annual Conference

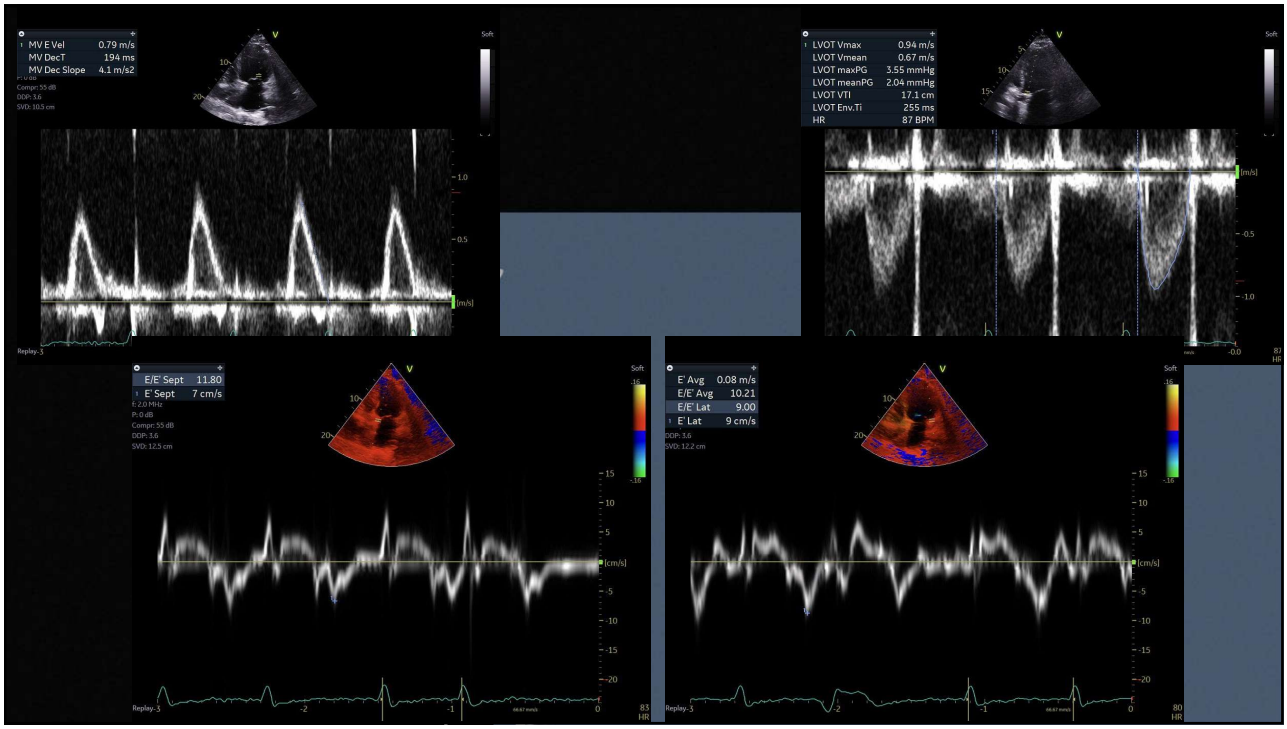

37

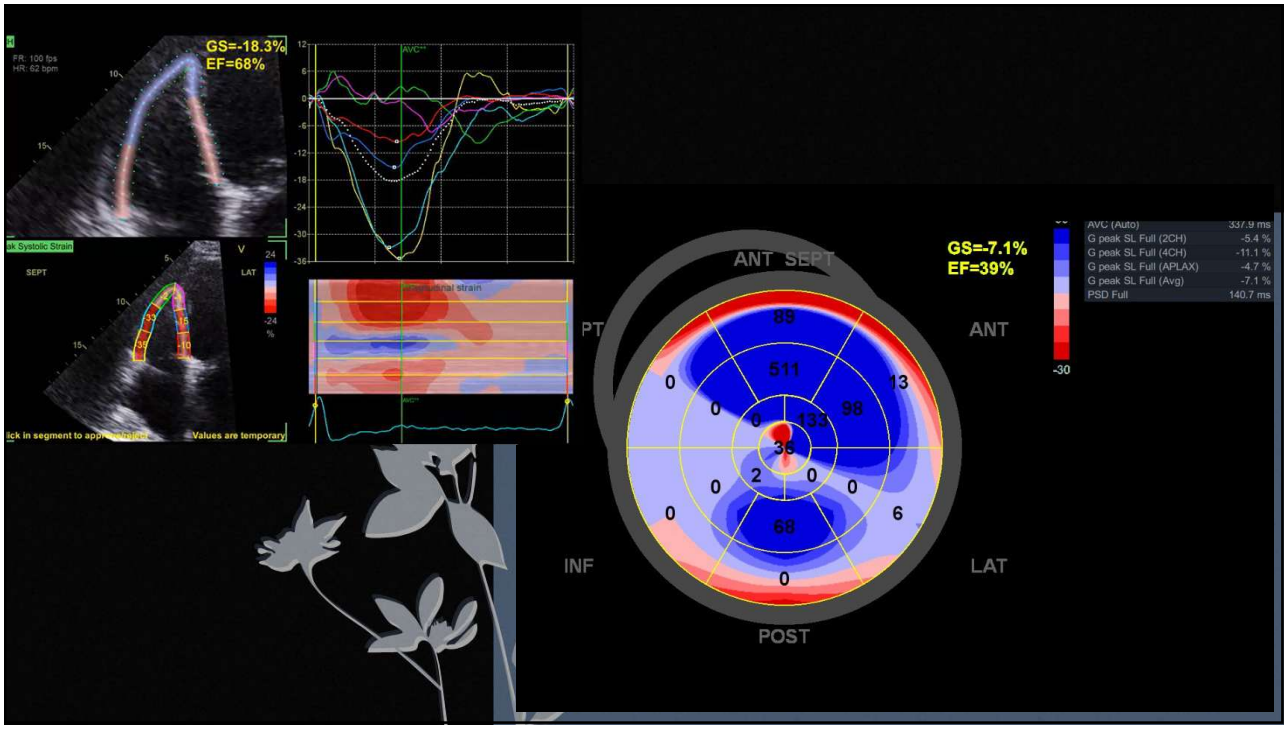

38

© Copyright. Society of Diagnostic Medical Sonography. All Rights Reserved.

WHY GLS MATTERS IN CARDIO-ONCOLOGY

:these early decreases in LVGLS predict later decreases in LVEF.116,117

The early identification of patients at high risk for developing car
diac dysfunction and failure is important as symptoms are late an
at that stage the prognosis is poor.[109] The identification of these pa

LVGLS has shown prognostic value in the prediction of overall mortality in a general population of patients undergoing echocardiography.[113] The value of baseline LVGLS in predicting clinical outcomes has also been recognized in a study of patients treated with anthracyclines.[114] One of the most valuable applications of LVGLS may be in patients with borderline LVEF. In a study of 158 patients with a base-

GUIDELINES AND STANDARDS

Clinical Applications of Strain Echocardiography: A Clinical Consensus Statement From the American Society of Echocardiography Developed in Collaboration With the European Association of Cardiovascular Imaging of the European Society of Cardiology

39

PREVENTION OF CARDIOTOXICITY IN EARLY RECOGNITION



1. Mass detection
2. Chamber distortion
3. Obstruction
4. Pericardial involvement
5. *Verbal cue:* "Watch the borders."

Baseline and Periodic Monitoring
Initial baseline assessment and regular echocardiographic monitoring help detect cardiotoxicity early in patients.

Cardioprotective Medications
Use of ACE inhibitors and beta blockers provides protective effects against cardiotoxicity in vulnerable patients.

Risk-Adapted Surveillance
Combining biomarker analysis with imaging techniques optimizes early detection and prevention strategies.

40

© Copyright. Society of Diagnostic Medical Sonography. All Rights Reserved.

MECHANISMS OF CARDIOTOXICITY

1. Anthracycline oxidative injury
2. HER2 blockade functional decline
3. Immune checkpoint myocarditis

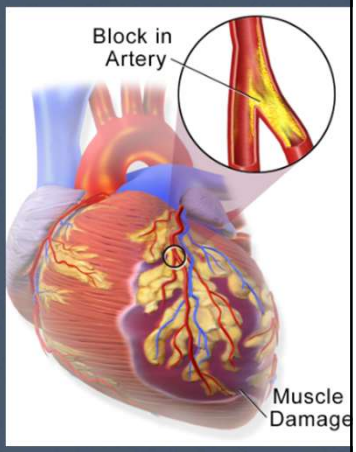

41

CARDIO-ONCOLOGY · THE LANDSCAPE

CV Disease: The #1 Non-Cancer Cause of Death in Survivors

38%

of cancer survivors die from **cardiovascular causes** rather than cancer recurrence

SEER DATA



- CV Disease — 38%
- Cancer Recurrence — 44%
- Other Causes — 18%

CAUSE-OF-DEATH PROPORTIONS — CANCER SURVIVORS



This statistic defines the field. Surviving cancer now means facing a lifelong cardiovascular consequence of the treatment that saved your life.

BY CANCER TYPE

- **Breast cancer survivors:** CVD mortality rivals cancer mortality at 10 years post-diagnosis
- **Prostate cancer survivors:** CVD is the leading cause of death — surpassing cancer itself
- **Lymphoma survivors:** 3–5× higher risk of cardiac death compared to the general population

CLINICAL IMPLICATION

As cancer survival improves, **CV outcomes become the defining challenge** of post-treatment survivorship care.

42

© Copyright. Society of Diagnostic Medical Sonography. All Rights Reserved.

GLS Basics (Fast Refresher)

- Normal GLS ≈ −18% to −22%
- Less negative = worse
- Vendor variability considerations
- *Side-by-side:* normal strain map vs abnormal strain map

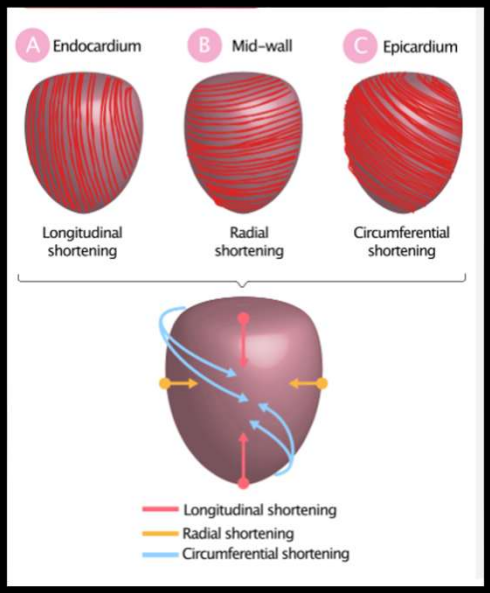

43

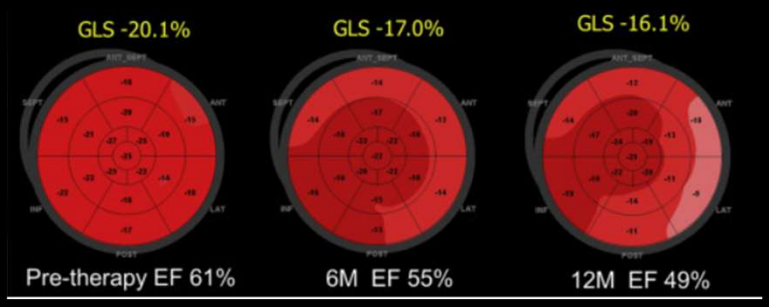

Serial GLS: What Counts as Significant Change?

≥15% relative reduction = clinically meaningful

Trend > single value

Example: −20% → −17% (15% dro

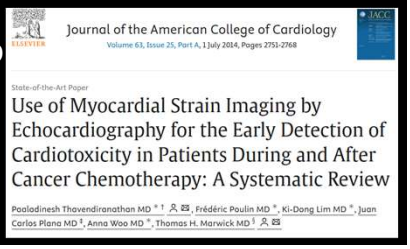
Journal of the American College of Cardiology
Volume 63, Issue 25, Part A, 1 July 2014, Pages 2751-2768

State-of-the-Art Paper

Use of Myocardial Strain Imaging by Echocardiography for the Early Detection of Cardiotoxicity in Patients During and After Cancer Chemotherapy: A Systematic Review

Paaladinesh Thavendiranathan MD *†, Frédéric Poulin MD *, Ki-Dong Lim MD *, Juan Carlos Plana MD ‡, Anna Woo MD *, Thomas H. Marwick MD †

44

© Copyright. Society of Diagnostic Medical Sonography. All Rights Reserved.

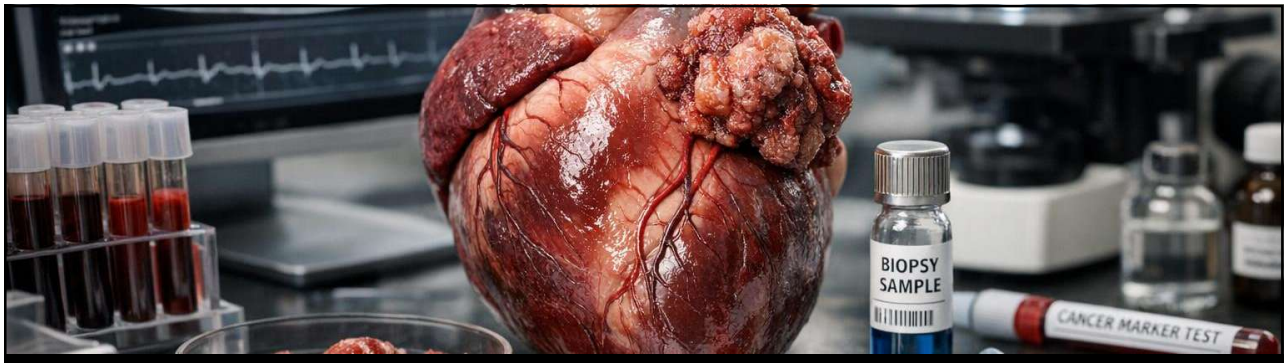

Clinical Challenges in Distinguishing Cardiac Involvement

Complex Symptom Overlap

Cardiac symptoms can arise from tumors, treatments, or existing cardiac issues, making differentiation complex.

Importance of Precise Imaging

Accurate diagnosis relies heavily on advanced imaging techniques and clinical correlation to identify cardiac involvement.

Challenges in Immunocompromised Patients

Immunocompromised oncology patients have increased diagnostic difficulty due to overlapping symptoms and risks.

45

Echocardiographic Findings Guiding

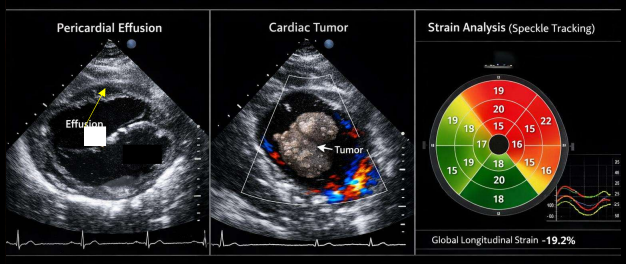

Pericardial Effusion Detection

Echocardiography identifies fluid accumulation in the pericardial sac indicating potential cardiac invasion or metastasis.

Intracardiac Mass Identification

Detection of masses inside cardiac chambers suggests metastatic deposits or tumor invasion.

Myocardial Dysfunction Indicators

Reduced ejection fraction and wall motion abnormalities reveal myocardial dysfunction, often from chemotherapy effects.

Global Longitudinal Strain Analysis

Quantitative strain measurement enhances detection of subtle, subclinical myocardial damage earlier than traditional metrics.

46

© Copyright. Society of Diagnostic Medical Sonography. All Rights Reserved.

The Decision Triad

1. **GLS trend**
2. **EF stability**
3. **Symptoms + biomarkers**





47

Cardiac Symptoms in Oncology Patients

Common Cardiac Symptoms

Oncology patients often experience chest pain, dyspnea, palpitations, or edema related to cardiac issues.

Causes of Symptoms

Symptoms may result from cardiac infiltration, pericardial effusion, or therapy-induced cardiotoxicity.

Diagnostic Challenges

Overlapping symptoms with non-cardiac conditions complicate diagnosis in oncology patients.

Need for Comprehensive Evaluation

Thorough cardiac assessment is vital for accurate diagnosis and management in symptomatic oncology patients.

48

© Copyright. Society of Diagnostic Medical Sonography. All Rights Reserved.

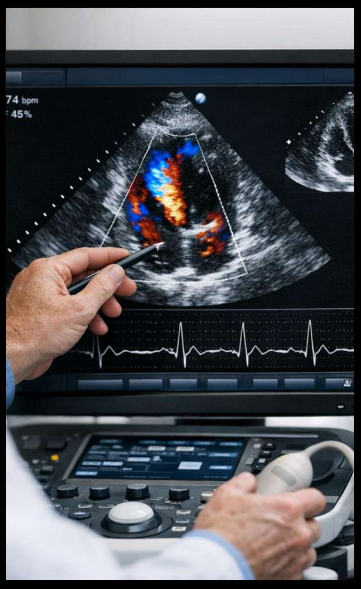

Impact of Echo on Patient Management Decisions

Treatment Modification

Echocardiography helps modify chemotherapeutic agents to reduce cardiac risks in patients undergoing cancer treatment.

Cardioprotective Therapies

Initiation of cardioprotective therapies guided by echo findings helps prevent cardiac complications effectively.

Surgical Interventions

Echo results inform timely surgical interventions to improve patient outcomes and survival rates.

Improved Survival and Quality of Life

Echo-guided management enhances patient survival and quality of life by mitigating cardiac complications.

49



Monitoring Disease Progression and Cardiac Complications

Tracking Tumor Progression

Serial echocardiographic exams help monitor tumor growth and response to treatment over time, enabling precision care.

Detecting Cardiotoxicity Early

Echocardiography detects early signs of cardiotoxicity from treatments, facilitating timely clinical intervention.

Guiding Clinical Management

Regular echocardiographic assessments guide adjustments in therapy, improving patient outcomes effectively.

50

© Copyright. Society of Diagnostic Medical Sonography. All Rights Reserved.

Reminder for Sonographers

What Sonographers Should Document

- Precise GLS values
- Vendor consistency
- Regional strain abnormalities
- EF + LV volumes
- Pericardial findings



51

In Summary



Non-invasive Cardiac Evaluation
Echocardiography offers a non-invasive way to assess heart function and structure in real time for cancer patients.

Critical Baseline Assessment
Baseline echocardiographic assessment is vital to detect pre-existing cardiac conditions before cancer treatment.

Advanced Imaging Techniques
Techniques such as 2D, Doppler, strain imaging, and contrast echo enable detailed cardiac monitoring.

Early Cardiotoxicity Detection
Echocardiography identifies early cardiac changes before symptoms of heart failure appear.

Key Echocardiographic Measurements
Left ventricular ejection fraction, strain measurements, and diastolic function are critical markers of cardiac health.

Importance of Early Intervention
Timely assessment allows interventions to preserve cardiac function during cancer therapy.

52

© Copyright. Society of Diagnostic Medical Sonography. All Rights Reserved.

Thank You!!

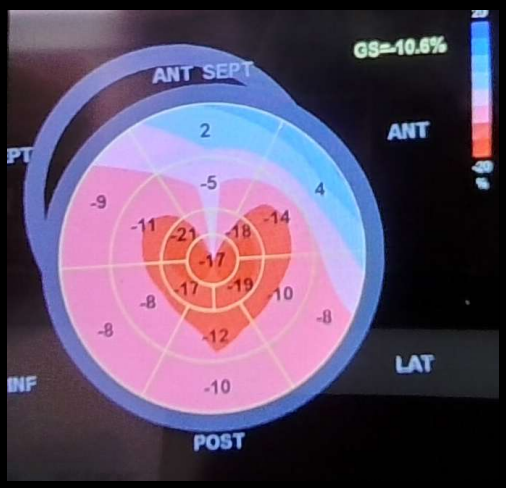

© Copyright. Society of Diagnostic Medical Sonography. All Rights Reserved.