MSK Sonography for the General Sonographer

Ted Whitten BA, RDMS, RVT, FSDMS
Ultrasound Practitioner
The Elliot Hospital
Manchester, NH

1

SPEAKER PRESENTATION DISCLAIMER

The content and views presented are made available for educational purposes only. The information presented are the opinions of the presenter and do not necessarily represent the views of the Society of Diagnostic Medical Sonography (SDMS) or its affiliated organizations, officers, Boards of Directors, or staff members.

The presenter is responsible for ensuring balance, independence, objectivity, scientific rigor, and avoiding commercial bias in their presentation. Before making the presentation, the presenter is required to disclose to the audience any relevant financial interests or relationships with manufacturers or providers of medical products, services, technologies, and programs.

The SDMS and its affiliated organizations, officers, Board of Directors, and staff members disclaim any and all liability for all claims that may arise out of the use of this educational activity.

2

© Copyright. Society of Diagnostic Medical Sonography. All Rights Reserved.

GENERATIVE AI DISCLAIMER

The presenter utilized the use of large language models (LLMs) and generative artificial intelligence (AI) as a productivity tool to assist in drafting and refining content in this presentation.

While these tools can aid in structuring ideas, summarizing, paraphrasing, and language polishing, they have inherent limitations and cannot replace human creativity, critical thinking, or expert judgment. AI-generated content may contain errors, biases, or gaps in knowledge.

This presentation is intended for informational purposes only and should not be construed as definitive or authoritative guidance. Participants are encouraged to critically evaluate the information presented and consult relevant experts as needed. The SDMS and its affiliated organizations, officers, Board of Directors, and staff members disclaim any and all liability for claims that may arise from the use or interpretation of this educational material.

3

Objectives

1. Recognize normal and abnormal musculoskeletal anatomy to support accurate sonographic interpretation.
2. Identify common musculoskeletal artifacts using fundamental imaging principles to improve image assessment.
3. Describe basic musculoskeletal scanning protocols for application in general sonography practice.

4

© Copyright. Society of Diagnostic Medical Sonography. All Rights Reserved.

LABELING NOTE- my suggestions…

- Avoid using “sagittal” and “transverse” because those terms frequently refer to body planes
- I prefer to use long axis and short axis as these terms refer more to structure orientation

* My suggestions only- please use terms that your facility uses

5

TYPES OF TISSUES SEEN IN MSK

6

© Copyright. Society of Diagnostic Medical Sonography. All Rights Reserved.

TENDONS

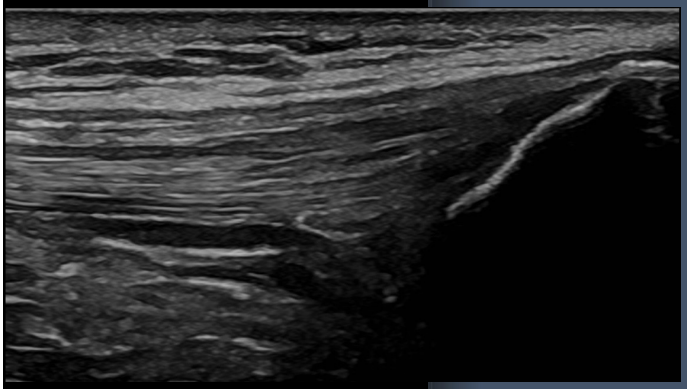

- Linear bands with a fibrillar pattern
- Speckled appearance
- Intact tendons are prone to ***anisotropy***

7

TENDONS

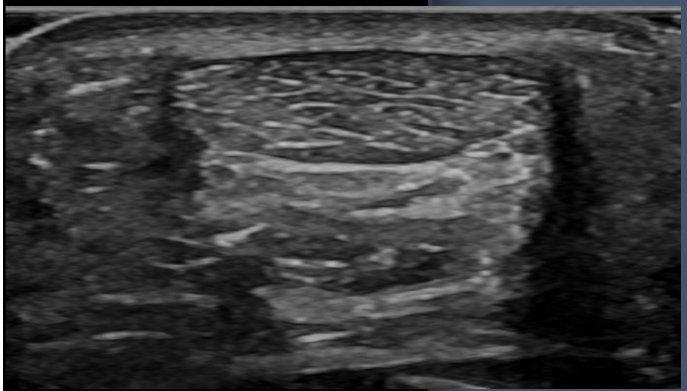

- Linear bands with a fibrillar pattern
- Speckled appearance
- Intact tendons are prone to ***anisotropy***

8

© Copyright. Society of Diagnostic Medical Sonography. All Rights Reserved.

TENDONS

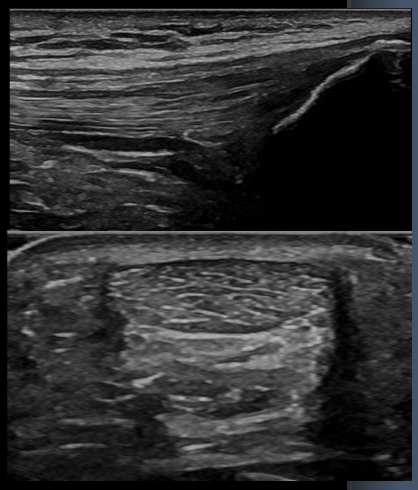

- Linear bands with a fibrillar pattern
- Speckled appearance
- Intact tendons are prone to ***anisotropy***

9

ANISOTROPY

- Appearance changes depending on the angle of incidence
- Artifact can cause misdiagnosis but can also be helpful!

10

© Copyright. Society of Diagnostic Medical Sonography. All Rights Reserved.

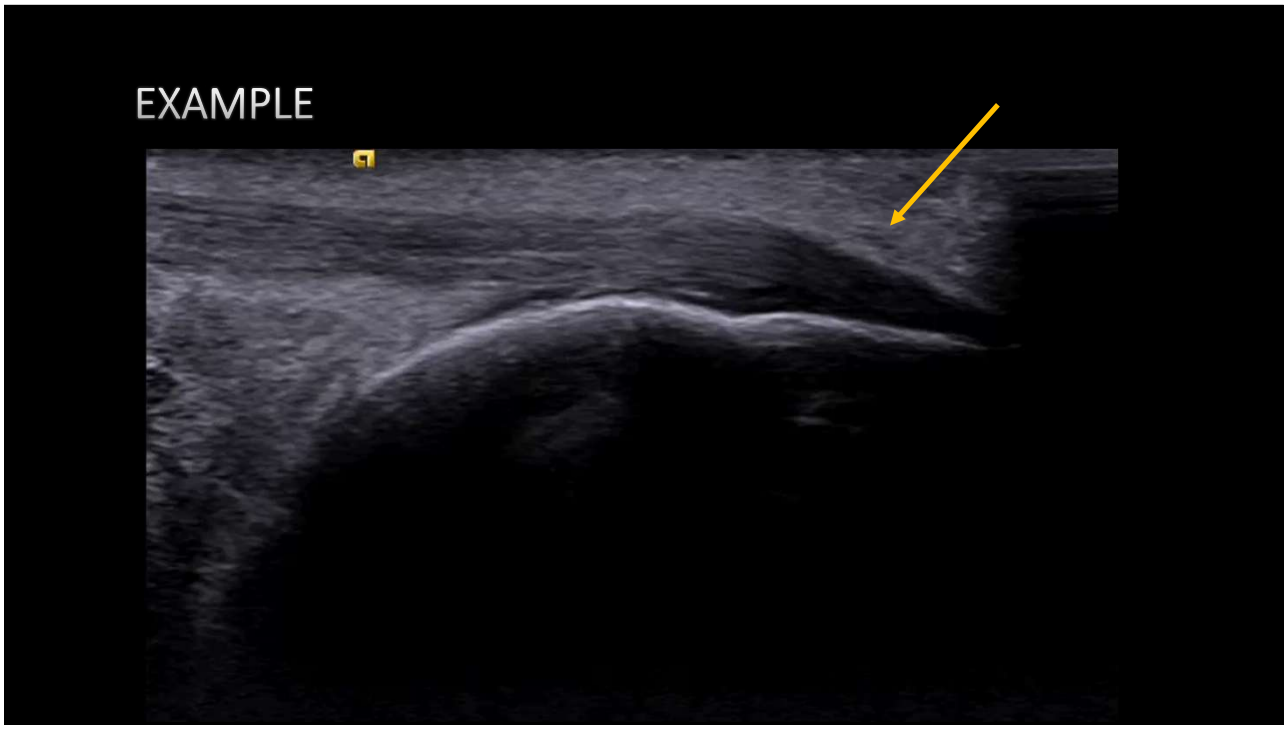

11

LIGAMENTS

- Connect bone to bone
- Echogenic linear bands- more compact fibrillar pattern
- Dense connective tissue with variable appearance

12

© Copyright. Society of Diagnostic Medical Sonography. All Rights Reserved.

MUSCLES

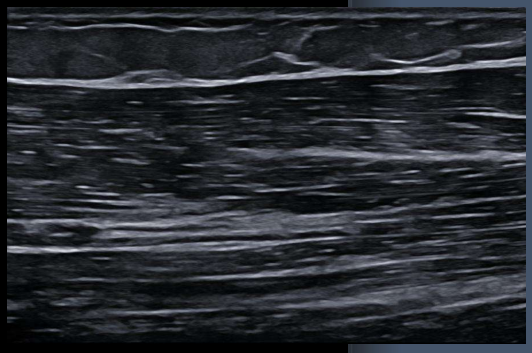

- Appear as bright linear bands separated by more hypoechoic muscle tissue
- On short axis appears more speckled
- Surrounded by fascia

13

MUSCLES

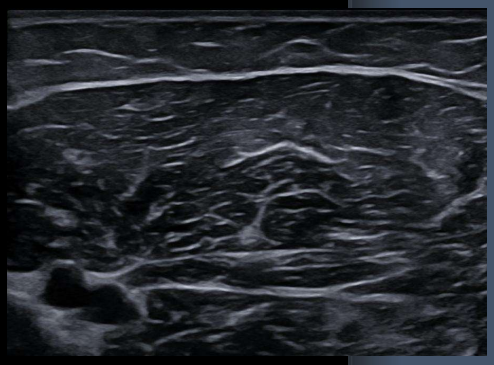

- Appear as bright linear bands separated by more hypoechoic muscle tissue
- On short axis appears more speckled
- Surrounded by fascia

14

© Copyright. Society of Diagnostic Medical Sonography. All Rights Reserved.

MUSCLES

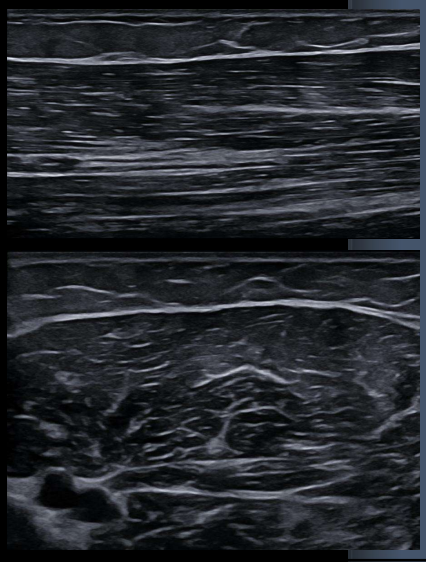

- Appear as bright linear bands separated by more hypoechoic muscle tissue
- On short axis appears more speckled
- Surrounded by fascia

15

FASCIA

- Structure and support throughout the body
- Provides lubrication, separation and facilitates movement

16

© Copyright. Society of Diagnostic Medical Sonography. All Rights Reserved.

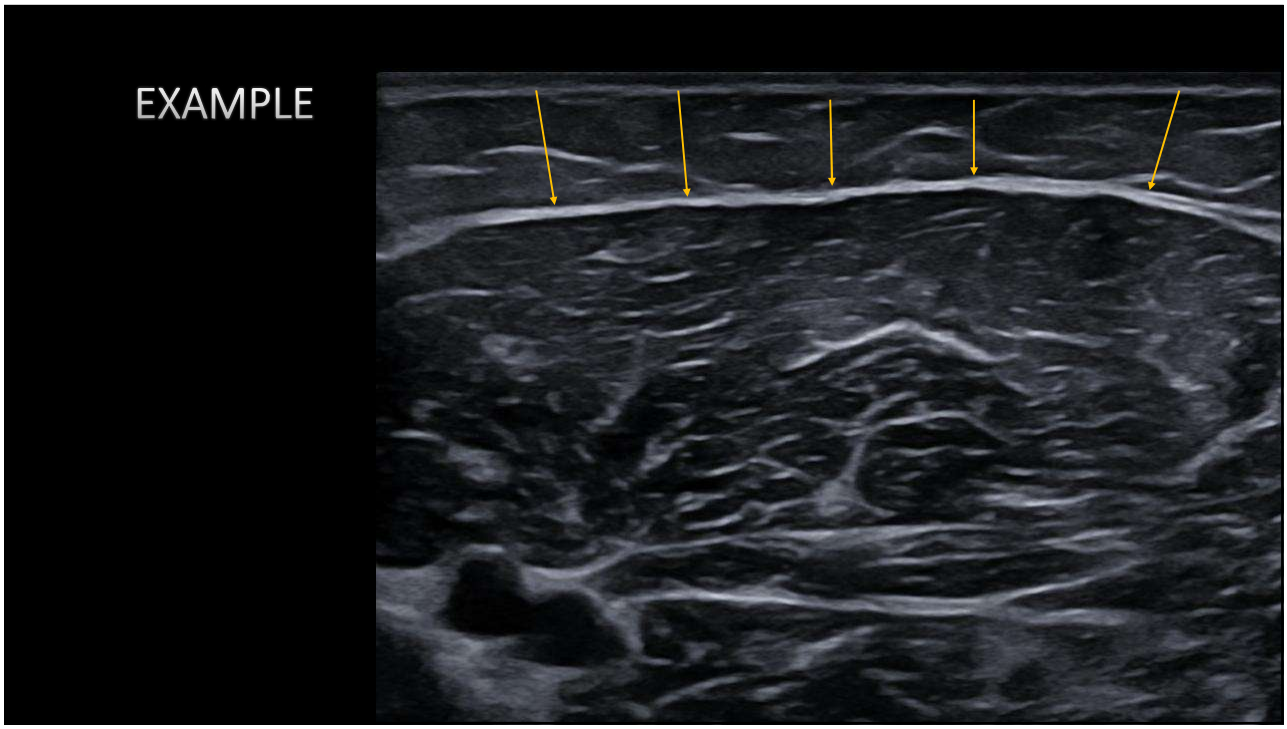

17

BURSAE

- Several types and appearance varies
- Usually thin and lined with synovium

18

© Copyright. Society of Diagnostic Medical Sonography. All Rights Reserved.

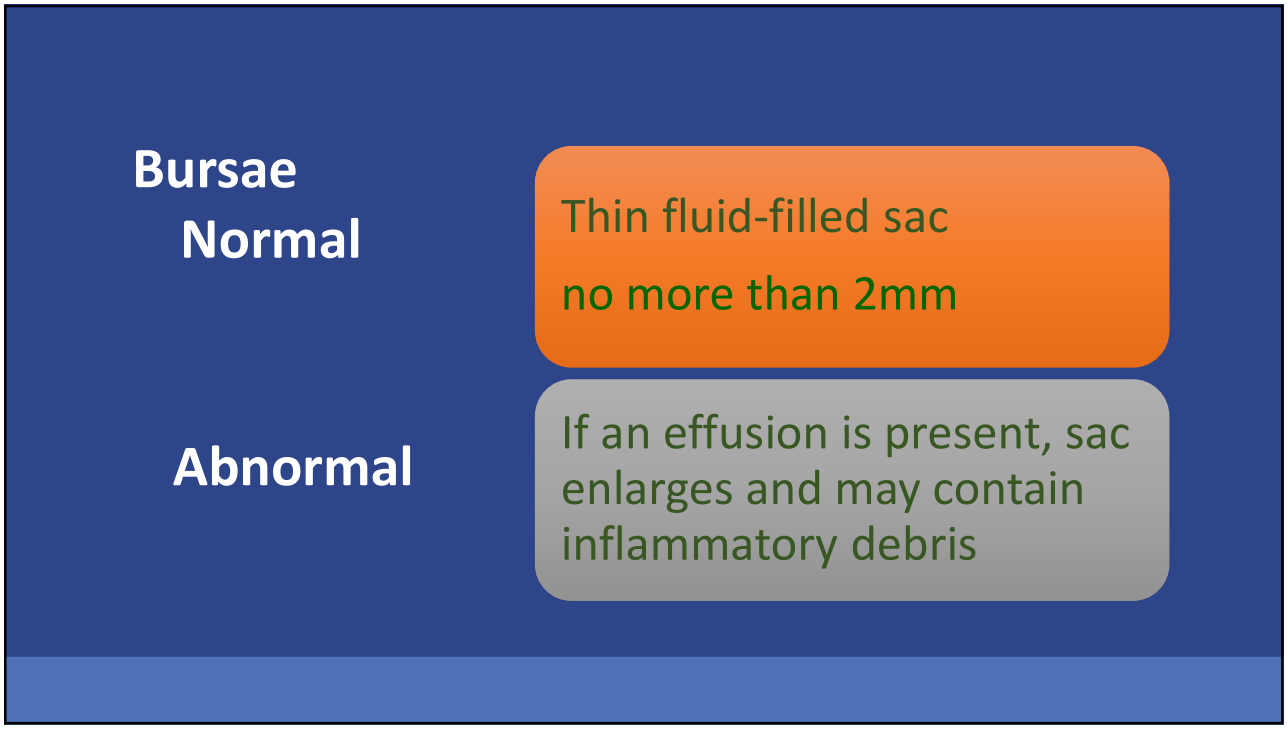

19

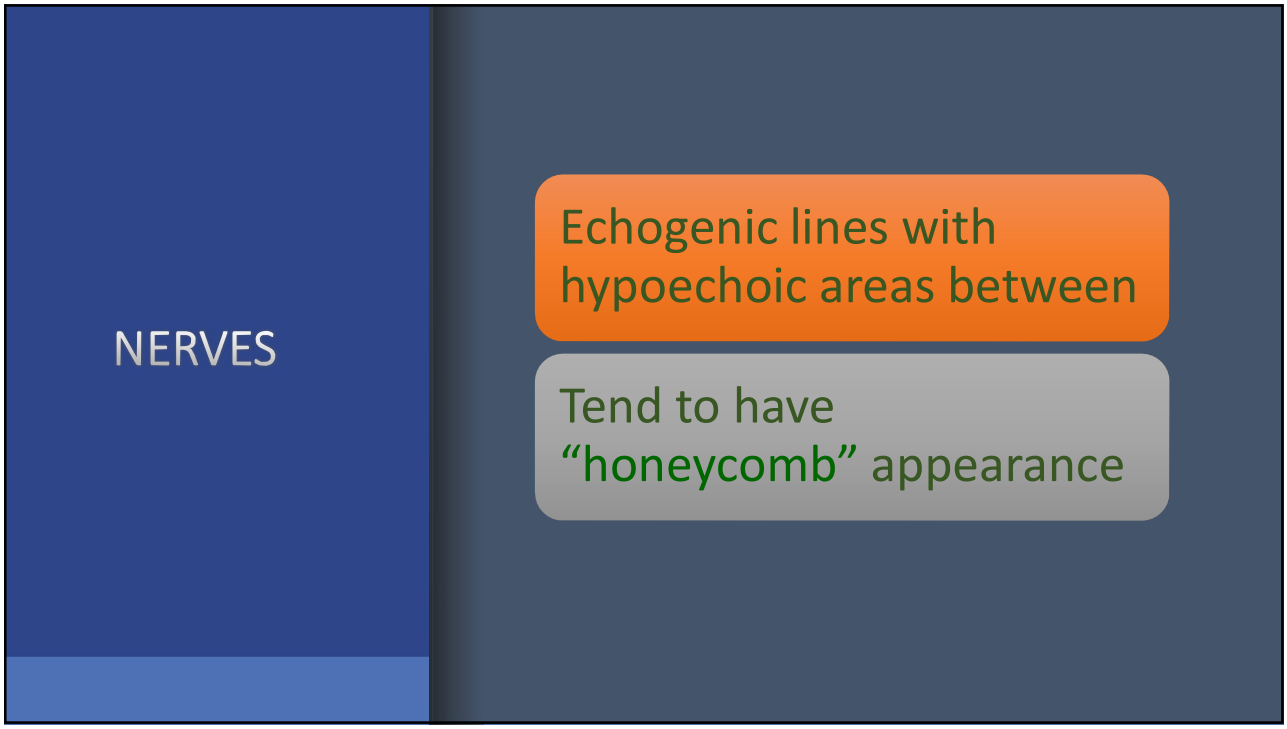

20

© Copyright. Society of Diagnostic Medical Sonography. All Rights Reserved.

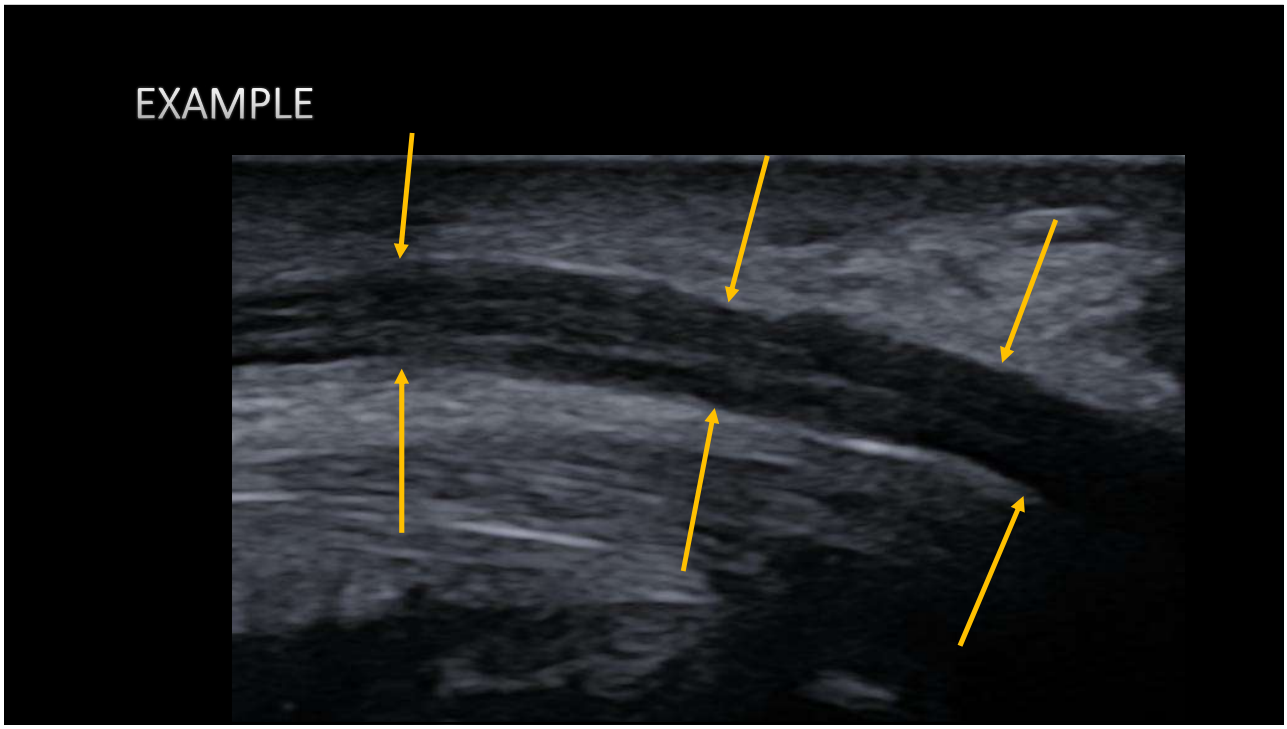

21

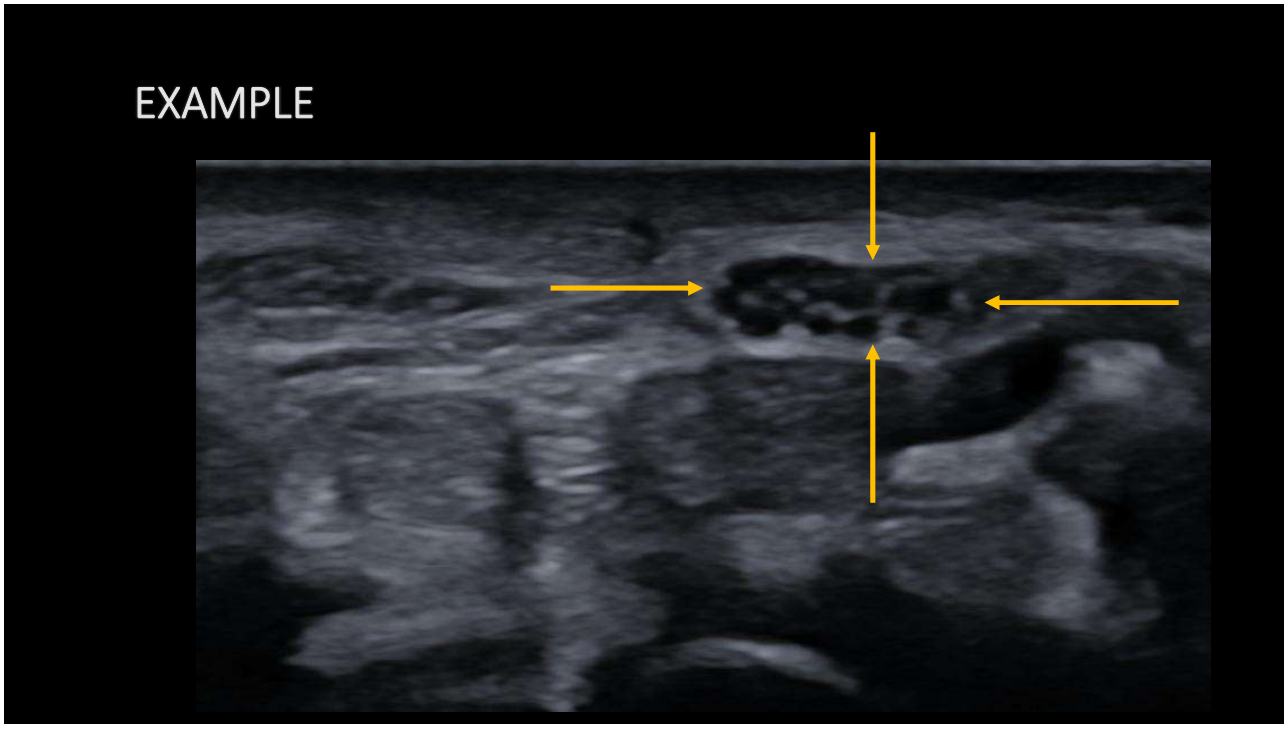

22

© Copyright. Society of Diagnostic Medical Sonography. All Rights Reserved.

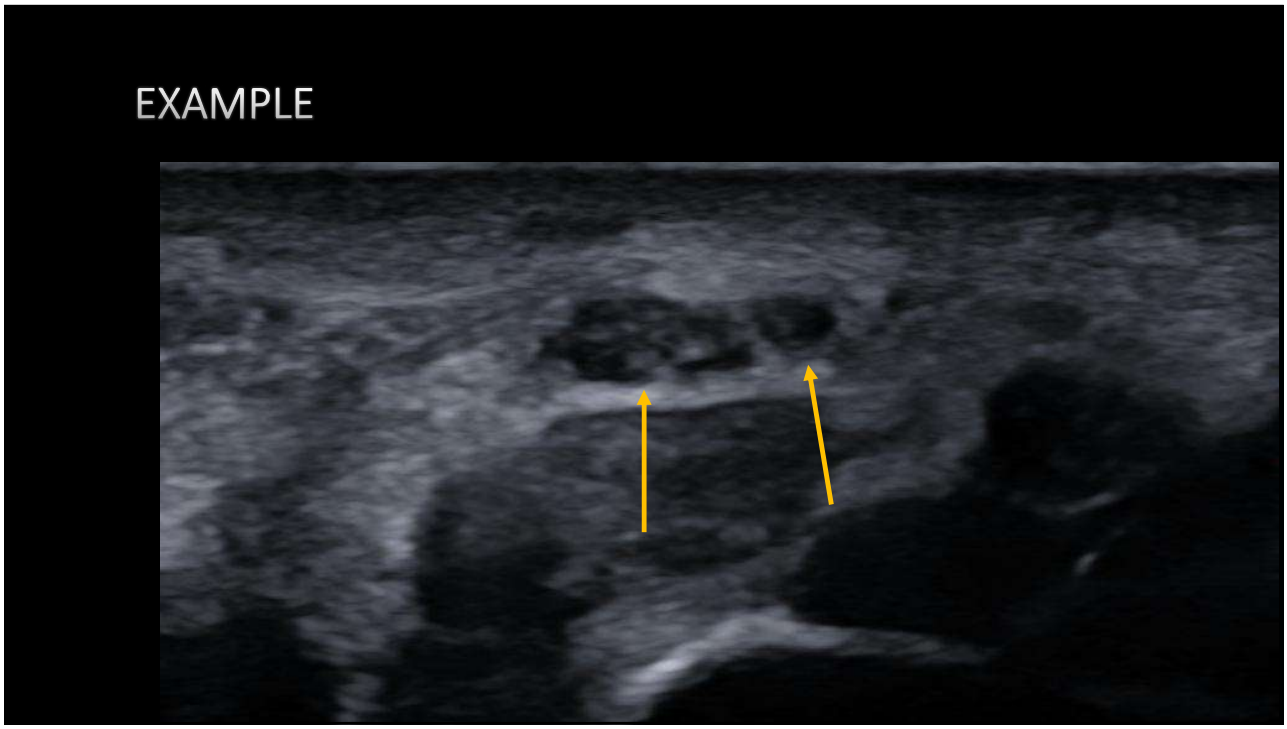

23

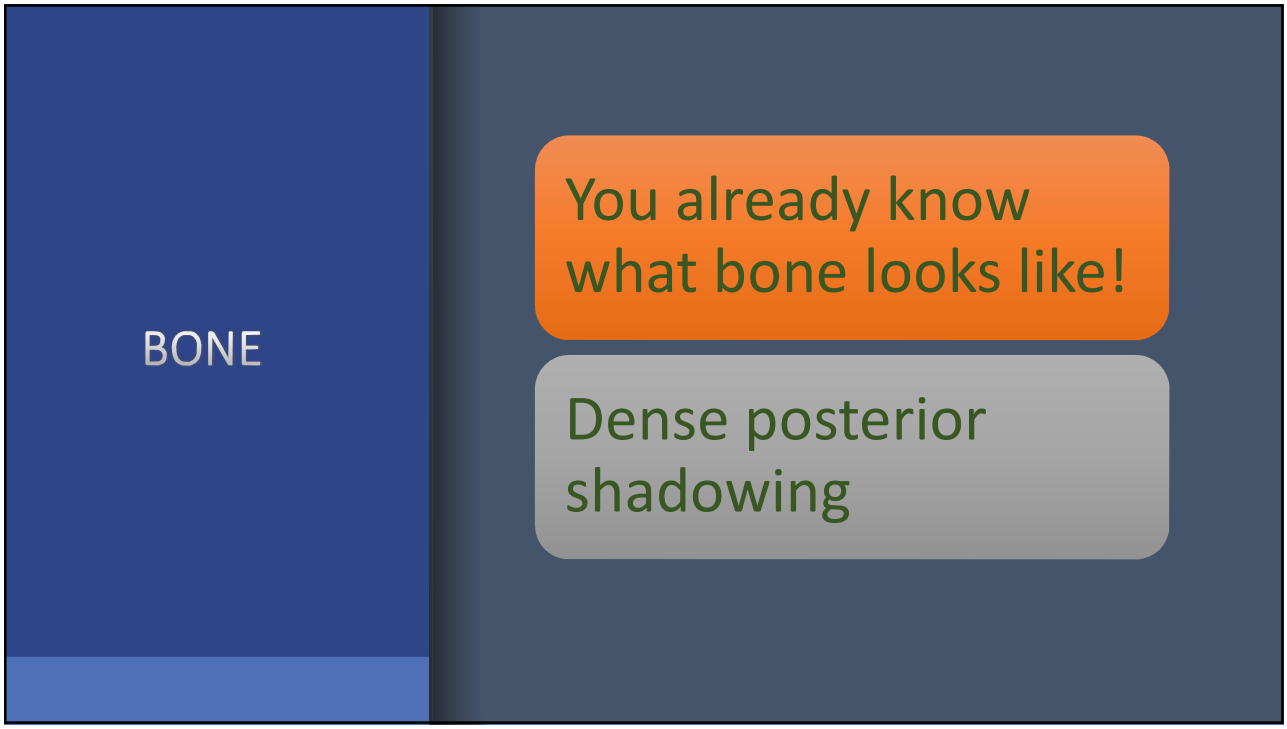

24

© Copyright. Society of Diagnostic Medical Sonography. All Rights Reserved.

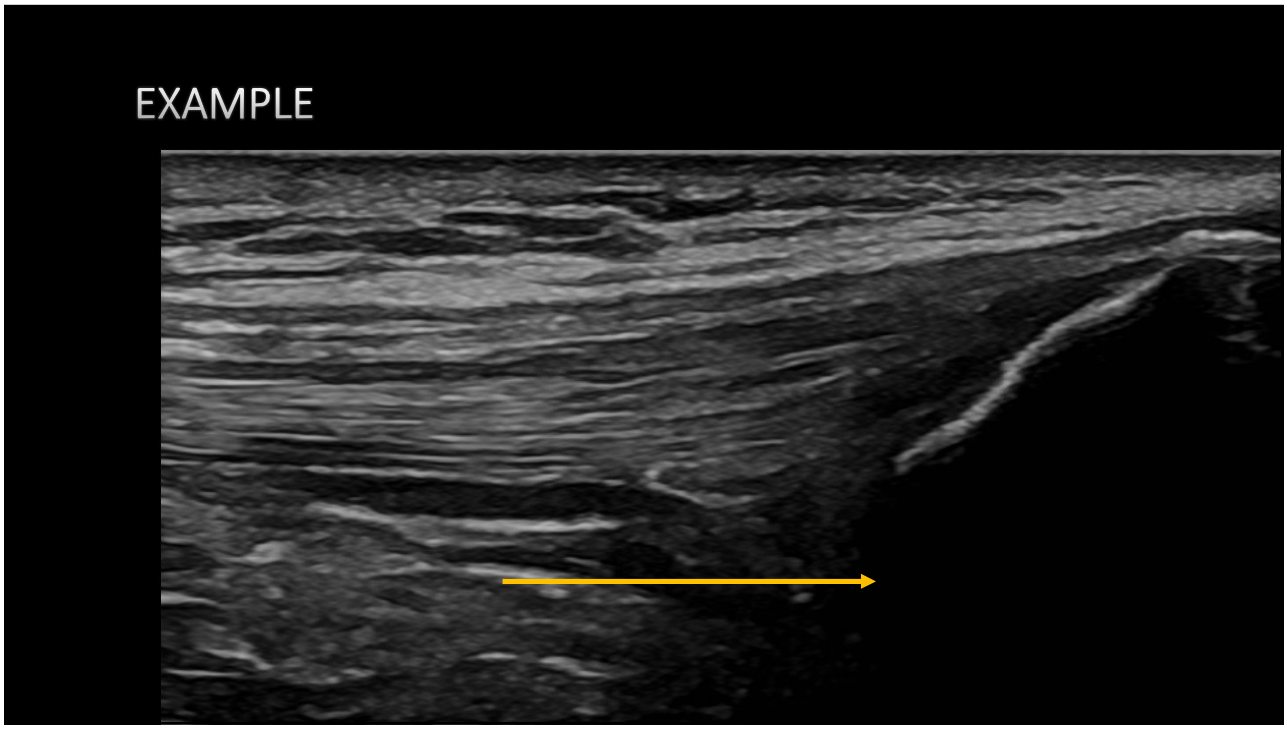

25

ACHILLES TENDON

26

© Copyright. Society of Diagnostic Medical Sonography. All Rights Reserved.

ACHILLES TENDON

- Connects the calf muscles to the Calcaneus (heel bone)
- When calf muscles flex, it pulls on the heel

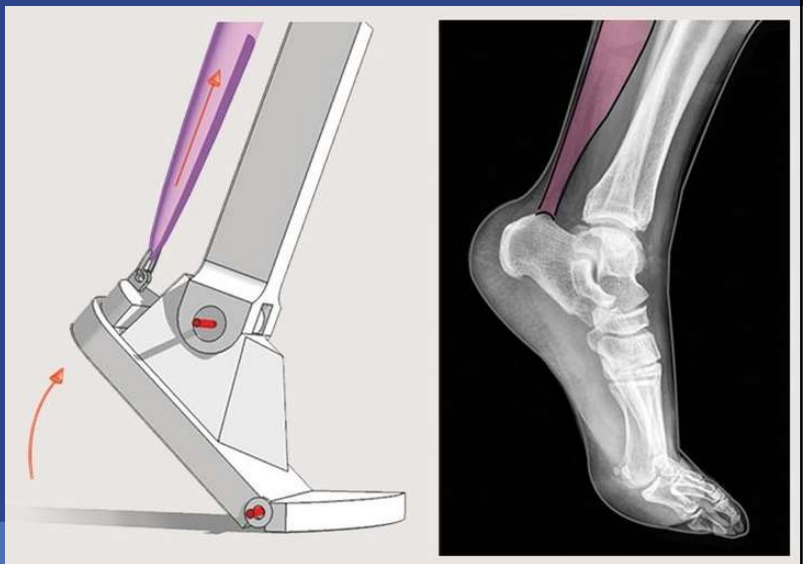

Image: https://www.pinterest.co.uk/pin/artstation-calf-muscles-anatomy-for-sculptors--779404279280558761/

27

ACHILLES TENDON

- Longest and strongest tendon in the body[3]
- Prone to injury due to poor blood supply and high tension on it
- Usually tears approximately 4-6cm above the calcaneal insertion[7]

28

© Copyright. Society of Diagnostic Medical Sonography. All Rights Reserved.

ACHILLES TENDON

- Haglund's deformity

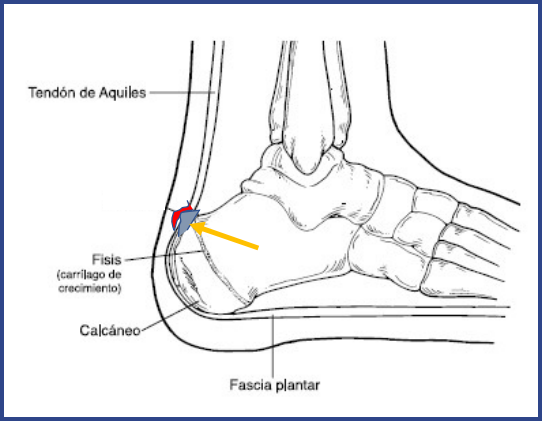

File:Pedheelpainsp1.jpg. (2022, September 19). *Wikimedia Commons*. Retrieved August 27, 2025, from https://commons.wikimedia.org/w/index.php?title=File:Pedheelpainsp1.jpg&oldid=690017899.

29

ACHILLES TENDON

- Tendonitis
  - Frequent activity, like running or walking, can cause inflammation, stiffness and pain
  - Rest, ice, and stretching may speed healing, which can take weeks or months
  - Sonography shows thickening and hyperemia with Power Doppler
    - Normal thickness is 4-6mm

30

© Copyright. Society of Diagnostic Medical Sonography. All Rights Reserved.

ACHILLES TENDON

- Tendinosis
  - Gradual thickening of the Achilles tendon without apparent inflammation, due to aging or overuse
  - Despite the thickening, the tendon is weakened and prone to further injury or rupture
  - Sonography can show thickening, and possibly calcs but without hyperemia on Power Doppler

31

ACHILLES TENDON

- Bursitis
  - Low-riding, or improperly fitting shoes can irritate the bursa, which is a fluid-filled sac that cushions the Achilles tendon at the heel
  - Pain in the back of the heel, worse with shoes on, is the common symptom
  - Sonography can show a fluid filled sac in the retro-calcaneal or retro-achilles area

    < 2-3mm is normal

32

© Copyright. Society of Diagnostic Medical Sonography. All Rights Reserved.

ACHILLES TENDON

- Bursitis

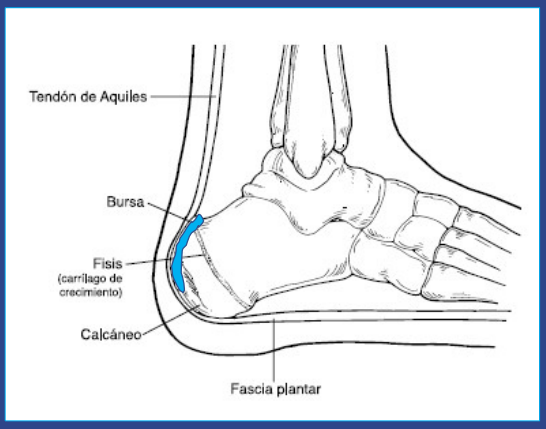

33

ACHILLES TENDON

- Bursitis

- Retro Achilles bursa -Adventitial bursa[8]

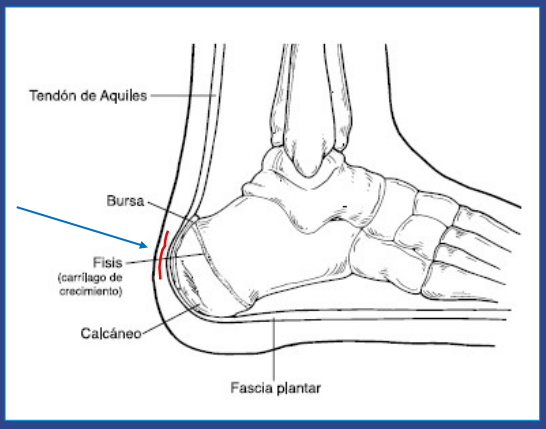

34

© Copyright. Society of Diagnostic Medical Sonography. All Rights Reserved.

ACHILLES TENDON

- Patient position
  - Have the patient lie face down on the exam table, with the feet dangling off the end of the table

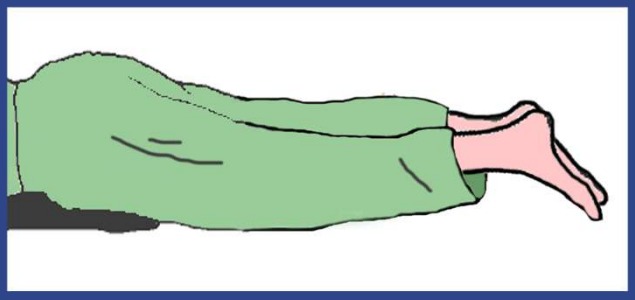

File:Prone position1.gif. (2023, June 3). *Wikimedia Commons*. Retrieved August 27, 2025, from https://commons.wikimedia.org/w/index.php?title=File:Prone_position1.gif&oldid=770471677.

35

ACHILLES TENDON

- Protocol
  - Have the patient lie face down on the exam table, with the feet dangling off the end of the table
  - Image the normal or asymptomatic side first!
  - Image the symptomatic side and in short and long axis with measurements, but be careful!
  - Use Power Doppler if thickening is present
  - Dynamic maneuvers may be helpful if a complete tear is suspected, but difficult to prove

36

© Copyright. Society of Diagnostic Medical Sonography. All Rights Reserved.

ACHILLES TENDON

- Achilles tear
  - Can be tiny or large
- Rupture, or complete tear
  - Dynamic imaging may be helpful
  - Measure the distance between tendon ends, if present

37

ACHILLES TENDON

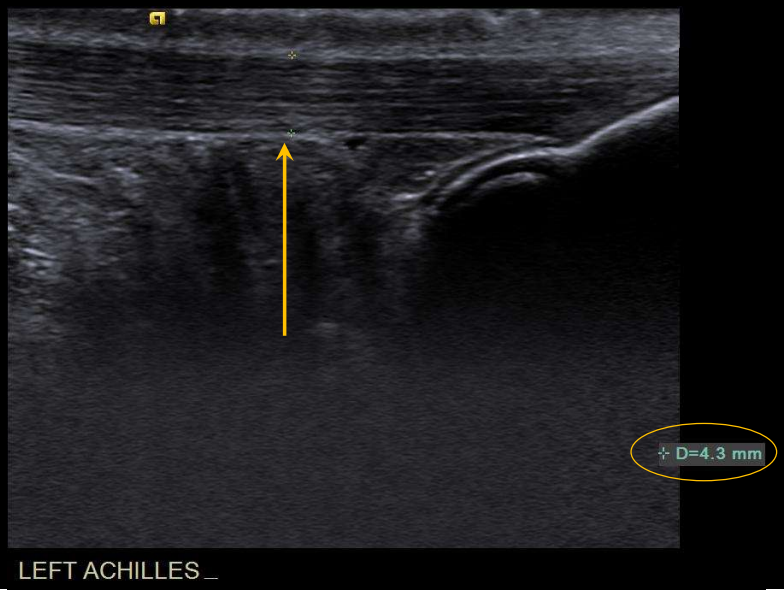

38

© Copyright. Society of Diagnostic Medical Sonography. All Rights Reserved.

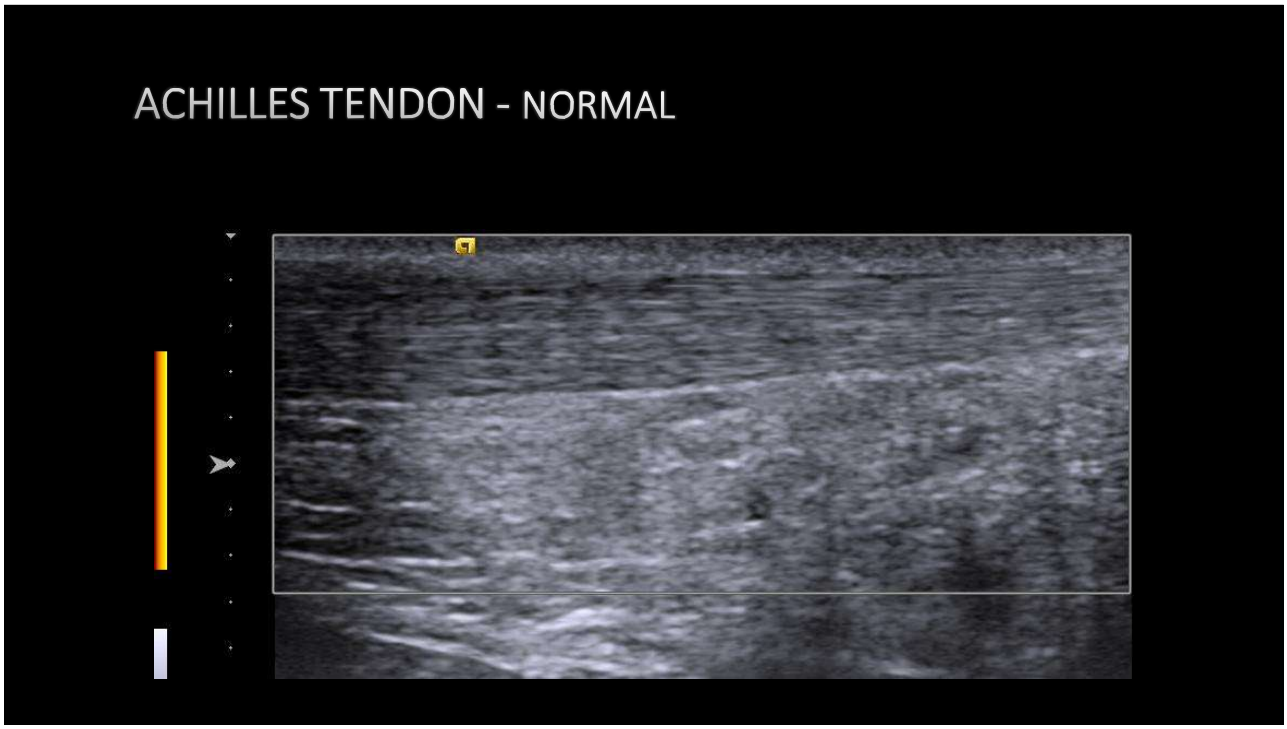

39

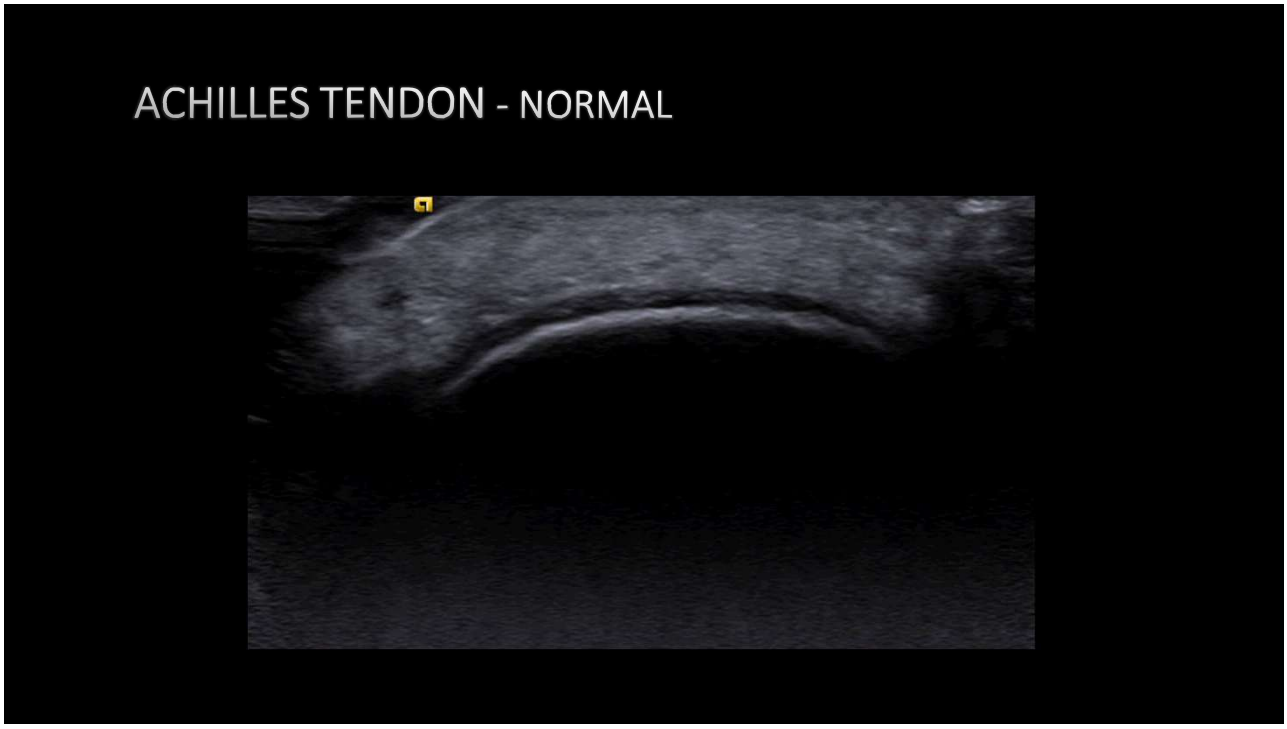

40

© Copyright. Society of Diagnostic Medical Sonography. All Rights Reserved.

ACHILLES TENDONITIS



41

ACHILLES TENDONITIS

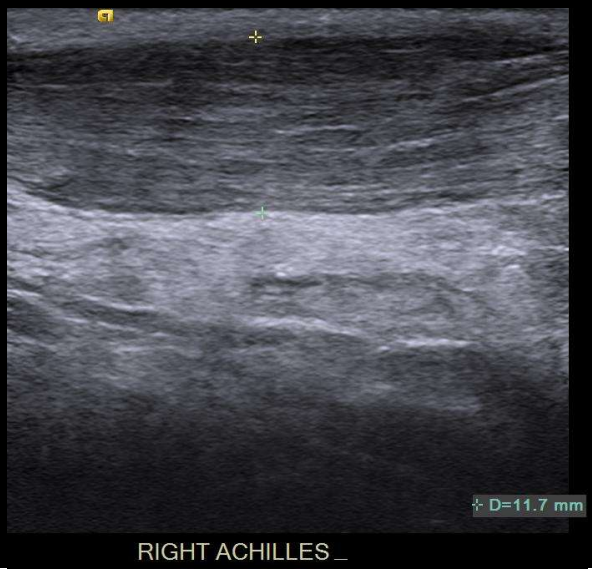

42

© Copyright. Society of Diagnostic Medical Sonography. All Rights Reserved.

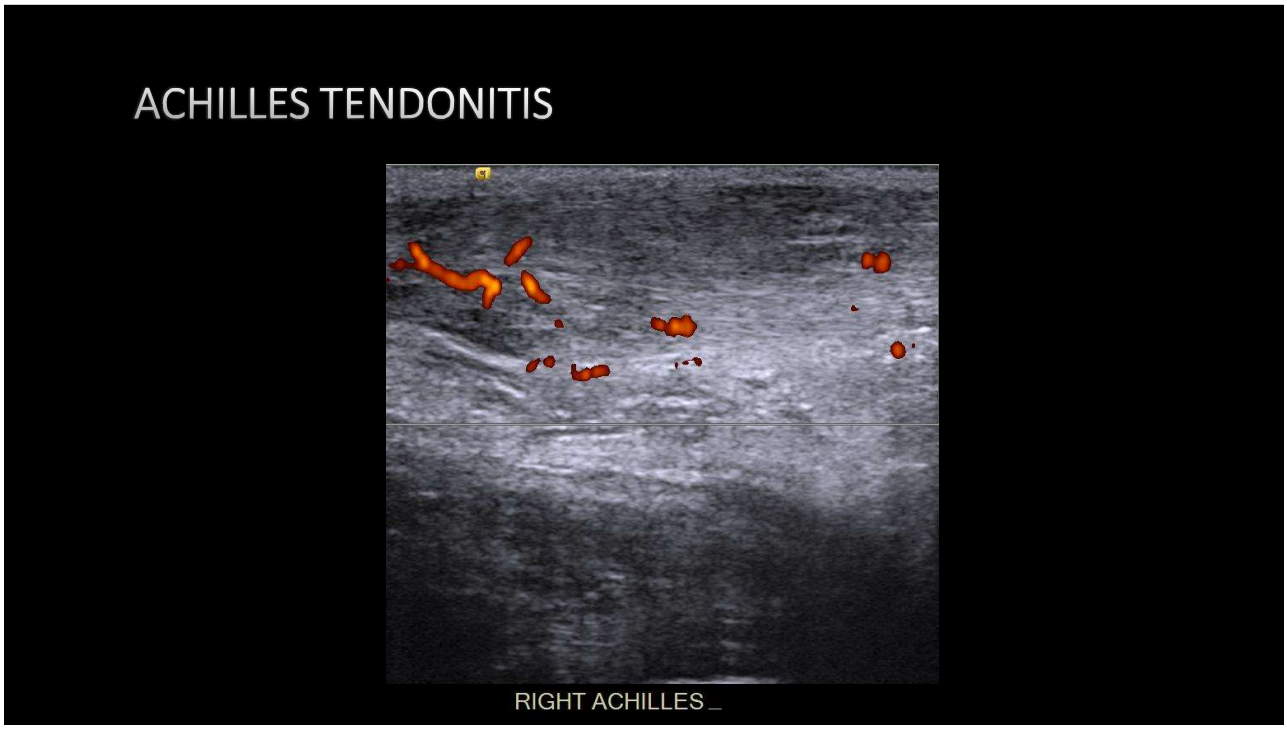

43

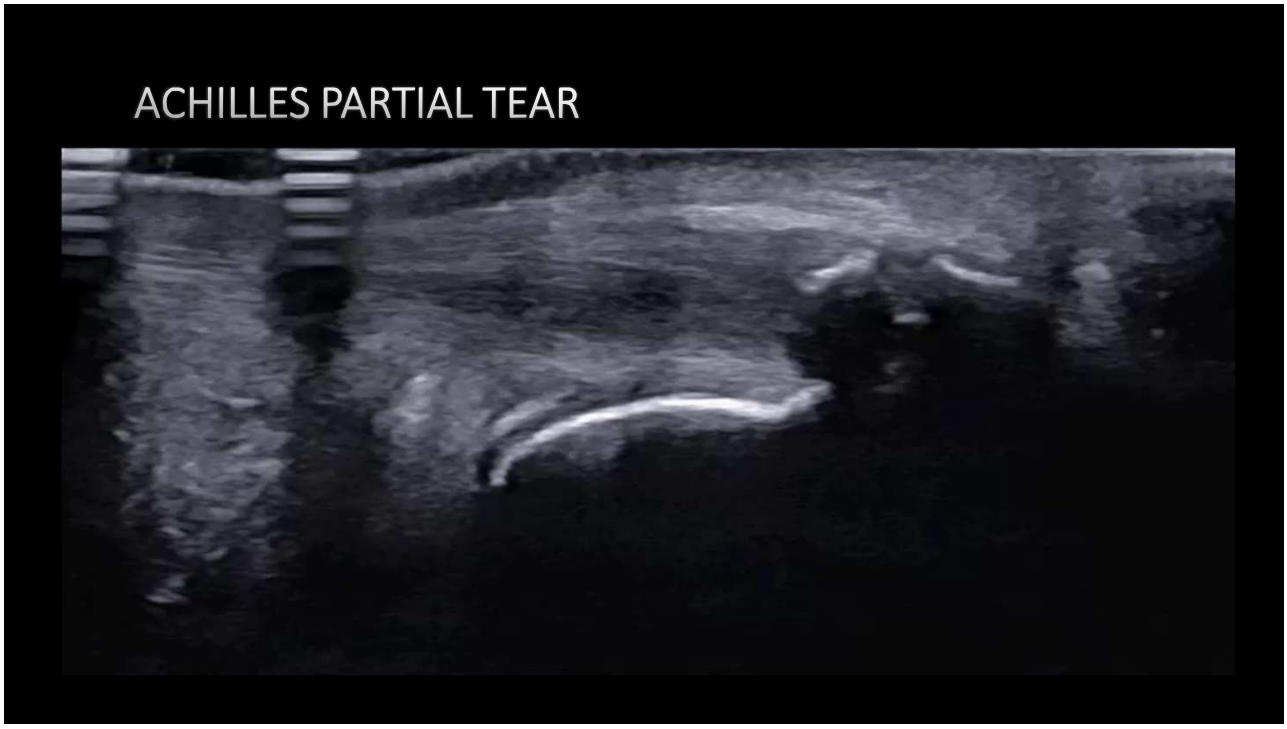

44

© Copyright. Society of Diagnostic Medical Sonography. All Rights Reserved.

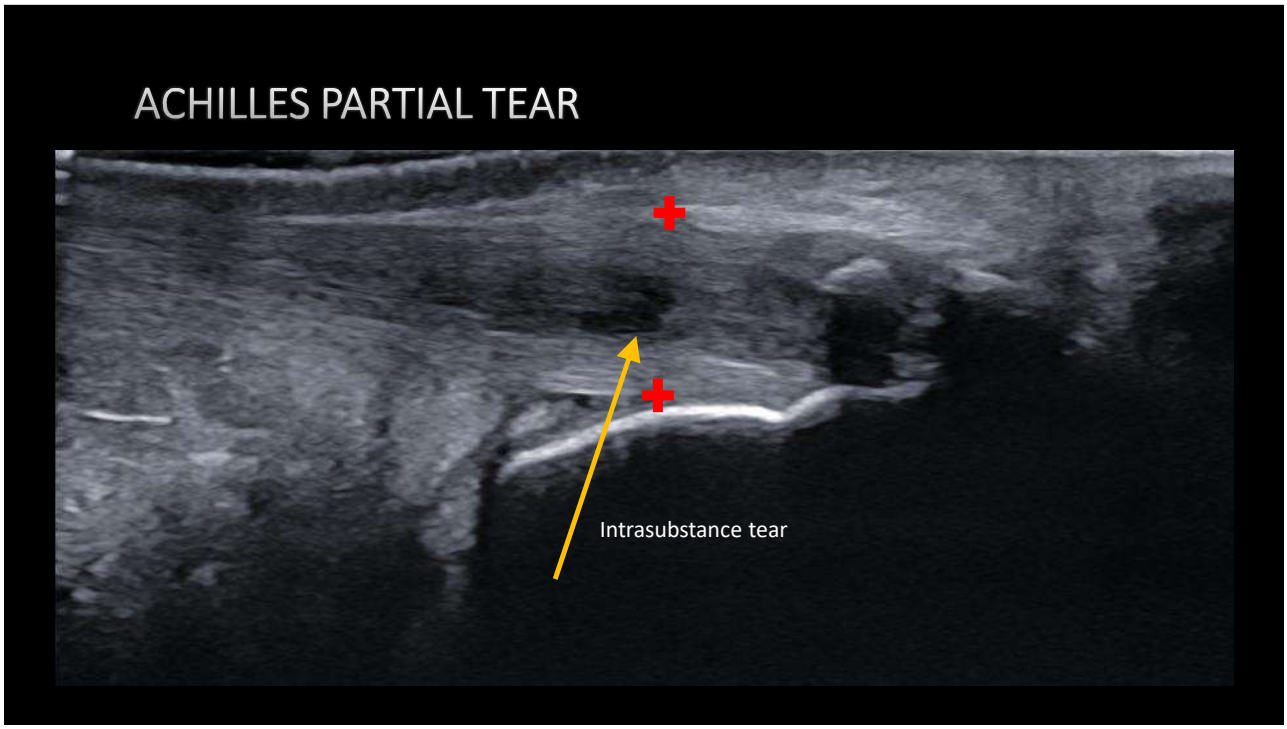

45

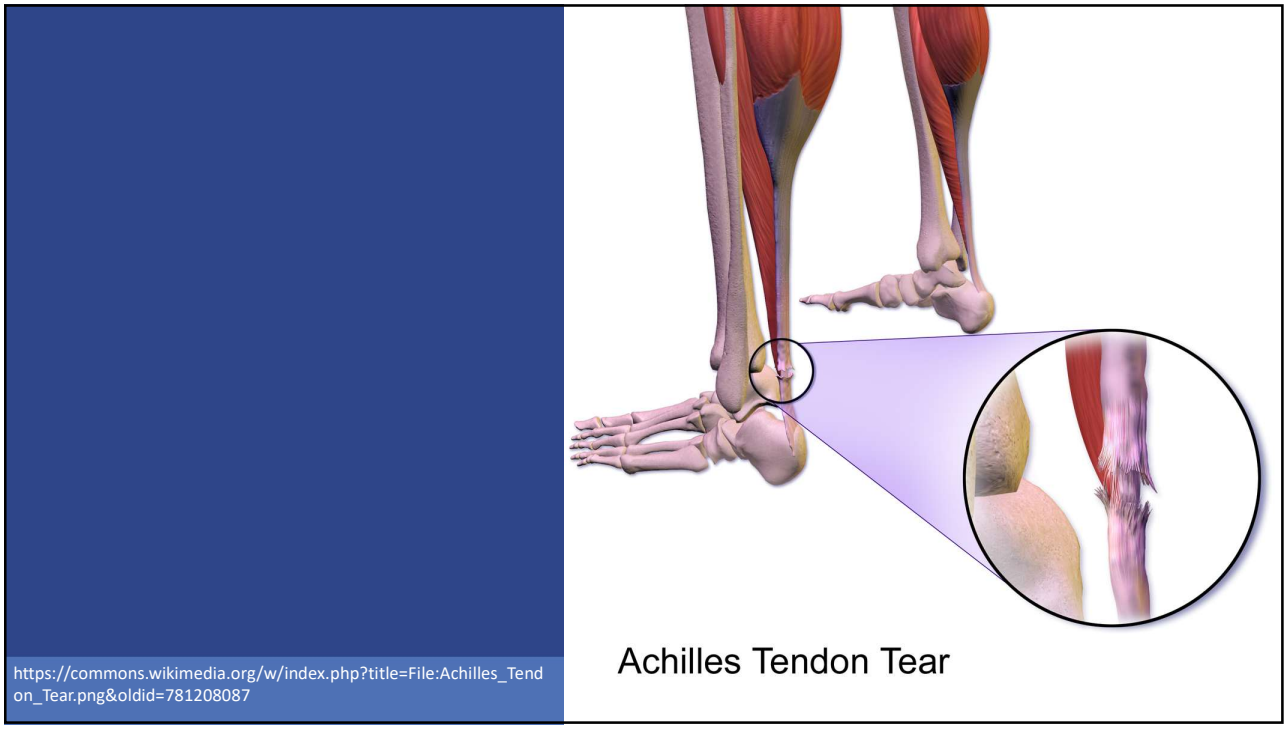

46

© Copyright. Society of Diagnostic Medical Sonography. All Rights Reserved.

PLANTARIS TENDON

- **Is absent in 7% to 10% of the population[2]**

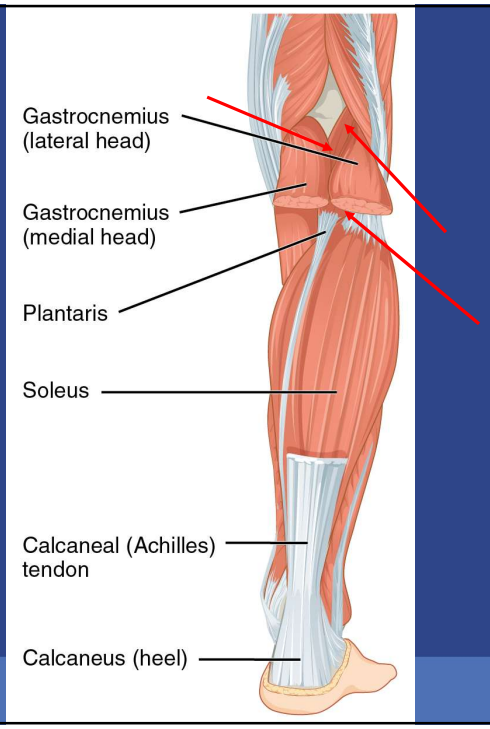

File:1123 Muscles of the Leg that Move the Foot and Toes b.png. (2023, March 23). Wikimedia Commons. Retrieved July 29, 2025, from https://commons.wikimedia.org/w/index.php?title=File:1123_Muscles_of_the_Leg_that_Move_the_Foot_and_Toes_b.png&oldid=742757047

47

PLANTARIS TENDON RUPTURE

- TENNIS LEG

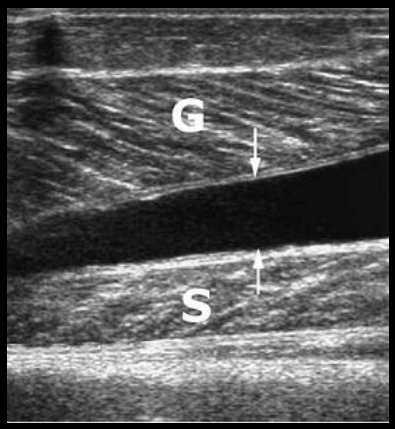

aponeurosis

File:Tenniskuit1.jpg. (2024, August 27). *Wikimedia Commons*. Retrieved August 27, 2025, from https://commons.wikimedia.org/w/index.php?title=File:Tenniskuit1.jpg&oldid=916326683.

48

© Copyright. Society of Diagnostic Medical Sonography. All Rights Reserved.

APONEUROSIS

Flat sheet of connective tissue that's important for movement and posture[4]

Aponeuroses (plural) cover your muscles and provide insertion points for the muscle fibers

49

APONEUROSIS VS FASCIA

Aponeurosis- provide a wide attachment for muscles to other muscles or bones

Fascia- Supports, separates, and protects organs and muscles

50

© Copyright. Society of Diagnostic Medical Sonography. All Rights Reserved.

QUAD TENDON AND PATELLAR TENDON

51

Quad tendon

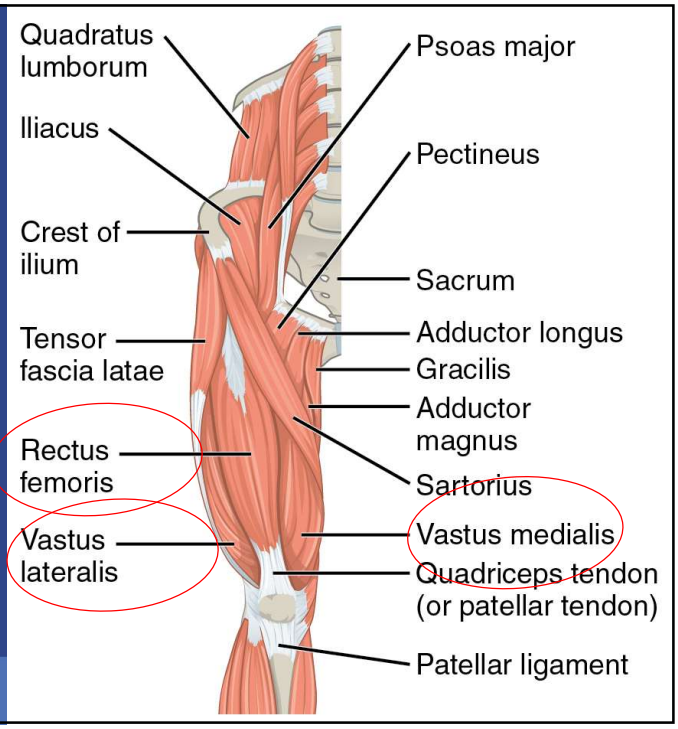

https://commons.wikimedia.org/w/index.php?title=File:1122_Gluteal_Muscles_that_Move_the_Femur_a.png&oldid=742756145

52

© Copyright. Society of Diagnostic Medical Sonography. All Rights Reserved.

Possible proprioceptive function role[1]

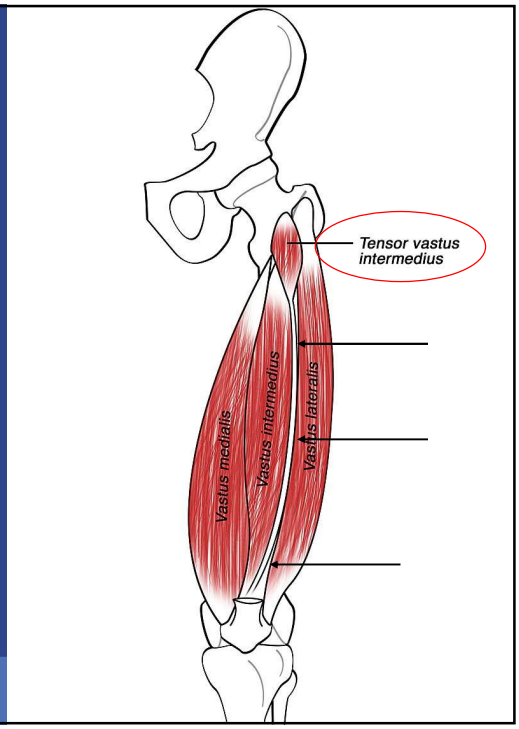

By Athikhun.suw - Own work, CC BY-SA 4.0, https://commons.wikimedia.org/w/index.php?curid=47146806

53

QUAD TENDON AND PATELLAR TENDON

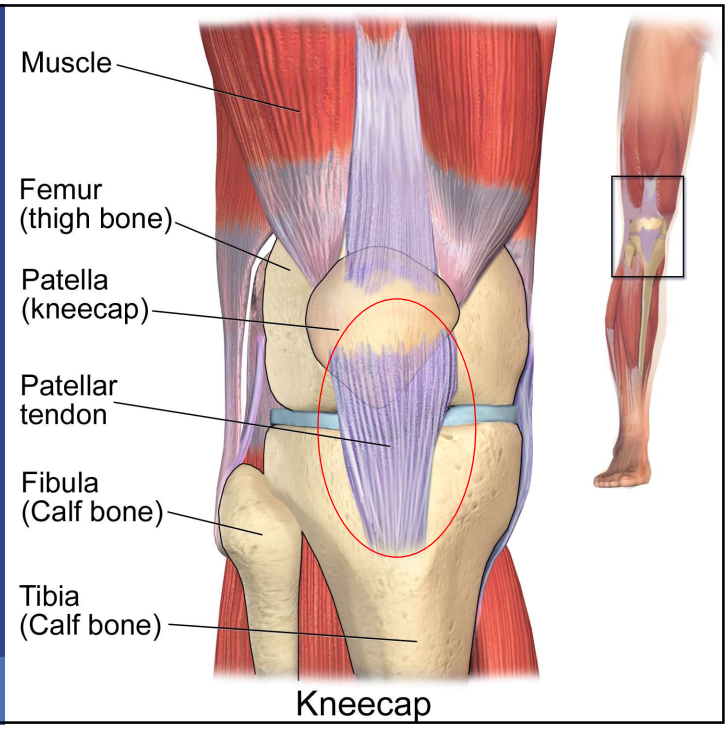

File:Blausen 0596 KneeAnatomy Front.png. (2023, November 27). Wikimedia Commons. Retrieved July 29, 2025, from https://commons.wikimedia.org/w/index.php?title=File:Blausen_0596_KneeAnatomy_Front.png&oldid=825516291.

54

© Copyright. Society of Diagnostic Medical Sonography. All Rights Reserved.

QUAD TENDON

- Protocol
- Have the patient lie supine with knee flexed and the foot flat on the stretcher
- If the patient is unable to lift the knee, you may have to assist



55

QUAD TENDON

- Protocol
- Scan in short axis from distal to up to at least the myotendinous junction for all muscle groups
- Do the same in the long axis
- Interrogate with power Doppler as necessary
- May use dynamic maneuvers if unsure about partial tear vs complete (rupture)



56

© Copyright. Society of Diagnostic Medical Sonography. All Rights Reserved.

QUAD TENDON

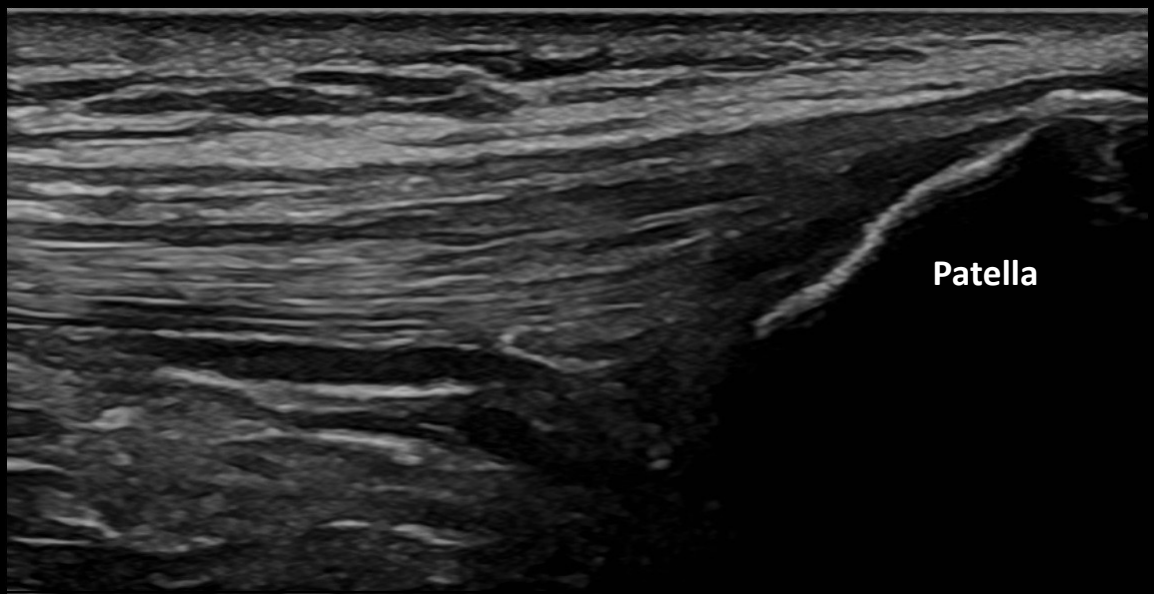

57

PATELLAR TENDON (LIGAMENT)

- Protocol
- Scan in short axis from the patella down to the tibial plateau
- Do the same in the long axis
- Interrogate with power Doppler as necessary
- May use dynamic maneuvers if unsure about partial tear vs complete (rupture)

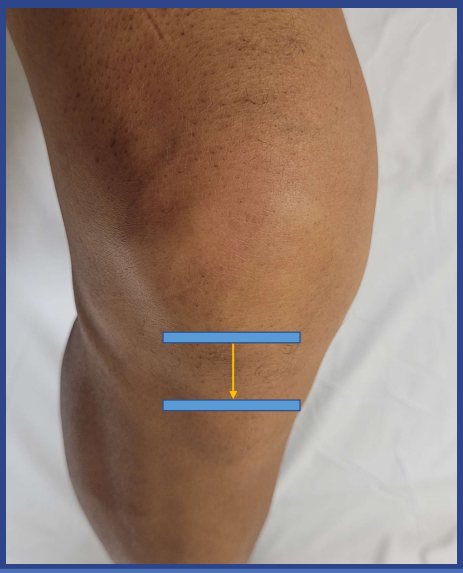

58

© Copyright. Society of Diagnostic Medical Sonography. All Rights Reserved.

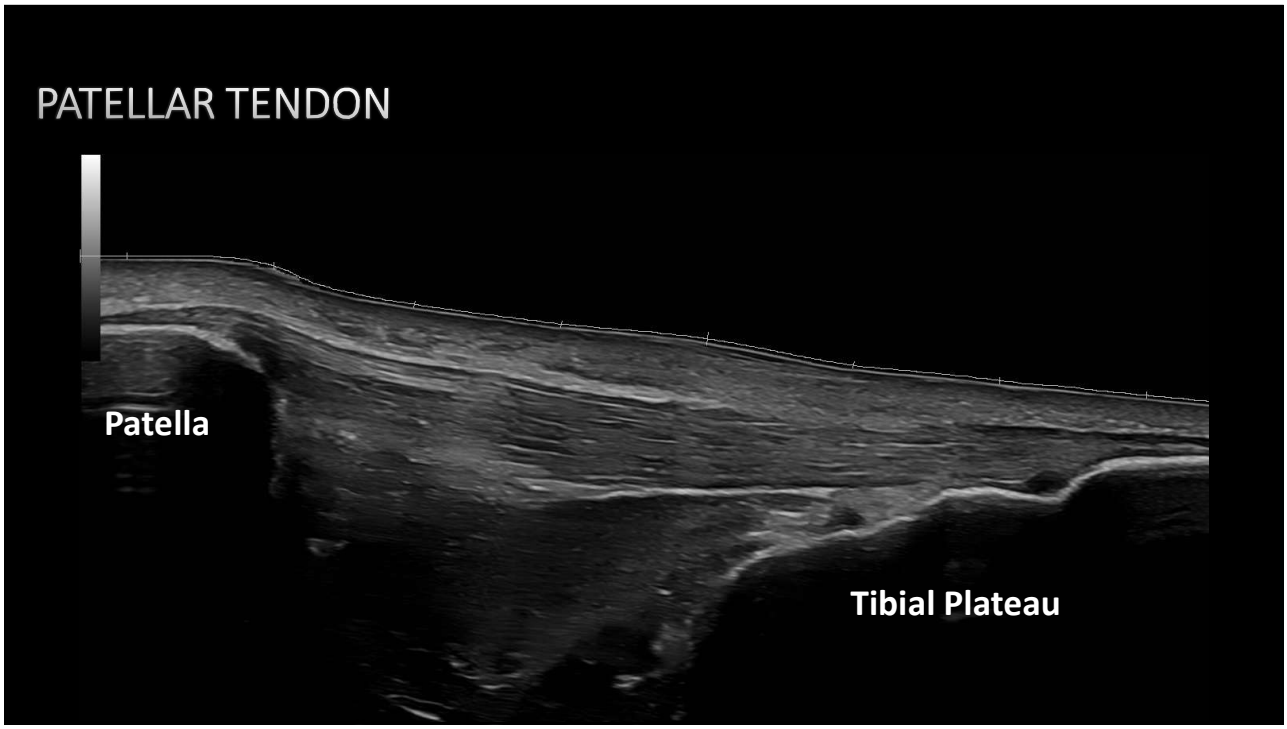

59

BICEPS TENDONS

60

© Copyright. Society of Diagnostic Medical Sonography. All Rights Reserved.

BICEPS TENDONS

- The long head biceps tendon originates from the supraglenoid tubercle of the scapula
- The short head biceps tendon attaches to the coracoid process, which is a smaller, hook-like projection at the front of the scapula
- Distally, it "appears" that both are fused together to attach at the radial tuberosity[5,6]

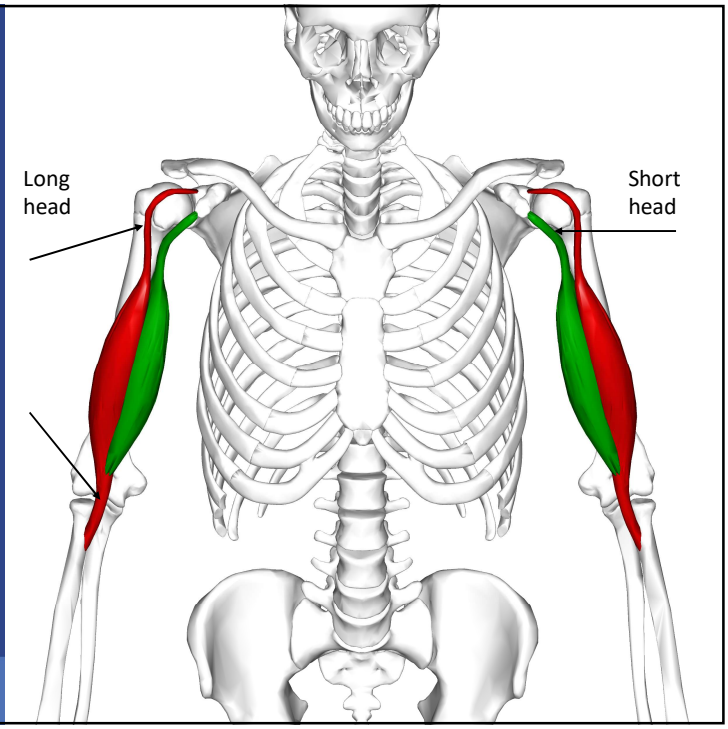

File:Biceps brachii muscle06.png. (2023, November 19). Wikimedia Commons. Retrieved July 29, 2025, from https://commons.wikimedia.org/w/index.php?title=File:Biceps_brachii_muscle06.png&oldid=823226385.

61

BICEPS TENDONS

Proximal Biceps

Long Head- bicipital groove at humeral head

Short Head- coracoid process of the scapula

62

© Copyright. Society of Diagnostic Medical Sonography. All Rights Reserved.

BICEPS TENDONS – LONG HEAD

Patient Position

- Sitting facing toward you with hand extended, palm up

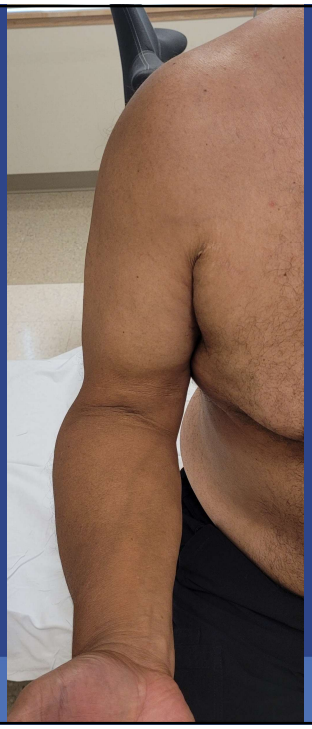

63

BICEPS TENDONS – LONG HEAD

- Evaluate the long head tendon in long and short axis from the bicipital groove down to the myotendinous junction

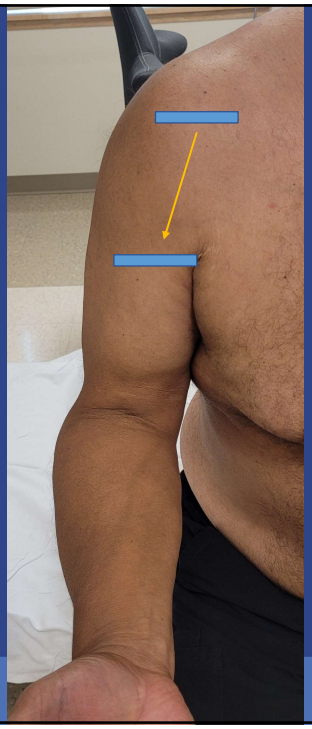

64

© Copyright. Society of Diagnostic Medical Sonography. All Rights Reserved.

BICEPS TENDONS

Proximal Biceps
-Long Head

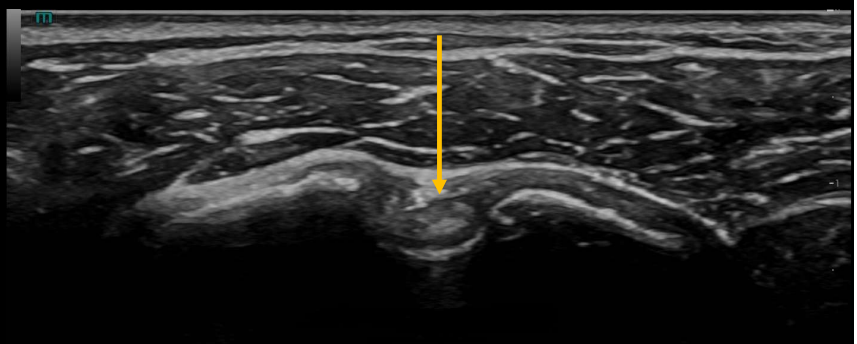

Short Axis

65

BICEPS TENDONS – LONG HEAD

- Measure the AP dimension in long axis and use power Doppler as necessary

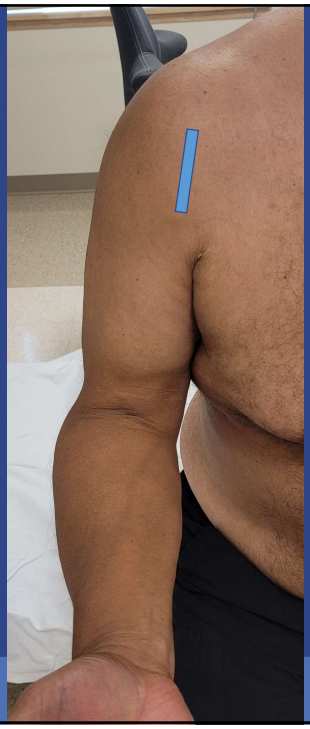

66

© Copyright. Society of Diagnostic Medical Sonography. All Rights Reserved.

BICEPS TENDONS

Proximal Biceps
-Long Head

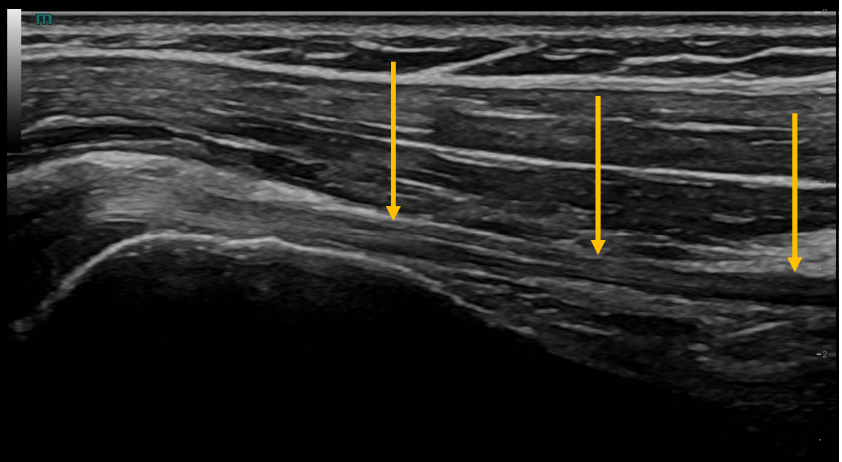

Long Axis

67

BICEPS TENDONS

Proximal Biceps
-Short Head

We don’t typically image this, but occasionally needed

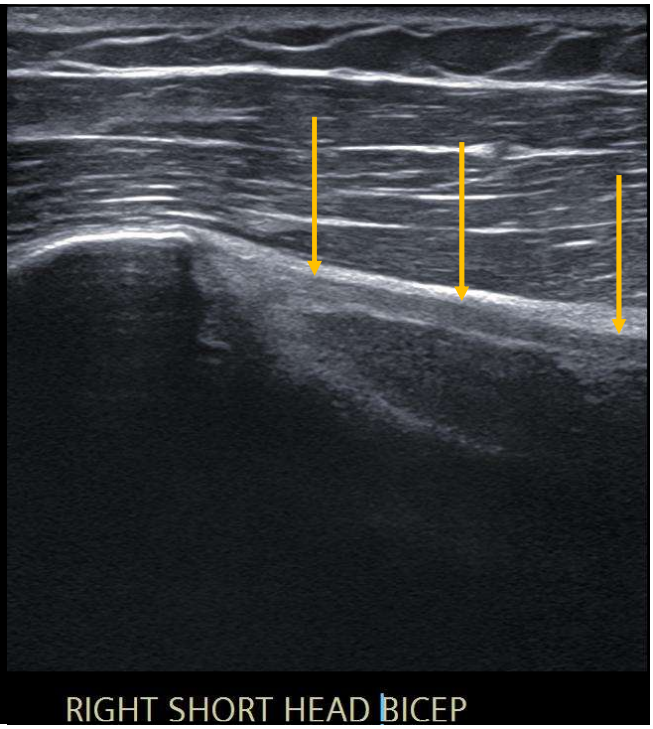

68

© Copyright. Society of Diagnostic Medical Sonography. All Rights Reserved.

BICEPS TENDONS – DISTAL INSERTION

Patient Position

- Sitting facing toward you with hand extended, palm up

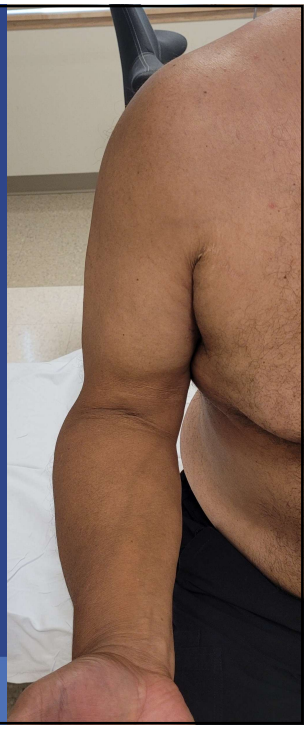

69

BICEPS TENDONS – DISTAL INSERTION

- Evaluate in short axis from the mid biceps muscle, through the myotendinous junction down to its insertion on the radial tuberosity (use transducer toggling to make tendon hypoechoic)
- Image distal insertion in long axis and use dynamic maneuvers as necessary

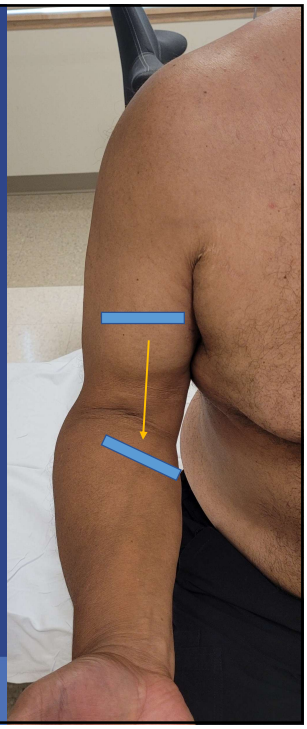

70

© Copyright. Society of Diagnostic Medical Sonography. All Rights Reserved.

BICEPS TENDONS

Distal Biceps

On Radial Tuberosity

71

BICEPS TENDONS

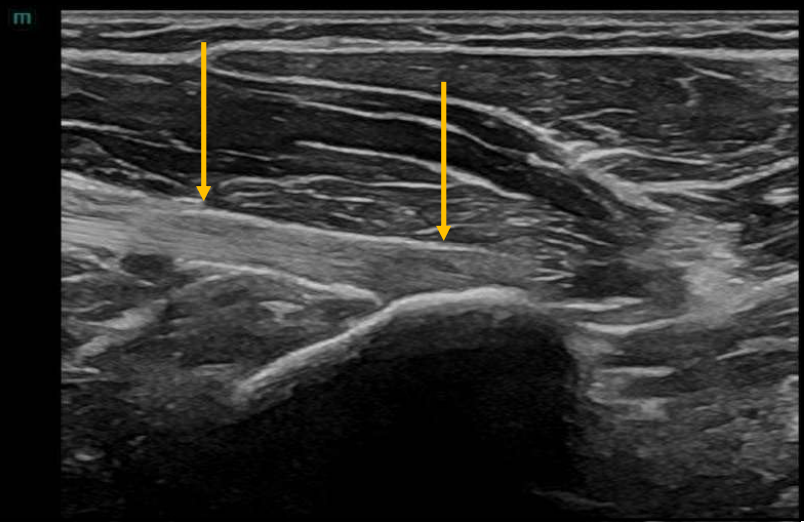

72

© Copyright. Society of Diagnostic Medical Sonography. All Rights Reserved.

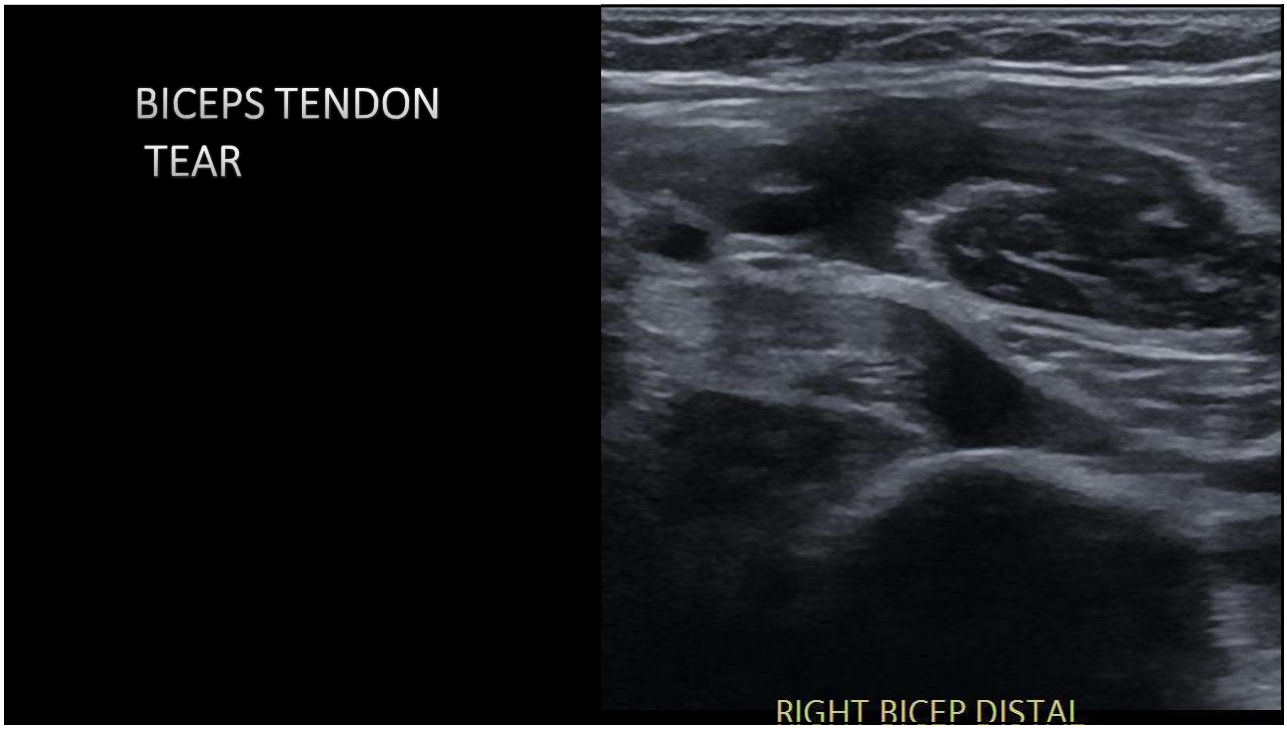

73

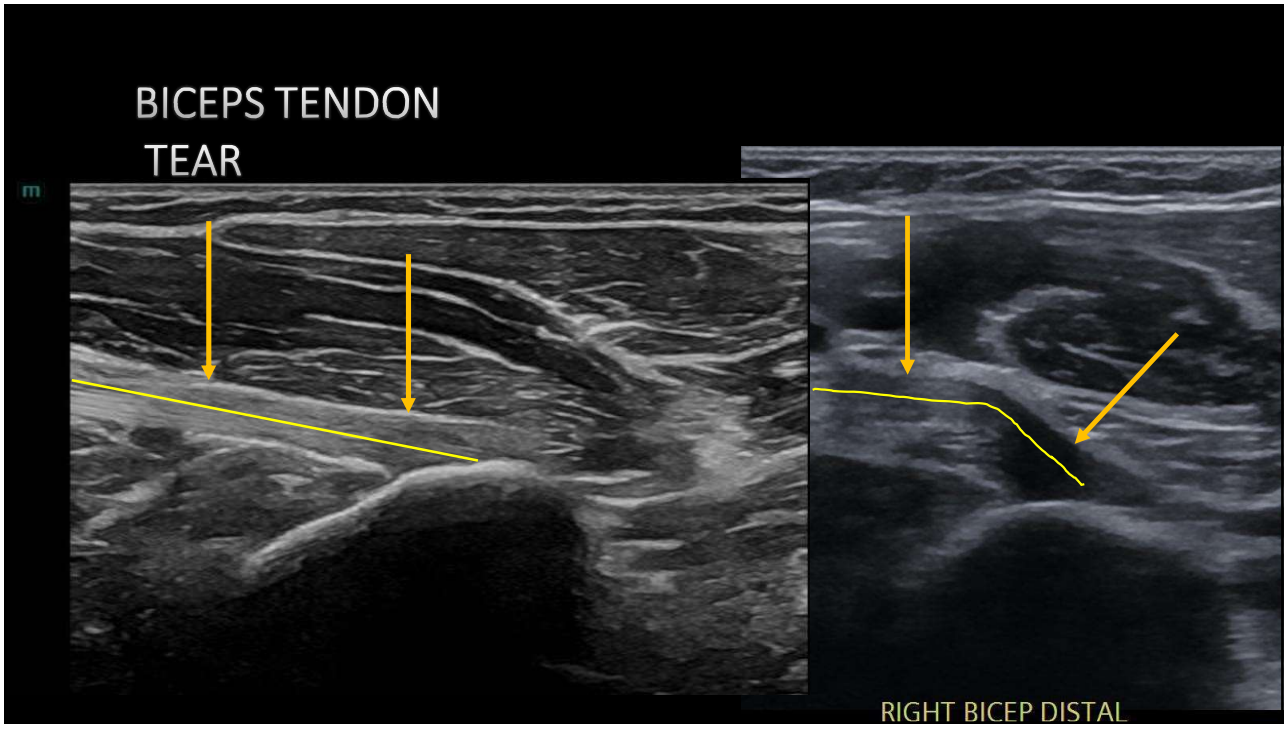

74

© Copyright. Society of Diagnostic Medical Sonography. All Rights Reserved.

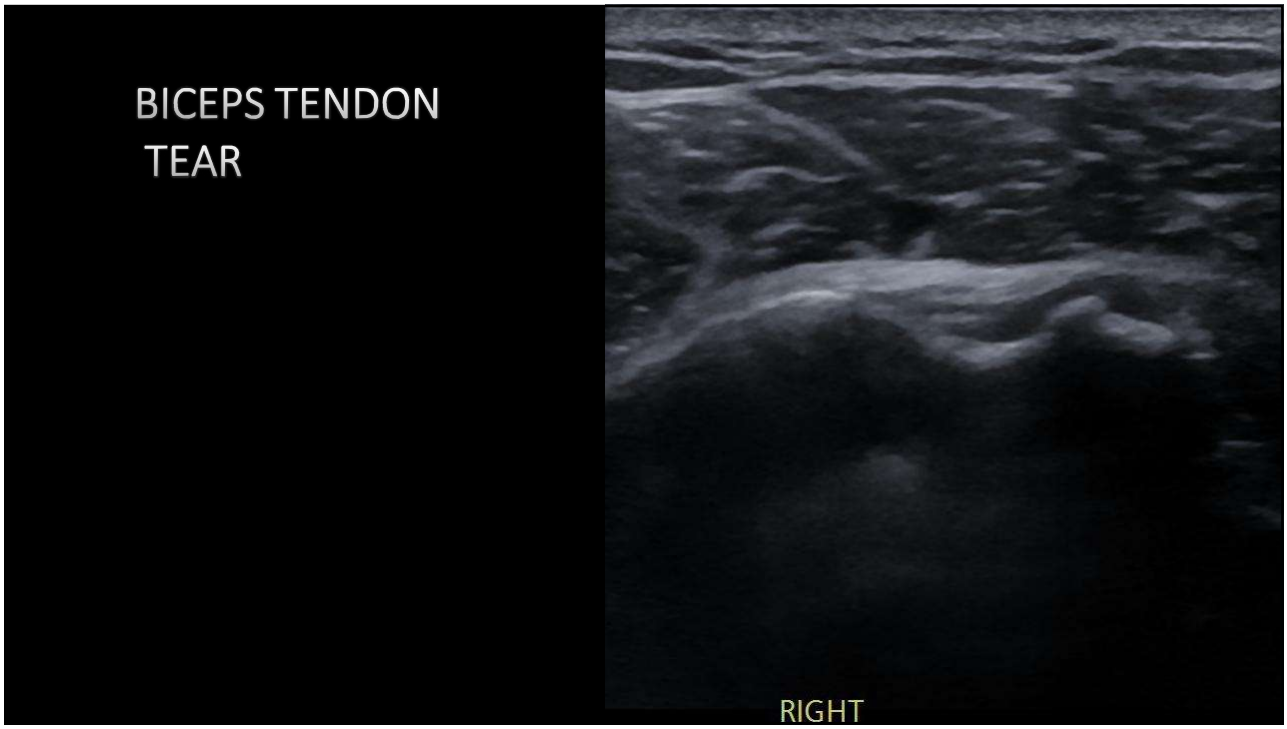

75



76

© Copyright. Society of Diagnostic Medical Sonography. All Rights Reserved.

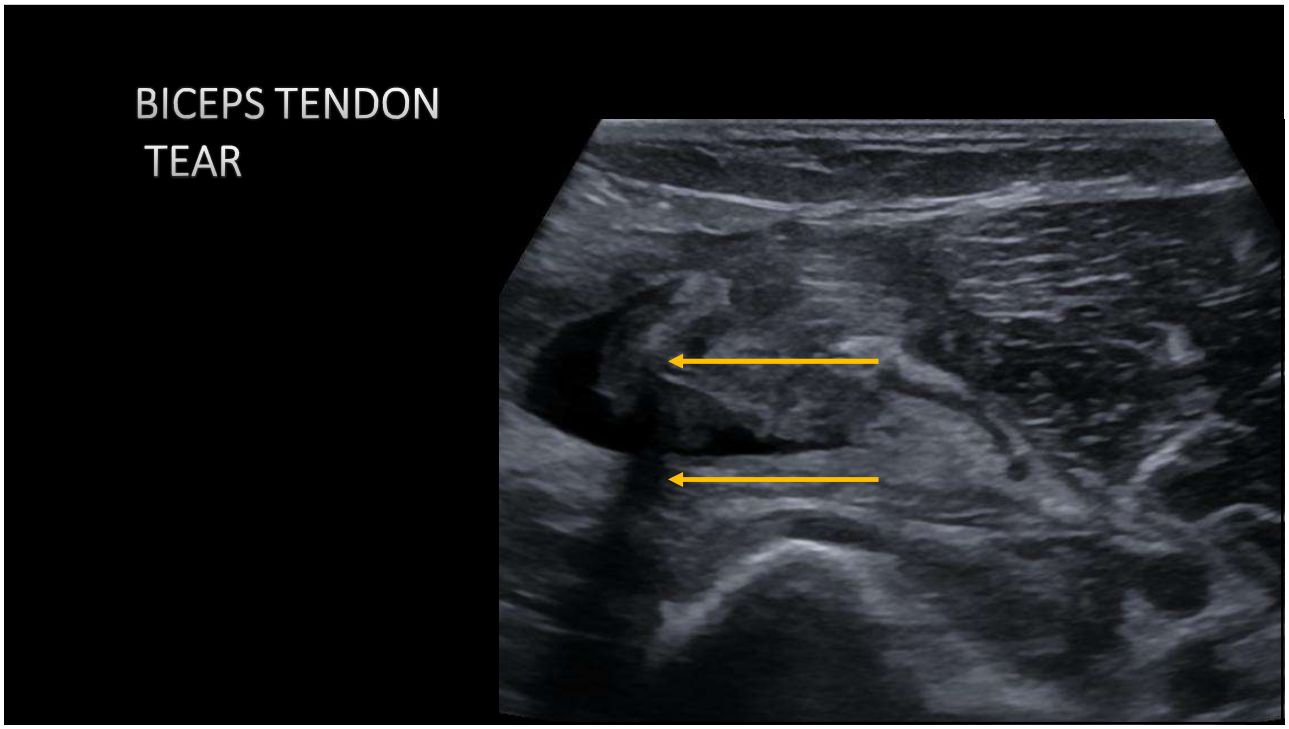

77

REFERENCES

1 https://my.clevelandclinic.org/health/articles/proprioception/ - accessed 08/26/2026

2 https://radsource.us/tennis-leg-plantaris-tendon-rupture/ - accessed 08/27/2025

3 Zielinska N, LaPrade RF, Olewnik Ł. Morphological variations of the calcaneal tendon: clinical significance. J Orthop Surg Res. 2023 Apr 4;18(1):275. doi: 10.1186/s13018-023-03748-y. PMID: 37016428; PMCID: PMC10074894.

4 https://my.clevelandclinic.org/health/body/23407-aponeurosis/ - accessed 08/27/2026

5 Zeid Al-Ani, Joshua Lauder, Ultrasound assessment in distal biceps tendon injuries: Techniques, pearls and pitfalls, Clinical Imaging, Volume 75, 2021, Pages 46-54, ISSN 0899-7071, https://doi.org/10.1016/j.clinimag.2021.01.017

6 Eames, M.H.A. MD1; Bain, G.I. MD2; Fogg, Q.A. MD3; van Riet, R.P. MD, PhD4. Distal Biceps Tendon Anatomy: A Cadaveric Study. The Journal of Bone & Joint Surgery 89(5):p 1044-1049, May 2007. | DOI: 10.2106/JBJS.D.02992

78

© Copyright. Society of Diagnostic Medical Sonography. All Rights Reserved.

REFERENCES

7. https://www.mayoclinic.org/diseases-conditions/achilles-tendon-rupture/symptoms-causes/syc-20353234#:~:text=Rupture%20usually%20occurs%20in%20the,associated%20with%20Achilles%20tendon%20ruptures. –accessed 8/28/2025

8. Di Muzio B, Knipe H, Eleterio Neto J, et al. Subcutaneous calcaneal bursa. Reference article, Radiopaedia.org (Accessed on 12 Sep 2025) https://doi.org/10.53347/rID-39137 -accessed 9/12/2025

79

THANK YOU!

Email: tedwhittensr@gmail.com

80

© Copyright. Society of Diagnostic Medical Sonography. All Rights Reserved.