2026 SDMS Annual Conference

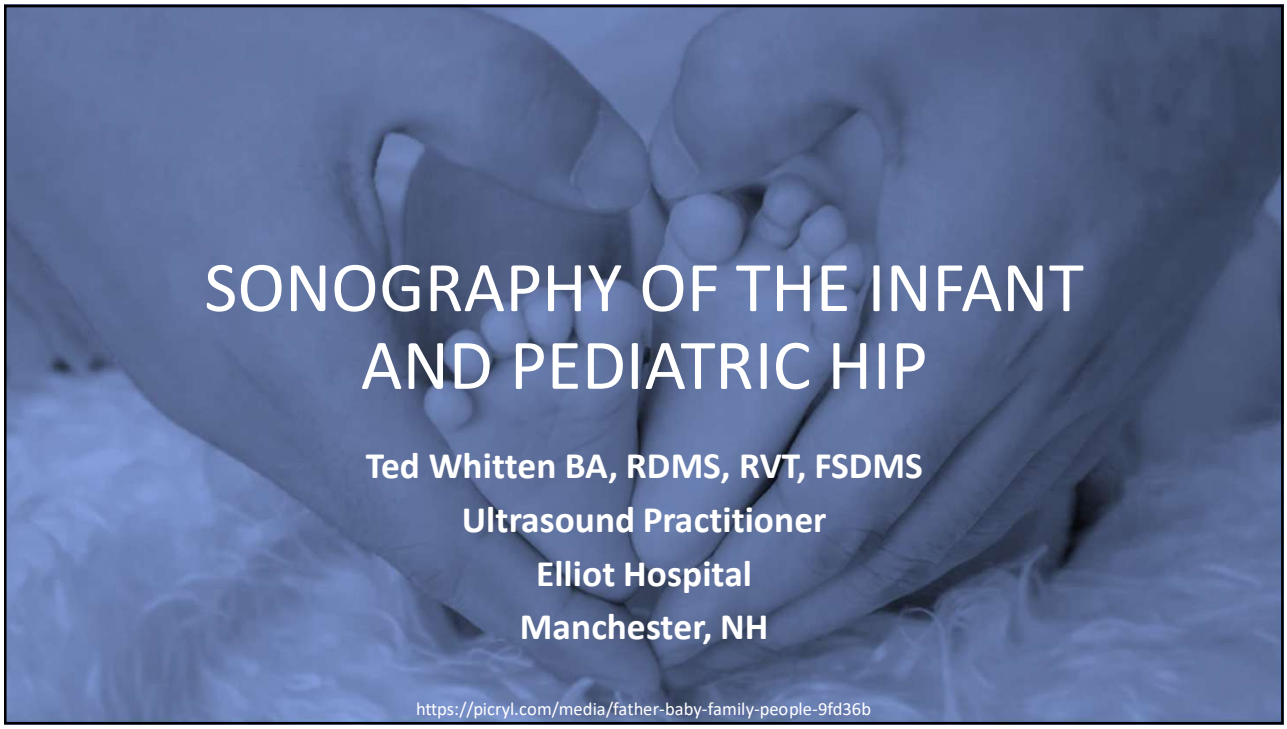

1

SPEAKER PRESENTATION DISCLAIMER

The content and views presented are made available for educational purposes only. The information presented are the opinions of the presenter and do not necessarily represent the views of the Society of Diagnostic Medical Sonography (SDMS) or its affiliated organizations, officers, Boards of Directors, or staff members.

The presenter is responsible for ensuring balance, independence, objectivity, scientific rigor, and avoiding commercial bias in their presentation. Before making the presentation, the presenter is required to disclose to the audience any relevant financial interests or relationships with manufacturers or providers of medical products, services, technologies, and programs.

The SDMS and its affiliated organizations, officers, Board of Directors, and staff members disclaim any and all liability for all claims that may arise out of the use of this educational activity.

2

© Copyright. Society of Diagnostic Medical Sonography. All Rights Reserved.

GENERATIVE AI DISCLAIMER

The presenter utilized the use of large language models (LLMs) and generative artificial intelligence (AI) as a productivity tool to assist in drafting and refining content in this presentation.

While these tools can aid in structuring ideas, summarizing, paraphrasing, and language polishing, they have inherent limitations and cannot replace human creativity, critical thinking, or expert judgment. AI-generated content may contain errors, biases, or gaps in knowledge.

This presentation is intended for informational purposes only and should not be construed as definitive or authoritative guidance. Participants are encouraged to critically evaluate the information presented and consult relevant experts as needed. The SDMS and its affiliated organizations, officers, Board of Directors, and staff members disclaim any and all liability for claims that may arise from the use or interpretation of this educational material.

3

OBJECTIVES

1. Describe normal infant hip anatomy and development to support accurate sonographic evaluation.
2. Explain developmental dysplasia of the hip, including risk factors and clinical significance, to enhance diagnostic understanding.
3. Identify standardized sonographic protocols for evaluating pediatric hip conditions in clinical practice.

4

© Copyright. Society of Diagnostic Medical Sonography. All Rights Reserved.

Key Terms

- Developmental dysplasia
- Abduct
- Adduct
- Arthrocentesis
- Erythrocyte sedimentation rate
- Mesoderm
- Osteomyelitis
- Torticollis
- Hip effusion
- Septic arthritis
- Transient synovitis
- Oligohydramnios

5

OLD TERM

- **Congenital dislocation of the hip (CDH)**

6

© Copyright. Society of Diagnostic Medical Sonography. All Rights Reserved.

PREFERRED TERM

- **Developmental dysplasia of the hip (DDH)**
  - Not all are present or identified at birth
  - Developmental more accurately describes the wide spectrum of disorders from mild instability to frank dislocation[1]

7

Developmental Dysplasia of The Hip

- Unstable hip due to abnormal formation in fetal development.
- Instability worsens with age and growth. May sometimes dislocate.
- Most frequently is present at birth but may appear through the infant period

8

© Copyright. Society of Diagnostic Medical Sonography. All Rights Reserved.

DDH

- Shortly after birth, hip laxity is normal
- If subluxation or dislocation persists, structural changes will develop

9

ANATOMY



10

© Copyright. Society of Diagnostic Medical Sonography. All Rights Reserved.

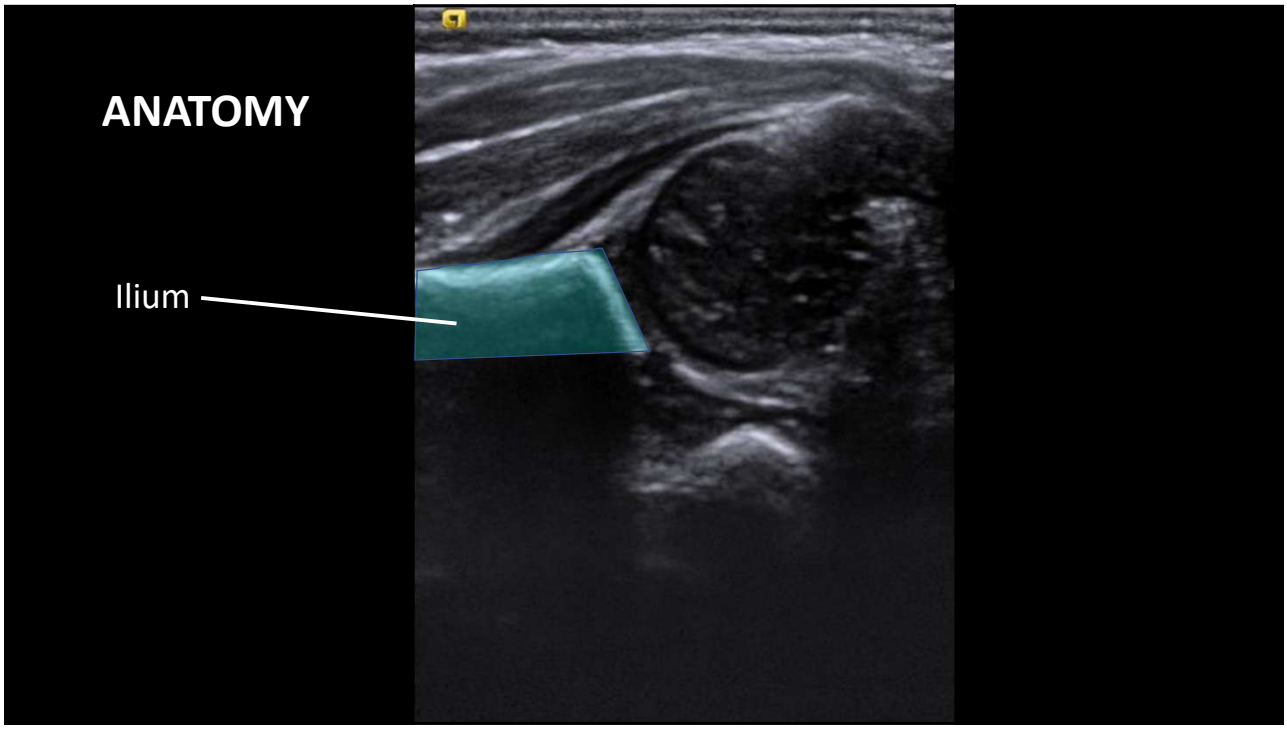

11

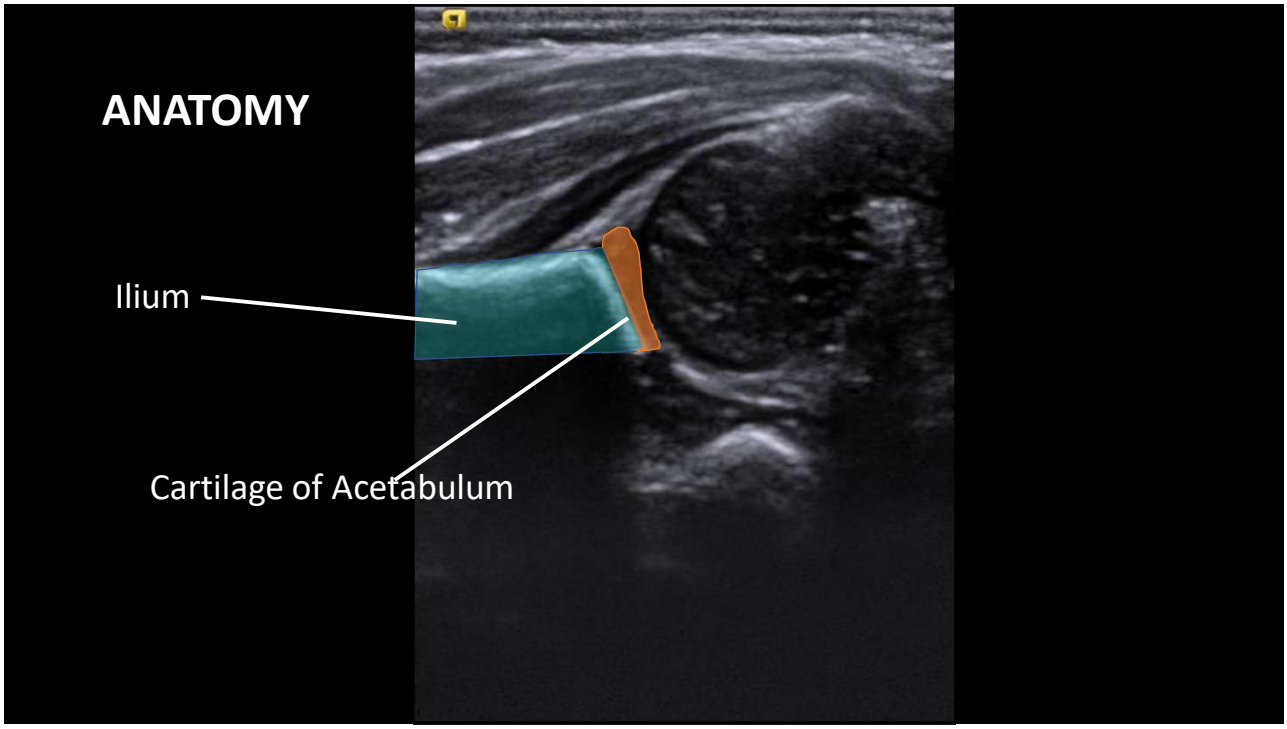

12

© Copyright. Society of Diagnostic Medical Sonography. All Rights Reserved.

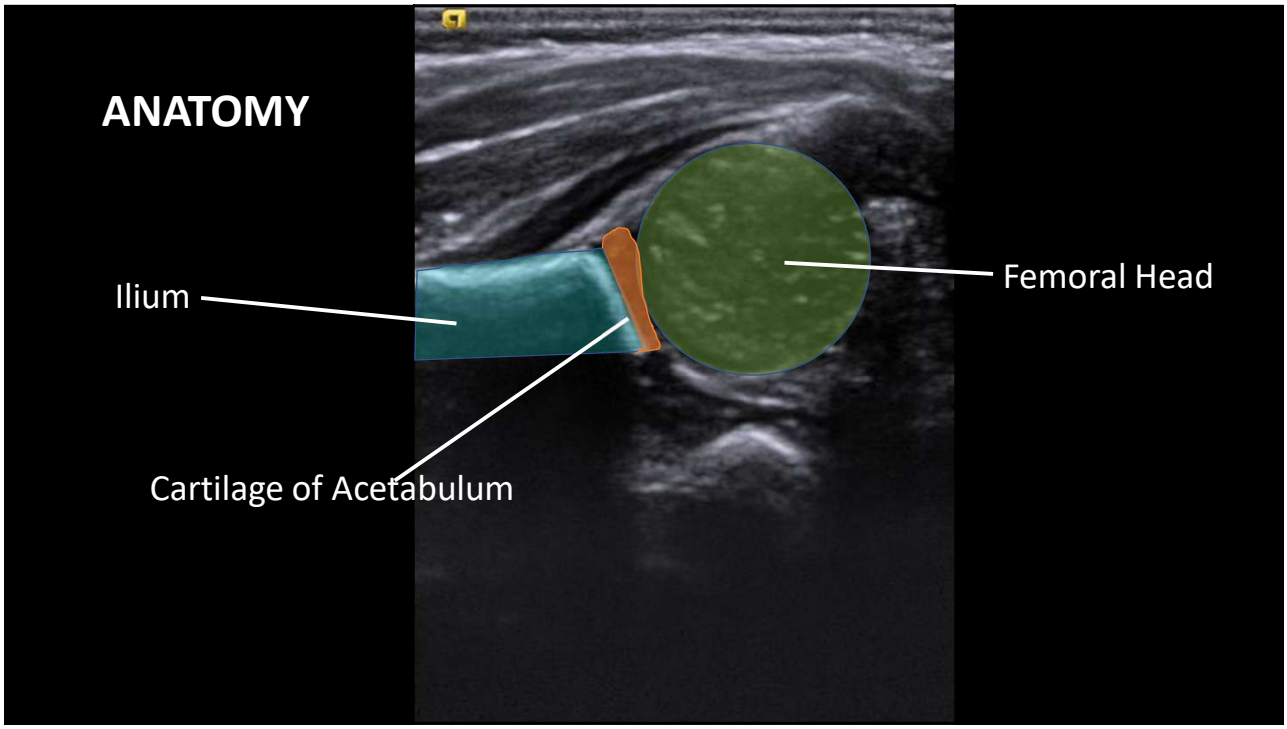

13

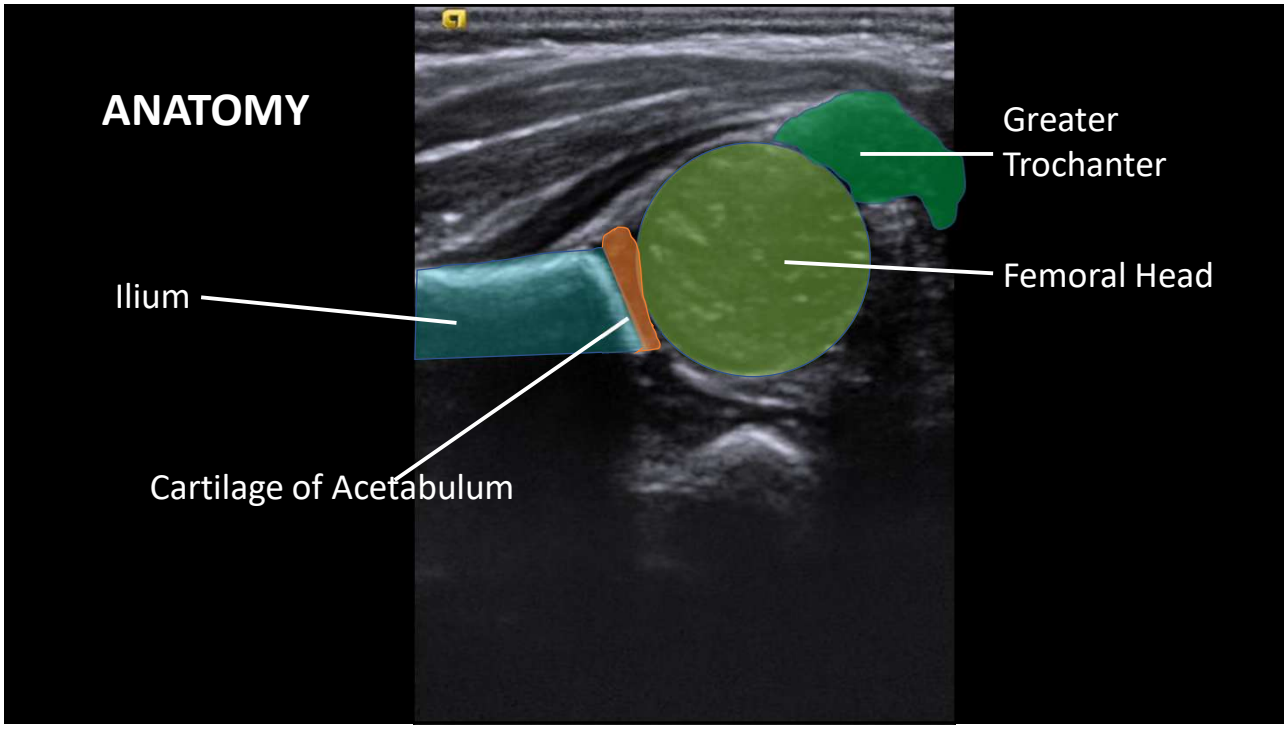

14

© Copyright. Society of Diagnostic Medical Sonography. All Rights Reserved.

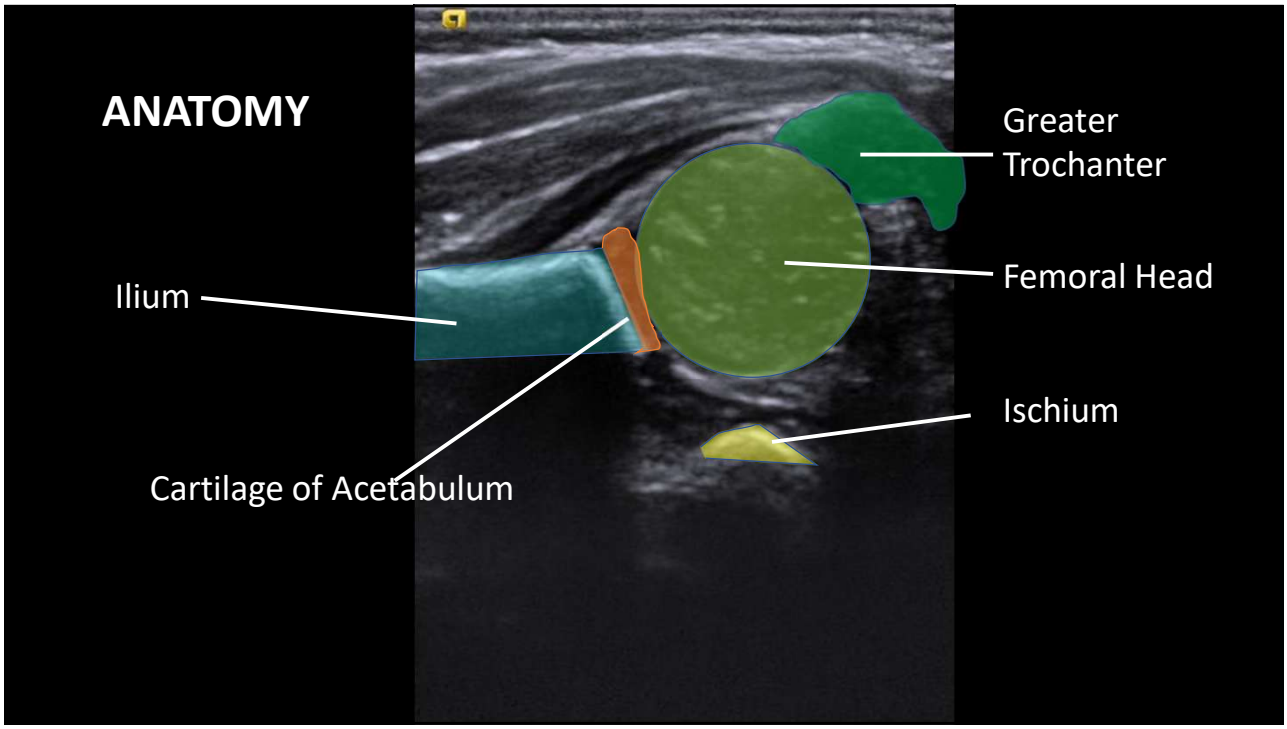

15

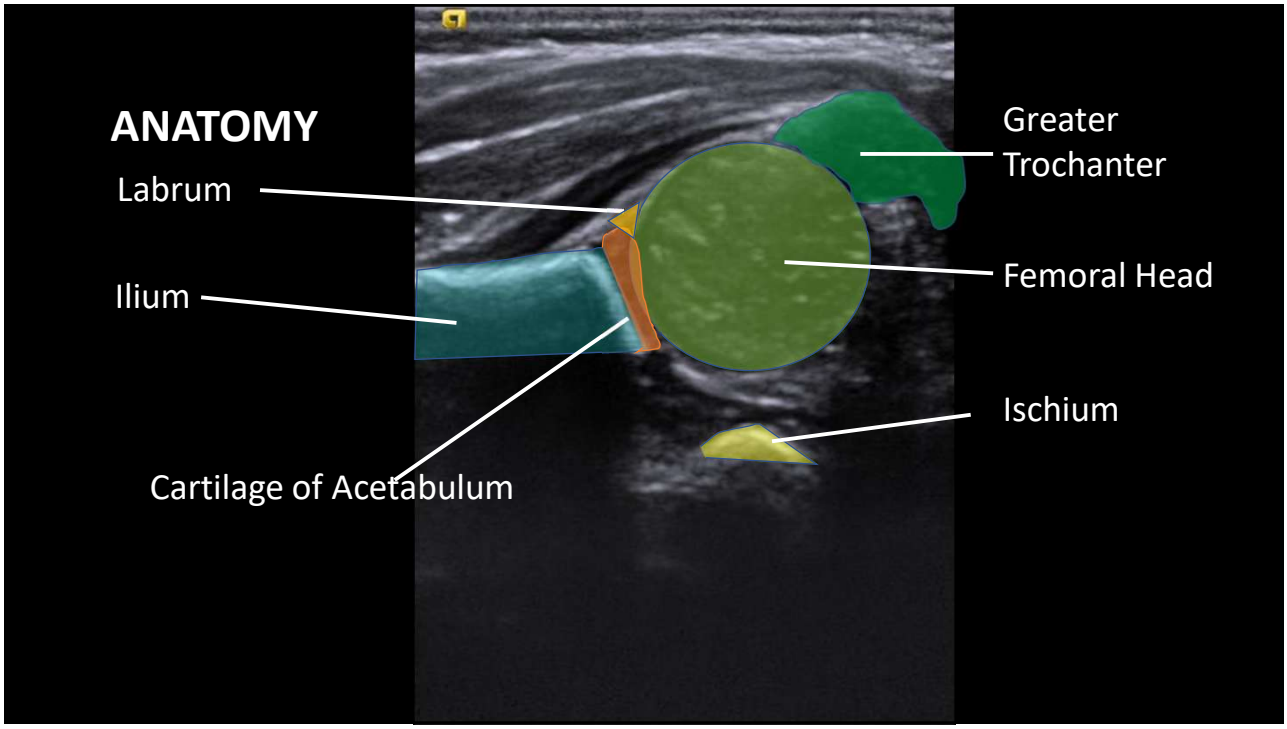

16

© Copyright. Society of Diagnostic Medical Sonography. All Rights Reserved.

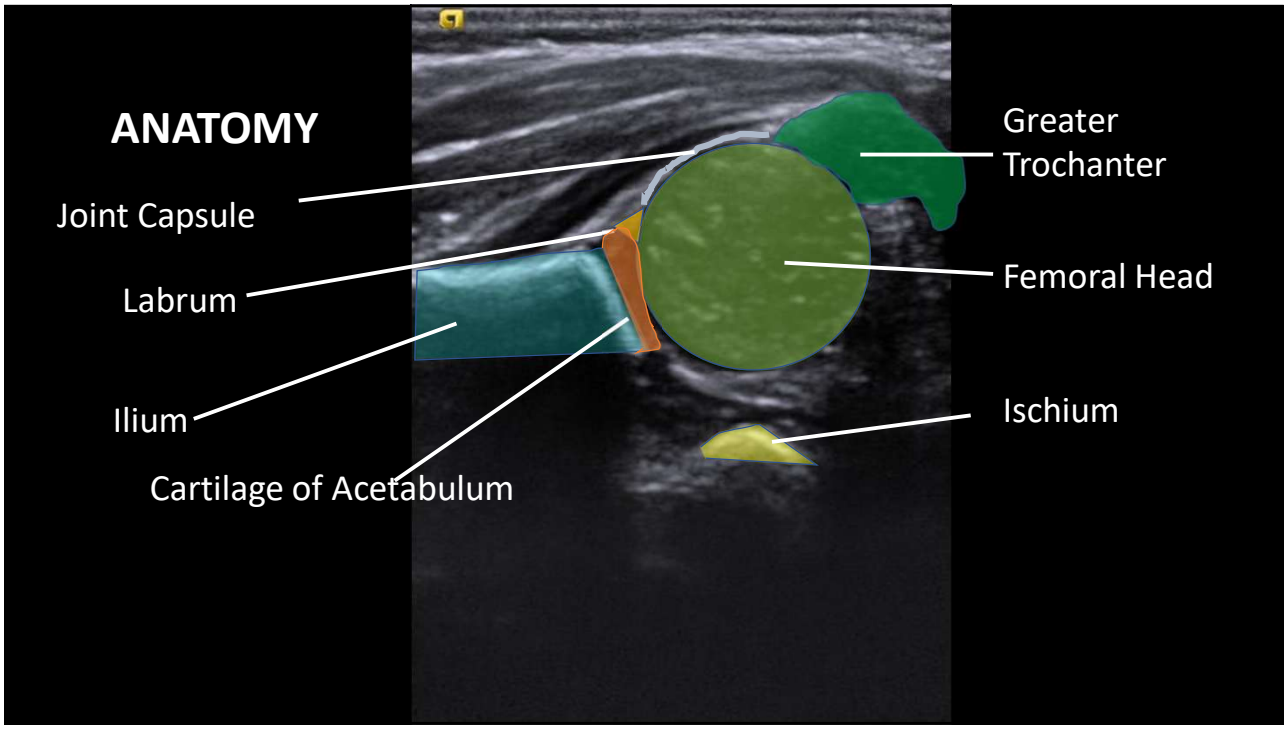

17

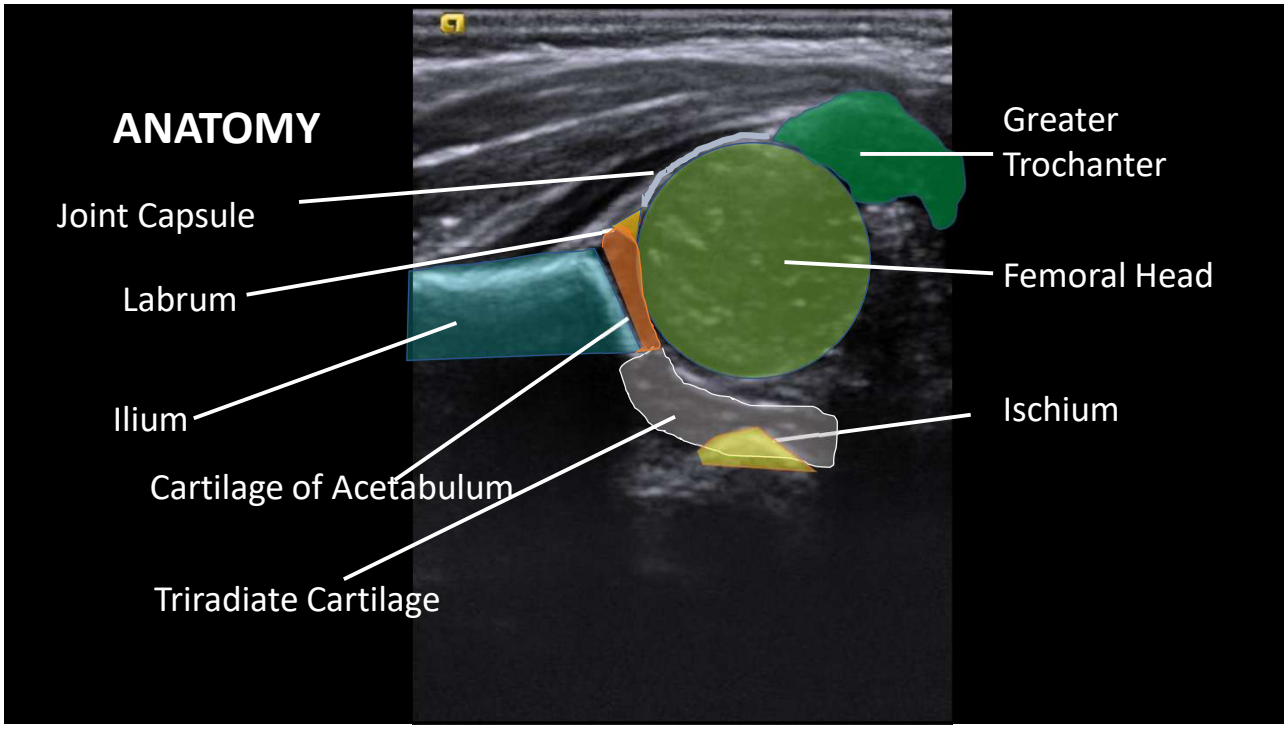

18

© Copyright. Society of Diagnostic Medical Sonography. All Rights Reserved.

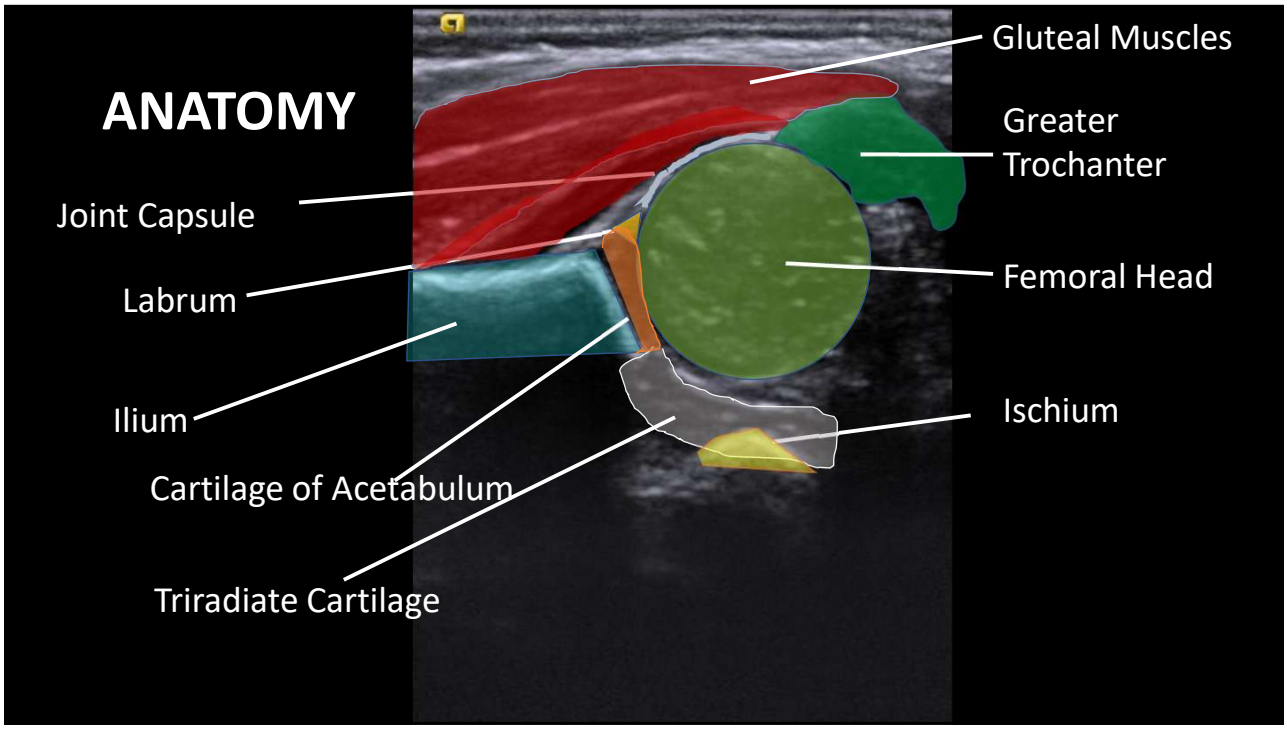

19

Acetabulum

- Large “socket” on the lateral portion of the pelvis that, together with the femoral head, makes up the hip joint
- Formed by the fusion of:
  - Ilium
  - Ischium
  - Pubis

20

© Copyright. Society of Diagnostic Medical Sonography. All Rights Reserved.

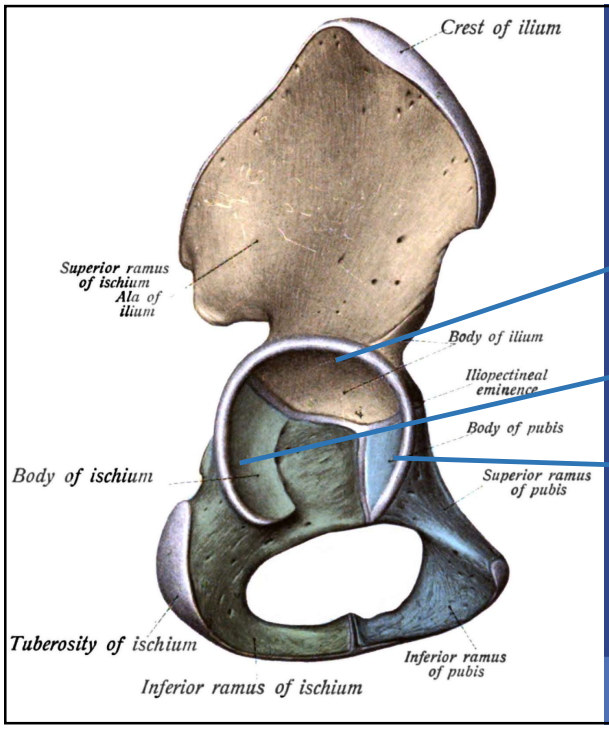

Acetabulum

Ilium

Ischium

Pubis

https://commons.wikimedia.org/wiki/File:Sobo_1909_136.png

21

ANATOMY

- Femoral head and acetabulum develop from mesenchymal cells
- 7 to 8 weeks gestation, a cleft develops
- Development is complete by 11 weeks gestation
- At birth, the femoral head and acetabulum are mostly cartilaginous

https://biomedres.us/fulltexts/BJSTR.MS.ID.002267.php

22

© Copyright. Society of Diagnostic Medical Sonography. All Rights Reserved.

The Infant Hip - Coronal Plane

- **Alpha angle:**
  - **Is the primary measure for hip dysplasia**
  - **>60 is normal**
- **Beta angle:**
  - **<55 is normal**

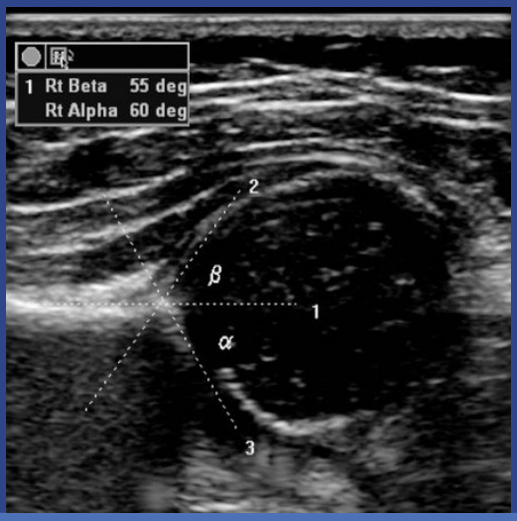

https://radiopaedia.org/articles/2727

23

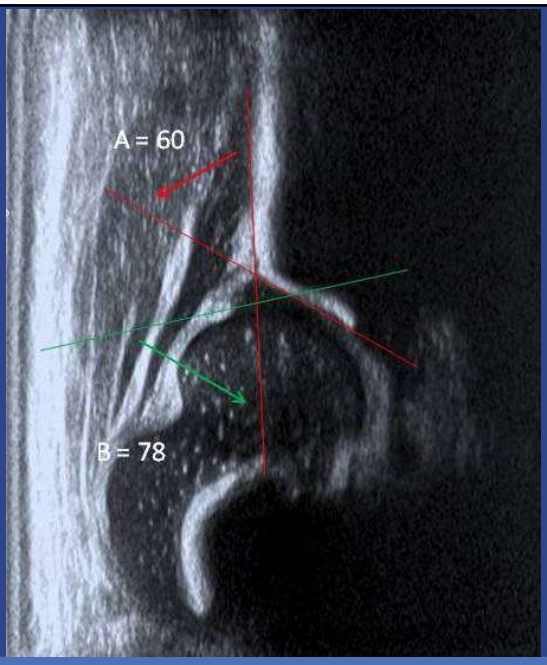

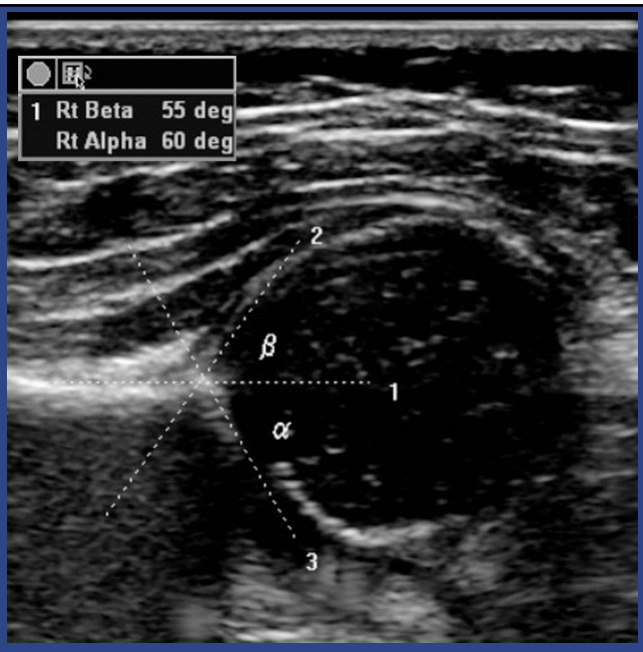

https://radiopaedia.org/articles/2724

24

© Copyright. Society of Diagnostic Medical Sonography. All Rights Reserved.

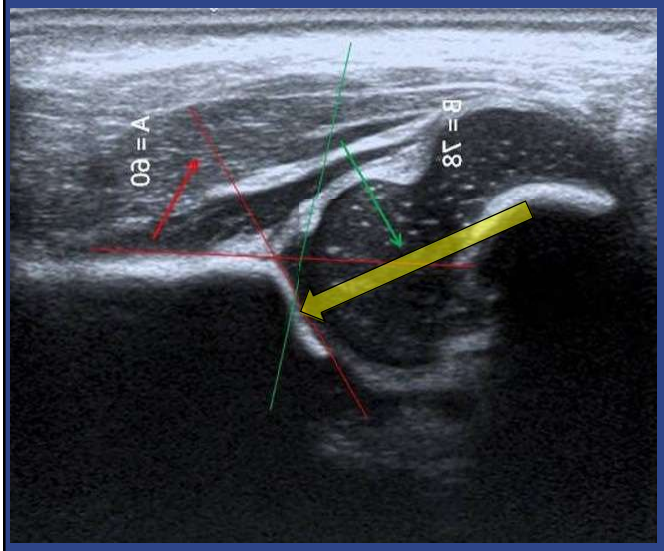

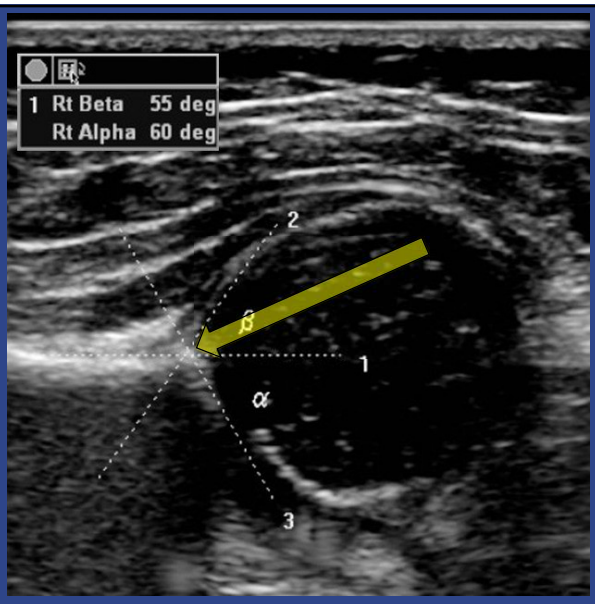

https://radiopaedia.org/articles/2724

25

Subluxation

- The femoral head is out of its normal location, but still keeps in contact with the acetabular cavity[6]

26

26

© Copyright. Society of Diagnostic Medical Sonography. All Rights Reserved.

Subluxation

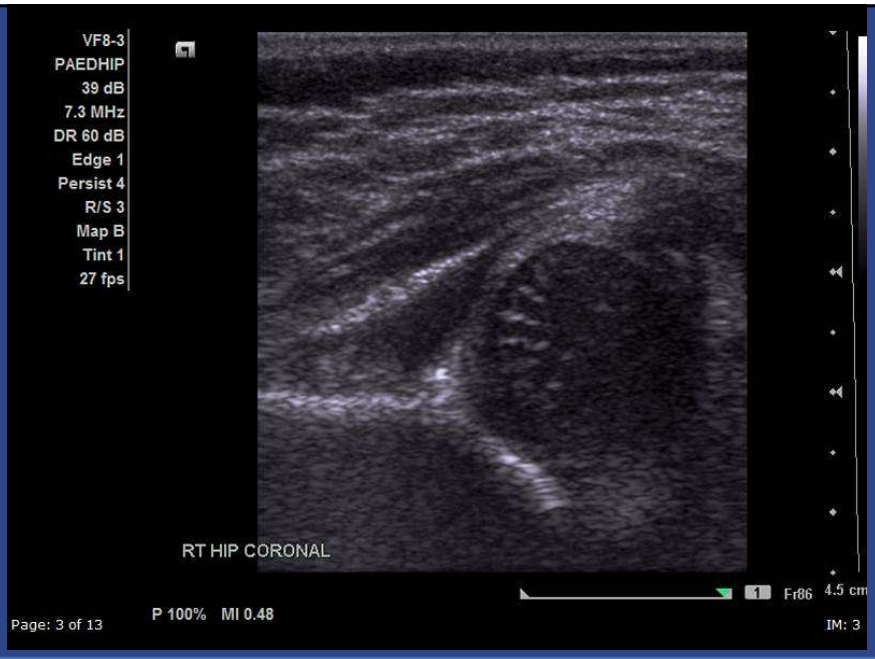

Gaillard F, Knipe H, Weerakkody Y, et al. Developmental dysplasia of the hip. Reference article, Radiopaedia.org (Accessed on 13 Mar 2026) https://doi.org/10.53347/rID-1214

27

27

Luxation (or dislocation)

- There is no contact between the femoral head and the acetabular cavity[6]

28

28

© Copyright. Society of Diagnostic Medical Sonography. All Rights Reserved.

Hip Dislocation



29

Femoral Head Coverage

- Calculate % coverage
  - ACR-50%

30

© Copyright. Society of Diagnostic Medical Sonography. All Rights Reserved.

Infant Hip Exam Review

Goal

- Institute appropriate treatment
- Ensure normal hip development
- To prevent long-term complications:
  - Leg length discrepancy
  - Gait abnormality
  - Pain
  - Osteoarthritis

31

Infant Hip Exam Review

- **Femoral head stability is described as:**
  - Normal
    - seated at rest, motion and stress
  - Lax
    - normal at rest, abnormal with movement
  - Subluxed
    - displaced laterally at rest or stress; but not dislocatable
  - Dislocated
    - can be returned to acetabulum with traction and abduction
  - Or irreducible

- % bony coverage of femoral head
- Alpha angle
- Acetabular Promontory (Roof):
  - angular/rounded/flat

32

© Copyright. Society of Diagnostic Medical Sonography. All Rights Reserved.

Barlow Test or maneuver

- **Determines if the hip can be dislocated**

Hip is flexed and thigh **adducted** (toward the midline)

- A gentle push posterior with outward pressure can dislocate the hip
- A palpable clunk is felt when the femoral head exits the acetabulum posteriorly

33

Ortolani Test or maneuver

- **Determines if the hip can be reduced**
- When the hip is **abducted**, a vibration or clunk is felt when the femoral head reduces into the acetabulum

34

© Copyright. Society of Diagnostic Medical Sonography. All Rights Reserved.

IMAGING OF THE INFANT HIP

- ***Sonography is the modality of choice in the infant!***
  - Less than 6 months old
- Plain AP radiograph may be indicated in infants greater than 6 months

35

Patient Prep

- No specific prep, BUT….
- Keep the baby warm
- Have the baby fed right before the exam, or during the exam
- Coupling gel should be at body temp

36

© Copyright. Society of Diagnostic Medical Sonography. All Rights Reserved.

Transducer

- High frequency linear transducer- 7.5 to 18 MHz
  - High enough for image detail
  - Low enough for penetration

37

Patient Position

- Supine or slight decubitus position

38

© Copyright. Society of Diagnostic Medical Sonography. All Rights Reserved.

Technical Considerations

- The exam should not be performed on patients younger than 6 weeks of age
  - If the patient is a preemie, gestational corrected age should be used
  - It may be appropriate to scan a baby prior to 6 weeks if the physician is concerned about hip dislocation
- Examining patients older than 6 months of age may be limited by ossification of the femoral head
  - Radiography is usually preferred in the older patient

39

Technique

- With the patient positioned with the head located toward the head of the bed…
  - It may be easier to **scan the right hip** with the transducer in your **left hand**, while stabilizing the leg with your right hand
  - While **scanning the left hip**, it will be easier to scan with the transducer in your **right hand**, while stabilizing the leg with your left hand

40

© Copyright. Society of Diagnostic Medical Sonography. All Rights Reserved.

RISK FACTORS

- Female (F:M 8:1)
- Breech presentation
- Family history of DDH
- Neuromuscular conditions
- Firstborn baby
- Oligohydramnios
- Improper swaddling

41



OK



NOT OK

42

© Copyright. Society of Diagnostic Medical Sonography. All Rights Reserved.

RISK FACTORS

- **Female** (F:M 8:1)
- **Breech presentation**
- **Family history of DDH**
- Neuromuscular conditions
- Firstborn baby
- Oligohydramnios
- Improper swaddling

43

VISUAL ASSESSMENT

- Uneven gluteal folds, high thigh folds, shortening of the thigh or redundant thigh folds on the affected leg
- Positive Allis or Galezzi sign (relative shortness of the femur when knees are flexed)

44

44

© Copyright. Society of Diagnostic Medical Sonography. All Rights Reserved.

INDICATIONS

- Any of the above risk factors listed above
- Abnormal or equivocal findings of hip instability on physical exam of the hip

45

USEFUL TOOL FOR REFERRING PHYSICIANS

- DDH orthoguidelines
  https://www.orthoguidelines.org/go/auc/default.cfm?auc_id=225001&actionxm=Terms

46

© Copyright. Society of Diagnostic Medical Sonography. All Rights Reserved.

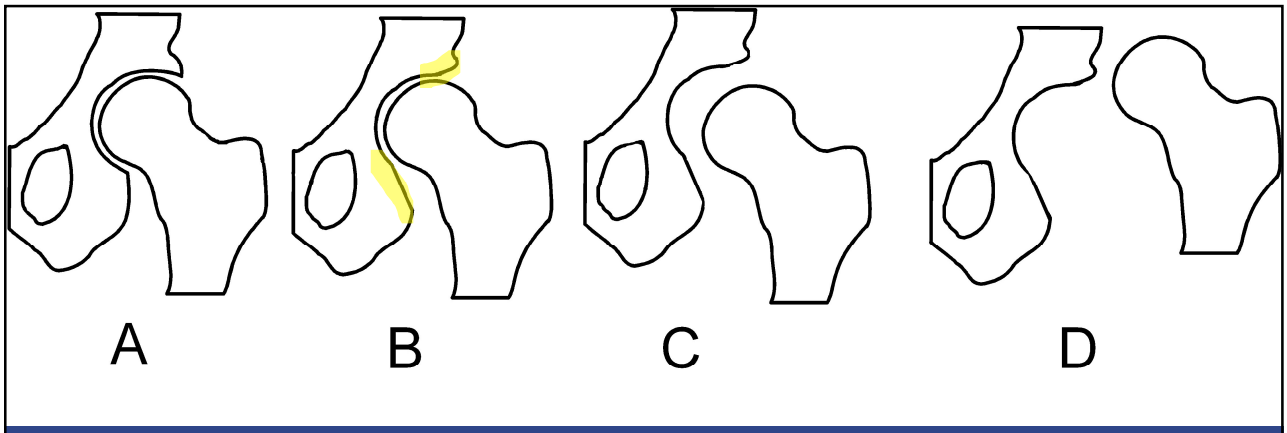

https://en.wikipedia.org/wiki/Hip_dysplasia - Accessed 4/26/23

47

AIUM-ACR-SPR-SRU Exam Guidelines

- Usually performed on patients of at least 6 weeks of age and less than 6 months of age
- Both hips should be examined
- Image in two planes, coronal and transverse (axial)
  - Coronal plane- measure alpha angle, measure coverage (optional), stress in this plane is optional
  - Axial plane- image at rest with gentle abduction and adduction, evaluate with stress maneuver
- Stress maneuver should be performed unless contraindicated (pt. in a Pavlik harness or splint device)

https://www.acr.org/-/media/ACR/Files/Practice-Parameters/us-hip-dys.pdf

48

© Copyright. Society of Diagnostic Medical Sonography. All Rights Reserved.

PROTOCOL

- Review previous exams, if available
- Introduce self to patient and parent/guardian
- Verify patient identity
- Obtain pertinent history and reason for the exam

49

PROTOCOL

- Image in the coronal plane (neutral or flexed position)



50

© Copyright. Society of Diagnostic Medical Sonography. All Rights Reserved.

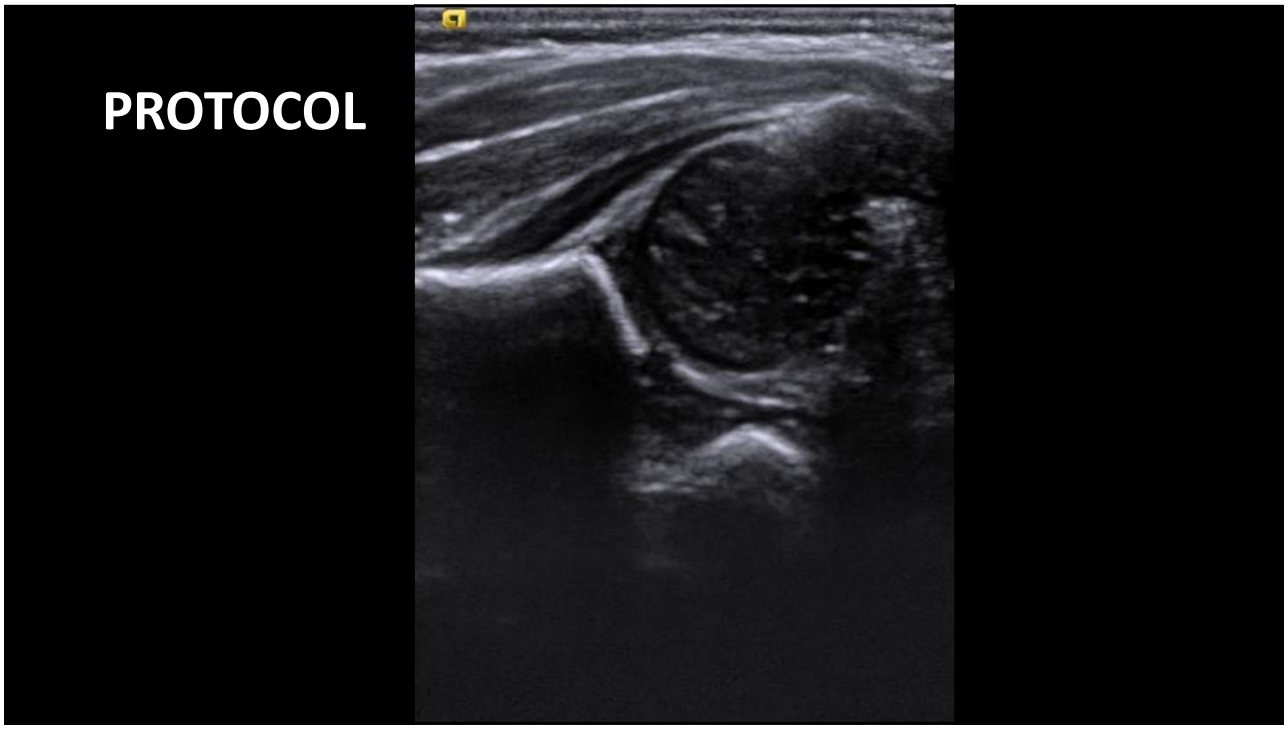

51

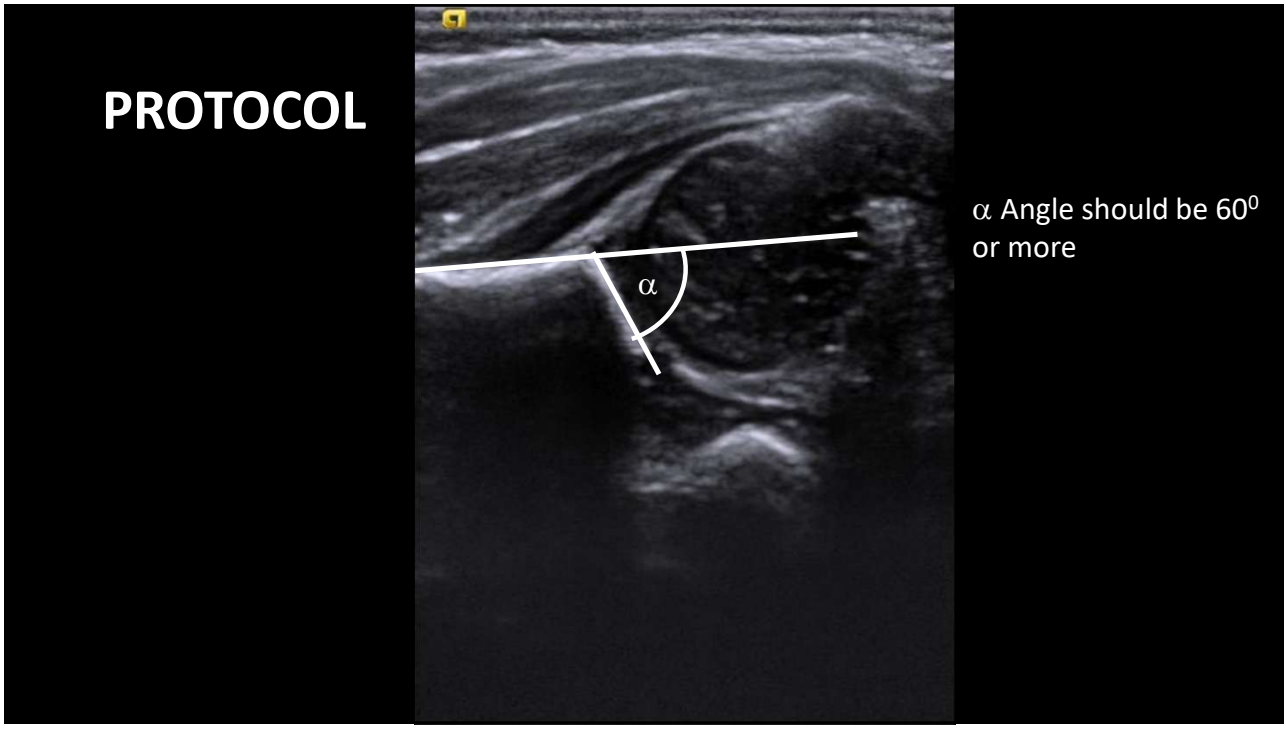

52

© Copyright. Society of Diagnostic Medical Sonography. All Rights Reserved.

PROTOCOL

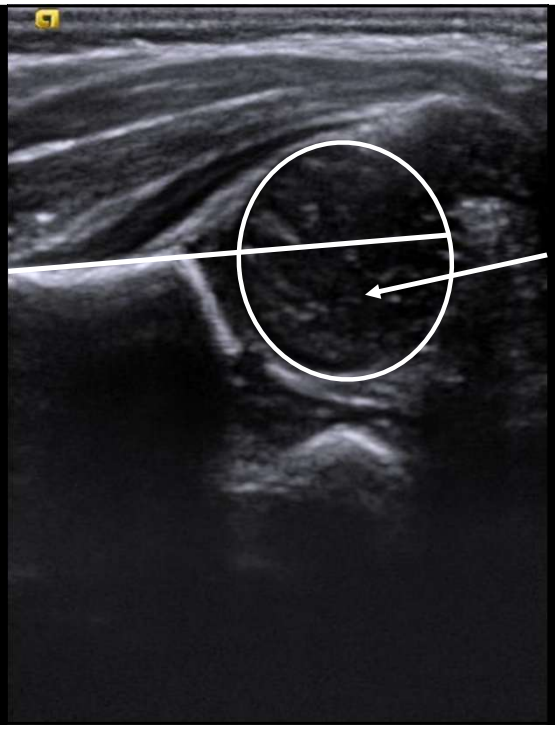

Coverage should be 50% or more (AAOS-American Academy of Orthopedic Surgeons uses greater than 45%)

53

PROTOCOL

TRANSVERSE IMAGE / FLEXION POSITION

- Image in the transverse or axial plane (flexed position)



54

© Copyright. Society of Diagnostic Medical Sonography. All Rights Reserved.

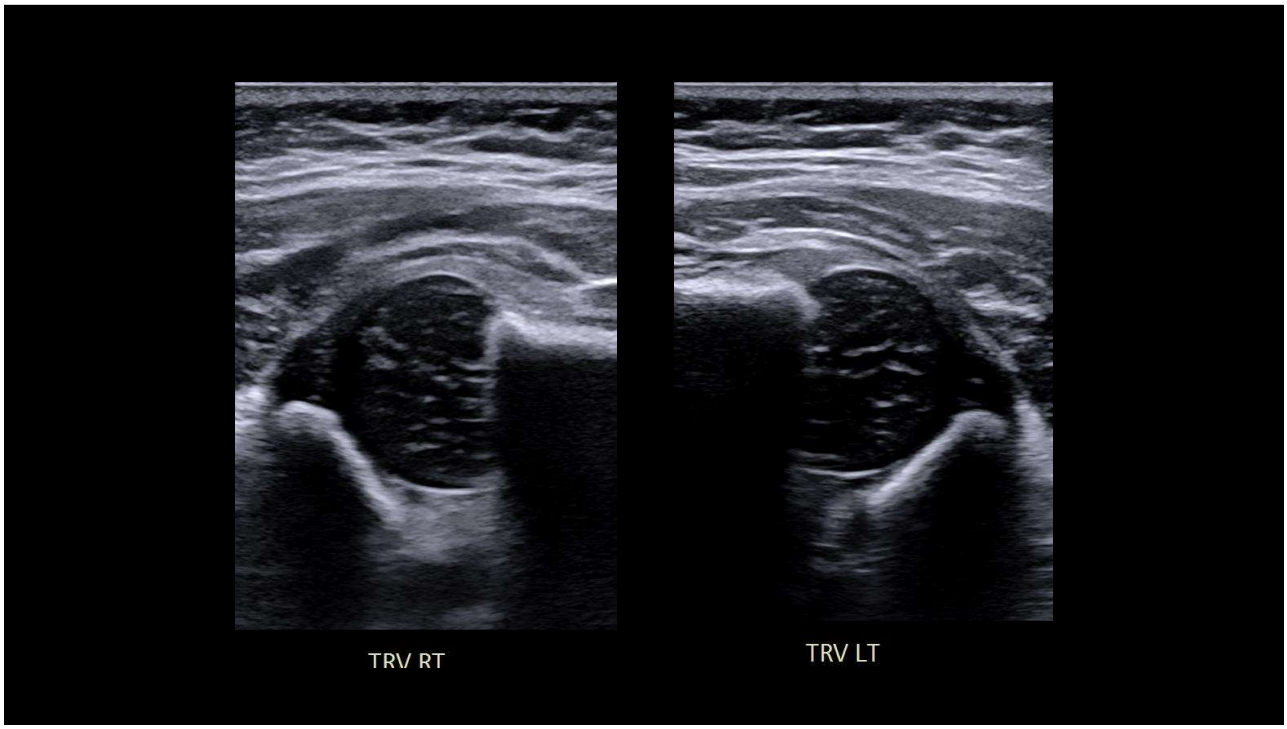

55

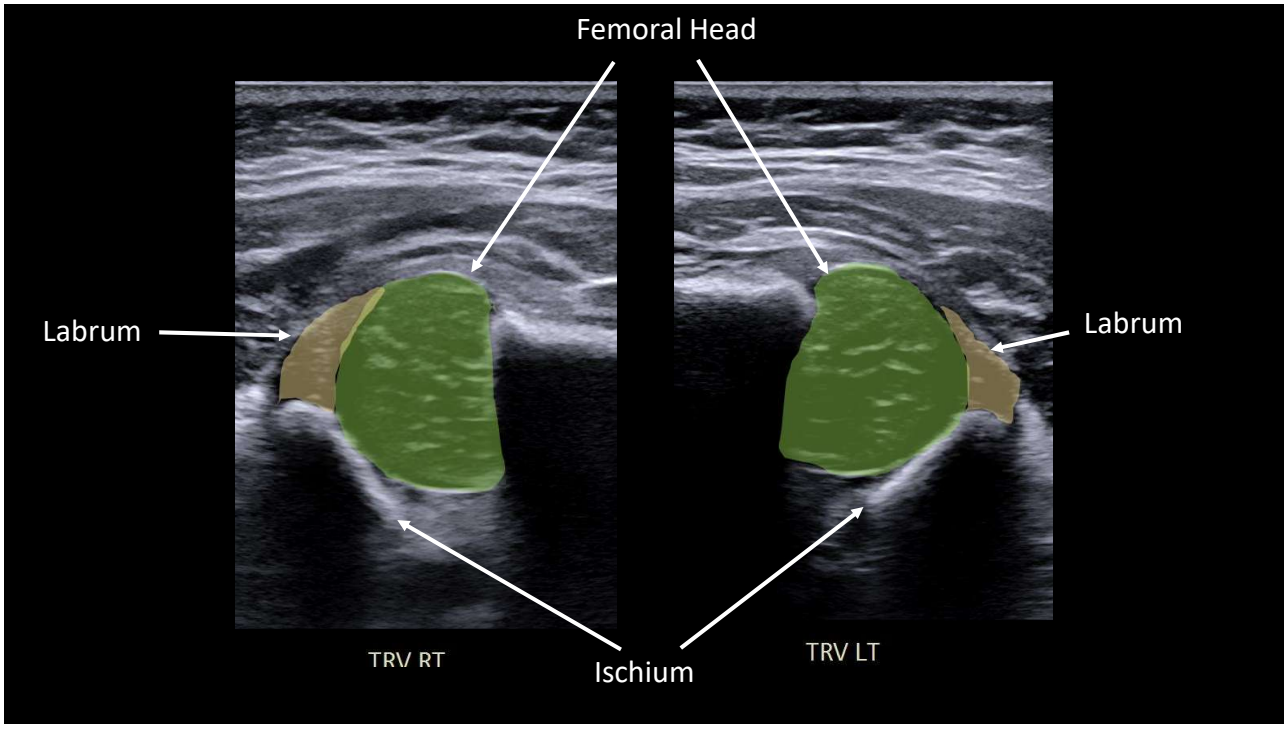

56

© Copyright. Society of Diagnostic Medical Sonography. All Rights Reserved.

PROTOCOL

- Stress maneuvers should also be performed bilaterally, unless contraindicated
- In the coronal plane

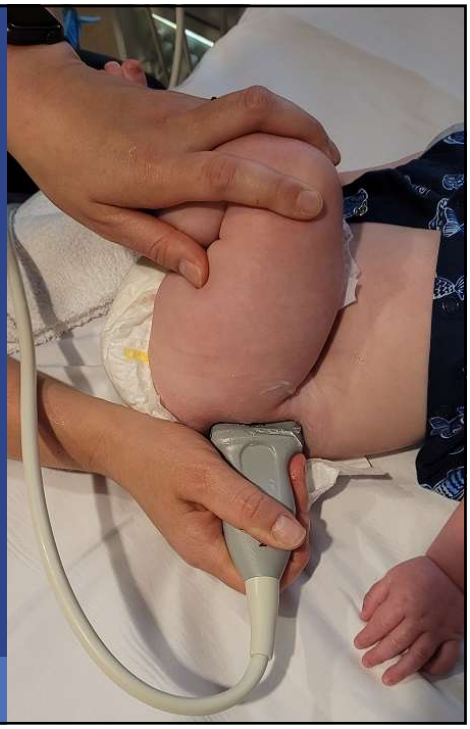

57

PROTOCOL

- Stress maneuvers should also be performed bilaterally, unless contraindicated
- In the axial plane



58

© Copyright. Society of Diagnostic Medical Sonography. All Rights Reserved.

PROTOCOL

- Additional measurements that may be helpful
  - AFD- Acetabular Fossa Distance (normal is <6mm)
  - PT- Pulvinar Thickness (normal is <4.2mm)[5]
  - CT- Cartilage Thickness (normal is <2.4mm to 3.5mm)[5]

59

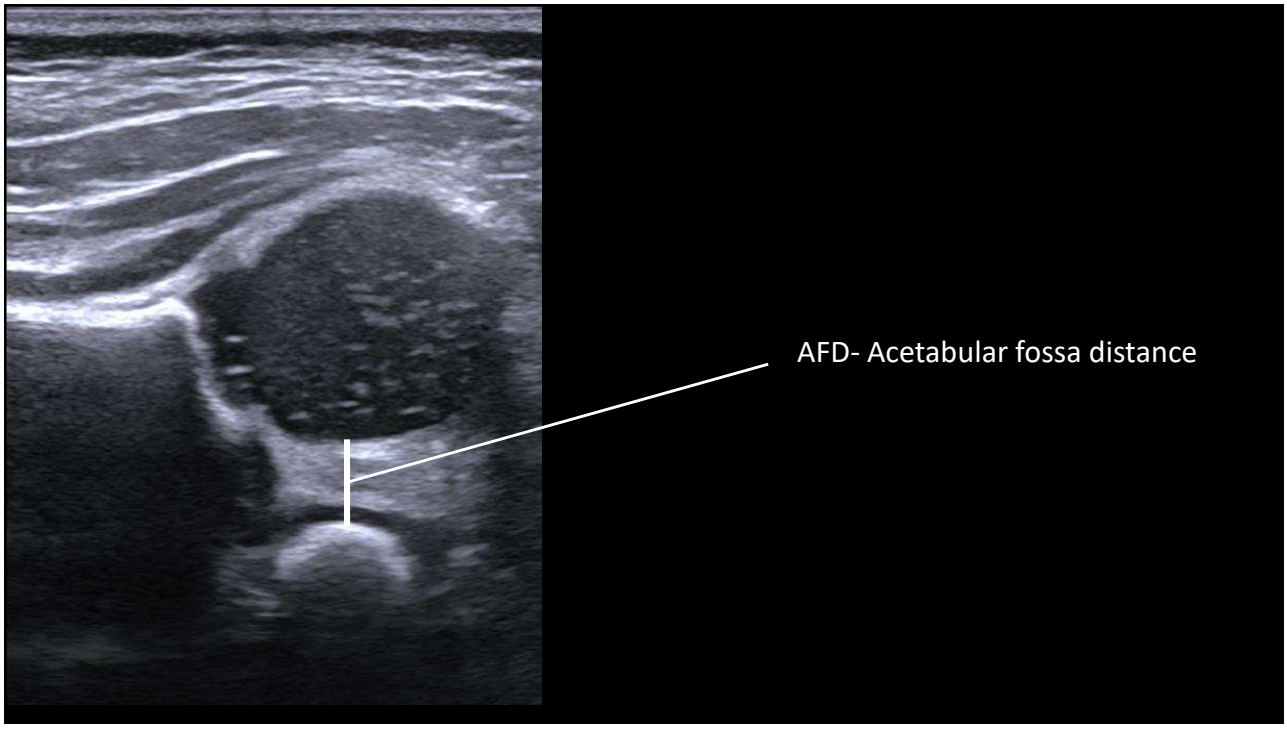

60

© Copyright. Society of Diagnostic Medical Sonography. All Rights Reserved.

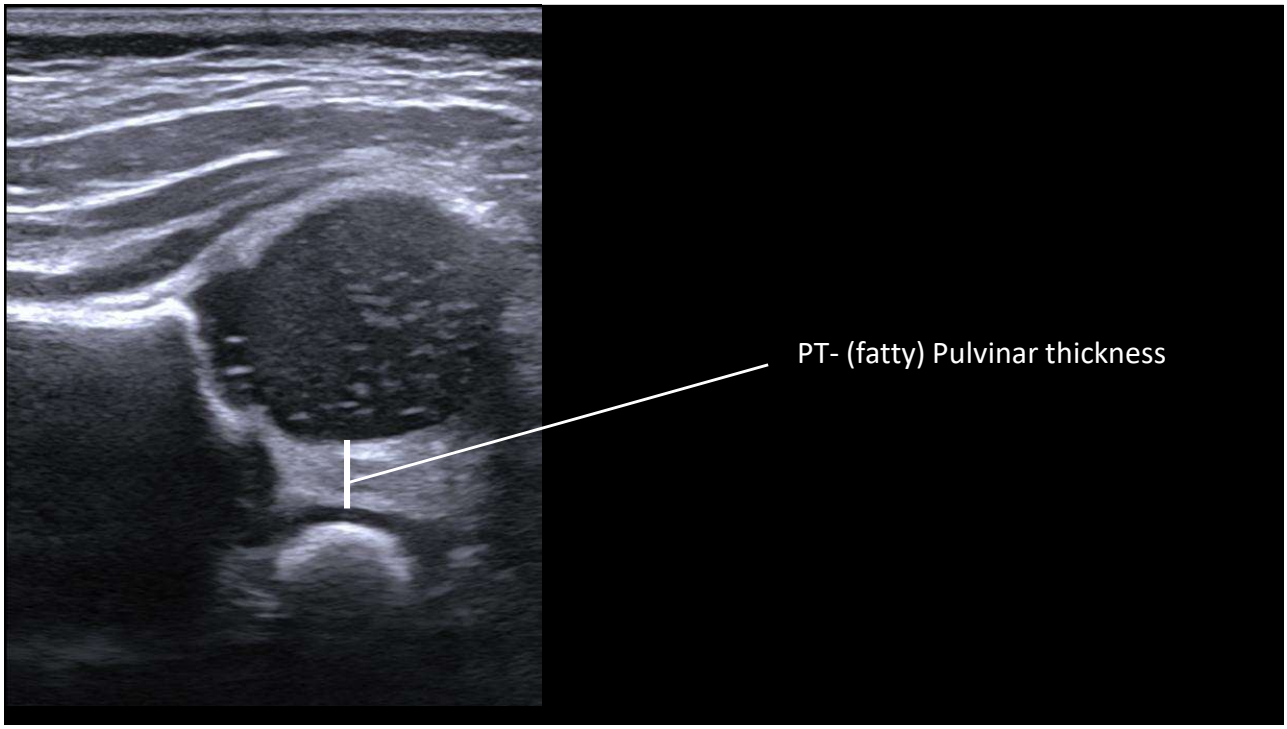

61

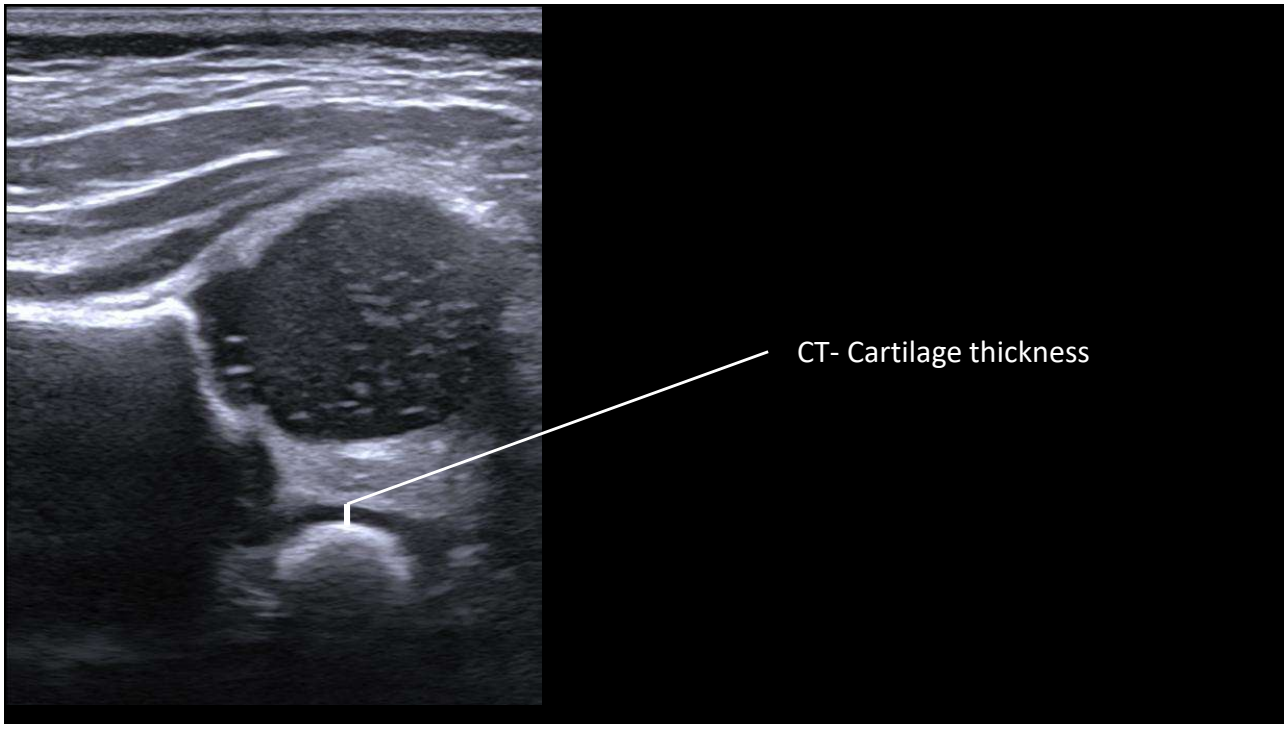

62

© Copyright. Society of Diagnostic Medical Sonography. All Rights Reserved.

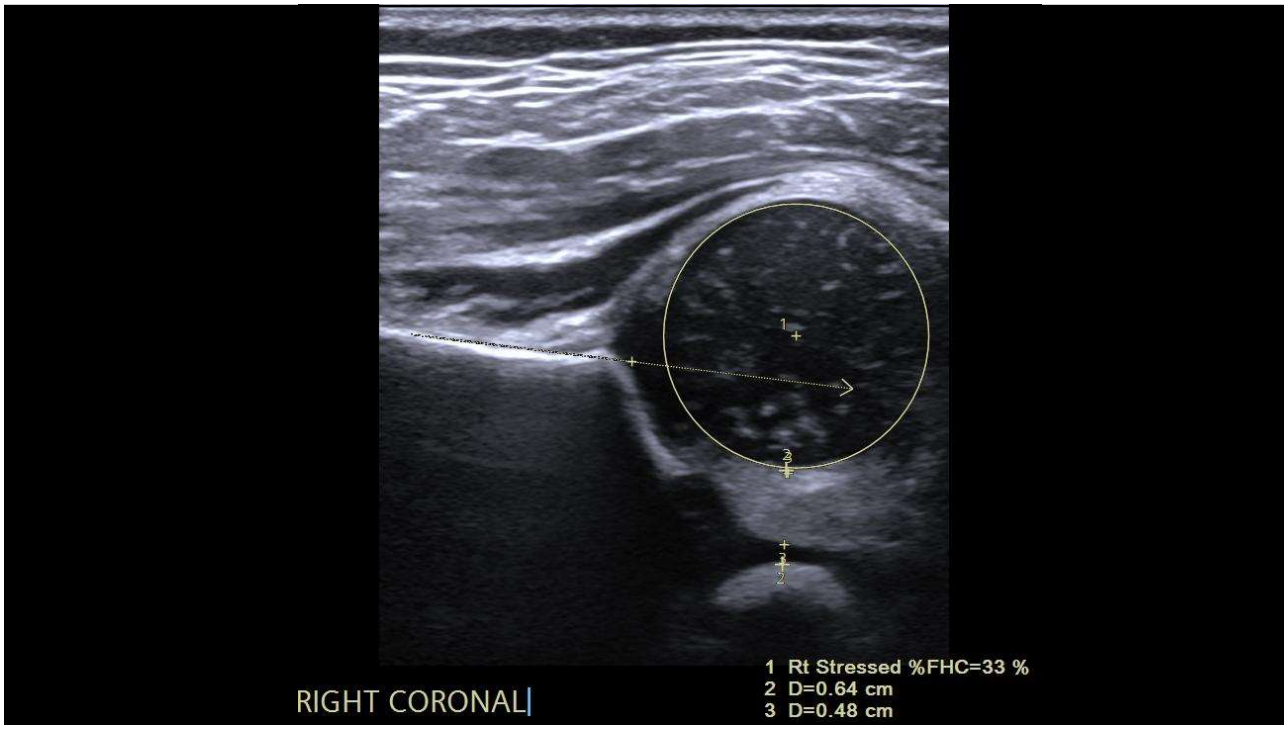

63

Sample Worksheet

Elliot Hospital
Ultrasound Findings

RT Hip	Lt Hip
Non Stressed α Angle: _____	Non Stressed α Angle: _____
% Coverage: _____	% Coverage: _____
Accetabular Fossa Measurement _____ mm	Accetabular Fossa Measurement _____ mm
Stressed Yes / No Subluxation with Stress Yes / No	Stressed Yes / No Subluxation with Stress Yes / No
Accetabular Fossa Measurement Stressed: _____ mm	Accetabular Fossa Measurement Stressed: _____ mm
Prominent Pulvinar Yes / No	Prominent Pulvinar Yes / No

Comments :

64

© Copyright. Society of Diagnostic Medical Sonography. All Rights Reserved.

TREATMENTS FOR DDH

- Pavlik harness
- Closed reduction
- Open reduction
- Surgical Repairs

*NOTE- Double diapering is no longer seen as an appropriate treatment

65



https://www.flickr.com/photos/30908884@N00/207498765 -accessed 6/7/23

66

© Copyright. Society of Diagnostic Medical Sonography. All Rights Reserved.

PAVLIK HARNESS

- Pavlik harness may be used to treat DDH in young infants (less than 6 months old)

67

Pavlik harness



https://upload.wikimedia.org/wikipedia/commons/thumb/2/22/Pavlik.svg/1842px-Pavlik.svg.png - accessed 3/21/2023

68

© Copyright. Society of Diagnostic Medical Sonography. All Rights Reserved.

CLOSED REDUCTION

- Closed reduction may be necessary in older children (usually between 6 and 24 months) that have a hip dislocation
- Done under general anesthesia
- After reduction, a spica cast is applied

69

OPEN REDUCTION

- Open reduction may be necessary in older patients, or if closed reduction is unsuccessful
- After surgical reduction, a spica cast is applied

70

© Copyright. Society of Diagnostic Medical Sonography. All Rights Reserved.



https://commons.wikimedia.org/wiki/File:Hip_Spica_Casts.png –accessed 6/7/23

71

SURGICAL OPTIONS

- Pelvic Osteotomy
- Periacetabular osteotomy (PAO)

72

© Copyright. Society of Diagnostic Medical Sonography. All Rights Reserved.

Pelvic Osteotomy

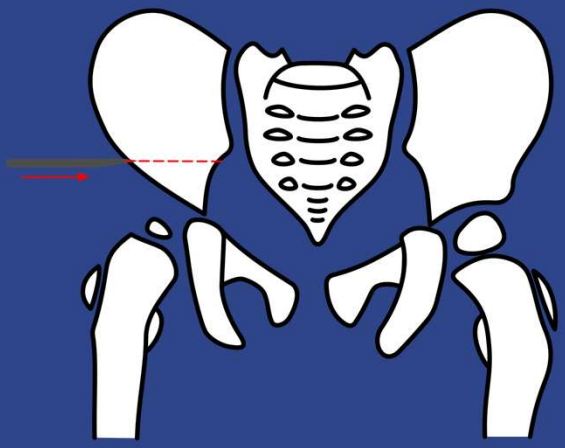

https://commons.wikimedia.org/wiki/File:Salter-Osteotomie-Schritt1.svg – accessed 3/21/2023

73

Pelvic Osteotomy

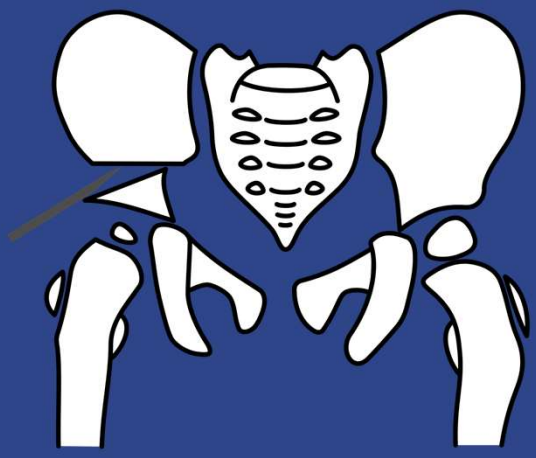

https://commons.wikimedia.org/wiki/File:Salter-Osteotomie-Schritt2.svg – accessed 3/21/2023

74

© Copyright. Society of Diagnostic Medical Sonography. All Rights Reserved.

Pelvic Osteotomy

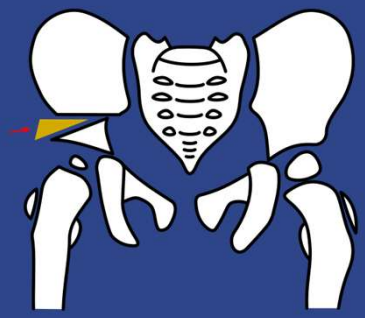

https://commons.wikimedia.org/wiki/File:Salter-Osteotomie-Schritt3.svg – accessed 3/21/2023

75

Pelvic Osteotomy

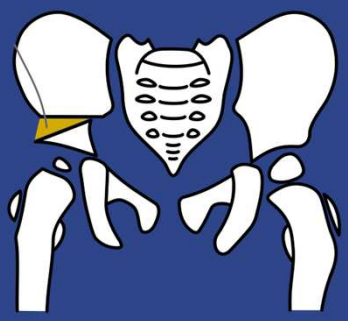

https://commons.wikimedia.org/wiki/File:Salter-Osteotomie-Schritt4.svg – accessed 3/21/2023

76

© Copyright. Society of Diagnostic Medical Sonography. All Rights Reserved.

Periacetabular osteotomy (PAO)

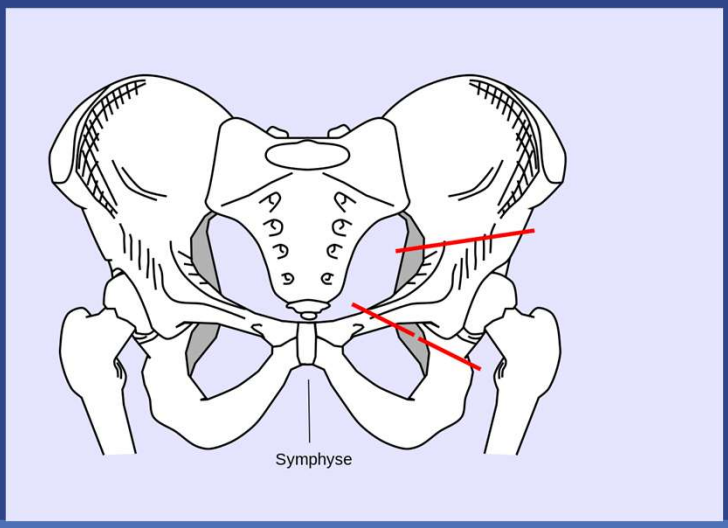

https://commons.wikimedia.org/wiki/File:Pelvis_Triple-Osteotomie.svg

77

Periacetabular osteotomy (PAO)

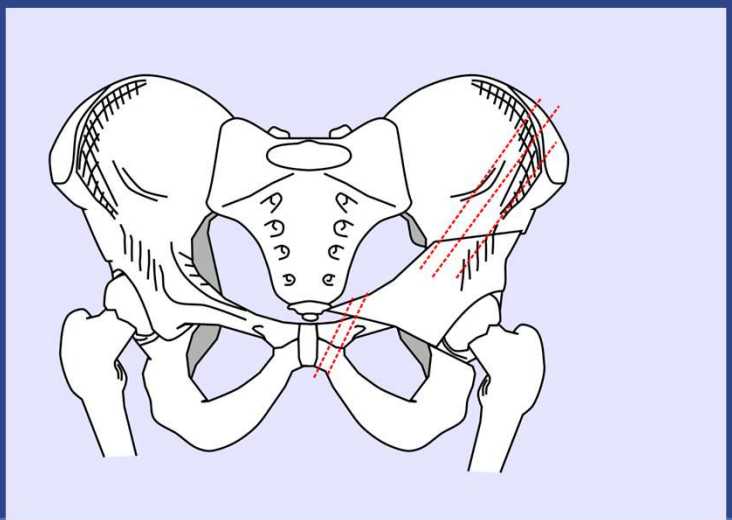

https://commons.wikimedia.org/wiki/File:Pelvis_Triple-Osteotomie-Operation.svg

78

© Copyright. Society of Diagnostic Medical Sonography. All Rights Reserved.

Periacetabular osteotomy (PAO)



https://commons.wikimedia.org/wiki/File:T%C3%B6nnis-TPO.jpg

79

Periacetabular osteotomy (PAO)





Triple osteotomy – Wikipedia – Accessed 4/26/23

80

© Copyright. Society of Diagnostic Medical Sonography. All Rights Reserved.

CASE STUDY

- A 5 week old infant presents to the sonography department with a right anterolateral neck mass
  - It feels hard
  - Extends to the scalp
  - Does not appear to be painful when palpated

81

INTERESTING CASE STUDY



82

© Copyright. Society of Diagnostic Medical Sonography. All Rights Reserved.

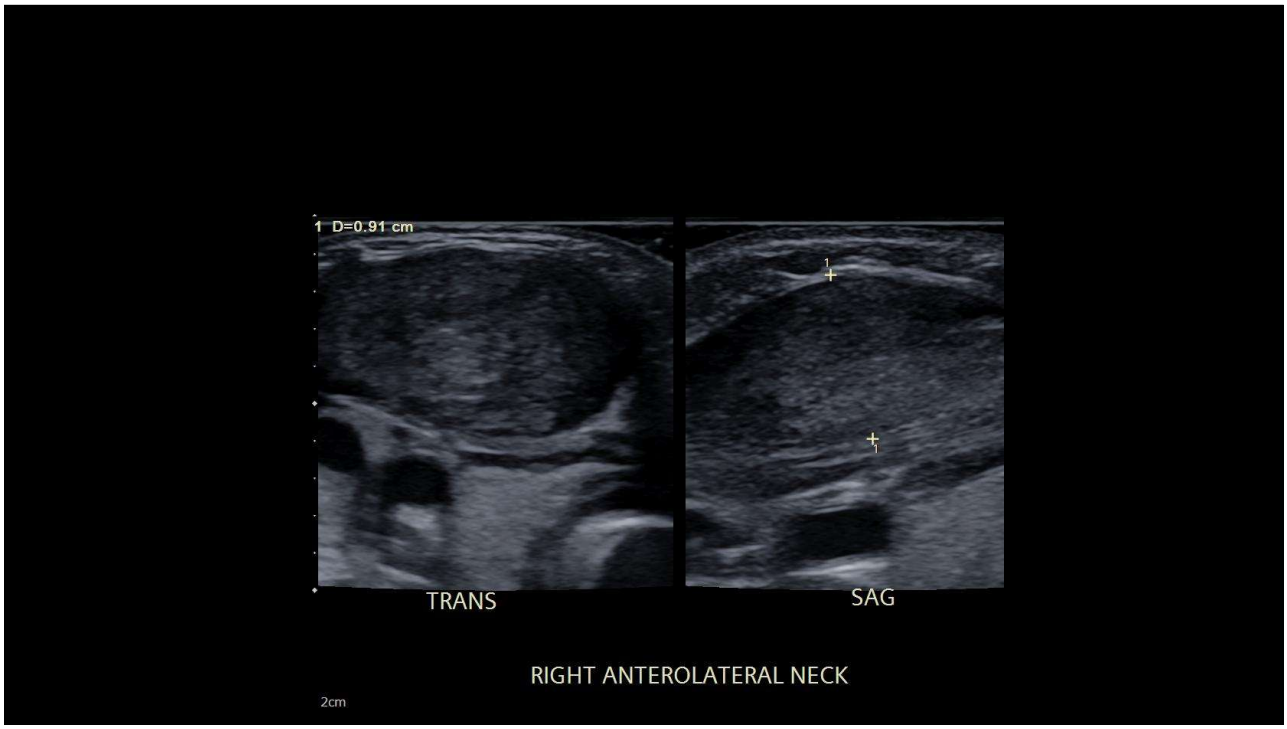

83

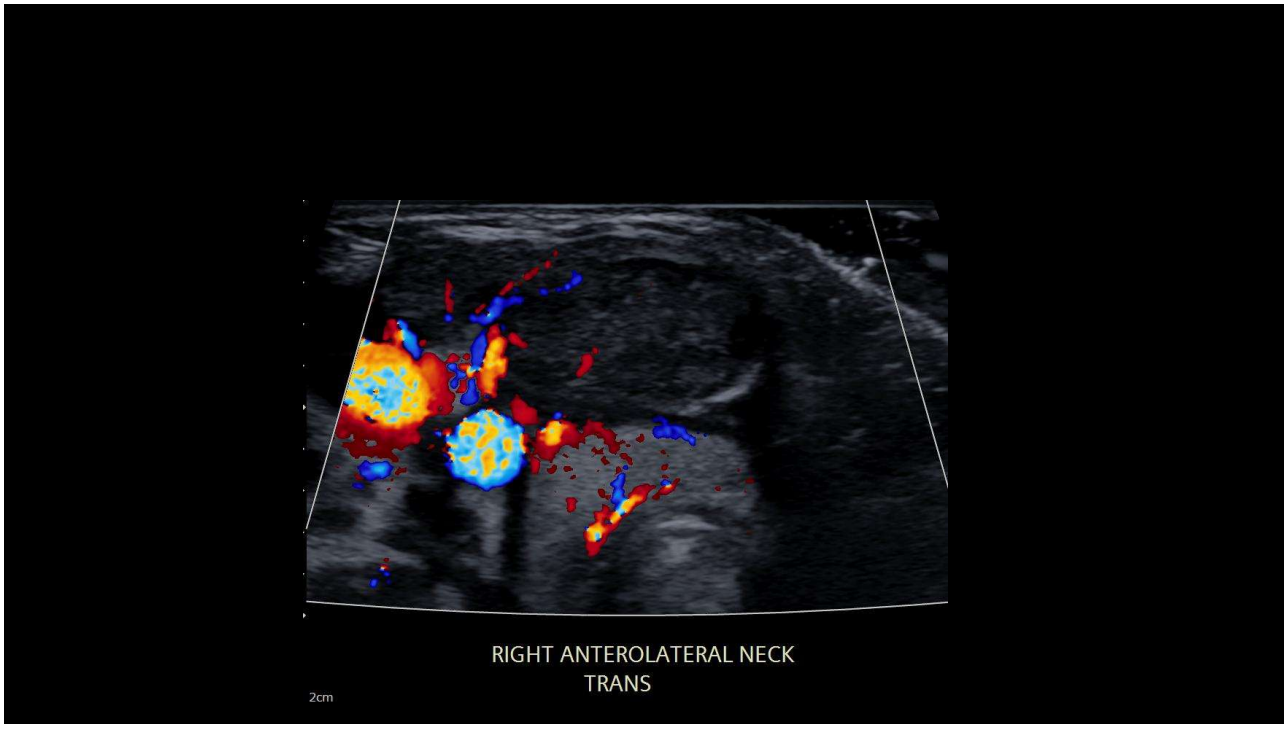

84

© Copyright. Society of Diagnostic Medical Sonography. All Rights Reserved.

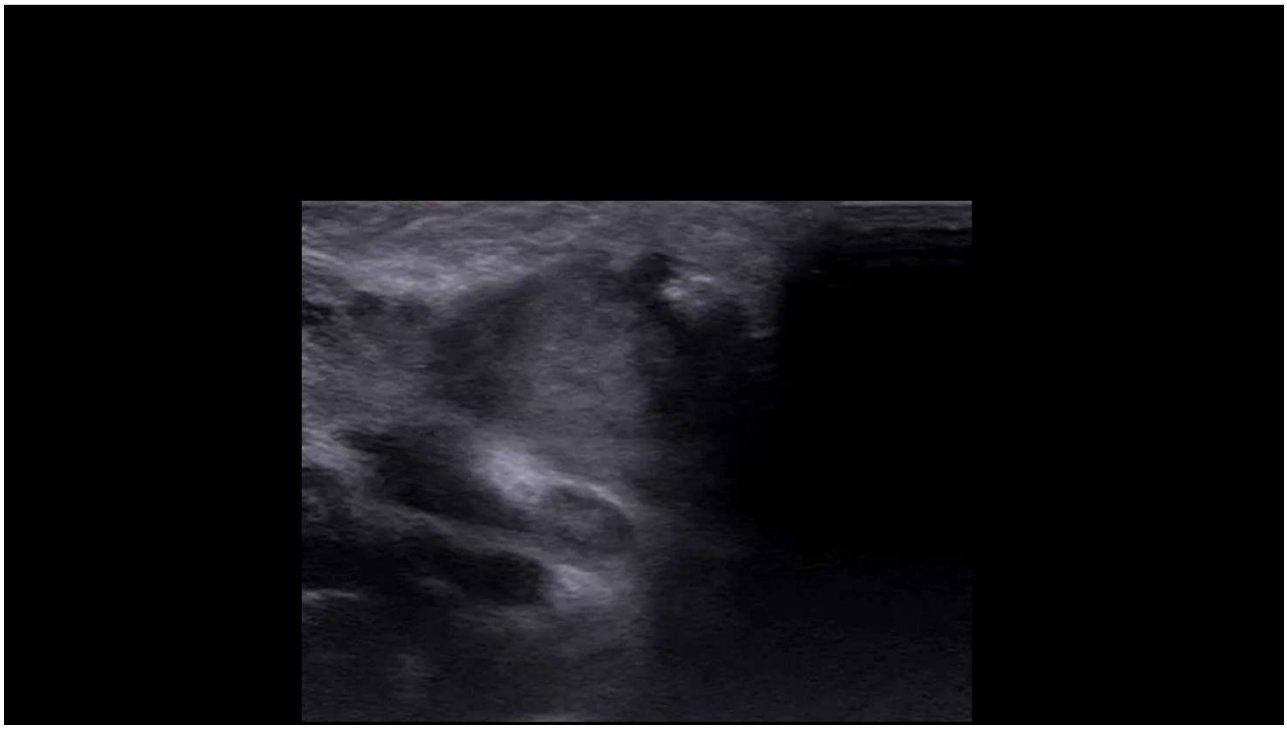

85

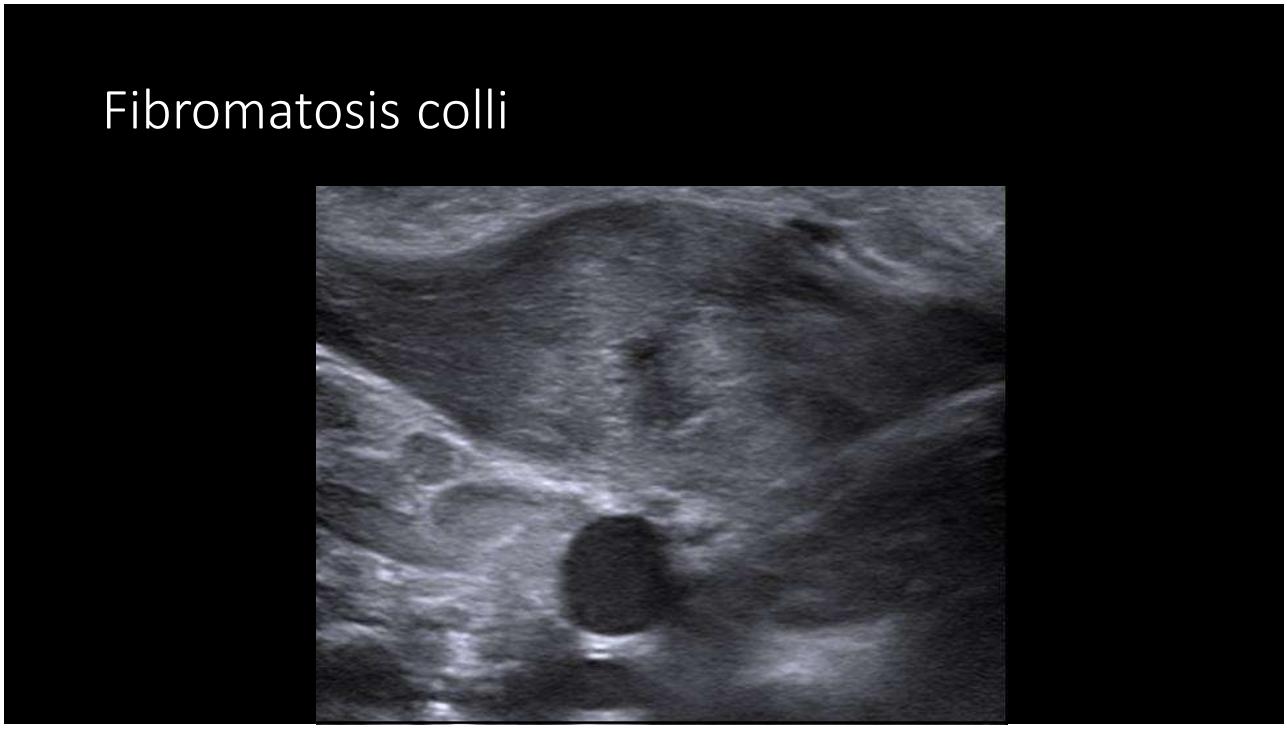

86

© Copyright. Society of Diagnostic Medical Sonography. All Rights Reserved.

A month later, the same patient comes back for a left hip “clunk”

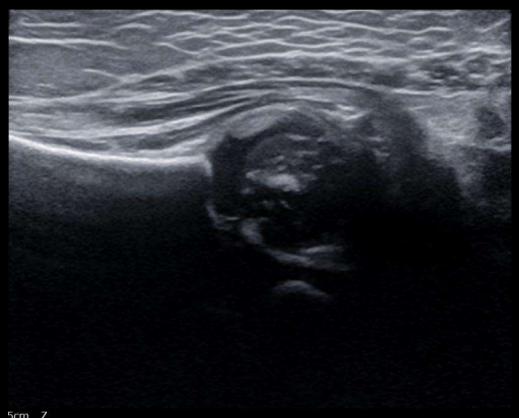

87



88

© Copyright. Society of Diagnostic Medical Sonography. All Rights Reserved.

2026 SDMS Annual Conference

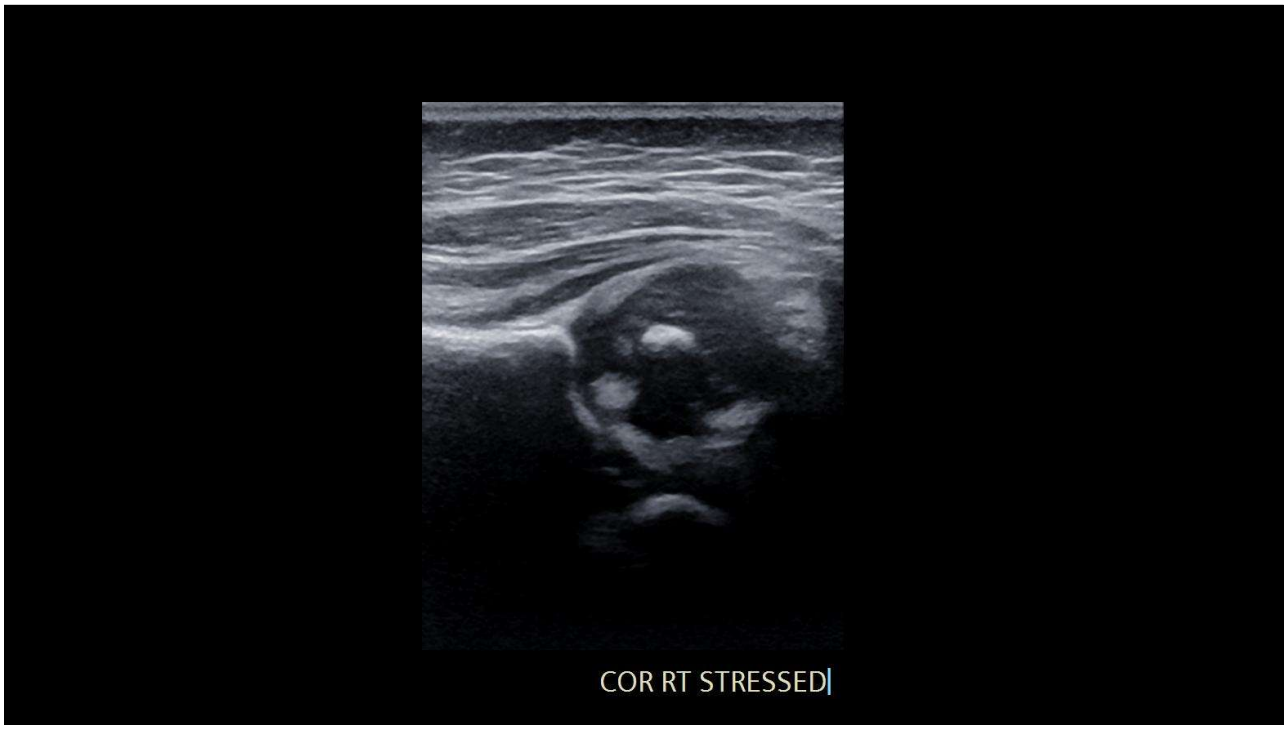

89

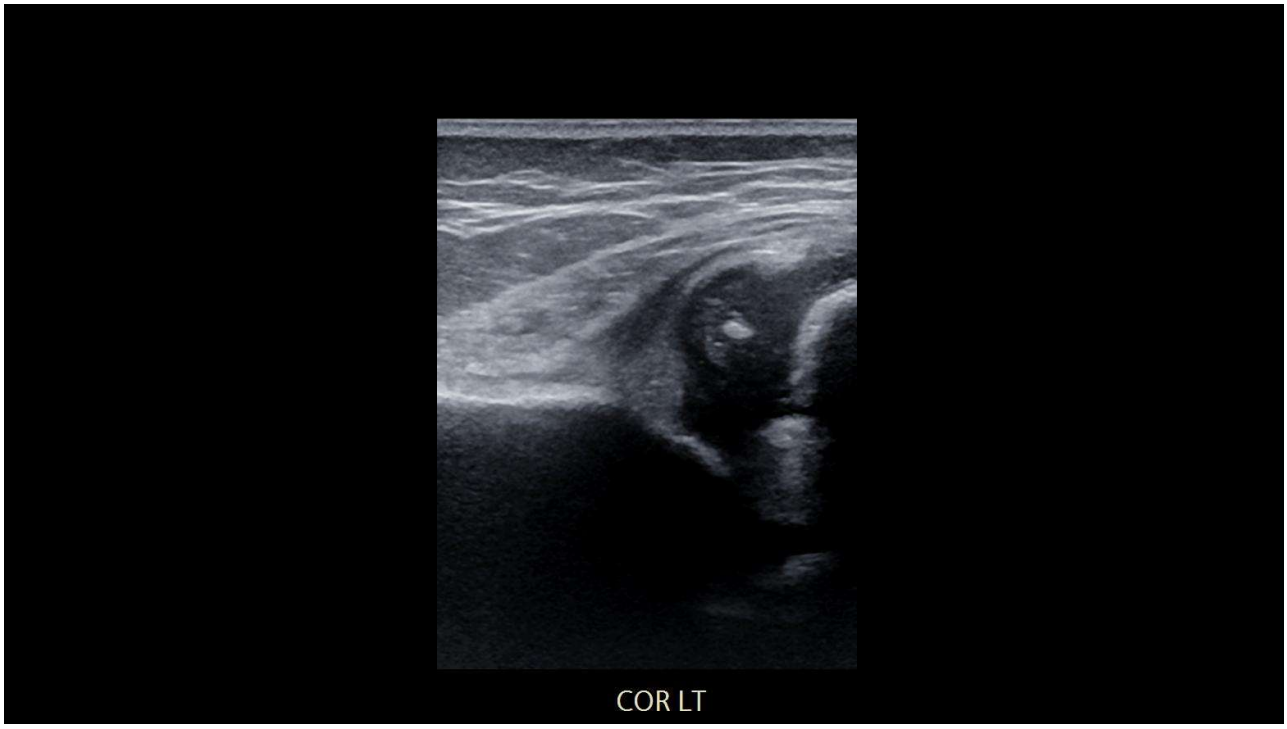

90

© Copyright. Society of Diagnostic Medical Sonography. All Rights Reserved.

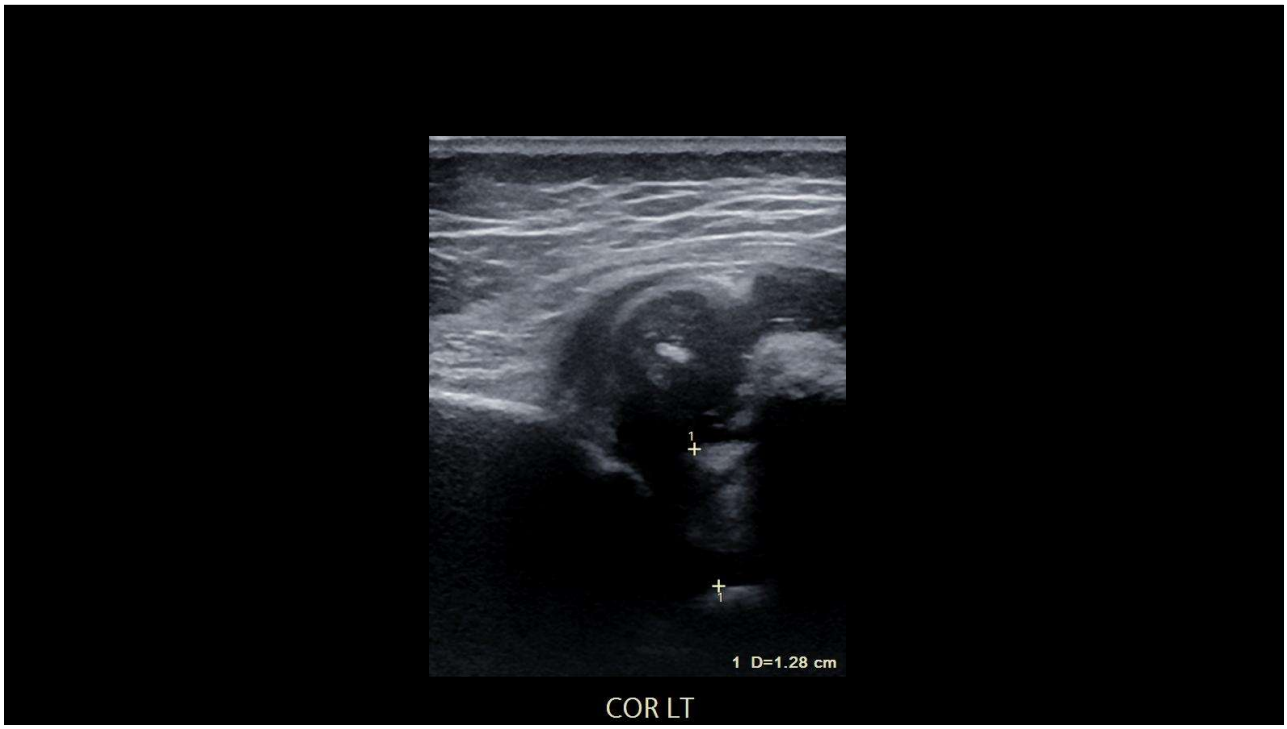

91

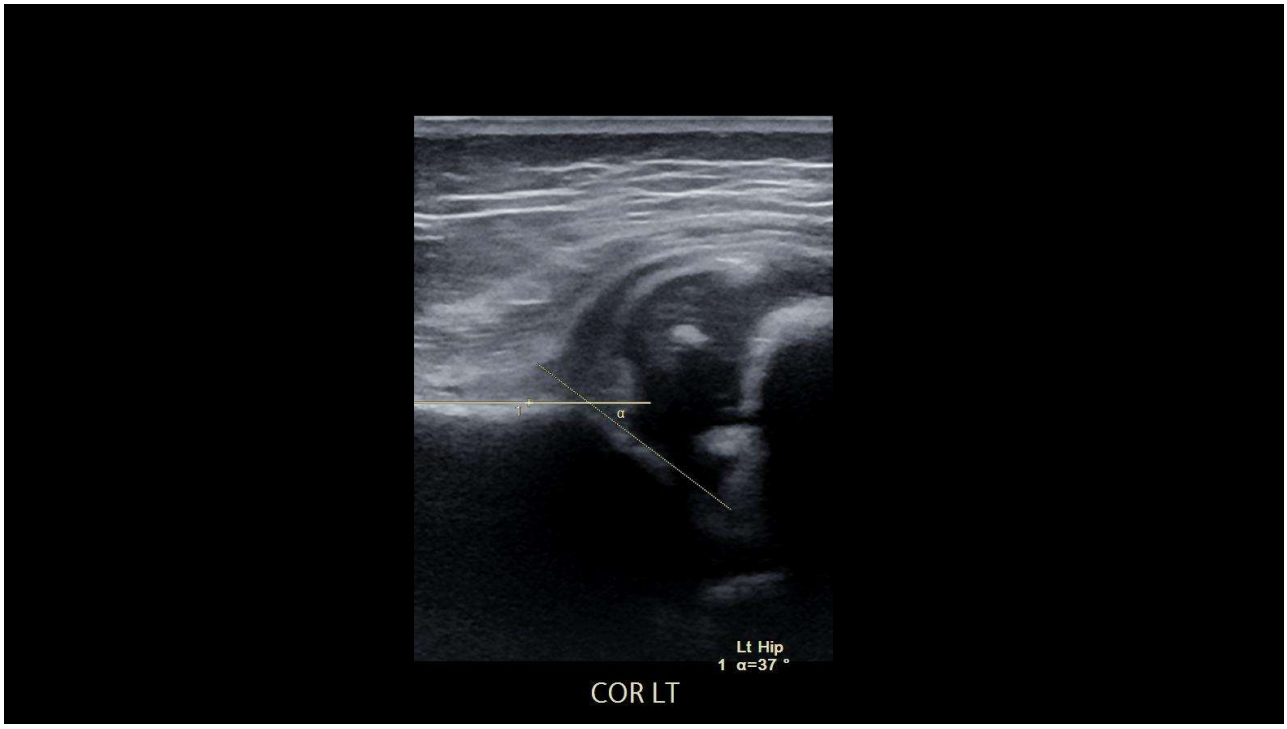

92

© Copyright. Society of Diagnostic Medical Sonography. All Rights Reserved.

2026 SDMS Annual Conference

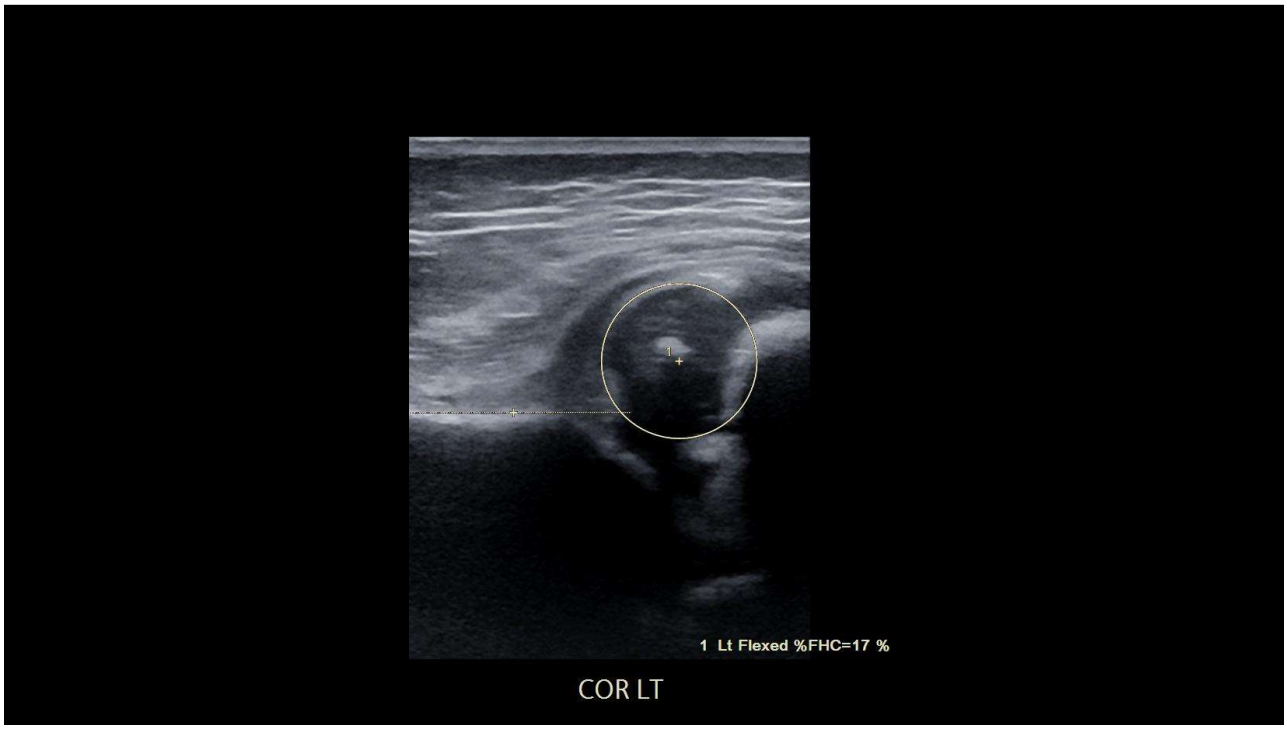

93

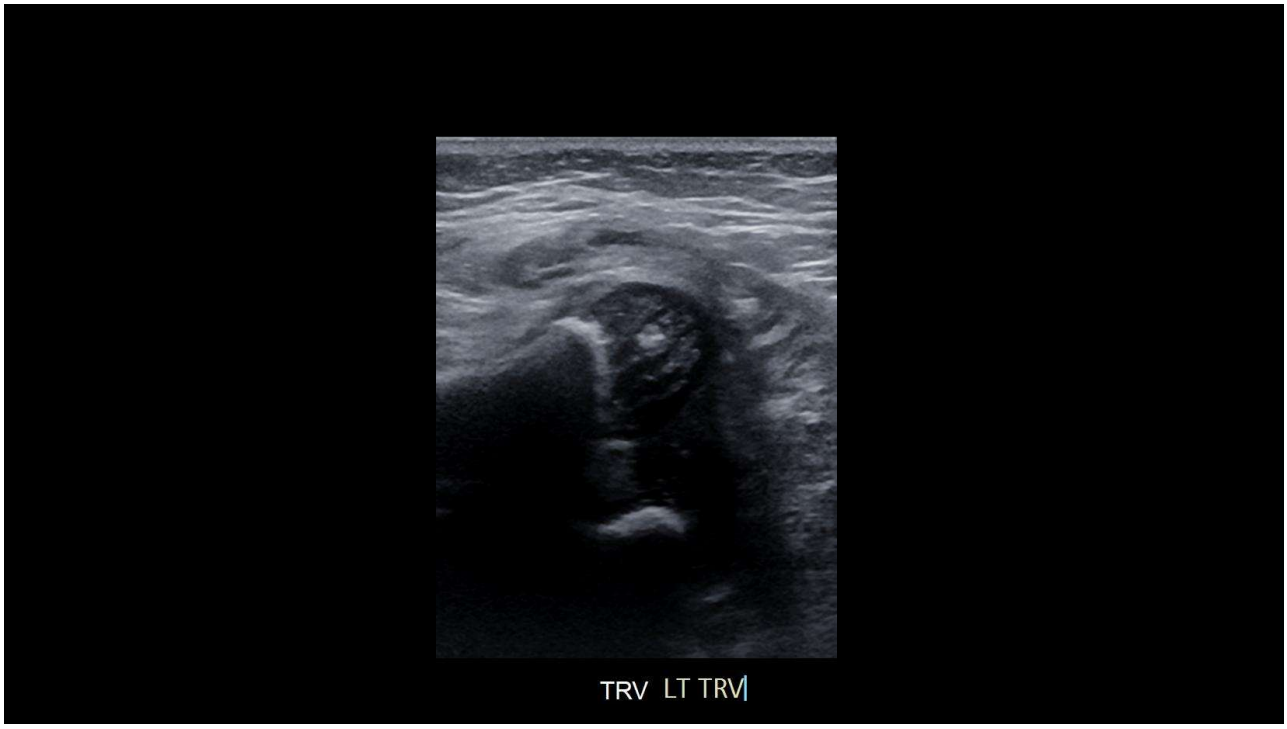

94

© Copyright. Society of Diagnostic Medical Sonography. All Rights Reserved.

2 ½ weeks later…



RIGHT

95

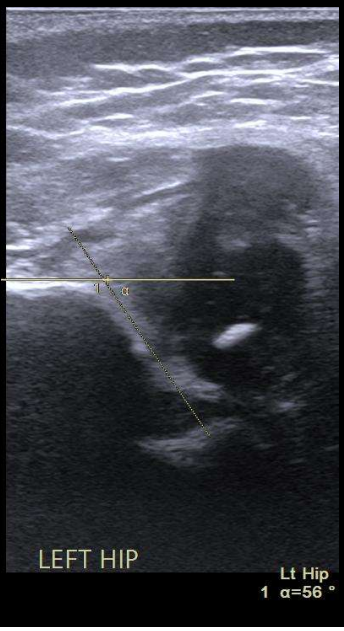

96

© Copyright. Society of Diagnostic Medical Sonography. All Rights Reserved.

3 weeks later…

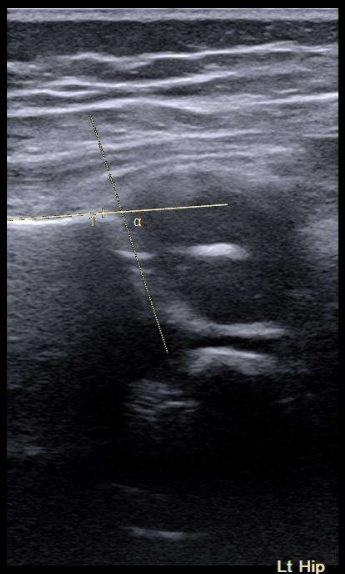

97

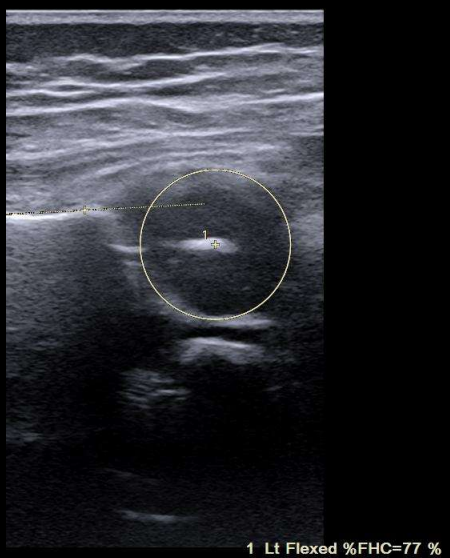

98

© Copyright. Society of Diagnostic Medical Sonography. All Rights Reserved.

2026 SDMS Annual Conference



99

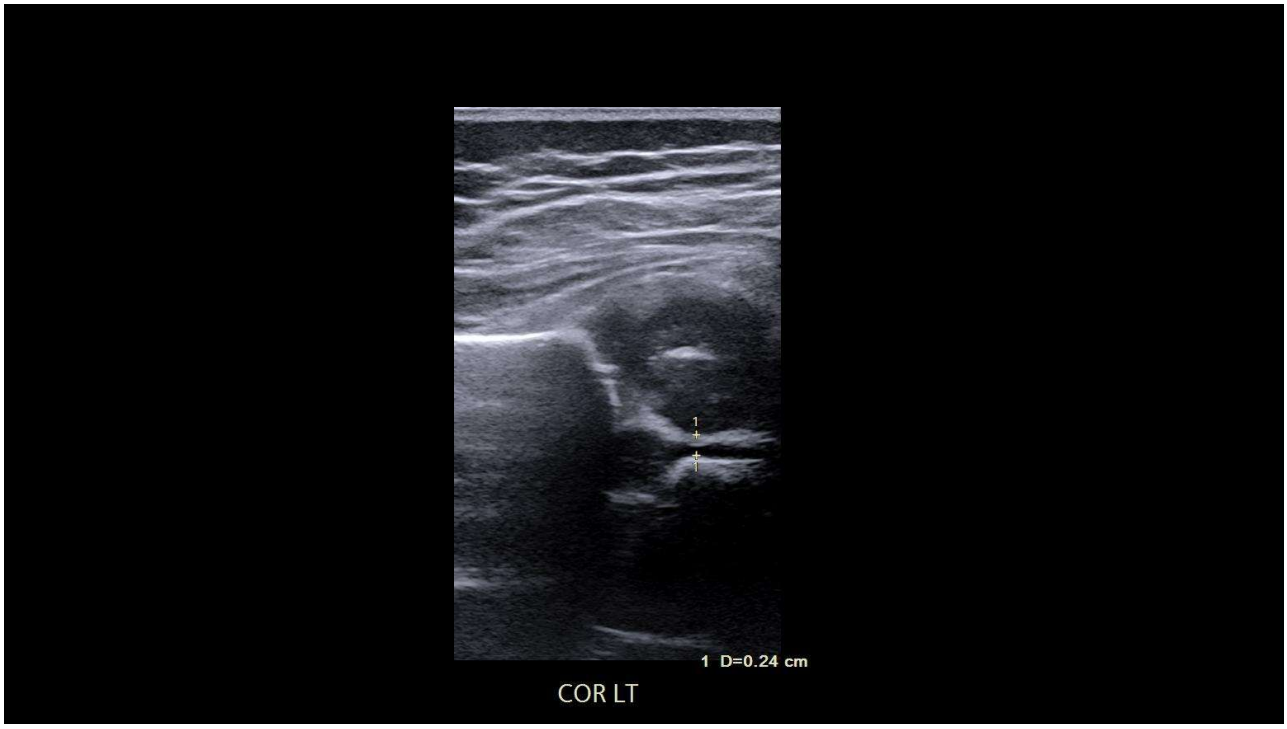

100

© Copyright. Society of Diagnostic Medical Sonography. All Rights Reserved.

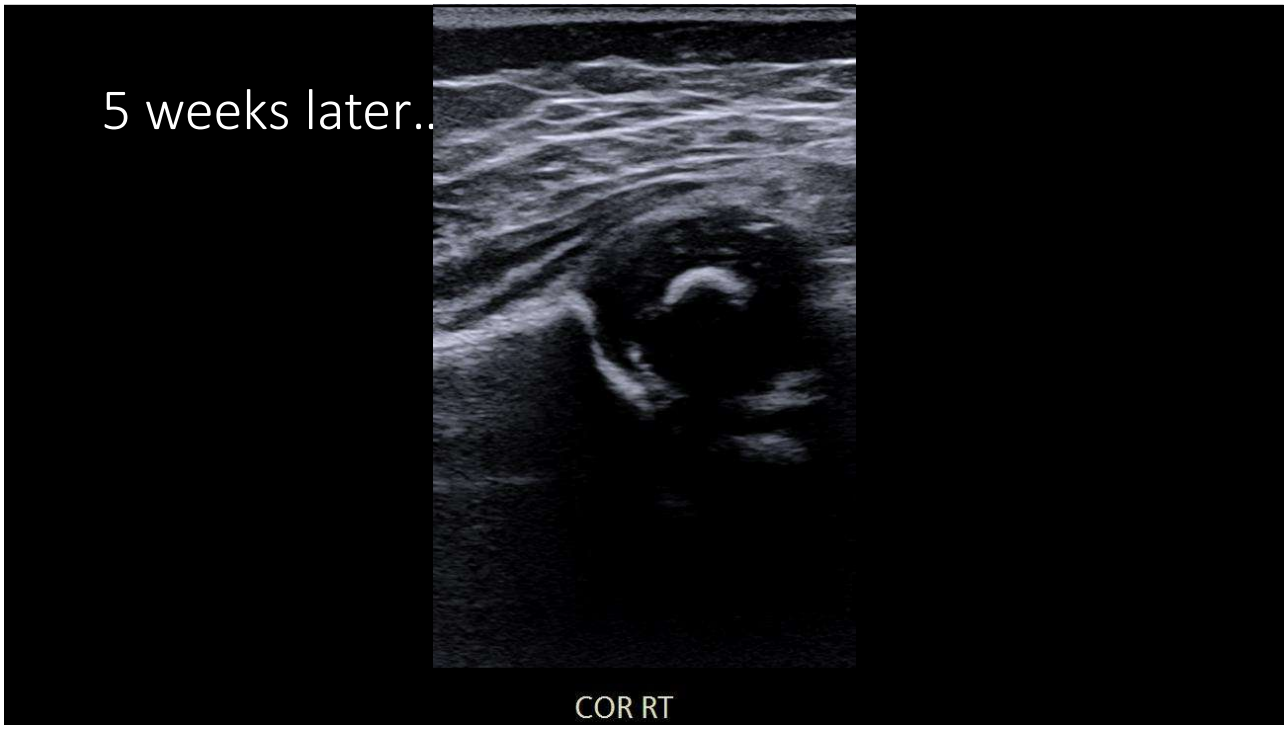

101

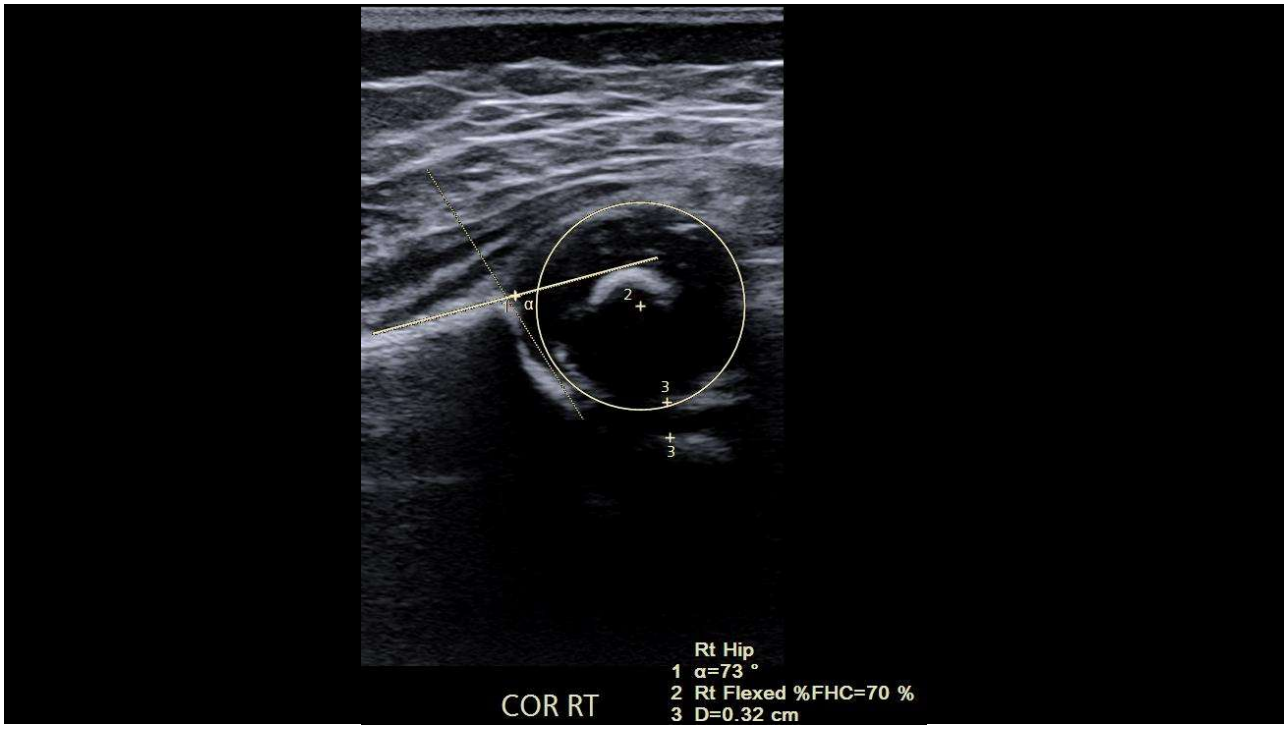

102

© Copyright. Society of Diagnostic Medical Sonography. All Rights Reserved.

2026 SDMS Annual Conference

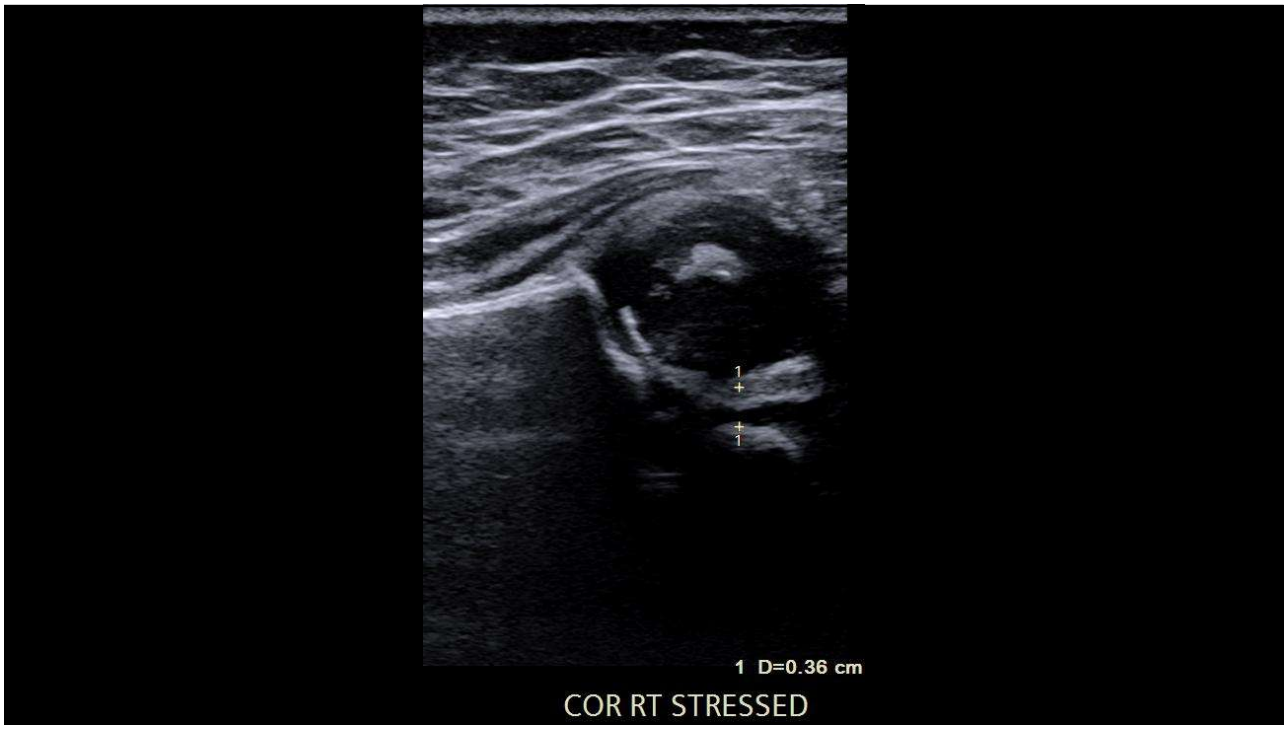

103

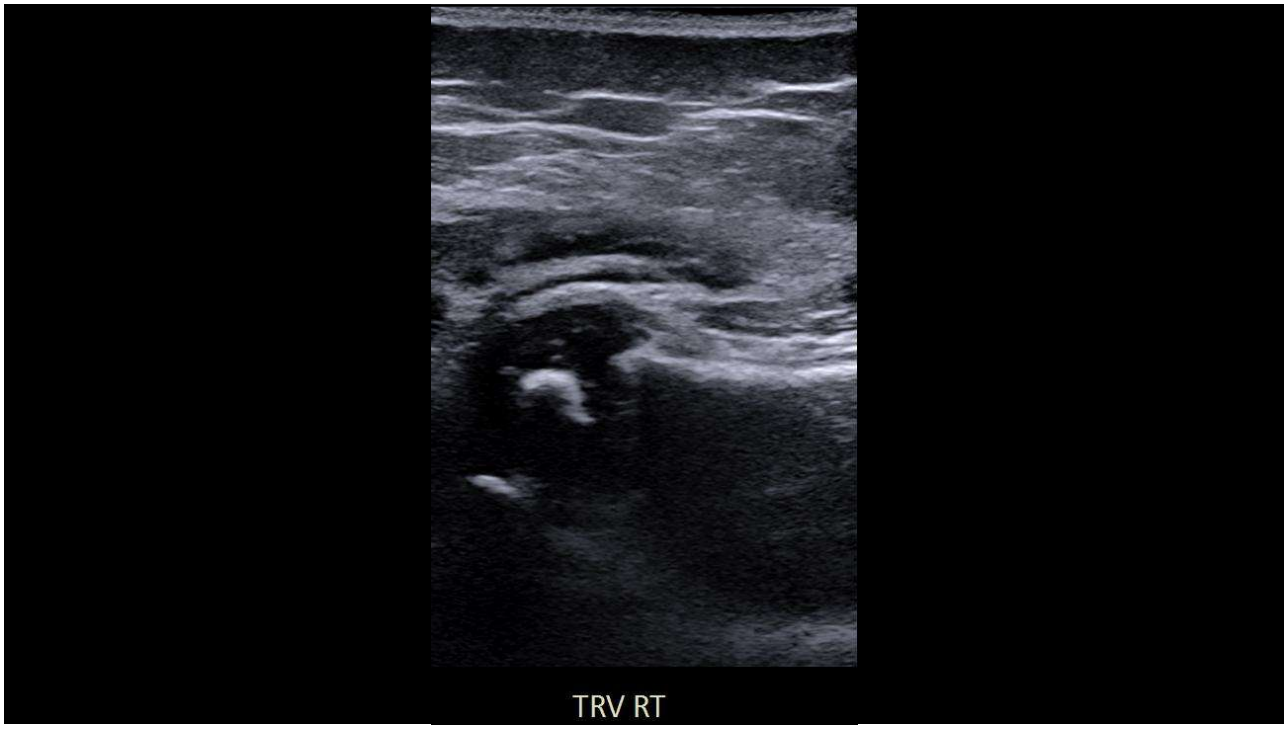

104

© Copyright. Society of Diagnostic Medical Sonography. All Rights Reserved.

2026 SDMS Annual Conference

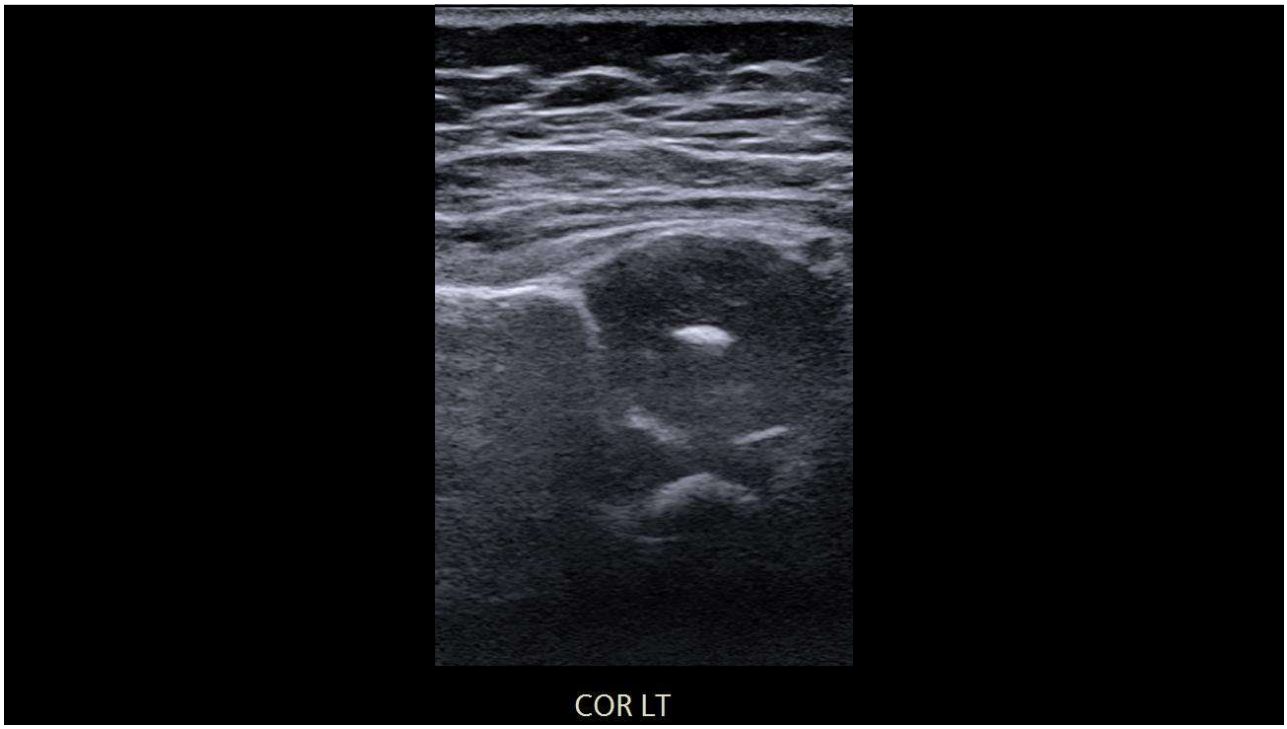

105

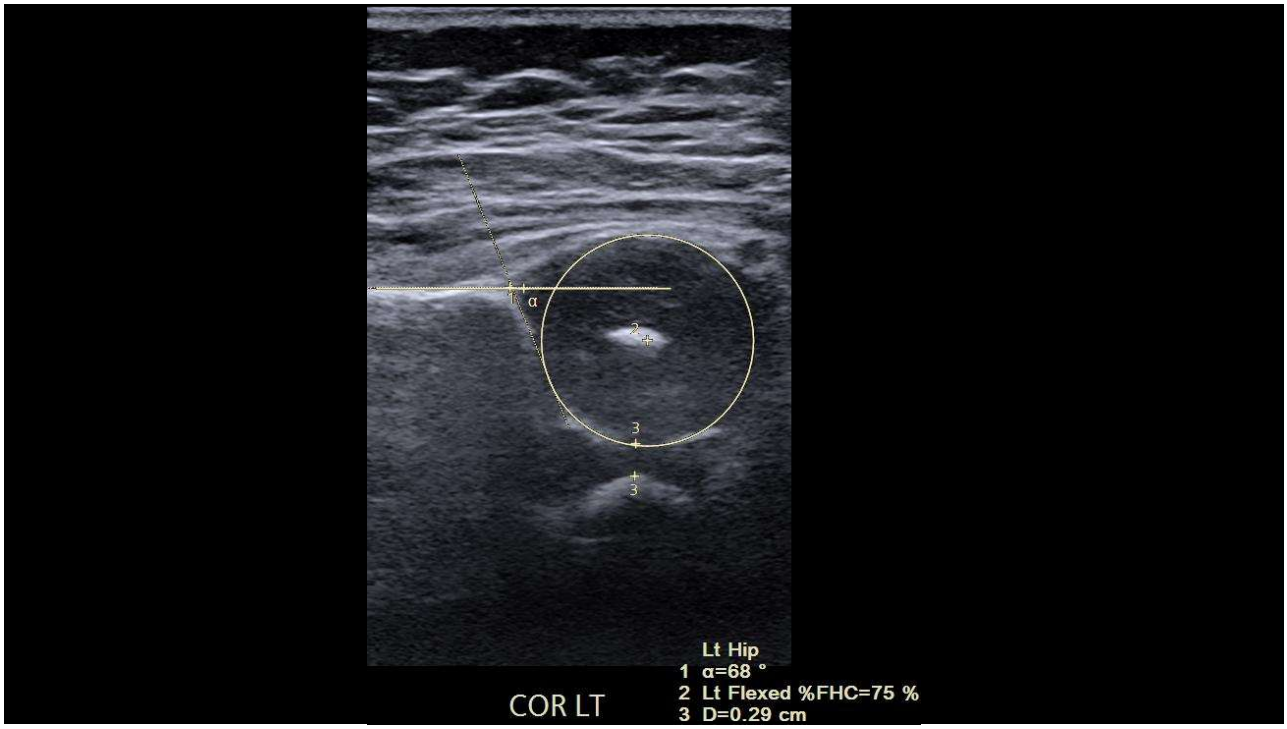

106

© Copyright. Society of Diagnostic Medical Sonography. All Rights Reserved.

2026 SDMS Annual Conference

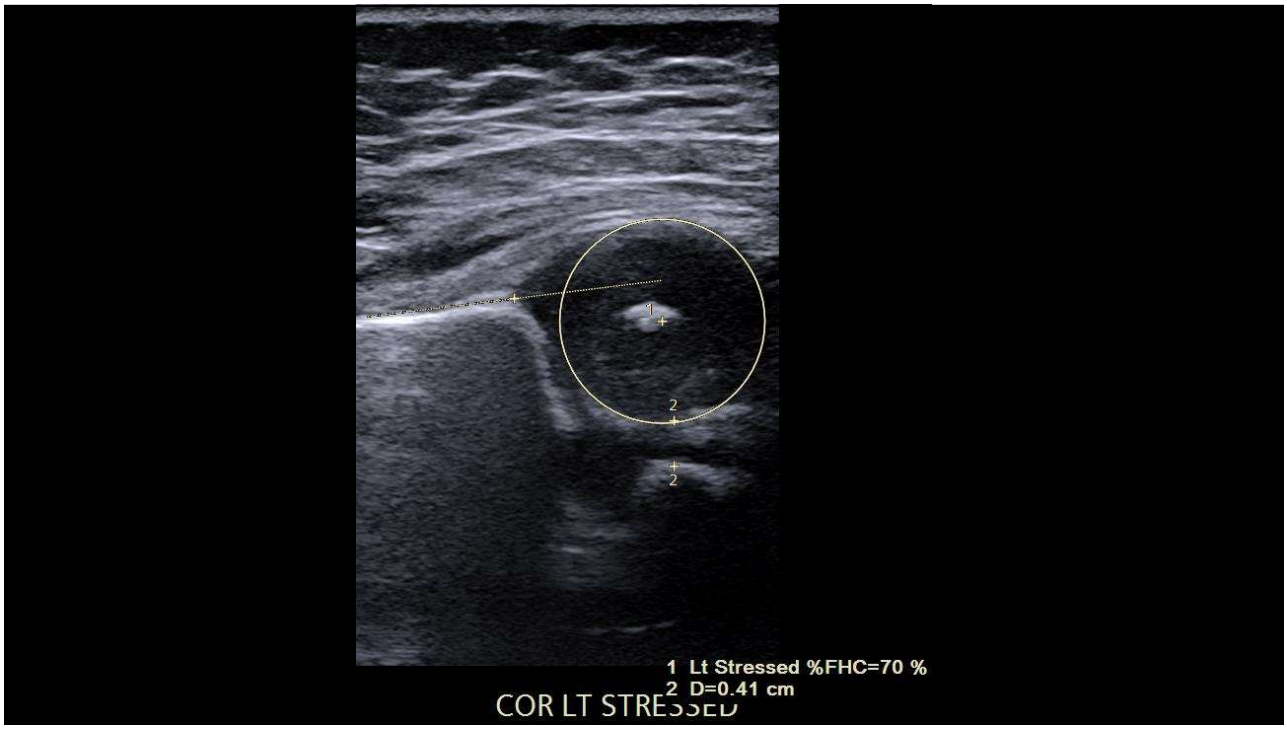

107

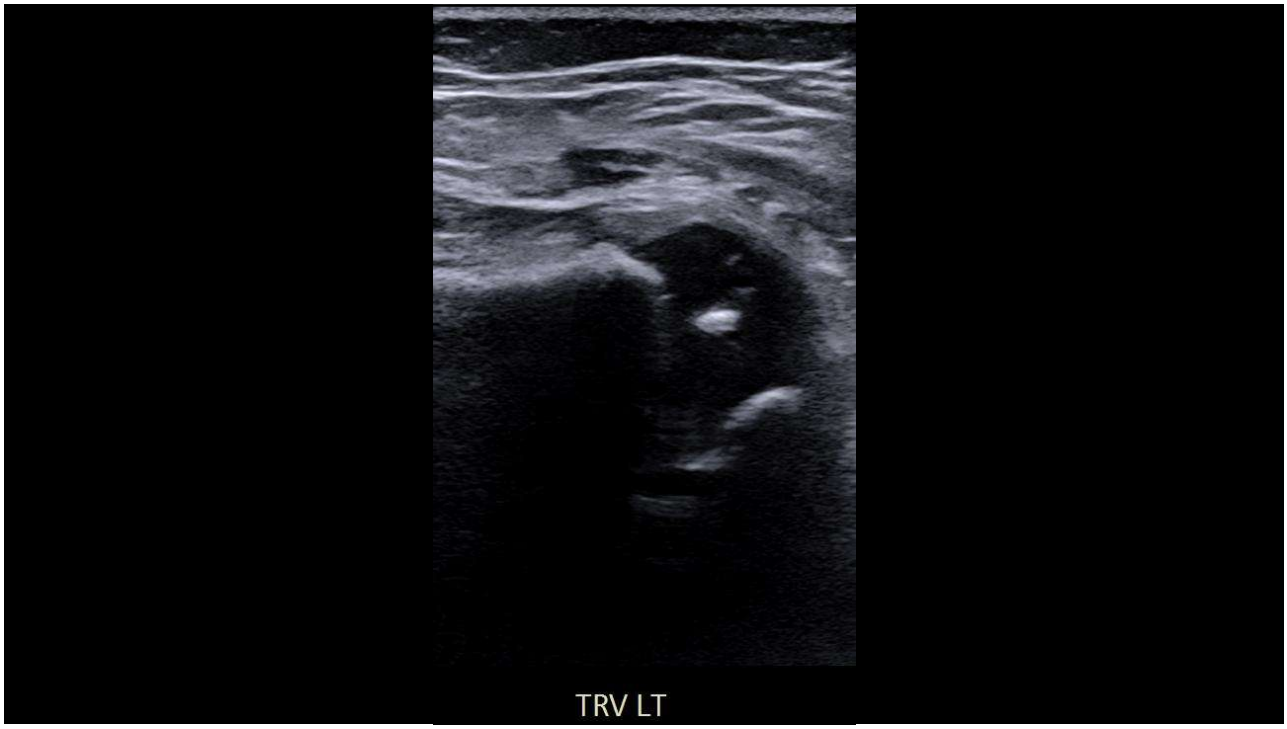

108

© Copyright. Society of Diagnostic Medical Sonography. All Rights Reserved.

BE CAREFUL!!

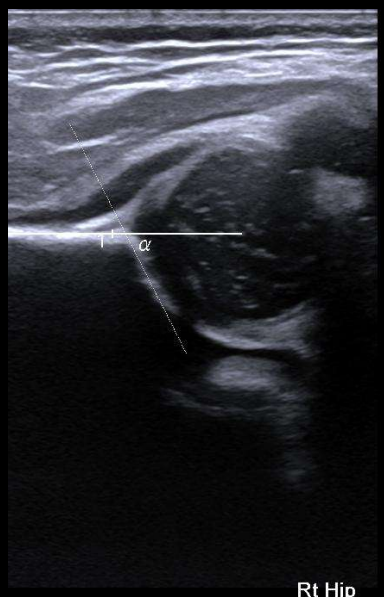

109



110

© Copyright. Society of Diagnostic Medical Sonography. All Rights Reserved.

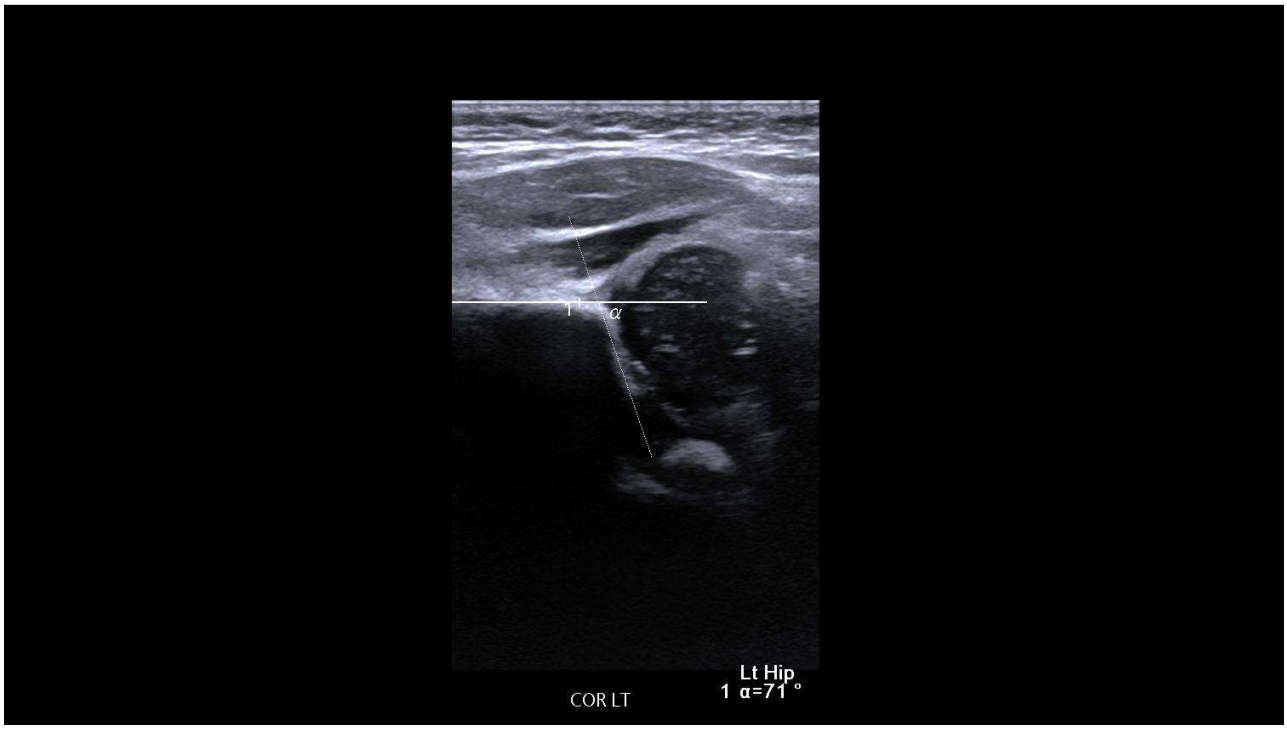

111

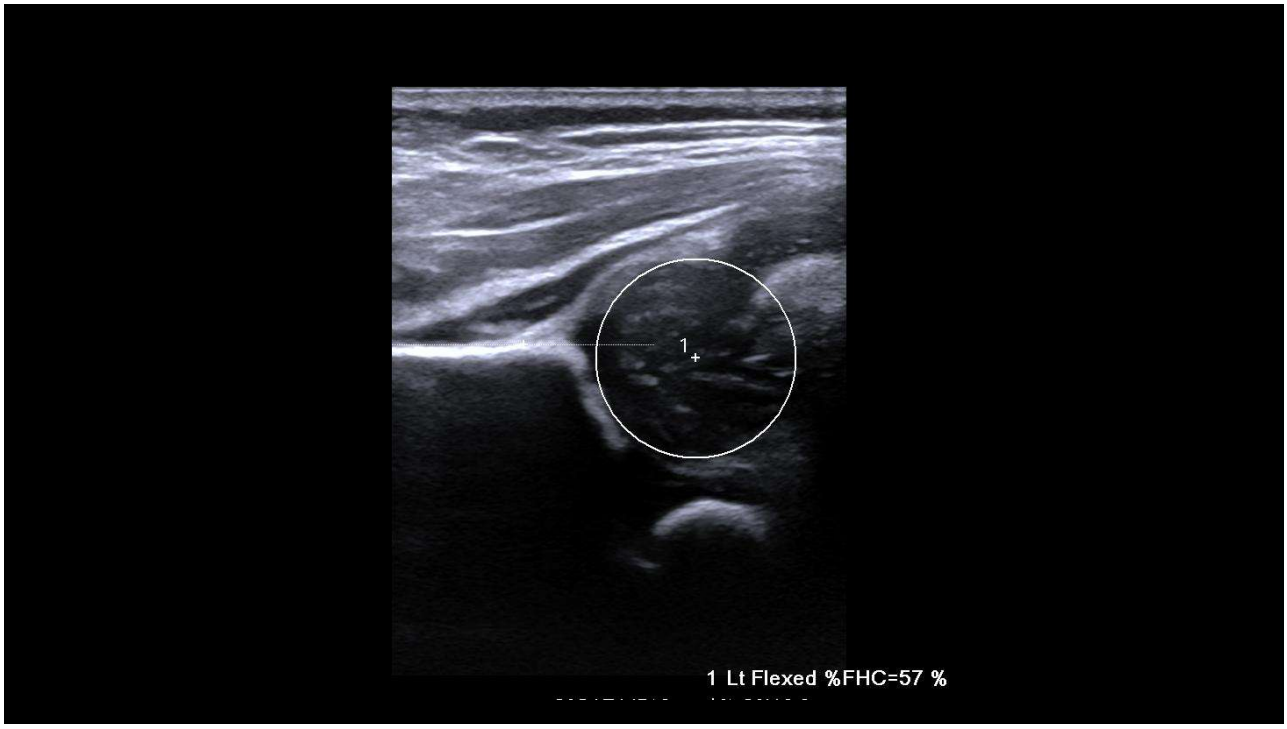

112

© Copyright. Society of Diagnostic Medical Sonography. All Rights Reserved.

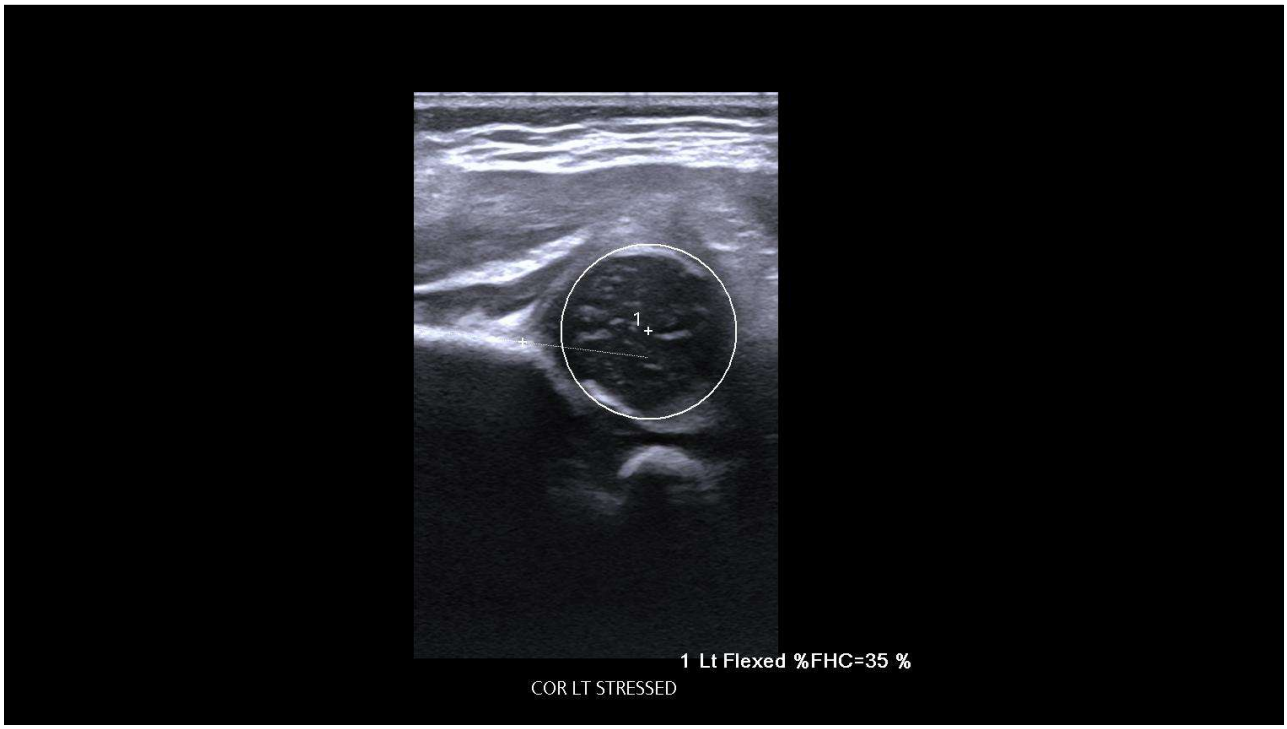

113

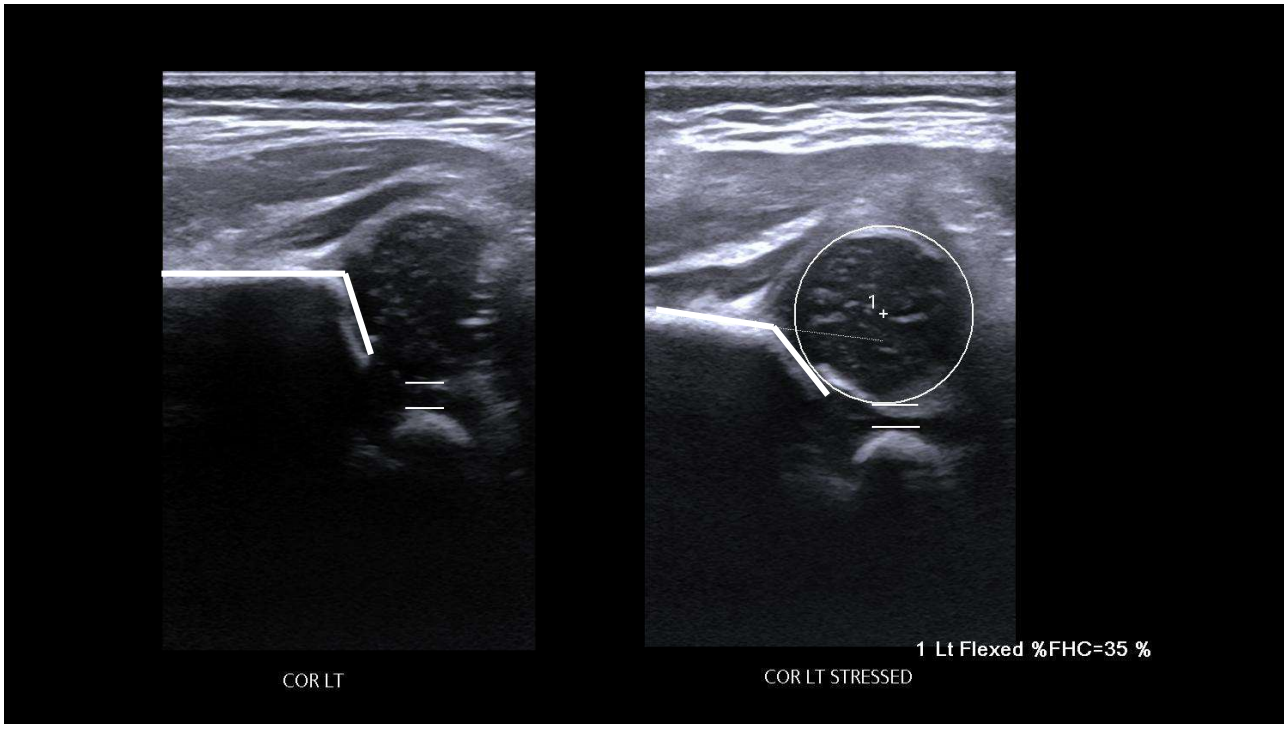

114

© Copyright. Society of Diagnostic Medical Sonography. All Rights Reserved.

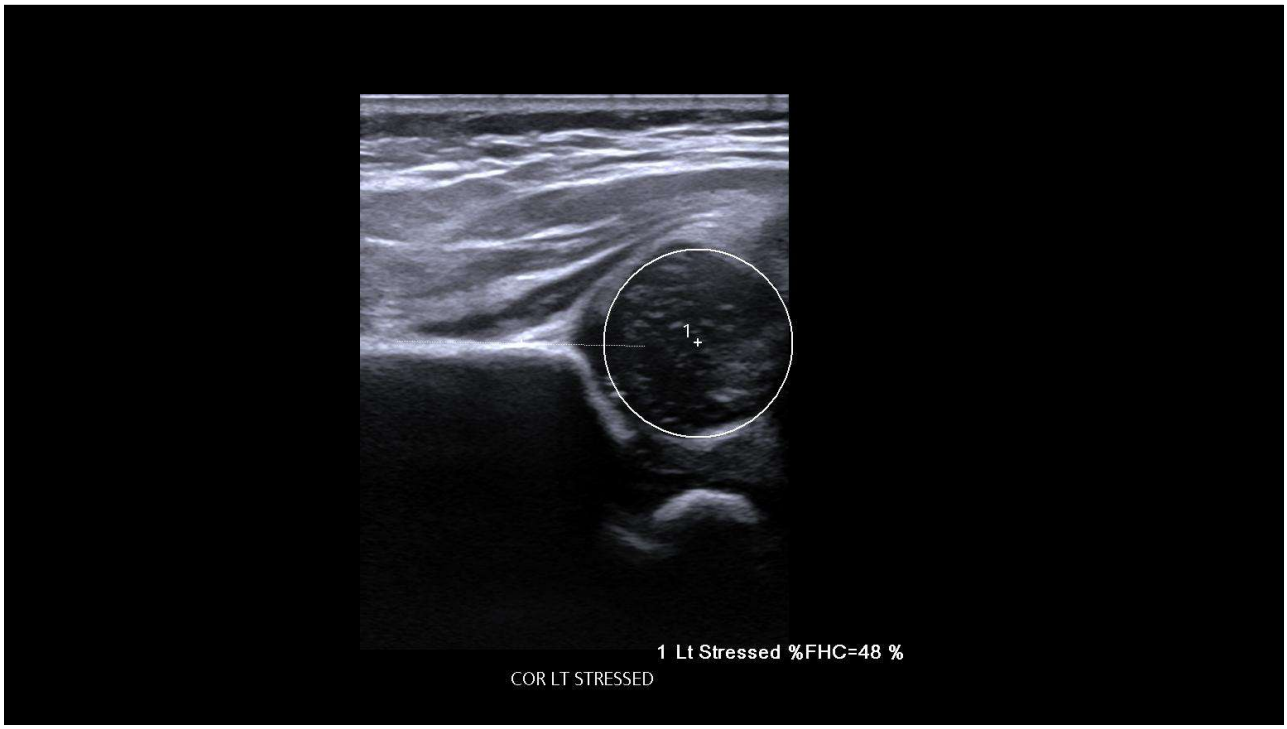

115



116

© Copyright. Society of Diagnostic Medical Sonography. All Rights Reserved.

EVALUATION OF THE PEDIATRIC HIP FOR EFFUSION

117

HIP ANATOMY

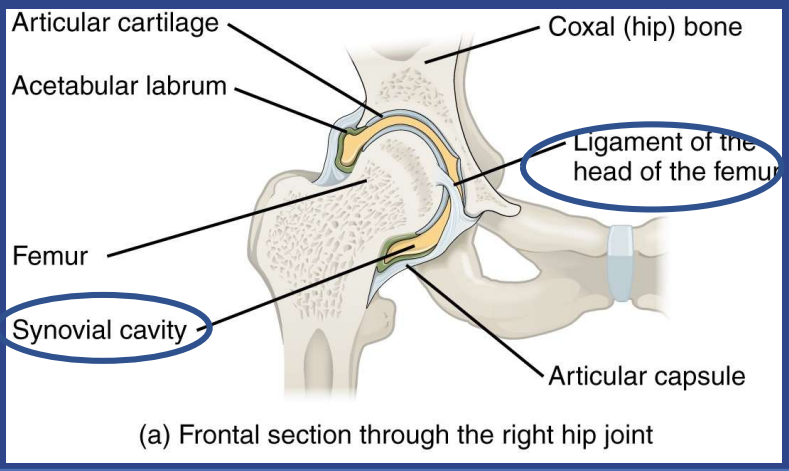

https://commons.wikimedia.org/wiki/File:916_Hip_Joint.jpg –accessed 7/6/23

118

© Copyright. Society of Diagnostic Medical Sonography. All Rights Reserved.

TRANSDUCER POSITION

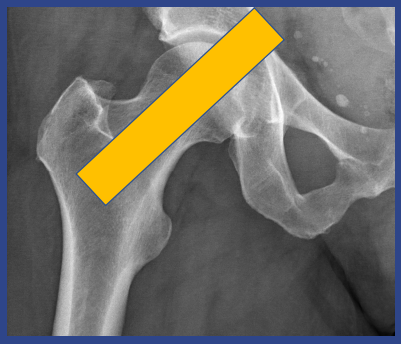

https://commons.wikimedia.org/wiki/File:X-ray_of_a_normal_hip.jpg –accessed 7/6/23

119

EVALUATION OF THE PEDIATRIC HIP FOR EFFUSION

- Evaluate both hips
- Traditional demonstration of a hip effusion is in the long axis plane
- May want to survey the hip joint in the short axis plane, especially if no effusion is seen in the symptomatic hip
- If an effusion is seen, an AP measurement of the fluid is helpful
- Abnormal is >5mm or >2mm difference compared to contralateral side (this measurement includes the synovium and fluid combined)
- Sonography is generally unable to differentiate between a septic and a sterile effusion

120

© Copyright. Society of Diagnostic Medical Sonography. All Rights Reserved.

MEASUREMENT

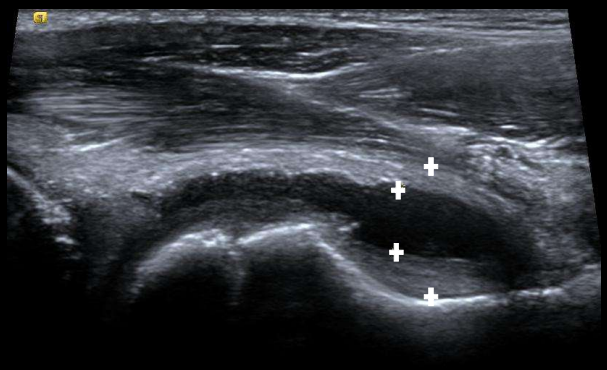

121

STERILE EFFUSION

- Also called transient synovitis
- Symptoms are usually milder
- Assumed to be a post viral syndrome
- Usually don't have significant pain on palpation
- Limping may be less
- Much more common, but is usually diagnosed by excluding septic arthritis

122

© Copyright. Society of Diagnostic Medical Sonography. All Rights Reserved.



123

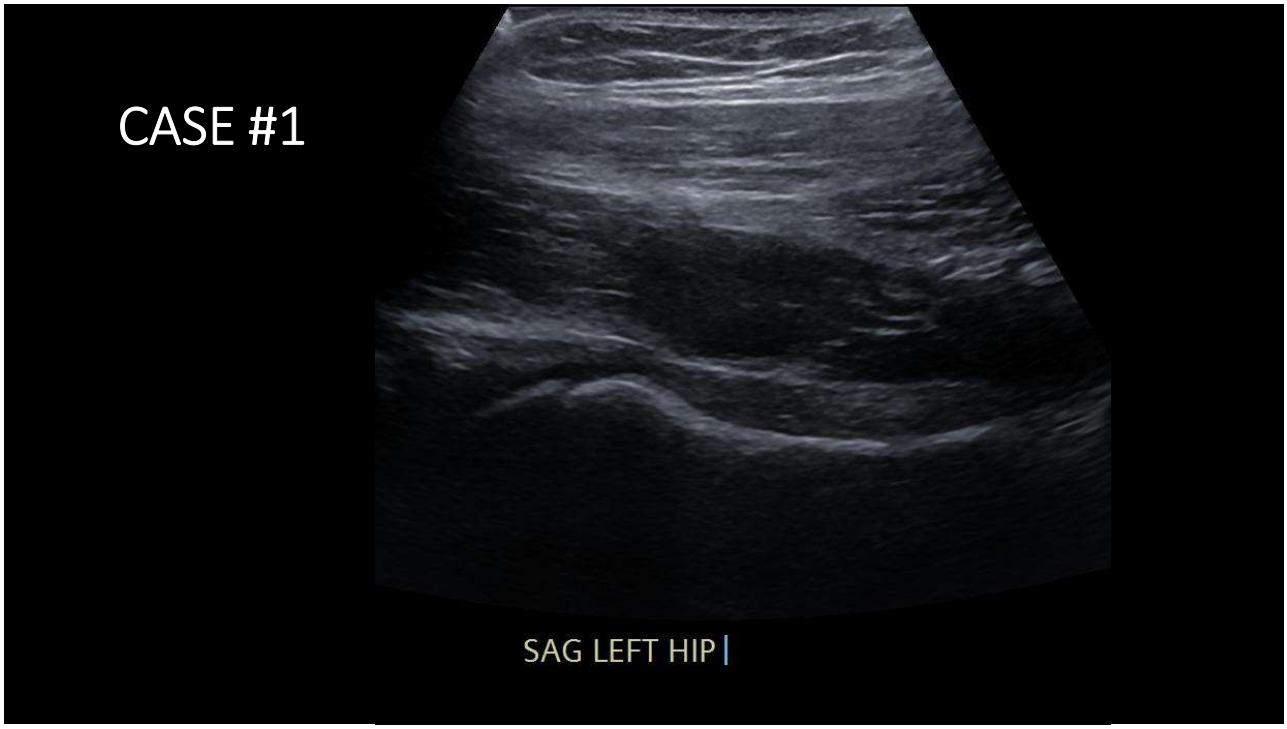

124

© Copyright. Society of Diagnostic Medical Sonography. All Rights Reserved.



125

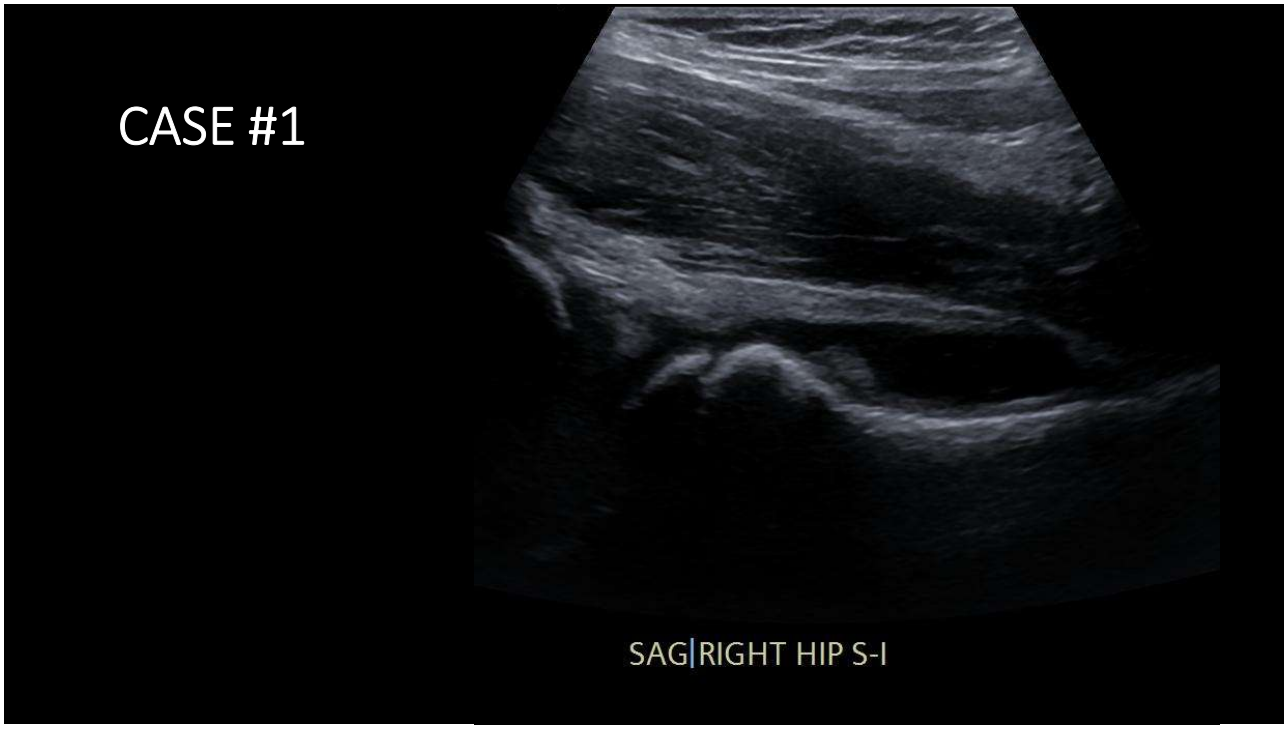

126

© Copyright. Society of Diagnostic Medical Sonography. All Rights Reserved.



127

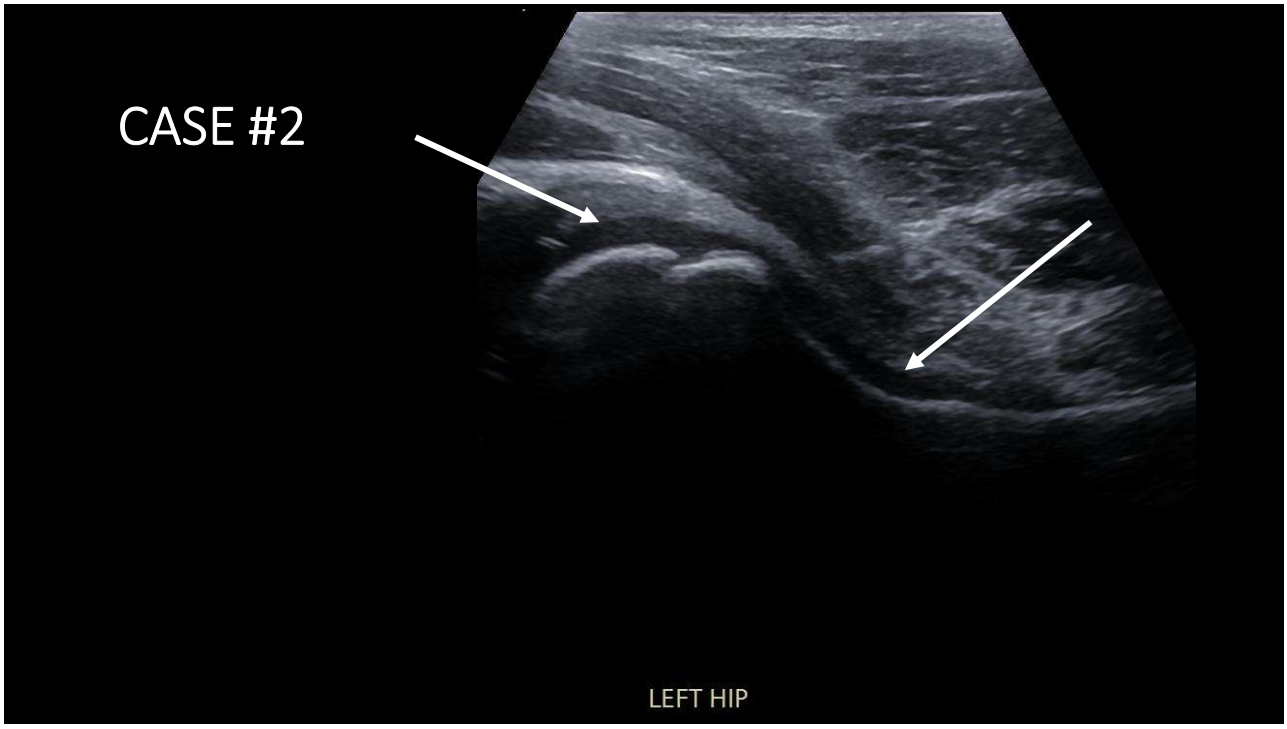

128

© Copyright. Society of Diagnostic Medical Sonography. All Rights Reserved.



129

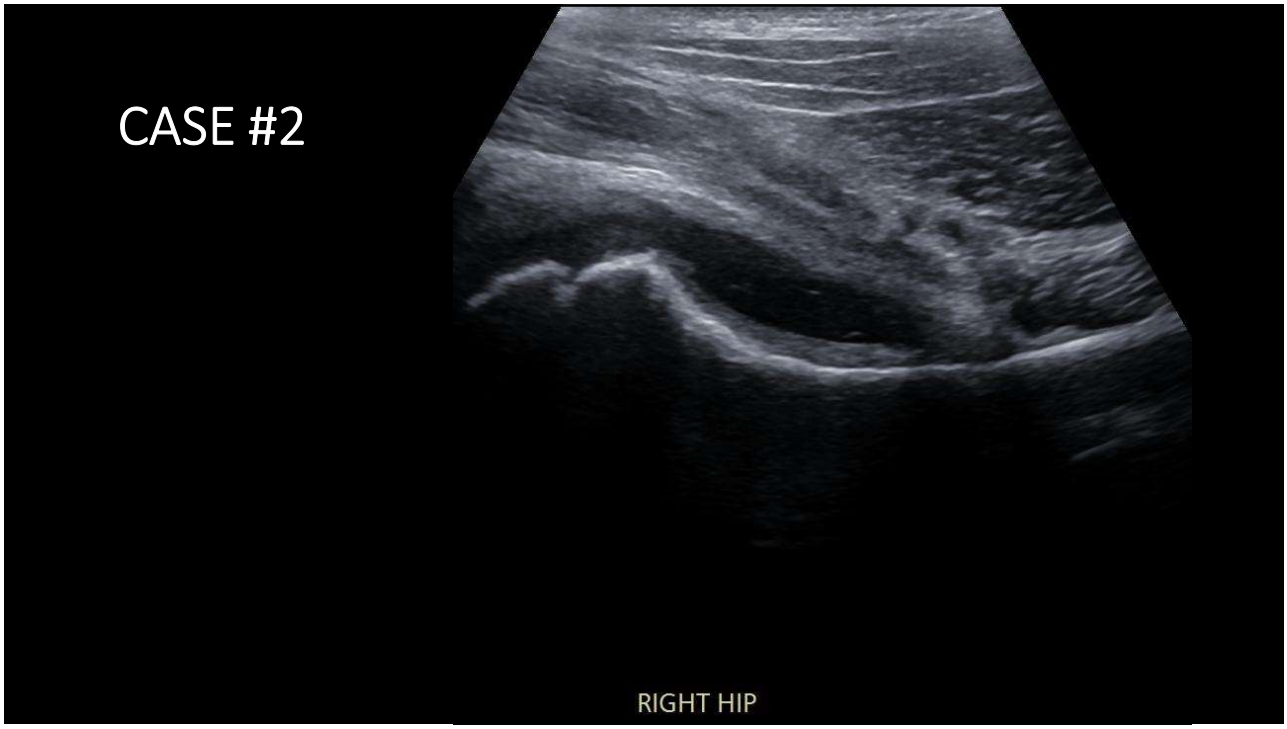

130

© Copyright. Society of Diagnostic Medical Sonography. All Rights Reserved.

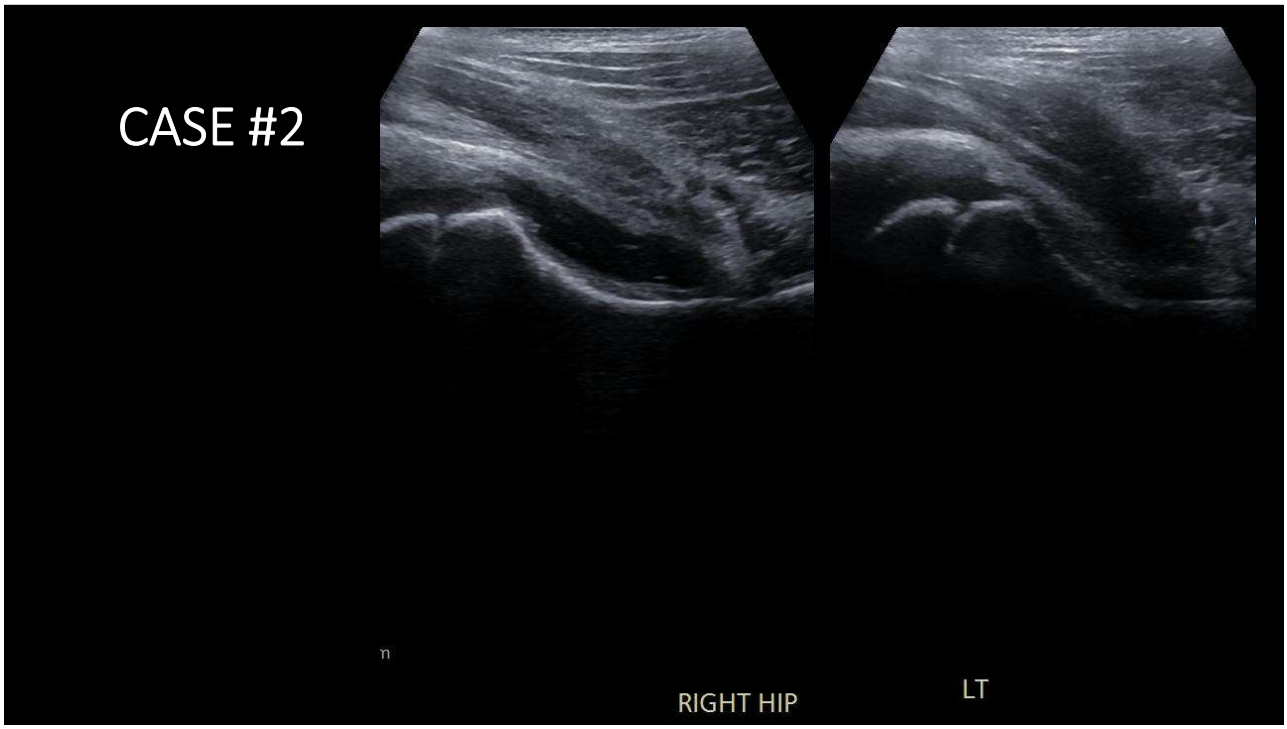

131

SEPTIC ARTHRITIS

- A true **surgical emergency**
- Incidence peaks in the first few years of life
- 50% occur in children younger than 2 years old
- More common in males than females- 2:1 ratio
- Patient presents with acute onset of pain
- Patient has a fever and appears ill
- Limping or refusal to bear weight
- Severe pain with passive motion of the hip
- If there is clinical suspicion of a septic joint when effusion is found, aspiration, lab analysis, and antibiotic treatment may be necessary

132

© Copyright. Society of Diagnostic Medical Sonography. All Rights Reserved.

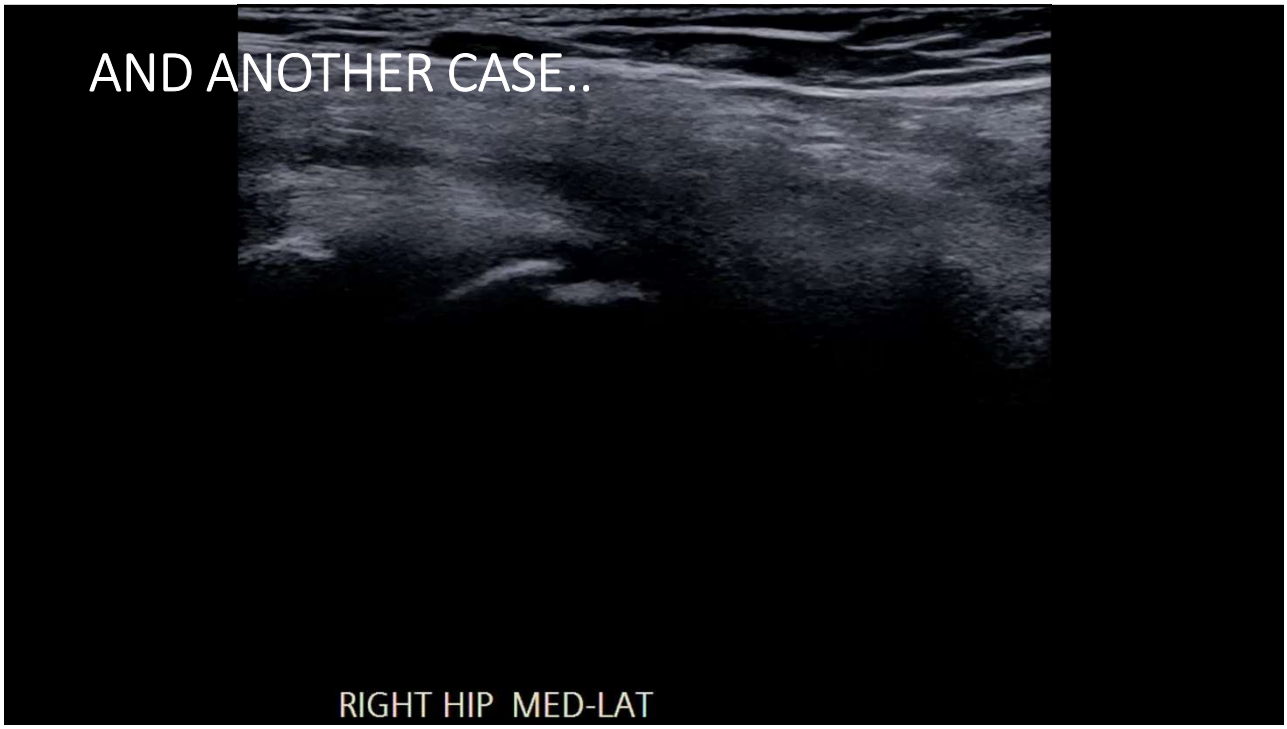

133

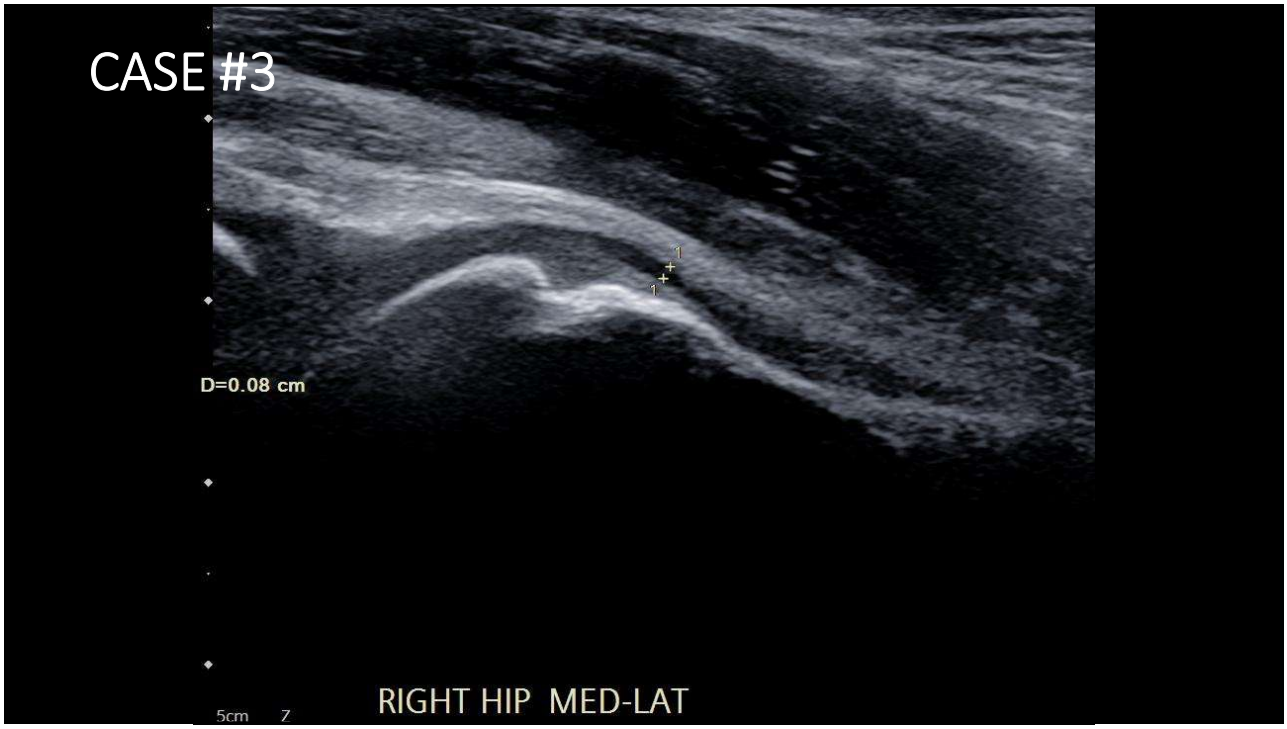

134

© Copyright. Society of Diagnostic Medical Sonography. All Rights Reserved.



135



136

© Copyright. Society of Diagnostic Medical Sonography. All Rights Reserved.

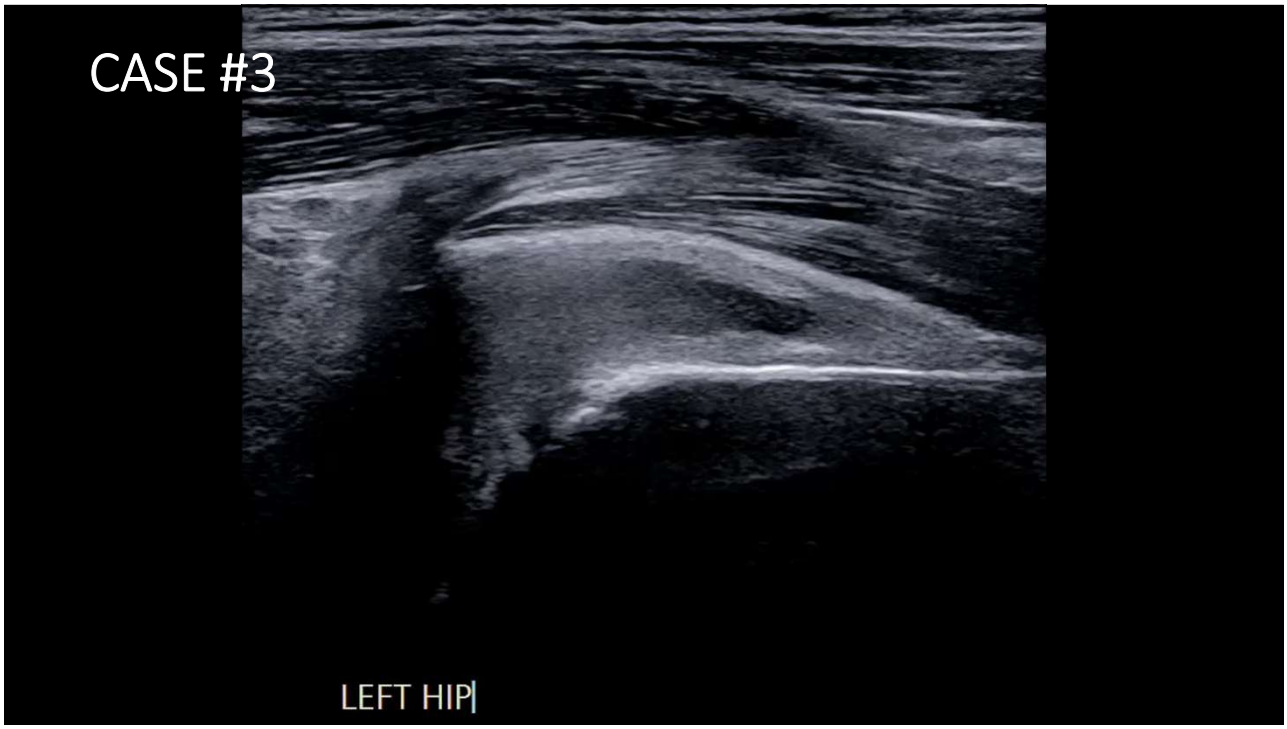

137

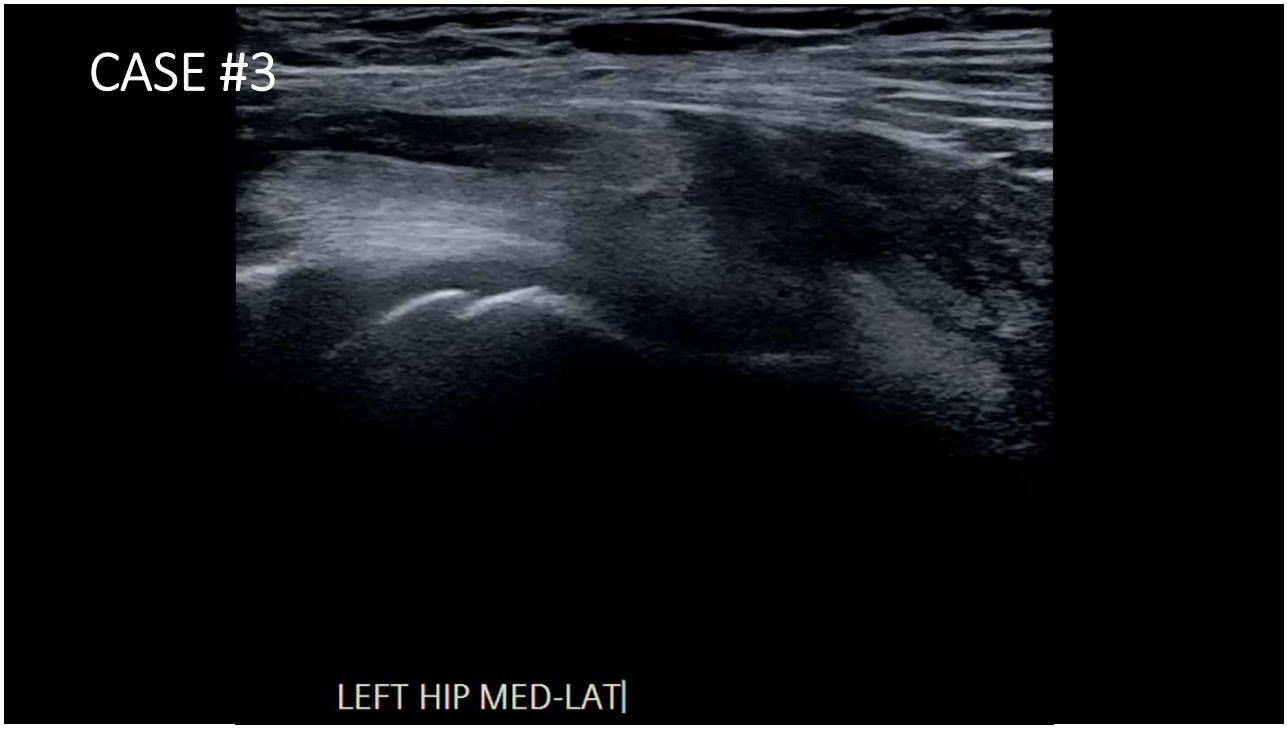

138

© Copyright. Society of Diagnostic Medical Sonography. All Rights Reserved.

I hope this has been helpful



https://en.wikipedia.org/wiki/Infant#/media/File:Baby_Face.JPG

139

References

1. Nandhagopal T, De Cicco FL. Developmental Dysplasia Of The Hip. [Updated 2022 Oct 3]. In: StatPearls [Internet]. Treasure Island (FL): StatPearls Publishing; 2023 Jan-. Available from: https://www.ncbi.nlm.nih.gov/books/NBK563157/
2. Zaghloul A, Mohamed EM. Hip Joint: Embryology, Anatomy and Biomechanics. Biomed J Sci & Tech Res. 2018; 12(3). 10.26717/BJSTR.2018.12.002267
3. Upton, A and Whitten, T. "Neonatal Brain, Spine, and Hip Scanning Protocols." Sonography Scanning- Principles and Protocols, edited by M. Robert DeJong, Elsevier, 2021, pages 481- 489.

140

© Copyright. Society of Diagnostic Medical Sonography. All Rights Reserved.

References

4. https://gravitas.acr.org/PPTS/GetDocumentView?docId=27 – accessed 8/10/2026
5. Guarniero R. DYSPLASIA OF HIP DEVELOPMENT: UPDATE. Rev Bras Ortop. 2015 Nov 16;45(2):116-21. doi: 10.1016/S2255-4971(15)30279-2. PMID: 27022528; PMCID: PMC4799082.

141

Other resources

- Ultrasound Training: Pediatric Hip and Spine
  - Basic images and measurements
  - https://www.youtube.com/watch?v=T57sN3SGAes
- Sonography of the Pediatric Hip
  - https://www.youtube.com/watch?v=Lue64bE5Rtg
- Developmental Dysplasia of the Hip – Dr. Matthew Halsey
  - https://www.youtube.com/watch?v=ZqRKwy20d00
- Infant Hip- www.SDMS.org Free Educational Content if you're a member

142

142

© Copyright. Society of Diagnostic Medical Sonography. All Rights Reserved.

THANK YOU!

Email address: tedwhittensr@gmail.com

© Copyright. Society of Diagnostic Medical Sonography. All Rights Reserved.